

## Submission Confirmation

---

From: Veterinary World (vetworld@ejmanager.com)

To: rma\_fispro@yahoo.com

Date: Wednesday, July 27, 2016 at 05:41 PM GMT+7

---

Dear Erma Safitri,

Your submission entitled **THE INDONESIAN BEE S HONEY CAN INDUCE ENDOGENOUS STEM CELLS IN REGENERATION OF OVARY DAMAGE DUE TO MALNUTRITION** (Manuscript Number: VETWORLD-2016-07-379) has been received by **Veterinary World**.

You could follow status of your manuscript by login to your author account at [www.ejmanager.com](http://www.ejmanager.com).

Thank you for submitting your work to our journal.

Best regards,

Editor  
Veterinary World  
<http://www.veterinaryworld.org>

-----  
**NEWS:**

1. Veterinary World is indexed in Emerging Sources Citation Index (ESCI) - Web of Science of Thomson Reuters. <http://science.thomsonreuters.com/cgi-bin/jrnlst/jlresults.cgi?PC=EX&SC=ZC>
2. Veterinary World is indexed in PubMed and PubMed Central. <http://www.ncbi.nlm.nih.gov/nlmcatalog/101504872>
3. A new, prestigious journal, International Journal of One Health ([www.onehealthjournal.org](http://www.onehealthjournal.org)) was launched in early 2015 by Veterinary World.

---

<http://www.scopemed.org>

[Author Login Page](#)

[Reviewer Login Page](#)

[Follow scopemed/ejmanager on twitter](#)

[Index of Fulltext Journals](#)

## Re: Submission Confirmation

---

From: Safitri Erma (rma\_fispro@yahoo.com)  
To: vetworld@ejmanager.com  
Date: Monday, August 8, 2016 at 09:13 PM GMT+7

---

Dear Editor

Please give me information estimated time of the review result my manuscript entitled : **THE INDONESIAN BEES HONEY CAN INDUCE ENDOGENOUS STEM CELLS IN REGENERATION OF OVARY DAMAGE DUE TO MALNUTRITION** (Manuscript Number: VETWORLD-2016-07-379) has been sent to **Veterinary World**

Thank's for your cooperation  
Dr. Erma Safitri, DVM., M.Si.

On Wednesday, July 27, 2016 5:41 PM, Veterinary World <vetworld@ejmanager.com> wrote:

Dear Erma Safitri,

Your submission entitled **THE INDONESIAN BEES HONEY CAN INDUCE ENDOGENOUS STEM CELLS IN REGENERATION OF OVARY DAMAGE DUE TO MALNUTRITION** (Manuscript Number: VETWORLD-2016-07-379) has been received by **Veterinary World**.

You could follow status of your manuscript by login to your author account at [www.ejmanager.com](http://www.ejmanager.com).

Thank you for submitting your work to our journal.

Best regards,

Editor  
Veterinary World  
<http://www.veterinaryworld.org>

-----  
NEWS:

1. Veterinary World is indexed in Emerging Sources Citation Index (ESCI) - Web of Science of Thomson Reuters. <http://science.thomsonreuters.com/cgi-bin/jrnlst/jlresults.cgi?PC=EX&SC=ZC>
2. Veterinary World is indexed in PubMed and PubMed Central. <http://www.ncbi.nlm.nih.gov/nlmcatalog/101504872>
3. A new, prestigious journal, International Journal of One Health ([www.onehealthjournal.org](http://www.onehealthjournal.org)) was launched in early 2015 by Veterinary World.

---

<http://www.scopemed.org>  
[Author Login Page](#)  
[Reviewer Login Page](#)  
[Follow scopemed/ejmanager on twitter](#)  
[Index of Fulltext Journals](#)

## Re: Submission Confirmation

---

From: Veterinary World (editorveterinaryworld@gmail.com)

To: rma\_fispro@yahoo.com

Date: Tuesday, August 9, 2016 at 12:25 PM GMT+7

---

Dear Dr.

Usually review process completed by reviewers within 6-8 weeks but there may be more or less than this time according to spare time of reviewers. We will pass on the reviewers comments to you by system generated email when we receive it.

### **NEWS:**

1. Veterinary World is indexed in Emerging Sources Citation Index (ESCI) - Web of Science of Thomson Reuters. <http://science.thomsonreuters.com/cgi-bin/jrnlst/jlresults.cgi?PC=EX&SC=ZC>
2. Veterinary World is indexed in PubMed and PubMed Central. <http://www.ncbi.nlm.nih.gov/nlmcatalog/101504872>
3. A new, prestigious journal, International Journal of One Health ([www.onehealthjournal.org](http://www.onehealthjournal.org)) was launched in early 2015 by Veterinary World.

-----  
Best Regards,

Dr. Anjum Sherasiya  
Editor-in-Chief  
Veterinary World  
Star, Gulshan Park, NH-8A,  
Chandrapur Road, Wankaner - 363621,  
Dist. Morbi (Gujarat), India.  
Website: [www.veterinaryworld.org](http://www.veterinaryworld.org), [onehealthjournal.org](http://onehealthjournal.org)  
E-mail: [editorveterinaryworld@gmail.com](mailto:editorveterinaryworld@gmail.com)

Follow us on

On Mon, Aug 8, 2016 at 7:43 PM, Safitri Erma <[rma\\_fispro@yahoo.com](mailto:rma_fispro@yahoo.com)> wrote:

Dear Editor

Please give me information estimated time of the review result my manuscript entitled  
**: THE INDONESIAN BEES HONEY CAN INDUCE ENDOGENOUS STEM CELLS  
IN REGENERATION OF OVARY DAMAGE DUE TO MALNUTRITION** (Manuscript Number: VETWORLD-2016-07-379) has  
been sent to **Veterinary World**

Thank's for your cooperation  
Dr. Erma Safitri, DVM., M.Si.

On Wednesday, July 27, 2016 5:41 PM, Veterinary World <[vetworld@ejmanager.com](mailto:vetworld@ejmanager.com)> wrote:

Dear Erma Safitri,

Your submission entitled **THE INDONESIAN BEES HONEY CAN INDUCE ENDOGENOUS STEM CELLS  
IN REGENERATION OF OVARY DAMAGE DUE TO MALNUTRITION** (Manuscript Number: VETWORLD-2016-07-379) has  
been received by **Veterinary World**.

You could follow status of your manuscript by login to your author account at [www.ejmanager.com](http://www.ejmanager.com).

Thank you for submitting your work to our journal.

Best regards,

Editor  
Veterinary World  
<http://www.veterinaryworld.org>

-----  
NEWS:

1. Veterinary World is indexed in Emerging Sources Citation Index (ESCI) - Web of Science of Thomson Reuters. <http://science.thomsonreuters.com/cgi-bin/jrnlst/jlresults.cgi?PC=EX&SC=ZC>
2. Veterinary World is indexed in PubMed and PubMed Central. <http://www.ncbi.nlm.nih.gov/nlmcatalog/101504872>
3. A new, prestigious journal, International Journal of One Health ([www.onehealthjournal.org](http://www.onehealthjournal.org)) was launched in early 2015 by Veterinary World.

---

<http://www.scopemed.org>

[Author Login Page](#)

[Reviewer Login Page](#)

[Follow scopemed/ejmanager on twitter](#)

[Index of Fulltext Journals](#)

## Re: Submission Confirmation

---

From: Safitri Erma (rma\_fispro@yahoo.com)

To: vetworld@ejmanager.com

Date: Friday, September 16, 2016 at 11:02 PM GMT+7

---

Dear Editor,

Please give me information about status of my manuscript.

Best Regard  
Erma Safitri

On Wednesday, July 27, 2016 5:41 PM, Veterinary World <vetworld@ejmanager.com> wrote:

Dear Erma Safitri,

Your submission entitled **THE INDONESIAN BEES HONEY CAN INDUCE ENDOGENOUS STEM CELLS IN REGENERATION OF OVARY DAMAGE DUE TO MALNUTRITION** (Manuscript Number: VETWORLD-2016-07-379) has been received by **Veterinary World**.

You could follow status of your manuscript by login to your author account at [www.ejmanager.com](http://www.ejmanager.com).

Thank you for submitting your work to our journal.

Best regards,

Editor  
Veterinary World  
<http://www.veterinaryworld.org>

-----  
NEWS:

1. Veterinary World is indexed in Emerging Sources Citation Index (ESCI) - Web of Science of Thomson Reuters. <http://science.thomsonreuters.com/cgi-bin/jrnlst/jlresults.cgi?PC=EX&SC=ZC>
2. Veterinary World is indexed in PubMed and PubMed Central. <http://www.ncbi.nlm.nih.gov/nlmcatalog/101504872>
3. A new, prestigious journal, International Journal of One Health ([www.onehealthjournal.org](http://www.onehealthjournal.org)) was launched in early 2015 by Veterinary World.

---

<http://www.scopemed.org>

[Author Login Page](#)

[Reviewer Login Page](#)

[Follow scopemed/ejmanager on twitter](#)

[Index of Fulltext Journals](#)

## Re: Submission Confirmation

---

From: Safitri Erma (rma\_fispro@yahoo.com)  
To: editorveterinaryworld@gmail.com  
Date: Sunday, September 18, 2016 at 10:22 PM GMT+7

---

Dear Editor

I am sorry, i have submitted my article as new article two times on 16-09-2016 which has overwritten the previous under review article. That is because my previous submission was said uncomplete (my manuscript not include line numbering on the left side of each row).

Please I want to continue with my article.

Together with this letter, I sent again my manuscript and complete with line numbering. Please acceptable premises either.

Thank you for your cooperation

Best regard

Dr.Erma Safitri,M.Si.,DVM.

On Saturday, September 17, 2016 6:12 PM, Veterinary World <editorveterinaryworld@gmail.com> wrote:

Dear Dr.

You have submitted your article as new article two times on 16-09-2016 which has overwritten the previous under review article and we lost the previous details. Now, we have to assign reviewers once again for your article.

I do not understand why you have submitted same article two times when it is under review ?

Please inform us whether you want to continue with your article or not ? as it will take time.

**NEWS:**

1. Veterinary World is indexed in Emerging Sources Citation Index (ESCI) - Web of Science of Thomson Reuters. <http://science.thomsonreuters.com/cgi-bin/jrnlst/jlresults.cgi?PC=EX&SC=ZC>
2. Veterinary World is indexed in PubMed and PubMed Central. <http://www.ncbi.nlm.nih.gov/nlmcatalog/101504872>
3. A new, prestigious journal, International Journal of One Health ([www.onehealthjournal.org](http://www.onehealthjournal.org)) was launched in early 2015 by Veterinary World.

-----  
Best Regards,

Dr. Anjum Sherasiya  
Editor-in-Chief  
Veterinary World  
Star, Gulshan Park, NH-8A,  
Chandrapur Road, Wankaner - 363621,  
Dist. Morbi (Gujarat), India.  
Website: [www.veterinaryworld.org](http://www.veterinaryworld.org), [onehealthjournal.org](http://onehealthjournal.org)  
E-mail: [editorveterinaryworld@gmail.com](mailto:editorveterinaryworld@gmail.com)

Follow us on

On Fri, Sep 16, 2016 at 9:32 PM, Safitri Erma <[rma\\_fispro@yahoo.com](mailto:rma_fispro@yahoo.com)> wrote:

Dear Editor,

Please give me information about status of my manuscript.

Best Regard  
Erma Safitri

On Wednesday, July 27, 2016 5:41 PM, Veterinary World <[vetworld@ejmanager.com](mailto:veworld@ejmanager.com)> wrote:

Dear Erma Safitri,

Your submission entitled **THE INDONESIAN BEES HONEY CAN INDUCE ENDOGENOUS STEM CELLS IN REGENERATION OF OVARY DAMAGE DUE TO MALNUTRITION** (Manuscript Number: VETWORLD-2016-07-379) has been received by **Veterinary World**.

You could follow status of your manuscript by login to your author account at [www.ejmanager.com](http://www.ejmanager.com).

Thank you for submitting your work to our journal.

Best regards,

Editor  
Veterinary World  
<http://www.veterinaryworld.org>

-----  
**NEWS:**

1. Veterinary World is indexed in Emerging Sources Citation Index (ESCI) - Web of Science of Thomson Reuters. <http://science.thomsonreuters.com/cgi-bin/jrnlst/jlresults.cgi?PC=EX&SC=ZC>
2. Veterinary World is indexed in PubMed and PubMed Central. <http://www.ncbi.nlm.nih.gov/nlmcatalog/101504872>
3. A new, prestigious journal, International Journal of One Health ([www.onehealthjournal.org](http://www.onehealthjournal.org)) was launched in early 2015 by Veterinary World.

<http://www.scopemed.org>  
[Author Login Page](#)

[Reviewer Login Page](#)  
[Follow scopemed/ejmanager on twitter](#)  
[Index of Fulltext Journals](#)



Main Document - VW.docx  
69.3kB



## Re: Submission Confirmation

---

From: Safitri Erma (rma\_fispro@yahoo.com)  
To: editorveterinaryworld@gmail.com  
Date: Monday, September 19, 2016 at 07:24 PM GMT+7

---

Dear Editor

Thank you for your attention. Pelase review time can be shortened of normally for may article.  
Than you

Best Regard  
Erma Safitri

On Monday, September 19, 2016 12:09 PM, Veterinary World <editorveterinaryworld@gmail.com> wrote:

Dear Dr.

OK. Thank you for confirmation. We have lost the details of your previous article. So, it will be treated as new.

**NEWS:**

1. Veterinary World is indexed in Emerging Sources Citation Index (ESCI) - Web of Science of Thomson Reuters. <http://science.thomsonreuters.com/cgi-bin/jrnlst/jlresults.cgi?PC=EX&SC=ZC>
2. Veterinary World is indexed in PubMed and PubMed Central. <http://www.ncbi.nlm.nih.gov/nlmcatalog/101504872>
3. A new, prestigious journal, International Journal of One Health ([www.onehealthjournal.org](http://www.onehealthjournal.org)) was launched in early 2015 by Veterinary World.

-----  
Best Regards,

Dr. Anjum Sherasiya  
Editor-in-Chief  
Veterinary World  
Star, Gulshan Park, NH-8A,  
Chandrapur Road, Wankaner - 363621,  
Dist. Morbi (Gujarat), India.  
Website: [www.veterinaryworld.org](http://www.veterinaryworld.org), [onehealthjournal.org](http://onehealthjournal.org)  
E-mail: [editorveterinaryworld@gmail.com](mailto:editorveterinaryworld@gmail.com)

Follow us on

On Sun, Sep 18, 2016 at 8:52 PM, Safitri Erma <[rma\\_fispro@yahoo.com](mailto:rma_fispro@yahoo.com)> wrote:

Dear Editor

I am sorry, i have submitted my article as new article two times on 16-09-2016 which has overwritten the previous under review article. That is because my previous submission was said uncomplete (my manuscript not include line numbering on the left side of each row).

Please I want to continue with my article.

Together with this letter, I sent again my manuscript and complete with line numbering. Please acceptable premises either.

Thank you for your cooperation

Best regard

Dr.Erma Safitri,M.Si.,DVM.

On Saturday, September 17, 2016 6:12 PM, Veterinary World <[editorveterinaryworld@gmail.com](mailto:editorveterinaryworld@gmail.com)> wrote:

Dear Dr.

You have submitted your article as new article two times on 16-09-2016 which has overwritten the previous under review article and we lost the previous details. Now, we have to assign reviewers once again for your article.

I do not understand why you have submitted same article two times when it is under review ?

Please inform us whether you want to continue with your article or not ? as it will take time.

**NEWS:**

1. Veterinary World is indexed in Emerging Sources Citation Index (ESCI) - Web of Science of Thomson Reuters. <http://science.thomsonreuters.com/cgi-bin/jrnlst/jlresults.cgi?PC=EX&SC=ZC>
2. Veterinary World is indexed in PubMed and PubMed Central. <http://www.ncbi.nlm.nih.gov/nlmcatalog/101504872>
3. A new, prestigious journal, International Journal of One Health ([www.onehealthjournal.org](http://www.onehealthjournal.org)) was launched in early 2015 by Veterinary World.

-----  
Best Regards,

Dr. Anjum Sherasiya  
Editor-in-Chief  
Veterinary World  
Star, Gulshan Park, NH-8A,

Chandrapur Road, Wankaner - 363621,  
Dist. Morbi (Gujarat), India.  
Website: [www.veterinaryworld.org](http://www.veterinaryworld.org), [onehealthjournal.org](http://onehealthjournal.org)  
E-mail: [editorveterinaryworld@gmail.com](mailto:editorveterinaryworld@gmail.com)

Follow us on

On Fri, Sep 16, 2016 at 9:32 PM, Safitri Erma <[rma\\_fispro@yahoo.com](mailto:rma_fispro@yahoo.com)> wrote:  
Dear Editor,

Please give me information about status of my manuscript.

Best Regard  
Erma Safitri

On Wednesday, July 27, 2016 5:41 PM, Veterinary World <[vetworld@ejmanager.com](mailto:vetworld@ejmanager.com)> wrote:

Dear Erma Safitri,

Your submission entitled **THE INDONESIAN BEES HONEY CAN INDUCE ENDOGENOUS STEM CELLS IN REGENERATION OF OVARY DAMAGE DUE TO MALNUTRITION** (Manuscript Number: VETWORLD-2016-07-379) has been received by **Veterinary World**.

You could follow status of your manuscript by login to your author account at [www.ejmanager.com](http://www.ejmanager.com).

Thank you for submitting your work to our journal.

Best regards,

Editor  
Veterinary World  
<http://www.veterinaryworld.org>

-----  
NEWS:

1. Veterinary World is indexed in Emerging Sources Citation Index (ESCI) - Web of Science of Thomson Reuters. <http://science.thomsonreuters.com/cgi-bin/jrnlst/jlresults.cgi?PC=EX&SC=ZC>
2. Veterinary World is indexed in PubMed and PubMed Central. <http://www.ncbi.nlm.nih.gov/nlmcatalog/101504872>
3. A new, prestigious journal, International Journal of One Health ([www.onehealthjournal.org](http://www.onehealthjournal.org)) was launched in early 2015 by Veterinary World.

---

<http://www.scopemed.org>  
[Author Login Page](#)  
[Reviewer Login Page](#)  
[Follow scopemed/ejmanager on twitter](#)  
[Index of Fulltext Journals](#)

## Article Revision Letter for Authors - (VETWORLD-2016-07-379)

---

From: Veterinary World (vetworld@ejmanager.com)

To: rma\_fispro@yahoo.com

Date: Friday, October 7, 2016 at 11:21 AM GMT+7

---

Dear Erma Safitri,

Your manuscript entitled "THE INDONESIAN BEE S HONEY CAN INDUCE ENDOGENOUS STEM CELLS IN REGENERATION OF OVARY DAMAGE DUE TO MALNUTRITION" (Ms.Nr. VETWORLD-2016-07-379) was reviewed by reviewers of the Veterinary World. As initial decision, your manuscript was found interesting but some revisions have to be made before it can reach a publishable value. Please refer comments given at bottom.

You should send your revised manuscript via the online system of ScopeMed on my.ejmanager.com.

Sincerely yours,

Dr. Anjum Sherasiya  
Editor-Veterinary World  
Star, Gulshan Park,  
NH-8A, Chandrapur Road, Wankaner 363621  
Dist. Morbi (Gujarat) INDIA

-----  
**NEWS:**

1. Veterinary World is indexed in Emerging Sources Citation Index (ESCI) - Web of Science of Thomson Reuters. <http://science.thomsonreuters.com/cgi-bin/jrnlst/jlresults.cgi?PC=EX&SC=ZC>
2. Veterinary World is indexed in PubMed and PubMed Central. <http://www.ncbi.nlm.nih.gov/nlmcatalog/101504872>
3. A new, prestigious journal, International Journal of One Health ([www.onehealthjournal.org](http://www.onehealthjournal.org)) was launched in early 2015 by Veterinary World.

-----  
**COMMENTS for Authors:**

**EDITORIAL COMMENTS:**

- Highlight all corrections/additions in red color font in revised manuscript.
- Please answer all the comments below point-by-point in an accompanying response letter to your revised submission.
- Include all authors name, affiliation and email address in revised word file. Please check latest article from [www.veterinaryworld.org](http://www.veterinaryworld.org) for format of this section.
- All journal names in references must be as per standard journal abbreviation. We do not allow full name or non-standardised abbreviation. You can check the abbreviation at [http://images.webofknowledge.com/WOK46/help/WOS/T\\_abrvjt.html](http://images.webofknowledge.com/WOK46/help/WOS/T_abrvjt.html), [www.journalseek.net](http://www.journalseek.net) etc.
- Include authors' contributions if you have not added.
- Include Acknowledgements along with source of fund for this study if you have not included.
- If you will not revise strictly as per suggestion then there will be chance of rejection. So, revise carefully. If you have any query then please mention it in revision letter or email to Editor-in-Chief.

**Reviewers' comments:**

thanks to author to search for natural and oral methods that stimulate stem cell release and homing to damaged tissues but the study was done on -ve control and +ve control that take water only, actually we need +ve control that receive substance that evidenced to release HSCs which is granulocyte colony stimulating factor, also it can be given orally and compare honey effect with GCSF effect  
HSC in many studies have no or little effect on repair of ovarian tissues and MSCs may explain repair.  
author should search for CD of MSCs.  
the author should report what is the new in his study since many authors examine effect of honey on HSCs  
histological figure are not clear and faint

---

<http://www.scopemed.org>  
[Author Login Page](#)

[Reviewer Login Page](#)  
[Follow scopemed/ejmanager on twitter](#)  
[Index of Fulltext Journals](#)

## Pembayaran Anda kepada Veterinary World

From: service@intl.paypal.com (service@intl.paypal.com)

To: rma\_fispro@yahoo.com

Date: Tuesday, October 18, 2016 at 08:18 PM GMT+7

**Anda telah mengirim pembayaran sebesar  
\$150,00 USD kepada Veterinary World.**

18 Okt 2016 6:17:50 GMT-07:00  
No. Resi:3056-4308-9190-2401

Halo ERMA SAFITRI,

Tagihan ini akan muncul di laporan kartu kredit Anda sebagai pembayaran kepada PAYPAL  
\*VETERINARYW.

**Lakukan pembayaran dengan lebih cepat di lain waktu - buat rekening PayPal**

Membayar dengan PayPal lebih aman dan lebih cepat. Anda hanya memerlukan email dan sandi ke rekening PayPal saat berikutnya berbelanja online.

[Daftar Sekarang](#)

**Berbelanja dengan nyaman**

Lakukan pembelian dengan beberapa klik. Cukup masukkan email dan sandi Anda saat membayar dengan PayPal.

**Berbelanja dengan lebih aman**

Pedagang tidak akan melihat perincian keuangan Anda karena kami menyimpannya secara aman.

**Belanja dengan penuh keyakinan**

Dapatkan uang Anda kembali untuk pembelian yang tidak diterima atau ternyata berbeda. [Pelajari lebih jauh](#)

**Informasi pedagang:**

Veterinary World  
sherasiyaanjum@gmail.com  
<http://www.veterinaryworld.org>  
9879065095

**Petunjuk untuk pedagang:**

Tidak ada yang diberikan

**Informasi pengiriman:**

ERMA SAFITRI  
Sukolilo Makmur 3 No 24  
Surabaya, JAWA TIMUR  
60111  
Indonesia

**Metode pengiriman:**

Tidak ditentukan

| Keterangan  | Harga satuan    | Kuantitas     | Jumlah              |
|---|-----------------|---------------|---------------------|
| Publication_charge_VETWORLD-2016-07-379<br>Barang #: 1470 | \$150,00<br>USD | 1             | \$150,00<br>USD     |
|   |                 | Diskon:       | -\$0,00 USD         |
|   |                 | <b>Total:</b> | <b>\$150,00 USD</b> |

**Nomor Resi: 3056-4308-9190-2401**

Simpanlah nomor resi ini untuk rujukan di masa mendatang. Anda akan memerlukannya jika menghubungi layanan pelanggan di Veterinary World atau PayPal.

Terima Kasih,  
PayPal

[Bantuan](#) | [Pusat Keamanan](#)

Jangan balas email karena kami tidak memantau kotak masuk ini. Untuk menghubungi kami, log in ke rekening Anda, lalu klik "Hubungi Kami" di bagian bawah halaman apapun.

Hak Cipta © 1999-2016 PayPal Inc. Semua hak dilindungi undang-undang.

Saran untuk konsumen: PayPal Pte Ltd, Pemilik fasilitas nilai tersimpan pembayaran PayPal™, tidak memerlukan persetujuan dari Otoritas Keuangan Singapura. Konsumen (pengguna) sebaiknya membaca [syarat dan ketentuan](#) dengan cermat.

ID Email PayPal PP1469 - 137e6a4f2c436

## Decision Letter to Authors - Acceptance - (VETWORLD-2016-07-379)

---

From: Veterinary World (vetworld@ejmanager.com)

To: rma\_fispro@yahoo.com

Date: Friday, October 21, 2016 at 01:36 PM GMT+7

---

Dear Erma Safitri, Thomas V Widiyatno, R Heru Prasetyo

I am pleased to inform you that your manuscript titled as "HONEYBEE PRODUCT THERAPEUTIC AS STEM CELLS HOMING FOR OVARY FAILURE" (Manuscript Number: VETWORLD-2016-07-379 is accepted for publication in the Veterinary World.

- We have received the revised manuscript as per reviewers suggestions.
- We have received the payment.
- You will get the signed acceptance letter within 2 days.

NEWS: A new, prestigious journal, International Journal of One Health ([www.onehealthjournal.org](http://www.onehealthjournal.org)) was launched in early 2015 by Veterinary World.

Sincerely yours,

Dr. Anjum Sherasiya  
Editor-Veterinary World  
Star, Gulshan Park,  
NH-8A, Chandrapur Road, Wankaner 363621  
Dist. Morbi (Gujarat) INDIA

---

NEWS:

1. Veterinary World is indexed in Emerging Sources Citation Index (ESCI) - Web of Science of Thomson Reuters. <http://science.thomsonreuters.com/cgi-bin/jrnlst/jlresults.cgi?PC=EX&SC=ZC>
2. Veterinary World is indexed in PubMed and PubMed Central. <http://www.ncbi.nlm.nih.gov/nlmcatalog/101504872>
3. A new, prestigious journal, International Journal of One Health ([www.onehealthjournal.org](http://www.onehealthjournal.org)) was launched in early 2015 by Veterinary World.

---

<http://www.scopemed.org>

[Author Login Page](#)

[Reviewer Login Page](#)

[Follow scopemed/ejmanager on twitter](#)

[Index of Fulltext Journals](#)



## Acceptance Letter

---

From: Veterinary World - Publisher (veterinaryworldpublisher@gmail.com)

To: rma\_fispro@yahoo.com; th\_v\_widiyatno@yahoo.co.id; rheru\_prasetyo@yahoo.co.id

Cc: editorveterinaryworld@gmail.com

Date: Monday, October 24, 2016 at 08:41 PM GMT+7

---

Dear Authors,

I am attaching herewith the acceptance letter of your article.

**NEWS:**

1. Veterinary World is indexed in Emerging Sources Citation Index (ESCI) - Thomson Reuters. <http://science.thomsonreuters.com/cgi-bin/jrnlst/jlresults.cgi?PC=EX&SC=ZC>
2. Veterinary World is indexed in PubMed and PubMed Central. <http://www.ncbi.nlm.nih.gov/nlmcatalog/101504872>
3. A new, prestigious journal, International Journal of One Health ([www.onehealthjournal.org](http://www.onehealthjournal.org)) was launched in early 2015 by Veterinary World.

-----  
Best Regards,

Nazir  
Editorial Assistant  
Veterinary World  
Star, Gulshan Park,  
NH-8A, Chandrapur Road,  
Wankaner, Dist. Morbi, Gujarat  
India  
[www.veterinaryworld.org](http://www.veterinaryworld.org)  
[www.onhealthjournal.org](http://www.onhealthjournal.org)



Erma Safitri - 194.pdf  
446.1kB



# VETERINARY WORLD

Open access and peer reviewed journal

Star, Gulshan Park, NH-8A, Chandrapur Road, Wankaner - 363621, Dist. Morbi (Gujarat) India,  
Website: [www.veterinaryworld.org](http://www.veterinaryworld.org), Email: [editorveterinaryworld@gmail.com](mailto:editorveterinaryworld@gmail.com)

**Editor-in-Chief:** Anjum V. Sherasiya, **Publisher:** Veterinary World, **EISSN:** 2231-0916

**NAAS (National Academy of Agricultural Sciences -INDIA) - 5.10, SCOPUS: SJR (Scimago Journal Rank) - 0.265,  
IPP (Impact per publication) - 0.47, SNIP (Source Normalized Impact per Paper) - 0.600**

## By Email

Ref No. VW/Accept/194/2016

21-10-2016

To,  
Erma Safitri  
Departement of Veterinary Reproduction,  
Faculty of Veterinary Medicine,  
Universitas Airlangga,  
Airlangga, East Java,  
Indonesia.  
E-mail: [rma\\_fispro@yahoo.com](mailto:rma_fispro@yahoo.com)

## Acceptance of article for publication in Veterinary World

Dear Dr.

I am pleased to inform you that your manuscript titled as -

**Honeybee product therapeutic as stem cells homing for ovary failure** - Erma Safitri, Thomas V. Widiyatno, and R. Heru Prasetyo

is accepted for publication in *Veterinary World*.

We have received the payment for publication (bill no. 147 dated 21-10-2016). So, you will get the galley proof within 4-5 weeks. You must have to solve the query, if we point out any in galley proof.

After correction of galley proof, your article will be published online at [www.veterinaryworld.org](http://www.veterinaryworld.org) in chronological order.

Thanking You.

Yours Sincerely,

Dr. Anjum V. Sherasiya  
Editor-in-Chief  
Veterinary World



Indexed and Abstracted in Academic Journals Database, AGORA, AGRICOLA, AGRIS, CABI, CAS, DOAJ, EBSCO, ESCI- Thomson Reuters, Gale, Google Scholar, HINARI, Index Scholar, Indian Animal Science Abstracts, Indian Science Abstracts, JournalSeek, Open J-gate, ProQuest, PubMed, PubMed Central, SCOPUS, TEEAL

## Safitri et al: proof for corrections

---

From: Veterinary World (editorveterinaryworld@gmail.com)

To: rma\_fispro@yahoo.com; th\_v\_widiyatno@yahoo.co.id; rheru\_prasetyo@yahoo.co.id

Date: Friday, November 18, 2016 at 10:56 AM GMT+7

---

Dear Authors,

PLEASE READ BELOW MESSAGE CAREFULLY BEFORE PROOF CORRECTIONS.

Please put all co-authors in cc email when you send the reply to us.

Please use Word 2010 or higher to read and correct the proof with track changes.

I am attaching herewith proof of copy-edited word file of your article. WE HAVE COPYEDITED AT MANY SENTENCES. We have not provided the article with track changed corrections as many authors get confused. SO, PLEASE CHECK EACH SENTENCE CAREFULLY.

Also check the highlighted words if any in your manuscript.

Also please check whole manuscript carefully for any mistake (author name, affiliation, emails, how to cite, text of article, abbreviation, full forms, figures (if any - figures will be formatted in exact size in the PDF), tables (if any). etc). Please check that all figures/tables are cited in the text part or not? Correct the manuscript as per comments given on right column if any. Please be careful in correction as we will create the PDF directly from this file. We will provide the PDF as final proof before publication.

PLEASE CHECK THAT ALL REFERENCES ARE IN CONTINUOUS NO. OR NOT ?

Please do the changes in this word file with track changes only or reply in comment box if any. Please do not add/delete anything without track changes. WE USE US ENGLISH SO, PLEASE DO NOT CONVERT SPELLINGS TO UK ENGLISH (i.e. estrus to oestrus, hematological to haematological etc.)

Please include authors' contribution section, acknowledgement along with source of fund for the study, competing interests statement etc if you have not included.

Also send the corrections in separate file with page no., line no. etc.

PLEASE COLLABORATE WITH CORRESPONDING AUTHOR AND SEND THE CORRECTION THROUGH CORRESPONDING AUTHOR EMAIL ONLY WITHIN 3 DAYS. WE WILL PROVIDE PDF PROOF AFTER CORRECTION OF COPYEDITED PROOF.

If there is no correction then reply accordingly.

### **NEWS:**

1. Veterinary World is indexed in Emerging Sources Citation Index (ESCI) - Web of Science of Thomson Reuters. <http://science.thomsonreuters.com/cgi-bin/jrnlst/jlresults.cgi?PC=EX&SC=ZC>

2. Veterinary World is indexed in PubMed and PubMed Central.

<http://www.ncbi.nlm.nih.gov/nlmcatalog/101504872>

3. A new, prestigious journal, International Journal of One Health ([www.onehealthjournal.org](http://www.onehealthjournal.org)) was launched in early 2015 by Veterinary World.

-----  
Best Regards,

Dr. Anjum Sherasiya

Editor-in-Chief

Veterinary World

Star, Gulshan Park, NH-8A,

Chandrapur Road, Wankaner - 363621,

Dist. Morbi (Gujarat), India.

Website: [www.veterinaryworld.org](http://www.veterinaryworld.org), [onehealthjournal.org](http://onehealthjournal.org).

E-mail: [editorveterinaryworld@gmail.com](mailto:editorveterinaryworld@gmail.com)

Follow us on



Erma Safitri.docx  
1.1MB

## Re: Safitri et al: proof for corrections

---

From: Safitri Erma (rma\_fispro@yahoo.com)  
To: editorveterinaryworld@gmail.com; rheru\_prasetyo@yahoo.co.id  
Date: Saturday, November 19, 2016 at 08:28 PM GMT+7

---

On Saturday, November 19, 2016 7:19 PM, Veterinary World <editorveterinaryworld@gmail.com> wrote:

Dear Dr. Erma Safitri,

We have sent you the proof in previous email. You have to just send the corrected proof to this email. Please refer the previous email for proof correction and correct as per suggestion and send to this email.

**NEWS:**

1. Veterinary World is indexed in Emerging Sources Citation Index (ESCI) - Web of Science of Thomson Reuters. <http://science.thomsonreuters.com/cgi-bin/jrnlst/jlresults.cgi?PC=EX&SC=ZC>
2. Veterinary World is indexed in PubMed and PubMed Central. <http://www.ncbi.nlm.nih.gov/nlmcatalog/101504872>
3. A new, prestigious journal, International Journal of One Health ([www.onehealthjournal.org](http://www.onehealthjournal.org)) was launched in early 2015 by Veterinary World.

-----  
Best Regards,

Dr. Anjum Sherasiya  
Editor-in-Chief  
Veterinary World  
Star, Gulshan Park, NH-8A,  
Chandrapur Road, Wankaner - 363621,  
Dist. Morbi (Gujarat), India.  
Website: [www.veterinaryworld.org](http://www.veterinaryworld.org), [onehealthjournal.org](http://onehealthjournal.org)  
E-mail: [editorveterinaryworld@gmail.com](mailto:editorveterinaryworld@gmail.com)

Follow us on

On Fri, Nov 18, 2016 at 10:13 PM, Safitri Erma <[rma\\_fispro@yahoo.com](mailto:rma_fispro@yahoo.com)> wrote:

Dear Editor

I can not send my proof article correction. Thank you for your cooperation

Best Regad  
Dr. Erma Safitri, M.Si. Drh

On Friday, November 18, 2016 10:56 AM, Veterinary World <[editorveterinaryworld@gmail.com](mailto:editorveterinaryworld@gmail.com)> wrote:

Dear Authors,

PLEASE READ BELOW MESSAGE CAREFULLY BEFORE PROOF CORRECTIONS.

Please put all co-authors in cc email when you send the reply to us.  
Please use Word 2010 or higher to read and correct the proof with track changes.

I am attaching herewith proof of copy-edited word file of your article. WE HAVE COPYEDITED AT MANY SENTENCES. We have not provided the article with track changed corrections as many authors get confused. SO, PLEASE CHECK EACH SENTENCE CAREFULLY.

Also check the highlighted words if any in your manuscript.

Also please check whole manuscript carefully for any mistake (author name, affiliation, emails, how to cite, text of article, abbreviation, full forms, figures (if any - figures will be formatted in exact size in the PDF), tables (if any). etc). Please check that all figures/tables are cited in the text part or not? Correct the manuscript as per comments given on right column if any. Please be careful in correction as we will create the PDF directly from this file. We will provide the PDF as final proof before publication.

PLEASE CHECK THAT ALL REFERENCES ARE IN CONTINUOUS NO. OR NOT ?

Please do the changes in this word file with track changes only or reply in comment box if any. Please do not add/delete anything without track changes.

WE USE US ENGLISH SO, PLEASE DO NOT CONVERT SPELLINGS TO UK ENGLISH (i.e. estrus to oestrus, hematological to haematological etc.)

Please include authors' contribution section, acknowledgement along with source of fund for the study, competing interests statement etc if you have not included.

Also send the corrections in separate file with page no., line no. etc.

PLEASE COLLABORATE WITH CORRESPONDING AUTHOR AND SEND THE CORRECTION THROUGH CORRESPONDING AUTHOR EMAIL ONLY WITHIN 3 DAYS. WE WILL PROVIDE PDF PROOF AFTER CORRECTION OF COPYEDITED PROOF.

If there is no correction then reply accordingly.

**NEWS:**

1. Veterinary World is indexed in Emerging Sources Citation Index (ESCI) - Web of Science of Thomson Reuters. <http://science.thomsonreuters.com/cgi-bin/jrnlst/jlresults.cgi?PC=EX&SC=ZC>
2. Veterinary World is indexed in PubMed and PubMed Central. <http://www.ncbi.nlm.nih.gov/nlmcatalog/101504872>
3. A new, prestigious journal, International Journal of One Health ([www.onehealthjournal.org](http://www.onehealthjournal.org)) was launched in early 2015 by Veterinary World.

-----  
Best Regards,

Dr. Anjum Sherasiya

Editor-in-Chief

Veterinary World

Star, Gulshan Park, NH-8A,

Chandrapur Road, Wankaner - 363621,

Dist. Morbi (Gujarat), India.

Website: [www.veterinaryworld.org](http://www.veterinaryworld.org), [onehealthjournal.org](http://onehealthjournal.org)

E-mail: [editorveterinaryworld@gmail.com](mailto:editorveterinaryworld@gmail.com)

Follow us on



Erma Safitri-Proof OK.docx  
1.1MB

Technical/copyediting by Tulyasys – 15.11.2016

## RESEARCH ARTICLE

### Honeybee product therapeutic as stem cells homing for ovary failure

Erma Safitri<sup>1,2</sup>, Thomas V. Widiyatno<sup>3</sup>, and R. Heru Prasetyo<sup>4</sup>

1. Department of Veterinary Reproduction, Faculty of Veterinary Medicine, Universitas Airlangga, Airlangga, East Java, Indonesia; 2. Stem Cells Research Division of Institute Tropical Disease, Universitas Airlangga, Airlangga, East Java, Indonesia; 3. Department of Veterinary Pathology, Faculty of Veterinary Medicine, Universitas Airlangga, Airlangga, East Java, Indonesia; 4. Department of Parasitology, Faculty of Medicine, Universitas Airlangga, Airlangga, East Java, Indonesia.

Formatted[Unknown]: Font: (Default) Times New Roman, (Asian) Calibri, 12 pt

**Corresponding author:** Erma Safitri, **e-mail:** rma\_fispro@yahoo.com,

TVW:

th\_v\_widiyatno@yahoo.co.id

, RHP:

rheru\_prasetyo@yahoo.co.id

**Received:** 16-09-2016, **Accepted:** 21-10-2016, **Published online:** \*\*\*

**doi:** \*\*\* **How to cite this article:** Safitri E, Widiyatno TV, Prasetyo RH (2016) Honeybee product therapeutic as stem cells homing for ovary failure, *Veterinary World*, 9(11): ?-?

#### Abstract

**Aim:** Complexity of the method of isolation, cultivation *in vitro* and the expensive cost of transplantation process of stem cells, it would require an innovation to homing and differentiation of stem cells and increase folliculogenesis. The stem cells homing was achieved through the provision of food or beverages derived from natural materials like honeybee product.



Through honeybee product, there will be homing of stem cells and accompany with the sources from the body itself will take place in regeneration of the ovary.

**Materials and Methods:** Female rats model of degenerative ovary was obtained through food fasting but still have drinking water for 5 days. It caused malnutrition and damage of the ovarian tissue. The administration of 50% honeybee product (T1) was performed for 10 consecutive days, while the positive control group (T0+) was fasted and not given honeybee product and the negative control (T0-) not fasted and without honeybee product. Observations were taken for homing of stem cells, raised of folliculogenesis, differentiation of stem cells, and regeneration of the ovarian tissue using routine H&E staining.

**Results:** Homing of stem cells shown the vascular endothelial growth factor and granulocyte colony-stimulating factor expression; enhancement of folliculogenesis was indicated by an increase of follicle de Graaf count; enhancement of differentiation of stem cells was indicated by growth differentiation factor-9 expression; and regeneration of ovarian tissue indicated by intact ovarian tissue with growing follicles.

**Conclusion:** Honeybee product can be induced endogenous stem cells in regeneration of ovary failure due to malnutrition.

**Keywords:** honeybee product, ovary failure, stem cells homing.

## <H1>Introduction

The interest of stem cell therapy today and the next few decades tends to be greatly increased [1-3]. The stem cells have tremendous promise to treat a range of diseases. Stem cell transplantation provides new hope in the treatment of various diseases including infertility due to degenerative conditions of the ovary which could not be cured through usual treatment and operative measures [3-7].

However, because of the complexity of the method of isolation [8], cultivation *in vitro* [9] and the expensive cost of transplantation process of stem cells [10], it would require an innovation to homing of stem cells and increase immune response [4,11,12] and in the same time induced a differentiation of endogenous stem cells [11,13], and therefore, avoid the expensive process of transplantation. Automobilization and increased immune response accompanied with the differentiation of stem cells was achieved through the provision of food or beverages derived from natural materials like honeybee product [3,4,11,14].

The recent study performed a provision of honeybee product [3,4,11,15,16]. Through the administration of honeybee products, it was expected a homing and differentiation of stem cells the patients with ovary failure [4,17]. The presence of homing and differentiation of stem cells is made from the body itself and it will regenerate the follicles of the ovary.

The regeneration of ovary can be proven microscopically and also on molecular level [13,18]. The histological appearance will reveal regeneration of ovarian tissue at molecular level there were evident of several expressions such as CD34+ and CD45+ of hematopoietic stem cells (HSCs) [4,19], expression of transforming growth factor- $\beta$  (TGF- $\beta$ ) [11], vascular endothelial growth factor (VEGF), granulocyte colony-stimulating factor (G-CSF) [11,20,21], and growth differentiation factor-9 (GDF-9) of the ovary [20,21].

The aim of the study was using honeybee product therapeutic will be homing of stem cells (based on VEGF and G-CSF expression), increase of folliculogenesis count and stem cells differentiation (based on GDF-9 expression) and accompany with the sources from the body itself will take place in regeneration of the ovary (based on histopathological observation with H&E staining) on rat model with ovary failure due to malnutrition.

## <H1>Materials and Methods

## <H2>Ethical approval

???

## <H2>Ovarian degeneration modeling

Malnutrition which causes the ovaries degeneration in female rats was performed following food fasting for 5 consecutive days, but they still have water to drink *ad libitum* using feeding tube [22]. The laboratory animals used in this study were healthy female Wistar rats, 12-14 week-old and each 250-300 g weight [23]. Healthy condition was determined by their active movement. Rats kept in an individual plastic cage in laboratory for Experimental Animal of Veterinary Medicine, Faculty of Universitas Airlangga with adequate ventilation.

Treatment: The study was divided into three groups, each has 15 replications. They were:

1. The negative control group (T0-): Rats with ovary normal (not fasted) and without honeybee product
2. The positive control group (T0+): Rats with ovary failure (fasted for 5 days) and without honeybee product
3. The treatment Group 2 (T1): Rats ovary failure (fasted for 5 days), given 50 % honeybee product in the drinking water for the next 10 days after fasted.

Honeybee products that used in this study were raw honeybee products from Batu Malang East Java, Indonesia. Observations were taken for homing stem cells, raised of folliculogenesis, differentiation of stem cells, and regeneration of the ovarian tissue. Homing of stem cells was shown by VEGF and G-CSF expressions [11,21]. Raised of folliculogenesis was indicated by an increase of follicle dee Graaf expression [24]. Differentiation of stem cells into progenitor cells presented by the expression of GDF-9 using immunohistochemistry technique in ovarian tissue [20,21] and regeneration of the ovarian tissue using routine HE staining [26].

## **<H2>Immunohistochemical (IHC) methods for observation of VEGF, G-CSF, and GDF-9**

IHC observation was performed to determine the expressions of VEGF, G-CSF, and GDF-9 [11,21,26]. First, made an incision through ovarian tissues transversely from paraffin blocks [26]. The IHC techniques using monoclonal antibodies anti-VEGF, anti-G-CSF, and anti-GDF-9. Observations of VEGF, G-CSF, and GDF-9 expressions were made using a light microscope with a magnification of 200 times. The expression of each variable is indicated by the number of cells with brownish discoloration due to DAB-chromogen in each incision [26,27].

## **<H2>Histological and follicle dee Graaf observation of ovary**

Identification of follicle dee Graaf and regenerate ovarian tissues performed through light microscopy examination [25]. Histological preparations such as the following: Fixation of rat ovary in 10% buffer formalin. Subsequently dehydration with a series of alcohol, i.e., from 70%, 80%, 90%, and 96% (absolute). Clearing of the ovary of rat in xylene solution. The tissues were infiltrated with embedding agent, the liquid paraffin. The sectioning was done with microtome that could be set with a distance at 4-6  $\mu$ , and the sections were placed on a slide. The embedding process must be reversed to get the paraffin wax out of the tissue and allow water soluble dyes to penetrate the sections. Therefore, before any staining can be done, the slides are “deparaffinized” by running them through xylenes to alcohols to water. The staining used was the routine H & E. The stained section then mounted with Canada balsam and placed a coverslip on it [26].

Observations and identifications of follicle dee Graaf and ovarian regenerations are based on the histological measures of that of the normal tissue [4,26].

## **<H2>Statistical analysis**

Expressions of follicle dee Graaf, VEGF, G-CSF, and GDF-9 were statistically analyzed using SPSS 15 for Windows XP with the level of significance 0.05 ( $p=0.05$ ) and the confidence level

99% ( $\alpha=0.01$ ). Steps of comparative hypothesis tests are as follows: Test data normality with the Kolmogorof–Smirnov test, homogeneity of variance test, analysis of variance factorial, and *post-hoc* test (least significant difference test) using the Tukey HSD 5%.

## <H1>Results and Discussion

The collected data from 45 female rats were divided into three groups: Negative control group (T0–) is normal ovary without honeybee product; positive control group (T0+) is ovary failure without honeybee product; (T1) group is ovary failure + 50% honeybee product in drinking water for 10 days. In detail, the results of the study are as follows: The effectiveness of honeybee product was based on: (1) Homing of stem cells based on VEGF and G-CSF expressions, (2) follicle dee Graaf count, (3) GDF-9 expressions, and (4) regeneration of ovarian tissue.

Homing of stem cells analyzed by IHC based on increased of VEGF and G-CSF expression. The analysis showed that: Nonsignificant of the negative control group (T0–) and the positive control group (T0+) showed homing of stem cells, based on the lower expression of VEGF and G-CSF with average were  $<1$  (Figures-1 and 2), while the (T1) group has shown homing of stem cells based on the average of VEGF and G-CSF= $2.75\pm 0.55^a$  and  $2.95\pm 0.43^b$  (Figures-1 and 2). Based on statistical analysis T1 group was significantly different ( $p<0.05$ ) than the other two treatments (T0– and T0+), but among the latter two treatments no significant difference ( $p>0.05$ ) (Table-1).

Furthermore, enhancement of folliculogenesis based on follicle dee Graaf expression, in the normal control group (T0–) where its count was  $7\pm 0.845^c$ . The group was significantly different ( $p<0,05$ ) than the group of ovary failure (T0+) was  $0.75\pm 0.125^a$  and The group with ovary failure +50% honeybee product (T1) was  $5.416\pm 0.807^b$  (Table-1). However, the group of ovary failure (T0+) has the lowest follicle dee Grasf expression. The group of ovary failure (T0+) was significantly different ( $p<0,05$ ) than the group with ovary failure +50% honeybee product (T1).

Deleted[PC]: T

Deleted[PC]: .

The effectiveness of honeybee product is based on GDF-9 expression as a result of the differentiation of the progenitor cells. Expression of GDF-9 in the group with 50% honeybee product (T1) had scored  $2 \pm 0.43^b$  (GDF-9 expression between 25% and 50%). Although, the T1 group's score was lower than the normal control group (T0-) with the score was  $2.95 \pm 0.41^c$  and GDF-9 expression >50%, but still higher than the (T0+) group with ovary failure, which was not expressed at all ( $0 \pm 0^a$  and GDF-9 expression 0%) (Table-1 and Figure-3).

In this study, the regeneration of the ovary could be observed histologically with H & E staining. Microscopic examination showed that the group with ovary failure +50% honeybee product (T1) did the best ovarian tissue repair. The tissue repair was determined by the regeneration of ovary which its follicles grew normally. The appearance of this improvement could be compared with the negative control group (T0-) which did not undergo ovarian failure and remains in normal condition and the follicles grew normally. The appearance of the tissue damage could be compared with the positive control rat (T0+) which experiencing ovarian degeneration. The group with ovary failure (T0+), was congested and showed severe hemorrhage, formation of hemosiderin granules due to erythrolysis (brownishyellow color) accompanied with fibrosis indicating that chronic inflammation has been occurred [28] (Figure-4).

This study showed that administration of 50% honey for 10 days (T1) can be used for the treatment of female rat with ovary failure model caused malnutrition. The effectiveness of honeybee product was based on: (1) Homing of stem cells (based on VEGF and G-CSF expressions); (2) follicle dee Graaf count; (3) GDF-9 expressions; (4) regeneration of ovarian tissue.

Homing of stem cells (based on VEGF and G-CSF expressions) using IHC method [11,21]. Increase of follicle dee Graaf count was indicated of folliculogenesis raised [25]. Differentiation

of stem cells into progenitor cells presented by the expression of GDF-9 using IHC technique in ovarian tissue [20,21,29]. Regeneration of ovarian tissue observation with routine HE staining [4].

Homing of stem cells could be performed by inducing the stem cells to mobilize toward the defect area [13,30]. Mobilization of stem cells toward defect area for engraft in tissue, and then, the cells have a function and repair effect. Furthermore, the cells have function including secretion of soluble mediator that occurred cooperation between the host cells with mobilization cells from exogenous stem cells that have paracrine effect [21]. The process of homing can occur in several ways, one of which is enhancement of the immune response that induced by an inflammatory reaction due to injurious signals (cytokines, nuclear factor  $\kappa$ B, Wnt through  $\beta$  catenin) from the damaged tissue [26]. In this study, injury due to malnutrition signal causes an increase in cytokines so that the alteration of ovarian tissue as the primary network of the female reproductive system could be inevitable [27]. Some cytokines that induction of stem cells for the migration and homing in the area of injury, in this study, is the VEGF and G-CSF [21].

Homing mechanism starts from HSCs out of the bone marrow through chemokine receptor (CCXR4) to locate the homing signal factor of stromal-derived factor 1 (SDF1) [4]. Furthermore, osteoblasts (cell progenitors) in cell adhesion proteins (cell adhesion proteins), among others VICAM. Furthermore, G-CSF stimulates an increase in neutrophils in the bone marrow and then increase the blood cells. Neutrophils increases will produce protease enzymes including elastase protein damage for stem cell homing signal such as SDF1 and VICAM and then caused the stem cells out of the bone marrow. After that, quiescent stem cells out into the blood flow. The role of honey administered orally in this research was caused an increase of G-CSF [21].

Furthermore, the ovarian tissue repair based on GDF-9 expression (Table-1). GDF-9 which is progenitor cells of germline stem cells will stimulate ovarian cortex cells proliferation [31]. The T1 group (ovary failure +50% honeybee product) score of GDF-9 expression was  $2\pm 0.43^b$ .

Although the score is below the negative control group (T0-) was significantly different ( $p<0.05$ ), with the score of which  $2.95\pm 0.41^c$ , but the score is still above the group of ovary failure without honeybee products (T0+) which shown no expression at all ( $0\pm 0^a$ ) (Table-1 and Figure-3). This is in accordance with the opinion that honeybee product causes the stem cells develop rapidly and differentiate into cells that are needed as a response to injury and enhance the immune response itself [32].

GDF-9 is the growth factor derived from TGF- $\beta$  family was produced by the oocyte. GDF-9 is a crucial factor in folliculogenesis and fertility [33]. Furthermore, progenitor germ cells will repair the damaged follicles and also can repair molecular communication in ovarian follicles by increasing the production of SCF and GDF-9, so as to overcome the problems of folliculogenesis due to malnutrition [21]. Homing will be activated oogenesis directly or indirectly. Directly through activation of cells inhibited and will indirectly stimulate the microenvironment (niche) of damaged cells [34].

Regeneration of ovarian tissue shown as an intact ovarian tissue with growing follicles is the third and fourth identification of the effectiveness from the use of honeybee product. In this study, the regeneration of the ovarium can be observed microscopically with HE staining [31,35]. Microscopic examination showed that 50% honeybee product administration (T1), leading to the ovarian tissue repair. Improvements are identified based on the regeneration of the ovary with growing follicles. Overview of these improvements can be compared with a negative control group (T0-) which did not suffer from ovarian failure and remains in normal condition with



growing follicles (Figure-4). The abnormal feature of the damaged ovary can be compared with positive control group of rat (T0+) rat with ovarian degenerative. The latter shown congested and there were severe hemorrhage and hemosiderosis (yellow-brown color) due to the hemolysis of the red blood cells with fibrin deposition, indicating that chronic congestion has been occurred (Figure-4).

## **<H1>Conclusions**

Treatment of 50% honeybee product for 10 days in female rat with ovary failure reveals: (1) Homing of stem cells, shown the VEGF and G-CSF markers which are expressed in ovarian tissue with IHC; (2) enhancement of folliculogenesis was indicated by increase of follicle dee Graaf count; (3) enhancement of GDF-9 expression in ovarian tissue with IHC staining; (4) regeneration of ovarian tissue indicated by intact ovarian tissue with growing follicles; although there is still slight hemorrhage and congestion, hemosiderin granules and fibrin deposition do not exist.

## **<H1>Authors' Contributions**

???

## **<H1>Acknowledgments**

The study was supported by funding from the Directorate General of Higher Education (DIKTI) 2016. The National Education Ministry, Republic of Indonesia.

## **<H1>Competing Interests**

The authors declare that they have no competing interest.

## **<H1>References**

1. Trounson, A. and McDonald, C. (2015) Stem cell therapies in clinical trials: Progress and challenges. *Cell Stem Cells*, 17(1): 11-22.
2. Watt, F.M. and Driskell, R.R. (2010) Review: The therapeutic potential of stem cells. *Philos. Trans. R. Soc.*, 365: 155-163.
3. Safitri, E., Utama, S., Widiyatno, T.V., Sandhika, W. and Prasetyo, R.H. (2016) Autoregeneration of mice testicle seminiferous tubules due to malnutrition based on stem cells mobilization using bee honey. *Asian Pac. J. Reprod.*, 5(1): 30-34.
4. Prasetyo, R.H. and Safitri, E. (2016) Effects of honey to mobilize endogenous stem cells in efforts intestinal and ovarian tissue regeneration in rats with protein energy malnutrition. *Asian Pac. J. Reprod.*, 5(3): 198-203.
5. Caplan, A.I. and Correa, D. (2011) The MSC: An injury drugstore. *Cell Stem Cells*, 8: 11-15.
6. Volarevic, V., Arsenijevic, N., Lukic, M.L. and Srojkovic, M. (2011) Concise review: Mesenchymal stem cells treatment of the complications of diabetes mellitus. Stem cells regenerative medicine. *Stem Cells*, 29(1): 5-10.

7. Halim, D.H., Murty, F., Sandra, A., Boediono, T., Djuwantono, B. and Setiawan, B. (2010) *Stem Cell Dasar Teori dan Aplikasi Klinis*. 1<sup>st</sup> ed. Penerbit Erlangga, Jakarta. p1-10.
8. De-Souza, N. (2014) Self-organizing stem cells. *Nat. Methods*, 11(31): 29-37.
9. Hu, C. and Li, L. (2015) Review: *In vitro* culture of isolated primary hepatocytes and stem cell-derived hepatocyte-like cells for liver regeneration. *Protein Cell*, 6(8): 562-574.
10. van-Agthoven, M., Groot, M.T., Verdonck, L.F., Lo-Wenberg, B., Schattenberg, A.V., Oudshoorn, M., Hagenbeek, A., Cornelissen, J.J., Uyl-de-Groot, C.A. and Willemze, R. (2012) Economic study cost analysis of HLA-identical sibling and voluntary unrelated allogeneic bone marrow and peripheral blood stem cell transplantation in adults with acute myelocytic leukaemia or acute lymphoblastic leukaemia. *Bone Marrow Transplant*, 30(4): 243-251.
11. Hozzein, W. (2016) Bee venom accelerates diabetic wound healing by suppressing the activating transcription factor-3 and inducible nitric oxid synthase-ediated oxidative stress and by recruiting bone marrow-derived endothelial progenitor cells in diabetic

- mice. Proceeding 13<sup>th</sup> Asian Apicultural Association Conference. April, 2016. Jeddah, Kingdom of Saudi Arabia. p134-135.
12. Aggarwal, S. and Pittenger, M.F. (2005) Human mesenchymal stem cells modulate allogeneic immune cell responses. *Blood*, 10(4): 1815-1822.
13. Najm, F., Madhavan, M., Zarembo, A., Shick, E., Karl, R.T., Factor, D.C., Miller, T.E., Nevin, Z.S., Kantor, C., Sargent, A., Quick, K.L., Schlatzer, D.M., Tang, H., Papoian, R., Brimacombe, K.R., Shen, M.N., Boxer, M.B., Jadhav, A., Robinson, A.P., Podojil, J.R., Miller, S.D., Miller, R.H. and Tesar, P.J. (2015) Drug-based modulation of endogenous stem cells promotes functional remyelination *in vivo*. *Nature*, 522(7555): 216-220.
14. Macey, M.G. (2007) Flow Cytometry, Principle and Applications. 1<sup>st</sup> ed. Human Press, Totowa, NJ. p1-31.
15. Sakri, F.M. (2012) Madu dan Khasiatnya, Suplemen Sehat Tanpa Efek Samping. 1<sup>st</sup> ed. Diandra Pustaka Indonesia, Yogyakarta. p20-25.
16. Nabiuni, M., Azimi, E., Shiravi, A. and Nazari, Z. (2012) Honey bee venom will differentiate mesenchymal stem cells into the osteocyte. International Conference on Applied Life Sciences, (ICALS 2012), Turkey. September, 10-12. p247-250.

17. Kumar, G.L. and Rudbeck, L. (2009) Immunohistochemical Staining Methods. 5<sup>th</sup> ed. Dako North America, Carpinteria, California. p11-14.
18. Caplan, A.I. (2007) Adult mesenchymal stemcells for tissue engineering versus regenerative medicine. Mini review. *J. Cell Physiol.*, 213(2): 341-347.
19. Wendy, W.P., Priceb, E.A., Sahooa, D., Beermanc, I., Maloneyd, W.J., Rossic, D.J., Schrierb, S.L. and Weissmana, I.L. (2011) Human bone marrow hematopoietic stem cells are increased in frequency and myeloid-biased with age. *PNAS*, 108(50): 20012-20017.
20. Santoro, N.F. and Cooper, A.R. (2016) Primary Ovarian Insufficiency - Clinical Guide to Early Menopause. e-Book. 1<sup>st</sup> ed. Springer, Switzerland. p82-83.
21. Rantam, F.A., Ferdiansyah. and Purwati. (2014) Stem Cell Mesenchymal, Hematopoetik dan Model Aplikasi. 2<sup>nd</sup>ed. Airlangga University Press, Surabaya. p45-50, 145-155.
22. Eckmann, L. (2006) Animal models of inflammatory bowel disease, lesson from enteric infections. *Ann. N. Y. Acad. Sci.*, 1072: 28-38.
23. Sengupta, P. (2013) The Laboratory rat: Relating its age with human's. *Int. J. Prev. Med.*, 4(6): 624-630.

24. Harrington, A.M., Olteanu, H. and Kroft, S.H. (2012) A dissection of the CD45/side scatter “Blast Gate”. *Am. J. Clin. Pathol.*, 137(5): 800-804.
25. Palermo, R. (2007) Differential actions of FSH and LH during folliculogenesis. *Reprod. Biomed. Online*, 5(3): 326-337.
26. Rantam, F.A., Ferdiansyah, Nasronudin. and Purwati. (2009) Stem Cell Exploration. Methods of Isolation and Culture. 1<sup>st</sup>ed. Airlangga University Press, Surabaya.
27. Crosby, K., Simendinger, J., Grange, C., Ferrante, M., Bernier, T. and Stanen, C. (2016) Immunohistochemistry protocol for paraffin-embedded tissue section-advertisement. *Cell Signal. Technol.*, ???: ???.
28. Barker, N. (2014) Adult intestinal stem cells: Critical drivers of epithelial homeostasis and regeneration. *Nat. Rev. Mol. Cell Biol.*, 15(1): 19-33.
29. Vander-Flier, L.G. and Clevers, H. (2009) Stem cells, self-renewal, and differentiation in the intestinal epithelium. *Annu. Rev. Physiol.*, 71: 241-260.
30. Hermann, M., Varrier, S. and Mauro, A. (2015) Strategies to stimulate mobilization and homing of endogenous stem and progenitor cells for bone tissue repair. *Front. Bioeng. Biotechnol.*, 2(3): 79.

31. Dong, J., Albertini, D.F., Nishimori, K., Kumar, T.J., Lu, N. and Matzuki, M.M. (1996) Growth differentiation factor-9 is required during early ovarian folliculogenesis. *Nature*, 383(6600): 531-535.
32. Dussaubat, C., Brunet, J.L., Higes, M., Colbourne, J.K., Lopez, J., Choi, J.H., Martin-Herna, R., Botias, C., Cousin, M., McDonnell, C., Bonnet, M., Belzunces, L.P., Moritz, R.F.A., Conte, Y.L. and Alaux, C.D. (2012) Gut pathology and responses to the microsporidium *nosemaceranae* in the honey bee *Apis mellifera*. *PLoS One*, 7(5): 1-12.
33. Filho, F.L.T., Baracat, E.C., Lee, T.H., Suh, C.S., Matsui, M., Chang, J., Shimasaki, S. and Erickson, G.F. (2001) Abberant expression of growth differentiation factor-9 in oocytes of polycystic ovary syndrome. *J. Clin. Endocrinol. Metab.*, 87: 1337-1344.
34. Lee, H.J., Salesniemi, K., Niikura, Y., Niikura, T., Klein, R., Dombkowski, D.M. and Tilly, J.L. (2007) Bone marrow transplantation generates immature oocytes and rescues long-term fertility in preclinical mouse model of chemotherapy-induced premature ovarian failure. *J. Clin. Oncol.*, 25: 198-204.
35. Dan, S., Haibo, L. and Hong, L. (2014) Review: Pathogenesis and stem cell therapy for premature ovarian failure. *OA Stem Cells*, 2(1): 1-8.

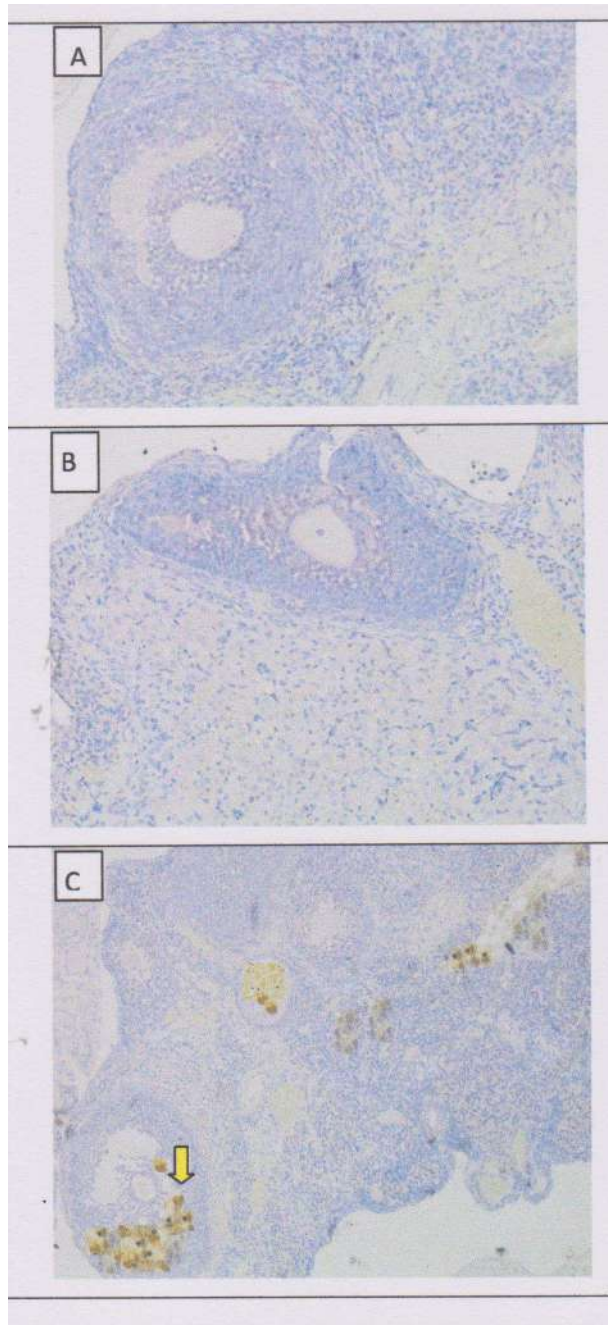
**Table-1:** Analysis of average VEGF, G-CSF and GDF-9 with immunohistochemical staining and Follicle dee Graaf count.

| <b>Treatments</b>   | <b>Average VEGF expression Score±SD</b> | <b>Average G-CSF expression Score±SD</b> | <b>Average GDF-9 expression Score±SD</b> | <b>Average follicle dee Graaf Count±SD</b> |
|---|---|--|--|--|
| Negative control group (T0-) with normal ovary without honeybee product         | 0.45±0.85 <sup>a</sup>                  | 0.75±0.35 <sup>a</sup>                   | 2.95±0.41 <sup>c</sup>                   | 7±0.85 <sup>c</sup>                        |
| Positive control group (T0+) with ovary failure without honeybee product        | 0.25±0.65 <sup>a</sup>                  | 0±0 <sup>a</sup>                         | 0±0 <sup>a</sup>                         | 0.75±0.125 <sup>a</sup>                    |
| T1 group, the ovary failure +50% honeybee product in drinking water for 10 days | 2.75±0.55 <sup>b</sup>                  | 2.95±0.43 <sup>b</sup>                   | 2±0.45 <sup>b</sup>                      | 5.416±0.807 <sup>b</sup>                   |

<sup>a,b,c</sup>Values in the same column with different superscripts indicate significant difference at  $p < 0.05$  (n=15). VEGF=Vascular endothelial growth factor, G-CSF=Granulocyte

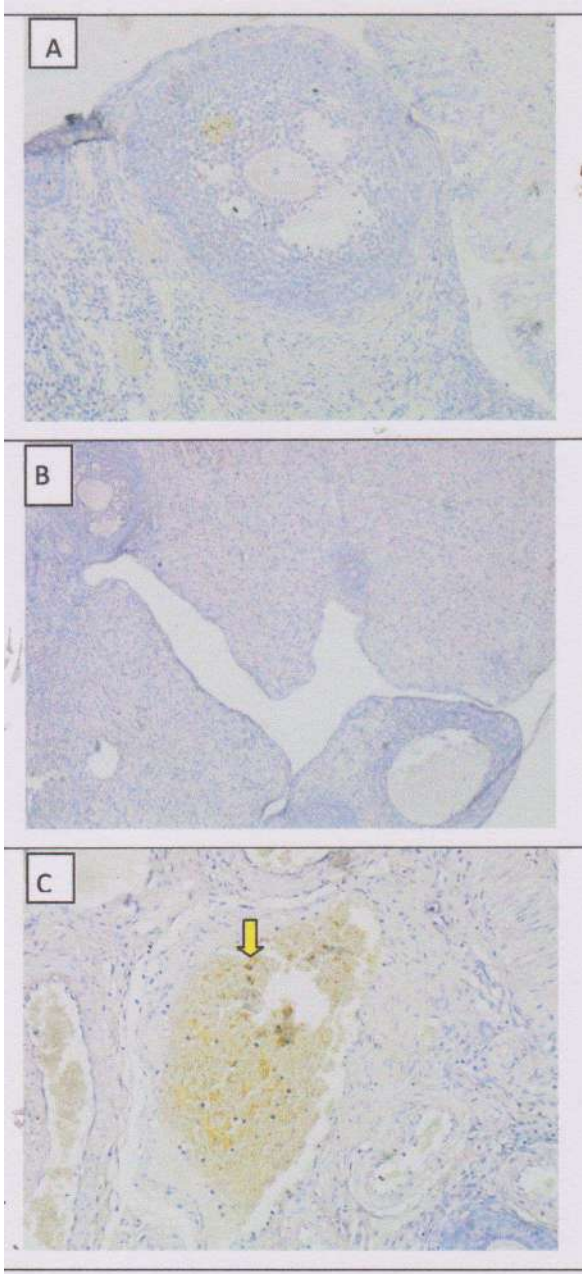


colony-stimulating factor, GDF-9=Growth differentiation factor-9

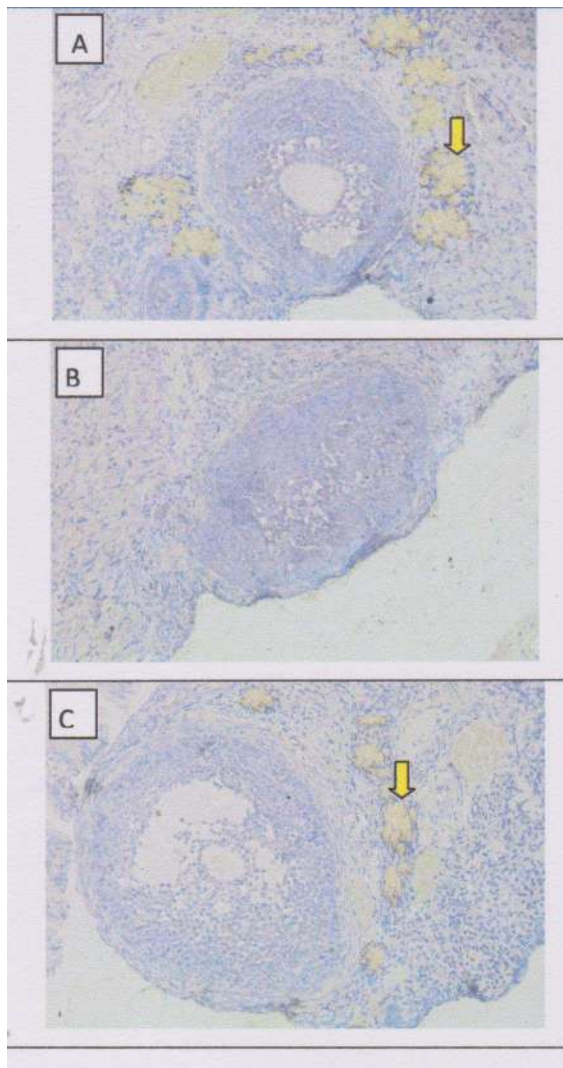


**Figure-1:** Homing of stem cells based on vascular endothelial growth factor (VEGF) expression in rat ovarian tissue by immunohistochemical. (a) Control negative group (T0-), with normal

ovary without honeybee product: Score of VEGF expression= $0.45\pm 0.85^a$ ; (b) control positive group (T0+), with ovary failure without honeybee product: Score of VEGF expression= $0.25\pm 0.65^a$ , (c) T1 group, the ovary failure +50% honeybee product in drinking water for 10 days: Score of VEGF expression  $2.75\pm 0.55^b$ . [The different superscripts indicate significant difference at  \$p<0.05\$](#)

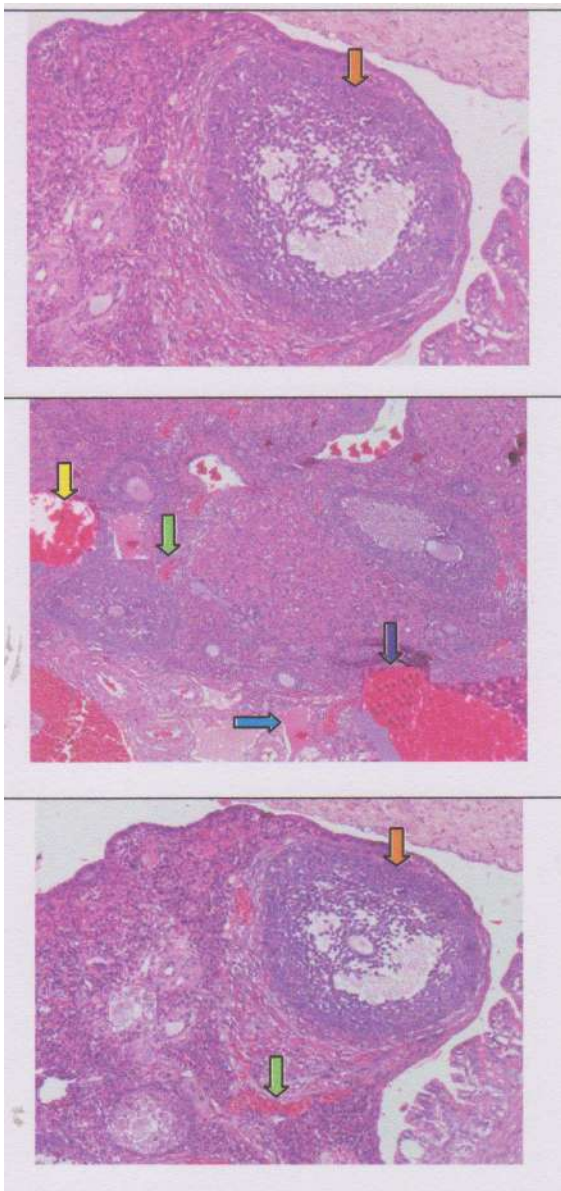


**Figure-2:** Homing of stem cells based on granulocyte colony-stimulating factor (G-CSF) expression in rat ovarian tissue by immunohistochemical. (a) Control negative group (T0-), with normal ovary without honeybee product: Score of G-CSF expression= $0.75\pm 0.35^a$ , (b) control positive group (T0+), with ovary failure without honeybee product: Score of G-CSF expression= $0\pm 0^a$ , (c) T1 group, the ovary failure +50% honeybee product in drinking water for 10 days: Score of G-CSF expression  $2.95\pm 0.43^b$ . [The different superscripts indicate significant difference at  \$p<0.05\$](#)



**Figure-3:** Growth differentiation factor-9 (GDF-9) expression in rat ovarian tissue shown by immunohistochemical staining on several treatments. (a) Control negative group (T0-), with

normal ovary without honeybee product: Score of GDF-9 expression= $2.95 \pm 0.41^c$ , (b) control positive group (T0+), with ovary failure without honeybee product: Score of GDF-9 expression= $0 \pm 0^a$ , (c) T1 group, the ovary failure +50% honeybee product in drinking water for 10 days: Score of GDF-9 expression  $2 \pm 0.45^b$ . [The different superscripts indicate significant difference at  \$p < 0.05\$](#)



**Figure-4:** The regeneration of ovarian tissue indicated by microscopic examination with hematoxylin and eosin (HE) staining in rat ovarian tissue in a few treatments. (a) Control negative group (T0-), with normal ovary without honeybee product was shown growing follicles (↓); (b) the group of ovary failure (T0+), congestion of ovarian (↓), and severe hemorrhage (↓), also visible hemosiderin (↓) due to blood cell lysis (brownish yellow color) with deposition of fibrin (⇒) indicating that chronic congestive has been occurred, (c) the group ovary failure + 50% honeybee product (T1), ovaries begin to regenerate so it looks intact, although there is still a slight hemorrhage and congestion in some areas, but has seen growing follicles (↓)

## Re: Safitri et al: proof for corrections

---

From: Safitri Erma (rma\_fispro@yahoo.com)  
To: editorveterinaryworld@gmail.com; rheru\_prasetyo@yahoo.co.id  
Date: Saturday, November 19, 2016 at 08:28 PM GMT+7

---

On Saturday, November 19, 2016 7:19 PM, Veterinary World <editorveterinaryworld@gmail.com> wrote:

Dear Dr. Erma Safitri,

We have sent you the proof in previous email. You have to just send the corrected proof to this email. Please refer the previous email for proof correction and correct as per suggestion and send to this email.

**NEWS:**

1. Veterinary World is indexed in Emerging Sources Citation Index (ESCI) - Web of Science of Thomson Reuters. <http://science.thomsonreuters.com/cgi-bin/jrnlst/jlresults.cgi?PC=EX&SC=ZC>
2. Veterinary World is indexed in PubMed and PubMed Central. <http://www.ncbi.nlm.nih.gov/nlmcatalog/101504872>
3. A new, prestigious journal, International Journal of One Health ([www.onehealthjournal.org](http://www.onehealthjournal.org)) was launched in early 2015 by Veterinary World.

-----  
Best Regards,

Dr. Anjum Sherasiya  
Editor-in-Chief  
Veterinary World  
Star, Gulshan Park, NH-8A,  
Chandrapur Road, Wankaner - 363621,  
Dist. Morbi (Gujarat), India.  
Website: [www.veterinaryworld.org](http://www.veterinaryworld.org), [onehealthjournal.org](http://onehealthjournal.org)  
E-mail: [editorveterinaryworld@gmail.com](mailto:editorveterinaryworld@gmail.com)

Follow us on

On Fri, Nov 18, 2016 at 10:13 PM, Safitri Erma <[rma\\_fispro@yahoo.com](mailto:rma_fispro@yahoo.com)> wrote:

Dear Editor

I can not send my proof article correction. Thank you for your cooperation

Best Regad  
Dr. Erma Safitri, M.Si. Drh

On Friday, November 18, 2016 10:56 AM, Veterinary World <[editorveterinaryworld@gmail.com](mailto:editorveterinaryworld@gmail.com)> wrote:

Dear Authors,

PLEASE READ BELOW MESSAGE CAREFULLY BEFORE PROOF CORRECTIONS.

Please put all co-authors in cc email when you send the reply to us.  
Please use Word 2010 or higher to read and correct the proof with track changes.

I am attaching herewith proof of copy-edited word file of your article. WE HAVE COPYEDITED AT MANY SENTENCES. We have not provided the article with track changed corrections as many authors get confused. SO, PLEASE CHECK EACH SENTENCE CAREFULLY.

Also check the highlighted words if any in your manuscript.

Also please check whole manuscript carefully for any mistake (author name, affiliation, emails, how to cite, text of article, abbreviation, full forms, figures (if any - figures will be formatted in exact size in the PDF), tables (if any). etc). Please check that all figures/tables are cited in the text part or not? Correct the manuscript as per comments given on right column if any. Please be careful in correction as we will create the PDF directly from this file. We will provide the PDF as final proof before publication.

PLEASE CHECK THAT ALL REFERENCES ARE IN CONTINUOUS NO. OR NOT ?

Please do the changes in this word file with track changes only or reply in comment box if any. Please do not add/delete anything without track changes.

WE USE US ENGLISH SO, PLEASE DO NOT CONVERT SPELLINGS TO UK ENGLISH (i.e. estrus to oestrus, hematological to haematological etc.)

Please include authors' contribution section, acknowledgement along with source of fund for the study, competing interests statement etc if you have not included.

Also send the corrections in separate file with page no., line no. etc.

PLEASE COLLABORATE WITH CORRESPONDING AUTHOR AND SEND THE CORRECTION THROUGH CORRESPONDING AUTHOR EMAIL ONLY WITHIN 3 DAYS. WE WILL PROVIDE PDF PROOF AFTER CORRECTION OF COPYEDITED PROOF.

If there is no correction then reply accordingly.

**NEWS:**

1. Veterinary World is indexed in Emerging Sources Citation Index (ESCI) - Web of Science of Thomson Reuters. <http://science.thomsonreuters.com/cgi-bin/jrnlst/jlresults.cgi?PC=EX&SC=ZC>
2. Veterinary World is indexed in PubMed and PubMed Central. <http://www.ncbi.nlm.nih.gov/nlmcatalog/101504872>
3. A new, prestigious journal, International Journal of One Health ([www.onehealthjournal.org](http://www.onehealthjournal.org)) was launched in early 2015 by Veterinary World.

-----  
Best Regards,

Dr. Anjum Sherasiya

Editor-in-Chief

Veterinary World

Star, Gulshan Park, NH-8A,

Chandrapur Road, Wankaner - 363621,

Dist. Morbi (Gujarat), India.

Website: [www.veterinaryworld.org](http://www.veterinaryworld.org), [onehealthjournal.org](http://onehealthjournal.org)

E-mail: [editorveterinaryworld@gmail.com](mailto:editorveterinaryworld@gmail.com)

Follow us on



Erma Safitri-Proof OK.docx  
1.1MB



## Re: Safitri et al: proof for corrections

---

From: Safitri Erma (rma\_fispro@yahoo.com)  
To: editorveterinaryworld@gmail.com  
Date: Tuesday, November 22, 2016 at 05:35 AM GMT+7

---

On Monday, November 21, 2016 7:45 PM, Veterinary World <editorveterinaryworld@gmail.com> wrote:

Dear Dr. Erma Safitri,

Please refer our previous email that we have asked you to provide the corrected proof as per below suggestions.

You have to cite the reference no. 28 in continuous no., you have cited it before 27 so, you must have to rearrange references to accommodate reference no. 28 in continuous no. in text part as well as in reference section.

Also you have to cite significant values i.e.  $P < 0.0.1$  or  $P > 0.01$ ,  $P < 0.05$  etc whichever applicable at appropriate places. Just putting a, b is not sufficient.

So, please include above corrections in the proof and send it to us as soon as possible. Please do not forget to keep all corrections/additions in track changes.

WE WILL NOT PREPARE THE PDF PROOF IF YOU DO NOT SUBMIT THE CORRECTED WORD PROOF AS PER SUGGESTIONS.

### **NEWS:**

1. Veterinary World is indexed in Emerging Sources Citation Index (ESCI) - Web of Science of Thomson Reuters. <http://science.thomsonreuters.com/cgi-bin/jrnlst/jlresults.cgi?PC=EX&SC=ZC>
2. Veterinary World is indexed in PubMed and PubMed Central. <http://www.ncbi.nlm.nih.gov/nlmcatalog/101504872>
3. A new, prestigious journal, International Journal of One Health ([www.onehealthjournal.org](http://www.onehealthjournal.org)) was launched in early 2015 by Veterinary World.

-----  
Best Regards,

Dr. Anjum Sherasiya  
Editor-in-Chief  
Veterinary World  
Star, Gulshan Park, NH-8A,  
Chandrapur Road, Wankaner - 363621,  
Dist. Morbi (Gujarat), India.  
Website: [www.veterinaryworld.org](http://www.veterinaryworld.org), [onehealthjournal.org](http://onehealthjournal.org)  
E-mail: [editorveterinaryworld@gmail.com](mailto:editorveterinaryworld@gmail.com)

Follow us on

On Mon, Nov 21, 2016 at 6:11 PM, Safitri Erma <[rma\\_fispro@yahoo.com](mailto:rma_fispro@yahoo.com)> wrote:

Dear Editor,  
I send my proof correction. Thank you for your cooperation

Best Regard,  
Dr. Erma Safitri

On Monday, November 21, 2016 11:18 AM, Veterinary World <[editorveterinaryworld@gmail.com](mailto:editorveterinaryworld@gmail.com)> wrote:

Dear Dr. Erma Safitri,

You have to cite the reference no. 28 in continuous no., you have cited it before 27 so, you must have to rearrange references to accommodate reference no. 28 in continuous no. in text part as well as in reference section.

Also you have to cite significant values i.e.  $P < 0.01$  or  $P > 0.01$ ,  $P < 0.05$  etc whichever applicable at appropriate places. Just putting a, b is not sufficient.

So, please include above corrections in the proof and send it to us as soon as possible. Please do not forget to keep all corrections/additions in track changes.

**NEWS:**

1. Veterinary World is indexed in Emerging Sources Citation Index (ESCI) - Web of Science of Thomson Reuters. <http://science.thomsonreuters.com/cgi-bin/jrnlst/jlresults.cgi?PC=EX&SC=ZC>
2. Veterinary World is indexed in PubMed and PubMed Central. <http://www.ncbi.nlm.nih.gov/nlmcatalog/101504872>
3. A new, prestigious journal, International Journal of One Health ([www.onehealthjournal.org](http://www.onehealthjournal.org)) was launched in early 2015 by Veterinary World.

-----  
Best Regards,

Dr. Anjum Sherasiya  
Editor-in-Chief  
Veterinary World  
Star, Gulshan Park, NH-8A,  
Chandrapur Road, Wankaner - 363621,  
Dist. Morbi (Gujarat), India.  
Website: [www.veterinaryworld.org](http://www.veterinaryworld.org), [onehealthjournal.org](http://onehealthjournal.org)  
E-mail: [editorveterinaryworld@gmail.com](mailto:editorveterinaryworld@gmail.com)

Follow us on

On Sat, Nov 19, 2016 at 6:58 PM, Safitri Erma <[rma\\_fispro@yahoo.com](mailto:rma_fispro@yahoo.com)> wrote:

On Saturday, November 19, 2016 7:19 PM, Veterinary World <[editorveterinaryworld@gmail.com](mailto:editorveterinaryworld@gmail.com)> wrote:

Dear Dr. Erma Safitri,

We have sent you the proof in previous email. You have to just send the corrected proof to this email. Please refer the previous email for proof correction and correct as per suggestion and send to this email.

**NEWS:**

1. Veterinary World is indexed in Emerging Sources Citation Index (ESCI) - Web of Science of Thomson Reuters. <http://science.thomsonreuters.com/cgi-bin/jrnlst/jlresults.cgi?PC=EX&SC=ZC>
2. Veterinary World is indexed in PubMed and PubMed Central. <http://www.ncbi.nlm.nih.gov/nlmcatalog/101504872>

3. A new, prestigious journal, International Journal of One Health ([www.onehealthjournal.org](http://www.onehealthjournal.org)) was launched in early 2015 by Veterinary World.

-----  
Best Regards,

Dr. Anjum Sherasiya  
Editor-in-Chief  
Veterinary World  
Star, Gulshan Park, NH-8A,  
Chandrapur Road, Wankaner - 363621,  
Dist. Morbi (Gujarat), India.  
Website: [www.veterinaryworld.org](http://www.veterinaryworld.org), [onehealthjournal.org](http://onehealthjournal.org)  
E-mail: [editorveterinaryworld@gmail.com](mailto:editorveterinaryworld@gmail.com)

Follow us on

On Fri, Nov 18, 2016 at 10:13 PM, Safitri Erma <[rma\\_fispro@yahoo.com](mailto:rma_fispro@yahoo.com)> wrote:  
Dear Editor

I can not send my proof article correction. Thank you for your cooperation

Best Regad  
Dr. Erma Safitri, M.Si. Drh

On Friday, November 18, 2016 10:56 AM, Veterinary World <[editorveterinaryworld@gmail.com](mailto:editorveterinaryworld@gmail.com)> wrote:

Dear Authors,

PLEASE READ BELOW MESSAGE CAREFULLY BEFORE PROOF CORRECTIONS.

Please put all co-authors in cc email when you send the reply to us.

Please use Word 2010 or higher to read and correct the proof with track changes.

I am attaching herewith proof of copy-edited word file of your article. WE HAVE COPYEDITED AT MANY SENTENCES. We have not provided the article with track changed corrections as many authors get confused. SO, PLEASE CHECK EACH SENTENCE CAREFULLY.

Also check the highlighted words if any in your manuscript.

Also please check whole manuscript carefully for any mistake (author name, affiliation, emails, how to cite, text of article, abbreviation, full forms, figures (if any - figures will be formatted in exact size in the PDF), tables (if any). etc). Please check that all figures/tables are cited in the text part or not? Correct the manuscript as per comments given on right column if any. Please be careful in correction as we will create the PDF directly from this file. We will provide the PDF as final proof before publication.

PLEASE CHECK THAT ALL REFERENCES ARE IN CONTINUOUS NO. OR NOT ?

Please do the changes in this word file with track changes only or reply in comment box if any. Please do not add/delete anything without track changes. WE USE US ENGLISH SO, PLEASE DO NOT CONVERT SPELLINGS TO UK ENGLISH (i.e. estrus to oestrus, hematological to haematological etc.)

Please include authors' contribution section, acknowledgement along with source of fund for the study, competing interests statement etc if you have

not included.

Also send the corrections in separate file with page no., line no. etc.

PLEASE COLLABORATE WITH CORRESPONDING AUTHOR AND SEND THE CORRECTION THROUGH CORRESPONDING AUTHOR EMAIL ONLY WITHIN 3 DAYS. WE WILL PROVIDE PDF PROOF AFTER CORRECTION OF COPYEDITED PROOF.

If there is no correction then reply accordingly.

**NEWS:**

1. Veterinary World is indexed in Emerging Sources Citation Index (ESCI) - Web of Science of Thomson Reuters. <http://science.thomsonreuters.com/cgi-bin/jrnlst/jlresults.cgi?PC=EX&SC=ZC>
2. Veterinary World is indexed in PubMed and PubMed Central. <http://www.ncbi.nlm.nih.gov/nlmcatalog/101504872>
3. A new, prestigious journal, International Journal of One Health ([www.onehealthjournal.org](http://www.onehealthjournal.org)) was launched in early 2015 by Veterinary World.

-----  
Best Regards,

Dr. Anjum Sherasiya  
Editor-in-Chief  
Veterinary World  
Star, Gulshan Park, NH-8A,  
Chandrapur Road, Wankaner - 363621,  
Dist. Morbi (Gujarat), India.  
Website: [www.veterinaryworld.org](http://www.veterinaryworld.org), [onehealthjournal.org](http://onehealthjournal.org)  
E-mail: [editorveterinaryworld@gmail.com](mailto:editorveterinaryworld@gmail.com)

Follow us on



Erma Safitri-Proof OK Rev.docx  
1.1MB

## Safitri et al.: Your article has been published online (Publication Certificate attached)

---

From: Veterinary World - Publisher (veterinaryworldpublisher@gmail.com)

To: rma\_fispro@yahoo.com; th\_v\_widiyatno@yahoo.co.id; rheru\_prasetyo@yahoo.co.id

Cc: editorveterinaryworld@gmail.com

Date: Tuesday, November 29, 2016 at 10:24 AM GMT+7

---

Dear Authors,

Your article has been published online at [www.veterinaryworld.org](http://www.veterinaryworld.org). Please take the print out of PDF and check for any error. Also check that each page of PDF display correctly in Google Chrome, Firefox, Internet explorer etc.

Your article is also posted on

Facebook at <https://www.facebook.com/pages/Veterinary-World/130258510480187>,

LinkedIn at [http://www.linkedin.com/groups/Veterinary-World-6574956?trk=my\\_groups-b-grp-v](http://www.linkedin.com/groups/Veterinary-World-6574956?trk=my_groups-b-grp-v)

Twitter at <https://twitter.com/VetWorld>,

Directory of open access journal at <https://doaj.org/toc/2231-0916>

Please confirm with us that there is no error. If any errors are there then please send us immediately.

I am attaching herewith the publication certificate of your article published in Veterinary World.

### **NEWS:**

1. Veterinary World is indexed in Emerging Sources Citation Index (ESCI) - Thomson Reuters. <http://science.thomsonreuters.com/cgi-bin/jrnlst/jlresults.cgi?PC=EX&SC=ZC>
2. Veterinary World is indexed in PubMed and PubMed Central. <http://www.ncbi.nlm.nih.gov/nlmcatalog/101504872>
3. A new, prestigious journal, International Journal of One Health ([www.onehealthjournal.org](http://www.onehealthjournal.org)) was launched in early 2015 by Veterinary World.

-----  
Best Regards,

Nazir  
Editorial Assistant  
Veterinary World  
Star, Gulshan Park,  
NH-8A, Chandrapur Road,  
Wankaner, Dist. Morbi, Gujarat  
India

[www.veterinaryworld.org](http://www.veterinaryworld.org)

[www.onehealthjournal.org](http://www.onehealthjournal.org)



26.pdf  
163.3kB



# Veterinary World

Open access and peer reviewed international journal

NAAS (National Academy of Agricultural Sciences -INDIA) - 5.10,  
SCOPUS: SJR (Scimago Journal Rank) - 0.265, IPP (Impact per publication) - 0.47, SNIP (Source Normalized Impact per Paper) - 0.600

## PUBLICATION CERTIFICATE

This is to certify that article entitled:

### **Honeybee product therapeutic as stem cells homing for ovary failure**

Erma Safitri, Thomas V. Widiyatno and R. Heru Prasetyo

has been published online at <http://www.veterinaryworld.org/Vol.9/November-2016/26.pdf> on 29-11-2016.

**Citation:** Safitri E, Widiyatno TV, Prasetyo RH (2016) Honeybee product therapeutic as stem cells homing for ovary failure, *Veterinary World*, 9(11): 1324-1330.

**doi:** 10.14202/vetworld.2016.1324-1330

Anjum V. Sherasiya  
Editor-in-Chief

**Certificate issue date: 29-11-2016**

**EISSN:** 2231-0916, **Website:** <http://www.veterinaryworld.org>

**Corresponding author:** Erma Safitri, Department of Veterinary Reproduction, Faculty of Veterinary Medicine, Universitas Airlangga, Surabaya, East Java, Indonesia; Stem Cells Research Division of Institute Tropical Disease, Universitas Airlangga, Surabaya, East Java, Indonesia. E-mail: [rma\\_fispro@yahoo.com](mailto:rma_fispro@yahoo.com)

## Safitri et al: final PDF proof for corrections (Veterinary World)

---

From: Veterinary World - Publisher (veterinaryworldpublisher@gmail.com)

To: rma\_fispro@yahoo.com; th\_v\_widiyatno@yahoo.co.id; rheru\_prasetyo@yahoo.co.id

Date: Thursday, November 24, 2016 at 08:23 PM GMT+7

---

Dear Authors,

I am attaching herewith formatted PDF for final proof corrections.

Please put all co-authors in cc email when you send the reply to us.

Please check that all suggested corrections (sent by you in Word file proof) are made in PDF or not. Also check that all reference no. in the text are in continuous no. or not.

Please send us the corrections with sticky note in PDF within 3 days. If there is no correction from your side then reply accordingly.

Please check everything carefully; Author name, affiliations, emails, how to cite article, article text, figures, tables, dates etc. Please check that all reference no. in the text are in continuous no. If not in continuous no. then amend it and amend in reference section also.

If you have any sticky note correction in proof then do accordingly and please insert it in corrected PDF also.

PLEASE COLLABORATE WITH CORRESPONDING AUTHOR AND SEND THE CORRECTION THROUGH CORRESPONDING AUTHOR EMAIL ONLY.

If there is no correction then reply accordingly.

**NEWS:**

1. Veterinary World is indexed in Emerging Sources Citation Index (ESCI) - Thomson Reuters. <http://science.thomsonreuters.com/cgi-bin/jrnlst/jlresults.cgi?PC=EX&SC=ZC>

2. Veterinary World is indexed in PubMed and PubMed Central. <http://www.ncbi.nlm.nih.gov/nlmcatalog/101504872>

3. A new, prestigious journal, International Journal of One Health ([www.onehealthjournal.org](http://www.onehealthjournal.org)) was launched in early 2015 by Veterinary World.

-----  
Best Regards,

Nazir  
Editorial Assistant  
Veterinary World  
Star, Gulshan Park,  
NH-8A, Chandrapur Road,  
Wankaner, Dist. Morbi, Gujarat  
India

[www.veterinaryworld.org](http://www.veterinaryworld.org)

[www.onehealthjournal.org](http://www.onehealthjournal.org)



26.pdf  
3.2MB

---

**Re: Safitri et al: final PDF proof for corrections (Veterinary World)**

---

From: Safitri Erma (rma\_fispro@yahoo.com)  
To: veterinaryworldpublisher@gmail.com; editorveterinaryworld@gmail.com  
Cc: rheru\_prasetyo@yahoo.co.id; th\_v\_widiyatno@yahoo.co.id  
Date: Friday, November 25, 2016 at 09:17 AM GMT+7

---

On Thursday, November 24, 2016 8:23 PM, Veterinary World - Publisher <veterinaryworldpublisher@gmail.com> wrote:

Dear Authors,

I am attaching herewith formatted PDF for final proof corrections.  
Please put all co-authors in cc email when you send the reply to us.  
Please check that all suggested corrections (sent by you in Word file proof) are made in PDF or not. Also check that all reference no. in the text are in continuous no. or not.  
Please send us the corrections with sticky note in PDF within 3 days. If there is no correction from your side then reply accordingly.  
Please check everything carefully; Author name, affiliations, emails, how to cite article, article text, figures, tables, dates etc. Please check that all reference no. in the text are in continuous no. If not in continuous no. then amend it and amend in reference section also. If you have any sticky note correction in proof then do accordingly and please insert it in corrected PDF also.

PLEASE COLLABORATE WITH CORRESPONDING AUTHOR AND SEND THE CORRECTION THROUGH CORRESPONDING AUTHOR EMAIL ONLY.

If there is no correction then reply accordingly.

NEWS:

1. Veterinary World is indexed in Emerging Sources Citation Index (ESCI) - Thomson Reuters. <http://science.thomsonreuters.com/cgi-bin/jrnlst/jlresults.cgi?PC=EX&SC=ZC>
2. Veterinary World is indexed in PubMed and PubMed Central. <http://www.ncbi.nlm.nih.gov/nlmcatalog/101504872>
3. A new, prestigious journal, International Journal of One Health ([www.onehealthjournal.org](http://www.onehealthjournal.org)) was launched in early 2015 by Veterinary World.

-----  
Best Regards,

Nazir  
Editorial Assistant  
Veterinary World  
Star, Gulshan Park,  
NH-8A, Chandrapur Road,  
Wankaner, Dist. Morbi, Gujarat  
India  
[www.veterinaryworld.org](http://www.veterinaryworld.org)  
[www.onhealthjournal.org](http://www.onhealthjournal.org)





26 - Revision.pdf  
3.2MB

## Honeybee product therapeutic as stem cells homing for ovary failure

Erma Safitri<sup>1,2</sup>, Thomas V. Widiyatno<sup>3</sup> and R. Heru Prasetyo<sup>4</sup>

1. Department of Veterinary Reproduction, Faculty of Veterinary Medicine, Universitas Airlangga, Airlangga, East Java, Indonesia; 2. Stem Cells Research Division of Institute Tropical Disease, Universitas Airlangga, Airlangga, East Java, Indonesia; 3. Department of Veterinary Pathology, Faculty of Veterinary Medicine, Universitas Airlangga, Airlangga, East Java, Indonesia; 4. Department of Parasitology, Faculty of Medicine, Universitas Airlangga, Airlangga, East Java, Indonesia.

**Corresponding author:** Erma Safitri, e-mail: [rma\\_fispro@yahoo.com](mailto:rma_fispro@yahoo.com),  
TVW: [th\\_v\\_widiyatno@yahoo.co.id](mailto:th_v_widiyatno@yahoo.co.id), RHP: [rheru\\_prasetyo@yahoo.co.id](mailto:rheru_prasetyo@yahoo.co.id)  
**Received:** 16-09-2016, **Accepted:** 21-10-2016, **Published online:** \*\*\*

**doi:** 10.14202/vetworld.2016.1324-1330 **How to cite this article:** Safitri E, Widiyatno TV, Prasetyo RH (2016) Honeybee product therapeutic as stem cells homing for ovary failure, *Veterinary World*, 9(11): 1324-1330.

### Abstract

**Aim:** Complexity of the method of isolation, cultivation *in vitro* and the expensive cost of transplantation process of stem cells, it would require an innovation to homing and differentiation of stem cells and increase folliculogenesis. The stem cells homing was achieved through the provision of food or beverages derived from natural materials like honeybee product. Through honeybee product, there will be homing of stem cells and accompany with the sources from the body itself will take place in regeneration of the ovary.

**Materials and Methods:** Female rats model of degenerative ovary was obtained through food fasting but still have drinking water for 5 days. It caused malnutrition and damage of the ovarian tissue. The administration of 50% honeybee product (T1) was performed for 10 consecutive days, while the positive control group (T0+) was fasted and not given honeybee product and the negative control (T0-) not fasted and without honeybee product. Observations were taken for homing of stem cells, raised of folliculogenesis, differentiation of stem cells, and regeneration of the ovarian tissue using routine H&E staining.

**Results:** Homing of stem cells shown the vascular endothelial growth factor and granulocyte colony-stimulating factor expression; enhancement of folliculogenesis was indicated by an increase of follicle dee Graaf count; enhancement of differentiation of stem cells was indicated by growth differentiation factor-9 expression; and regeneration of ovarian tissue indicated by intact ovarian tissue with growing follicles.

**Conclusion:** Honeybee product can be induced endogenous stem cells in regeneration of ovary failure due to malnutrition.

**Keywords:** honeybee product, ovary failure, stem cells homing.

### Introduction

The interest of stem cell therapy today and the next few decades tends to be greatly increased [1-3]. The stem cells have tremendous promise to treat a range of diseases. Stem cell transplantation provides new hope in the treatment of various diseases including infertility due to degenerative conditions of the ovary which could not be cured through usual treatment and operative measures [3-7].

However, because of the complexity of the method of isolation [8], cultivation *in vitro* [9] and the expensive cost of transplantation process of stem cells [10], it would require an innovation to homing of stem cells and increase immune response [4,11,12] and in the same time induced a differentiation of endogenous stem cells [11,13], and therefore, avoid the expensive process of transplantation. Automobilization and increased immune response accompanied with the

differentiation of stem cells was achieved through the provision of food or beverages derived from natural materials like honeybee product [3,4,11,14].

The recent study performed a provision of honeybee product [3,4,11,15,16]. Through the administration of honeybee products, it was expected a homing and differentiation of stem cells the patients with ovary failure [4,17]. The presence of homing and differentiation of stem cells is made from the body itself and it will regenerate the follicles of the ovary.

The regeneration of ovary can be proven microscopically and also on molecular level [13,18]. The histological appearance will reveal regeneration of ovarian tissue at molecular level there were evident of several expressions such as CD34+ and CD45+ of hematopoietic stem cells (HSCs) [4,19], expression of transforming growth factor- $\beta$  (TGF- $\beta$ ) [11], vascular endothelial growth factor (VEGF), granulocyte colony-stimulating factor (G-CSF) [11,20,21], and growth differentiation factor-9 (GDF-9) of the ovary [20,21].

The aim of the study was using honeybee product therapeutic will be homing of stem cells (based on VEGF and G-CSF expression), increase of folliculogenesis count and stem cells differentiation (based on GDF-9 expression) and accompany with the sources from the body itself will take place in regeneration of the ovary (based on histopathological observation

Copyright: Safitri, et al. Open Access. This article is distributed under the terms of the Creative Commons Attribution 4.0 International License (<http://creativecommons.org/licenses/by/4.0/>), which permits unrestricted use, distribution, and reproduction in any medium, provided you give appropriate credit to the original author(s) and the source, provide a link to the Creative Commons license, and indicate if changes were made. The Creative Commons Public Domain Dedication waiver (<http://creativecommons.org/publicdomain/zero/1.0/>) applies to the data made available in this article, unless otherwise stated.

with H&E staining) on rat model with ovary failure due to malnutrition.

## Materials and Methods

### Ethical approval

The present study was approved by ethical committee vide Ethical Clearance No: 064-KE (Komisi Etik Penelitian, Fakultas Kedokteran Hewan Universitas Airlangga, Animal Care and Use Committee (ACUC)).

### Ovarian degeneration modeling

Malnutrition which causes the ovaries degeneration in female rats was performed following food fasting for 5 consecutive days, but they still have water to drink *ad libitum* using feeding tube [22]. The laboratory animals used in this study were healthy female Wistar rats, 12-14 week-old and each 250-300 g weight [23]. Healthy condition was determined by their active movement. Rats kept in an individual plastic cage in laboratory for Experimental Animal of Veterinary Medicine, Faculty of Universitas Airlangga with adequate ventilation.

Treatment: The study was divided into three groups, each has 15 replications. They were:

1. The negative control group (T0-): Rats with ovary normal (not fasted) and without honeybee product
2. The positive control group (T0+): Rats with ovary failure (fasted for 5 days) and without honeybee product
3. The treatment Group 2 (T1): Rats ovary failure (fasted for 5 days), given 50% honeybee product in the drinking water for the next 10 days after fasted.

Honeybee products that used in this study were raw honeybee products from Batu Malang East Java, Indonesia. Observations were taken for homing stem cells, raised of folliculogenesis, differentiation of stem cells, and regeneration of the ovarian tissue. Homing of stem cells was shown by VEGF and G-CSF expressions [11,21]. Raised of folliculogenesis was indicated by an increase of follicle dee Graaf expression [24]. Differentiation of stem cells into progenitor cells presented by the expression of GDF-9 using immunohistochemistry technique in ovarian tissue [20,21] and regeneration of the ovarian tissue using routine HE staining [25].

### Immunohistochemical (IHC) methods for observation of VEGF, G-CSF, and GDF-9

IHC observation was performed to determine the expressions of VEGF, G-CSF, and GDF-9 [11,21,25]. First, made an incision through ovarian tissues transversely from paraffin blocks [25]. The IHC techniques using monoclonal antibodies anti-VEGF, anti-G-CSF, and anti-GDF-9. Observations of VEGF, G-CSF, and GDF-9 expressions were made using a light microscope with a magnification of 200 times. The expression of each variable is indicated by the number of cells with brownish discoloration due to DAB-chromogen in each incision [25,26].

### Histological and follicle dee Graaf observation of ovary

Identification of follicle dee Graaf and regenerate ovarian tissues performed through light microscopy examination [27]. Histological preparations such as the following: Fixation of rat ovary in 10% buffer formalin. Subsequently dehydration with a series of alcohol, i.e., from 70%, 80%, 90%, and 96% (absolute). Clearing of the ovary of rat in xylene solution. The tissues were infiltrated with embedding agent, the liquid paraffin. The sectioning was done with microtome that could be set with a distance at 4-6  $\mu$ , and the sections were placed on a slide. The embedding process must be reversed to get the paraffin wax out of the tissue and allow water soluble dyes to penetrate the sections. Therefore, before any staining can be done, the slides are "deparaffinized" by running them through xylenes to alcohols to water. The staining used was the routine H & E. The stained section then mounted with Canada balsam and placed a coverslip on it [25].

Observations and identifications of follicle dee Graaf and ovarian regenerations are based on the histological measures of that of the normal tissue [4,25].

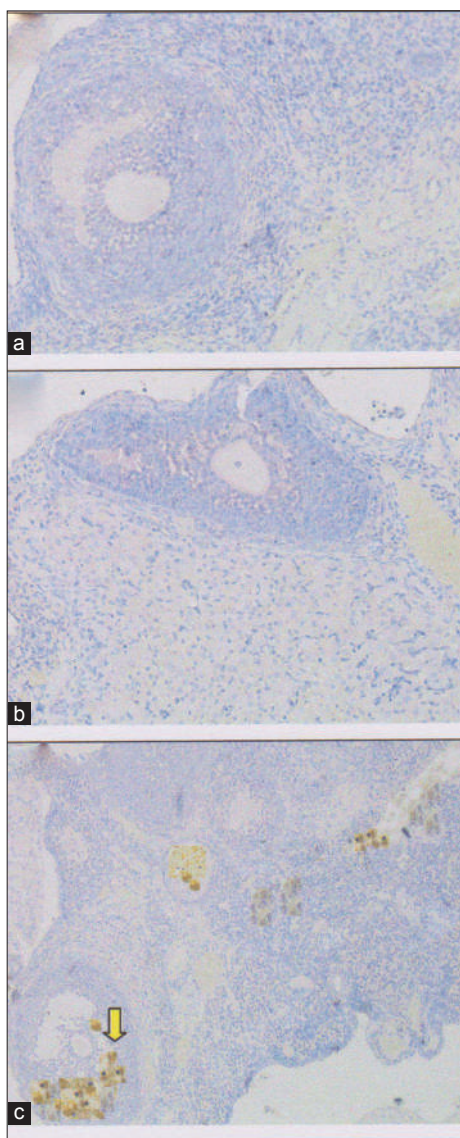
### Statistical analysis

Expressions of follicle dee Graaf, VEGF, G-CSF, and GDF-9 were statistically analyzed using SPSS 15 for Windows XP with the level of significance 0.05 ( $p=0.05$ ) and the confidence level 99% ( $\alpha=0.01$ ). Steps of comparative hypothesis tests are as follows: Test data normality with the Kolmogorof-Smirnov test, homogeneity of variance test, analysis of variance factorial, and *post-hoc* test (least significant difference test) using the Tukey HSD 5%.

### Results and Discussion

The collected data from 45 female rats were divided into three groups: Negative control group (T0-) is normal ovary without honeybee product; positive control group (T0+) is ovary failure without honeybee product; (T1) group is ovary failure + 50% honeybee product in drinking water for 10 days. In detail, the results of the study are as follows: The effectiveness of honeybee product was based on: (1) Homing of stem cells based on VEGF and G-CSF expressions, (2) follicle dee Graaf count, (3) GDF-9 expressions, and (4) regeneration of ovarian tissue.

Homing of stem cells analyzed by IHC based on increased of VEGF and G-CSF expression. The analysis showed that: Nonsignificant of the negative control group (T0-) and the positive control group (T0+) showed homing of stem cells, based on the lower expression of VEGF and G-CSF with average were <1 (Figures-1 and 2), while the (T1) group has shown homing of stem cells based on the average of VEGF and G-CSF=2.75 $\pm$ 0.55<sup>b</sup> and 2.95 $\pm$ 0.43<sup>b</sup> (Figures-1 and 2). Based on statistical analysis T1 group was significantly different ( $p<0.05$ ) than the other two treatments (T0- and T0+), but among the latter two treatments no significant difference ( $p>0.05$ ) (Table-1).



**Figure-1:** Homing of stem cells based on vascular endothelial growth factor (VEGF) expression in rat ovarian tissue by immunohistochemical. (a) Control negative group (T0-), with normal ovary without honeybee product: Score of VEGF expression= $0.45\pm 0.85^a$ ; (b) control positive group (T0+), with ovary failure without honeybee product: Score of VEGF expression= $0.25\pm 0.65^a$ , (c) T1 group, the ovary failure +50% honeybee product in drinking water for 10 days: Score of VEGF expression  $2.75\pm 0.55^b$ . The different superscripts indicate significant difference at  $p<0.05$ .

Furthermore, enhancement of folliculogenesis based on follicle dee Graaf expression, in the normal control group (T0-) where its count was  $7\pm 0.845^c$ . The group was significantly different ( $p<0,05$ ) than the group of ovary failure (T0+) was  $0.75\pm 0.125^a$  and The group with ovary failure +50% honeybee product (T1) was  $5.416\pm 0.807^b$  (Table-1). However, the group of ovary failure (T0+) has the lowest follicle dee Grasf expression. The group of ovary failure (T0+) was significantly different ( $p<0,05$ ) than the group with ovary failure +50% honeybee product (T1).

The effectiveness of honeybee product is based on GDF-9 expression as a result of the differentiation of the progenitor cells. Expression of GDF-9 in the group with 50% honeybee product (T1) had scored  $2\pm 0.43^b$  (GDF-9 expression between 25% and 50%). Although, the T1 group's score was lower than the normal control group (T0-) with the score was  $2.95\pm 0.41^c$  and GDF-9 expression >50%, but still higher than the (T0+) group with ovary failure, which was not expressed at all ( $0\pm 0^a$  and GDF-9 expression 0%) (Table-1 and Figure-3).

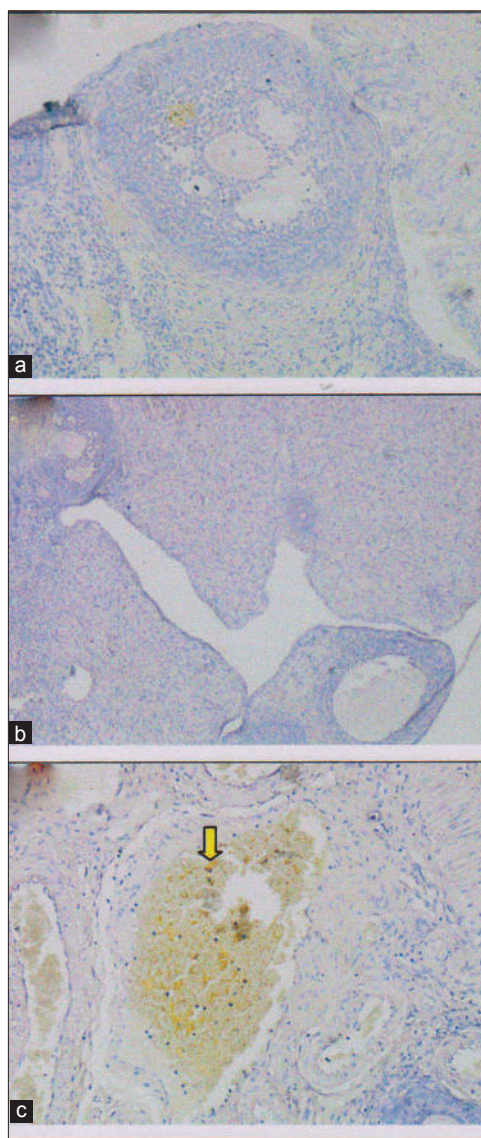
In this study, the regeneration of the ovary could be observed histologically with H & E staining. Microscopic examination showed that the group with ovary failure +50% honeybee product (T1) did the best ovarian tissue repair. The tissue repair was determined by the regeneration of ovary which its follicles grew normally. The appearance of this improvement could be compared with the negative control group (T0-) which did not undergo ovarian failure and remains in normal condition and the follicles grew normally. The appearance of the tissue damage could be compared with the positive control rat (T0+) which experiencing ovarian degeneration. The group with ovary failure (T0+), was congested and showed severe hemorrhage, formation of hemosiderin granules due to erythrolysis (brownishyellow color) accompanied with fibrosis indicating that chronic inflammation has been occurred [28] (Figure-4).

This study showed that administration of 50% honey for 10 days (T1) can be used for the treatment of female rat with ovary failure model caused malnutrition. The effectiveness of honeybee product was

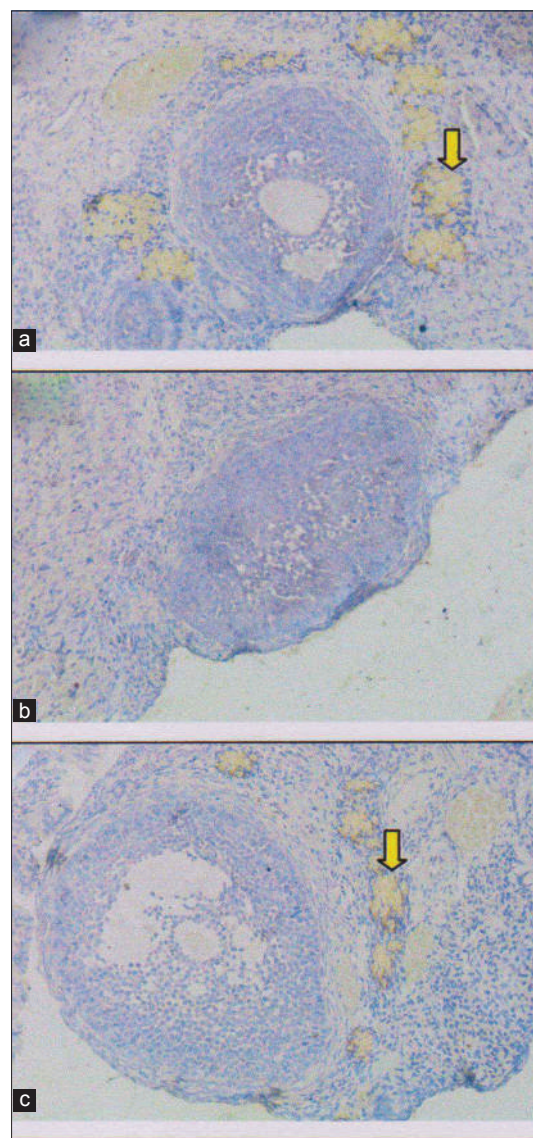
**Table-1:** Analysis of average VEGF, G-CSF and GDF-9 with immunohistochemical staining and Follicle dee Graaf count.

| Treatments   | Score $\pm$ SD          |                          |                          | Average follicle dee Graaf Count $\pm$ SD |
|--|-------------------------|--------------------------|--------------------------|---|
|  | Average VEGF expression | Average G-CSF expression | Average GDF-9 expression |   |
| Negative control group (T0-) with normal ovary without honeybee product        | $0.45\pm 0.85^a$        | $0.75\pm 0.35^a$         | $2.95\pm 0.41^c$         | $7\pm 0.85^c$                             |
| Positive control group (T0+) with ovary failure without honeybee product       | $0.25\pm 0.65^a$        | $0\pm 0^a$               | $0\pm 0^a$               | $0.75\pm 0.125^a$                         |
| T1 group, the ovary failure+50% honeybee product in drinking water for 10 days | $2.75\pm 0.55^b$        | $2.95\pm 0.43^b$         | $2\pm 0.45^b$            | $5.416\pm 0.807^b$                        |

a,b,c Values in the same column with different superscripts indicate significant difference at  $p<0.05$  (n=15). VEGF=Vascular endothelial growth factor, G-CSF=Granulocyte colony-stimulating factor, GDF-9=Growth differentiation factor-9



**Figure-2:** Homing of stem cells based on granulocyte colony-stimulating factor (G-CSF) expression in rat ovarian tissue by immunohistochemical. (a) Control negative group (T0-), with normal ovary without honeybee product: Score of G-CSF expression= $0.75 \pm 0.35^a$ , (b) control positive group (T0+), with ovary failure without honeybee product: Score of G-CSF expression= $0 \pm 0^a$ , (c) T1 group, the ovary failure +50% honeybee product in drinking water for 10 days: Score of G-CSF expression  $2.95 \pm 0.43^b$ . The different superscripts indicate significant difference at  $p < 0.05$ .



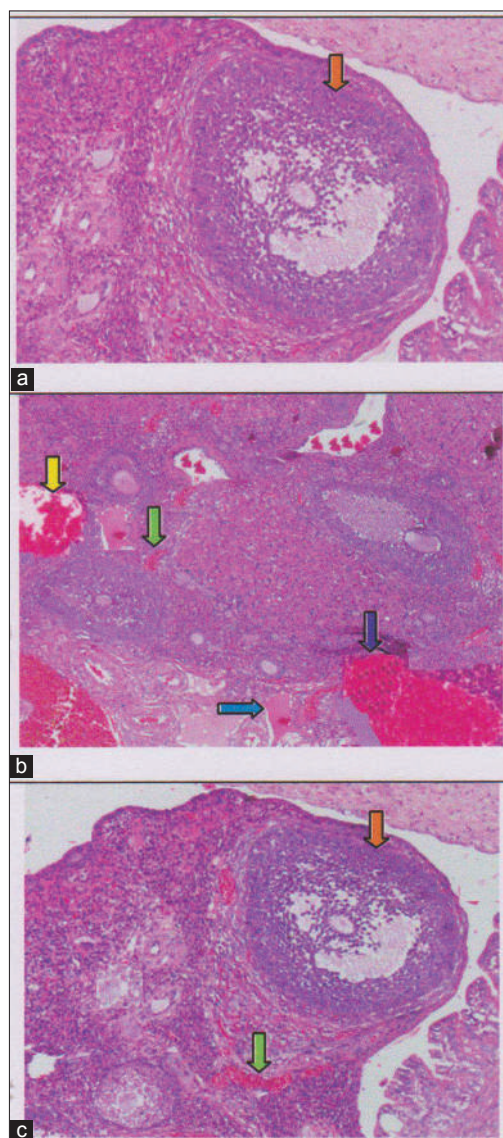
**Figure-3:** Growth differentiation factor-9 (GDF-9) expression in rat ovarian tissue shown by immunohistochemical staining on several treatments. (a) Control negative group (T0-), with normal ovary without honeybee product: Score of GDF-9 expression= $2.95 \pm 0.41^c$ , (b) control positive group (T0+), with ovary failure without honeybee product: Score of GDF-9 expression= $0 \pm 0^a$ , (c) T1 group, the ovary failure +50% honeybee product in drinking water for 10 days: Score of GDF-9 expression  $2 \pm 0.45^b$ . The different superscripts indicate significant difference at  $p < 0.05$ .

based on: (1) Homing of stem cells (based on VEGF and G-CSF expressions); (2) follicle dee Graaf count; (3) GDF-9 expressions; (4) regeneration of ovarian tissue.

Homing of stem cells (based on VEGF and G-CSF expressions) using IHC method [11,21]. Increase of follicle dee Graaf count was indicated of folliculogenesis raised [27]. Differentiation of stem cells into progenitor cells presented by the expression of GDF-9 using IHC technique in ovarian tissue [20,21,29]. Regeneration of ovarian tissue observation with routine HE staining [4].

Homing of stem cells could be performed by inducing the stem cells to mobilize toward the defect

area [13,30]. Mobilization of stem cells toward defect area for engraft in tissue, and then, the cells have a function and repair effect. Furthermore, the cells have function including secretion of soluble mediator that occurred cooperation between the host cells with mobilization cells from exogenous stem cells that have paracrine effect [21]. The process of homing can occur in several ways, one of which is enhancement of the immune response that induced by an inflammatory reaction due to injurious signals (cytokines, nuclear factor  $\kappa$ B, Wnt through  $\beta$  catenin) from the damaged tissue [25]. In this study, injury due to malnutrition signal causes an increase in cytokines so that the alteration of ovarian tissue as the primary network of the



**Figure-4:** The regeneration of ovarian tissue indicated by microscopic examination with hematoxylin and eosin (HE) staining in rat ovarian tissue in a few treatments. (a) Control negative group (T0-), with normal ovary without honeybee product was shown growing follicles (↓); (b) the group of ovary failure (T0+), congestion of ovarian (↓), and severe hemorrhage (↓), also visible hemosiderin (↓) due to blood cell lysis (brownish yellow color) with deposition of fibrin (↓) indicating that chronic congestive has been occurred, (c) the group ovary failure + 50% honeybee product (T1), ovaries begin to regenerate so it looks intact, although there is still a slight hemorrhage and congestion in some areas, but has seen growing follicles (↓).

female reproductive system could be inevitable [26]. Some cytokines that induction of stem cells for the migration and homing in the area of injury, in this study, is the VEGF and G-CSF [21].

Homing mechanism starts from HSCs out of the bone marrow through chemokine receptor (CCXR4) to locate the homing signal factor of stromal-derived factor 1 (SDF1) [4]. Furthermore, osteoblasts (cell progenitors) in cell adhesion proteins (cell adhesion proteins), among others VICAM. Furthermore, G-CSF stimulates an increase in neutrophils in the bone marrow and then increase the blood cells.

Neutrophils increases will produce protease enzymes including elastase protein damage for stem cell homing signal such as SDF1 and VICAM and then caused the stem cells out of the bone marrow. After that, quiescent stem cells out into the blood flow. The role of honey administered orally in this research was caused an increase of G-CSF [21].

Furthermore, the ovarian tissue repair based on GDF-9 expression (Table-1). GDF-9 which is progenitor cells of germline stem cells will stimulate ovarian cortex cells proliferation [31]. The T1 group (ovary failure +50% honeybee product) score of GDF-9 expression was  $2 \pm 0.43^b$ . Although the score is below the negative control group (T0-) was significantly different ( $p < 0,05$ ), with the score of which  $2.95 \pm 0.41^c$ , but the score is still above the group of ovary failure without honeybee products (T0+) which shown no expression at all ( $0 \pm 0^a$ ) (Table-1 and Figure-3). This is in accordance with the opinion that honeybee product causes the stem cells develop rapidly and differentiate into cells that are needed as a response to injury and enhance the immune response itself [32].

GDF-9 is the growth factor derived from TGF- $\beta$  family was produced by the oocyte. GDF-9 is a crucial factor in folliculogenesis and fertility [33]. Furthermore, progenitor germ cells will repair the damaged follicles and also can repair molecular communication in ovarian follicles by increasing the production of SCF and GDF-9, so as to overcome the problems of folliculogenesis due to malnutrition [21]. Homing will be activated oogenesis directly or indirectly. Directly through activation of cells inhibited and will indirectly stimulate the microenvironment (niche) of damaged cells [34].

Regeneration of ovarian tissue shown as an intact ovarian tissue with growing follicles is the third and fourth identification of the effectiveness from the use of honeybee product. In this study, the regeneration of the ovary can be observed microscopically with HE staining [31,35]. Microscopic examination showed that 50% honeybee product administration (T1), leading to the ovarian tissue repair. Improvements are identified based on the regeneration of the ovary with growing follicles. Overview of these improvements can be compared with a negative control group (T0-) which did not suffer from ovarian failure and remains in normal condition with growing follicles (Figure-4). The abnormal feature of the damaged ovary can be compared with positive control group of rat (T0+) rat with ovarian degenerative. The latter shown congested and there were severe hemorrhage and hemosiderosis (yellow-brown color) due to the hemolysis of the red blood cells with fibrin deposition, indicating that chronic congestion has been occurred (Figure-4).

## Conclusions

Treatment of 50% honeybee product for 10 days in female rat with ovary failure reveals: (1) Homing of stem cells, shown the VEGF and G-CSF markers which

are expressed in ovarian tissue with IHC; (2) enhancement of folliculogenesis was indicated by increase of follicle dee Graaf count; (3) enhancement of GDF-9 expression in ovarian tissue with IHC staining; (4) regeneration of ovarian tissue indicated by intact ovarian tissue with growing follicles; although there is still slight hemorrhage and congestion, hemosiderin granules and fibrin deposition do not exist.

### Authors' Contributions

ES: Research coordinator and flowcytometri method, drafted and revised the manuscript. TVW: Method of Immunohistochemical, Histopathology Anatomy and statistical analysis. RHP: Prepared female rats model of degenerative ovary due to malnutrition and administration of 50% honeybee product. All authors read and approved the final manuscript.

### Acknowledgments

The study was supported by funding from the Directorate General of Higher Education (DIKTI) 2016, The National Education Ministry, Republic of Indonesia.

### Competing Interests

The authors declare that they have no competing interest.

### References

1. Trounson, A. and McDonald, C. (2015) Stem cell therapies in clinical trials: Progress and challenges. *Cell Stem Cells*, 17(1): 11-22.
2. Watt, F.M. and Driskell, R.R. (2010) Review: The therapeutic potential of stem cells. *Philos. Trans. R. Soc.*, 365: 155-163.
3. Safitri, E., Utama, S., Widiyatno, T.V., Sandhika, W. and Prasetyo, R.H. (2016) Autoregeneration of mice testicle seminiferous tubules due to malnutrition based on stem cells mobilization using bee honey. *Asian Pac. J. Reprod.*, 5(1): 30-34.
4. Prasetyo, R.H. and Safitri, E. (2016) Effects of honey to mobilize endogenous stem cells in efforts intestinal and ovarian tissue regeneration in rats with protein energy malnutrition. *Asian Pac. J. Reprod.*, 5(3): 198-203.
5. Caplan, A.I. and Correa, D. (2011) The MSC: An injury drugstore. *Cell Stem Cells*, 8: 11-15.
6. Volarevic, V., Arsenijevic, N., Lukic, M.L. and Srojkovic, M. (2011) Concise review: Mesenchymal stem cells treatment of the complications of diabetes mellitus. Stem cells regenerative medicine. *Stem Cells*, 29(1): 5-10.
7. Halim, D.H., Murty, F., Sandra, A., Boediono, T., Djuwantono, B. and Setiawan, B. (2010) Stem Cell Dasar Teori dan Aplikasi Klinis. 1<sup>st</sup> ed. Penerbit Erlangga, Jakarta. p1-10.
8. De-Souza, N. (2014) Self-organizing stem cells. *Nat. Methods*, 11(31): 29-37.
9. Hu, C. and Li, L. (2015) Review: *In vitro* culture of isolated primary hepatocytes and stem cell-derived hepatocyte-like cells for liver regeneration. *Protein Cell*, 6(8): 562-574.
10. van-Agthoven, M., Groot, M.T., Verdonck, L.F., Lo-Wenberg, B., Schattenberg, A.V., Oudshoorn, M., Hagenbeek, A., Cornelissen, J.J., Uyl-de-Groot, C.A. and Willemze, R. (2012) Economic study cost analysis of HLA-identical sibling and voluntary unrelated allogeneic bone marrow and peripheral blood stem cell transplantation in adults with acute myelocytic leukaemia or acute lymphoblastic leukaemia. *Bone Marrow Transplant*, 30(4): 243-251.
11. Hozzein, W. (2016) Bee venom accelerates diabetic wound healing by suppressing the activating transcription factor-3 and inducible nitric oxid synthase-ediated oxidative stress and by recruiting bone marrow-derived endothelial progenitor cells in diabetic mice. Proceeding 13<sup>th</sup> Asian Apicultural Association Conference. April, 2016. Jeddah, Kingdom of Saudi Arabia. p134-135.
12. Aggarwal, S. and Pittenger, M.F. (2005) Human mesenchymal stem cells modulate allogeneic immune cell responses. *Blood*, 10(4): 1815-1822.
13. Najm, F., Madhavan, M., Zaremba, A., Shick, E., Karl, R.T., Factor, D.C., Miller, T.E., Nevin, Z.S., Kantor, C., Sargent, A., Quick, K.L., Schlatzer, D.M., Tang, H., Papoian, R., Brimacombe, K.R., Shen, M.N., Boxer, M.B., Jadhav, A., Robinson, A.P., Podojil, J.R., Miller, S.D., Miller, R.H. and Tesar, P.J. (2015) Drug-based modulation of endogenous stem cells promotes functional remyelination *in vivo*. *Nature*, 522(7555): 216-220.
14. Macey, M.G. (2007) Flow Cytometry, Principle and Applications. 1<sup>st</sup> ed. Human Press, Totowa, NJ. p1-31.
15. Sakri, F.M. (2012) Madu dan Khasiatnya, Suplemen Sehat Tanpa Efek Samping. 1<sup>st</sup> ed. Diandra Pustaka Indonesia, Yogyakarta. p20-25.
16. Nabiuni, M., Azimi, E., Shiravi, A. and Nazari, Z. (2012) Honey bee venom will differentiate mesenchymal stem cells in to the osteocyte. International Conference on Applied Life Sciences, (ICALS 2012), Turkey. September, 10-12. p247-250.
17. Kumar, G.L. and Rudbeck, L. (2009) Immunohistochemical Staining Methods. 5<sup>th</sup> ed. Dako North America, Carpinteria, California. p11-14.
18. Caplan, A.I. (2007) Adult mesenchymal stemcells for tissue engineering versus regenerative medicine. Mini review. *J. Cell Physiol.*, 213(2): 341-347.
19. Wendy, W.P., Priceb, E.A., Sahooa, D., Beermanc, I., Maloneyd, W.J., Rossic, D.J., Schrierb, S.L. and Weissmana, I.L. (2011) Human bone marrow hematopoietic stem cells are increased in frequency and myeloid-biased with age. *PNAS*, 108(50): 20012-20017.
20. Santoro, N.F. and Cooper, A.R. (2016) Primary Ovarian Insufficiency - Clinical Guide to Early Menopause. e-Book. 1<sup>st</sup> ed. Springer, Switzerland. p82-83.
21. Rantam, F.A., Ferdiansyah, M. and Purwati, A. (2014) Stem Cell Mesenchymal, Hematopoetik dan Model Aplikasi. 2<sup>nd</sup> ed. Airlangga University Press, Surabaya. p45-50, 145-155.
22. Eckmann, L. (2006) Animal models of inflammatory bowel disease, lesson from enteric infections. *Ann. N. Y. Acad. Sci.*, 1072: 28-38.
23. Sengupta, P. (2013) The Laboratory rat: Relating its age with human's. *Int. J. Prev. Med.*, 4(6): 624-630.
24. Harrington, A.M., Olteanu, H. and Kroft, S.H. (2012) A dissection of the CD45/side scatter "Blast Gate". *Am. J. Clin. Pathol.*, 137(5): 800-804.
25. Rantam, F.A., Ferdiansyah, M. Nasronudin and Purwati, A. (2009) Stem Cell Exploration. Methods of Isolation and Culture. 1<sup>st</sup> ed. Airlangga University Press, Surabaya.
26. Crosby, K., Simendinger, J., Grange, C., Ferrante, M., Bernier, T. and Stanen, C. (2016) Immunohistochemistry protocol for paraffin-embedded tissue section-advertisement. *Cell Signal. Technol.*, Available from: <https://www.jove.com/.../immunohistochemistry-protocol-for>.
27. Palermo, R. (2007) Differential actions of FSH and LH during folliculogenesis. *Reprod. Biomed. Online*, 5(3): 326-337.
28. Barker, N. (2014) Adult intestinal stem cells: Critical drivers of epithelial homeostasis and regeneration. *Nat. Rev. Mol. Cell Biol.*, 15(1): 19-33.
29. Vander-Flier, L.G. and Clevers, H. (2009) Stem cells, self-renewal, and differentiation in the intestinal epithelium. *Annu. Rev. Physiol.*, 71: 241-260.

30. Hermann, M., Varrier, S. and Mauro, A. (2015) Strategies to stimulate mobilization and homing of endogenous stem and progenitor cells for bone tissue repair. *Front. Bioeng. Biotechnol.*, 2(3): 79.
31. Dong, J., Albertini, D.F., Nishimori, K., Kumar, T.J., Lu, N. and Matzki, M.M. (1996) Growth differentiation factor-9 is required during early ovarian folliculogenesis. *Nature*, 383(6600): 531-535.
32. Dussaubat, C., Brunet, J.L., Higes, M., Colbourne, J.K., Lopez, J., Choi, J.H., Martin-Herna, R., Botias, C., Cousin, M., McDonnell, C., Bonnet, M., Belzunces, L.P., Moritz, R.F.A., Conte, Y.L. and Alaux, C.D. (2012) Gut pathology and responses to the microsporidium *nosemacerae* in the honey bee *Apis mellifera*. *PLoS One*, 7(5): 1-12.
33. Filho, F.L.T., Baracat, E.C., Lee, T.H., Suh, C.S., Matsui, M., Chang, J., Shimasaki, S. and Erickson, G.F. (2001) Abberant expression of growth differentiation factor-9 in oocytes of polycystic ovary syndrome. *J. Clin. Endocrinol. Metab.*, 87: 1337-1344.
34. Lee, H.J., Salesniemi, K., Niikura, Y., Niikura, T., Klein, R., Dombkowski, D.M. and Tilly, J.L. (2007) Bone marrow transplantation generates immature oocytes and rescues long-term fertility in preclinical mouse model of chemotherapy-induced premature ovarian failure. *J. Clin. Oncol.*, 25: 198-204.
35. Dan, S., Haibo, L. and Hong, L. (2014) Review: Pathogenesis and stem cell therapy for premature ovarian failure. *OA Stem Cells*, 2(1): 1-8.

\*\*\*\*\*

Author Query???

AQ1: Kindly provide the date on which you have accessed this web page



## Veterinary World: Soft Copy of November 2016 issue alongwith title

---

From: Veterinary World - Publisher (veterinaryworldpublisher@gmail.com)

Cc: editorveterinaryworld@gmail.com

Bcc: rma\_fispro@yahoo.com

Date: Saturday, December 3, 2016 at 08:02 PM GMT+7

---

Dear Authors,

I am attaching herewith PDF of November 2016 issue of Veterinary World alongwith title. If you need hard copy then you can print it from these files from any commercial printer.

### **NEWS:**

1. Veterinary World is indexed in Emerging Sources Citation Index (ESCI) - Thomson Reuters. <http://science.thomsonreuters.com/cgi-bin/jrnlst/jlresults.cgi?PC=EX&SC=ZC>
2. Veterinary World is indexed in PubMed and PubMed Central. <http://www.ncbi.nlm.nih.gov/nlmcatalog/101504872>
3. A new, prestigious journal, International Journal of One Health ([www.onehealthjournal.org](http://www.onehealthjournal.org)) was launched in early 2015 by Veterinary World.

-----  
Best Regards,

Nazir  
Editorial Assistant  
Veterinary World  
Star, Gulshan Park,  
NH-8A, Chandrapur Road,  
Wankaner, Dist. Morbi, Gujarat  
India  
[www.veterinaryworld.org](http://www.veterinaryworld.org)  
[www.onhealthjournal.org](http://www.onhealthjournal.org)



November-2016.pdf  
19.9MB



Title-November-2016.pdf  
553kB