

Dental Modification on the Skull Found During Basement Construction at Balai Pemuda Building, Indonesia

by Toetik Koesbardiati

Submission date: 11-Nov-2022 04:36PM (UTC+0800)

Submission ID: 1951005414

File name: ng_Basement_Construction_at_Balai_Pemuda_Building,_Indonesia.pdf (1.02M)

Word count: 3336

Character count: 18407

Dental modification on the skull found during basement construction at Balai Pemuda building, Indonesia *

• Yusuf Bilal Abdillah, Biandro Wisnuyana, Bayoghanta Maulana Mahardika, Suhendra Bagaskara Adhinugroho, Thoriq Firdaus, Delta Bayu Murti, Toetik Koesbardiati •

Department of Anthropology, Faculty of Social and Political Science, Universitas Airlangga, Indonesia

Address for correspondence:

Toetik Koesbardiati

Surabaya, Indonesia

E-mail: Toetik.Koesbardiati@fisip.unair.ac.id

Bull Int Assoc Paleodont. 2018;12(2):47-53.

Abstract

Two skulls have been found during basement construction of Balai Pemuda Building in the depth of 6-7 meters from the ground. Those skulls have been coded as skull 16089 and 16090. The maxillary teeth of skull 16090 was almost in complete formation and there was an evidence of dental modification similar to dental modification found in Java. To identify the pattern of dental modification, macroscopic observation is needed. Also, the comparative study will be used to find the link between the pattern of dental modifications. The result is that the pattern of dental modification on the skull 160690 is hexagon-like shaped. The "hexagon-like" pattern is very similar to what was found in Kedaton Temple and Upas Well which had diamond-like pattern.

Keywords: Dental modification; skull; Balai Pemuda; Java; Indonesia

** Author is responsible for language correctness and content.*



Introduction

Balai Pemuda is one of the historical buildings during the development of Surabaya City. This building is located near the Residence of the Governor of East Java, Indonesia. Balai Pemuda building was designed by Westmaas, a Dutch architect, and was established in 1907. During the Dutch colonization, the name of this building was *De Simpangsche Societeit* that functioned as an entertainment area for the European elites who lived in Surabaya (1). Moreover, it was a restricted area and indigeneous people were prohibited from entering the building. A sign stated '*Anjing dan Pribumi Dilarang Masuk*' (dogs and inlanders not allowed), which implies that Indigeneous people were considered equal to dogs (1, 9). Balai Pemuda used to be the basecamp of '*Pemuda Republik Indonesia*' or The Indonesian Youth during the battle for Independence. According to Widodo (13) there was a bunker inside Balai Pemuda Building, to which the Dutch detainees in camp *interniran* were brought and killed. The function of the bunker was to store the corpses. In recent time Balai Pemuda has been operated as a multifunctional building specially to hold cultural events.

In 2016 according to *detiknews.com* (15), two human skulls with code 160689 and 160690 were found in the depth of 6 – 7 meters from the ground surface in the area of Balai Pemuda building. Both human skulls were accidentally found during the construction of the underground parking area. The neurocranium of both skulls were in complete condition but some parts of splanchnocranium were also missing in both skulls. At the skull 160690 there were tooth remains in the maxilla while there was no tooth remains found in the skull 160689. On the labial tooth of skull 160690 there was a sign of dental modification. The pattern of modified tooth was similar to dental modification found in Indonesia. Dental modifications often found among population in Indonesia and Southeast Asia. The term *Pangur* is used among population in Java. In Indonesia, dental modifications exist within population in Sumatra, Java, Bali, Kalimantan, Sulawesi and Papua (8). Moreover, dental modifications were already exist since the prehistoric until the Indonesian classic (Majapahit) period of time. The patterns were pointy, T shape, those patterns of dental modifications were present among Binangun and Leran prehistoric populations that were found on the human remains at Kedaton Temple, Trowulan (5,6) (see *Table 1*). According

to Martens (8), mostly the type of dental modification in Indonesia is tooth filing that has two types; to make the teeth even and to make the teeth pointy. Tooth filing that has intention to make the teeth pointy is found among the Mentawai people (Sumatra), numerous groups in Kalimantan and Kamoro people on the south coast of Papua. Dental modifications have never been found among populations who lived during the Dutch colonization era. However, there are evidence of dental modification on the skull 160690 that was found at Balai Pemuda that was actually built during colonization era.

This indication will be the starting point to see whether there is any link between skull 160690 and another skull found in Java as well as the recent population based on the dental modification patterns. The aim of this research paper is to describe the pattern of dental modification on the skull 160690 and to contribute to knowledge about dental modifications in Indonesia.

Materials and methods

The skull 160690 found in Balai Pemuda building will be the material of this research. Due to the missing of mandible, this research will only focus on the maxillary teeth. The indication of dental modifications can be seen on the first and second incisors and also canines. This research will observe and focus on the occlusal and labial view of maxillary teeth.

This research will use descriptive analysis by observing the macroscopic features of the maxillary teeth on the skull 160690 because basically the anatomy of bones shows specific characteristics that can be recognized. Dental modification's pattern of skull 160690 will be identified using the categorization stated by Romero (10) and Koesbardiati et al (6). According to Romero (10), there are three techniques of dental modifications; 1) modifying the contour of dental crown, 2) modifying the labial side of dental crown and 3) modifying both contour and labial side of dental crown. Besides, Romero also classifies 7 types of dental modifications among Amerindian population. Meanwhile, Koesbardiati et al (6) classifies 3 types of dental modifications among Indonesian population (see *Figure 4*).

The identification of the teeth will be done anatomically with the standardisation of physical anthropology identification. In this case, the evidence of dental modifications might contain a value on explaining the relation between the

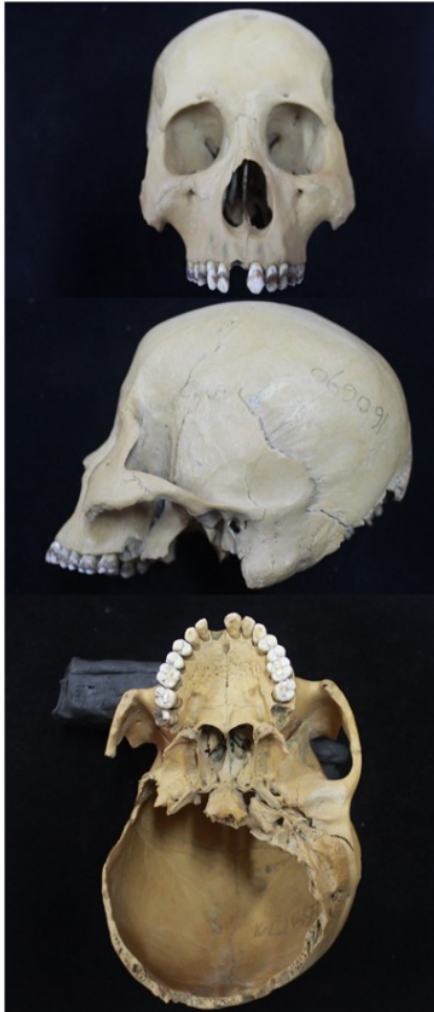

Figure 1 Skull of Balai Pemuda (160690) from frontal side, lateral and basilaris.

evidence itself with the context of the related population (11).

Moreover, a comparative study will also be used to see the link between dental modification patterns with population that practised it. The objects of the comparison are the patterns of dental modification on the remains found in several sites in. Koesbardiati *et al.* (6) examined the history of migration in Indonesia through dental modification on the numerous prehistoric populations. Koesbardiati (5) also stated that the pattern of dental modification could be used to trace social identity. Based on the methods of

previous research, the pattern of dental modification on the skull 160690 can then be matched with population that practised dental modification.

Results

Figure 1 shows facial bones and cranial vault of skull 160690. There are no basilar bone and mandible. The maxillary tooth is not in complete condition because of the disappearance of the first incisor on the right side and the third molar on the left side. The disappearance of the first incisor on the right side and the third molar on the left side are postmortem loss. It is apparently a postmortem loss because the alveolar bones are still open and did not experience a good reform (3).

Based on the dental identification, the skull 160690 tends to have more Mongoloid features, as seen in the presence of shovel-shaped incisors. According to Byers (3), the probability of appearance of shovel-shaped incisors among population in Asia and Native Americans is about 90% but less than 15% would be found among Caucasoid and Negroid. There are a number of dental traits that are related to particular populations such as carabelli's cup among Europeans and shovel-shaped incisors among Asians and Native Americans as well as Bushman canine and cusp number 7 on the lower molar among Africans (4). Besides, there are evidence of dental modifications with particular patterns on the incisors and canine.

Generally, dental modifications that are frequently found in Indonesia are tooth filing (to make the teeth pointy and even). The main reason of practising dental modifications is that it is part of the initiation rites, the symbol of beauty and the expression of mourning situation. In Kalimantan, various groups still practice dental modifications also in Bali, teenagers who are about to enter the new phase of adulthood would cut their teeth as an obedience to their religion (5).

Figures 2 and 3 show another angle of skull 160690. A clear evidence of dental modification is shown on the first left incisor. The evidence of dental modification is hexagon-like shape. This hexagon-like shape is also present on the second left incisor. On the right second incisor, the shape of the dental modification is also similar to what is on the first and second left incisor. The similarities are based on the tooth filing evidence found on the occlusal surfaces (see Figure 3). On the mesial and distal surfaces, there are also evidence of tooth filing

eventhough it is not clearly visible (see Figure 2). The pattern of tooth filing on the incisors show that tooth filling had been done on the occlusal, mesial, distal and lingual surfaces. The evidence of tooth filing done on the lingual surfaces is also shown on the right and left canines (see Figure 3).

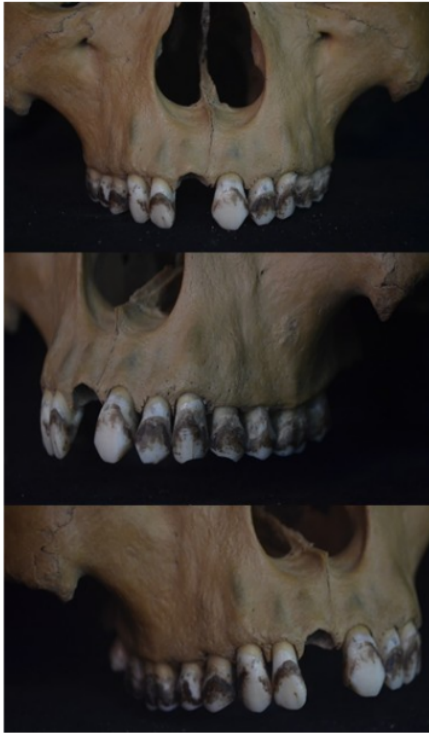

Figure 2 Dental modification of skull 160690 from frontal view.

Discussion

Dental modification is part of initiation rites that was commonly practised in the past. In particular populations, the practice still exists

where teeth are cut in such ways that the resulting shapes are considered representing their culture. This phenomenon symbolizes new phases of life such as adulthood or marriage life. These traditions could be found in many populations in Indonesia and even in Southeast Asia (7).

There are two types of dental modifications; intentional and accidental. Intentional dental modification is related to cultural practice while accidental dental modification is caused by human daily activities. Tooth that are used as a tool would result in certain grooves different from those caused by mastication process (11). As an example among Alaskan and Pacific Northwest natives, the use of labrets has shown dental wear on labial or buccal tooth surfaces. The use of pipe for smoking also leaves an accidental wear pattern (2).

Dental modification found on skull 160690 are shown in the maxillary teeth. Anthroposcopically, this pattern of dental modification is indicated as an intentional modification, because this modification caused particular teeth were cut. The shape of dental modification found on skull 160690 is similar to column C1 in the classification by Romero. Romero (10) had classified dental modifications based on their shapes. However, Romero's classification demonstrates dental modifications among Amerindian population.

Furthermore, dental modification found on skull 160690 tends to have a similar shape to one type of dental modification among Indonesian population by Koesbardiati et al (6). Skull 160690 has a similar shape of dental modification to column 3A of Koesbardiati's classification. However, the classification by Koesbardiati et al (6) only demonstrates the mandible teeth whereas dental modification on skull 160690 is in the maxillary teeth. Therefore, it is valid to state that dental modification on skull 160690 is a new shape of dental modification in regard to dental modification in the maxillary teeth of skull 160690. Thus, the findings have enriched the knowledge regarding the history of dental modifications among Indonesian population.

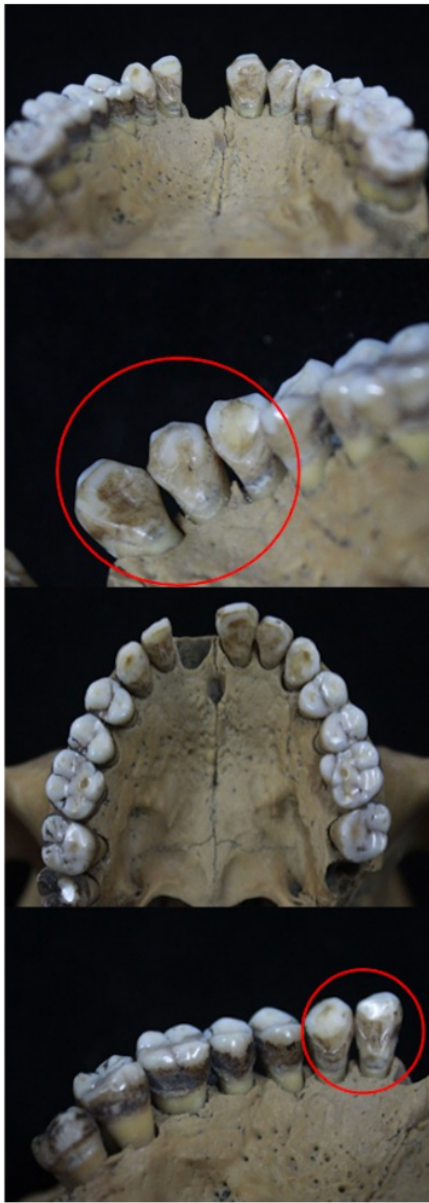

Figure 3 Dental modification of skull 160690 from lingual and occlusal view.

According to Koesbardiati et al. (6), there were various patterns of dental modifications found on the prehistoric skulls and one of those was found in Java (Binangun, Leran). Generally,

tooth filing was the most often type of dental modifications that was found. This type of dental modifications was practised on the labial, lingual and occlusal side of the teeth. Tooth filing was also type of dental modifications of Leran, Binangun (Java) and Semawang (Bali) population. Different pattern of dental modifications were also present on human remains lives during classic period of time that were found in Kedaton Temple and Upas Well with 'T' and diamond shape. Those human remains from Kedaton Temple and Upas Well that were found at the residence complex of Majapahit Kingdom (about 1500-1600) showed a tooth filing practice that formed 'T' pattern.

On the colonization era, dental modification is only found on the skull 160690 that was found during basement construction at Balai Pemuda building. The pattern of dental modification found on the skull 160690 is "hexagon-like" pattern. Based on the pattern of teeth that were modified, it indicated that the technique of filing was practised on the occlusal and lingual surface and also at the side of incisors and canines as shown in Figure 2 and 3. Observed in detail, there is a similarity of dental modifications pattern between skull 160690 (hexagon-like pattern) that lived during the colonization era and those that were found in Kedaton Temple and Upas Well (diamond pattern) that lived in the classic period of time. According to Koesbardiati (5), diamond pattern is usually found on female's incisors. The skull 160690 has been identified as a female. The identification found that the mastoid is small, browridges not prominent, high frontal and sharp supraorbital (14). The similarity is that remains from colonization and classic period of time used the technique of filing. However, there was no excessive filing on the skull 160690 whereas only particular side of teeth (occlusal, lingual, mesial and distal) were modified.

Table 1 shows that there were changes on the pattern of dental modifications from time to time. In the prehistoric time, dental modification was practised to make teeth sharp and pointy. In fact, there were some pattern of dental modifications that have the form as dog teeth (6). However, there was no evidence of sharpened teeth on the human remains from Kedaton Temple and Upas Well that lived in the classic period of time, instead the more complex pattern was found in the form diamond and 'T' pattern. The more complex pattern was also found on the skull 160690 that might lived during colonization era in the form of "hexagon-like".

Moreover, filing was also practised on the lingual side of the incisors and canines. This shows that from time to time, pattern of dental modifications changed from sharp to more complex pattern. Besides that, various groups among population in Indonesia still practise tooth sharpening such as Mentawai that is still a very traditional group. Based on that, pattern of dental modification is actually able to show the changes of cultural value of a population from traditional to the complex one. In addition, dental staining (unintentional modification, effect of betel-nut chewing) was also present on the skull 160690 on the frontal and lingual side of teeth. Dental staining has never been found among prehistoric as well as Indonesian classic population in Java. However, dental staining is still exist among the rural population especially practised by elderly women in Java (6). Usually, dental staining is valued as the symbol beauty,

so that dental staining on the skull 160690 might be form of a cultural activity (beauty).

Conclusion

The type of dental modification on the skull 160690 is tooth filing. The pattern of tooth filing is hexagon-like shape on the incisors. There is also evidence of dental modification on the lingual surfaces of incisors and canines. This pattern of dental modifications is similar to the pattern of dental modifications on the skull found in Kedaton Temple. Based on the classification, dental modification found in skull 160690 is also similar to dental modification found in Semawang. However, dental modification from Semawang was only found in the mandible teeth whereas dental modification on skull 160690 seen in the maxillary teeth. This might indicate that there is a different kind of cultural behavior based on which part of teeth (maxillary or

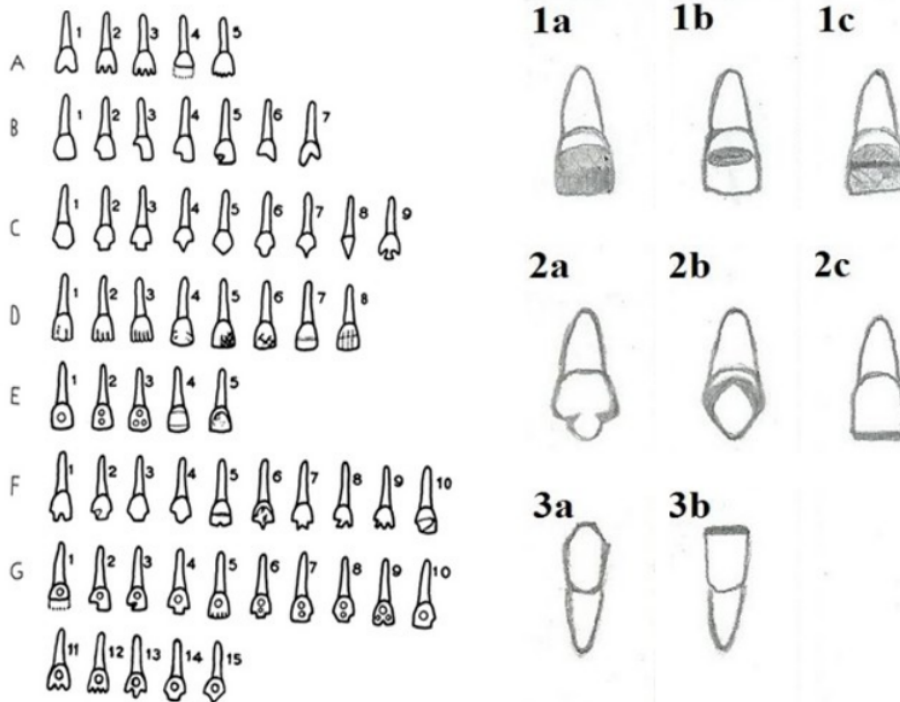


Figure 4 Classification of Romero (12), left; classification of Koesbardiati et al (6), right.

mandible) used as the object of dental modification.

It is already known that Balai Pemuda was a building built during colonization period, therefore the skull 160690 may have lived during that period of time. So that, it is possible to say that dental modifications were still practised until the colonization era. However, a further research and dating is needed to understand more about the context of skull 160690.

No	Periods	Dental	Type of modification
1	Prehistoric (3000 BP – 2000 BP) (6)	Upper left and right incisors and canine	Filing dog-teeth-like (labial surface), pointed shape.
2	Classic (13 th – 15 th Century) (5)	Upper left lateral incisors Upper lateral incisors	Clearly show Pattern of "T". filling (labial surface and upper labial surface) show diamond-like pattern.
3	Colonial (19 th Century)	Upper left and right lateral incisors and canine	Filing: Occlusal surface, lingual, mesial and distal (Incisors) show "hexagon-like" pattern. Lingual surface (Canine). All parts of teeth: Dental staining.

Table 1. Dental modifications found in Java.

References

- Adysti, Nurina Listya., Antarksa., Noviani Suryasari. Pelestarian Gedung Merah Putih Balai Pemuda Surabaya. *Arsitektur e-Journal*. 2011; 4(2): 71-84.
- Barnes, Danielle M. Dental Modification: An Anthropological Perspective. University of Tennessee Honors Thesis Project. http://trace.tennessee.edu/utk_chanhonoproj/1345. 2010.
- Byers, Steven. Introduction to Forensic Anthropology (Third Edition). Boston: Pearson Prentice Hall. 2010
- Edgar, Heather J H., and Anna L.M. Rautman. Forensic Odontology. In *A Companion to Dental Anthropology*. Joel D. Irish and G. Richard Scott (eds). Chichester: Wiley Blackwell. 2016.
- Koesbardiati, Toetik. Social Identity: an Interpretation of Dental Modification Practices on Indonesian Historical Human Remains. *Bull Int Assoc Paleodont*. 2016;10(2):60-65.
- Koesbardiati, Toetik., Delta Bayu Murti., Rusyad Adi Suriyanto. Cultural Dental Modification in Preshistoric Population in Indonesia. *Bull Int Assoc Paleodont*. 2015;9(2):52-60.
- Koesbardiati, Toetik., & Rusyad Adi Suriyanto. Dental Modifications: A Perspective of Indonesia Chronology and The Current Applications. *Dental Journal Majalah Kedokteran Gigi*. 2010;43(2):81-90.
- Martens, Michael. Tooth Transfiguration in Indonesia. In *Sulang Language Data and Working Papers: Topic in Lexicography Vol 17*. 2013
- Perkasa, Adrian. The Two Faces of Janus: Revolution and Violence in Surabaya 1945-1949. *Mozaik Humaniora*. 2015; 15(2): 131-141
- Romero, Javier. 1970. Dental Mutilation, Trephination and, Cranial Deformation. In *Handbook of Middle American Indians, Vol 9: physical anthropology*. Thomas Dale Stewart (ed). Austin: University of Texas Press.
- Schiffer, M.B. Behavioral Archaeology: Principle and Practice. London: Equinox Publishing Ltd. 2010.
- Scott, G. Richard and Christy G. Turner. Dental Anthropology. *Annual Review of Anthropology*. 1988;17:99-126.
- Soedarso., Muchammad Nurif., Windiani. *Dinamika Multikultural Masyarakat Kota Surabaya*. *Jurnal Sosial Humaniora*. 2013; 6(1): 62-75.
- Suhendra., Bagaskara Adhinugroho., Thoriq Firdaus., Toetik Koesbardiati., et al. The Positive Identification of Skulls Specimen During The Construction of Balai Pemuda's Basement (Unpublished). 2018.
- Effendi, Zainal, [website]. <https://detik.com/news/berita-jawa-timur/d-3361086/dua-tengkorak-manusia-ditemukan-di-proyek-basement-balai-pemuda..2016>.



Dental Modification on the Skull Found During Basement Construction at Balai Pemuda Building, Indonesia

ORIGINALITY REPORT

1 %

SIMILARITY INDEX

0%

INTERNET SOURCES

1%

PUBLICATIONS

0%

STUDENT PAPERS

PRIMARY SOURCES

- 1 Wood, Bernard. "The Human Fossil Record. *Volume Two: Craniodental Morphology of Genus Homo (Africa and Asia)* . By Jeffrey Schwartz and Ian Tattersall . Hoboken (New Jersey): Wiley-Liss. \$150.00. xi + 603 p; ill.; no index. ISBN: 0471319287. 2003.", *The Quarterly Review of Biology*, 2005. 1 %
- Publication

- 2 icollate2017.uny.ac.id <1 %
- Internet Source

Exclude quotes Off

Exclude matches Off

Exclude bibliography On