

# The Role of MMP-9 and VEGF in the Invasion State of Bladder Urothelial Carcinoma

*by* Novalia Chumaladewi Guntarno

---

**Submission date:** 21-Nov-2022 05:28PM (UTC+0800)

**Submission ID:** 1960194916

**File name:** d\_VEGF\_in\_the\_Invasion\_State\_of\_Bladder\_Urothelial\_Carcinoma.pdf (822.96K)

**Word count:** 3986

**Character count:** 20831

## RESEARCH ARTICLE

## The Role of MMP-9 and VEGF in the Invasion State of Bladder Urothelial Carcinoma

Novalia Chumaladewi Guntarno<sup>1,2,3</sup>, Anny Setijo Rahaju<sup>1,2,3\*</sup>, Nila Kurniasari<sup>1,2,3</sup>

<sup>1</sup>Department of Anatomical Pathology, Faculty of Medicine, Universitas Airlangga, Jl. Mayjen Prof. Dr. Moestopo No.47, Surabaya, Indonesia

<sup>2</sup>Universitas Airlangga Hospital, Jl. Dharmasada Permai No.116, Surabaya, Indonesia

<sup>3</sup>Dr. Soetomo General Academic Hospital, Jl. Mayjen Prof. Dr. Moestopo No.6-8, Surabaya, Indonesia

\*Corresponding author. E-mail: anny\_sr@fk.unair.ac.id

Received date: Jul 22, 2020; Revised date: Dec 31, 2020; Accepted date: Jan 4, 2021

### Abstract

**BACKGROUND:** Bladder cancer is the tenth-most common cancer in worldwide and the majority are urothelial carcinomas. The depth of invasion plays important role in the prognostic and therapeutic factor in urothelial carcinomas. The expression of vascular endothelial growth factor (VEGF) and matrix metalloproteinase-9 (MMP-9) may associated with the progression of bladder carcinoma, such as depth of invasion. In this study, the correlation between these two markers in urothelial bladder carcinoma invasion will be analyzed.

**METHODS:** An analytical observational research with cross-sectional were conducted on 54 formalin fixed paraffin-embedded tissue from radical cystectomy (RC) which were diagnosed as bladder urothelial carcinoma at the Anatomical Pathology Laboratory of Dr. Soetomo Academic Hospital, Surabaya and divided based on the T stage were immunostained using VEGF and MMP-9 monoclonal antibodies. The difference of VEGF and MMP-

9 expression in T stage of bladder urothelial carcinoma were analyzed using Kruskal-Wallis and Anova test, the correlation between VEGF and MMP-9 expression in various T stage of bladder urothelial carcinoma were analyzed using Spearman test.

**RESULTS:** This study showed no significant difference of VEGF expression among T stage of bladder urothelial carcinoma ( $p>0.05$ ) but there was significant difference of MMP-9 expression in T stage of bladder urothelial carcinoma ( $p=0.043$ ). There was a correlation between VEGF and MMP-9 in various T stage of bladder urothelial carcinoma ( $rs=0.50, p=0.001$ ).

**CONCLUSION:** The significant correlation of VEGF and MMP-9 expression in bladder urothelial carcinoma may prove the synergistically role of both proteins in tumor invasion by MMP-9 degradation extracellular matrix.

**KEYWORDS:** urothelial carcinoma, VEGF, MMP-9, T stage

*Indones Biomed J. 2021; 13(1): 61-7*

### Introduction

Bladder carcinoma is the ninth malignancy worldwide and seventh of the most common malignancy in men. Based on Global Cancer Statistic (GLOBOCAN) 2018, bladder carcinoma was the tenth malignancy with 549.000 cases and 200.000 cases of mortality rate.(1)

Urothelial cell carcinoma is the most common histopathology subtype in bladder carcinoma, accounting for about 90% of all bladder malignancies.(2) Determination of the degree of invasive tumor in bladder carcinoma is very important both for prognosis and the determination of therapy. T1 stage is stage of bladder carcinoma that has not yet penetrated to the muscular layer has a recurrence rate of 50 to 70% with good prognosis and the management

of the treatment is provided by cystoscopy resection and intravesicular therapy radical cystectomy (RC) can be performed in T1 stage with high risk condition such as tumor size >3 cm and multiple tumors. While T2, T3, T4 stage are stage of bladder carcinoma that has penetrated the muscular layer has a worse prognosis with combination therapy between cystectomy and cisplatin-based combination chemotherapy.(3-6) Therefore, it is important to analyze the factors that play a role in bladder carcinoma invasion.

One of the most important factors in tumor growth and invasion is angiogenesis. Rapid tumor growth increases the need for oxygen and nutrients for metabolic processes. Tumor cells require the formation of new blood vessels to deliver oxygen and nutrients to tumor cells that are very proliferative.(7) Vascular endothelial growth factor (VEGF) is one of the angiogenic factor that important to stimulates angiogenesis and tumor growth family of growth factors and the VEGF receptor forms a tumor angiogenesis signal pathway. The significance of the prognosis of VEGF expression has been studied in various types of cancer and several studies state that VEGF has an important role in bladder cancer progression and invasion.(8-10)

The basis of angiogenesis is the migration of endothelial cells into the surrounding loose tissue. Matrix metalloproteinases (MMPs) has complex roles including degradation of extracellular matrix, release of proangiogenic substances such as VEGF play a role in facilitating tumor angiogenesis.(11,12) Matrix metalloproteinase-9 (MMP-9) is the type of MMP that is involves in the process of degradation of basement membrane and the formation of new blood vessels are characteristic of the progression in bladder carcinoma.(12) Degradation of basement membrane is the key of tumor invasion which is supported by angiogenesis to support the oxygen and nutrient needs. Therefore, this study was conducted to analyze the role and the relationship between VEGF and MMP-9 in invasion (T stage) bladder urothelial carcinoma.

## Methods

### Research Design and Sample

This study had been approved by the Health Research Ethic Committee of Dr. Soetomo Academic Hospital, Surabaya (Ethical Clearance No. 1851/KEPK/II/2020). An analytical observational research with cross-sectional approach were conducted on 54 formalin fixed paraffin-embedded tissue from RC which were diagnosed as bladder urothelial

carcinoma at the Anatomical Pathology Laboratory of Dr. Soetomo Academic Hospital, Surabaya during January 2010 to August 2019. The samples of bladder urothelial carcinoma were divided based on the T stage (T1, T2, T3, T4) (Table 1).

### Immunohistochemistry Staining

The paraffin blocks of samples were cut into 4 µm sections with Leica microtome into slides, deparaffinized three times with xylol for 5 minutes each, and rehydrated through graded alcohol (96%, 96%, 90%, 80%) for 2 minutes each. To reduce nonspecific staining due to peroxidase block, the slides were incubated in hydrogen peroxide for 10-15 minutes. Antigen retrieval was achieved by microwaves treatment in sodium citrate buffer (pH 6.0) for 45 minutes at 95°C, then applied background sniper, Biogear - Excell Block, (GitHub, San Francisco, CA, USA). The slides then were incubated with monoclonal antibodies for VEGF (C-1 - sc 7269 dilution 1:200; Santa Cruz Biotechnology, Dallas, TX, USA) and MMP-9 (7-11C - sc 13520 dilution 1:200; Santa Cruz Biotechnology) overnight, and washed in phosphates buffer saline. Secondary antibody, Biogear Universal HRP Excell Stain System – Biogear, BDK-HES125 (GitHub) then applied for 15-20 minutes at room temperature followed 3,3'-diaminobenzidine (DAB) chromogen for 5-15 minutes. Slides then were counterstained with Meyer's hematoxylin and dehydrated with 95% alcohol.

### Evaluation of Immunohistochemical Expression

The expression of VEGF and MMP-9 was then evaluated using light microscopes Olympus CX41RF at 400x (Olympus, Tokyo, Japan) magnification and documented using Olympus DP2-BSW (Olympus). The results of VEGF expression were interpreted according to the percentage and intensity of immunoreactive product in the cytoplasm of tumor cells. The percentage of tumor cell positively stained was determine by counting the tumor cell that had the highest immunoreactivity. Less than 10% was scored 0, more than 10% to 25% indicated score 1, more than 25% but less than 50% was scored 2 and more than 50% of staining was scored 3. The staining intensity were scored as 1,2,3 for weak, moderate and strong. Then the extend and intensity score were summed as total score, 0-2, 3-4, 5-6 were considered as negative, positive and strong positive.(13)

The results of MMP-9 expression were interpreted according to the percentage of immunoreactive product in the cytoplasm of tumor cells. When the tumor cells

**Table 1. T Stages in urothelial bladder carcinoma.(3)**

T Stages	
T1	Tumor invades the submucosa or lamina propria
T2	Tumor invades muscle tissue
T3	Tumor extends beyond muscle into the perivesical fat
T4	Tumor invades the prostate, vagina, uterus, or bowel, or is fixed to abdominal wall, pelvic wall, or other organs

showed less than 5% indicated negative, more than 5% to 25% indicated low levels, more than 25% but less than 50% intermediate and more than 50 high levels of staining indicated high.(14)

### Statistical Analysis

All statistical analyses were calculated using SPSS version 25.0 (IBM Corporation, Armonk, NY, USA). The comparison of VEGF was tested using Mann-Whitney U test and MMP-9 using Anova test. The correlation between VEGF and MMP-9 was analyzed using Spearman test with  $p < 0.05$ .

## Results

The average age of the sample in this study was 60.59 years. The youngest age at diagnosis was 34 years while the oldest was 81 years old. The distribution of samples based on age groups was divided into 5 groups with a span of 10 years. The highest number of samples was found in the age group 41-50 years with 13 samples (32.5%), followed by the 51-60 years' age group with 10 samples (25%). The gender distribution was 50 samples (92.59%) from male patients and 4 samples from female patients. In this study, it was found that the most cases were stage T4 with 16 cases (29.62%), followed by stages T2 and T3 with the same number of 14 cases (25.92%) and stage T1 as many as 10 cases (18.51%) (Table 2).

### VEGF Expression in Bladder Urothelial Carcinoma

Positive immunoreaction was observed as a brown color staining localized in the cell cytoplasm. There was no significance difference of VEGF expression was found in various T stage of bladder urothelial carcinoma  $p = 0.322$  ( $p > 0.05$ ) (Table 3). This study found that VEGF expression in the T1 stage samples had a final score that was evenly distributed from negative to strong positive expressions. Half of the samples in stages T2 and T3 were expressed

with score 3 with VEGF and most of the samples in stages T4 were expressed with score 5-6 (Figure 1).

### MMP-9 Expression in Bladder Urothelial Carcinoma

Positive immunoreaction was observed as a brown color staining localized in the cell cytoplasm. There was a significance difference of MMP-9 expression in various T stage of bladder urothelial carcinoma  $p = 0.043$  ( $p < 0.05$ ) (Table 4). MMP-9 expression at T1 stage in this study were expressed score 3 in 50% cases (Figure 2). The data distribution of the MMP-9 expression group was normal, so it was followed by LSD test to find out which group had the most significant difference. The LSD test showed that the T3 and T4 groups were the groups that had the most significant difference with  $p = 0.008$  and the T2 and T4 groups with  $p = 0.04$ . The other groups did not have a significant difference (Table 5).

**Table 2. The clinicopathological characteristic of subjects.**

Characteristics	n (%)
Age (years)*	
≤ 40	2 (3.7)
41-50	6 (11.1)
51-60	14 (25.9)
61-70	26 (48.1)
71-80	5 (9.3)
≥ 81	1 (1.9)
Gender	
Male	50 (92.6)
Female	4 (7.4)
Tumor grade	
Low	7 (13.0)
High	47 (87.0)
T stage	
T1	10 (18.5)
T2	14 (25.9)
T3	14 (25.9)
T4	16 (29.6)

**Table 3. VEGF expression in various T stage bladder urothelial carcinoma.**

T Stage		T1	T2	T3	T4
Percentage	0-10% (Score 0)	2 (20%)	2 (14.3%)	0	1 (6.2%)
	10 – 25% (Score 1)	2 (20%)	0	5 (35.7%)	1 (6.2%)
	25-50% (Score 2)	2 (20%)	1 (7.2%)	4 (28.6%)	3 (18.7%)
	≥ 50% (Score 3)	6 (60%)	11 (78.5%)	5 (35.7%)	11 (6.9%)
Intensity	Weak (Score 1)	5 (50%)	6 (42.8%)	6 (42.8%)	7 (43.7%)
	Moderate (Score 2)	4 (40%)	5 (35.7%)	5 (35.7%)	7 (43.7%)
	Strong (Score 3)	1 (10%)	3 (21.4%)	3 (21.4%)	2 (12.4%)
Total Score	Negative (Score 0-2)	3 (30%)	2 (14.2%)	4 (28.5%)	2 (12.4%)
	Positive (Score 3-4)	3 (30%)	5 (35.7%)	3 (21.4%)	7 (43.7%)
	Strong positive (Score 5-6)	4 (40%)	7 (50%)	7 (50%)	7 (43.7%)
<i>p</i> -value* (Total Score)		0.322			

\*Tested with Kruskal-Wallis.

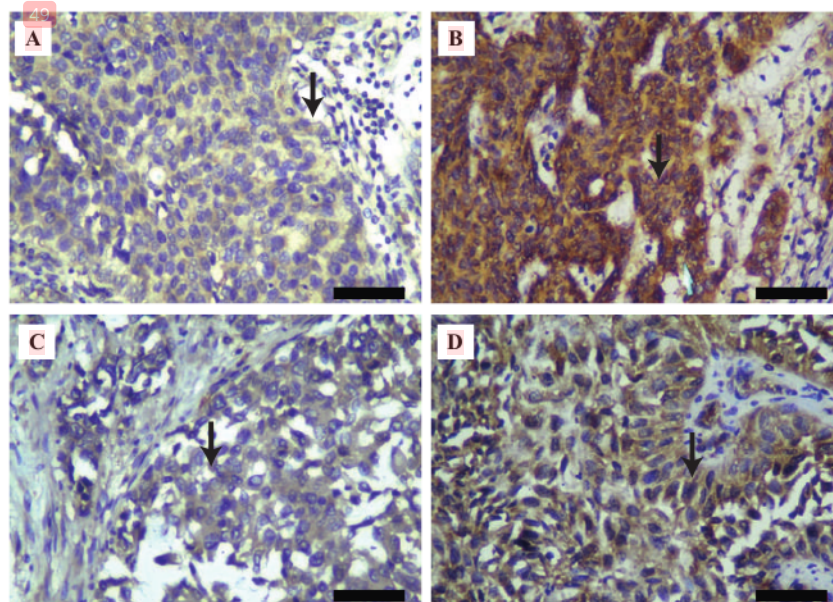
### Correlation between VEGF and MMP-9 in Bladder Urothelial Carcinoma

The correlation between VEGF and MMP-9 expression in bladder urothelial carcinoma was significant positive correlation  $r_s=0.50$ ;  $p=0.001$  ( $p<0.05$ ).

## Discussion

This study found that VEGF expression in the 10 samples of T1 stage had final scores that were distributed from negative

to strongly positive expressions. Half of the samples in stage T2 (7 samples) and T3 (7 samples) were strongly positive and most of the samples in stages T4 were strongly positive. Factors that can affect VEGF expression with T stage are VEGF receptors (VEGFR-1 and VEGFR-2), which are correlated with tumor invasion in bladder urothelial carcinoma ( $p=0.01$ ).<sup>(8)</sup> The most important interaction between VEGFR-2 and VEGF is the process of mitogenic, chemotactic, angiogenic and the increased permeability effects of VEGF. VEGF and VEGFR-2 bonds can trigger different signaling pathways, for example activation of the



**Figure 1. Immunohistochemical expression of VEGF in various T stage of bladder urothelial carcinoma.** A: T1 stage, 90% tumor cells were stained with weak intensity; B: T2 Stage, 65% tumor cell were stained with strong intensity; C: T3 stage, 70% tumor cells were stained with weak intensity; D: T4 stage, 95% tumor cells were stained with moderate intensity. Black bar: 5  $\mu$ m.

**Table 4. MMP-9 expression in various T stage bladder urothelial carcinoma.**

T Stage	T1	T2	T3	T4
Percentage	1 (10%)	0	0	0
0 -5% (Score 0)	1 (10%)	5 (35.7%)	1 (7.2%)	3 (6.2%)
5 - 25% (Score 1)	3 (30%)	2 (14.2%)	5 (35.7%)	2 (12.5%)
25-50% (Score 2)	5 (50%)	7 (50%)	8 (57.1%)	11 (6.9%)
> 50% (Score 3)	51.8	62.3	69.2	41.7
Average				
p-value*	0.043			

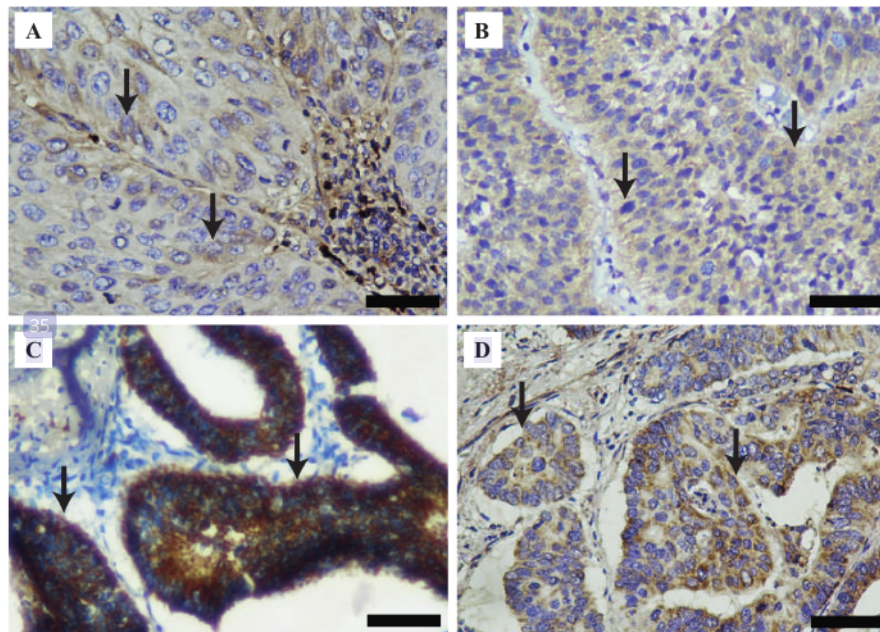
\*Tested with Anova.

46 phospholipase C gamma (PLC $\gamma$ ) – protein kinase C (PKC) – Raf kinase – MEK – mitogen-activated protein kinase (MAPK) pathway and the phosphatidylinositol 3' – kinase (PI3K) pathway that triggers changes in actin cytoskeleton and induces cell migration.(8)

27 VEGF expressions in this study varied at each T stage. There are several factors that can regulate VEGF expression, including hypoxia, free radicals, pH imbalance, and nutrient deficiencies.(15) To compensate the hypoxia and nutrient deficiencies and to escape from tumor necrosis, tumor cells express hypoxia-inducible factors (HIF), which will activate the transcription of over 40 genes, including VEGF. (9) Suitable with the previous study, there was a positive correlation between HIF-1 $\alpha$  and VEGF immunoreactivities

( $p < 0.001$ ) in urothelial carcinoma.(16) VEGF and VEGF receptor transcription are directly activated by HIF-1 $\alpha$  by binding hypoxia response element (HRE) and plays an important role during normal growth and tumor formation. (17) In addition of hypoxia, conditions of pH imbalance and high temperature can also affect the level of VEGF transcription and VEGF expression through observation of nitric oxide (NO) donor sodium nitroprusside (SNP) and hydrogen peroxide.(15) These factors may have more direct role in VEGF expression than their relation to T stage, and these factors have not been analyzed in this study.

The different expression of MMP-9 on each T stage indicate a difference in expression of MMP-9 on the depth of tumor cell invasion. This is in accordance with the previous



**Figure 2. Immunohistochemical expression of MMP-9 expression in various T stage of bladder urothelial carcinoma.** A: T1 stage, 70% tumor cells were stained; B: T2 stage, 90% tumor cells were stained; C: T3 stage, 100% tumor cells were stained; D: T4 stage, 35% tumor cells were stained. Black bar: 5  $\mu$ m.

**Table 5. Comparison of MMP-9 expression between two group.**

T Stage	p -value
T1-T2	0.353
T1-T3	0.127
T1-T4	0.364
T2-T3	0.504
T2-T4	0.044
T3-T4	0.008

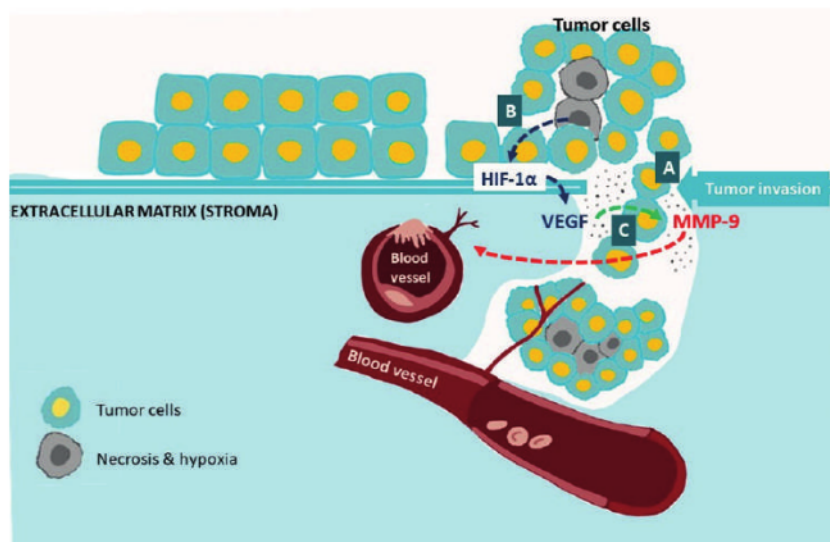
research which conducted research on MMP-9 expression in the progression of urothelial bladder carcinoma and obtained an increase in MMP-9 expression is in line with increased tumor invasion.(18,19) Likewise, in the prior study which compared normal bladder tissue and bladder urothelial carcinoma, they found an increase in MMP-9 expression (up to 50%) in bladder urothelial carcinoma compared with normal bladder tissue.(20)

MMP-9 is involved in several biological processes as a proteolytic that degrades extracellular matrix, separator between cells, separator of interactions between cells and extracellular matrix, division of proteins on cell surfaces, division of proteins in the extracellular environment.(21) MMP-9 which is secreted by tumor cells is related to the

ability to metastasize, this is because MMP-9 can degrade collagen types IV, V, VII and X. Type IV collagen is the main collagen supporting the basal membrane and is especially abundant in vascular endothelium in basal membrane, and acts as a barrier to invasion and metastasis. The high expression of MMP-9 causes degradation of extracellular matrix making it easier for tumor cells to invade.(22,23)

The correlation between VEGF expression and MMP-9 expression in T-stage urothelial bladder carcinoma showed a significant result where the higher VEGF expression, the higher the MMP-9 expression in invasion bladder urothelial carcinoma (Figure 3). The results of this study are similar with previous study which stated a correlation between VEGF and MMP-9 in retinoblastoma tumor invasion.(24) The basis of angiogenesis is the migration of endothelial cells into the surrounding loose tissue. MMP-9 has complex roles including remodelling of extracellular matrix, and is activated by angiogenic factors, one of which is VEGF. Conversely, MMP-9 also promotes endothelial cell migration and triggers angiogenic switches (a balance effect between proangiogenic and anti-angiogenic) by releasing VEGF during the carcinogenesis process.(11,25)

The limitation of this study was the small number of samples which originating from only one hospital thus making us use total sampling procedure.



**Figure 3. VEGF and MMP-9 expression.** A: The invasion process begins with the destruction of the basement membrane and extracellular matrix by the proteolytic enzyme MMP9 secreted by tumor cells; B: The uncontrolled proliferation of tumor cells results a lack of nutrient and oxygen supply to tumor cells. To prevent necrosis, tumor cells express HIF 1α. HIF 1α then triggers the release of VEGF which is the main mediator of tumor angiogenesis; C: At the same time, MMP9 secretion is also triggered by VEGF to support the angiogenesis process by degrading the extracellular matrix around blood vessels.

## Conclusion

MMP-9 expression is different on each depth of invasion in bladder urothelial carcinoma. The significant correlation of VEGF and MMP-9 expression in bladder urothelial carcinoma may prove the synergistically role of both proteins in tumor invasion by MMP-9 degradation extracellular matrix.

## Acknowledgements

Thanks to Dr. Budi Utomo, dr., M.Kes. who helped us in the statistical analysis also to all the lecturers in Department of Anatomical Pathology, Faculty of Medicine, Universitas Airlangga for the guidance in finishing this study.

## Authors Contribution

All authors were involved in concepting and planning the research, performed the data acquisition/collection, calculated the experimental data and performed the analysis, drafted the manuscript and designed the figures, interpreted the results and took parts in giving critical revision of the manuscript.

## References

- Bray F, Ferlay J, Soerjomataram I, Siegel R, Torre L, Jemal A. Global cancer statistics 2018: GLOBOCAN estimates of incidence and mortality worldwide for 36 cancers in 185 countries. *Ca Cancer J Clin.* 2018; 68: 394-424.
- Giridhar KV, Kohli M. Management of muscle-invasive urothelial cancer and the emerging role of immunotherapy in advanced urothelial cancer. *Mayo Clin Proc.* 2017; 92: 1564-82.
- Tanaka MF, Sonpavde G. Diagnosis and management of urothelial carcinoma of the bladder diagnosis and management of urothelial carcinoma of the bladder. *J Postgrad Med.* 2015; 123: 43-55.
- Zhao M, He XL, Teng XD. Understanding the molecular pathogenesis and prognostics of bladder cancer : an overview. *Chin J Cancer Res.* 2016; 28: 92-8.
- Inamura K. Bladder cancer: new insights into its molecular pathology. *Cancers.* 2018; 10: 100. doi: 10.3390/cancers10040100.
- Magers MJ, Lopez-Beltran A, Montironi R, Williamson SR, Kaimakliotis HZ, Cheng L. Staging of bladder cancer. *Histopathology.* 2019; 74: 112-34.
- Magalhaes A, Dias S. Angiogenesis—vessels recruitment by tumor cells. In: Fior R, Zilhão R, editors. *Molecular and Cell Biology of Cancer.* Freiburg: Springer Nature; 2019. p.141-57.
- Kopparapu PK, Boorjian SA, Robinson BD, Downes M, Gudas LJ, Mongan NP, *et al.* Expression of VEGF and its receptors VEGFR1/VEGFR2 is associated with invasiveness of bladder cancer. *Anticancer Res.* 2013; 33: 2381-90.
- Bronsart P, Werner M. *Pathology of Tumor Angiogenesis.* Freiburg: Springer Nature; 2018.
- Fus LP, Gornicka B. Role of angiogenesis in urothelial bladder carcinoma. *Cent European J Urol.* 2016; 69: 258-63.
- Amalinei C, Caruntu ID, Giusca SE, Balan RA. Matrix metalloproteinases involvement in pathologic conditions. *Rom J Morphol Embryol.* 2010; 51: 215-28.
- Gunes M, Kemik AS, Pirincci N, Gecit I, Taken K, Yuksel MB, *et al.* Preoperative levels of matrix metalloproteinase-7 and-9 and tissue inhibitor of matrix metalloproteinase-1 relation to pathologic parameters in bladder carcinoma patients. *Asian Pac J Cancer Prev.* 2013; 14: 873-6.
- Al-Bassam SSA, Kadhim HS, Khashman BM. Possible association of vascular endothelial growth factor with grades of breast cancer. *Int J Res Pharm Chem.* 2014; 4: 291-3.
- Ali HH, Ibraheem MH, Alhindawi MM. Immunohistochemical expression of matrix metalloproteinase-9 in urothelial carcinoma of urinary bladder. *Kasr AlAiny Med J.* 2018; 24: 109-14.
- Wang F, Xu P, Xie KC, Chen XF, Li CY, Huang Q. Effects of tumor microenvironmental factors on VEGF expression. *Biomed Rep.* 2013; 1: 539-44.
- Deniz H, Karakök M, Yagcı F, Güldür ME. Evaluation of relationship between HIF-1 $\alpha$  immunoreactivity and stage, grade, angiogenic profile and proliferative index in bladder urothelial carcinomas. *Int Urol Nephrol.* 2010; 42: 103-7.
- Yang Y, Sun M, Wang L, Jiao B. HIFs, angiogenesis, and cancer. *J Cell Biochem.* 2013; 114: 967-74.
- Reis ST, Leite KRM, Piovesan LF, Pontes-Junior J, Viana NI, Abe DK, *et al.* Increased expression of MMP-9 and IL-8 are correlated with poor prognosis of bladder cancer. *BMC Urol.* 2012; 12: 18. doi: 10.1186/1471-2490-12-18.
- Tang Z, Tang C, Juanfen MO, Ying X. Role of MMPs expression in the invasion and metastasis of bladder cancer. *Chin J Primary Med Pharm.* 2018; 25: 156-60.
- Wu GJ, Bao JS, Yue ZJ, Zeng FC, Cen S, Tang ZY, *et al.* Elevated expression of matrix metalloproteinase-9 is associated with bladder cancer pathogenesis. *J Cancer Res Ther.* 2018; 14: 54-9.
- Huang H. Matrix metalloproteinase-9 (MMP-9) as a cancer biomarker and MMP-9 biosensors: recent advances. *Sensors.* 2018; 18: 3249. doi: 10.3390/s18103249.
- Vandooren J, Van den Steen PE, Opendakker G. Biochemistry and molecular biology of gelatinase B or matrix metalloproteinase-9 (MMP-9): the next decade. *Crit Rev Biochem Mol Biol.* 2013; 48: 222-72.
- Conlon GA, Murray GI. Recent advances in understanding the roles of matrix metalloproteinases in tumour invasion and metastasis. *J Pathol.* 2019; 247: 629-40.
- Wijayanti E, Fauzyah D. Correlation between VEGF and MMP-9 expression in retinoblastoma extraocular invasion. *Majalah Patologi Indonesia.* 2017; 26: 44-9.
- Quintero-Fabián S, Arreola R, Becerril-Villanueva E, Torres-Romero JC, Arana-Argáez VE, Lara-Riegos J, *et al.* Role of matrix metalloproteinases in angiogenesis and cancer. *Front Oncol.* 2019; 9: 1370. doi: 10.3389/fonc.2019.01370.



# The Role of MMP-9 and VEGF in the Invasion State of Bladder Urothelial Carcinoma

## ORIGINALITY REPORT

17%

SIMILARITY INDEX

10%

INTERNET SOURCES

14%

PUBLICATIONS

0%

STUDENT PAPERS

## PRIMARY SOURCES

- 1 Khalil Zaman, Robert Driscoll, Diane Hahn, Patricia Werffeli et al. "Monitoring multiple angiogenesis-related molecules in the blood of cancer patients shows a correlation between VEGF-A and MMP-9 levels before treatment and divergent changes after surgical vs. conservative therapy", *International Journal of Cancer*, 2006  
Publication 1%
- 2 [biotm.cis.udel.edu](http://biotm.cis.udel.edu)  
Internet Source 1%
- 3 [www.spandidos-publications.com](http://www.spandidos-publications.com)  
Internet Source 1%
- 4 Alexis B. Ulrich. "Differences in the Expression of Glutathione S-Transferases in Normal Pancreas, Chronic Pancreatitis, Secondary Chronic Pancreatitis, and Pancreatic Cancer :", *Pancreas*, 04/2002  
Publication 1%

5	Internet Source	1 %
6	<a href="https://digital.library.unt.edu">digital.library.unt.edu</a> Internet Source	<1 %
7	Muhammet Derda Ozer, Muhammed Batur, Erbil Seven, Serek Tekin, Fatih Kebapci. "In Vivo Analysis and Comparison of Anterior Segment Structures of Both Eyes in Unilateral Herpetic Anterior Uveitis", <i>Ocular Immunology and Inflammation</i> , 2020 Publication	<1 %
8	<a href="https://web.archive.org">web.archive.org</a> Internet Source	<1 %
9	Felipe R. Matos. "Immunoexpression of MMP-9, VEGF, and vWF in central and peripheral giant cell lesions of the jaws : MMP-9, VEGF, and vWF in giant cell lesions", <i>Journal of Oral Pathology and Medicine</i> , 04/2011 Publication	<1 %
10	Masaki Katsurahara. "Reactive Nitrogen Species Mediate DNA Damage in <i>Helicobacter pylori</i> -Infected Gastric Mucosa", <i>Helicobacter</i> , 12/2009 Publication	<1 %
11	<a href="https://repository.ubaya.ac.id">repository.ubaya.ac.id</a> Internet Source	<1 %

12	<a href="http://scholar.unand.ac.id">scholar.unand.ac.id</a> Internet Source	<1 %
13	<a href="http://bmcoophthalmol.biomedcentral.com">bmcoophthalmol.biomedcentral.com</a> Internet Source	<1 %
14	<a href="http://spandidos-publications.com">spandidos-publications.com</a> Internet Source	<1 %
15	<a href="http://www.nutriweb.org.my">www.nutriweb.org.my</a> Internet Source	<1 %
16	Imaging in Clinical Oncology, 2014. Publication	<1 %
17	Yongzhi Yang, Mingjuan Sun, Lianghua Wang, Binghua Jiao. "HIFs, angiogenesis, and cancer", Journal of Cellular Biochemistry, 2013 Publication	<1 %
18	Rosy Setiawati, Paulus Rahardjo, Ika Ruriana, Giuseppe Guglielmi. "Anthropometric study using three-dimensional pelvic CT scan in sex determination among adult Indonesian population", Forensic Science, Medicine and Pathology, 2022 Publication	<1 %
19	Alexandrakis, M.G.. "Relationship between serum levels of vascular endothelial growth factor, hepatocyte growth factor and matrix metalloproteinase-9 with biochemical markers	<1 %

of bone disease in multiple myeloma", Clinica Chimica Acta, 200704

Publication

---

20

Chaan S. Ng, Arlene O. Siefker-Radtke, Ashish Kamat. "Bladder Cancer and Upper Tracts", Elsevier BV, 2012

Publication

---

<1 %

21

Luo, Yang, Shao-Lan Qin, Yi-Fei Mu, Zheng-Shi Wang, Ming Zhong, and Zheng-Qian Bian. "Elevated expression of ECT2 predicts unfavorable prognosis in patients with colorectal cancer", Biomedicine & Pharmacotherapy, 2015.

Publication

---

<1 %

22

P O-charoenrat, P.H Rhys-Evans, D.J Archer, S.A Eccles. "C-erbB receptors in squamous cell carcinomas of the head and neck: clinical significance and correlation with matrix metalloproteinases and vascular endothelial growth factors", Oral Oncology, 2002

Publication

---

<1 %

23

U. Baylan, A. Korn, R. W. Emmens, C. G. Schalkwijk, H. WM Niessen, P. AJ Krijnen, S. Simsek. "Liraglutide treatment attenuates inflammation markers in the cardiac, cerebral and renal microvasculature in streptozotocin - induced diabetic rats",

<1 %

24

[ijp.iranpath.org](http://ijp.iranpath.org)

Internet Source

<1 %

25

[kclpure.kcl.ac.uk](http://kclpure.kcl.ac.uk)

Internet Source

<1 %

26

[pt.scribd.com](http://pt.scribd.com)

Internet Source

<1 %

27

"VEGF and Notch Signaling in Angiogenesis",  
Endothelial Signaling in Development and  
Disease, 2015.

Publication

<1 %

28

Kazumi Nishimae, Nobuyuki Tsunoda,  
Yukihiro Yokoyama, Toshio Kokuryo, Akari  
Iwakoshi, Masahide Takahashi, Masato  
Nagino. "The impact of Girdin expression on  
recurrence-free survival in patients with  
luminal-type breast cancer", Breast Cancer,  
2013

Publication

<1 %

29

Lee, S.J.. "Signaling pathway for TNF- $\alpha$ -  
induced MMP-9 expression: Mediation  
through p38 MAP kinase, and inhibition by  
anti-cancer molecule magnolol in human  
urinary bladder cancer 5637 cells",

<1 %

# International Immunopharmacology, 20081220

Publication

---

30

P S H Soon. "Microarray gene expression and immunohistochemistry analyses of adrenocortical tumors identify IGF2 and Ki-67 as useful in differentiating carcinomas from adenomas", Endocrine Related Cancer, 06/01/2009

Publication

---

<1 %

31

academic.oup.com

Internet Source

---

<1 %

32

fjfsdata01prod.blob.core.windows.net

Internet Source

---

<1 %

33

peerj.com

Internet Source

---

<1 %

34

researchonline.ljmu.ac.uk

Internet Source

---

<1 %

35

www.cellmolbiol.org

Internet Source

---

<1 %

36

www.researchgate.net

Internet Source

---

<1 %

37

"Gynecologic", Laboratory Investigation, 02/2006

Publication

---

<1 %

38

"PP3 - Displayed on Tuesday, September 11",  
Virchows Archiv, 2007

Publication

---

<1 %

39

Agung Sosiawan, Dadik Raharjo, Indah  
Nuraini, Nadia Kartikasari, Alexander Patera  
Nugraha, Muhammad Dimas Aditya Ari.  
"Detection of short tandem repeats at 5 loci  
and amelogenin with cell-free fetal DNA as a  
specimen in the development of prenatal  
paternity diagnostic tests", Egyptian Journal of  
Forensic Sciences, 2018

Publication

---

<1 %

40

Amir Hossein Jafarian, Melika Kooshki  
forooshani, Hossein Reisi, Nema Mohamadian  
roshan. "Matrix metalloproteinase-9 (MMP-9)  
Expression in Non-Small Cell Lung Carcinoma  
and Its Association with Clinicopathologic  
Factors", Iranian Journal of Pathology, 2020

Publication

---

<1 %

41

Haitao Li, Jianqiang Liu, Wen Wang, Zhijian  
Zhang, Dazhou Li, Kerong Lin, Zhiping Chen,  
Wulian Lin. "Matrix Metalloproteinase 9 and  
Vasodilator-Stimulated Phosphoprotein  
Related to Acute Kidney Injury in Severe Acute  
Pancreatitis Rats", Digestive Diseases and  
Sciences, 2015

Publication

---

<1 %

42	I M Fierro. "ATL-1, an analogue of aspirin-triggered lipoxin A4, is a potent inhibitor of several steps in angiogenesis induced by vascular endothelial growth factor", British Journal of Pharmacology, 03/2008 Publication	<1 %
43	cigwiki.houstonmethodist.org Internet Source	<1 %
44	mdpi-res.com Internet Source	<1 %
45	www.frontiersin.org Internet Source	<1 %
46	www.oncotarget.com Internet Source	<1 %
47	"Precision Molecular Pathology of Bladder Cancer", Springer Science and Business Media LLC, 2018 Publication	<1 %
48	Enyu Lin, Xuechao Liu, Yanjun Liu, Zedan Zhang, Lu Xie, Kaiwen Tian, Jiumin Liu, Yuming Yu. "Roles of the Dynamic Tumor Immune Microenvironment in the Individualized Treatment of Advanced Clear Cell Renal Cell Carcinoma", Frontiers in Immunology, 2021 Publication	<1 %



49

Porcellato, Ilaria, Andrea Giontella, Luca Mechelli, Emilia Del Rossi, and Chiara Brachelente. "Feline eosinophilic dermatoses: a retrospective immunohistochemical and ultrastructural study of extracellular matrix remodelling", *Veterinary Dermatology*, 2014.

Publication

&lt;1 %

50

"Urinary Bladder Pathology", Springer Science and Business Media LLC, 2021

Publication

&lt;1 %

51

Aukie Hooglugt, Miesje M. van der Stoel, Reinier A. Boon, Stephan Huveneers. "Endothelial YAP/TAZ Signaling in Angiogenesis and Tumor Vasculature", *Frontiers in Oncology*, 2021

Publication

&lt;1 %

52

Bénédicte Cauwe, Philippe E. Van den Steen, Ghislain Opdenakker. "The Biochemical, Biological, and Pathological Kaleidoscope of Cell Surface Substrates Processed by Matrix Metalloproteinases", *Critical Reviews in Biochemistry and Molecular Biology*, 2008

Publication

&lt;1 %

53

Chun-Te Wu, Ying-Hsu Chang, Paul- Yang Lin, Wen-Cheng Chen, Miao-Fen Chen. "Thrombomodulin expression regulates tumorigenesis in bladder cancer", *BMC Cancer*, 2014

&lt;1 %

54

Lee, Se-Jung, Jung-Hyurk Lim, Yung Hyun Choi, Wun-Jae Kim, and Sung-Kwon Moon.

<1 %

"Interleukin-28A triggers wound healing migration of bladder cancer cells via NF- $\hat{\text{B}}$ -mediated MMP-9 expression inducing the MAPK pathway", Cellular Signalling, 2012.

Publication

---

55

O. Simonetti. "Expression of vascular endothelial growth factor, apoptosis inhibitors (survivin and p16) and CCL27 in alopecia areata before and after diphencyprone treatment: an immunohistochemical study", British Journal of Dermatology, 5/2004

<1 %

Publication

---

Exclude quotes      On

Exclude matches      Off

Exclude bibliography      On

# The Role of MMP-9 and VEGF in the Invasion State of Bladder Urothelial Carcinoma

---

## GRADEMARK REPORT

---

FINAL GRADE

**/100**

GENERAL COMMENTS

**Instructor**

---

PAGE 1

---

PAGE 2

---

PAGE 3

---

PAGE 4

---

PAGE 5

---

PAGE 6

---

PAGE 7

---