
Re-submit paper ID 21322094304297515

2 messages

Gondo Mastutik <gondomastutik@gmail.com>

Wed, Sep 15, 2021 at 2:16 PM

To: Research Journal of Pharmacy and Technology Monika Daharwal <editor.rjpt@gmail.com>

Dear Editor,

I hereby submit the manuscript:

Paper ID: **21322094304297515**Title: [Presentation of Human Cytomegalovirus \(HCMV\) in liver tissues of cholestatic infants with extrahepatic and non-extrahepatic biliary atresia](#)

I've been trying to upload on the web since yesterday, but it always doesn't work because of a server error. If it's still needed to upload on the web, I'll do it.

Thank you.

Best wishes
Gondo Mastutik

=====

[Gondo Mastutik, DVM, MSc., PhD.](#)[Department of Anatomic Pathology, Faculty of Medicine](#)[Universitas Airlangga, Surabaya, Indonesia.](#)[St. Prof. Dr. Moestopo No 47, Surabaya 60132, Indonesia, Phone: +62-31-5020251 ext 151.](#)[E-mail: gondomastutik@fk.unair.ac.id, gondomastutik@gmail.com](#)

3 attachments**CMV liver GM Copy right transfer form & conflict of interest.pdf**

813K

**Turnitin Plagirms RJPT GONDO MASTUTIK CMV Liver.pdf**

2724K

**SUBMIT RJPT GONDO MASTUTIK re submit 14 Sept 2021.docx**

1070K

Research Journal of Pharmacy and Technology Monika Daharwal

<editor.rjpt@gmail.com>

Wed, Sep 15, 2021 at 7:00

PM

To: Gondo Mastutik <gondomastutik@gmail.com>

pls upload after sometimes

thanks

editor

[Quoted text hidden]

--

Editor,

Research Journal of Pharmacy and Technology,

RJPT House, Lokmanya Grih Nirman Society,

Rohanipuram, In-front of Sector- 1,

Pt. Deendayal Upadhyay Nagar,

Raipur 492 010. (CG) India.

Phone No. +919406051618

www.ajronline.orgwww.anvpublication.org

www.rjptonline.org

www.asianpharmaonline.org <<http://www.asianpharmapress.org>>

Paper ID: 21322094304297515

10 messages

Gondo Mastutik <gondomastutik@gmail.com>

Mon, Sep 13, 2021 at 11:54 AM

To: Research Journal of Pharmacy and Technology Monika Daharwal <editor.rjpt@gmail.com>

Dear Editor,

I would like to know the progression of my paper.

Paper ID: 21322094304297515**Title:** Presentation of Human Cytomegalovirus (HCMV) in liver tissues of cholestatic infants with extrahepatic and non-extrahepatic biliary atresia**Authors:** Alphania Rahniayu; Gondo Mastutik*; Willy Sandhika; S. Eriaty N. Ruslan; Anny Setijo Rahaju; Bagus Setyoboedi

I submitted in 22 March, 2021.

How are the results of the review?

I hope you could process it immediately.

Thank you,

Best wishes

Gondo Mastutik

=====

Gondo Mastutik, DVM, MSc., PhD.

Department of Anatomic Pathology, Faculty of Medicine

Universitas Airlangga, Surabaya, Indonesia.

St. Prof. Dr. Moestopo No 47, Surabaya 60132, Indonesia, Phone: +62-31-5020251 ext 151.

E-mail: gondomastutik@fk.unair.ac.id, gondomastutik@gmail.com

Research Journal of Pharmacy and Technology Monika Daharwal

Mon, Sep 13, 2021 at 6:57

<editor.rjpt@gmail.com>

PM

To: Gondo Mastutik <gondomastutik@gmail.com>

Dear Author,

Your article has been Sent to Reviewers. Comments still awaited. So we will go for editorial review process.

thanks

editor.

[Quoted text hidden]

--

Editor,

Research Journal of Pharmacy and Technology,

RJPT House, Lokmanya Grih Nirman Society,

Rohanipuram, In-front of Sector- 1,

Pt. Deendayal Upadhyay Nagar,

Raipur 492 010. (CG) India.

Phone No. +919406051618

www.ajronline.orgwww.anvpublication.orgwww.rjptonline.org

Gondo Mastutik <gondomastutik@gmail.com>
To: Research Journal of Pharmacy and Technology Monika Daharwal <editor.rjpt@gmail.com>

Fri, Sep 24, 2021 at 3:53 PM

Dear Editor,

I have tried every day to resubmit my manuscript, but until today the server is still in error.
I wonder how long the fix will take so I can upload my script?
Thank you

Best wishes,
Gondo Mastutik

[Quoted text hidden]

Research Journal of Pharmacy and Technology Monika Daharwal <editor.rjpt@gmail.com> Fri, Sep 24, 2021 at 7:09 PM
To: Gondo Mastutik <gondomastutik@gmail.com>

pl try now
thanks
editor
[Quoted text hidden]

Gondo Mastutik <gondomastutik@gmail.com>
To: Research Journal of Pharmacy and Technology Monika Daharwal <editor.rjpt@gmail.com>

Fri, Sep 24, 2021 at 8:20 PM

Dear Editor,
I have tried, but it did not work, it is still in the error server.

Best Wishes,
Gondo Mastutik

[Quoted text hidden]

Research Journal of Pharmacy and Technology Monika Daharwal
<editor.rjpt@gmail.com>
To: Gondo Mastutik <gondomastutik@gmail.com>

Sat, Sep 25, 2021 at 3:03 PM

Dear Author,
Thanks for information. We will update u soon.

Editor
[Quoted text hidden]

Gondo Mastutik <gondomastutik@gmail.com>
To: Research Journal of Pharmacy and Technology Monika Daharwal <editor.rjpt@gmail.com>

Wed, Oct 6, 2021 at 3:18 AM

Dear Editor,
Please help.
Until today, I still have trouble uploading the re-submit manuscripts.
Already 3 weeks.
Everyday I try it to upload, but the result is the same...

Server Error in '/' Application.

I hope you will help to repair it soon.

Thank you for your kindness

Best wishes
Gondo Mastutik

[Quoted text hidden]

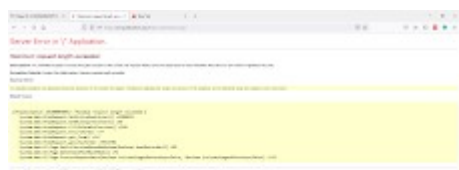Research Journal of Pharmacy and Technology Monika Daharwal <editor.rjpt@gmail.com> Wed, Oct 6, 2021 at 2:42 PM
To: Gondo Mastutik <gondomastutik@gmail.com>

dear author
u have submitted article on portal so all the process will be done on portal only.
thanks
editor
[Quoted text hidden]

Gondo Mastutik <gondomastutik@gmail.com> Wed, Oct 6, 2021 at 4:55 PM
To: Research Journal of Pharmacy and Technology Monika Daharwal <editor.rjpt@gmail.com>

Dear Editor
I have tried again using another computer, the result is still the same.
I hope the problem will be repaired soon.
Thank you.

Best wishes
Gondo Mastutik
[Quoted text hidden]



AV RJPT 2021.png
152K

Research Journal of Pharmacy and Technology Monika Daharwal <editor.rjpt@gmail.com> Wed, Oct 6, 2021 at 5:37 PM
To: Gondo Mastutik <gondomastutik@gmail.com>

dear author
when the file size is more than the above instruction comes so pl reduce the length of article while resubmission.
thanks
editor
[Quoted text hidden]

How is the progress of Paper ID: 21322094304297515

4 messages

Gondo Mastutik <gondomastutik@gmail.com>

Thu, Oct 21, 2021 at 6:07 AM

To: Research Journal of Pharmacy and Technology Monika Daharwal <editor.rjpt@gmail.com>

Dear Editor,
I would like to know the progression of my paper.

Paper ID: 21322094304297515**Title: Presentation of Human Cytomegalovirus (HCMV) in liver tissues of cholestatic infants with extrahepatic and non-extrahepatic biliary atresia.**

I submitted in 22 March, 2021.
How are the results of the review?
I hope it will be published immediately.

Thank you for your attention.

Best wishes
Gondo Mastutik

Research Journal of Pharmacy and Technology Monika Daharwal

Thu, Oct 21, 2021 at 2:45

<editor.rjpt@gmail.com>

PM

To: Gondo Mastutik <gondomastutik@gmail.com>

Dear Author,
Thanks for information. We will update u soon.

Editor

[Quoted text hidden]

--

Editor,
Research Journal of Pharmacy and Technology,
RJPT House, Lokmanya Grih Nirman Society,
Rohanipuram, In-front of Sector- 1,
Pt. Deendayal Upadhyay Nagar,
Raipur 492 010. (CG) India.
Phone No. +919406051618

www.ajronline.orgwww.anvpublication.orgwww.rjptonline.orgwww.asianpharmaonline.org <<http://www.asianpharmapress.org>>

Gondo Mastutik <gondomastutik@gmail.com>

Sat, Oct 23, 2021 at 7:21 AM

To: Research Journal of Pharmacy and Technology Monika Daharwal <editor.rjpt@gmail.com>

Dear Editor,
Here I inform that I have submitted the final version of our manuscript.
I hope you will send us the payment link.
Thank you for your attention.

Best Regard,
Gondo Mastutik

[Quoted text hidden]

Research Journal of Pharmacy and Technology Monika Daharwal <editor.rjpt@gmail.com> Sat, Oct 23, 2021 at 3:28 PM
To: Gondo Mastutik <gondomastutik@gmail.com>

dear author

ur article has been accepted for Year : 2022, Vol: 15, Issue: 6
u can pay processing fee and upload payment proof on portal.

thanks

editor

[Quoted text hidden]



Processing fee-RJPT-USD-200.pdf

113K

Request for invoice

19 messages

Gondo Mastutik <gondomastutik@gmail.com>

Thu, Nov 18, 2021 at 6:16 AM

To: Research Journal of Pharmacy and Technology Monika Daharwal <editor.rjpt@gmail.com>

Dear Editor,

I am grateful that you are willing to publish our article in your journal.

I am the corresponding author of the following articles:

Paper ID: 21522070126432681Title: [Detection of Cytomegalovirus in urine specimen of Cholestasis Infants by Polymerase Chain](#)**Payment Transaction No. : pay_HsXj6HPjptEsLV****Paid On : 9/2/2021 12:00:00 AM**Paper ID: 21322094304297515Title: [Presentation of Human Cytomegalovirus \(HCMV\) in liver tissues of cholestatic infants with extrahepatic and non-extrahepatic biliary atresia](#)**Payment Transaction No. : pay_IDu3BPNZfwd6gX****Paid On : 10/26/2021 12:00:00 AM**

I have paid APC for these two manuscripts (the proof is attached).

Before paying, I haven't saved the bill. And now, I need the invoice, to give to my institution as an official report on the payment.

Can you help us by providing invoices for these 2 articles?

I am very grateful for your kindness.

I am waiting for your reply.

Thank you.

Bets regard,
Gondo Mastutik=====
Gondo Mastutik, Ph.D.

Associate Professor

Department of Anatomic Pathology, Faculty of Medicine

Universitas Airlangga, Surabaya, Indonesia.

St. Prof. Dr. Moestopo No 47, Surabaya 60132, Indonesia, Phone: +62-31-5020251 ext 151.

E-mail: gondomastutik@fk.unair.ac.id, gondomastutik@gmail.com

2 attachments**Receipt pay RJPT CMV Liver GM.pdf**

68K

**Receipt pay RJPT Gondo Mastutik 2 Sept 2021.pdf**

68K

To: Gondo Mastutik <gondomastutik@gmail.com>

pl download

<https://anvpublication.org/invoice.aspx?i=21101174457>

<https://anvpublication.org/invoice.aspx?i=211110135020>

thanks

editor

[Quoted text hidden]

--

Editor,
Research Journal of Pharmacy and Technology,
RJPT House, Lokmanya Grih Nirman Society,
Rohanipuram, In-front of Sector- 1,
Pt. Deendayal Upadhyay Nagar,
Raipur 492 010. (CG) India.
Phone No. +919406051618

www.ajronline.org

www.anvpublication.org

www.rjptonline.org

www.asianpharmaonline.org <<http://www.asianpharmapress.org>>

Gondo Mastutik <gondomastutik@gmail.com>

Fri, Nov 19, 2021 at 2:27 PM

To: Research Journal of Pharmacy and Technology Monika Daharwal <editor.rjpt@gmail.com>

Dear Editor,
Thank you very much.

Best Regards,
Gondo Mastutik

[Quoted text hidden]

Research Journal of Pharmacy and Technology Monika Daharwal <editor.rjpt@gmail.com>

Thu, May 5, 2022 at 1:29 PM

To: Gondo Mastutik <gondomastutik@gmail.com>

Dear Author,
Regards

The submitted manuscript is ready for publication in Research Journal of Pharmacy and Technology
(RJPT) Vol. 15 Issue 6, June 2022.

The gallery proof of the paper is attaching herewith for any necessary correction if required, please convey
by E. Mail as in the attached format before **May 12, 2022.**

Thanking you,

Yours truly,


Editor

Gallery Proof of published article in **RJPT_15_6_2022**

[Quoted text hidden]

2 attachments

 **Formate.docx**
15K

 **21322094304297515-FOREIGN-----INDONESIA-----PG.7.pdf**
451K

Gondo Mastutik <gondomastutik@gmail.com>

Mon, May 9, 2022 at 7:29 AM

To: Research Journal of Pharmacy and Technology Monika Daharwal <editor.rjpt@gmail.com>

Dear Editors,

Herewith I attach the correction file for gallery proof. There are many revisions, including on abstract, keyword, the material and method, result, discussion, and references.

In references, There is one reference from PJPT issues May 2022, therefore I am still waiting for the page number and link online.

Thank you very much.

Best Regard,
Gondo Mastutik

[Quoted text hidden]

2 attachments

 **edit 21322094304297515-FOREIGN-----INDONESIA-----PG.7.pdf**
470K

 **Formate gallery proof Alphania Rahniayu May 2022.docx**
1138K

Research Journal of Pharmacy and Technology Monika Daharwal

Mon, May 9, 2022 at 7:01

<editor.rjpt@gmail.com>

PM

To: Gondo Mastutik <gondomastutik@gmail.com>


Dear author

here we have attached the corrected word file of ur article plz do correction and resent to us in word file without changing format

thanks

editor

[Quoted text hidden]

 **21322094304297515-----S-05-05----FOREIGN-INDONESIA-----PAGE--7.doc**
5533K

Gondo Mastutik <gondomastutik@gmail.com>

Wed, May 11, 2022 at 2:07 PM

To: Research Journal of Pharmacy and Technology Monika Daharwal <editor.rjpt@gmail.com>

Dear Editor,


I have revised the manuscript as an attachment. The sentences or words were revised, I highlighted it in yellow.

By the way, I have one problem. I cited our previous article that publishes in the RJPT issue in May 2022 as reference number 26 (I wrote it in red font), but I have not known the page number and DOI link. If you do not mind, would you please add the page number and DOI.

Thank you very much.

Best wishes,
Gondo Mastutik

[Quoted text hidden]

 **Edit 21322094304297515-----S-05-05----FOREIGN-INDONESIA-----PAGE--7.doc**
5651K

Research Journal of Pharmacy and Technology Monika Daharwal <editor.rjpt@gmail.com> Fri, May 13, 2022 at 5:21 PM

To: Gondo Mastutik <gondomastutik@gmail.com>

Dear Author,
Thanks for submission of Revised copy of manuscript.

Editor

[Quoted text hidden]


Gondo Mastutik <gondomastutik@gmail.com>

Tue, May 31, 2022 at 12:46 PM

To: Research Journal of Pharmacy and Technology Monika Daharwal <editor.rjpt@gmail.com>

Dear Editor,
I have corrected reference number 26 in this file.
Thank you.

Best Regard,
Gondo Mastutik
[Quoted text hidden]

 **Edit Ref no 26 - 21322094304297515-----S-05-05----FOREIGN-INDONESIA-----PAGE--7.doc**
5652K

Research Journal of Pharmacy and Technology Monika Daharwal

Tue, May 31, 2022 at 3:19

<editor.rjpt@gmail.com>

PM

To: Gondo Mastutik <gondomastutik@gmail.com>

[Quoted text hidden]

Research Journal of Pharmacy and Technology Monika Daharwal

Tue, May 31, 2022 at 3:19

<editor.rjpt@gmail.com>

PM

To: Gondo Mastutik <gondomastutik@gmail.com>

Dear Author,
Thanks for submission of Revised copy of manuscript.
Editor

[Quoted text hidden]

Research Journal of Pharmacy and Technology Monika Daharwal <editor.rjpt@gmail.com>

Fri, Jun 24, 2022 at 2:07

PM

To: Gondo Mastutik <gondomastutik@gmail.com>

Dear Author,


Regards

Please find enclosed the soft copy of article after publication in Research Journal of Pharmacy and Technology, Volume -15, Issue -6, 2022.

Thanks
Editor

Soft copy of article after publication.

[Quoted text hidden]

 **19_RJPT_15_6_2022.pdf**
303K

Gondo Mastutik <gondomastutik@gmail.com>

Mon, Jun 27, 2022 at 6:21 AM

To: alphania-r <alphania-r@fk.unair.ac.id>, Willy Sandhika <willysandh@gmail.com>, anny_sr <anny_sr@fk.unair.ac.id>, "S. Eriaty. N. Ruslan" <senruslan@gmail.com>, baguzze@gmail.com, erna.fkg@unej.ac.id

Date: April 10, 2022

Research Journal of Pharmacy and Technology

Paper ID:21322094304297515

Author's Name:Alphania Rahniayu, Gondo Mastutik*, Willy Sandhika, S. Eriaty N. Ruslan, Anny Setijo Rahaju, Bagus Setyoboedi

Paper Title: Presentation of Human Cytomegalovirus (HCMV) in liver tissues of cholestatic infants with extrahepatic and non-extrahepatic biliary atresia



Acceptance of Manuscript

With reference to your article titled '**Presentation of Human Cytomegalovirus (HCMV) in liver tissues of cholestatic infants with extrahepatic and non-extrahepatic biliary atresia**' Author by **Alphania Rahniayu, Gondo Mastutik*, Willy Sandhika, S. Eriaty N. Ruslan, Anny Setijo Rahaju, Bagus Setyoboedi**. We wish to bring to your kind notice the following:

- We acknowledge the receipt of the above mentioned article.
- The above mentioned article has been sent to the reviewer of expert comments.
- The above mentioned article have been accepted for publication in Year : 2022, Vol: 15, Issue: 6 of the journal.

Thanking you for submission of manuscript.

Yours sincerely.



Dr. Baharwal
Editor in Chief

Note: -

1. To verify the originality of this certificate please visit the following link:

http://www.anvpublication.org/Download_Acceptance.aspx?PID=21322094304297515

PRINT

Menjawab comments reviewer

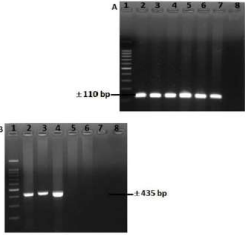
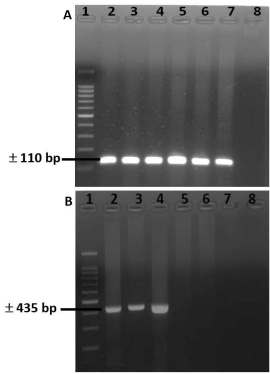
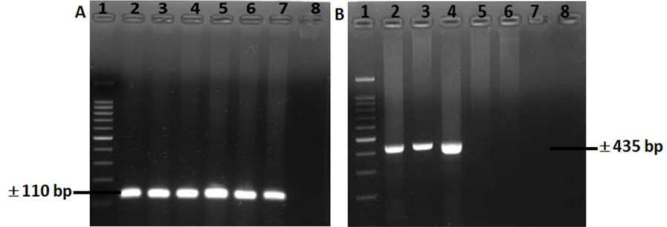
Journal's name	Research Journal of Pharmacy and Technology
Article title	Presentation of Human Cytomegalovirus (HCMV) in Liver Tissues of Cholestatic Infants with Extrahepatic and Non-Extrahepatic Biliary Atresia
Article Number (original Submitted manuscript No)	<u>Paper ID: 21322094304297515</u>
Only Corresponding authors name	Gondo Mastutik
I would like to recheck the corrections: corrections to be done within week very carefully	Yes

List of corrections

Page number	Column (Left / Right)	Paragraph number from top/	Line number from top of paragraph	Delete this text (Error)	Replace deleted text with (correction)

		Name of Paragraph			
1	Center	Abstract	Abstract	<p>Introduction: Human cytomegalovirus (HCMV) is associated with cholestasis in infants. Diagnosis of HCMV infection is most often based on serological anti-HCMV. Identification of HCMV in liver tissue has been rarely reported. The aims of this study were to determine the presentation of HCMV in liver tissues and to analyze its association with serological anti-HCMV of cholestatic infants with extrahepatic and non-extrahepatic biliary atresia. Methods: This observational study was performed during December 2017- December 2018 with ethics from our institutions. The parents or guardians of subjects signed the informed consent. The researchers collected the serological anti-HCMV data. Histopathological diagnosis and polymerase chain reaction (PCR) for HCMV were performed from liver biopsy tissues. The data were analyzed by Chi-square. Results: There were 47 cholestatic infants, 38.3% EBA and 61.7% non-EBA. Anti-HCMV IgM was positive in 38.3% patients and IgG was positive in 91.5% patients. Acute infection or recent infection were 38.3%, past or not acute infection were 53.1%, and uninfected or early infection were 8.5% patients. The presentation of HCMV in liver tissues was 68.1% patients, consisting of 11/18 EBA and 21/29 non-EBA and negative in 31.9% patients, consisting of 7/18 EBA and 8/29 non-EBA. There was no association between serological anti-HCMV and PCR HCMV with histopathological features. Conclusion: It suggests that PCR can be used as a routine tool to detect the presentation of HCMV DNA in liver tissue. Type of cholestasis in infants, both EBA and non-EBA, cannot be determined based on the serological and PCR examination, but based on histopathological features.</p>	<p>Introduction: Human cytomegalovirus (HCMV) is associated with cholestasis in infants. Diagnosis of HCMV infection is most often based on serological anti-HCMV. Identification of HCMV in liver tissue has been rarely reported. The aims of this study were to determine the presentation of HCMV in liver tissues and to analyze its association with serological anti-HCMV of cholestatic infants with extrahepatic and non-extrahepatic biliary atresia. Methods: This observational study was performed during December 2017- December 2018 with ethics from our institutions. The parents or guardians of subjects signed the informed consent. Anti-HCMV serological data were collected from patient medical records. Histopathological diagnosis and polymerase chain reaction (PCR) for HCMV were performed from liver biopsy tissues. The data were analyzed by Chi-square. Results: There were 47 cholestatic infants, 38.3% EBA and 61.7% non-EBA. Anti-HCMV IgM was positive in 38.3% patients and IgG was positive in 91.5% patients. Acute infection or recent infection were 38.3%, past or not acute infection were 53.1%, and uninfected or early infection were 8.5% patients. The presentation of HCMV in liver tissues was 68.1% patients, consisting of 11/18 EBA and 21/29 non-EBA and negative in 31.9% patients, consisting of 7/18 EBA and 8/29 non-EBA. There was no association between serological anti-HCMV and PCR HCMV with histopathological features. Conclusion: It suggests that PCR can be used as a routine tool to detect the presentation of HCMV DNA in liver tissue. Type of cholestasis in infants, both EBA and non-EBA, cannot be determined based on the serological and PCR examination, but based on histopathological features.</p>
1	Center	keyword	KEYWORDS	Human cytomegalovirus, cholestatic infants , liver biopsy, extrahepatic biliary atresia, non-extrahepatic biliary atresia.	Human cytomegalovirus, infant mortality , liver biopsy, biliary atresia, infectious disease

2	Right	Paragraph 2	Material and methods Sample collection	Subjects who took part in this study were required to obtain the parental or guardian consent by signing a written informed consent after receiving an informed consent explanation.	Subjects who participated in this study had obtained the parental or guardian consent by signing a written informed consent after receiving an explanation of the informed consent.																																		
3	Left	Paragraph 1	Detection Infection HCMV	Electrophoresis of PCR beta globin gene products showed a band of 110 base pair (bp). Samples with positive results for the beta globin gene will be followed by PCR HCMV.	Electrophoresis of PCR beta-globin gene products showed a band of 110 base pair (bp). Samples with positive results for the beta-globin gene will be followed by PCR HCMV.																																		
3	Right	Paragraph 3	Results	Serological examination showed that anti-HCMV IgM was positive in 18/47(38.3%) patients and anti-HCMV IgG was positive in 43/47(91.5%) patients, including 17 EBA and 26 non-EBA. In the IgM+ and IgG+ groups (acute or recent infection of HCMV groups), there were 18(38.3%) patients consisting of 10/18 the EBA patients and 8/18 the non-EBA patients. In the IgM- and IgG + groups (past or not acute infection of HCMV groups), there were 25(53.2%) patients consisting of 7/25 the EBA patients and 18/25 the non-EBA patients. In the IgM- and IgG- group (uninfected or early infection of HCMV), there were 4 (8.5%) patients (Table 3, 4, Figure 2).	Serological examination showed that anti-HCMV IgM was positive in 18/47 (38.3%) patients and anti-HCMV IgG was positive in 43/47 (91.5%) patients, including 17 EBA and 26 non-EBA. In the IgM+ and IgG+ groups (acute or recent infection of HCMV groups), there were 18 (38.3%) patients consisting of 10/18 the EBA patients and 8/18 the non-EBA patients. In the IgM- and IgG + groups (past or not acute infection of HCMV groups), there were 25 (53.2%) patients consisting of 7/25 the EBA patients and 18/25 the non-EBA patients. In the IgM- and IgG- group (uninfected or early infection of HCMV), there were 4 (8.5%) patients (Table 3, 4, Figure 2).																																		
3	Right	Paragraph 3	Table 2	<p>Table 2. Characterization of patients</p> <table border="1"> <tr><td>Age (mean ± SD)</td><td>3,28 ± 2,214</td></tr> <tr><td>Age (n / %)</td><td></td></tr> <tr><td>1-2 month</td><td>23 / 48.9</td></tr> <tr><td>3-4 month</td><td>16 / 34.1</td></tr> <tr><td>5-6 month</td><td>4 / 8.5</td></tr> <tr><td>>6 month</td><td>4 / 8.5</td></tr> <tr><td>Sex</td><td></td></tr> <tr><td>Male (n / %)</td><td>27/57.4</td></tr> <tr><td>Female (n / %)</td><td>20/42.6</td></tr> <tr><td>D Bil (mean ± SD)</td><td>7.9430 ± 4.13824</td></tr> <tr><td>T Bil (mean ± SD)</td><td>11.0828 ± 5.50279</td></tr> </table> <p>D Bil = the direct / conjugated bilirubin level, T Bil = total bilirubin level</p>	Age (mean ± SD)	3,28 ± 2,214	Age (n / %)		1-2 month	23 / 48.9	3-4 month	16 / 34.1	5-6 month	4 / 8.5	>6 month	4 / 8.5	Sex		Male (n / %)	27/57.4	Female (n / %)	20/42.6	D Bil (mean ± SD)	7.9430 ± 4.13824	T Bil (mean ± SD)	11.0828 ± 5.50279	<p>Give space between number and symbol (</p> <table border="1"> <tr><td>Age (mean □ SD)</td><td>3,28 □ 2,214</td></tr> <tr><td>Age (n / %)</td><td></td></tr> <tr><td>1-2 month</td><td>23/48.9</td></tr> <tr><td>3-4 month</td><td>16/34.1</td></tr> <tr><td>5-6 month</td><td>4/8.5</td></tr> <tr><td>>6 month</td><td>4/8.5</td></tr> </table> <p>Delete space between number and symbol /</p>	Age (mean □ SD)	3,28 □ 2,214	Age (n / %)		1-2 month	23/48.9	3-4 month	16/34.1	5-6 month	4/8.5	>6 month	4/8.5
Age (mean ± SD)	3,28 ± 2,214																																						
Age (n / %)																																							
1-2 month	23 / 48.9																																						
3-4 month	16 / 34.1																																						
5-6 month	4 / 8.5																																						
>6 month	4 / 8.5																																						
Sex																																							
Male (n / %)	27/57.4																																						
Female (n / %)	20/42.6																																						
D Bil (mean ± SD)	7.9430 ± 4.13824																																						
T Bil (mean ± SD)	11.0828 ± 5.50279																																						
Age (mean □ SD)	3,28 □ 2,214																																						
Age (n / %)																																							
1-2 month	23/48.9																																						
3-4 month	16/34.1																																						
5-6 month	4/8.5																																						
>6 month	4/8.5																																						

4	Right	Paragraph 1	Figure 2		 <p>The figure should be like figure in above OR in below</p> 
5	Left	Paragraph 1	Discussion	<p>Neonatal cholestatic syndrome may be a result of intrahepatic alterations caused by metabolic, toxic medication, hereditary, anatomic, and idiopathic infections. It is also the result of extrahepatic alterations caused by extrahepatic biliary atresia (EBA) and choledochal cysts. EBA is the final result of a destructive inflammatory process that affects the intrahepatic and extrahepatic biliary ducts leading to fibrosis and obliteration of the biliary tract at some point between the porta hepatis and the duodenum¹⁶. Histological assessment of the liver tissue from cholestatic patients revealed mainly mixed lymphocytic/granulocytic inflam-matory infiltrations, giant cell transformation and fibrosis¹⁷. This study was conducted on the liver biopsy specimens from infants with cholestasis. All</p>	<p>Neonatal cholestatic syndrome may be a result of intrahepatic alterations caused by metabolic, toxic medication, hereditary, anatomic, and idiopathic infections. It is also the result of extrahepatic alterations caused by extrahepatic biliary atresia (EBA) and choledochal cysts. EBA is the final result of a destructive inflammatory process that affects the intrahepatic and extrahepatic biliary ducts leading to fibrosis and obliteration of the biliary tract at some point between the porta hepatis and the duodenum¹⁶. Histological assessment of the liver tissue from cholestatic patients revealed mainly mixed lymphocytic/granulocytic inflam-matory infiltrations, giant cell transformation and fibrosis¹⁷. This study was conducted on the liver biopsy specimens from infants with cholestasis. All</p>

				specimens diagnosed as EBA and non-EBA based on histopathological appearance, 18/47(38.3%) patients referred as EBA, and 29/47(61.7%) patients referred as non-EBA. The microscopic features of EBA are ductular reaction, ductular cholestasis, portal edema, and fibrosis ¹⁸ . Some of liver cells infected with HCMV showed the intranuclear and intracytoplasmic inclusions bodies and inflammatory cell aggregates ¹⁹ . Microscopic feature other than those characteristics are categorized as non-EBA ¹⁸ . It is also associated with intrahepatic bile duct destruction and ductal paucity, indicating a possible role in the pathogenesis and progression of extrahepatic BA ²⁰ .	specimens diagnosed as EBA and non-EBA based on histopathological appearance, 18/47 (38.3%) patients referred as EBA, and 29/47 (61.7%) patients referred as non-EBA. The microscopic features of EBA are ductular reaction, ductular cholestasis, portal edema, and fibrosis ¹⁸ . Some of liver cells infected with HCMV showed the intranuclear and intracytoplasmic inclusions bodies and inflammatory cell aggregates ¹⁹ . Microscopic feature other than those characteristics are categorized as non-EBA ¹⁸ . It is also associated with intrahepatic bile duct destruction and ductal paucity, indicating a possible role in the pathogenesis and progression of extrahepatic BA ²⁰ .
					Give space between number and symbol (
5	Right	Paragraph 3	Discussion	In this study, the researchers used major immediate early and late antigen genes.	In this study, the major immediate early gene was used as PCR targets.
5	Right	Paragraph 3	Discussion	It showed that 32/47 (68.1%) patients had positive for DNA HCMV in their liver. Another study in cholestasis infants showed that 12/25 (48%) liver DNA was positive for HCMV ²² and 16/31 (52%) ²⁴ .	It showed that 32/47 (68.1%) patients had positive for DNA HCMV in their liver. Another study in cholestatic infants showed that 12/25 (48%) liver DNA was positive for HCMV ²² and 16/31 (52%) ²⁴ .
6	Left	Paragraph 2	Discussion	Most of the patients in this study on EHBA and non-EHBA were infected by HCMV. The results of this study showed 11/18 (61.1%) of the EBA patients and 21/29(72.4%) of the non-EBA patients were infected by HCMV. This showed that HCMV contributed to the development of cholestasis in infants, including EHBA and non-EHBA. This was also in accordance with several previous studies. DNA HCMV was presented in 8/15(53.3%) EHBA patients and 8/16 (50%) non-EHBA patients ²⁴ , 9/18(50%) EHBA patients and 3/7(42.9 %) non-EHBA patients ²² , and 9/33(27.3%) in the liver of EHBA patients ⁵ .	Most of the patients in this study on EHBA and non-EHBA were infected by HCMV. The results of this study showed 11/18 (61.1%) of the EBA patients and 21/29 (72.4%) of the non-EBA patients were infected by HCMV. This showed that HCMV contributed to the development of cholestasis in infants, including EHBA and non-EHBA. This was also in accordance with several previous studies. DNA HCMV was presented in 8/15 (53.3%) EHBA patients and 8/16 (50%) non-EHBA patients ²⁴ , 9/18 (50%) EHBA patients and 3/7 (42.9 %) non-EHBA patients ²² , and 9/33 (27.3%) in the liver of EHBA patients ⁵ .
					Give space between number and symbol (
6	Right	Paragraph 3	Discussion	Other studies also shown that no correlation between HCMV positivity by PCR and the histological findings ⁵ .	It should be: Other studies shown that no correlation between HCMV positivity by PCR and the histological findings ⁵ .
7	Right	Number 26	References	Mastutik G. Kurniasari N. Rahniayu A. Rahaju AN. Ruslan SEN. Ilmiah K. Setyo boedi B. Sulistyani E. Detection of cytomegalovirus in urine specimen of cholestasis infants by	It should be Mastutik G. Kurniasari N. Rahniayu A. Rahaju AN. Ruslan SEN. Ilmiah K. Setyo boedi B. Sulistyani E. Detection of cytomegalovirus in urine specimen of cholestasis infants

				polymerase chain reaction. Research Journal of Pharmacy and Technology. 2022; 15(4)	by polymerase chain reaction. Research Journal of Pharmacy and Technology. 2022; 15(5): page number. Wait online link from RJPT May 2022
--	--	--	--	---	--

ISSN 0974-3618 (Print)
0974-360X (Online)

www.rjptonline.org

RESEARCH ARTICLE

Presentation of Human Cytomegalovirus (HCMV) in Liver Tissues of Cholestatic Infants with Extrahepatic and Non-Extrahepatic Biliary Atresia

Alphania Rahniayu^{1,2}, Gondo Mastutik^{1*}, Willy Sandhika^{1,2}, S. Eriaty N. Ruslan³,
Anny Setijo Rahaju^{1,2}, Bagus Setyo boedi^{4,5}, Erna Sulistyani⁶

¹Department of Anatomic Pathology, Faculty of Medicine, Universitas Airlangga, Surabaya-60132, Indonesia

²Department of Anatomic Pathology, Dr. Soetomo General Academic Hospital, Surabaya-60132, Indonesia

³Institute of Tropical Diseases, Universitas Airlangga, Surabaya-60132, Indonesia

⁴Department of Child Health of Pediatric, Faculty of Medicine, Universitas Airlangga, Surabaya-60132, Indonesia

⁵Department of Child Health of Pediatric, Dr. Soetomo General Academic Hospital, Surabaya-60132, Indonesia

⁶Department of Oral Medicine, Faculty Dentistry, Jember University, Jember-68121, Indonesia

*Corresponding Author E-mail: gondomastutik@fk.unair.ac.id, gondomastutik@gmail.com

ABSTRACT:

Introduction: Human cytomegalovirus (HCMV) is associated with cholestasis in infants. Diagnosis of HCMV infection is most often based on serological anti-HCMV. Identification of HCMV in liver tissue has been rarely reported. The aims of this study were to determine the presentation of HCMV in liver tissues and to analyze its association with serological anti-HCMV of cholestatic infants with extrahepatic and non-extrahepatic biliary atresia. **Methods:** This observational study was performed during December 2017- December 2018 with ethics from our institutions. The parents or guardians of subjects signed the informed consent. ~~The researchers collected the serological anti-HCMV data.~~ Histopathological diagnosis and polymerase chain reaction (PCR) for HCMV were performed from liver biopsy tissues. The data were analyzed by Chi-square. **Results:** There were 47 cholestatic infants, 38.3% EBA and 61.7% non-EBA. Anti-HCMV IgM was positive in 38.3% patients and IgG was positive in 91.5% patients. Acute infection or recent infection were 38.3%, past or not acute infection were 53.1%, and uninfected or early infection were 8.5% patients. The presentation of HCMV in liver tissues was 68.1% patients, consisting of 11/18 EBA and 21/29 non-EBA and negative in 31.9% patients, consisting of 7/18 EBA and 8/29 non-EBA. There was no association between serological anti-HCMV and PCR HCMV with histopathological features. **Conclusion:** It suggests that PCR can be used as a routine tool to detect the presentation of HCMV DNA in liver tissue. Type of cholestasis in infants, both EBA and non-EBA, cannot be determined based on the serological and PCR examination, but based on histopathological features.

KEYWORDS: ~~Human cytomegalovirus, cholestatic infants, liver biopsy, extrahepatic biliary atresia, non-extrahepatic biliary atresia.~~

INTRODUCTION:

Human cytomegalovirus (HCMV) is the most common viral infection causing neonatal cholestasis and the most frequent congenital virus infection worldwide^{1,2}. HCMV infects 30,000 to 40,000 infants each year in the United States³.

Infants can acquire CMV infection from their mother through intrauterine infection (congenital infection), through contact with infected genital secretions during passage through the birth canal (perinatal infection), or postpartum through breastfeeding (postnatal infection)³. Approximately 10-15% newborns show symptomatic congenital infection with the clinical manifestation including fetal growth restriction, low birth weight, and cerebral and multiple organs involvement and 85-90% is asymptomatic^{3,4}. Approximately 10-15% of newborns with asymptomatic CMV infection develop long-term sequel, for example, progressive sensorineural

hearing difficulty and psychomotor retardation⁴. Therefore, it is very important to be able to diagnose of HCMV infection early, so that it can provide the appropriate interventions to reduce the sequelae of infection.

The most common diagnosis of HCMV infection is serological examination, namely anti-HCMV immunoglobulin M (IgM) and anti-HCMV immunoglobulin G (IgG). IgM is formed 2-4 weeks after infection, persists and decreases rapidly within 2-4 months, and then is undetectable within 12 months and IgG is formed⁵. However, in newborns, the ability to synthesize IgM and IgG is still low. IgG for newborns is obtained maternally from the mother, while IgM is still in the learning process to synthesize slowly¹ so that the serological examination of IgM and IgG anti-HCMV in the first week of a baby is still unable to reflect the condition of HCMV infection in infants. Furthermore, laboratory tests of cholestasis have shown an increase in conjugated bilirubin, which is a conjugated bilirubin level of more than 20% of the total bilirubin level if the total bilirubin level is >5mg/dl or the direct bilirubin level is more than 2mg/dl if the total bilirubin is <5 mg/dl⁶⁻⁸ but this examination only shows the condition of cholestasis without knowing the main cause of diseases. In addition, HCMV can be isolated by PCR examination of body tissues and body fluids such as tears, salivary glands, breast milk, urine, feces, semen, cervical secretions, amniotic fluid, blood, and organ transplants⁹⁻¹¹ that might be performed to explain the main cause of cholestasis.

Neonatal cholestasis is often classified as either extrahepatic or intrahepatic in origin. Extrahepatic is most known as biliary atresia and intrahepatic known as neonatal hepatitis. Biliary atresia is a decrease or obstruction of the hepatic or bile ducts at any point from the porta hepatis to the duodenum with an ongoing intrahepatic bile duct damage². Based on the histopathological features, there are two type of cholestasis, namely extrahepatic biliary atresia (EBA) and non-EBA. The histopathological features of the liver biopsy in biliary atresia are biliary duct proliferation, bile plugs, portal tract fibrosis and edema, whereas in non-biliary atresia are showing feature of viral hepatitis, such as human cytomegalovirus (HCMV) or herpes simplex, and changes thought to be due to metabolic disease¹². The time of diagnosis is a critical time for disease intervention because biliary atresia rapidly leads to the liver to cirrhosis¹³. Percutaneous liver biopsy has a high accuracy (88.2%) for diagnosing biliary atresia¹⁴ and is the best method to differentiate biliary atresia and non-biliary atresia¹⁵.

The objective was to determine the presentation of HCMV DNA in the liver biopsy tissues and to analyze

its association with serological anti-HCMV in cholestasis infants and histological features, both EBA and non-EBA. The results of this study are expected to be used as a theoretical basis for using PCR examination as a routine procedure to diagnose HCMV infection in cholestatic infants.

MATERIALS AND METHODS:

Sample Collections:

This research was a descriptive observational study with a cross-sectional approach at the Inpatient Clinic, Department of Pediatric, Dr. Soetomo General Academic Hospital, Surabaya, Indonesia, during December 2017-December 2018. This study has obtained ethics from the Health Research Ethics Commission, Dr. Soetomo General Academic Hospital, Surabaya, number 729/Panke.KKE/XII/ 2017. ~~Subjects who took part in this study were required to obtain~~ the parental or guardian consent by signing a written informed consent after receiving an informed consent explanation.

The sample was liver biopsy tissues obtained from cholestatic infants who showed symptoms of jaundice with conjugated bilirubin levels 20% of total bilirubin levels, if total bilirubin is ≥ 5 mg/dL or direct bilirubin levels >2 mg/dL if total bilirubin <5 mg/dL. Inclusion criteria was aged 1-12 months. Exclusion criteria were patients who had received antiviral therapy, HIV patients, miliary tuberculosis patients, malnourished patients, history of use of immunosuppressive drugs such as corticosteroids and cytostatics, platelets $<80,000$ mg/dl, prolonged hemostasis physiology, and ascites.

Histopathological Diagnosis:

The histopathological diagnosis of liver biopsy tissues was performed by two pathologists based on microscopic features in Hematoxylin Eosin and Masson Trichrome staining. The histopathological diagnosis consisted of extrahepatic biliary atresia and non-extrahepatic biliary atresia.

Detection Infection HCMV:

Serological examination of HCMV infection was performed by measuring IgM and IgG levels using The VIDAS CMV IgM and IgG Assay (Biomérieux). IgM interpretation is the IgM index unit <0.7 is negative, $<0.7 - 0.9$ is equivocal, > 0.9 is positive. IgG interpretation is the IgG index unit <4 is negative, $> 4 - <6$ is equivocal, > 6 is positive. This data were secondary data from patient medical record.

Detection of HCMV DNA in liver tissues were performed by nested polymerase chain reaction (PCR) using MIE4/MIE5 primers for the first round and IE1/IE2 primers for the second round (Table 1)⁵. DNA was extracted from the liver biopsy using QIAamp DNA

Mini Kit (Qiagen) and used for PCR. First, PCR was conducted for the β -globin gene using PCO3 + and PCO4 + primers⁵ (Table 1) and secondly for HCMV. The master mix used PCR Master Mix (Promega), namely a reaction mix composed by 10 μ l master mix (Promega), 1 μ l forward primer (PCO3 +) 10 pmol, 1 μ l reverse primer (PCO4 +) 10 pmol, 5 μ l ddH₂O (water), and 3 μ l DNA template. PCR conditions were pre-denaturation 94°C, 5 minutes for one cycle, denaturation 94°C for 30 seconds, annealing 55°C for 30 seconds, extension 72°C for 45 seconds, all for 40 cycles, then the final extension was 72°C for 7 minutes. Electrophoresis of PCR ~~beta-globin~~ ~~gene~~ products showed a band of 110 base pair (bp). Samples with positive results for the ~~beta-globin~~ ~~gene~~ will be followed by PCR HCMV.

The PCR master mix (Promega) for identification HCMV at the first round was 10 μ l master mix PCR, 1 μ l the 10 pmol MIE4 primer, 1 μ l the 10pmol MIE5 primer, 4 μ l ddH₂O, and 4 μ l DNA template. The PCR conditions were pre-denaturation 94°C for 5 minutes, denaturation 94°C for 30 seconds, annealing 55°C for 30 seconds, extension 72°C for 45 seconds for 40 cycles. The final extension was 72°C for 7 minutes. For the second round, the PCR conditions were the same as the first round PCR, but the template was 1 μ l of the first round PCR product and PCR was performed by IE1/IE2 primers. PCR results were electrophoresed on 2% acrylamide gel and documented.

Table 1. Oligonucleotide primers for PCR amplification of HCMV

Primer Name	Position	Sequence	Product (base pair)
PCO3+	Forward	5'-CCT CTG ACA CAA CTG TGT TCA CTA GC-3'	110 bp
PCO4+	Reverse	5'-TCA CCA CCA ACT TCA TCC ACG TTC ACC-3'	
MIE4	Forward	5'-CCA AGC GGC CTC TGA TAA CCA AGC C-3'	435 bp
MIE5	Reverse	5'-CAG CAC CAT CCT CCT CTT CCT CTG G-3'	
IE1	Forward	5'- CCA CCC GTG GTG CCA GCT CC-3'	161 bp
IE2	Reverse	5'-CCC GCT CCT CCT GAG GAC CC-3'	

Statistical analysis:

The association between the serological examinations of HCMV with PCR examination of liver biopsy tissue from infants with cholestasis was done by Chi-square, if significantly different, the strength of the relationship was known by contingency coefficient

RESULT:

Samples were 47 infants with cholestasis symptoms, consisting of 27 boys and 20 girls, aged between 1-12

months (mean \pm SD = 3.28 \pm 2.214). Patients consisted of 39 patients aged under 4 months and 8 patients aged over 5 months. The direct/conjugated bilirubin (D Bil) level was 7.9430 \pm 4.13824 (mean \pm SD) and the total bilirubin (T Bil) was 11.0828 \pm 5.50279 (mean \pm SD) (Table 2).

Histopathological diagnosis of liver biopsy tissue from infants with cholestasis showed that there were 29 (61.7%) non-extrahepatic biliary atresia patients and 18 (38.3%) extrahepatic biliary atresia patients (Table 3, Figure 1).

Serological examination showed that anti-HCMV IgM was positive in 18/47(38.3%) patients and anti-HCMV IgG was positive in 43/47(91.5%) patients, including 17 EBA and 26 non-EBA. In the IgM+ and IgG+ groups (acute or recent infection of HCMV groups), there were 18(38.3%) patients consisting of 10/18 the EBA patients and 8/18 the non-EBA patients. In the IgM- and IgG + groups (past or not acute infection of HCMV groups), there were 25(53.2%) patients consisting of 7/25 the EBA patients and 18/25 the non-EBA patients. In the IgM- and IgG- group (uninfected or early infection of HCMV), there were 4 (8.5%) patients (Table 3, 4, Figure 2).

Table 2. Characterization of patients

Age (mean \pm SD)	3,28 \pm 2,214
Age (n / %)	
1-2 month	23 / 48.9
3-4 month	16 / 34.1
5-6 month	4 / 8.5
>6 month	4 / 8.5
Sex	
Male (n / %)	27/57.4
Female (n / %)	20/42.6
D Bil (mean \pm SD)	7.9430 \pm 4.13824
T Bil (mean \pm SD)	11.0828 \pm 5.50279

D Bil = the direct / conjugated bilirubin level, T Bil = total bilirubin level

Table 3. The histopathological diagnosis, serological examination, and HCMV PCR in cholestatic infants

		n	Percentage
Histopathological diagnosis	Extrahepatic biliary atresia	18	38,3%
	Non-extrahepatic biliary atresia	29	61,7%
Serological examination	IgM+	18	38,3%
	IgG+	43	91,5%
	IgM+, IgG+ (recent or past/recurrent infection)	18	38,3%
	IgM-, IgG+ (past infection)	25	53,2%
	IgM-, IgG- (uninfected or early infected)	4	8,5%
PCR HCMV	Positive	32	68,1%
	Negative	15	31,9%

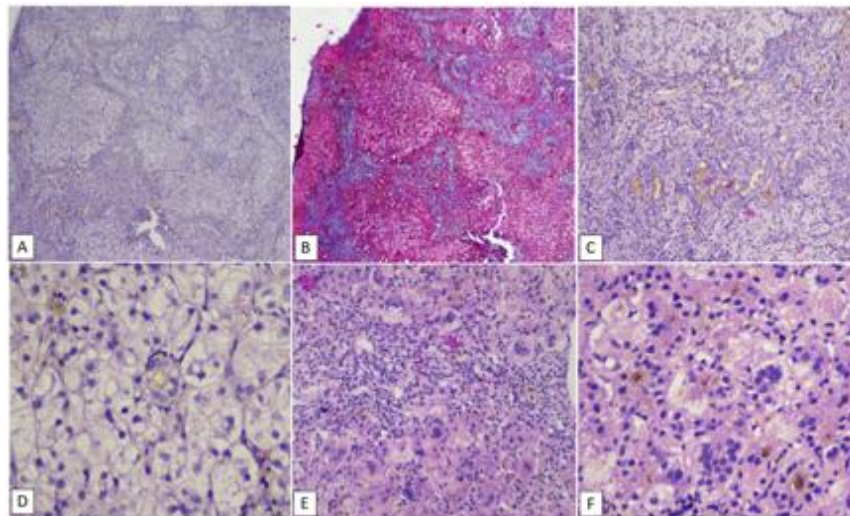


Figure 1. Histopathological features of extrahepatic biliary atresia and non-extrahepatic biliary atresia. (A) Disrupted hepatic parenchymal architecture in EBA (HE, 40x), (B) Biliary cirrhosis in EBA (MT, 40x), (C) Bile ductular proliferation containing bile plug in widened portal area displayed in EBA (HE, 100x), (D) Dilated canaliculi containing bile pigment and ballooning degeneration of hepatocytes documented in EBA (HE, 400x), (E), (F) Numerous multinucleated giant cell hepatocytes accompanied with lobular inflammation in Non-EBA (HE, 200x and 400x). MT: Masson Trichrome, HE: Hematoxylin Eosin.

HCMV DNA was detected in liver biopsy specimens from 32 of 47 (68.1%) (Table 4, Figure 2) that consisted of 11/18 (61.1%) EBA patients and 21/29 (72.4%) non-EBA patients. In 11 EHBA patients with the HCMV DNA positive in their liver showed that 7 patients had anti-HCMV IgM and IgG in their sera and the rest showed anti-HCMV IgG in their sera. The 21 non-EHBA patients with the HCMV DNA positive in their liver showed that 5 patients had positive for anti-HCMV IgM and IgG, 15 had positive for anti HCMV IgG, and 1 patient had negative for anti-HCMV IgM and IgG (Table 4, Figure 2).

HCMV DNA was not detected in liver biopsies specimens from 15 of 47 (31.9%) patients that consisted of 7/15 (46.7%) EBA patients and 8/29 (53.3%) non-EBA patients. In 7 EHBA patients with the HCMV DNA negative in their liver showed that 3 patients had anti-HCMV IgM and IgG in their sera and 3 had positive for anti HCMV IgG, and 1 patient had negative for anti-HCMV IgM and IgG. In 8 non-EHBA patients with the HCMV DNA negative in their liver showed that 3 patients had anti-HCMV IgM and IgG in their sera and 3 had positive for anti HCMV IgG, and 2 patients had negative for anti-HCMV IgM and IgG (Table 4, Figure 2).

There was no association between serological anti-HCMV and PCR HCMV liver with histopathological diagnosis, neither EBA nor non-EBA ($p=0.151$, $p=0.627$) (Table 4). There was no association between serological anti-HCMV with PCR HCMV liver specimens in cholestatic infants ($p=0.106$) (Table 5).

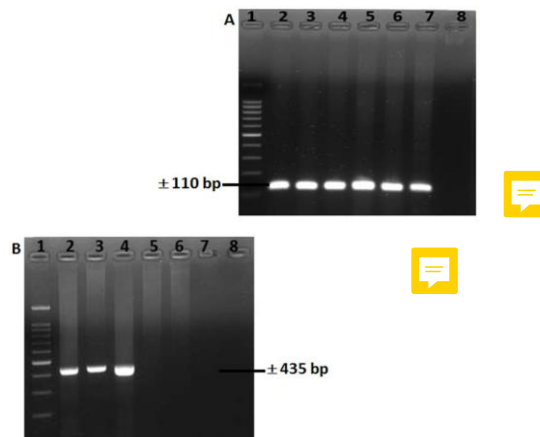


Figure 2. PCR β -globin with the oligonucleotide primer PCO3+/PCO4+ (A) and HCMV with the oligonucleotide primer MIE4/MIE5 (B) from the liver tissue of cholestatic infant. (A) lane 1 = marker, lane 2, 3, 4, 5, 6, 7 = specimens showed positive (± 110 bp), lane 8 = positive control. (B) lane 1 = M, lane 2, 3, 4 = specimens showed positive (± 435 bp), lane 5, 6, 7 = specimens showed negative, lane 8 = positive control.

Table 4. Association of HCMV infections based on the results of serological examination and PCR from liver tissues in extrahepatic biliary atresia and non-extrahepatic biliary atresia

	EBA	Non-EBA	Total	P value
Serology				0.151
IgM+ IgG+	10	8	18	
IgM- IgG+	7	18	25	
IgM- IgG-	1	3	4	
Total	18	29	47	
PCR				0.627
Positive	11	21	32	
Negative	7	8	15	
Total	18	29	47	

Note: EBA = extrahepatic biliary atresia, non-EBA = non-extrahepatic biliary atresia

Table 5. Association between HCMV identification by serological anti-HCMV and PCR HCMV

Serology anti-HCMV	The PCR HCMV of Liver						Total	p value
	Positive			Negative				
	EBA	Non-EBA	Total	EBA	Non-EBA	Total		
IgM+, IgG+	7	5	12	3	3	6	18	0.106
IgM-, IgG+	4	15	19	3	3	6	25	
IgM-, IgG-	0	1	1	1	2	3	4	
Total	11	21	32	7	8	15	47	

Note: EBA = extrahepatic biliary atresia, non-EBA = non-extrahepatic biliary atresia

DISCUSSION:

Neonatal cholestatic syndrome may be a result of intrahepatic alterations caused by metabolic, toxic medication, hereditary, anatomic, and idiopathic infections. It is also the result of extrahepatic alterations caused by extrahepatic biliary atresia (EBA) and choledochal cysts. EBA is the final result of a destructive inflammatory process that affects the intrahepatic and extrahepatic biliary ducts leading to fibrosis and obliteration of the biliary tract at some point between the porta hepatis and the duodenum¹⁶. Histological assessment of the liver tissue from cholestatic patients revealed mainly mixed lymphocytic/granulocytic inflammatory infiltrations, giant cell transformation and fibrosis¹⁷. This study was conducted on the liver biopsy specimens from infants with cholestasis. All specimens diagnosed as EBA and non-EBA based on histopathological appearance, 18/47(38.3%) patients referred as EBA, and 29/47(61.7%) patients referred as non-EBA. The microscopic features of EBA are ductular reaction, ductular cholestasis, portal edema, and fibrosis¹⁸. Some of liver cells infected with HCMV showed the intranuclear and intracytoplasmic inclusions bodies and inflammatory cell aggregates¹⁹. Microscopic feature other than those characteristics are categorized as non-EBA¹⁸. It is also associated with intrahepatic bile duct destruction and ductal paucity, indicating a possible role in the pathogenesis and progression of extrahepatic BA²⁰.

Human CMV is associated with cholestasis in infants. Diagnosis of HCMV infection is most often based on serological anti-HCMV. Serological examination is used to detect the specific reaction of antigen and antibody. HCMV serological examination is intended to detect the presence of anti-CMV specific antibodies in the serum²¹. In this study, 18/47 (38.3%) patients were positive for anti-HCMV IgM and 43/47 (91.5%) patients were positive for anti-HCMV IgG. Other studies showed that anti-HCMV IgM was positive in 13/31 (42%) patients, anti-HCMV IgG was positive in 26/31 (84%) patients²⁴. IgM positive for CMV in neonatal cholestasis in Sweden was 19/59 (32.2%), IgG positive was 53/59 (90%), IgM-

and IgG- was in 6/59 infants²². Neonatal cholestasis in Egypt, IgM CMV was positive in 23/185 (12.4%), that consisted of 4/94 (4.3%) in EHBA and 19/91 (20.9%) in non-EHBA²³.

Serological tests are also very useful to determine whether a patient has had CMV infection in the past, by evaluating anti-HCMV IgG. Detection of IgM antibodies is used as an indicator of acute infection or new infection²¹. The interpretation of acute or recent infection is if anti-HCMV IgM and IgG are positive (IgM+ IgG+), past or not acute infection is if IgM is negative and IgG is positive (IgM- IgG+), and uninfected or to early infected is if IgM and IgG are negative (IgM- IgG-)¹. In this study, acute or recent infection (IgM+ IgG+) were 18/47 (38.3%) patients, past or not acute infection (IgM- IgG+) were 25/47 (53.1%) patients, and uninfected or early infection (IgM-IgG-) were 4/47 (8.5%) patients. Another study from 35 extrahepatic neonatal cholestasis patients showed that acute infection was 14/35 (40%), past infection was 9/35 (25.7%) and uninfected or early infection was 12/35 (34.3%)⁵. Neonatal cholestasis patients showed that 19/59 (32%) patients were on going infection, 34/59 (57.6%) patients were past infection, and uninfected or early infection was 6/59 patients²². Patients with acute infection appears to have greater liver damage. The infection of HCMV is associated with intrahepatic bile duct destruction and ductal paucity, indicating a possible role in the pathogenesis and progression of extrahepatic BA²⁰.

The presentation of HCMV in liver of cholestasis infants was detected by PCR HCMV from liver biopsy tissues. PCR is a sensitive method for detecting HCMV based on amplification of nucleic acids that usually perform on the conserved regions as target gene²¹. In this study, the researchers used major immediate early and late antigen genes. It showed that 32/47 (68.1%) patients had positive for DNA HCMV in their liver. Another study in cholestasis infants showed that 12/25 (48%) liver DNA was positive for HCMV²² and 16/31 (52%)²⁴. Another study reported the presentations of HCMV DNA in 50 liver specimens from transplant patients with HCMV infection. It was evaluated by immunohistochemistry (IHC) staining and in situ DNA hybridization using DNA-CMV probe. IHC staining uses two anti-CMV antibodies to detect early and late CMV antigens in the nucleus and cytoplasm and CMV antibody to detect nuclear antigen. The positive cytomegalovirus-infected cells using IHC staining and ISH were detected in the livers of patients who had viremia (as measured by viral culture) during life and at autopsy¹⁹. Using IHC and in situ DNA HCMV can detect the presence of HCMV DNA in liver cells, it can directly affect liver cells at real time examination. However, the role of HCMV infection in the liver diseases can be more complex, because

HCMV-induced immune mechanism may affect the liver, even if the virus is no longer demonstrable²². It shows that HCMV can be found in the liver in infected cells.

Most of the patients in this study on EHBA and non-EHBA were infected by HCMV. The results of this study showed 11/18 (61.1%) of the EBA patients and 21/29(72.4%) of the non-EBA patients were infected by HCMV. This showed that HCMV contributed to the development of cholestasis in infants, including EHBA and non-EHBA. This was also in accordance with several previous studies. DNA HCMV was presented in 8/15(53.3%) of EBA patients and 8/16 (50%) non-EHBA patients²⁴, 9/18(50%) of EBA patients and 3/7(42.9 %) non-EHBA patients²², 9/33(27.3%) in the liver of EHBA patients⁵.

Some patients in acute or recent infection of HCMV group based on serological examination showed that it was also positive for HCMV DNA in their liver biopsy specimens. In addition, in the past or not acute infection of HCMV group, it was also still found HCMV DNA in their liver specimens. Another study was also found the same result that DNA HCMV was positive in the liver specimens, not only found in the acute infection patients, but also found in past infection patients^{5,22}. DNA HCMV was detected in the liver specimens of acute and past patients, including the portal hepatitis⁵. HCMV detected by IHC and ISH deposits in the liver tissue in viremia patients¹⁹. The primary infection of HCMV leads to a lifelong latency that is characterized by maintenance of the viral genome without active infectious virus production. The latent human HCMV genome is distributed at low copy numbers that DNA HCMV is still detectable in the past infection patients²⁵.

In this study, 12 patients presented positive for anti-HCMV serology in their serum (6 patients with IgM+IgG+ and 6 patients with IgM-IgG +), but negative for HCMV DNA in the liver biopsy. PCR analysis of the β -globin gene in these patients showed a strong positive so that it showed that the specimen was sufficiently qualified for the study. In this case, patients with IgM+IgG-, might be because the viral load is low, therefore, HCMV DNA was not detected in the liver tissue. The new born IgG is obtained maternally from the mother, whereas IgM is still in the learning process to synthesize slowly¹, so serological examination of IgM and IgG anti-HCMV in the first week of the new born still cannot reflect the condition HCMV infection in infants. Another factor to be considered in patients with positive IgM serology and negative PCR is the cross-reaction examination with other herpesviruses⁵.

Some patients with positive for PCR HCMV DNA were negative for anti-HCMV antibodies. In this study, one patient that showed positive for DNA HCMV in the liver biopsy, but not presented IgM and or IgG in the serum. The data showed that the patient had a diagnosis of non-extrahepatic biliary atresia and was 2 months old. This result was also the same as others, like in Korea showing that a few young patients under 3 months old had negative for the anti-HCMV IgM but positive for PCR HCMV DNA³. In Brazil, it showed that there were 3 patients with positive PCR DNA HCMV but negative for serology of HCMV⁵. Newborn children have a low ability to produce IgM or IgG. Young infants have immature immune systems, which may fail to produce antibodies during acute infection, so that anti-HCMV IgM has presented negative results³ or the patient in the early stages of HCMV infection, therefore anti-HCMV IgM had not been produced²³.

There were 3 patients who serologic and HCMV PCR results were equally negative but showed symptoms of cholestasis. The results of the data search showed that 2 patients had a diagnosis of non-extrahepatic biliary atresia and 1 patient with a diagnosis of extrahepatic biliary atresia. This may be due to any of these causes, including α 1-antitrypsin deficiency (AATD), viral infections and genetic cholestatic disorders, such as Alagille's syndrome and various types of progressive familial intrahepatic cholestasis (PFIC)² that progress to extrahepatic biliary atresia or non-extrahepatic biliary atresia.

This study showed that there was no association between serological anti-HCMV and PCR HCMV liver with histopathological diagnosis and between serological anti-HCMV and PCR HCMV liver, while in our previous study showed association between serological anti-HCMV and PCR HCMV from urine specimens²⁶. Other studies also shown that no correlation between HCMV positivity by PCR and the histological findings⁵. The accuracy of serology for detecting HCMV antibodies is low⁵. Other studies examining the correlation between severity of cholestasis, the degree of liver damage, and the presence of the virus in the liver tissue, showed that there was no correlation between the degree of cholestasis and CMV infection. Correlation between serology and virus detection in the liver is poor¹⁷. This indicates that serological examination and PCR HCMV liver cannot be used to determine the type of cholestasis, neither EBA nor non-EBA.

CONCLUSION:

Most of cholestasis patients in this study were seropositive anti-HCMV IgG, with acute or past infections of HCMV. HCMV DNA is detected in more than 50% of liver biopsy tissue. Some patients in recent

or past infection showed positive for HCMV DNA in the liver tissues, but conversely some patients who were negative for HCMV DNA in the liver tissues showed positive serology anti-HCMV in the sera. PCR HCMV DNA in the liver tissues indicates the presentation of HCMV, inactivity or latent infection status. It suggests that PCR can be used as routine tools to detect the presentation of HCMV DNA. Type of cholestasis infants, both EBA and non-EBA, cannot be determined based on the serological and PCR examination, but based on histopathological feature.

ACKNOWLEDGEMENT:


We thank to the Government of the Republic of Indonesia, the Ministry of Research, Technology, and Higher Education, in particular the Faculty of Medicine, Airlangga University for financial support and all the patients who are willing to participate in this study.

CONFLICT OF INTEREST:

We declare no conflict of interest.

REFERENCES:

- Mack CL. What causes biliary atresia? Unique aspects of the neonatal immune system provide clues to disease pathogenesis. *Cellular Molecular Gastroenterology and Hepatology*. 2015; 1(3):267-74. <https://doi.org/10.1016/j.jcmgh.2015.04.001>
- Fischler B, Lamireau T. Cholestasis in the newborn and infant. *Clinics and Research in Hepatology and Gastroenterology*. 2014; 38(3): 263-7. <https://doi.org/10.1016/j.clinre.2014.03.010>
- Min CY, Song JY, Jeong SJ. Characteristics and prognosis of hepatic cytomegalovirus infection in children: 10 years of experience at a university hospital in Korea. *Korean Journal of Pediatrics*. 2017; 60(8):261. <https://doi.org/10.3345/kjp.2017.60.8.261>
- Tanimura K, Yamada H. Potential biomarkers for predicting congenital cytomegalovirus infection. *International Journal of Molecular Sciences*. 2018; 19(12):3760. <https://doi.org/10.3390/ijms19123760>
- De Tommaso AM, Andrade PD, Costa SC, Escanhoela CA, Hessel G. High frequency of human cytomegalovirus DNA in the liver of infants with extrahepatic neonatal cholestasis. *BMC Infectious Disease*. 2005; 5(1):1-8. <https://doi.org/10.1186/1471-2334-5-108>.
- Feldman AG, Sokol RJ. Neonatal cholestasis. *Neoreviews*. 2013; 14(2):e63-73. <https://doi.org/10.1542/neo.14-2-e63>
- Davis AR, Rosenthal P, Escobar GJ, Newman TB. Interpreting conjugated bilirubin levels in newborns. *The Journal of Pediatrics*. 2011; 158(4): 562-5. <https://doi.org/10.1016/j.jpeds.2010.09.061>
- Rashed YK, Saber MA, Tawfik M, Mourad WS. Histopathological features and accuracy for diagnosing biliary atresia by prelaparotomy liver biopsy in Egypt. *Egyptian Pediatric Association Gazette*. 2013; 61(1): 42-5. <https://doi.org/10.1016/j.epag.2013.05.001>
- Stehel EK, Sánchez PJ. Cytomegalovirus infection in the fetus and neonate. *Neoreviews*. 2005; 6(1):e38-45. <https://doi.org/10.1542/neo.6-1-e38>.
- Soetens O, Vauloup-Fellous C, Foulon I, Dubreuil P, De Saeger B, Grangeot-Keros L, Naessens A. Evaluation of different cytomegalovirus (CMV) DNA PCR protocols for analysis of dried blood spots from consecutive cases of neonates with congenital CMV infections. *Journal of Clinical Microbiology*. 2008; 46(3):943-6. <https://doi.org/10.1128/JCM.01391-07>.
- Goegebuer T, Van Meensel B, Beuselinck K, Cossey V, Van Ranst M, Hanssens M, Lagrou K. Clinical predictive value of real-time PCR quantification of human cytomegalovirus DNA in amniotic fluid samples. *Journal of Clinical Microbiology*. 2009; 47(3):660-5. <https://doi.org/10.1128/JCM.01576-08>.
- Suchy FJ. Neonatal cholestasis. *Pediatrics in Review*. 2004; 25(11): 388-96. <https://doi.org/10.1542/pir.25-11-388>
- Zagory JA, Nguyen MV, Wang KS. Recent advances in the

- pathogenesis and management of biliary atresia. *Current Opinion in Pediatrics*. 2015; 27(3):389. <https://doi.org/10.1097/MOP.0000000000000214>
- Rastogi A, Krishnani N, Yachha SK, Khanna V, Poddar U, Lal R. Histopathological features and accuracy for diagnosing biliary atresia by prelaparotomy liver biopsy in developing countries. *Journal of Gastroenterology and Hepatology*. 2009; 24(1):97-102. <https://doi.org/10.1111/j.1440-1746.2008.05737.x>.
- Poddar U, Thapa BR, Das A, Bhattacharya A, Rao KL, Singh K. Neonatal cholestasis: differentiation of biliary atresia from neonatal hepatitis in a developing country. *Acta Paediatrica*. 2009; 98(8):1260-4. <https://doi.org/10.1111/j.1651-2227.2009.01338.x>
- Oliviera NL, Kanawaty FR, Costa S, Hessel G. Infection by cytomegalovirus in patients with neonatal cholestasis. *Arquivos de Gastroenterologia*. 2002; 39(2): 132-6. <https://doi.org/10.1590/s0004-28032002000200012>
- Pawlowska J, Swiatkowska E, Gliwicz D, Jankowska I, Kluge P, Cukrawska B, Dzierzanowski-Fangrat K. The role of cytomegalovirus infection in pathogenesis of neonatal cholestasis. *Experimental & Clinical Hepatology*. 2010; 6(1):25-9.
- Russo P, Magee JC, Anders RA, Bove KE, Chung C, Cummings OW, Finegold MJ, Finn LS, et al. Childhood Liver Disease Research Network (ChiLDRen). Key Histopathologic Features of Liver Biopsies That Distinguish Biliary Atresia from Other Causes of Infantile Cholestasis and Their Correlation with Outcome: A Multicenter Study. *The American Journal of Surgical Pathology*. 2016 Dec;40(12):1601-1615. <https://doi.org/10.1097/PAS.0000000000000755>.
- McDonald GB, Sarmiento JI, Rees-Lui G, Myerson D. Cytomegalovirus hepatitis after bone marrow transplantation: An autopsy study with clinical, histologic and laboratory correlates. *Journal of Viral Hepatitis*. 2019; 26(11):1344-1350. <https://doi.org/10.1111/jvh.13176>
- Moore SW, Zabiegaj-Zwick C, Nel E. Problems related to CMV infection and biliary atresia. *South African Medical Journal*. 2012; 102(11):890-2. <https://doi.org/10.7196/samj.6163>
- Ross SA, Novak Z, Pati S, Boppana SB. Diagnosis of Cytomegalovirus Infections. *Infectious Disorders Drug Targets*. 2011; 11(5): 466-74. <https://doi.org/10.2174/187152611797636703>
- Fischler B, Ehrnst A, Forsgren M, Orvell C, Nemeth A. The viral association of neonatal cholestasis in Sweden: a possible link between cytomegalovirus infection and extrahepatic biliary atresia. *Journal of Pediatric Gastroenterology and Nutrition*. 1998; 27(1): 57-64. <https://doi.org/10.1097/00005176-199807000-00010>
- Sira MM, Sira AM, Elhenawy IA, Khalil FO. Prevalence of serological markers of TORCH infections in biliary atresia and other neonatal cholestatic disorders. *Open Journal of Pediatric and Child Health*. 2016; 2(1):013-7. <https://doi.org/10.17352/2640-7612.000010>
- Goel A, Chaudhari S, Sutar J, Bhone G, Bhatnagar S, Patel V, Bhor V, Shah I. Detection of Cytomegalovirus in Liver Tissue by Polymerase Chain Reaction in Infants with Neonatal Cholestasis. *Pediatric Infectious Disease Journal*. 2018; 37(7): 632-6. <https://doi.org/10.1097/INF.0000000000001889>
- Slobedman B, Mocarski ES. Quantitative analysis of latent human cytomegalovirus. *Journal of Virology*. 1999; 73(6):4806-12. <https://doi.org/10.1128/JVI.73.6.4806-4812.1999>
- Mastutik G, Kurniasari N, Rahniayu A, Rahaju AN, Ruslan SEN, Ilmiah K, Setyoboedi B, Sulistyani E. Detection of cytomegalovirus in urine specimen of cholestasis infants by polymerase chain reaction. *Research Journal of Pharmacy and Technology*. 2022; 15(4) 

ISSN 0974-3618 (Print)
0974-360X (Online)

www.rjptonline.org

RESEARCH ARTICLE

Presentation of Human Cytomegalovirus (HCMV) in Liver Tissues of Cholestatic Infants with Extrahepatic and Non-Extrahepatic Biliary Atresia

Alphania Rahniayu^{1,2}, Gondo Mastutik^{1*}, Willy Sandhika^{1,2}, S. Eriaty N. Ruslan³,
Anny Setijo Rahaju^{1,2}, Bagus Setyo boedi^{4,5}, Erna Sulistyani⁶

¹Department of Anatomic Pathology, Faculty of Medicine, Universitas Airlangga, Surabaya-60132, Indonesia

²Department of Anatomic Pathology, Dr. Soetomo General Academic Hospital, Surabaya-60132, Indonesia

³Institute of Tropical Diseases, Universitas Airlangga, Surabaya-60132, Indonesia

⁴Department of Child Health of Pediatric, Faculty of Medicine, Universitas Airlangga, Surabaya-60132, Indonesia

⁵Department of Child Health of Pediatric, Dr. Soetomo General Academic Hospital, Surabaya-60132, Indonesia

⁶Department of Oral Medicine, Faculty Dentistry, Jember University, Jember-68121, Indonesia

*Corresponding Author E-mail: gondomastutik@fk.unair.ac.id, gondomastutik@gmail.com

ABSTRACT:

Introduction: Human cytomegalovirus (HCMV) is associated with cholestasis in infants. Diagnosis of HCMV infection is most often based on serological anti-HCMV. Identification of HCMV in liver tissue has been rarely reported. The aims of this study were to determine the presentation of HCMV in liver tissues and to analyze its association with serological anti-HCMV of cholestatic infants with extrahepatic and non-extrahepatic biliary atresia. **Methods:** This observational study was performed during December 2017- December 2018 with ethics from our institutions. The parents or guardians of subjects signed the informed consent. The researchers collected the serological anti-HCMV data. Histopathological diagnosis and polymerase chain reaction (PCR) for HCMV were performed from liver biopsy tissues. The data were analyzed by Chi-square. **Results:** There were 47 cholestatic infants, 38.3% EBA and 61.7% non-EBA. Anti-HCMV IgM was positive in 38.3% patients and IgG was positive in 91.5% patients. Acute infection or recent infection were 38.3%, past or not acute infection were 53.1%, and uninfected or early infection were 8.5% patients. The presentation of HCMV in liver tissues was 68.1% patients, consisting of 11/18 EBA and 21/29 non-EBA and negative in 31.9% patients, consisting of 7/18 EBA and 8/29 non-EBA. There was no association between serological anti-HCMV and PCR HCMV with histopathological features. **Conclusion:** It suggests that PCR can be used as a routine tool to detect the presentation of HCMV DNA in liver tissue. Type of cholestasis in infants, both EBA and non-EBA, cannot be determined based on the serological and PCR examination, but based on histopathological features.

KEYWORDS: Human cytomegalovirus, cholestatic infants, liver biopsy, extrahepatic biliary atresia, non-extrahepatic biliary atresia.

INTRODUCTION:

Human cytomegalovirus (HCMV) is the most common viral infection causing neonatal cholestasis and the most frequent congenital virus infection worldwide^{1,2}. HCMV infects 30,000 to 40,000 infants each year in the United States³.

Infants can acquire CMV infection from their mother through intrauterine infection (congenital infection), through contact with infected genital secretions during passage through the birth canal (perinatal infection), or postpartum through breastfeeding (postnatal infection)³. Approximately 10-15% newborns show symptomatic congenital infection with the clinical manifestation including fetal growth restriction, low birth weight, and cerebral and multiple organs involvement and 85-90% is asymptomatic^{3,4}. Approximately 10-15% of newborns with asymptomatic CMV infection develop long-term sequel, for example, progressive sensorineural

hearing difficulty and psychomotor retardation⁴. Therefore, it is very important to be able to diagnose of HCMV infection early, so that it can provide the appropriate interventions to reduce the sequelae of infection.

The most common diagnosis of HCMV infection is serological examination, namely anti-HCMV immunoglobulin M (IgM) and anti-HCMV immunoglobulin G (IgG). IgM is formed 2-4 weeks after infection, persists and decreases rapidly within 2-4 months, and then is undetectable within 12 months and IgG is formed⁵. However, in newborns, the ability to synthesize IgM and IgG is still low. IgG for newborns is obtained maternally from the mother, while IgM is still in the learning process to synthesize slowly¹ so that the serological examination of IgM and IgG anti-HCMV in the first week of a baby is still unable to reflect the condition of HCMV infection in infants. Furthermore, laboratory tests of cholestasis have shown an increase in conjugated bilirubin, which is a conjugated bilirubin level of more than 20% of the total bilirubin level if the total bilirubin level is >5mg/dl or the direct bilirubin level is more than 2mg/dl if the total bilirubin is <5 mg/dl⁶⁻⁸ but this examination only shows the condition of cholestasis without knowing the main cause of diseases. In addition, HCMV can be isolated by PCR examination of body tissues and body fluids such as tears, salivary glands, breast milk, urine, feces, semen, cervical secretions, amniotic fluid, blood, and organ transplants⁹⁻¹¹ that might be performed to explain the main cause of cholestasis.

Neonatal cholestasis is often classified as either extrahepatic or intrahepatic in origin. Extrahepatic is most known as biliary atresia and intrahepatic known as neonatal hepatitis. Biliary atresia is a decrease or obstruction of the hepatic or bile ducts at any point from the porta hepatis to the duodenum with an ongoing intrahepatic bile duct damage². Based on the histopathological features, there are two type of cholestasis, namely extrahepatic biliary atresia (EBA) and non-EBA. The histopathological features of the liver biopsy in biliary atresia are biliary duct proliferation, bile plugs, portal tract fibrosis and edema, whereas in non-biliary atresia are showing feature of viral hepatitis, such as human cytomegalovirus (HCMV) or herpes simplex, and changes thought to be due to metabolic disease¹². The time of diagnosis is a critical time for disease intervention because biliary atresia rapidly leads to the liver to cirrhosis¹³. Percutaneous liver biopsy has a high accuracy (88.2%) for diagnosing biliary atresia¹⁴ and is the best method to differentiate biliary atresia and non-biliary atresia¹⁵.

The objective was to determine the presentation of HCMV DNA in the liver biopsy tissues and to analyze

its association with serological anti-HCMV in cholestasis infants and histological features, both EBA and non-EBA. The results of this study are expected to be used as a theoretical basis for using PCR examination as a routine procedure to diagnose HCMV infection in cholestatic infants.

MATERIALS AND METHODS:

Sample Collections:

This research was a descriptive observational study with a cross-sectional approach at the Inpatient Clinic, Department of Pediatric, Dr. Soetomo General Academic Hospital, Surabaya, Indonesia, during December 2017-December 2018. This study has obtained ethics from the Health Research Ethics Commission, Dr. Soetomo General Academic Hospital, Surabaya, number 729/Panke.KKE/XII/ 2017. Subjects who took part in this study were required to obtain the parental or guardian consent by signing a written informed consent after receiving an informed consent explanation.

The sample was liver biopsy tissues obtained from cholestatic infants who showed symptoms of jaundice with conjugated bilirubin levels 20% of total bilirubin levels, if total bilirubin is ≥ 5 mg/dL or direct bilirubin levels >2 mg/dL if total bilirubin <5 mg/dL. Inclusion criteria was aged 1-12 months. Exclusion criteria were patients who had received antiviral therapy, HIV patients, miliary tuberculosis patients, malnourished patients, history of use of immunosuppressive drugs such as corticosteroids and cytostatics, platelets $<80,000$ mg/dl, prolonged hemostasis physiology, and ascites.

Histopathological Diagnosis:

The histopathological diagnosis of liver biopsy tissues was performed by two pathologists based on microscopic features in Hematoxylin Eosin and Masson Trichrome staining. The histopathological diagnosis consisted of extrahepatic biliary atresia and non-extrahepatic biliary atresia.

Detection Infection HCMV:

Serological examination of HCMV infection was performed by measuring IgM and IgG levels using The VIDAS CMV IgM and IgG Assay (Biomérieux). IgM interpretation is the IgM index unit <0.7 is negative, $<0.7 - 0.9$ is equivocal, > 0.9 is positive. IgG interpretation is the IgG index unit <4 is negative, $> 4 - <6$ is equivocal, > 6 is positive. This data were secondary data from patient medical record.

Detection of HCMV DNA in liver tissues were performed by nested polymerase chain reaction (PCR) using MIE4/MIE5 primers for the first round and IE1/IE2 primers for the second round (Table 1)⁵. DNA was extracted from the liver biopsy using QIAamp DNA

Mini Kit (Qiagen) and used for PCR. First, PCR was conducted for the β -globin gene using PCO3 + and PCO4 + primers⁵ (Table 1) and secondly for HCMV. The master mix used PCR Master Mix (Promega), namely a reaction mix composed by 10 μ l master mix (Promega), 1 μ l forward primer (PCO3 +) 10 pmol, 1 μ l reverse primer (PCO4 +) 10 pmol, 5 μ l ddH₂O (water), and 3 μ l DNA template. PCR conditions were pre-denaturation 94°C, 5 minutes for one cycle, denaturation 94°C for 30 seconds, annealing 55°C for 30 seconds, extension 72°C for 45 seconds, all for 40 cycles, then the final extension was 72°C for 7 minutes. Electrophoresis of PCR beta globin gene products showed a band of 110 base pair (bp). Samples with positive results for the beta globin gene will be followed by PCR HCMV.

The PCR master mix (Promega) for identification HCMV at the first round was 10 μ l master mix PCR, 1 μ l the 10 pmol MIE4 primer, 1 μ l the 10pmol MIE5 primer, 4 μ l ddH₂O, and 4 μ l DNA template. The PCR conditions were pre-denaturation 94°C for 5 minutes, denaturation 94°C for 30 seconds, annealing 55°C for 30 seconds, extension 72°C for 45 seconds for 40 cycles. The final extension was 72°C for 7 minutes. For the second round, the PCR conditions were the same as the first round PCR, but the template was 1 μ l of the first round PCR product and PCR was performed by IE1/IE2 primers. PCR results were electrophoresed on 2% acrylamide gel and documented.

Table 1. Oligonucleotide primers for PCR amplification of HCMV

Primer Name	Position	Sequence	Product (base pair)
PCO3+	Forward	5'-CCT CTG ACA CAA CTG TGT TCA CTA GC-3'	110 bp
PCO4+	Reverse	5'-TCA CCA CCA ACT TCA TCC ACG TTC ACC-3'	
MIE4	Forward	5'-CCA AGC GGC CTC TGA TAA CCA AGC C-3'	435 bp
MIE5	Reverse	5'-CAG CAC CAT CCT CCT CTT CCT CTG G-3'	
IE1	Forward	5'- CCA CCC GTG GTG CCA GCT CC-3'	161 bp
IE2	Reverse	5'-CCC GCT CCT CCT GAG GAC CC-3'	

Statistical analysis:

The association between the serological examinations of HCMV with PCR examination of liver biopsy tissue from infants with cholestasis was done by Chi-square, if significantly different, the strength of the relationship was known by contingency coefficient

RESULT:

Samples were 47 infants with cholestasis symptoms, consisting of 27 boys and 20 girls, aged between 1-12

months (mean \pm SD = 3.28 \pm 2.214). Patients consisted of 39 patients aged under 4 months and 8 patients aged over 5 months. The direct/conjugated bilirubin (D Bil) level was 7.9430 \pm 4.13824 (mean \pm SD) and the total bilirubin (T Bil) was 11.0828 \pm 5.50279 (mean \pm SD) (Table 2).

Histopathological diagnosis of liver biopsy tissue from infants with cholestasis showed that there were 29 (61.7%) non-extrahepatic biliary atresia patients and 18 (38.3%) extrahepatic biliary atresia patients (Table 3, Figure 1).

Serological examination showed that anti-HCMV IgM was positive in 18/47(38.3%) patients and anti-HCMV IgG was positive in 43/47(91.5%) patients, including 17 EBA and 26 non-EBA. In the IgM+ and IgG+ groups (acute or recent infection of HCMV groups), there were 18(38.3%) patients consisting of 10/18 the EBA patients and 8/18 the non-EBA patients. In the IgM- and IgG + groups (past or not acute infection of HCMV groups), there were 25(53.2%) patients consisting of 7/25 the EBA patients and 18/25 the non-EBA patients. In the IgM- and IgG- group (uninfected or early infection of HCMV), there were 4 (8.5%) patients (Table 3, 4, Figure 2).

Table 2. Characterization of patients

Age (mean \pm SD)	3,28 \pm 2,214
Age (n / %)	
1-2 month	23/ 48.9
3-4 month	16 / 34.1
5-6 month	4 / 8.5
>6 month	4 / 8.5
Sex	
Male (n / %)	27/57.4
Female (n / %)	20/42.6
D Bil (mean \pm SD)	7.9430 \pm 4.13824
T Bil (mean \pm SD)	11.0828 \pm 5.50279

D Bil = the direct / conjugated bilirubin level, T Bil = total bilirubin level

Table 3. The histopathological diagnosis, serological examination, and HCMV PCR in cholestatic infants

		n	Percentage
Histopathological diagnosis	Extrahepatic biliary atresia	18	38,3%
	Non-extrahepatic biliary atresia	29	61,7%
Serological examination	IgM+	18	38,3%
	IgG+	43	91,5%
	IgM+, IgG+ (recent or past/recurrent infection)	18	38,3%
	IgM-, IgG+ (past infection)	25	53,2%
	IgM-, IgG- (uninfected or early infected)	4	8,5%
PCR HCMV	Positive	32	68,1%
	Negative	15	31,9%

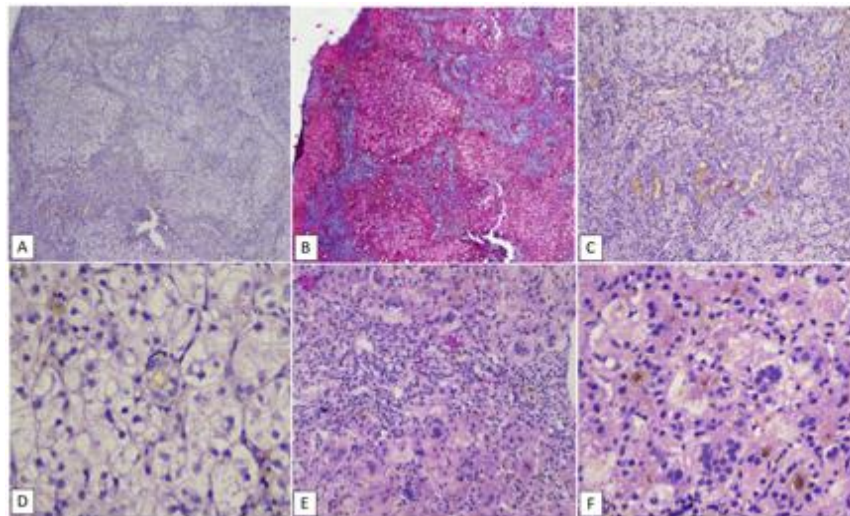


Figure 1. Histopathological features of extrahepatic biliary atresia and non-extrahepatic biliary atresia. (A) Disrupted hepatic parenchymal architecture in EBA (HE, 40x), (B) Biliary cirrhosis in EBA (MT, 40x), (C) Bile ductular proliferation containing bile plug in widened portal area displayed in EBA (HE, 100x), (D) Dilated canaliculi containing bile pigment and ballooning degeneration of hepatocytes documented in EBA (HE, 400x), (E), (F) Numerous multinucleated giant cell hepatocytes accompanied with lobular inflammation in Non-EBA (HE, 200x and 400x). MT: Masson Trichrome, HE: Hematoxylin Eosin.

HCMV DNA was detected in liver biopsy specimens from 32 of 47 (68.1%) (Table 4, Figure 2) that consisted of 11/18 (61.1%) EBA patients and 21/29 (72.4%) non-EBA patients. In 11 EHBA patients with the HCMV DNA positive in their liver showed that 7 patients had anti-HCMV IgM and IgG in their sera and the rest showed anti-HCMV IgG in their sera. The 21 non-EHBA patients with the HCMV DNA positive in their liver showed that 5 patients had positive for anti-HCMV IgM and IgG, 15 had positive for anti HCMV IgG, and 1 patient had negative for anti-HCMV IgM and IgG (Table 4, Figure 2).

HCMV DNA was not detected in liver biopsies specimens from 15 of 47 (31.9%) patients that consisted of 7/15 (46.7%) EBA patients and 8/29 (53.3%) non-EBA patients. In 7 EHBA patients with the HCMV DNA negative in their liver showed that 3 patients had anti-HCMV IgM and IgG in their sera and 3 had positive for anti HCMV IgG, and 1 patient had negative for anti-HCMV IgM and IgG. In 8 non-EHBA patients with the HCMV DNA negative in their liver showed that 3 patients had anti-HCMV IgM and IgG in their sera and 3 had positive for anti HCMV IgG, and 2 patients had negative for anti-HCMV IgM and IgG (Table 4, Figure 2).

There was no association between serological anti-HCMV and PCR HCMV liver with histopathological diagnosis, neither EBA nor non-EBA ($p=0.151$, $p=0.627$) (Table 4). There was no association between serological anti-HCMV with PCR HCMV liver specimens in cholestatic infants ($p=0.106$) (Table 5).

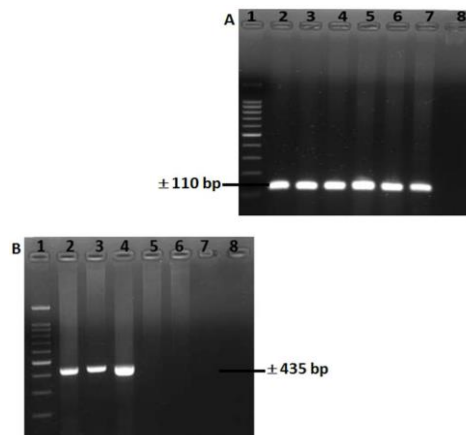


Figure 2. PCR β -globin with the oligonucleotide primer PCO3+/PCO4+ (A) and HCMV with the oligonucleotide primer MIE4/MIE5 (B) from the liver tissue of cholestatic infant. (A) lane 1 = marker, lane 2, 3, 4, 5, 6, 7 = specimens showed positive (± 110 bp), lane 8 = positive control. (B) lane 1 = M, lane 2, 3, 4 = specimens showed positive (± 435 bp), lane 5, 6, 7 = specimens showed negative, lane 8 = positive control.

Table 4. Association of HCMV infections based on the results of serological examination and PCR from liver tissues in extrahepatic biliary atresia and non-extrahepatic biliary atresia

	EBA	Non-EBA	Total	P value
Serology				0.151
IgM+ IgG+	10	8	18	
IgM- IgG+	7	18	25	
IgM- IgG-	1	3	4	
Total	18	29	47	
PCR				0.627
Positive	11	21	32	
Negative	7	8	15	
Total	18	29	47	

Note: EBA = extrahepatic biliary atresia, non-EBA = non-extrahepatic biliary atresia

Table 5. Association between HCMV identification by serological anti-HCMV and PCR HCMV

Serology anti-HCMV	The PCR HCMV of Liver						Total	p value
	Positive			Negative				
	EBA	Non-EBA	Total	EBA	Non-EBA	Total		
IgM+, IgG+	7	5	12	3	3	6	18	0.106
IgM-, IgG+	4	15	19	3	3	6	25	
IgM-, IgG-	0	1	1	1	2	3	4	
Total	11	21	32	7	8	15	47	

Note: EBA = extrahepatic biliary atresia, non-EBA = non-extrahepatic biliary atresia

DISCUSSION:

Neonatal cholestatic syndrome may be a result of intrahepatic alterations caused by metabolic, toxic medication, hereditary, anatomic, and idiopathic infections. It is also the result of extrahepatic alterations caused by extrahepatic biliary atresia (EBA) and choledochal cysts. EBA is the final result of a destructive inflammatory process that affects the intrahepatic and extrahepatic biliary ducts leading to fibrosis and obliteration of the biliary tract at some point between the porta hepatis and the duodenum¹⁶. Histological assessment of the liver tissue from cholestatic patients revealed mainly mixed lymphocytic/granulocytic inflammatory infiltrations, giant cell transformation and fibrosis¹⁷. This study was conducted on the liver biopsy specimens from infants with cholestasis. All specimens diagnosed as EBA and non-EBA based on histopathological appearance, 18/47(38.3%) patients referred as EBA, and 29/47(61.7%) patients referred as non-EBA. The microscopic features of EBA are ductular reaction, ductular cholestasis, portal edema, and fibrosis¹⁸. Some of liver cells infected with HCMV showed the intranuclear and intracytoplasmic inclusions bodies and inflammatory cell aggregates¹⁹. Microscopic feature other than those characteristics are categorized as non-EBA¹⁸. It is also associated with intrahepatic bile duct destruction and ductal paucity, indicating a possible role in the pathogenesis and progression of extrahepatic BA²⁰.

Human CMV is associated with cholestasis in infants. Diagnosis of HCMV infection is most often based on serological anti-HCMV. Serological examination is used to detect the specific reaction of antigen and antibody. HCMV serological examination is intended to detect the presence of anti-CMV specific antibodies in the serum²¹. In this study, 18/47 (38.3%) patients were positive for anti-HCMV IgM and 43/47 (91.5%) patients were positive for anti-HCMV IgG. Other studies showed that anti-HCMV IgM was positive in 13/31 (42%) patients, anti-HCMV IgG was positive in 26/31 (84%) patients²⁴. IgM positive for CMV in neonatal cholestasis in Sweden was 19/59 (32.2%), IgG positive was 53/59 (90%), IgM-

and IgG- was in 6/59 infants²². Neonatal cholestasis in Egypt, IgM CMV was positive in 23/185 (12.4%), that consisted of 4/94 (4.3%) in EHBA and 19/91 (20.9%) in non-EHBA²³.

Serological tests are also very useful to determine whether a patient has had CMV infection in the past, by evaluating anti-HCMV IgG. Detection of IgM antibodies is used as an indicator of acute infection or new infection²¹. The interpretation of acute or recent infection is if anti-HCMV IgM and IgG are positive (IgM+ IgG+), past or not acute infection is if IgM is negative and IgG is positive (IgM- IgG+), and uninfected or to early infected is if IgM and IgG are negative (IgM- IgG-)¹. In this study, acute or recent infection (IgM+ IgG+) were 18/47 (38.3%) patients, past or not acute infection (IgM- IgG+) were 25/47 (53.1%) patients, and uninfected or early infection (IgM-IgG-) were 4/47 (8.5%) patients. Another study from 35 extrahepatic neonatal cholestasis patients showed that acute infection was 14/35 (40%), past infection was 9/35 (25.7%) and uninfected or early infection was 12/35 (34.3%)⁵. Neonatal cholestasis patients showed that 19/59 (32%) patients were on going infection, 34/59 (57.6%) patients were past infection, and uninfected or early infection was 6/59 patients²². Patients with acute infection appears to have greater liver damage. The infection of HCMV is associated with intrahepatic bile duct destruction and ductal paucity, indicating a possible role in the pathogenesis and progression of extrahepatic BA²⁰.

The presentation of HCMV in liver of cholestasis infants was detected by PCR HCMV from liver biopsy tissues. PCR is a sensitive method for detecting HCMV based on amplification of nucleic acids that usually perform on the conserved regions as target gene²¹. In this study, the researchers used major immediate early and late antigen genes. It showed that 32/47 (68.1%) patients had positive for DNA HCMV in their liver. Another study in cholestasis infants showed that 12/25 (48%) liver DNA was positive for HCMV²² and 16/31 (52%)²⁴. Another study reported the presentations of HCMV DNA in 50 liver specimens from transplant patients with HCMV infection. It was evaluated by immunohistochemistry (IHC) staining and in situ DNA hybridization using DNA-CMV probe. IHC staining uses two anti-CMV antibodies to detect early and late CMV antigens in the nucleus and cytoplasm and CMV antibody to detect nuclear antigen. The positive cytomegalovirus-infected cells using IHC staining and ISH were detected in the livers of patients who had viremia (as measured by viral culture) during life and at autopsy¹⁹. Using IHC and in situ DNA HCMV can detect the presence of HCMV DNA in liver cells, it can directly affect liver cells at real time examination. However, the role of HCMV infection in the liver diseases can be more complex, because

HCMV-induced immune mechanism may affect the liver, even if the virus is no longer demonstrable²². It shows that HCMV can be found in the liver in infected cells.

Most of the patients in this study on EHBA and non-EHBA were infected by HCMV. The results of this study showed 11/18 (61.1%) of the EBA patients and 21/29(72.4%) of the non-EBA patients were infected by HCMV. This showed that HCMV contributed to the development of cholestasis in infants, including EHBA and non-EHBA. This was also in accordance with several previous studies. DNA HCMV was presented in 8/15(53.3%) EHBA patients and 8/16 (50%) non-EHBA patients²⁴, 9/18(50%) EHBA patients and 3/7(42.9 %) non-EHBA patients²², and 9/33(27.3%) in the liver of EHBA patients⁵.

Some patients in acute or recent infection of HCMV group based on serological examination showed that it was also positive for HCMV DNA in their liver biopsy specimens. In addition, in the past or not acute infection of HCMV group, it was also still found HCMV DNA in their liver specimens. Another study was also found the same result that DNA HCMV was positive in the liver specimens, not only found in the acute infection patients, but also found in past infection patients^{5,22}. DNA HCMV was detected in the liver specimens of acute and past patients, including the portal hepatitis⁵. HCMV detected by IHC and ISH deposits in the liver tissue in viremia patients¹⁹. The primary infection of HCMV leads to a lifelong latency that is characterized by maintenance of the viral genome without active infectious virus production. The latent human HCMV genome is distributed at low copy numbers that DNA HCMV is still detectable in the past infection patients²⁵.

In this study, 12 patients presented positive for anti-HCMV serology in their serum (6 patients with IgM+IgG+ and 6 patients with IgM-IgG +), but negative for HCMV DNA in the liver biopsy. PCR analysis of the β -globin gene in these patients showed a strong positive so that it showed that the specimen was sufficiently qualified for the study. In this case, patients with IgM+IgG-, might be because the viral load is low, therefore, HCMV DNA was not detected in the liver tissue. The new born IgG is obtained maternally from the mother, whereas IgM is still in the learning process to synthesize slowly¹, so serological examination of IgM and IgG anti-HCMV in the first week of the new born still cannot reflect the condition HCMV infection in infants. Another factor to be considered in patients with positive IgM serology and negative PCR is the cross-reaction examination with other herpesviruses⁵.

Some patients with positive for PCR HCMV DNA were negative for anti-HCMV antibodies. In this study, one patient that showed positive for DNA HCMV in the liver biopsy, but not presented IgM and or IgG in the serum. The data showed that the patient had a diagnosis of non-extrahepatic biliary atresia and was 2 months old. This result was also the same as others, like in Korea showing that a few young patients under 3 months old had negative for the anti-HCMV IgM but positive for PCR HCMV DNA³. In Brazil, it showed that there were 3 patients with positive PCR DNA HCMV but negative for serology of HCMV⁵. Newborn children have a low ability to produce IgM or IgG. Young infants have immature immune systems, which may fail to produce antibodies during acute infection, so that anti-HCMV IgM has presented negative results³ or the patient in the early stages of HCMV infection, therefore anti-HCMV IgM had not been produced²³.

There were 3 patients who serologic and HCMV PCR results were equally negative but showed symptoms of cholestasis. The results of the data search showed that 2 patients had a diagnosis of non-extrahepatic biliary atresia and 1 patient with a diagnosis of extrahepatic biliary atresia. This may be due to any of these causes, including α 1-antitrypsin deficiency (AATD), viral infections and genetic cholestatic disorders, such as Alagille's syndrome and various types of progressive familial intrahepatic cholestasis (PFIC)² that progress to extrahepatic biliary atresia or non-extrahepatic biliary atresia.

This study showed that there was no association between serological anti-HCMV and PCR HCMV liver with histopathological diagnosis and between serological anti-HCMV and PCR HCMV liver, while in our previous study showed association between serological anti-HCMV and PCR HCMV from urine specimens²⁶. Other studies also shown that no correlation between HCMV positivity by PCR and the histological findings⁵. The accuracy of serology for detecting HCMV antibodies is low⁵. Other studies examining the correlation between severity of cholestasis, the degree of liver damage, and the presence of the virus in the liver tissue, showed that there was no correlation between the degree of cholestasis and CMV infection. Correlation between serology and virus detection in the liver is poor¹⁷. This indicates that serological examination and PCR HCMV liver cannot be used to determine the type of cholestasis, neither EBA nor non-EBA.

CONCLUSION:

Most of cholestasis patients in this study were seropositive anti-HCMV IgG, with acute or past infections of HCMV. HCMV DNA is detected in more than 50% of liver biopsy tissue. Some patients in recent

Menjawab comments reviewer

Research J. Pharm. and Tech. 15(6): June 2022

or past infection showed positive for HCMV DNA in the liver tissues, but conversely some patients who were negative for HCMV DNA in the liver tissues showed positive serology anti-HCMV in the sera. PCR HCMV DNA in the liver tissues indicates the presentation of HCMV, inactivity or latent infection status. It suggests that PCR can be used as routine tools to detect the presentation of HCMV DNA. Type of cholestasis infants, both EBA and non-EBA, cannot be determined based on the serological and PCR examination, but based on histopathological feature.

ACKNOWLEDGEMENT:

We thank to the Government of the Republic of Indonesia, the Ministry of Research, Technology, and Higher Education, in particular the Faculty of Medicine, Airlangga University for financial support and all the patients who are willing to participate in this study.

CONFLICT OF INTEREST:

We declare no conflict of interest.

REFERENCES:

- Mack CL. What causes biliary atresia? Unique aspects of the neonatal immune system provide clues to disease pathogenesis. *Cellular Molecular Gastroenterology and Hepatology*. 2015; 1(3):267-74. <https://doi.org/10.1016/j.jcmgh.2015.04.001>
- Fischler B, Lamireau T. Cholestasis in the newborn and infant. *Clinics and Research in Hepatology and Gastroenterology*. 2014; 38(3): 263-7. <https://doi.org/10.1016/j.clinre.2014.03.010>
- Min CY, Song JY, Jeong SJ. Characteristics and prognosis of hepatic cytomegalovirus infection in children: 10 years of experience at a university hospital in Korea. *Korean Journal of Pediatrics*. 2017; 60(8):261. <https://doi.org/10.3345/kjp.2017.60.8.261>
- Tanimura K, Yamada H. Potential biomarkers for predicting congenital cytomegalovirus infection. *International Journal of Molecular Sciences*. 2018; 19(12):3760. <https://doi.org/10.3390/ijms19123760>
- De Tommaso AM, Andrade PD, Costa SC, Escanhoela CA, Hessel G. High frequency of human cytomegalovirus DNA in the liver of infants with extrahepatic neonatal cholestasis. *BMC Infectious Disease*. 2005; 5(1):1-8. <https://doi.org/10.1186/1471-2334-5-108>
- Feldman AG, Sokol RJ. Neonatal cholestasis. *Neoreviews*. 2013; 14(2):e63-73. <https://doi.org/10.1542/neo.14-2-e63>
- Davis AR, Rosenthal P, Escobar GJ, Newman TB. Interpreting conjugated bilirubin levels in newborns. *The Journal of Pediatrics*. 2011; 158(4): 562-5. <https://doi.org/10.1016/j.jpeds.2010.09.061>
- Rashed YK, Saber MA, Tawfik M, Mourad WS. Histopathological features and accuracy for diagnosing biliary atresia by prelaparotomy liver biopsy in Egypt. *Egyptian Pediatric Association Gazette*. 2013; 61(1): 42-5. <https://doi.org/10.1016/j.epag.2013.05.001>
- Stehel EK, Sánchez PJ. Cytomegalovirus infection in the fetus and neonate. *Neoreviews*. 2005; 6(1):e38-45. <https://doi.org/10.1542/neo.6-1-e38>
- Soetens O, Vauloup-Fellous C, Foulon I, Dubreuil P, De Saeger B, Grangeot-Keros L, Naessens A. Evaluation of different cytomegalovirus (CMV) DNA PCR protocols for analysis of dried blood spots from consecutive cases of neonates with congenital CMV infections. *Journal of Clinical Microbiology*. 2008; 46(3):943-6. <https://doi.org/10.1128/JCM.01391-07>
- Goegebuer T, Van Meensel B, Beuselinck K, Cossey V, Van Ranst M, Hanssens M, Lagrou K. Clinical predictive value of real-time PCR quantification of human cytomegalovirus DNA in amniotic fluid samples. *Journal of Clinical Microbiology*. 2009; 47(3):660-5. <https://doi.org/10.1128/JCM.01576-08>
- Suchy FJ. Neonatal cholestasis. *Pediatrics in Review*. 2004; 25(11): 388-96. <https://doi.org/10.1542/pir.25-11-388>
- Zagory JA, Nguyen MV, Wang KS. Recent advances in the pathogenesis and management of biliary atresia. *Current Opinion in Pediatrics*. 2015; 27(3):389. <https://doi.org/10.1097/MOP.0000000000000214>
- Rastogi A, Krishnani N, Yachha SK, Khanna V, Poddar U, Lal R. Histopathological features and accuracy for diagnosing biliary atresia by prelaparotomy liver biopsy in developing countries. *Journal of Gastroenterology and Hepatology*. 2009; 24(1):97-102. <https://doi.org/10.1111/j.1440-1746.2008.05737.x>
- Poddar U, Thapa BR, Das A, Bhattacharya A, Rao KL, Singh K. Neonatal cholestasis: differentiation of biliary atresia from neonatal hepatitis in a developing country. *Acta Paediatrica*. 2009; 98(8):1260-4. <https://doi.org/10.1111/j.1651-2227.2009.01338.x>
- Oliviera NL, Kanawaty FR, Costa S, Hessel G. Infection by cytomegalovirus in patients with neonatal cholestasis. *Arquivos de Gastroenterologia*. 2002; 39(2): 132-6. <https://doi.org/10.1590/s0004-28032002000200012>
- Pawlowska J, Swiatkowska E, Gliwicz D, Jankowska I, Kluge P, Cukrawska B, Dzierzanowski-Fangrat K. The role of cytomegalovirus infection in pathogenesis of neonatal cholestasis. *Experimental & Clinical Hepatology*. 2010; 6(1):25-9.
- Russo P, Magee JC, Anders RA, Bove KE, Chung C, Cummings OW, Finegold MJ, Finn LS, et al. Childhood Liver Disease Research Network (ChILDRen). Key Histopathologic Features of Liver Biopsies That Distinguish Biliary Atresia from Other Causes of Infantile Cholestasis and Their Correlation with Outcome: A Multicenter Study. *The American Journal of Surgical Pathology*. 2016 Dec;40(12):1601-1615. <https://doi.org/10.1097/PAS.0000000000000755>
- McDonald GB, Sarmiento JI, Rees-Lui G, Myerson D. Cytomegalovirus hepatitis after bone marrow transplantation: An autopsy study with clinical, histologic and laboratory correlates. *Journal of Viral Hepatitis*. 2019; 26(11):1344-1350. <https://doi.org/10.1111/jvh.13176>
- Moore SW, Zabiegaj-Zwick C, Nel E. Problems related to CMV infection and biliary atresia. *South African Medical Journal*. 2012; 102(11):890-2. <https://doi.org/10.7196/samj.6163>
- Ross SA, Novak Z, Pati S, Boppana SB. Diagnosis of Cytomegalovirus Infections. *Infectious Disorders Drug Targets*. 2011; 11(5): 466-74. <https://doi.org/10.2174/187152611797636703>
- Fischler B, Ehrnst A, Forsgren M, Orvell C, Nemeth A. The viral association of neonatal cholestasis in Sweden: a possible link between cytomegalovirus infection and extrahepatic biliary atresia. *Journal of Pediatric Gastroenterology and Nutrition*. 1998; 27(1): 57-64. <https://doi.org/10.1097/00005176-199807000-00010>
- Sira MM, Sira AM, Elhenawy IA, Khalil FO. Prevalence of serological markers of TORCH infections in biliary atresia and other neonatal cholestatic disorders. *Open Journal of Pediatric and Child Health*. 2016; 2(1):013-7. <https://doi.org/10.17352/2640-7612.000010>
- Goel A, Chaudhari S, Sutar J, Bhone G, Bhatnagar S, Patel V, Bhor V, Shah I. Detection of Cytomegalovirus in Liver Tissue by Polymerase Chain Reaction in Infants with Neonatal Cholestasis. *Pediatric Infectious Disease Journal*. 2018; 37(7): 632-6. <https://doi.org/10.1097/INF.0000000000001889>
- Slobedman B, Mocarski ES. Quantitative analysis of latent human cytomegalovirus. *Journal of Virology*. 1999; 73(6):4806-12. <https://doi.org/10.1128/JVI.73.6.4806-4812.1999>
- Mastutik G, Kurniasari N, Rahniayu A, Rahaju AN, Ruslan SEN, Ilmiah K, Setyoboedi B, Sulistyani E. Detection of cytomegalovirus in urine specimen of cholestasis infants by polymerase chain reaction. *Research Journal of Pharmacy and Technology*. 2022; 15(4)