

ISSN-0973-9122 (Print) • ISSN-0973-9130 (Electronic)

Volume 15 / Number 2 / April-June 2021



Indian Journal of Forensic Medicine & Toxicology

Website: www.ijfmt.com



Official Organ of Indian Association of Medico-Legal Experts (Regd.)

Indian Journal of Forensic Medicine & Toxicology

EDITOR in Chief

Prof. R K Sharma

Formerly at All India Institute of Medical Sciences, New Delhi, E-mail: editor.ijfmt@gmail.com

EDITOR

Prof. Dr. Adarsh Kumar

Forensic Medicine & Toxicology, AIIMS, New Delhi

INTERNATIONAL EDITORIAL ADVISORY BOARD

1. **Prof Mete Gulmen** Cukurova University, TURKEY
2. **Prof. Leandro Duarte De Carvalho**, Minas Gerais, Belo Horizonte, Brazil
3. **Prof. Donata Favretto** (Full Professor) Forensic Toxicology at University of Padova, Italy
4. **Prof. Babak Mostafazadeh** Department of Forensic Medicine & Toxicology, Shahid Beheshti University of Medical Sciences, Tehran-Iran
5. **Prof Halis Dokgoz**, Mersin University, TURKEY
6. **Prof Jozef Sidlo**, Comenius University, Bratislava, SLOVAKIA
7. **Dr. Rahul Pathak** (Lecturer) Forensic Science, Dept of Life Sciences Anglia Ruskin University, Cambridge, United Kingdom
8. **Dr. Hareesh** (Professor & Head) Forensic Medicine, Ayder Referral Hospital, College of Health Sciences, Mekelle University, Mekelle Ethiopia East Africa
9. **Dr. Mokhtar Ahmed Alhrani** (Specialist) Forensic Medicine & Clinical Toxicology, Director of Forensic Medicine Unit, Attorney General's Office, Sana'a, Yemen
10. **Dr. Sarathchandra** Kodikara (Senior Lecturer) Forensic Medicine, Department of Forensic Medicine, Faculty of Medicine, University of Peradeniya, Sri Lanka
11. **Dr Noha A. Magdie El Rafie**, Forensic Toxicology, Ain Shams University, Cairo, EGYPT

SCIENTIFIC COMMITTEE

1. **Prof Udai Pratap Singh**, Department of Anthropology Lucknow University Lucknow
2. **Dr Anil Rahule** (Associate Professor) Dept of Anatomy, Govt Medical College Nagpur
3. **Dr Shankar Bakkanwar** (Associate Professor) Forensic Medicine, Kasturba Medical College, Manipal, Karnatakad
4. **Dr K. Ravikumar** Raksha Shakti University, Ahmedabad, Gujrat.
5. **Dr. Pragnesh Parmar** (Associate Professor) Forensic Medicine, Valsad, Gujrat
6. **Dr Vandana Mudda** (Awati) (Associate Prof) Dept of FMT, M.R. Medical College, Gulbarga, Karnataka,
7. **Dr. Asha Srivastava** (Senior Scientific Officer) Forensic Psychology, Central Forensic Science Laboratory, CBI, Delhi
8. **Dr. Lav Kesharwani** (Asst.Prof.) School of Forensic Science, Sam Higginbottom Institute of Agriculture Technology & Sciences, Allahabad U.P,
9. **Dr. Anu Sharma** (Associate Prof) Dept of Anatomy, DMCH, Ludhiana (PB)
10. **Dr. Shalini Gupta** (Prof) Oral Pathology and Microbiology, Dental Sciences King George Medical University, Lucknow, UP
11. **Dr Rituja Sharma**, Associate Prof, Law Banasthali Vidyapeeth Jaipur

"Indian Journal of Forensic Medicine & Toxicology" is peer reviewed quarterly journal. It deals with Forensic Medicine, Forensic Science, Toxicology, DNA fingerprinting, sexual medicine and environment medicine. It has been assigned International standard serial No. p-0973-9122 and e- 0973-9130. The Journal has been assigned RNI No. DELENG/2008/21789. The journal is indexed with Index Copernicus (Poland) and is covered by EMBASE (Excerpta Medica Database). The journal is also abstracted in Chemical Abstracts (CAS) database (USA). The journal is also covered by EBSCO (USA) database. The Journal is now part of UGC, DST and CSIR Consortia. It is now official publication of Indian Association of Medico-Legal Experts (Regd.).

NATIONAL EDITORIAL ADVISORY BOARD

Chairman

Prof Sudhir K Gupta - Head, Department of Forensic Medicine
All India Institute of Medical Sciences, New Delhi

Members

1. **Prof. SK Dhatarwal**, Forensic Medicine, PGIMS, Rohtak, Haryana
2. **Prof. N K Aggrawal** Forensic Medicine, UCMS, Delhi
3. **Prof Ajay Ghangale** Forensic Medicine Dr DY Patil Medical College, Pune, Maharashtra
4. **Dr. Amar Jyoti** Patwory Professor, Forensic Medicine NEIGRIHMS, Shillong
5. **Dr S. Venkata Raghava** Professor, Forensic Medicine, Bangalore Medical College, Bengaluru
6. **Prof Praveen Arora**, Professor Department of Forensic Medicine & Toxicology, SAIMS, Indore
7. **Dr. Pankaj Datta** (Principal & Head) Department of Prosthodontics, Indraprastha Dental College & Hospital, Ghaziabad
8. **Dr. Mahindra Nagar** (Head) Department of Anatomy, UCMS & GTB Hospital, Delhi
9. **Dr. Virender Kumar Chhoker** Professor Forensic Medicine and Toxicology, Santosh Medical College, Ghaziabad, UP
10. **Dr. Dayanand G Gannur** (Professor) Department of Forensic Medicine & Toxicology, Shri BM Patil Medical College, Hospital & Research centre, Bijapur, Karnataka
11. **Dr. Alok Kumar** Professor Department of Forensic Medicine & Toxicology, UP Rural Institute of Medical Sciences and Research, Saifai, Etawah, U.P.

Print-ISSN:0973-9122 Electronic - ISSN: 0973-9130

Frequency: Quarterly, © All Rights reserved The views and opinions expressed are of the authors and not of the Indian Journal of Forensic Medicine & Toxicology. Indian Journal of Forensic Medicine & Toxicology does not guarantee directly or indirectly the quality or efficacy of any products or service featured in the advertisement in the journal, which are purely commercial.

Website: www.ijfmt.com

Editor

Dr. R.K. Sharma
Institute of Medico-legal Publications
Logix Office Tower, Unit No. 1704, Logix City Centre Mall, Sector- 32, Noida
- 201 301 (Uttar Pradesh)

Printed, published and owned by

Dr. R.K. Sharma
Institute of Medico-legal Publications
Logix Office Tower, Unit No. 1704, Logix City Centre Mall, Sector- 32, Noida
- 201 301 (Uttar Pradesh)

Published at

Institute of Medico-legal Publications
Logix Office Tower, Unit No. 1704, Logix City Centre Mall, Sector- 32, Noida
- 201 301 (Uttar Pradesh)



DOI: <https://doi.org/10.37506/ijfmt.v15i2>

Published: 2021-04-13

Articles

Psychological Aspects in Terms of Physical, Mental and Sociological Factors During Worldwide Corona Crisis

Akanksha Mandal

1-5

pdf

Anatomical Variation of Superficial Branch of Radial Nerve in Gujrat Region

Nirali Chavda, K.M. Parmar, Hetal Vaishanani, Kinjal Jethva, Priyanka Sharma, A.R.Gandotra

6-10

PDF

Combined Effect of Neural Tissue Mobilization and Deep Friction Massage in Piriformis Syndrome: A Research Protocol

Vrushali K. Athawale, Divya Jethwani, Moh'd Arshad Qureshi, Ragini Dadgal

11-16

PDF

Police Brutality and Custodial Torture in Technological Era: Need for Anti-Torture Law in India - A Critical Analysis

A Nirma Singh Heera, Rajasathya K.R, N. Prabhavathi

17-24

PDF

Study of Socio-Demographic Profile of Thoraco-Abdominal Injuries in Fatal Road Traffic Accidents in Mangalore City

Abymon K K, Mohd Amjad Bhat, Azia Manzoor Bhat

25-31

PDF

Study of Mortality Due to Thoraco-Abdominal Injuries in Road Traffic Accidents in Mangalore City

Abymon K K, Mohd Amjad Bhat, Azia Manzoor Bhat

32-37

PDF

Pattern of Thoraco-Abdominal Injuries in Fatal Road Traffic Accidents in Mangalore City

Abymon K K, Mohd Amjad Bhat, Azia Manzoor Bhat

38-42

PDF

PDF

Comparative Study between Two Methods of Management of Thalassemia Patients Have Complicated Spinal Cord Compression

Ha der Mekhlif Ali

2659-2663

PDF

Marked Dominance of methicillin Resistant Staphylococcus aureus among Iraqi Patients

Heba K. Jawfeeq, Muthanna Hamid, Harith Jabbar Fahad A-Mathkhury

2664-2667

PDF

Successful Conservative Management of Premature Rupture Membranes of Twin Pregnancy with one Fetus Papyraceus

Ketut Edy Sudarta

2668-2672

PDF

Comparison of Histological Changes in Mice Infected with the Cryptosporidium Parvum after Treatment with an Aquatic Leaf Extract of Salvia Officinalis, Pimpinella Anisum and, Spiramycin Drug

Khadiji Kh eaf Al Dulaimi, Karama Tahreer Ahmed Al Tzee, Thaeer Abdulqader Sa ih

2673-2680

PDF

Cardiac Arrest Induced by Anti-hypertensive and NSAIDS Drug Abuse Uses due to their Role Effect on Electrolytes and Aldosterone Levels in Hypertensive Patients with Renal Insufficiency

Khama'a Hussein abod A-Khafaji, Ahmed A-mukhtar, A' Hassan Abood, Hydar M khalfa

2681-2686

PDF

Study of Some Biomarkers and HLA-G for Early Detection of Multiple Sclerosis Disease

Khama'e Abdul a Taha, Mayada N qbal, Gheyath Abd Ali Sha al

2687-2694

PDF

The Covid-19 Pandemic and Developing the Legal Certainty on Bankruptcy for Health Institution in Indonesia

Krista Y tawati, Adi Su ist'yono, Pujiono

2695-2699

PDF

Impact of Active Release Technique and Core Strengthening on Pain, Muscle Stiffness, Muscle Hardness and Quality of Life on Non- Specific Low Back Pain: An Experimental Study

Lauk'k Va'dya, R. K. S'nha

2700-2708

PDF

The Correlation of EMMPRIN and EGFR Overexpression toward Muscle Invasiveness in Urothelial Carcinoma of Bladder

Leon'ta Agustin Hambal'e, Anny Setijo Rahaju, Gondo Mastutik

2709-2715

PDF

The Correlation of EMMPRIN and EGFR Overexpression toward Muscle Invasiveness in Urothelial Carcinoma of Bladder

Leonita Agustin Hambalie¹, Anny Setijo Rahaju^{2,3,4}, Gondo Mastutik²

¹Resident, Department of Anatomical Pathology, Faculty of Medicine, Universitas Airlangga, Surabaya, Indonesia,

²Lecturer, Department of Anatomical Pathology, Faculty of Medicine, Universitas Airlangga, Surabaya, Indonesia,

³Lecturer, Universitas Airlangga Hospital, Universitas Airlangga, Surabaya, Indonesia, ⁴Lecturer, Dr. Soetomo General Academic Hospital, Surabaya, Indonesia

Abstract

Urothelial carcinomas represent 90% of all primary bladder cancers. Muscle invasion is a critical prognostic determinant in urothelial carcinoma. The overexpression of EMMPRIN and EGFR was found in urothelial carcinoma. The association between the two markers has not been reported in urothelial carcinoma, therefore we aimed to analyze the expression of EMMPRIN and EGFR and investigate their association with urothelial carcinoma invasiveness. Paraffin-embedded tissues were obtained from 54 urothelial carcinoma patients which then underwent immunohistochemistry staining for EMMPRIN and EGFR antibody. The comparison of EMMPRIN and EGFR expression was tested using the Mann Whitney U test. The correlation was analyzed using the Spearman test. Results showed a significant difference of EMMPRIN expression between non-muscle-invasive and muscle-invasive bladder cancer ($p = 0.000$), and EMMPRIN expression was significantly correlated with the muscle invasion ($r_s = 0.481$, $p = 0.000$). A significant difference of EGFR expression between the non-muscle-invasive and muscle-invasive bladder cancer was also found ($p = 0.020$), and EGFR expression was significantly correlated with the muscle invasion ($r_s = 0.319$, $p = 0.019$). The expression of EMMPRIN was positively correlated with EGFR in urothelial carcinoma ($r_s = 0.322$, $p = 0.018$). The expression of EMMPRIN and EGFR are two potential biomarkers for urothelial carcinoma invasiveness which may be helpful to differentiate between muscle-invasive and non-muscle-invasive bladder cancer.

Keywords: Urothelial carcinoma, muscle invasiveness, EGFR, EMMPRIN.

Introduction

Bladder cancer is the most common cancer in the urogenital system and urothelial carcinoma accounts for about 90% of all primary bladder cancer^[1]. The most important factor for determining prognosis in urothelial carcinoma is the depth of invasion^[2]. Depending on the presence of muscularis propria invasion, pT1 tumor is classified as non-muscle-invasive bladder cancer (NMIBC), while pT2 tumors and above are classified as muscle-invasive bladder cancer (MIBC)^[3].

It is important to identify tumor invasion of the muscularis propria; the presence of which determines the therapeutic approaches. While accurate identification of

muscularis propria invasion is crucial, it is considered as a challenge to evaluate muscle invasion solely on H&E. Because of this reason, the detection of abnormal expression of biological markers for urothelial carcinoma invasiveness, specifically muscle invasiveness, would be very helpful to determine the presence of muscle invasion in the tumor and assist doctors in providing a suitable treatment for patients^[4].

Extracellular matrix metalloproteinase inducer (EMMPRIN), other names include CD147 and basigin, is a transmembrane glycoprotein of the immunoglobulin superfamily. It is highly expressed on the cell surface of many malignant tumors, including liver, breast, colon, prostate, and esophageal cancer^[5]. Overexpression of

EMMPRIN is found in 71.2% of urothelial carcinoma^[6]. EMMPRIN is best-known to stimulate the production of some matrix metalloproteinases (MMPs) in tumor cells and fibroblasts. MMPs are major proteases in degrading the extracellular matrix, leading to cancer cell invasion and metastasis^[7].

Epidermal growth factor receptor (EGFR) is a tyrosine kinase transmembrane receptor that plays an important role in carcinogenesis^[1]. It is overexpressed in many tumors, such as head and neck, lung, colon, breast, kidney, prostate, and bladder cancer^[1]. EGFR is involved in the regulation of MMPs, several studies have shown that EGFR stimulation induces MMPs expression^[8]. Therefore, this study was conducted to analyze the role of EMMPRIN and EGFR in urothelial carcinoma, also their relationship, specifically toward the tumor invasion.

Materials and Methods

Research Design and Sample

This study was analytic observational research with a cross-sectional approach. A total of 54 formalin-fixed, paraffin-embedded tissues were obtained from patients diagnosed as urothelial carcinoma and underwent Radical Cystectomy (RC) during 2010-2019 in the Anatomical Pathology Laboratory, Dr. Soetomo General Hospital. Samples were divided based on their muscle invasion, pT1 tumor was classified as non-muscle-invasive bladder cancer (NMIBC) and pT2-4 tumor was classified as muscle-invasive bladder cancer (MIBC).

Immunohistochemistry Staining

The tissues were cut into 4mm sections, deparaffinized three times with xylol for 5 minutes each, and rehydrated through graded alcohol. Antigen retrieval was accomplished by incubation for 10 minutes in sodium citrate buffer (pH 6.0). Afterward, the tissue sections were incubated with monoclonal antibodies for EMMPRIN (1.BB.218: sc-71038; dilution 1:250; Santa Cruz Biotechnology) and EGFR (0.N.268: sc-71034; dilution 1:100; Santa Cruz Biotechnology) overnight, followed by a secondary antibody for 10 minutes at room temperature. Sections were then counterstained with hematoxylin and dehydrated with alcohol. Human placental tissue was used as a positive control for EGFR

while human gastric tissue was used as a positive control for EMMPRIN.

Evaluation of Immunohistochemical Expression

All samples were evaluated by two pathologists in the blinded fashion. Any discordant was solved by interobserver agreement. Membranous and cytoplasmic staining of EMMPRIN and EGFR were evaluated on the basis of the percentage of stained tumor cells and the staining intensity of the tumor cells. The staining intensity for both EMMPRIN and EGFR was scored as 0 (absent), 1 (weak), 2 (moderate), and 3 (strong). For EMMPRIN, the percentage of stained tumor cells was scored as 0 for no - <10% positive cells; 1, 10% - 24%; 2, 25% - 49%; 3, 50% - 74%; and 4, ³75%. The sum of the percentage of stained tumor cells and the staining intensity score was then used as the final EMMPRIN score. Final scores of 0 to 1 were considered negatives, 2 to 3 were considered weak, 4 to 5 were considered moderate, and 6 to 7 were considered strong^[9].

For EGFR evaluation, the percentage of stained cells score was slightly different from EMMPRIN, as follows: 0 for no positive cells; 1, 1-25%; 2, 26-50%; 3, 51-75%; and 4, >75%. Then, a final score was obtained by multiplying the score of staining intensity and percentage of stained cells: a score of 0 was considered negative, 1-4 was weak, 5-8 was moderate, and 9 - 12 was strong^[1].

Statistical Analysis

All statistical analysis was calculated using SPSS v.25.0. The comparison of EMMPRIN and EGFR expression was tested using the Mann Whitney U test. The correlation was analyzed using the Spearman test, with a significance level <0.05 ($p < 0.05$).

Results and Discussion

The average age of patients was 60.6 ± 9.4 years with a male to female ratio of 50:4. In the study, muscle-invasive bladder cancer (MIBC) was found in 81.5% (44/54) cases, whereas non-muscle-invasive bladder cancer (NMIBC) was only found in 18.5% (10/54) cases. Around 87% of the cases (47/54) were high-grade, whereas 13% (7/54) were low-grade.

EMMPRIN Expression in Urothelial Carcinoma

EMMPRIN was found to be expressed at the plasma membrane and/or cytoplasm (Figure 1). We compared EMMPRIN expression between non-muscle-invasive and muscle-invasive bladder cancer, also between low grade and high-grade tumors. A significant difference of EMMPRIN expression was found between the non-muscle-invasive and muscle-invasive tumors ($p = 0.000$), while no significant difference of EMMPRIN expression was found between the low grade and high-grade tumor ($p = 0.105$). Strong EMMPRIN expression was mainly found in tumors with muscle invasion (52.3%), while none of the non-muscle-invasive tumors showed strong EMMPRIN expression. Spearman correlation test showed a highly significant positive correlation between EMMPRIN expression and muscle invasion of the tumor ($r_s = 0.481, p = 0.000$) (Table 1).

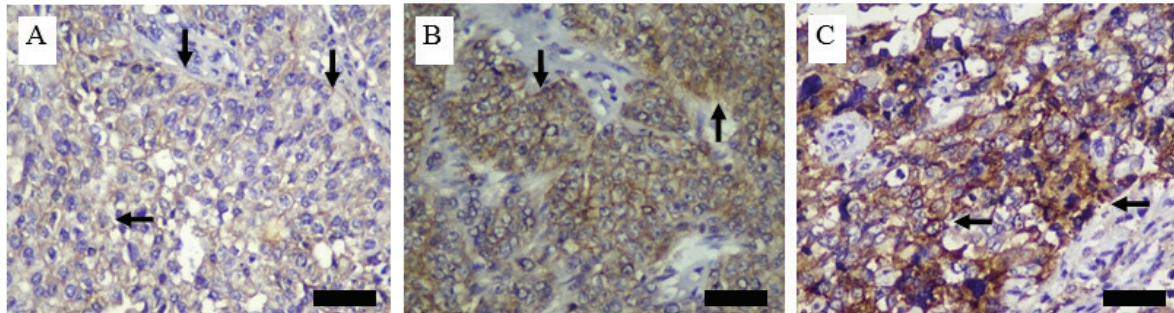


Figure 1. Immunohistochemical expression of EMMPRIN in urothelial carcinoma (brown stain in membrane and/or cytoplasm), 400x magnification. A: Weak intensity staining of EMMPRIN; B: Moderate intensity staining of EMMPRIN; C: Strong intensity staining of EMMPRIN. Black arrows: EMMPRIN expression; black bars: 50 µm.

Table 1. Association between EMMPRIN expression with muscle invasion and tumor grade.

	EMMPRIN Expression				p-value a	rs b	p-value b
	Negative n (%)	Weak n (%)	Moderate n (%)	High n (%)			
Muscle Invasion					0.000	0.481	0.000
Absent (pT1) / NMIBC	1 (10)	3 (30)	6 (60)	0 (0)			
Present (pT2-4) / MIBC	0 (0)	3 (6.8)	18 (40.9)	23 (52.3)			
Tumor Grade					0.105	-	-
Low Grade	1 (14.2)	2 (28.6)	2 (28.6)	2 (28.6)			
High Grade	0 (0)	4 (8.5)	22 (46.8)	21 (44.7)			

^aMann Whitney U test applied.

^bSpearman correlation test applied.

p-value <0.05, considered as significant.

EGFR Expression in Urothelial Carcinoma

EGFR was found to be expressed at the plasma membrane and/or cytoplasm (Figure 2). We compared EGFR expression between non-muscle-invasive and muscle-invasive bladder cancer, also between low grade and high-grade tumors. We observed a significant difference of EGFR between the non-muscle-invasive and muscle-invasive tumors ($p = 0.020$), while no significant difference of EGFR expression was found between the low grade and high-grade tumor ($p = 0.079$). Moderate and strong EGFR expressions were only found in the muscle-invasive tumor, while the non-muscle-invasive tumor only showed negative and weak EGFR expression. Spearman correlation test showed a significant positive correlation between EGFR expression and muscle invasion of the tumor ($r_s = 0.319, p = 0.019$) (Table 2).

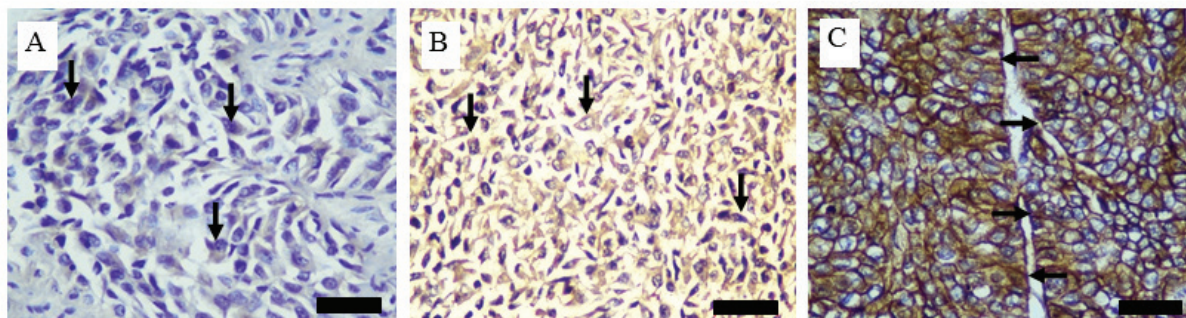


Figure 2. Immunohistochemical expression of EGFR in urothelial carcinoma with 400× magnification. A: Weak intensity staining of EGFR; B: Moderate intensity staining of EGFR; C: Strong intensity staining of EGFR. Black arrows: EGFR expression; black bars: 50 μm.

Table 2. Association between EGFR expression with muscle invasion and tumor grade.

	EGFR Expression				<i>p</i> -value ^a	<i>r_s</i> ^b	<i>p</i> -value ^b
	Negative n (%)	Weak n (%)	Moderate n (%)	High n (%)			
Muscle Invasion					0.020	0.319	0.019
Absent (pT1) / NMIBC	6 (60)	4 (40)	0 (0)	0 (0)			
Present (pT2-4) / MIBC	11 (25)	24 (54.5)	7 (16)	2 (4.5)			
Tumor Grade					0.079	-	-
Low Grade	4 (57.1)	3 (42.9)	0 (0)	0 (0)			
High Grade	13 (27.7)	25 (53.2)	7 (14.9)	2 (4.2)			

^aMann Whitney U test applied.

^bSpearman correlation test applied.

p-value < 0.05, considered as significant.

Correlation between EMMPRIN and EGFR in Urothelial Carcinoma

A significant positive correlation was found between EMMPRIN and EGFR expression in urothelial carcinoma ($r_s = 0.322, p = 0.018$).

Discussion

The age of the patients observed in this study ranged from the age of 34 to 81 years (mean 60.6 ± 9.4). In this study, the majority of the patients had muscle-invasive bladder cancer/MIBC (pT2-4) (81.5%), whereas non-muscle-invasive bladder cancer/NMIBC (pT1) was only found in 18.5% of the cases. Our study showed that EMMPRIN expression was significantly different between non-muscle-invasive bladder cancer/NMIBC (pT1) and muscle-invasive bladder cancer/MIBC (pT2-4), and EMMPRIN expression is significantly correlated with the muscle invasion, with a positive r-value of 0.481. Similar results were reported by other studies, showing a significant difference of EMMPRIN expression between superficial (pT1) and muscle-invasive (pT2) urothelial carcinoma^[10]. Another study found that negative or low EMMPRIN expression was strongly correlated with non-muscle-invasive urothelial carcinoma (pT1 tumor) compared to muscle-invasive urothelial carcinoma (pT2-4 tumor)^[6]. EMMPRIN stimulates the tumor cells and peritumoral fibroblasts to produce matrix metalloproteinases (MMPs), which then degrade the extracellular matrix of basement membranes, which normally play a role as mechanical barriers to tumor cell migration and invasion^[11]. EMMPRIN induce MMPs production through the MKK-p38-MAPKAP signaling pathway, and the induction of MMPs by EMMPRIN occurs at the transcription level^[12].

Regarding EGFR expression, a significant difference of EGFR expression was also found between non-muscle-invasive bladder cancer/NMIBC (pT1) and muscle-invasive bladder cancer/MIBC (pT2-4), and EGFR expression is significantly correlated with the muscle invasion in this study with a positive r-value of 0.319. This result is in accordance with a prior study that found a significant association between EGFR expression and muscle invasion in urothelial carcinoma, with strong EGFR expression, which was mainly found in the muscle-invasive tumor, while negative and weak EGFR expression was mainly found in the non-muscle-invasive

tumor. A prior study found that EGFR overexpression was significantly associated with tumor grade which is in contrast with the result of this study that found no significant association between EGFR expression and tumor grade^[4]. Several studies showed that basal tumors of urothelial carcinoma expressed high levels of EGFR, CD49 and Cyclin D1. A prior study showed no EGFR mutations were identified in all urothelial carcinoma cases observed, hence it was hypothesized that EGFR overexpression is the result of deregulation of the protein recycling and degradation pathway^[13]. EGFR expression is higher in urothelial carcinoma than in normal urothelium^[14]. EGFR signaling triggers Ras activation, this process can increase MAPK activity, which activates important regulators of the epithelial-mesenchymal transition^[3].

We found that EMMPRIN expression was significantly correlated with EGFR expression with a positive r-value of 0.322. To our knowledge, this correlation has not been reported in urothelial carcinoma, although another study described a correlation between the two markers in colorectal adenocarcinoma^[15]. A prior study suggested that EGFR might play a role in regulating EMMPRIN expression and is relevant for the tumor invasion in urothelial carcinoma^[16]. Elevated EMMPRIN expression was able to stimulate hyaluronan production in tumor cells and hyaluronan is the main ligand for the cell surface receptor CD44. Hyaluronan and CD44 interaction induce the assembly of lipid raft-associated complexes containing EMMPRIN, CD44 and EGFR^[17,18,19].

Conclusion

The expression of EMMPRIN and EGFR are potentially significant biomarkers of urothelial carcinoma invasiveness and that may be helpful to discriminate between muscle-invasive and non-muscle invasive bladder cancer, where urothelial carcinoma with EMMPRIN and EGFR overexpression is found more likely in urothelial carcinoma with muscle invasion. The EMMPRIN and EGFR overexpression further help to determine the patients who need more radical treatment.

Conflict of Interest: The authors declare that they have no conflict of interest.

Source of Funding: None.

Acknowledgements: We thank Dr. Budi Utomo, dr., M.Kes. and all of the lecturers in Department of Anatomical Pathology, Faculty of Medicine, Universitas Airlangga for the guidance in finishing this study. We additionally thank Putri Amaristya Purwono and Arif Nur Muhammad Ansori for editing the manuscript.

Ethical Approval: This study had been approved by the Health Research Ethics Committee of Dr. Soetomo General Hospital, Surabaya (Ethical Clearance No. 1534/KEPK/IX/2019).

References

- Li W, Wang Y. Overexpression of Epidermal Growth Factor Receptor (EGFR) and HER-2 in Bladder Carcinoma and Its Association with Patients' Clinical Features. *Med Sci Monit.* 2018; 24: 7178–7185.
- Humphrey PA, Moch H, Cubilla AL, *et al.* The 2016 WHO Classification of Tumours of the Urinary System and Male Genital Organs—Part B: Prostate and Bladder Tumours. *European urology.* 2016; 70: 106-119.
- Knowles MA, Hurst CD. Molecular biology of bladder cancer: New insights into pathogenesis and clinical diversity. *Nat Publ Gr.* 2015; 15: 25–41.
- Hashmi AA, Hussain ZF, Irfan M, *et al.* Prognostic significance of epidermal growth factor receptor (EGFR) over expression in urothelial carcinoma of urinary bladder. *BMC Urol.* 2018; 1–6.
- Liu B, Wan Z, Sheng B, *et al.* Overexpression of EMMPRIN is associated with lymph node metastasis and advanced stage of non-small cell lung cancer: A retrospective study. *BMC Pulm Med.* 2017; 17: 1–9.
- El-RehimDMABD, MohamedN, AbdR. Expression of extracellular matrix metalloproteinase inducer and fascin in urinary bladder cancer: Correlation with clinicopathological characteristics. *Mol Clin Oncol.* 2013; 1: 297–304.
- Xu J, Lu Y, Qiu S, *et al.* A novel role of EMMPRIN/CD147 in transformation of quiescent fibroblasts to cancer-associated fibroblasts by breast cancer cells. *Cancer Lett.* 2013; 335: 380–386.
- Guéguinou M, Gambade A, Félix R, *et al.* Lipid rafts, KCa/CiCa/Ca²⁺ channel complexes and EGFR signaling: Novel targets to reduce tumor development by lipids?. *Biochim Biophys Acta - Biomembr.* 2015; 1848: 2603–2620.
- Monteiro LS, Delgado ML, Ricardo S, *et al.* EMMPRIN expression in oral squamous cell carcinomas: Correlation with tumor proliferation and patient survival. *Biomed Res Int.* 2014; 2014: 1–9.
- Wittschieber D, Klauschen F. Decreased RECK and increased EMMPRIN expression in urothelial carcinoma of the bladder are associated with tumor aggressiveness. *Pathobiology.* 2011; 123–131.
- Sato M, Nakai Y, Nakata W, *et al.* EMMPRIN Promotes Angiogenesis, Proliferation, Invasion and Resistance to Sunitinib in Renal Cell Carcinoma, and Its Level Predicts Patient Outcome. *PLoS One.* 2013; 8: 1–10.
- Xin X, Zeng X, Gu H, *et al.* CD147 / EMMPRIN overexpression and prognosis in cancer: A systematic review and meta-analysis. *Sci Rep.* 2016; 113: 1–12.
- Mooso BA, Vinall RL, Mudryj M, *et al.* The Role of EGFR Family Inhibitors in Muscle Invasive Bladder Cancer: A Review of Clinical Data and Molecular Evidence. *J Urol.* 2016; 193: 19–29.
- Black PC, Dinney CPN. Growth Factors and Receptors as Prognostic Markers in Urothelial Carcinoma. *Curr Urol Rep.* 2008; 9: 55–61.
- Jin J, Wu C, Lin Y, *et al.* Higher expression of epidermal growth factor receptor is associated with extracellular matrix metalloprotease inducer in colorectal adenocarcinoma: Tissue microarray analysis of immunostaining score with clinicopathological parameters. *Dis Markers.* 2006; 22: 309–316.
- Grass GD, Tolliver LB, Bratoeva M, *et al.* CD147, CD44, and the epidermal growth factor receptor (EGFR) signaling pathway cooperate to regulate breast epithelial cell invasiveness. *J Biol Chem.* 2013; 288: 26089–26104.
- Grass GD, Dai L, Qin Z, *et al.* CD147: Regulator of hyaluronan signaling in invasiveness and chemoresistance. In: *Hyaluronan Signaling and Turnover.* 1st ed. Elsevier Inc. 123: 351–373; 2014.
- Huang S, Ren X, Wang L, *et al.* Lung-cancer chemoprevention by induction of synthetic lethality in mutant KRAS premalignant cells in vitro and in

- vivo. *Cancer Prev Res.* 2011; 4: 666–673.
19. Kong LM, Liao CG, Zhang Y, *et al.* A regulatory loop involving miR-22, Sp1, and c-Myc modulates CD147 expression in breast cancer invasion and metastasis. *Cancer Res.* 2014; 74: 3764–3778.

Source details

Indian Journal of Forensic Medicine and Toxicology

Scopus coverage years: from 2008 to Present

(coverage discontinued in Scopus)

Publisher: Institute of Medico-Legal Publications

ISSN: 0973-9122 E-ISSN: 0973-9130

Subject area: Social Sciences: Law Medicine: Pathology and Forensic Medicine

Pharmacology, Toxicology and Pharmaceutics: Toxicology Environmental Science: Health, Toxicology and Mutagenesis

Source type: Journal

CiteScore 2020
0.1

SJR 2020
0.115

SNIP 2020
0.243

[View all documents >](#) [Set document alert](#) [Save to source list](#)

[CiteScore](#) [CiteScore rank & trend](#) [Scopus content coverage](#)

i Improved CiteScore methodology

CiteScore 2020 counts the citations received in 2017-2020 to articles, reviews, conference papers, book chapters and data papers published in 2017-2020, and divides this by the number of publications published in 2017-2020. [Learn more >](#)

CiteScore 2020 ▼

$$0.1 = \frac{387 \text{ Citations 2017 - 2020}}{3,509 \text{ Documents 2017 - 2020}}$$

Calculated on 05 May, 2021

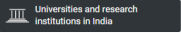
CiteScore rank 2020 ⓘ

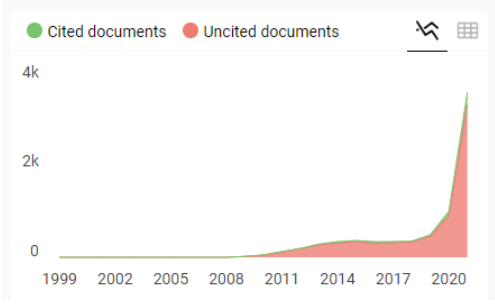
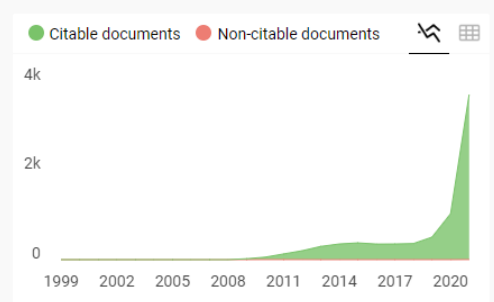
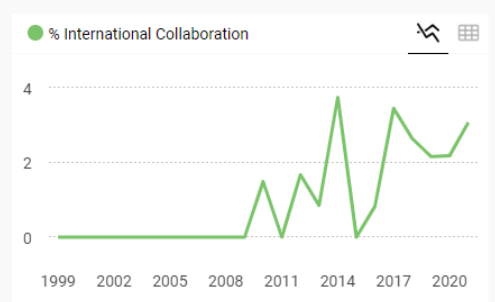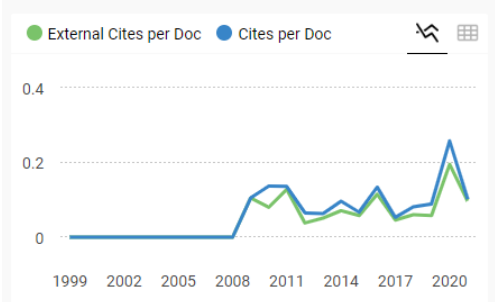
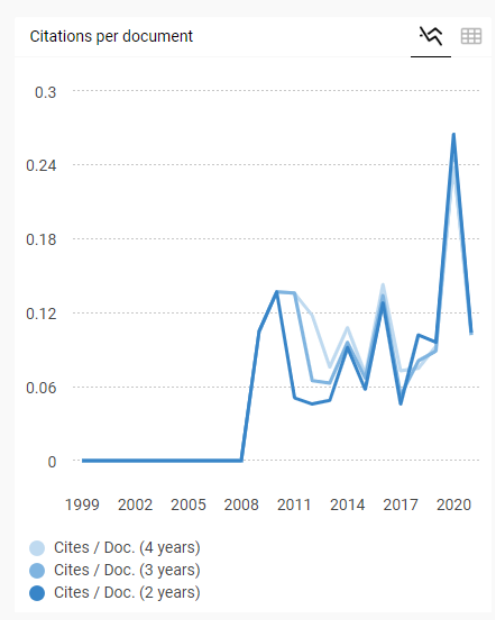
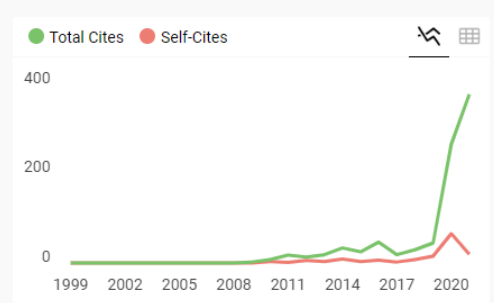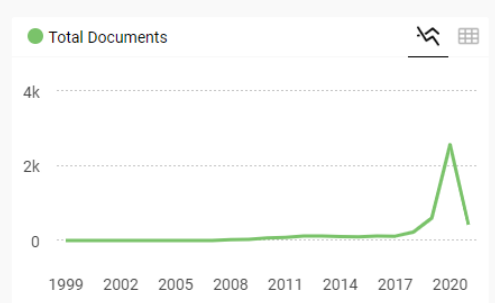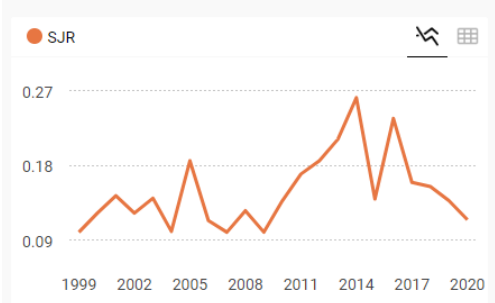
Category	Rank	Percentile
Social Sciences		
└ Law	#639/722	11th
Medicine		
└ Pathology and Forensic Medicine	#183/191	4th
Pharmacology,		

[View CiteScore methodology >](#) [CiteScore FAQ >](#) [Add CiteScore to your site ↗](#)

Indian Journal of Forensic Medicine and Toxicology

Discontinued in Scopus as of 2020

<p>COUNTRY</p> <p>India</p> 	<p>SUBJECT AREA AND CATEGORY</p> <ul style="list-style-type: none"> Environmental Science <ul style="list-style-type: none"> Health, Toxicology and Mutagenesis Medicine <ul style="list-style-type: none"> Pathology and Forensic Medicine Pharmacology, Toxicology and Pharmaceutics <ul style="list-style-type: none"> Toxicology Social Sciences <ul style="list-style-type: none"> Law 	<p>PUBLISHER</p> <p>Institute of Medico-legal Publications</p>	<p>H-INDEX</p> <p>12</p>
<p>PUBLICATION TYPE</p> <p>Journals</p>	<p>ISSN</p> <p>09739122, 09739130</p>	<p>COVERAGE</p> <p>2008-2021</p>	<p>INFORMATION</p> <p>Homepage</p> <p>How to publish in this journal</p> <p>editor:ijfmt@gmail.com</p>



Indian Journal of Forensic Medicine and Toxicology

← Show this widget in your own website

Not yet assigned quartile

SJR 2021: 0

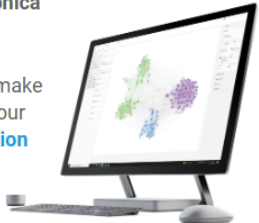
powered by scimagojr.com

Just copy the code below and paste within your html code:

```
<a href="https://www.scimagojr.com" data-bbox="428 925 515 940">
```

SCImago Graphica

Explore, visually communicate and make sense of data with our **new data visualization tool**.



Fw: Trs: Fwd: [IJFMT] Editor Decision  Kotak Masuk

anny setjorahaju

kepada saya ▾

[Sent from Yahoo Mail on Android](#)

----- Forwarded Message -----

From: "widiana ferriastuti" <widiana_ferriastuti@yahoo.com>
To: "anny_setjorahaju@yahoo.com" <anny_setjorahaju@yahoo.com>
Sent: Tue, Sep 6, 2022 at 8:37
Subject: Trs: Fwd: [IJFMT] Editor Decision

[Dikirim dari Yahoo Mail di Android](#)

----- Pesan yang Diteruskan -----

Dari: "widiana ferriastuti" <widiana-f@fk.unair.ac.id>
Kepada: "widiana_ferriastuti@yahoo.com" <widiana_ferriastuti@yahoo.com>
Cc:
Terkirim: Sel, 6 Sep 2022 pada 8:25
Judul: Fwd: [IJFMT] Editor Decision

----- Forwarded message -----

From: **Indian Journal of Forensic Medicine & Toxicology** <editor.ijfmt@gmail.com>
Date: Mon, May 10, 2021 at 7:06 PM
Subject: Re: [IJFMT] Editor Decision
To: widiana ferriastuti <widiana-f@fk.unair.ac.id>

Find an enclosed soft copy of the acceptance letter as attachment.

PS Please note :- The Journal is no longer in Scopus as per their mail received on 10th May 2021

With warm regards
Yours sincerely

Prof R K Sharma
Editor, Indian Journal of Forensic Medicine & Toxicology
Former Head , Department of Forensic Medicine, A I I M S , New Delhi
<http://medicopublication.com/index.php/ijfmt/index>
www.ijfmt.com

Address for Correspondence

Dr R K Sharma
Editor, IJFMT
Institute of Medico-legal Publications
Logix Office Tower, Unit No. 1704, Logix City Centre Mall
Sector- 32, Noida - 201 301 (Uttar Pradesh)
<http://medicopublication.com/index.php/ijfmt/index>



**KOMITE ETIK PENELITIAN KESEHATAN
RSUD Dr. SOETOMO SURABAYA**

**KETERANGAN KELAIKAN ETIK
(" ETHICAL CLEARANCE ")**

1534/KEPK/IX/2019

**KOMITE ETIK RSUD Dr. SOETOMO SURABAYA TELAH MEMPELAJARI
SECARA SEKSAMA RANCANGAN PENELITIAN YANG DIUSULKAN, MAKA
DENGAN INI MENYATAKAN BAHWA PENELITIAN DENGAN JUDUL :**

**" Korelasi antara ekspresi EMMPRIN dan EGFR dengan status stadium T pada
karsinoma urotelial buli "**

PENELITI UTAMA : Anny Setijo Rahaju, dr., Sp.PA(K).

**PENELITI LAIN : 1. Leonita Agustin Hambalie, dr
2. Dr. Gondho Mastutik, drh., M.Kes**

UNIT / LEMBAGA / TEMPAT PENELITIAN : RSUD Dr. Soetomo

DINYATAKAN LAIK ETIK

Berlaku dari : 24/09/2019 s.d 24/09/2020

Surabaya, 24 September 2019

KETUA



(Dr. Elizeus Hanindito, dr., Sp.An, KIC, KAP)

NIP. 19511007 197903 1 002

****) Sertifikat ini dinyatakan sah apabila telah mendapatkan stempel asli dari Komite Etik
Penelitian Kesehatan***