

C11 The Correlation of EMMPRIN and EGFR Overexpression toward Muscle Invasiveness in Urothelial Carcinoma of Bladder

by Leonita Agustin Hambalie

Submission date: 04-Oct-2022 04:36PM (UTC+0800)

Submission ID: 1916286513

File name: oward_Muscle_Invasiveness_in_Urothelial_Carcinoma_of_Bladder.pdf (1.11M)

Word count: 3059

Character count: 17204

The Correlation of EMMPRIN and EGFR Overexpression toward Muscle Invasiveness in Urothelial Carcinoma of Bladder

Leonita Agustin Hambalie¹, Anny Setijo Rahaju^{2,3,4}, Gondo Mastutik²

¹Resident, Department of Anatomical Pathology, Faculty of Medicine, Universitas Airlangga, Surabaya, Indonesia,

²Lecturer, Department of Anatomical Pathology, Faculty of Medicine, Universitas Airlangga, Surabaya, Indonesia,

³Lecturer, Universitas Airlangga Hospital, Universitas Airlangga, Surabaya, Indonesia, ⁴Lecturer, Dr. Soetomo General Academic Hospital, Surabaya, Indonesia

Abstract

Urothelial carcinomas represent 90% of all primary bladder cancers. Muscle invasion is a critical prognostic determinant in urothelial carcinoma. The overexpression of EMMPRIN and EGFR was found in urothelial carcinoma. The association between the two markers has not been reported in urothelial carcinoma, therefore we aimed to analyze the expression of EMMPRIN and EGFR and investigate their association with urothelial carcinoma invasiveness. Paraffin-embedded tissues were obtained from 54 urothelial carcinoma patients which then underwent immunohistochemistry staining for EMMPRIN and EGFR antibody. The comparison of EMMPRIN and EGFR expression was tested using the Mann Whitney U test. The correlation was analyzed using the Spearman test. Results showed a significant difference of EMMPRIN expression between non-muscle-invasive and muscle-invasive bladder cancer ($p = 0.000$), and EMMPRIN expression was significantly correlated with the muscle invasion ($r_s = 0.481$, $p = 0.000$). A significant difference of EGFR expression between the non-muscle-invasive and muscle-invasive bladder cancer was also found ($p = 0.020$), and EGFR expression was significantly correlated with the muscle invasion ($r_s = 0.319$, $p = 0.019$). The expression of EMMPRIN was positively correlated with EGFR in urothelial carcinoma ($r_s = 0.322$, $p = 0.018$). The expression of EMMPRIN and EGFR are two potential biomarkers for urothelial carcinoma invasiveness which may be helpful to differentiate between muscle-invasive and non-muscle-invasive bladder cancer.

Keywords: Urothelial carcinoma, muscle invasiveness, EGFR, EMMPRIN.

Introduction

Bladder cancer is the most common cancer in the urogenital system and urothelial carcinoma accounts for about 90% of all primary bladder cancer^[1]. The most important factor for determining prognosis in urothelial carcinoma is the depth of invasion^[2]. Depending on the presence of muscularis propria invasion, pT1 tumor is classified as non-muscle-invasive bladder cancer (NMIBC), while pT2 tumors and above are classified as muscle-invasive bladder cancer (MIBC)^[3].

It is important to identify tumor invasion of the muscularis propria; the presence of which determines the therapeutic approaches. While accurate identification of

muscularis propria invasion is crucial, it is considered as a challenge to evaluate muscle invasion solely on H&E. Because of this reason, the detection of abnormal expression of biological markers for urothelial carcinoma invasiveness, specifically muscle invasiveness, would be very helpful to determine the presence of muscle invasion in the tumor and assist doctors in providing a suitable treatment for patients^[4].

Extracellular matrix metalloproteinase inducer (EMMPRIN), other names include CD147 and basigin, is a transmembrane glycoprotein of the immunoglobulin superfamily. It is highly expressed on the cell surface of many malignant tumors, including liver, breast, colon, prostate, and esophageal cancer^[5]. Overexpression of

EMMPRIN is found in 71.2% of urothelial carcinoma⁶. EMMPRIN is best-known to stimulate the production of some matrix metalloproteinases (MMPs) in tumor cells and fibroblasts. MMPs are major proteases in degrading the extracellular matrix, leading to cancer cell invasion and metastasis⁷.

Epidermal growth factor receptor (EGFR) is a tyrosine kinase transmembrane receptor that plays an important role in carcinogenesis¹¹. It is overexpressed in many tumors, such as head and neck, lung, colon, breast, kidney, prostate, and bladder cancer¹¹. EGFR is involved in the regulation of MMPs, several studies have shown that EGFR stimulation induces MMPs expression⁸. Therefore, this study was conducted to analyze the role of EMMPRIN and EGFR in urothelial carcinoma, also their relationship, specifically toward the tumor invasion.

Materials and Methods

Research Design and Sample

This study was analytic observational research with a cross-sectional approach. A total of 54 formalin-fixed, paraffin-embedded tissues were obtained from patients diagnosed as urothelial carcinoma and underwent Radical Cystectomy (RC) during 2010-2019 in the Anatomical Pathology Laboratory, Dr. Soetomo General Hospital. Samples were divided based on their muscle invasion, pT1 tumor was classified as non-muscle-invasive bladder cancer (NMIBC) and pT2-4 tumor was classified as muscle-invasive bladder cancer (MIBC).

Immunohistochemistry Staining

The tissues were cut into 4mm sections, deparaffinized three times with xylol for 5 minutes each, and rehydrated through graded alcohol. Antigen retrieval was accomplished by incubation for 10 minutes in sodium citrate buffer (pH 6.0). Afterward, the tissue sections were incubated with monoclonal antibodies for EMMPRIN (1.BB.218: sc-71038; dilution 1:250; Santa Cruz Biotechnology) and EGFR (0.N.268: sc-71034; dilution 1:100; Santa Cruz Biotechnology) overnight, followed by a secondary antibody for 10 minutes at room temperature. Sections were then counterstained with hematoxylin and dehydrated with alcohol. Human placental tissue was used as a positive control for EGFR

while human gastric tissue was used as a positive control for EMMPRIN.

Evaluation of Immunohistochemical Expression

All samples were evaluated by two pathologists in the blinded fashion. Any discordant was solved by interobserver agreement. Membranous and cytoplasmic staining of EMMPRIN and EGFR were evaluated on the basis of the percentage of stained tumor cells and the staining intensity of the tumor cells. The staining intensity for both EMMPRIN and EGFR was scored as 0 (absent), 1 (weak), 2 (moderate), and 3 (strong). For EMMPRIN, the percentage of stained tumor cells was scored as 0 for no 0 - <10% positive cells; 1, 10% - 24%; 2, 25% - 49%; 3, 50% - 74%; and 4, 75%. The sum of the percentage of stained tumor cells and the staining intensity score was then used as the final EMMPRIN score. Final scores of 0 to 1 were considered negatives, 2 to 3 were considered weak, 4 to 5 were considered moderate, and 6 to 7 were considered strong⁹.

For EGFR evaluation, the percentage of stained cells score was slightly different from EMMPRIN, as follows: 0 for no positive cells; 1, 1-25%; 2, 26-50%; 3, 51-75%; and 4, >75%. Then, a final score was obtained by multiplying the score of staining intensity and percentage of stained cells: a score of 0 was considered negative, 1-4 was weak, 5-8 was moderate, and 9 - 12 was strong¹¹.

Statistical Analysis

All statistical analysis was calculated using SPSS v.25.0. The comparison of EMMPRIN and EGFR expression was tested using the Mann Whitney U test. The correlation was analyzed using the Spearman test, with a significance level <0.05 ($p < 0.05$).

Results and Discussion

The average age of patients was 60.6 ± 9.4 years with a male to female ratio of 50:4. In the study, muscle-invasive bladder cancer (MIBC) was found in 81.5% (44/54) cases, whereas non-muscle-invasive bladder cancer (NMIBC) was only found in 18.5% (10/54) cases. Around 87% of the cases (47/54) were high-grade, whereas 13% (7/54) were low-grade.

EMMPRIN Expression in Urothelial Carcinoma

EMMPRIN was found to be expressed at the plasma membrane and/or cytoplasm (Figure 1). We compared EMMPRIN expression between non-muscle-invasive and muscle-invasive bladder cancer, also between low grade and high-grade tumors. A significant difference of EMMPRIN expression was found between the non-muscle-invasive and muscle-invasive tumors ($p = 0.000$), while no significant difference of EMMPRIN expression was found between the low grade and high-grade tumor ($p = 0.105$). Strong EMMPRIN expression was mainly found in tumors with muscle invasion (52.3%), while none of the non-muscle-invasive tumors showed strong EMMPRIN expression. Spearman correlation test showed a highly significant positive correlation between EMMPRIN expression and muscle invasion of the tumor ($r_s = 0.481, p = 0.000$) (Table 1).

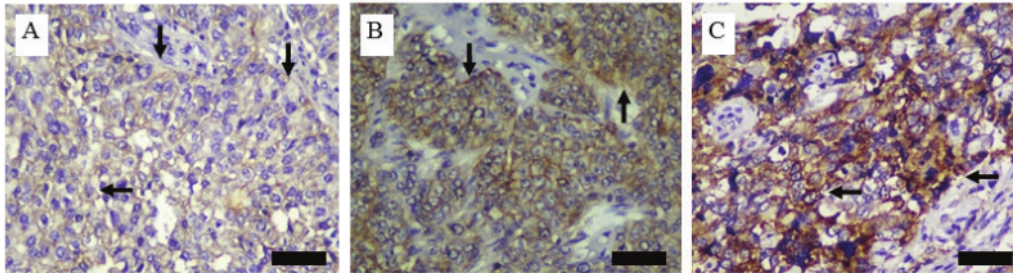


Figure 1. Immunohistochemical expression of EMMPRIN in urothelial carcinoma (brown stain in membrane and/or cytoplasm), 400x magnification. **A:** Weak intensity staining of EMMPRIN; **B:** Moderate intensity staining of EMMPRIN; **C:** Strong intensity staining of EMMPRIN. Black arrows: EMMPRIN expression; black bars: 50 μm.

Table 1. Association between EMMPRIN expression with muscle invasion and tumor grade.

	EMMPRIN Expression				p-value a	rs b	p-value b
	Negative n (%)	Weak n (%)	Moderate n (%)	High n (%)			
Muscle Invasion					0.000	0.481	0.000
Absent (pT1) / NMIBC	1 (10)	3 (30)	6 (60)	0 (0)			
Present (pT2-4) / MIBC	0 (0)	3 (6.8)	18 (40.9)	23 (52.3)			
Tumor Grade					0.105	-	-
Low Grade	1 (14.2)	2 (28.6)	2 (28.6)	2 (28.6)			
High Grade	0 (0)	4 (8.5)	22 (46.8)	21 (44.7)			

^aMann Whitney U test applied.

^bSpearman correlation test applied.

p-value <0.05, considered as significant.

EGFR Expression in Urothelial Carcinoma

EGFR was found to be expressed at the plasma membrane and/or cytoplasm (Figure 2). We compared EGFR expression between non-muscle-invasive and muscle-invasive bladder cancer, also between low grade and high-grade tumors. We observed a significant difference of EGFR between the non-muscle-invasive and muscle-invasive tumors ($p = 0.020$), while no significant difference of EGFR expression was found between the low grade and high-grade tumor ($p = 0.079$). Moderate and strong EGFR expressions were only found in the muscle-invasive tumor, while the non-muscle-invasive tumor only showed negative and weak EGFR expression. Spearman correlation test showed a significant positive correlation between EGFR expression and muscle invasion of the tumor ($r_s = 0.319$, $p = 0.019$) (Table 2).

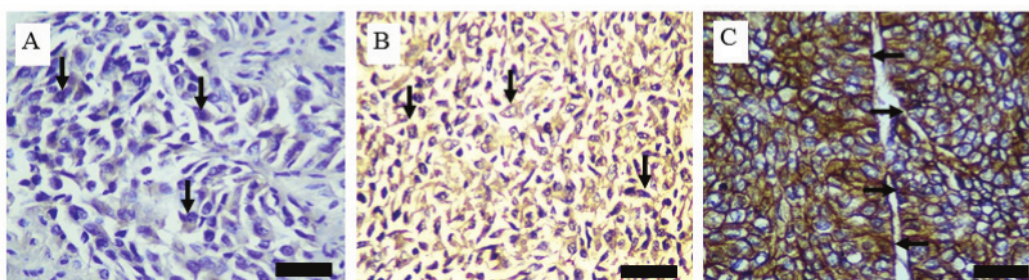


Figure 2. Immunohistochemical expression of EGFR in urothelial carcinoma with 400× magnification. A: Weak intensity staining of EGFR; B: Moderate intensity staining of EGFR; C: Strong intensity staining of EGFR. Black arrows: EGFR expression; black bars: 50 μm.

Table 2. Association between EGFR expression with muscle invasion and tumor grade.

	EGFR Expression				<i>p</i> -value ^a	<i>r_s</i> ^b	<i>p</i> -value ^b
	Negative n (%)	Weak n (%)	Moderate n (%)	High n (%)			
Muscle Invasion					0.020	0.319	0.019
Absent (pT1) / NMIBC	6 (60)	4 (40)	0 (0)	0 (0)			
Present (pT2-4) / MIBC	11 (25)	24 (54.5)	7 (16)	2 (4.5)			
Tumor Grade					0.079	-	-
Low Grade	4 (57.1)	3 (42.9)	0 (0)	0 (0)			
High Grade	13 (27.7)	25 (53.2)	7 (14.9)	2 (4.2)			

^aMann Whitney U test applied.

^bSpearman correlation test applied.

p-value < 0.05, considered as significant.

Correlation between EMMPRIN and EGFR in Urothelial Carcinoma

²⁹ A significant positive correlation was found between EMMPRIN and EGFR expression in urothelial carcinoma ($r_s = 0.322, p = 0.018$).

Discussion

The age of the patients observed in this study ranged from the age of 34 to 81 years (mean 60.6 ± 9.4). In this study, the majority of the patients had muscle-invasive bladder cancer/MIBC (pT2-4) (81.5%), whereas non-muscle-invasive bladder cancer/NMIBC (pT1) was only found in 18.5% of the cases. Our study showed that EMMPRIN expression was significantly different between non-muscle-invasive bladder cancer/NMIBC (pT1) and muscle-invasive bladder cancer/MIBC (pT2-4), and EMMPRIN expression is significantly correlated with the muscle invasion, with a positive r-value of 0.481. Similar results were reported by other studies, showing a significant difference of EMMPRIN expression between superficial (pT1) and muscle-invasive (pT2) urothelial carcinoma^[10]. Another study found that negative or low EMMPRIN expression was strongly correlated with non-muscle-invasive urothelial carcinoma (pT1 tumor) compared to muscle-invasive urothelial carcinoma (pT2-4 tumor)^[6]. EMMPRIN stimulates the tumor cells and peritumoral fibroblasts to produce matrix metalloproteinases (MMPs), which then degrade the extracellular matrix of basement membranes, which normally play a role as mechanical barriers to tumor cell migration and invasion^[11]. EMMPRIN induce MMPs production through the MKK-p38-MAPKAP signaling pathway, and the induction of MMPs by EMMPRIN occurs at the transcription level^[12].

Regarding EGFR expression, a significant difference of EGFR expression was also found between non-muscle-invasive bladder cancer/NMIBC (pT1) and muscle-invasive bladder cancer/MIBC (pT2-4), and EGFR expression is significantly correlated with the muscle invasion in this study with a positive r-value of 0.319. This result is in accordance with a prior study that found a significant association between EGFR expression and muscle invasion in urothelial carcinoma, with strong EGFR expression, which was mainly found in the muscle-invasive tumor, while negative and weak EGFR expression was mainly found in the non-muscle-invasive

tumor. A prior study found that EGFR overexpression was significantly associated with tumor grade which is in contrast with the result of this study that found no significant association between EGFR expression and tumor grade^[4]. Several studies showed that basal tumors of urothelial carcinoma expressed high levels of EGFR, CD49 and Cyclin D1. A prior study showed no EGFR mutations were identified in all urothelial carcinoma cases observed, hence it was hypothesized that EGFR overexpression is the result of deregulation of the protein recycling and degradation pathway^[13]. EGFR expression is higher in urothelial carcinoma than in normal urothelium^[14]. EGFR signaling triggers Ras activation, this process can increase MAPK activity, which activates important regulators of the epithelial-mesenchymal transition^[3].

³³ We found that EMMPRIN expression was significantly correlated with EGFR expression with a positive r-value of 0.322. To our knowledge, this correlation has not been reported in urothelial carcinoma, although another study described a correlation between the two markers in colorectal adenocarcinoma^[15]. A prior study suggested that EGFR might play a role in regulating EMMPRIN expression and is relevant for the tumor invasion in urothelial carcinoma^[16]. Elevated EMMPRIN expression was able to stimulate hyaluronan production in tumor cells and hyaluronan is the main ligand for the cell surface receptor CD44. Hyaluronan and CD44 interaction induce the assembly of lipid raft-associated complexes containing EMMPRIN, CD44 and EGFR^[17,18,19].

Conclusion

The expression of EMMPRIN and EGFR are potentially significant biomarkers of urothelial carcinoma invasiveness and that may be helpful to discriminate between muscle-invasive and non-muscle invasive bladder cancer, where urothelial carcinoma with EMMPRIN and EGFR overexpression is found more likely in urothelial carcinoma with muscle invasion. The EMMPRIN and EGFR overexpression further help to determine the patients who need more radical treatment.

⁴ **Conflict of Interest:** The authors declare that they have no conflict of interest.

Source of Funding: None.

Acknowledgements: We thank Dr. Budi Utomo, dr., M.Kes. and all of the lecturers in Department of Anatomical Pathology, Faculty of Medicine, Universitas Airlangga for the guidance in finishing this study. We additionally thank Putri Amaristya Purwono and Arif Nur Muhammad Ansori for editing the manuscript.

Ethical Approval: This study had been approved by the Health Research Ethics Committee of Dr. Soetomo General Hospital, Surabaya (Ethical Clearance No. 1534/KEPK/IX/2019).

References

- Li W, Wang Y. Overexpression of Epidermal Growth Factor Receptor (EGFR) and HER-2 in Bladder Carcinoma and Its Association with Patients' Clinical Features. *Med Sci Monit.* 2018; 24: 7178–7185.
- Humphrey PA, Moch H, Cubilla AL, *et al.* The 2016 WHO Classification of Tumours of the Urinary System and Male Genital Organs—Part B: Prostate and Bladder Tumours. *European urology.* 2016; 70: 106-119.
- Knowles MA, Hurst CD. Molecular biology of bladder cancer: New insights into pathogenesis and clinical diversity. *Nat Publ Gr.* 2015; 15: 25–41.
- Hashmi AA, Hussain ZF, Irfan M, *et al.* Prognostic significance of epidermal growth factor receptor (EGFR) over expression in urothelial carcinoma of urinary bladder. *BMC Urol.* 2018; 1–6.
- Liu B, Wan Z, Sheng B, *et al.* Overexpression of EMMPRIN is associated with lymph node metastasis and advanced stage of non-small cell lung cancer: A retrospective study. *BMC Pulm Med.* 2017; 17: 1–9.
- El-Rehim DMABD, Mohamed N, Abd R. Expression of extracellular matrix metalloproteinase inducer and fascin in urinary bladder cancer: Correlation with clinicopathological characteristics. *Mol Clin Oncol.* 2013; 1: 297–304.
- Xu J, Lu Y, Qiu S, *et al.* A novel role of EMMPRIN/CD147 in transformation of quiescent fibroblasts to cancer-associated fibroblasts by breast cancer cells. *Cancer Lett.* 2013; 335: 380–386.
- Guéguinou M, Gambade A, Félix R, *et al.* Lipid rafts, KCa/CICa/Ca²⁺ channel complexes and EGFR signaling: Novel targets to reduce tumor development by lipids?. *Biochim Biophys Acta - Biomembr.* 2015; 1848: 2603–2620.
- Monteiro LS, Delgado ML, Ricardo S, *et al.* EMMPRIN expression in oral squamous cell carcinomas: Correlation with tumor proliferation and patient survival. *Biomed Res Int.* 2014; 2014: 1–9.
- Wittschieber D, Klauschen F. Decreased RECK and increased EMMPRIN expression in urothelial carcinoma of the bladder are associated with tumor aggressiveness. *Pathobiology.* 2011; 123–131.
- Sato M, Nakai Y, Nakata W, *et al.* EMMPRIN Promotes Angiogenesis, Proliferation, Invasion and Resistance to Sunitinib in Renal Cell Carcinoma, and Its Level Predicts Patient Outcome. *PLoS One.* 2013; 8: 1–10.
- Xin X, Zeng X, Gu H, *et al.* CD147 / EMMPRIN overexpression and prognosis in cancer: A systematic review and meta-analysis. *Sci Rep.* 2016; 113: 1–12.
- Mooso BA, Vinnall RL, Mudryj M, *et al.* The Role of EGFR Family Inhibitors in Muscle Invasive Bladder Cancer: A Review of Clinical Data and Molecular Evidence. *J Urol.* 2016; 193: 19–29.
- Black PC, Dinney CPN. Growth Factors and Receptors as Prognostic Markers in Urothelial Carcinoma. *Curr Urol Rep.* 2008; 9: 55–61.
- Jin J, Wu C, Lin Y, *et al.* Higher expression of epidermal growth factor receptor is associated with extracellular matrix metalloproteinase inducer in colorectal adenocarcinoma: Tissue microarray analysis of immunostaining score with clinicopathological parameters. *Dis Markers.* 2006; 22: 309–316.
- Grass GD, Tolliver LB, Bratoeva M, *et al.* CD147, CD44, and the epidermal growth factor receptor (EGFR) signaling pathway cooperate to regulate breast epithelial cell invasiveness. *J Biol Chem.* 2013; 288: 26089–26104.
- Grass GD, Dai L, Qin Z, *et al.* CD147: Regulator of hyaluronan signaling in invasiveness and chemoresistance. In: *Hyaluronan Signaling and Turnover.* 1st ed. Elsevier Inc. 123: 351–373; 2014.
- Huang S, Ren X, Wang L, *et al.* Lung-cancer chemoprevention by induction of synthetic lethality in mutant KRAS premalignant cells in vitro and in

- vivo. *Cancer Prev Res.* 2011; 4: 666–673.
19. Kong LM, Liao CG, Zhang Y, *et al.* A regulatory loop involving miR-22, Sp1, and c-Myc modulates CD147 expression in breast cancer invasion and metastasis. *Cancer Res.* 2014; 74: 3764–3778.

C11 The Correlation of EMMPRIN and EGFR Overexpression toward Muscle Invasiveness in Urothelial Carcinoma of Bladder

ORIGINALITY REPORT

17%

SIMILARITY INDEX

13%

INTERNET SOURCES

14%

PUBLICATIONS

0%

STUDENT PAPERS

PRIMARY SOURCES

1	esou17.uroweb.org Internet Source	1%
2	Katia Piton Serra, Raquel Mary Rodrigues Peres, Luis Otávio Sarian, José Vassallo et al. "Cyclooxygenase-2 (COX2) and p53 protein expression are interdependent in breast cancer but not associated with clinico-pathological surrogate subtypes, tumor aggressiveness and patient survival.", Acta Histochemica, 2016 Publication	1%
3	bmcmmedicine.biomedcentral.com Internet Source	1%
4	old.jsp.org.pk Internet Source	1%
5	worldwidescience.org Internet Source	1%
6	www.labome.org Internet Source	

1 %

7

tel.archives-ouvertes.fr

Internet Source

1 %

8

Ping Zhang, Lijuan Tang, Huanhuan Gao, Hua Xu, Wenxin Zhang, Jianxian Lin, Shuxia Chen. "An Immunohistochemical Study of Epidermal Growth Factor Receptor in Sebaceous Carcinoma of the Eyelid: A Potential Therapeutic Target", *Ophthalmic Plastic & Reconstructive Surgery*, 2022

Publication

1 %

9

Pratistadevi K. Ramdial, Sameer S. Nadvi, Rene Mallett. "Cervical Spine Dysraphism with Teratoma Exhibiting Pulmonary Differentiation: Case Report and Review of the Literature", *Pediatric and Developmental Pathology*, 2019

Publication

1 %

10

josr-online.biomedcentral.com

Internet Source

1 %

11

repository.unair.ac.id

Internet Source

1 %

12

Lingling Gao, Mingjun Zheng, Qian Guo, Xin Nie, Xiao Li, Yingying Hao, Juanjuan Liu, Liancheng Zhu, Bei Lin. "Downregulation of Rab23 inhibits proliferation, invasion, and

1 %

metastasis of human ovarian cancer", The International Journal of Biochemistry & Cell Biology, 2019

Publication

13

Mohan Adithi, Mallikarjuna Kandalam, Hema L. Ramkumar, Ayshwarya Subramanian, Nalini Venkatesan, Subramanian Krishnakumar.

"Retinoblastoma: Expression of HLA-G", Ocular Immunology and Inflammation, 2009

Publication

1 %

14

academic.oup.com

Internet Source

1 %

15

ijp.iranpath.org

Internet Source

1 %

16

Marie-Lisa Eich, Lars Dyrskjøt, George J. Netto. "Toward personalized management in bladder cancer: the promise of novel molecular taxonomy", Virchows Archiv, 2017

Publication

<1 %

17

Tomoko Umeda, Mitsuaki Ishida, Satoshi Murata, Tsuyoshi Mori et al. "Immunohistochemical analyses of CD44 variant isoforms in invasive micropapillary carcinoma of the breast: comparison with a concurrent conventional invasive carcinoma of no special type component", Breast Cancer, 2015

Publication

<1 %

18	tcr.amegroups.com Internet Source	<1 %
19	www.nature.com Internet Source	<1 %
20	e-journal.unair.ac.id Internet Source	<1 %
21	Jang, K.S.. "Id-1 overexpression in invasive ductal carcinoma cells is significantly associated with intratumoral microvessel density in ER-negative/node-positive breast cancer", Cancer Letters, 20061208 Publication	<1 %
22	bmcpulmed.biomedcentral.com Internet Source	<1 %
23	pub2.db.tokushima-u.ac.jp Internet Source	<1 %
24	www.redorbit.com Internet Source	<1 %
25	G. Daniel Grass, Lu Dai, Zhiqiang Qin, Chris Parsons, Bryan P. Toole. "CD147", Elsevier BV, 2014 Publication	<1 %
26	Xu, Jing, Yang Lu, Songbo Qiu, Zhi-Nan Chen, and Zhen Fan. "A novel role of EMMPRIN/CD147 in transformation of quiescent fibroblasts to cancer-associated	<1 %

fibroblasts by breast cancer cells", Cancer Letters, 2013.

Publication

27

datasheets.scbt.com

Internet Source

<1 %

28

downloads.hindawi.com

Internet Source

<1 %

29

tessera.spandidos-publications.com

Internet Source

<1 %

30

"3. Berliner Woche der Pathologie", Der Pathologe, 2010

Publication

<1 %

31

G. Daniel Grass, Lauren B. Tolliver, Momka Bratoeva, Bryan P. Toole. "CD147, CD44, and the Epidermal Growth Factor Receptor (EGFR) Signaling Pathway Cooperate to Regulate Breast Epithelial Cell Invasiveness", Journal of Biological Chemistry, 2013

Publication

<1 %

32

docksci.com

Internet Source

<1 %

33

legacy.impactjournals.com

Internet Source

<1 %

34

www.mdpi.com

Internet Source

<1 %

35

"Gastrointestinal", Modern Pathology,
02/2005

Publication

<1 %

36

Li, Z.. "VEGF-C as a Decision-making
Biomarker for Selected Patients with Invasive
Bladder Cancer Who Underwent Bladder-
preserving Radical Surgery", Archives of
Medical Research, 201107

Publication

<1 %

37

Yetti Hernaningsih, Ersya Bayung Maulidan.
"Chapter 4 Examination of Laboratory for
Monitoring Heparin Anticoagulant Therapy",
IntechOpen, 2020

Publication

<1 %

38

Baolei Wu, Jianhua Wei, Zhiqiang Hu, Chun
Shan, Lei Wang, Chenping Zhang, Xi Yang,
Xinjie Yang, Delin Lei. "Slug silencing inhibited
perineural invasion through regulation of
EMMPRIN expression in human salivary
adenoid cystic carcinoma", Tumor Biology,
2015

Publication

<1 %

39

Xiuyun Tian, Chunxiang Ye, Yongyong Yang,
Xiaoya Guan, Bin Dong, Min Zhao, Chunyi
Hao. "Expression of CD147 and matrix
metalloproteinase-11 in colorectal cancer and
their relationship to clinicopathological

<1 %

features", Journal of Translational Medicine, 2015

Publication

Exclude quotes On

Exclude matches Off

Exclude bibliography On

C11 The Correlation of EMMPRIN and EGFR Overexpression toward Muscle Invasiveness in Urothelial Carcinoma of Bladder

GRADEMARK REPORT

FINAL GRADE

/0

GENERAL COMMENTS

Instructor

PAGE 1

PAGE 2

PAGE 3

PAGE 4

PAGE 5

PAGE 6

PAGE 7
