

MALAYSIAN ORTHOPAEDIC JOURNAL



*Official Journal of the
Malaysian Orthopaedic Association*

The journal is indexed/abstracted by PubMed Central, PubMed, SCOPUS, Emerging Source Citation Index (ESCI),
Directory Open Access Journal (DOAJ), APAMED Central, Western Pacific Region Index Medicine (WPRIM),
Index Copernicus, ASEAN Citation Index (ACI), Google Scholar, MyAn and MyCite


Volume 15

Issue Number 2

July 2021

ISSN No: 1985-2533

ISSN No: PP 15451/06/20130032812



MOJ Editorial Board

Chief Editor

Saw Aik

Editorial Board

1	Abdul Hamid Abdul Kadir	Assunta Hospital, Petaling Jaya, Malaysia
2	Abdul Razak Sulaiman	Universiti Sains Malaysia, Kubang Kerian, Malaysia
3	Aree Tanavalee	Chulalongkorn Memorial Hospital, Bangkok, Thailand
4	Awang Bulgiba Awang Mahmud	University of Malaya, Kuala Lumpur, Malaysia
5	Azlina Amir Abbas	University of Malaya, Kuala Lumpur, Malaysia
6	Denny Lie Tjauw Tjoen	Singapore General Hospital, Singapore
7	Chris Chan Yin Wei	University of Malaya, Kuala Lumpur, Malaysia
8	Edward H M Wang	University of the Philippines, Manila, Philippines
9	Ifran Saleh	University of Indonesia, Jakarta, Indonesia
10	Ismail Hadisoebroto Dilogo	University of Indonesia, Jakarta, Indonesia
11	Joyce Koh Suang Bee	Singapore General Hospital, Singapore
12	Kamarul Ariffin Khalid	International Islamic University Malaysia, Malaysia
13	Maung Mg Htwe	University of Medicine, Mandalay, Myanmar
14	Mohammad Anwar Hau Abdullah	Raja Perempuan Zainab II Hospital, Kota Bharu, Malaysia
15	Mohd Imran Yusof	Universiti Sains Malaysia, Kubang Kerian, Malaysia
16	Ng Kwan Hoong	University of Malaya, Kuala Lumpur, Malaysia
17	Sharaf Ibrahim	Universiti Kebangsaan Malaysia, Kuala Lumpur, Malaysia
18	Sharifah Roohi Syed Waseem Ahmad	Pantai Hospital, Kuala Lumpur, Malaysia
19	Srijit Das	Universiti Kebangsaan Malaysia, Kuala Lumpur, Malaysia
20	Tunku Kamarul Zaman Tunku Zainol Abidin	University of Malaya, Kuala Lumpur, Malaysia
21	Tunku Sara Ahmad	University of Malaya, Kuala Lumpur, Malaysia
22	Wan Faisham Nu'man Wan Ismail	Universiti Sains Malaysia, Kubang Kerian, Malaysia

Asean Regional Editorial Board

1	Howe Tet Sen	Singapore General Hospital, Singapore
---	--------------	---------------------------------------

2	James Hui	National University Health System, Singapore
3	Ketan C Pande	Raja Isteri Pengiran Anak Saleha Hospital, Bandar Seri Begawan, Brunei
4	Luthfi Gatam	University of Indonesia, Jakarta, Indonesia
5	Myint Thuang	University of Medicine, Yangon, Myanmar
6	Nathaniel Orillaza	University of the Philippines, Manila, Philippines
7	Nguyen Le Bao Tien	Hanoi Medical University, Hanoi, Vietnam
8	Saranatra Waikakul	Mahidol University, Bangkok, Thailand
9	Vo Van Thanh	University of Pharmacy and Medicine, Ho Chi Minh City, Vietnam

International Editorial Board

1	Aziz Nather	National University Health System, Singapore
2	Benjamin Joseph	Medcare Orthopaedics & Spine Hospital, Dubai, United Arab Emirates
3	Christopher Mow	Stanford University Medical Center, California, United States
4	Kaye E Wilkins	Christus Santa Rosa Children's Hospital, San Antonio, United States
5	Ken N Kuo	Shriners Hospitals for Children, Chicago, USA
6	Lee Eng Hin	National University Health System, Singapore
7	Wilfred Peh	Khoo Teck Puat Hospital, Singapore

Editorial Secretary

Ain Syuhada Kalip

Editorial Assistant

Nursyafeira Nabella Shofian

Administration Secretary

Uma Sundaram

MOJ Webmaster

Teng Kim Teng

Copy Editor

Gracie Ong Siok Yan
Mohamed Razif Mohamed Ali
Marzida Mansor

Publisher

Malaysian Orthopaedic Association

Printer

Digital Perspective Sdn Bhd

Secretariat

Malaysian Orthopaedic Journal

Unit 2-6, Level 2, Enterprise 3B, Technology Park Malaysia (TPM),
Jalan Innovasi 1, Lebuhraya Puchong-Sg. Besi, 57000 Bukit Jalil,
Kuala Lumpur, Malaysia

Tel: +603 8996 6300

Fax: +603 8996 6400

Email: morthoj@gmail.com (<mailto:morthoj@gmail.com>)

Website: <http://www.morthoj.org> (<http://www.morthoj.org>)

About Us

The *Malaysian Orthopaedic Journal* is a peer-reviewed journal that is published three times a year in both print and electronic online version. The purpose of this journal is to publish original research studies, evaluation of current practices and case reports in various subspecialties of orthopaedics and traumatology, as well as associated fields like basic science, biomedical engineering, rehabilitation medicine and nursing.

MOJ Menu

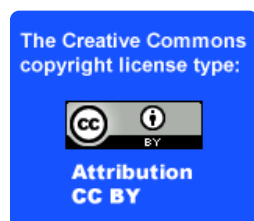- › About MOJ (/about-moj.php)
- › About ASEAN Edition of MOJ (/about-ASEAN-edition-moj.php)
- › Editorial Board (/editorial.php)
- › Editorial Process (/editorial-process.php)
- › Panel of Reviewers (/panel-reviewers.php)
- › Links (/links.php)

Quick Links

- › Manuscript Submission
(<http://www.editorialmanager.com/moj/default.aspx>)
- › Reviewers Submission
(<http://www.editorialmanager.com/moj/default.aspx>)
- › Instructions for Authors (/instructions-for-authors.php)
- › Past Issues (/past-issues.php)
- › Instructions for Advertisers (/instructions-for-advertisers.php)
- › Search MOJ (/search.php)

Keep in Touch

f (<https://www.facebook.com/mojorthopaedicjournal>)
in (<https://www.linkedin.com/company/mojorthopaedic-journal-335589108>)



(<https://creativecommons.org/licenses/>)

Current Issue - July 2021, Volume 15, Issue No. 2

Official Journal of Malaysian Orthopaedic Association and ASEAN Orthopaedic Association

[Home \(index.php\)](#)


[f \(https://doi.org/10.1111/moj.12451\)](#) [in \(https://pubmed.ncbi.nlm.nih.gov/pubmed/33612345\)](#)

Indexed by & Member of

- > Pubmed Central (<http://www.ncbi.nlm.nih.gov/pmc/>)
- > Pubmed (<https://pubmed.ncbi.nlm.nih.gov/>)
- > SCOPUS (<https://www.scopus.com/home.uri>)
- > Emerging Sources Citation Index (ESCI)
(<http://mj1.clarivate.com/cgi-bin/jrnlist/jlresults.cgi?PC=EX>)
- > DOAJ (<https://doaj.org/>)
- > APAMED Central (<http://apamedcentral.org/>)
- > WPRIM (<http://www.wprim.org/>)
- > Asean Citation Index (<http://www.asean-cites.org/>)
- > Google Scholar (<https://scholar.google.com>)
- > Global Index Medicus
(<http://www.globalhealthlibrary.net/php/index.php>)
- > Index Copernicus (<https://journals.indexcopernicus.com/>)
- > MyAis (<http://www.my-ais.org/>)
- > MyCite (<http://www.mycite.my/>)
- > COPE (<http://publicationethics.org>)
- > WAME (<http://www.wame.org/>)
- > APAME (<http://www.wpro.who.int/entity/apame/about/en/>)
- > Council of Science Editors (<http://www.councilscienceeditors.org/>)
- > Malaysia Citation Centre (<http://mycc.my/>)

ISSN Print: 1985-2533

ISSN Electronic: 2232-111X



Contents for July 2021, Volume 15, Issue No. 2 (2021/v15n2/contents.pdf)

SPECIAL ARTICLES

Explaining Osteomyelitis and Prosthetic Joint Infections (PJI) in terms of Biofilm – A Review 📄

(2021/v15n2/osteomyelitis-prosthetic-biofilm.pdf)

Singh S, Tan CL, Ahmad AR

Abstract 📄 (2021/v15n2/osteomyelitis-prosthetic-biofilm-abstract.php) | Reference 📄 (2021/v15n2/osteomyelitis-prosthetic-biofilm-reference.php)

Transcolumnar” a better Terminology than “Transverse” in Judet-Letournel Classification of Acetabular Fractures?

📄 (2021/v15n2/transcolumnar-judet-letournel.pdf)

Sood A

Abstract 📄 (2021/v15n2/transcolumnar-judet-letournel-abstract.php) | Reference 📄 (2021/v15n2/transcolumnar-judet-letournel-reference.php)

Malaysian Orthopaedic Journal (MOJ) has participated in the initiative to make publications on COVID-19 and coronavirus related conditions immediately accessible in PubMed Central (PMC) and other public repositories. For further information, please refer to : Public Health Emergency COVID-19 Initiative (<https://www.ncbi.nlm.nih.gov/pmc/about/covid-19/>)

ORIGINAL ARTICLES

Comparison of Bone-Patellar Tendon-Bone Graft, Semitendinosus–Gracilis Graft and Semitendinosus–Gracilis with Preserved Tibial Insertion Graft in Anterior Cruciate Ligament Reconstruction in Sports Persons 📄
(2021/v15n2/anterior-cruciate-sports.pdf)

Soni A, Gupta RK, Raghav M, Masih GD, Bansal P

Abstract 📄 (2021/v15n2/anterior-cruciate-sports-abstract.php) | Reference 📄 (2021/v15n2/anterior-cruciate-sports-reference.php)

Association between Psychological Status and Functional Outcome in Surgically Managed Fractures around Hip in Geriatric Patients - A Prospective Study 📄 (2021/v15n2/hip-fractures-in-geriatric.pdf)

Bishnoi S, Huda N, Islam SMU, Pant A, Agarwal S, Dholariya R

Abstract 📄 (2021/v15n2/hip-fractures-in-geriatric-abstract.php) | Reference 📄 (2021/v15n2/hip-fractures-in-geriatric-reference.php)

Angular Deformities of the Knee in Children Treated with Guided Growth 📄 (2021/v15n2/deformities-knee.pdf)

Jamil K, Yahaya MY, Abd-Rasid AF, Ibrahim S, Abdul-Rashid AH

Abstract 📄 (2021/v15n2/deformities-knee-abstract.php) | Reference 📄 (2021/v15n2/deformities-knee-reference.php)

Axillary versus Forearm Crutches: A Prospective Cohort Comparing which is Superior for 3-Point Crutch Gait 📄 (2021/v15n2/axillary-forearm-crutches.pdf)

Yap WMQ, Hairodin Z, Kwek EBK

Abstract 📄 (2021/v15n2/axillary-forearm-crutches-abstract.php) | Reference 📄 (2021/v15n2/axillary-forearm-crutches-reference.php)

Normal Baseline Values for Isometric Shoulder Strength in Scaption for the Healthy Filipino Individuals Aged 20 to 30 Years Old 📄 (2021/v15n2/isometric-shoulder-strength.pdf)

Lorenzo PH, Nunez R

Abstract 📄 (2021/v15n2/isometric-shoulder-strength-abstract.php) | Reference 📄 (2021/v15n2/isometric-shoulder-strength-reference.php)



Functional Outcome and Complications in Management of Proximal Humerus Fractures Operated with Proximal Humerus Locking Plate 📄 (2021/v15n2/proximal-humerus-locking.pdf)


George PK, Dasgupta B, Bhaladhare SM, Reddy BPV, Jain A, Jogani AD

Abstract 📄 (2021/v15n2/proximal-humerus-locking-abstract.php) | Reference 📄 (2021/v15n2/proximal-humerus-locking-reference.php)



Early Clinical and Functional Outcome of Rotator Cuff Tendinopathy of the Shoulder Treated with Platelet Rich Plasma Injection 📄 (2021/v15n2/rotator-cuff-tendinitis.pdf)


Pritem AR, Abraham VT, Krishnagopal R

Abstract  (2021/v15n2/rotator-cuff-tendinitis-abstract.php) | Reference  (2021/v15n2/rotator-cuff-tendinitis-reference.php)



Thoracic Spine Stenosis: Does Ultrasonic Osteotome Improve Outcome in Comparison to Conventional Technique?  (2021/v15n2/thoracic-spine-stenosis.pdf)


Krishnan A, Samal P, Mayi S, Degulmadi D, Rai RR, Dave B

Abstract  (2021/v15n2/thoracic-spine-stenosis-abstract.php) | Reference  (2021/v15n2/thoracic-spine-stenosis-reference.php)



Are Dropped Bone Grafts Safe to be Re-used? - An Experimental Study Comparing Efficacy of Chlorhexidine, Povidone-Iodine and Alcohol  (2021/v15n2/dropped-bone-chlorhexidine.pdf)


Mat-Salleh MF, Sadagatullah AN, Ibrahim MY, Abdul-Aziz I, Wan-Abdullah WA, Maning N, Md-Hassan MN, Ab-Rashid MR

Abstract  (2021/v15n2/dropped-bone-chlorhexidine-abstract.php) | Reference  (2021/v15n2/dropped-bone-chlorhexidine-reference.php)



Nutritional Status and Health-Related Quality of Life among Knee and Hip Osteoarthritis Patients under Rehabilitation Care in Kuala Nerus, Terengganu, Malaysia  (2021/v15n2/nutritional-knee-hip-osteoarthritis.pdf)


Zamri NAA, Harith S, Mat-Hassan N, Ong YQ

Abstract  (2021/v15n2/nutritional-knee-hip-osteoarthritis-abstract.php) | Reference  (2021/v15n2/nutritional-knee-hip-osteoarthritis-reference.php)



Results of ala carte Posteromedial Soft Tissue Release in Idiopathic Clubfoot  (2021/v15n2/posteromedial-tissue-clubfoot.pdf)


Barik S, Das L, Yadav AK, Arora SS, Singh V

Abstract  (2021/v15n2/posteromedial-tissue-clubfoot-abstract.php) | Reference  (2021/v15n2/posteromedial-tissue-clubfoot-reference.php)

Platelet Rich Plasma Injection for Soft Tissue Musculoskeletal Pain  (2021/v15n2/plasma-injection-musculoskeletal.pdf)


Irianto KA, PhD, Bakri AH, MD, Kloping N

Abstract  (2021/v15n2/plasma-injection-musculoskeletal-abstract.php) | Reference  (2021/v15n2/plasma-injection-musculoskeletal-reference.php)



Mismatch between Conventional Femoral Arthroplasty Stems and Hip Morphology in the Elderly Chinese Hip Fracture Population  (2021/v15n2/femoral-stems.pdf)


Siow JWX, Kwek EBK

Abstract  (2021/v15n2/femoral-stems-abstract.php) | Reference  (2021/v15n2/femoral-stems-reference.php)



Mortality Following Hip Fracture Surgery During COVID-19 Pandemic Compared to Pre-COVID-19 Period: A Case Matched Cohort Series  (2021/v15n2/mortality-surgery-covid19.pdf)


De C, Harbham PK, Postoyalko C, Bhavanasi B, Paringe V, Theivendran K

Abstract  (2021/v15n2/mortality-surgery-covid19-abstract.php) | Reference  (2021/v15n2/mortality-surgery-covid19-reference.php)



Early Clinical Outcomes of Short versus Long Proximal Femoral Nail Anti-rotation (PFNA) in the Treatment of Intertrochanteric Fractures  (2021/v15n2/femoral-nail-intertrochanteric.pdf)


Loh JLM, Huang DME, Lei J, Yeo W, Wong MK

Abstract  (2021/v15n2/femoral-nail-intertrochanteric-abstract.php) | Reference  (2021/v15n2/femoral-nail-intertrochanteric-reference.php)



Anxiety Reaction in Children During Cast Removal using Oscillating Saw versus Cast Shear - A Randomised, Prospective Trial  (2021/v15n2/anxiety-cast-removal.pdf)


Mohamed-Zain NA, Jamil K, Penafort R, Singh A, Ibrahim S, Abdul-Rashid AH

Abstract  (2021/v15n2/anxiety-cast-removal-abstract.php) | Reference  (2021/v15n2/anxiety-cast-removal-reference.php)



Functional Outcome of Surgical Stabilisation of Acetabular Fractures  (2021/v15n2/acetabular-fractures.pdf)


Fakru NH, Faisham WI, Hadizie D, Yahaya S

Abstract  (2021/v15n2/acetabular-fractures-abstract.php) | Reference  (2021/v15n2/acetabular-fractures-reference.php)



Mortality Rate and Ten Years Survival of Elderly Patients Treated with Total Hip Arthroplasty for Femoral Neck Fractures  (2021/v15n2/total-hip-arthroplasty.pdf)


Nanchappan NS, Chopra S, Samuel A, Therumurte L, Ganapathy SS

Abstract  (2021/v15n2/total-hip-arthroplasty-abstract.php) | Reference  (2021/v15n2/total-hip-arthroplasty-reference.php)



C-reactive protein (CRP) and Erythrocyte Sedimentation Rate (ESR) Trends following Total Hip and Knee Arthroplasties in an Indian Population – A Prospective Study  (2021/v15n2/CRP-ESR-indian.pdf)

Krishna A, Garg S, Gupta S, Bansal H

Abstract  (2021/v15n2/CRP-ESR-indian-abstract.php) | Reference  (2021/v15n2/CRP-ESR-indian-reference.php)

Functional Outcome of Open Latarjet Procedure in Non-Athletic Middle-Aged Patients  (2021/v15n2/open-latarjet-procedure.pdf)

Joshi S, Rao VKV, Shetty UC, Rai S, Arora S, Kumar SR

Abstract  (2021/v15n2/open-latarjet-procedure-abstract.php) | Reference  (2021/v15n2/open-latarjet-procedure-reference.php)

CASE REPORTS

Introducing a Novel Method of Patella Tendon Defunctioning Using Suture Anchors After a Tibial Tuberosity Avulsion Repair: Report of Three Cases 📄 (2021/v15n2/defunctioning-patella-tendon.pdf)

Cheong EJY, Tan LTJ

Abstract 📄 (2021/v15n2/defunctioning-patella-tendon-abstract.php) | Reference 📄 (2021/v15n2/defunctioning-patella-tendon-reference.php)

Removing a Bent Femoral Intramedullary Nail Cost Effectively: A Case Report 📄 (2021/v15n2/bent-intramedullary-nail.pdf)

Sa'aid SH, Bajuri MY, Dzeidee-Schaff FN, Abdul-Suki MH

Abstract 📄 (2021/v15n2/bent-intramedullary-nail-abstract.php) | Reference 📄 (2021/v15n2/bent-intramedullary-nail-reference.php)

Aneurysmal Bone Cyst of the Lateral Malleolus Treated with Intralesional Curettage and Masquelet Technique: A Case Report 📄 (2021/v15n2/aneurysmal-bone-cyst.pdf)

Gaspar M Jr, Lasam MP, Carag JA, Malana J

Abstract 📄 (2021/v15n2/aneurysmal-bone-cyst-abstract.php) | Reference 📄 (2021/v15n2/aneurysmal-bone-cyst-reference.php)

Distal Humeral Shaft Fracture with Simultaneous Ipsilateral Supracondylar Humeral Fracture in a Child: A Case Report 📄 (2021/v15n2/supracondylar-humeral-fracture.pdf)

Talal JA, Abdulmuhsen NA, Rakan MK

Abstract 📄 (2021/v15n2/supracondylar-humeral-fracture-abstract.php) | Reference 📄 (2021/v15n2/supracondylar-humeral-fracture-reference.php)

LETTER TO EDITOR

Vitamin D in Ankle Fractures 📄 (2021/v15n2/vitamin-D-ankle-fractures.pdf)

Sinha NK, Sinha RK

Reference 📄 (2021/v15n2/vitamin-D-ankle-fractures-reference.php)

BOOK REVIEW

Something Doesn't Add Up: Surviving Statistics in a Post-Truth Age 📄 (2021/v15n2/book-review.pdf)

Paul Goodwin and reviewed by Ren Yi Kow

Orthopaedic Clinical Quiz (2021/v15n2/orthopaedic-clinical-quiz.pdf)

Answer to Orthopaedic Clinical Quiz (2021/v15n2/orthopaedic-clinical-answer.pdf)

Instructions for Authors (2021/v15n2/instructions-for-authors.pdf)

Future Events (2021/v15n2/future-events.pdf)

Executive Committee of Malaysian Orthopaedic Association 2020-2021 (2021/v15n2/committee-MOA.pdf)

Platelet Rich Plasma Injection for Soft Tissue Musculoskeletal Pain

Irianto KA¹, PhD, Bakri AH², MD, Kloping NA³, MD

¹Department of Orthopaedics and Traumatology, Universitas Airlangga, Surabaya, Indonesia

²Department of Orthopaedics, Surabaya Orthopedic and Traumatology Hospital, Surabaya, Indonesia

³Faculty of Medicine, Universitas Airlangga, Surabaya, Indonesia



This is an open-access article distributed under the terms of the Creative Commons Attribution License, which permits unrestricted use, distribution, and reproduction in any medium, provided the original work is properly cited

Date of submission: 28th July 2020
Date of acceptance: 19th February 2021

ABSTRACT

Introduction: Treating soft tissue injuries can be a challenge for physicians as it can be overlooked which can lead to more problems. In recent studies, the use of Platelet Rich Plasma (PRP) has been gaining popularity for soft tissue injuries because of its benefits and minimal side effects. This study aims to evaluate the effect of PRP injection on various musculoskeletal soft tissues inflammation.

Materials and methods: This is a retrospective study of patients with soft tissue injury who underwent PRP therapy between 2015 and 2018 at an orthopaedic and traumatology hospital. The study collected demographic data including the type of soft tissue injury and Visual Analog Scale (VAS) before and after the PRP injection. Those data were statistically analysed to identify the significance of PRP.

Results: Seventy-six patients were included, predominantly female, middle aged (40-69 years old) and class one obesity. Most of the complaints (61.8%) were in the lower extremity region. Pain improvements measured with mean VAS score were observed in both acute (3.06 ± 1.28 to 0.8 ± 0.65) and chronic (4 ± 1.75 to 0.97 ± 0.62) cases. There was a significant decrease of VAS score before and after the PRP injection ($p < 0.000$).

Conclusion: PRP injection is able to alleviate both acute and chronic pain in soft tissue injuries without additional analgesic.

Keywords:

soft tissues inflammation, platelet-rich plasma, chronic pain

INTRODUCTION

Soft tissue pain is frequently overlooked and may lead to debilitating conditions. This problem occurs mainly among people with high physical workload such as athletes^{1,2}. Soft tissues generally include muscles, fascia, tendon, cartilage,

synovium, fibrous capsules, nerves, and ligament, nearly every element beside bones¹. Surgery is a prevalent option for patients who have persistent symptoms of pain². However, recent studies are trying to focus on anti-inflammatory regimens with greater benefits than surgery. Currently non-surgical approaches include physiotherapy, activity modification, steroid injections, and non-steroidal anti-inflammatory drugs (NSAID)³. Even though steroid injections displayed a positive outcome of pain relief, there were reports of harmful effects such as tendon degeneration and muscle atrophy⁴. One of the suggested natural regimens rich in anti-inflammatory agents is platelet-rich plasma (PRP)^{2,4,5}.

PRP is an autologous blood product which contains four to five times more platelets than the normal value². The platelets and leucocytes in the PRP have the capability of releasing numerous growth factors, namely platelet-derived growth factor (PDGF), vascular endothelial growth factor (VEGF), epithelial growth factor (EGF), and transforming growth factor beta (TGF- β). This modality has been investigated intensively to foster healing of various musculoskeletal soft tissue diseases, especially soft tissue pain due to excessive or repetitive activities including tendinopathy and injured muscle. Although PRP injection has minor side effects to a certain degree, the advantages of not having cross reactivity and immune reaction or disease transmission risks are much more valuable. PRP can be the lead alternative for soft tissue pain therapy due to its autologous nature^{2,3,6}.

Despite positive reports regarding its efficacy, the use of PRP in specific musculoskeletal soft tissues is limited. This study aims to seek the efficacy of PRP injection on the inflammation of various musculoskeletal soft tissues as a stand-alone therapy regimen.

MATERIALS AND METHODS

This retrospective study has been approved by the Internal Institutional Review Board of Surabaya Orthopaedic and Traumatology Hospital. Prior to drawing blood, informed consent was obtained from each patient. Patients' data from between January 2015 and December 2018 were extracted from medical records. The inclusion criteria for the study were adult patients who were diagnosed with musculoskeletal soft tissue inflammation, treated with PRP injection, and had their pain measured with VAS before and after the surgery. Meanwhile, patients with incomplete medical record and who had received additional analgesic after PRP injection were excluded from the study. Demographic data such as subject's age, sex, body mass index (BMI), duration of pain, confounding disease, and site of lesion were also added. In this study, patients' BMI were classified based on Asia-Pacific population classification as underweight (<18.5), normal (18.5 – 22.9), overweight (23 – 24.9), obese I (25 – 29.9), and obese II (> 30).

Soft tissue inflammation is defined as non-infectious, non-trauma inflammation involving musculoskeletal structures other than the bone or joint. All soft tissue inflammation cases were diagnosed by orthopaedic surgeons and were grouped into upper and lower extremity based on their anatomical location. There were no limitations of the type of soft tissue inflammation. During the duration of the complaints, samples were categorised into acute pain (< 6 weeks) and chronic pain (> 6 weeks).

The process of collecting PRP was conducted by the hospital laboratory. First, we collected 10 cc of the patient's peripheral blood. Then the blood was processed and separated in a tube of Z-gel containing ACD (Adenine Citrate Dextrose) anticoagulant using high-speed centrifuge (RCF 2500 G) for 10 minutes. Three separate layers were produced: plasma, buffy coat (platelet), and red blood cells. The thick buffy coat layer, rich in platelet and growth factors, were collected and directly injected within 5 minutes to the subcutaneous tissue of the inflammation site. The bump was slowly massaged to help spread the PRP around the inflammation site. In this study, we made sure to avoid injecting tendon, ligament, as well as the vascular region in the inflammation site.

VAS was measured to define pain before and after the injection. Pain was categorised based on the scale range of 0 (no pain), 1-3 (mild pain), 4-6 (moderate pain), and 7-10 (severe pain). The post-treatment pain score was measured during the patients' following visit, ranging from 3 weeks to 3 months. Quantitative data were described in terms of mean \pm standard deviation. Statistical analysis was performed with SPSS software [version 23.0; SPSS Inc, Chicago, IL, USA]. Paired Samples T-Test was used to determine the significant difference of VAS on pre-post PRP injection. A value of $p < 0.05$ indicates the result is statistically significant.

RESULTS

A total of 134 patients were first included in this study. However, 58 samples were excluded as the patients had received additional analgesic after injection. The final total was 76 subjects. The participants were primarily female (55.3%), middle-aged (40 - 69 years), and classified as obese I (42.1%). More than half (56.6%) had confounding disease, and 59.2% were in chronic pain. The baseline characteristics of the subjects are presented in Table I. The distribution of the type of musculoskeletal soft tissue lesions were similar in both acute and chronic cases. Lateral epicondylitis (tennis elbow) is the most frequent case in the upper extremity group, whereas plantar fasciitis is the most prevalent case in the lower extremity group (Fig. I). Other cases in the upper extremity group included common extensor tendon tear, rotator cuff syndrome, subscapularis partial tear, and a particular case of both supraspinatus tendon tear and subscapularis tendinosis in one patient. Meanwhile, cases in the lower extremity group consisted of achilles tendon tear, ATFL tear, flexor digitorum longus tear, gastrocnemius partial tear, iliotibial band bursitis, labral tear hip, osteochondral defect, posterior tibialis tendon dysfunction, and lastly a case of both ATFL and CFL tear.

The result of VAS evaluation is displayed in Table II. Patients in both acute and chronic group only reported that they felt mild to no pain after PRP injection (VAS: 0-3). Moreover, in the acute group there were only reports of pain with VAS scores of 0-2. The Paired Samples T-test revealed that both acute and chronic pain were significantly ($p < 0.000$) reduced after the injection (Table III).

DISCUSSION

PRP's efficacy comes from the various growth factors which are released from alpha granules of activated platelets, specifically platelet-derived growth factor (PDGF), epidermal growth factor (EGF), transforming growth factor-beta 1 (TGF- β 1), vascular endothelial growth factor (VEGF), basic fibroblast growth factor (FGF), hepatocyte growth factor (HGF), and insulin-like growth factor (IGF-I)^{2,3,6,7}. The degranulation also acts as chemoattractant for macrophages to take part in the healing process⁸. Based on previous literatures, increased platelet concentration is believed to escalate the total growth factors released, which enhance healing and the regeneration process^{2,6,9,10}. The enhancement of the migratory ability leads to a better regeneration capability and slows down the natural progression of the disease. PRP works gently and will heal the microenvironment of the lesion⁷.

The characteristics of our subjects were similar to other patients in different centres¹¹. We found that the majority of the patients with soft tissue injuries were female (42%). Although we did not account for any correlation between

Table I: Subjects' characteristics

Baseline characteristics		N (%)
Sex	Male	34 (44.7)
	Female	42 (55.3)
Age (range: 15 - 83 years)	< 30 yrs.	10 (13.2)
	30-39 yrs.	11 (14.4)
	40-49 yrs.	11 (14.4)
	50-59 yrs.	23 (30.3)
	60-69 yrs.	16 (21.1)
	>70 yrs.	5 (6.6)
BMI	Underweight (< 18.5)	1 (1.3)
	Normal (18.5-22.9)	16 (21.1)
	Overweight (23-24.9)	21 (27.6)
	Obese I (25-29.9)	32 (42.1)
	Obese II (≥ 30)	6 (7.9)
Duration of Pain	Acute	31 (40.8)
	Chronic	45 (59.2)
Confounding Disease	Yes	43 (56.6)
	No	33 (43.4)
Site of Lesion	Upper Extremity	29 (38.2)
	Lower Extremity	47 (61.8)

Table II: VAS evaluation before and after PRP injection

	Before PRP Injection	After PRP Injection
Acute Soft Tissue Inflammation		
VAS (Mean ± SD)	3.06 (±1.28)	0.8 (±0.65)
Degree of Pain (N (%))	VAS	VAS
No pain	0 (0)	9 (29)
Mild pain (1-3)	21 (67.7)	22 (71)
Moderate pain (4-6)	10 (32.3)	0 (0)
Severe pain (>7)	0 (0)	0 (0)
Chronic Soft Tissue Inflammation		
VAS (Mean ± SD)	4 (±1.75)	0.97 (±0.62)
Degree of Pain (N (%))	VAS	VAS
No pain	0 (0)	9 (38.3)
Mild pain (1-3)	21 (46.7)	36 (61.7)
Moderate pain (4-6)	21 (46.7)	0 (0)
Severe pain (>7)	3 (6.6)	0 (0)

Table III: Paired T-Test evaluating the significance of PRP injection

		N	Mean VAS	Std Dev.	Mean difference	T	df	p value
Acute Pain	Before	31	3.06	1.28	2.25 (± 1.23)	10.16	30	<0.000
	After	31	0.80					
Chronic Pain	Before	45	4.00	1.75	3.02 (± 1.54)	13.125	44	<0.000
	After	45	0.97					

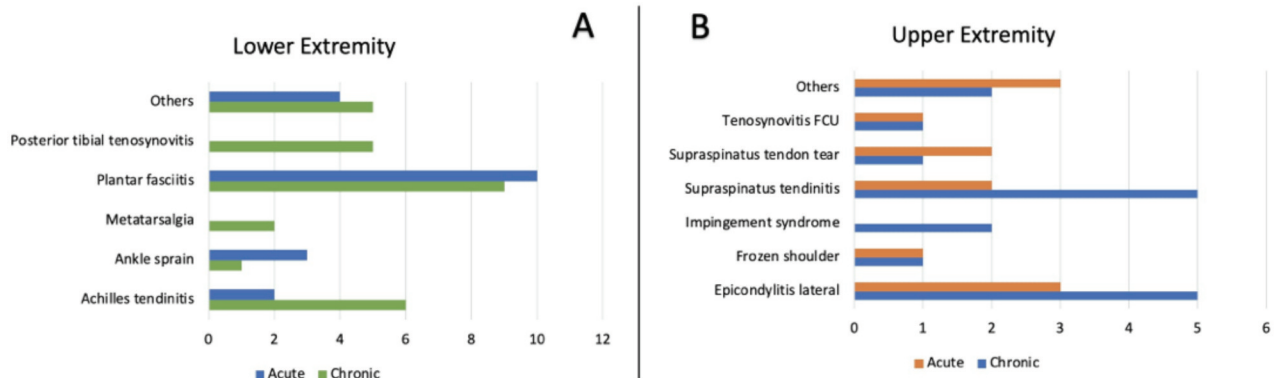


Fig. 1: Distribution of soft tissue inflammation (upper extremity and lower extremity). (a) Chronic pain. (b) Acute pain.

gender and PRP, previous studies reported that there was not enough evidence to suggest gender plays a significant role in the outcome of PRP therapy^{12,13}. The patients' age (40 - 69 years old) reveals that the lesions were mostly found in people who were still relatively active, which might impair their daily activities and will further worsen in time¹³. The predominant age may also reflect the confounding diseases found in each patient. Diabetes and hypertension are notoriously frequent in this age range. Whilst this study did not correlate confounding diseases with pain, the improvements in VAS score implied that systemic condition did not have an effect on PRP modulation. Inflamed tendon lesions are often instigated by chronic microinjuries due to excessive repetitive stress^{10,14,15}. Patients whose injuries were sustained from jobs with extensive movement such as manual handling of heavy loads and demanding handgrip forces, or those with repetitive movement should be considered¹¹ for this form of therapy. Certain activities or sports such as soccer and tennis are known to be the major causes of achilles tendinitis and lateral epicondylitis^{14,16}. Some soft tissue injuries are also linked to high BMI. This may be caused by a higher loading force, particularly in the lower extremity of obese patients. Obesity is associated with prolonged low-grade inflammation and impaired insulin sensitivity⁷. In addition, enlargement of the diameter of tendon fibre with the shortening of its modulus could weaken the fibre's ability to resist stress and reduce its healing process capacity. This is also supported by the fact that almost 70% of our patients were overweight and obese.

The pain relief may not be as potent as those from the use of corticosteroid or NSAID. However, PRP will stimulate the healing process⁴, thus the prolonged use of NSAID could be avoided. This was seen in various studies about plantar fasciitis which reported that PRP is capable of treating chronic pain^{8,17,18}. After six months of follow-up, PRP showed a better outcome compared to corticosteroid injection in the management of elbow epicondylitis¹⁹. Conversely, there was no significant difference between PRP and corticosteroid in short to intermediate settings¹⁷. These findings were in concordance with our study where PRP has a significant value in treating both acute and chronic pain, with a considerably better result in chronic pain with a mean difference of 3.02 (± 1.54).

Some surgeons are reluctant to prescribe PRP as a stand-alone treatment without additional analgesic regimen. This hesitation could be avoided by understanding the basic role and function of PRP. It is not necessary to inject the plasma directly to the tendon or ligament. Instead, the purpose of PRP injection is to enrich the surrounding inflamed locus. Our method is to inject it subcutaneously to the loose connective tissue, then gently massage the bump to disperse PRP evenly around the inflamed region. Another important element is to meticulously prepare the patient's blood into a ready-to-use PRP that is then injected within five minutes before a clot could form.

This study had limitations as well. The design of this study is retrospective which could raise some biases and confounding factors which could influence the outcome. Further studies that can focus on one type of inflammation would be beneficial. Despite the favourable outcome, we acknowledge double-blinded RCTs with large sample sizes are needed before standardising PRP as the sole treatment modality for soft tissue inflammation.

CONCLUSION

Our study indicates that PRP injection can provide both short-term and long-term relief in soft tissue musculoskeletal inflammation without any additional analgesic.

ACKNOWLEDGMENT

The authors would like to express their utmost gratitude to all Orthopaedic and Traumatology Hospital staff. There was no grant involved in supporting this work.

CONFLICT OF INTEREST

The authors declare no potential conflict of interest.

REFERENCES

1. Wright B. Management of Chronic Soft Tissue Pain. *Top Companion Anim Med.* 2010; 25(1): 26-31. doi: 10.1053/j.tcam.2009.10.004
2. Hussain N, Johal H, Bhandari M. An evidence-based evaluation on the use of platelet rich plasma in orthopedics – a review of the literature. *Sicot J.* 2017; 3: 57. doi: 10.1051/sicotj/2017036
3. Hastie G, Soufi M, Wilson J, Roy B. Platelet rich plasma injections for lateral epicondylitis of the elbow reduce the need for surgical intervention. *J Orthop.* 2018; 15(1): 239-41. doi: 10.1016/j.jor.2018.01.046
4. Gautam VK, Verma S, Batra S, Bhatnagar N, Arora S. Platelet-rich plasma versus corticosteroid injection for recalcitrant lateral epicondylitis: Clinical and ultrasonographic evaluation. *J Orthop Surg (Hong Kong).* 2015; 23(1): 1-5. doi: 10.1177/230949901502300101
5. Niewczas P, Kotela A, Łęgosz P, Pirko-Kotela K, Sarzyńska S, Starczyńska M. Use of platelet-rich plasma in orthopaedics and traumatology. *Med Stud.* 2016; 32(1): 63-8. doi: 10.5114/ms.2016.58808
6. Kloping YP, Desnantyo AT, Rehatta NM. The Effects of Platelet-Rich-Plasma (PRP) Injection on Ligament Injury. *Bali Med J.* 2016; 5(1): 31-7. doi: 10.15562/bmj.v5i1.174
7. Alves R, Grimalt R. A Review of Platelet-Rich Plasma: History, Biology, Mechanism of Action, and Classification. *Ski Appendage Disord.* 2018; 4(1): 18-24. doi: 10.1159/000477353
8. Soraganvi P, Nagakiran KV, Raghavendra-Raju RP, Anilkumar D, Wooly S, Basti BD, et al. Is platelet-rich plasma injection more effective than steroid injection in the treatment of chronic plantar fasciitis in achieving long-term relief? *Malays Orthop J.* 2019; 13(3): 8-14. doi: 10.5704/MOJ.1911.002
9. Sengodan VC, Kurian S, Ramasamy R. Treatment of Partial Rotator Cuff Tear with Ultrasound-guided Platelet-rich Plasma. *J Clin Imaging Sci.* 2017; 7(1): 32. doi: 10.4103/jcis.JCIS_26_17
10. Franceschi F, Papalia R, Paciotti M, Franceschetti E, Martino A Di, Maffulli N, et al. Obesity as a risk factor for tendinopathy: A systematic review. *Int J Endocrinol.* 2014; 2014: 670262. doi: 10.1155/2014/670262
11. Walker-Bone K, Palmer KT, Reading I, Coggon D, Cooper C. Occupation and epicondylitis: a population-based study. *Rheumatology (Oxford).* 2012; 51(2): 305-10. doi: 10.1093/rheumatology/ker228
12. Evanson JR, Guyton MK, Oliver DL, Hire JM, Topolski RL, Zumbrun SD, et al. Gender and Age Differences in Growth Factor Concentrations From Platelet-Rich Plasma in Adults. *Mil Med.* 2014; 179(7): 799-805. doi: 10.7205/MILMED-D-13-00336
13. Taniguchi Y, Yoshioka T, Sugaya H, Goshio M, Aoto K, Kanamori A, et al. Growth factor levels in leukocyte-poor platelet-rich plasma and correlations with donor age, gender, and platelets in the Japanese population. *J Exp Orthop.* 2019; 6(1): 4-11. doi: 10.1186/s40634-019-0175-7
14. Lipman K, Wang C, Ting K, Soo C, Zheng Z. Tendinopathy: Injury, repair, and current exploration. *Drug Des Devel Ther.* 2018; 12: 591-603. doi: 10.2147/DDDT.S154660
15. Petraglia F, Ramazzina I, Costantino C. Plantar fasciitis in athletes: Diagnostic and treatment strategies. A systematic review. *Muscles Ligaments Tendons J.* 2017; 7(1): 107-18. doi: 10.11138/mltj/2017.7.1.107
16. Middleton KK, Barro V, Muller B, Terada S, Fu FH. Evaluation of the effects of platelet-rich plasma (PRP) therapy involved in the healing of sports-related soft tissue injuries. *Iowa Orthop J.* 2012; 32: 150-63.
17. Ling Y, Wang S. Effects of platelet-rich plasma in the treatment of plantar fasciitis. *Medicine (Baltimore).* 2018; 97(37): e12110. doi: 10.1097/MD.00000000000012110
18. Yang WY, Han YH, Cao XW, Pan JK, Zeng LF, Lin JT, et al. Platelet-rich plasma as a treatment for plantar fasciitis. *Medicine (Baltimore).* 2017; 96(44): e8475. doi: 10.1097/MD.00000000000008475
19. Varshney A, Maheshwari R, Juyal A, Agrawal A, Hayer P. Autologous platelet-rich plasma versus corticosteroid in the management of elbow epicondylitis: A randomized study. *Int J Appl Basic Med Res.* 2017; 7(2): 125-8. doi: 10.4103/2229-516X.205808