

# INTERNATIONAL JOURNAL OF SURGERY CASE REPORTS

Advancing surgery through shared experience



ERUDITIO • DILIGENTIA • FIDES

EST. 2003



INTERNATIONAL JOURNAL OF  
**SURGERY CASE REPORTS**  
The Largest Journal Publishing Surgical Case Reports

ADVERTISEMENT

Lc

[Articles & Issues](#) [For Authors](#) [For Reviewers](#) [Journal Info](#) [Sister Journals](#) [Thomas Starzl Prize](#) [Submit Your Manuscript](#)

All Content Search [Advanced Search](#)

## Editorial Board

### Editor-in-Chief

**David Rosin**, Bridgetown, Barbados

### Managing and Executive Editor

**Riaz Agha**, London, England, UK

### Senior Editors

**R.Y. Afifi**, Cairo, Egypt

**H. Alam**, Ann Arbor, USA

**J. P. Barret**, Barcelona, Spain

**B. Challacombe**, London, UK

**X-P. Chen**, Wuhan, China

**R.L. De Wilde**, Oldenburg, Germany

**B. Ekser**, Indianapolis, USA

**H.B. Hechtman**, Boston, USA

**J. W. Y. Lau**, Shatin, Hong Kong

**O. Muensterer**, Mainz, Germany

**S. Rogers**, Chicago, USA

**J. Talati**, Karachi, Pakistan

**M. Thorat**, London, UK

**F.C. Wei**, Taipei, Taiwan

### Associate Editors

**R. Coppola**, Rome, Italy

**V. Kasivisvanathan**, London, UK

**R Keijzer**, Winnipeg, Canada

**B Kirshtein**, Beer-Sheva, Israel

**J.A. McCaul**, Bradford, UK

**E.R. McGlone**, London, UK

**D. Muzumdar**, Mumbai, India

**A Petroianu**, Belo Horizonte, Brazil

**S.G. Raja**, London, UK

**K Raveendran**, Ipoh, Malaysia

**D. Yeh**, Boston, USA

#### Assistant Editors

**R. Al-mahfoudh**, Oxford, England, UK

**H. M. Atta**, Boston, Massachusetts, USA

**M. Bashashati**, Calgary, Canada

**S. Basu**, Varanasi, India

**A. Beamish**, Gothenburg, Sweden

**A. G. Charles**, Chapel Hill, North Carolina, USA

**A. Das**, Hyderabad, India

**M.E. Erdil**, Istanbul, Turkey

**S. A. Esquivel Gaón**, Mexico

**J. Gómez Rivas**, Madrid, Spain

**H. Kaafarani**, Boston, Massachusetts, USA

**Y. D. Kamat**

**O. Khan**, London, UK

**T. Manning**, Melbourne, Victoria, Australia

**I. Mukherjee**, Staten Island, USA

**E Ofo**, Adelaide, South Australia

**S. Pai**, Mumbai, India

**S. Feng**, Shanghai, China

**A. Smailys**, Kaunas, Lithuania

**D.G. Weber**, Perth, Australia

**H. Zhu**, Shanghai, China

#### Statistical Editors

**N. Donaldson**, Colombia, South America

**M.W. Gray**, Washington DC, USA

#### Society Representatives

**X.P. Chen**, President of the Chinese Chapter of International Hepato-Pancreato-Biliary Association

**G.F. Coppa**, President of the New York Surgical Society

**A. Williams**, President, Association of Surgeons in Training

#### Executive Committee

**Professor D.K.C Cooper**, Pittsburgh, USA

**A. Darzi**, London, England, UK

**H. Ellis**, London, England, UK

**Sir G. Catto**, London, UK

**Sir B. Jackson**, London, UK

**Professor S. Standring**, London, UK

**Lord R. Winston**, London, UK

**Sir N. Williams**, London, UK

**C.-H. Leong**, Hong Kong, China

**A. Li K-C.**, Wanchai, Hong Kong

**I. McColl**, London, UK

**J. Norcini**, Philadelphia, USA

**M. Yacoub**, London, England, UK

## Editorial Board

**R. A. Badwe**, Mumbai, India

**M. Boscoe**, Middlesex, England, UK

**R. Bueno**, Boston, USA

**K. Chatamra**, Bangkok, Thailand

**P. Coulthard**, Manchester, UK

**A. d'Cruz**, Mumbai, India

**M. Desai**, Mumbai, India

**W. Green**, London, UK

**I. Harirchi**, Tehran, Iran

**D. Henne-Bruns**, Ulm, Germany

**D. Kahn**, Cape Town, South Africa

**X. Lin**, Shanghai, China

**A. Mahapatra**, New Delhi, India

**I. Mitra**, Mumbai, India

**V. Naraynsingh**, West Indies

**F. Nicoli**, London, England, UK

**A. Núñez De Pierro**, Buenos Aires, Argentina

**R. Orda**, Tel Aviv, Israel

**V. Semiglazov**, St Petersburg, Russia

**T. Singh**, Ludhiana, India

**B.L. Smith**, Boston, USA

**T.E. Udwardia**, Mumba, India

**M. C. Warlé**, Nijmegen, Netherlands

**J. Wee**, Boston, Massachusetts, USA

**M. Weiser**, New York, USA

**Y. Zhang**, Shanghai, China

**J Zhong**, Shanghai, China

[Articles & Issues](#) ▾ [About](#) ▾ [Publish](#) ▾ 

## Actions for selected articles

[Select all](#) / [Deselect all](#) [Download PDFs](#) [Export citations](#) [Show all article previews](#)

Vania Myralda Giamour Marbun, Agi Satria Putranto  
Pages 338-344

[Download PDF](#) [Article preview](#) ▾

Case report • [Open access](#)

### Unusual presentation of primary myelofibrosis with spontaneous bleeding after laparoscopic adrenalectomy: A case report

Sara Colozzi, Benedetta Costantini, Serena Rupoli, Attilio Olivieri, ... Mario Guerrieri  
Pages 345-347

[Download PDF](#) [Article preview](#) ▾

Case report • [Open access](#)

### Malignant transformation of oral squamous cell papilloma: a case report

Reem Hassan Saad, Samir Mohamed Halawa, Ahmed Mohamed Zidan, Nashwa Mohamed Emara, Omar Abdellatif Abdelghany  
Pages 348-351

[Download PDF](#) [Article preview](#) ▾

Case report • [Open access](#)

### Glomus tumor-induced lower extremity pain: A case report

Laskar Pradnyan Klopung, Lukas Widhiyanto, Komang Agung Irianto, Oen Sindrawati, Yudhistira Pradnyan Klopung  
Pages 352-356

[Download PDF](#) [Article preview](#) ▾

Case report • [Open access](#)

### Huge perinephric hematoma after ureteroscopy and pneumatic lithotripsy for ureteral stone; A life-threatening rare complication: Case report and review of literature

Adel Alrabadi, Hammam Mansi, Sohaib Alhamss, Saddam Al Demour, Mahmoud Odeh  
Pages 357-360

[Download PDF](#) [Article preview](#) ▾

Case report • [Open access](#)

### Gastric neuroendocrine tumor with *Helicobacter pylori*-associated chronic gastritis

Giovanni Serio, Armando Dell'Anna, Anna Debenedittis, Elisa Stasi, Maria Arcangela Cascarano  
Pages 361-366

[Download PDF](#) [Article preview](#) ▾

Case report • [Open access](#)

### Oral management in a patient with Gardner-Diamond Syndrome: A case report



Contents lists available at ScienceDirect

## International Journal of Surgery Case Reports

journal homepage: [www.casereports.com](http://www.casereports.com)

## Glomus tumor-induced lower extremity pain: A case report

Laskar Pradnyan Kloping<sup>a</sup>, Lukas Widhiyanto<sup>a</sup>, Komang Agung Irianto<sup>a,\*</sup>,  
Oen Sindrawati<sup>b</sup>, Yudhistira Pradnyan Kloping<sup>c</sup><sup>a</sup> Department of Orthopaedic and Traumatology, Faculty of Medicine, Airlangga University, Dr. Soetomo General Hospital, Surabaya, Indonesia<sup>b</sup> Department of Pathology, Faculty of Medicine, Widya Mandala Catholic University, Surabaya, Indonesia<sup>c</sup> Medical Faculty of Universitas Airlangga, Jl. Prof. Dr Moestopo 6-8, Surabaya, 60115, Indonesia

## ARTICLE INFO

## Article history:

Received 12 August 2020

Received in revised form

12 September 2020

Accepted 12 September 2020

Available online 17 September 2020

## Keywords:

Glomus tumor

Chronic pain

Lower extremity pain

Case report

## ABSTRACT

**INTRODUCTION:** Glomus tumor located in the lower limb could be easily mistaken as lower extremity pain whether it is radiating, sciatic, or just a localized one. This could lead to misdiagnosis and improper management.

**PRESENTATION OF CASE:** This case reported a 56-year-old man complaining of pain in his left thigh. The pain was characterized as sharp and sometimes radiated to the skin of the calf muscles region. There was no history of trauma. Physical examination of the left thigh region revealed a small and barely palpable deep subcutaneous mass. Ultrasound examination showed a 6 × 5.3 mm partly cystic subcutaneous mass in the posteromedial region of the left distal femur. Doppler USG showed that the blood flow in the cystic lesion originated from the medial genicular artery. Surgical tumor excision through the medial femoral approach exposed a 15 × 10 × 5 mm yellowish-white thin encapsulated subdermal tumor attached to the vascular wall. Histopathology examination resulted in a Glomus Tumor.

**DISCUSSION:** Glomus tumor usually occurs in areas that are rich in glomus bodies. Thigh is not a specific location for glomus bodies. It presented as bluish small nodule that are sensitive to touch and temperature changes. Glomus tumors in the thigh region rarely recurs since they are solitary and encapsulated, making them easily recognizable from the surrounding tissue during the operation.

**CONCLUSION:** Meticulous history taking, physical examination, and imaging modalities are necessary to differentiate between tumor and non-tumor lesions in less common areas.

© 2020 The Authors. Published by Elsevier Ltd on behalf of IJS Publishing Group Ltd. This is an open access article under the CC BY-NC-ND license (<http://creativecommons.org/licenses/by-nc-nd/4.0/>).

## 1. Introduction

Glomus tumor is a rare small benign perivascular tumor, which develops from the glomus body located in the reticular dermis [1]. Glomus bodies are thermoregulatory neuro-myoarterial structure that arise from arterio-venous anastomoses and are enveloped by condensed collagenous tissue [2]. The vascular lumens are surrounded by several layers of modified smooth muscle cells (glomus cells). These structures are found in the fingers and toes and are responsible for regulating the temperature and tone of blood vessels, as well as sensory functions [2,3]. Although the exact etiology is still unclear, glomus tumor is thought to arise from skin arteriovenous anastomosis [3]. This tumor usually appears as a painful, firm, purplish blue, solitary subcutaneous nodule around the fingernail. It is generally small, but the average tumor size in lower extremity was slightly above 2 cm, in contrast to the more typical location in the tip of finger, under the nail. Symptoms include

burning pain at the tumor site, which occurs spontaneously or is triggered by changes in temperature or touch [1,4]. It is quite different when the tumor is located in the lower limb where the undergarment and trouser would swiftly touch the surface of the tumor. The pain could be easily mistaken to lower extremity pain whether it is radiating, sciatic, or just a localized one [5,6].

When a patient complains of chronic pain in the lower limb, the diagnoses of low back pain is always in the perimeter, especially when the pain is starting to restrict the mobility. All lower back pain examination including imaging such as MRI would be scheduled. When the imaging revealed a frequently found protruded nucleus pulposus, or mild canal stenosis, or bone spurs, it could lead to misdiagnosis and delays in handling the neoplasm itself [4,7]. A case report of lower extremity “deep” seated glomus tumor is presented to be discussed from the perspective of simple yet meticulous physical diagnosis and thorough imaging findings. This case report has been reported in line with the SCARE criteria [8].

## 2. Case presentation

A 56 years old male complained of pain in the inner back site of the left thigh for six years, which worsened in the last two years. The

\* Corresponding author at: Dr. Soetomo General Hospital, Medical Faculty of Airlangga University, Jl. Prof. Dr Moestopo 6-8, Surabaya, 60115, Indonesia.  
E-mail address: [komang168@yahoo.com](mailto:komang168@yahoo.com) (K.A. Irianto).

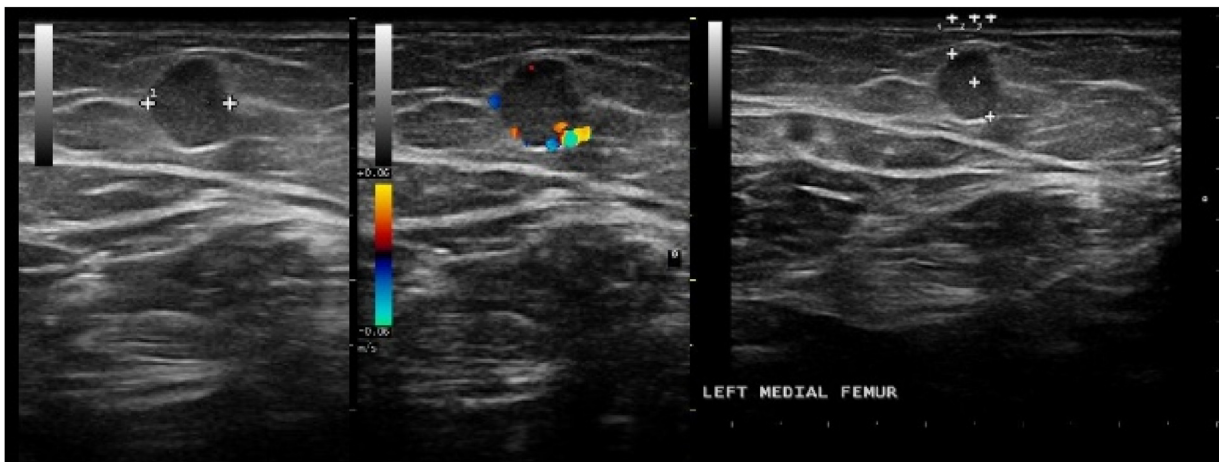


Fig. 1. USG showed a 6 × 5.3 mm round oval subcutaneous cystic lesion in the posteromedial area of the distal femoral region.

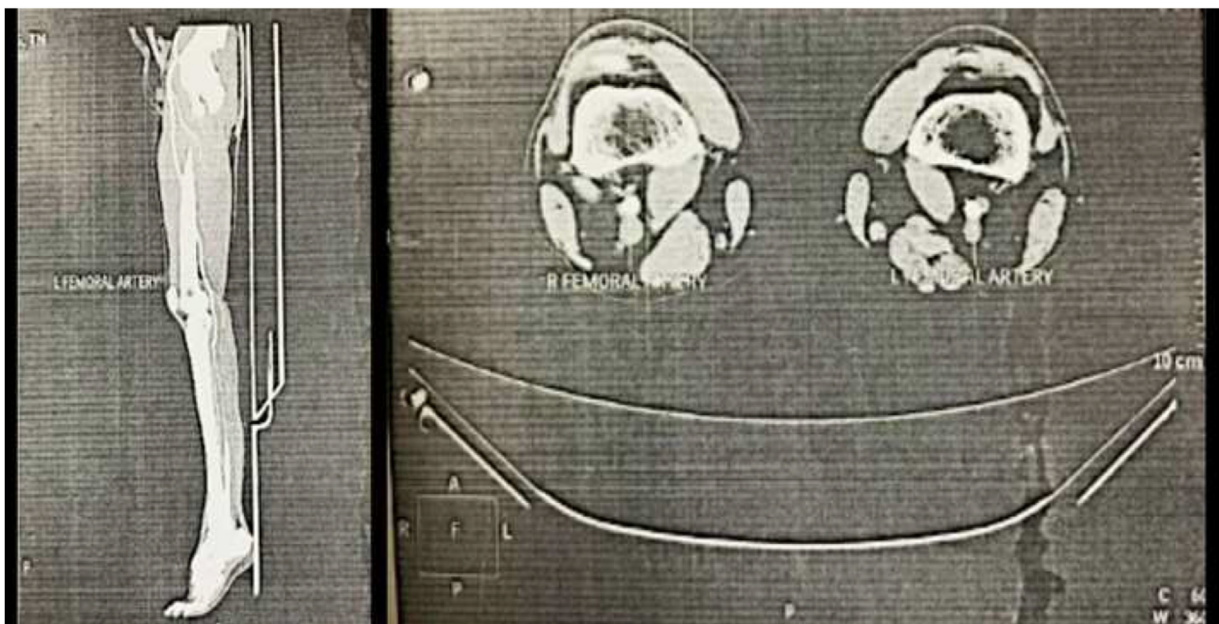


Fig. 2. CT Angiography resulted in normal muscular and skeletal structures without vascular abnormality features.

patient could not tell what precipitated the pain. The pain was sudden, brief, and intermittent. Sometimes it radiated to the calf region. The aching was more frequent after the patient had undergone a reflexology therapy. There was no history of trauma or any comorbidities. Since the onset of the complaint, he has been prescribed over the counter (OTC) pain relievers by a general practitioner. He was slightly Obese (Body Mass Index: 28.1, 85 Kg/174 cm) and regularly treated with antihypertensive medication, 5 mg Amlodipine tablet. The patient was unemployed and occasionally smoked two to three cigarettes a day. Apart from the complaint in his left lower thigh, the general physical examination was within normal value. A tender, indistinct deep subcutaneous lump was felt in the posteromedial side of the lower left femur. The lump was painful when touched but was stable under pressure. Sciatic-related pain was not present. He had been evaluated for low back pain using MRI with normal results. Rehabilitative therapy did not provide relief for the patient. Ultrasound of the lesion showed a 6 × 5.3 mm subcutaneous cystic lesion in the posteromedial of the distal femur. The USG Doppler showed an aneurysm in the left femoral region arteries. The vascularization of the tumor originated from the medial

genicular artery. During the USG procedure as shown in Fig. 1, the patient complained of pain, presumably due to an inflammatory process of the lesion. The USG findings showed a traumatic femoral aneurysm, suggesting a Pseudoaneurysm of the medial genicular artery. The USG findings was followed by CT angiography to evaluate the possibility of DVT vascular neoplasm. The CT angiography in Fig. 2 revealed normal muscular and skeletal structures without vascular abnormality features. The working diagnosis based on history, physical examination, and radio imaging examination was a vascular lesion, indicating a haemangioma. Despite the possible presentation of a haemangioma, a tumor in toto excision was planned. The surgery was performed through the medial femoral approach, allowing for the medial genicular artery to be exposed by an Orthopedic surgeon. An encapsulated soft bluish dermal tumor was seen adhered to vascular wall. In toto excision was pursued to achieve a clean margin and preventing tumor recurrence. The gross specimen was 1.5 × 10 × 0.5 cm, firm, solid, and partly cystic with yellowish-white nodules as shown in Fig. 3. The microscopic feature in Fig. 4 showed relatively well-circumscribed nodule with small dilated vascular spaces surrounded by sheets and clusters of round

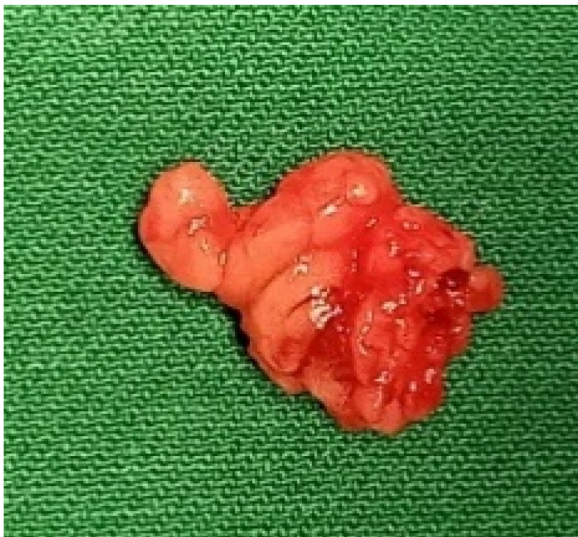

Fig. 3. Yellowish, firm, thin, and encapsulated tumor measuring 1.5 × 10 × 0.5 cm.

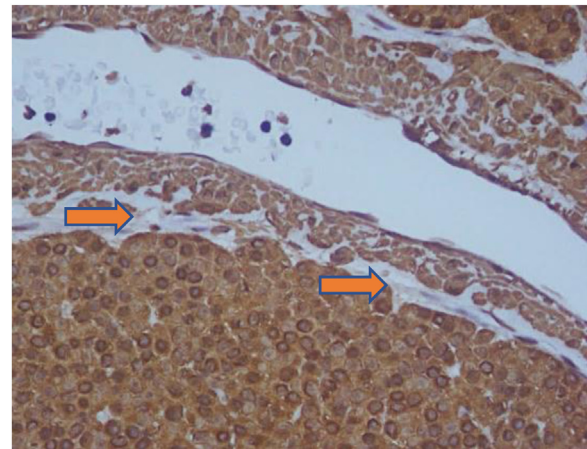


Fig. 5. Smooth Muscle Actin (SMA) (40×). All positive tumor cells are surrounded by thin capillary spaces and form a “perivascular collar” (marked with the arrows).

monomorphic glomus cells with rounded nuclei and moderated amounts of eosinophilic cytoplasm. The cells were atypical, without necrosis nor increased mitotic activity. The histopathology examination indicated a glomus tumor. Several immunohistochemistry examinations were performed to differentiate tumor from neurogenic origins. As shown in Fig. 5, the specific smooth muscles’ actin protein indicated tumor cells, while S100 for the neurogenic origin and CD 31 for the endothelial cells of the tumor cells were negative. There were no specific post-op interventions. Based on the visual analogue scale, the patient no longer felt pain after the procedure. During the follow-up, six months after the procedure, the patient was relieved from any lower extremity pain and no recurrent nodule was detected in the post-surgical area.

### 3. Discussion

On account of the specific location and symptoms, despite the rare incidence, glomus tumor should not be difficult to diagnosed [5,9]. The benign perivascular neoplasm usually located in the distal limb, especially in the subungual (nail bed), as a localized blue-red nodules that are sensitive to cold and touch. Glomus tumor usually occurs in areas that are rich in glomus bodies such as digit or dermis in the palms, wrists, and forearms [7,9,10]. Thigh is not a specific location for glomus bodies, yet glomus tumor in thighs was reported and presented as bluish small nodule that are sensitive to touch and temperature changes [10]. In this case, the nodule although subcutaneous, was barely palpable, owing to the difficulty in palpating/examining without initiating severe pain. Without a palpable lump, pain in that region is usually related

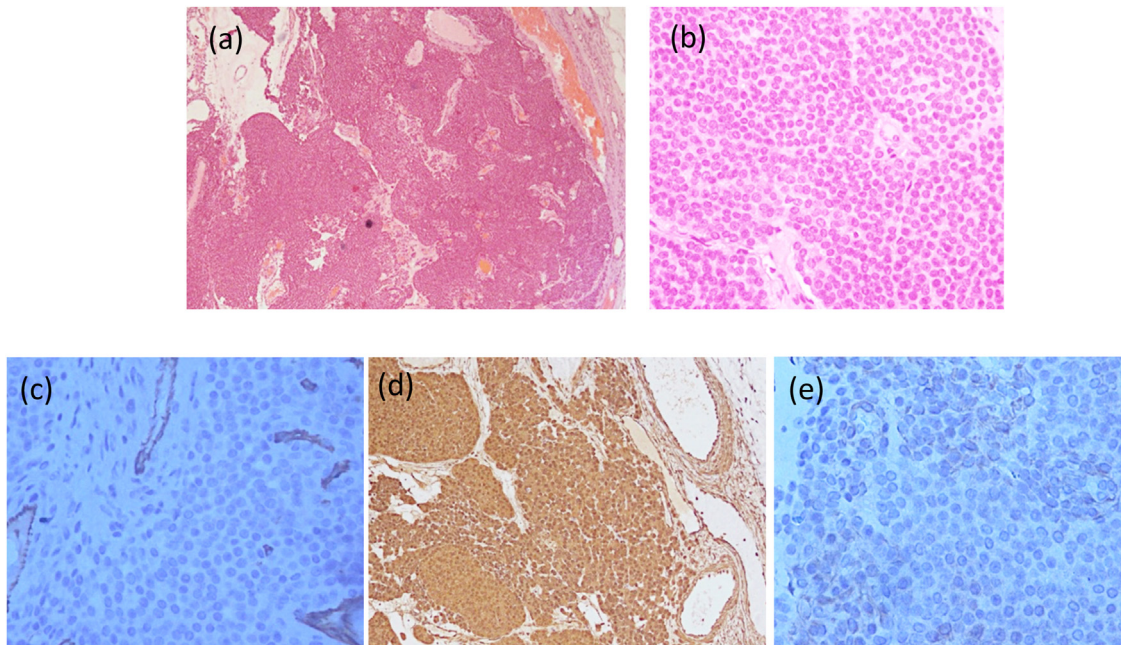


Fig. 4. Excised Tissue Microscopic features. (a) Finely demarcated nodules composed of small rounded cells forming syncytial structures surrounding thin capillary vessels (perivascular growth). Some empty cystic area was seen (H&E, 10×), (b) Round tumor cells with round or oval smooth nucleus, and bland chromatin (H&E, 40×), (c) Immunohistochemistry CD 31 (40×), showing vascular endothelial cells (brown). All tumor cells are negative stained thus confirmed to be non-endothelial neoplasm, (d) Immunohistochemistry Smooth Muscle Actin (SMA). All tumor cells and vascular are positive stained. SMA is a characteristic of protein in glomus cells<sup>1-3</sup> (20×), (e) Immunohistochemistry S100. All tumor cells are negative stained. Tumor cells are not neurogenic tumor (40×).



to a neurologic lesion in the nerve root in the vertebrae. Fortunately the patient's spinal lesion was minor and do not induce sciatic pain. There is often a delay in diagnosis of many years. Proper clinical suspicion and physical examination is the key to a proper diagnosis [11,12]. Imaging evaluations are not routinely performed for glomus tumor, especially when it is located subungually [9,13]. The USG evaluation in this patient was meant to confirm the indistinct palpable lump, while Doppler is used to measure the vascularization of the suspected neoplasia. Even when haemangioma was diagnosed, questions about the incongruent symptom for haemangioma was vague. The pathognomonic glomus tumor triad symptoms (localized tenderness, severe paroxysmal pain and sensitivity to temperature or pressure) [12,14] could not easily lead to a glomus diagnosis if it was located in an infrequent region, especially the one with a higher prevalent of more common conditions like low back pain. The decision for surgery was discussed, mainly for the intraoperative possible difficulties in maintaining to excise the nodule completely without unnecessary damage to the feeding artery. As soon as nodular tumor was exposed, the first interpretation was haemangioma due to its purplish-blue colour. After it was found out to be attached to vascular wall and not difficult to be detached, the exact diagnoses of this soft tissue tumor was again questioned. The tumor could be excised completely. The recurrence rate of these subcutaneous neoplasms is infrequent [14,15]. If there is a recurrence after treatment, it is usually caused by incomplete removal of the tumor and is not an infiltrative growth. If it was recurrent, the patient would complain of pain one month after the excision [16]. In this case, after 6 months of follow-up the patient no longer had any complaints. The recurrence rate of subungual glomus tumor is 14%, due to the narrow and complicated surrounding structures which make it hard to differentiate the tumor from a normal tissue and excision in this area requires the surgeon to maintain the patient's nail matrix [12,16]. Glomus tumours in the thigh region rarely recurs since they are solitary and encapsulated, making them easily recognizable from the surrounding tissue [7,8]. In the six major published series, glomus tumor recurrence rates were ranging from 0% to 33.3%. Early relapses may occur within a few weeks to months of surgery and may reflect inadequate excision [15]. Later relapses may be the result of the development of a new neoplasia, not a recurrency [3,5,11].

#### 4. Conclusion

Chronic lower extremity pain is often misinterpreted. Meticulous history taking and physical examination in clearly differentiating tumor and non-tumor lesion is very helpful. Correct differential diagnosis is a way to managed correctly thus safe a patient's quality of daily life.

#### Declaration of Competing Interest

The authors report no declarations of interest.

#### Funding

The authors received no financial support for the research, authorship and/or publication of this article.

#### Ethical approval

Ethical approval to report this case was obtained from The Hospital Research Ethics Committee of "Rumah Sakit Orthopedi dan Traumatologi Surabaya" where the patient was admitted.

#### Consent

Written informed consent was obtained from the patient for publication of this case report and accompanying images. A copy of the written consent is available for review by the Editor-in-Chief of this journal on request.

#### Registration of research studies

NA.

#### Guarantor

Komang Agung Irianto.

#### Provenance and peer review

Not commissioned, externally peer-reviewed.

#### CRedit authorship contribution statement

**Laskar Pradnyan Kloping:** Conceptualization, Writing - original draft, Writing - review & editing. **Lukas Widhiyanto:** Investigation, Resources, Writing - original draft. **Komang Agung Irianto:** Conceptualization, Investigation, Resources, Writing - original draft, Supervision, Project administration. **Oen Sindrawati:** Investigation, Resources, Writing - original draft. **Yudhistira Pradnyan Kloping:** Writing - original draft, Writing - review & editing.

#### Acknowledgements

The authors thank the Medical Record staff of "Rumah Sakit Orthopedi dan Traumatologi Surabaya" for providing additional patient data.

#### References

- [1] M.R. Lindberg, T. Mentzel, *Glomus Tumor and Variants*, Diagnostic Pathology Soft Tissue Tumors/Matthew R. Lindberg, 2nd ed., Elsevier, Philadelphia, 2016, pp. 338–343.
- [2] Z. Gombos, P.J. Zhang, Glomus tumor, *Arch. Pathol. Lab. Med.* 132 (2008) 1448–1452.
- [3] A. Gnaneshwar Rao, D. Indira, J. Kamal, *Indian J. Dermatol.* 55 (October–December (4)) (2010) 397–398.
- [4] M. Mravic, G. LaChaud, A. Nguyen, M.A. Scott, S.M. Dry, A.W. James, Clinical and histopathological diagnosis of glomus tumor: an institutional experience of 138 cases, *Int. J. Surg. Pathol.* 23 (3) (2015) 181–188.
- [5] B. Frumuseanu, R. Balanescu, A. Ulici, M. Golumbeanu, M. Barbu, V. Orita, et al., A new case of lower extremity glomus tumor up-to date review and case report, *J. Med. Life* 5 (2) (2012) 211–214.
- [6] B. Granel, M. Boufi, P. Rossi, J. Soussan, Y. Alimi, A voluminous glomus tumor of the lower extremity, *Q. J. Med.* 106 (7) (2013) 693–694.
- [7] L.R. Luis, G.R. Kaoru, P.B. Shemuel, J.L. Mills, Lower extremity glomus tumors: comprehensive review for surgeons, *Vascular* 16 (6) (2008) 326–332.
- [8] R.A. Agha, M.R. Borrelli, R. Farwana, K. Koshy, A.J. Fowler, D.P. Orgill, et al., The SCARE 2018 statement: updating consensus Surgical Case Report (SCARE) guidelines, *Int. J. Surg.* 60 (2018) 132–136.
- [9] K.N. Glazebrook, M.J. Most, T.K. Schiefer, C.Y. Inwards, F.H. Sim, Multiple glomus tumors of the lower lower extremity, *J. Ultrasound Med.* 29 (4) (2010) 667–670.
- [10] MAI Sbai, S. Benzarti, W. Gharbi, W. Khoffi, R. Maalla, Glomus tumor of the lower extremity: a case report, *Pan Afr. Med. J.* 31 (186) (2018) 1–6.
- [11] V.M. Morey, B. Garg, P.P. Kotwal, Glomus tumours of the hand: review of literature, *J. Clin. Orthop. Trauma* 7 (4) (2016) 286–291.
- [12] Douglas R. Stewart, et al., Diagnosis, management, and complications of glomus tumors of the digits in neurofibromatosis type 1, *J. Med. Genet.* 47 (August (8)) (2010) 525–532.

- [13] D. Singh, R.S. Garg, Y. Garg, V. Arora, Glomus tumor - a rarity; M.R.I- a big help in early diagnosis, *J. Orthop. Case Rep.* 6 (3) (2016) 38–39.
- [14] M.T. Semaan, C.A. Megerian, Current assessment and management of glomus tumors, *Curr. Opin. Otolaryngol. Head Neck Surg.* 16 (5) (2008) 420–426.
- [15] T. Chou, S.C. Pan, S.J. Shieh, J.W. Lee, H.Y. Chiu, C.L. Ho, Glomus tumor twenty-year experience and literature review, *Ann. Plast. Surg.* 76 (March) (2016) S35–40.
- [16] P. Paliogiannis, E. Trignano, M. Trignano, Surgical management of the glomus tumors of the fingers: a single center experience, *Ann. Ital. Chir.* 82 (6) (2011) 465–468.

#### Open Access

This article is published Open Access at [sciencedirect.com](https://www.sciencedirect.com). It is distributed under the [IJSCR Supplemental terms and conditions](#), which permits unrestricted non commercial use, distribution, and reproduction in any medium, provided the original authors and source are credited.