

# INCREASED HIF-1a AND VEGF EXPRESSION FOUND IN VARIOUS T STAGES OF CLEAR CELL RENAL CELL CARCINOMA

*by* Yohana Octavianda

---

**Submission date:** 28-Oct-2022 03:54PM (UTC+0800)

**Submission ID:** 1937670238

**File name:** FOUND\_IN\_VARIOUS\_T\_STAGES\_OF\_CLEAR\_CELL\_RENAL\_CELL\_CARCINOMA.pdf (238.29K)

**Word count:** 3442

**Character count:** 17355

## INCREASED HIF- $\alpha$ AND VEGF EXPRESSION FOUND IN VARIOUS T STAGES OF CLEAR CELL RENAL CELL CARCINOMA

Yohana Octavianda, Anny Setijo Rahaju

Department of Anatomic Pathology, Faculty of Medicine, Universitas Airlangga/Dr. Soetomo Hospital, Surabaya, Indonesia

### ABSTRAK

Terjadi peningkatan karsinoma sel ginjal pada laki-laki usia dekade kelima ke atas dengan faktor resiko merokok. Karsinoma sel ginjal tipe Clear Cell merupakan tumor ganas tersering yang ditemukan pada ginjal yang mempunyai sifat alamiah agresif. Karsinoma ini diklasifikasikan menurut TNM menjadi stadium T1, T2, T3 dan T4. Makin tinggi stadium T, semakin buruk prognosis penderita, karena melibatkan peran faktor transkripsi HIF-1 $\alpha$  yang terakumulasi pada kondisi hipoksia karena inaktivasi VHL, sehingga mengaktifasi VEGF. Sejauh ini, karsinoma sel ginjal tipe Clear Cell yang banyak terjadi pada laki-laki perokok usia dekade kelima keatas belum dapat dijelaskan. Penelitian observasional analitik dilakukan pada sampel blok parafin penderita karsinoma sel ginjal tipe Clear Cell pada tahun 2010-2016. Stadium T1 sebanyak 9 sampel, stadium T2 dan T3 masing-masing 12 sampel, dan stadium T4 sebanyak 6 sampel di Laboratorium Patologi Anatomi RSUD Dr. Soetomo. Deteksi ekspresi HIF-1 $\alpha$  dan VEGF dengan pulasan imunohistokimia menggunakan antibodi HIF-1 $\alpha$  dan VEGF. Hasil penelitian dianalisis statistik dengan metode Kruskal-Wallis dan Mann-Whitney. Korelasi antara HIF-1 $\alpha$  dan VEGF dengan stadium T dianalisa menggunakan metode Spearman. Terdapat perbedaan ekspresi HIF-1 $\alpha$  antar stadium T1 dan T2, T1 dan T3, T1 dan T4 ( $p=0,041$ ,  $p=0,000$ , dan  $p=0,002$ ), serta pada stadium T2 dan T3 hingga stadium T2 dan T4 ( $p=0,001$ , dan  $p=0,013$ ). Terdapat perbedaan ekspresi VEGF pada stadium T1 dan T2, T1 dan T3, T1 dan T4 ( $p=0,007$ ,  $p=0,000$ , dan  $p=0,002$ ), serta pada stadium T2 dan T3 ( $p=0,001$ ). Terdapat korelasi antara ekspresi HIF-1 $\alpha$  dan VEGF dengan seluruh stadium T ( $rs=0,624$  dengan  $p=0,000$ ). Sebagai simpulan, semakin tinggi stadium T, semakin tinggi ekspresi HIF-1 $\alpha$  dan VEGF. Semakin tinggi kadar HIF-1 $\alpha$  dan VEGF, semakin buruk prognosis penderita karsinoma sel ginjal tipe Clear Cell. HIF-1 $\alpha$  dan VEGF berperan dalam patogenesis karsinoma sel ginjal tipe Clear Cell. Dengan demikian HIF-1 $\alpha$  dan VEGF dapat dikembangkan sebagai penanda prognostik. (FMI 2018;54:102-107)

**Kata kunci:** Karsinoma sel ginjal tipe Clear Cell; HIF-1 $\alpha$ ; VEGF; stadium T

### ABSTRACT

There is an increase in renal cell carcinoma in males aged over fifty years with smoking risk factors. Clear cell renal cell carcinoma is the most common malignant tumor found in the kidneys that have an aggressive nature. This carcinoma is classified according to TNM into T1, T2, T3 and T4 stages. The higher the T stage, the worse the prognosis of the patient, as it involves the role of the HIF-1 $\alpha$  transcription factor accumulated under hypoxic condition due to inactivation of VHL, thus activating VEGF. So far, clear cell renal cell carcinoma frequently found in smoking males of fifth decade of age or older has not been explained. An observational analytic study was conducted on the sample of paraffin blocks of patients with clear cell renal cell carcinoma in 2010-2016. T1, T2, T3, and T4 stages of 9 samples, 12 samples, 12 samples and 6 samples, respectively, were collected in Anatomic Pathology Laboratory, Dr. Soetomo Hospital, Surabaya. Detection of HIF-1 $\alpha$  and VEGF expression was performed using immunohistochemical immunity with HIF-1 $\alpha$  and VEGF antibodies. The results were analyzed statistically by Kruskal-Wallis and Mann-Whitney methods. The correlation between HIF-1 $\alpha$  and VEGF in T stages was analyzed using Spearman method. There was a difference of HIF-1 $\alpha$  expression between stage T1 with T2, T1 with T3, T1 with T4 ( $p=0.041$ ,  $p=0.000$ , and  $p=0.002$ ), stage T2 with T3 and stage T2 with T4 ( $p=0.001$ , and  $p=0.013$ ). There was a difference in VEGF expression in stage T1 with T2, T1 with T3, T1 with T4 ( $p=0.007$ ,  $p=0.000$ , and  $p=0.002$ ), and stage T2 with T3 ( $p=0.001$ ). There was a correlation between HIF-1 $\alpha$  and VEGF expressions with all T stages ( $rs=0.624$  with  $p=0.000$ ). As a conclusion, the higher the stage of T, the higher the expression of HIF-1 $\alpha$  and VEGF. The higher the levels of HIF-1 $\alpha$  and VEGF, the worse the prognosis of clear cell renal carcinoma. HIF-1 $\alpha$  and VEGF play a role in the pathogenesis of clear cell renal cell carcinoma. Thus, HIF-1 $\alpha$  and VEGF can be developed as prognostic markers. (FMI 2018;54:102-107)

**Keywords:** Clear cell renal cell carcinoma; HIF-1 $\alpha$ ; VEGF; T stages

**Correspondence:** Yohana Oktavianda, Department of Anatomic Pathology, Faculty of Medicine, Universitas Airlangga/Dr. Soetomo Hospital, Surabaya, Indonesia. Email: yoctavianda@gmail.com

### INTRODUCTION

There is an increase in renal cell carcinoma in males of fifth-decade and older with risk factor of smoking

(Umbas et al 2012). Renal cell carcinoma consists of 4 histologic types. Clear cell type is the most common malignant tumor found in the kidney, consisting of about 80-85% (Waxman 2005). Clear cell renal cell

carcinoma has the most aggressive and deadly nature among malignancy in the urogenital system. A third of individuals with clear cell renal cell carcinoma come to the physician when they have been in an advanced stage, another third come with a more severe recurrence (De et al 2012). So far, the most common clear cell renal cell carcinoma in men of the fifth decade and above can not be explained. The incidence of renal cell carcinoma in Indonesia is estimated to reach 2-4 cases in 100,000 populations. This number is increasing in 2012, so the case of renal cell carcinoma was ranked as the 18th incidence of carcinoma in both men and women. Complete data on renal cell carcinoma in Dr. Soetomo Hospital until then has not existed, while in Dr. Cipto Mangunkusumo Hospital and Dharmais Cancer Hospital in Jakarta from January 1995 to December 2008, there were 81 cases of renal cell carcinoma, with median age 52 years and ratio of man to woman 3:1 (Umbas et al 2012).

Like other solid tumors, it is expected that there will be molecular marker tumors that can be used for the patient's prognostic information as well as the target therapy for clear cell renal cell carcinoma. To date, no molecular marker meets the College of American Pathologist criteria for general use in the management of patients with clear cell renal cell carcinoma (Pantuck et al 2003). Clinical stages depicting the anatomical spread of malignancy are the most important independent prognostic factor in renal cell carcinoma (RCC). The system used today is according to the WHO 2016 classification system.

The tumor cells in renal cell carcinoma develop rapidly due to the supply of oxygen and nutrients obtained from blood vessels that undergo angiogenesis. Angiogenesis supplies oxygen and nutrients adequately to tumor cells through various stages (De et al 2012). In normal cells there is no tissue hypoxia, so there is no HIF-1 $\alpha$  accumulation, and no increase in angiogenesis. In renal tumors with impaired function (mutations) of VHL as a suppressor gene tumor, HIF-1 $\alpha$  (hypoxia-induced factor-1 $\alpha$ ) accumulates in cells, triggering potent proangiogenic growth factors, one of which is vascular endothelial growth factor (VEGF). This protein binds to a specific endothelial surface receptor (VEGFR), which activates signaling pathways that causes endothelial cell proliferation, migration and capillary vessel formation (Hudes et al 2008). This study aimed to determine the correlation between HIF-1 $\alpha$  and VEGF expression in various stages of T clear cell renal cell carcinoma.

## MATERIALS AND METHODS

Patients' paraffin blocks of clear cell renal cell carcinoma were collected in Laboratory of Anatomic Patho-

logy, Dr. Soetomo Hospital, Surabaya, from January 1, 2010 to December 31, 2016 to obtain the population. Data from the population were collected to obtain the patients' T stage. There were 9 samples of T1 stage and 6 samples of T4 stage which were obtained by total sampling. In T2 and T3 stages, random sampling was taken using sample formula and 12 samples for each stage were obtained. HIF-1 $\alpha$  expression was immunohistochemically examined with rabbit anti-human monoclonal antibodies from Novus Biologicals with 1:200 dilution and rabbit anti-human VEGF monoclonal antibodies from Biocare with 1:100 dilution.

The expression of HIF-1 $\alpha$  and VEGF was positive if it was stained in the cytoplasm. Positively responded tumor cells were calculated visually with a 400x magnification binocular light microscope, and then the assessment based on the percentage of positive cell counts was performed. The data collected were analyzed statistically. The differences of HIF-1 $\alpha$  and VEGF expression were analyzed by Kruskal Wallis and Mann-Whitney ( $p=0.05$ ). Whereas, the correlation between HIF-1 $\alpha$  and VEGF expressions with T stages was analyzed using Spearman correlation test.

## RESULTS

There were 64 patients with clear cell renal cell carcinoma, and only 39 patients met the inclusion criteria. The mean age of the patients in this study was  $56.03 \pm 12.48$  years old. The youngest patient was 19 years old and the oldest was 77 years old. In this study, most patients were in the age range of 51-60 years old as much as 33.3%. The assessment of mean percentage of HIF-1 $\alpha$  expression in each T stage resulted in: mean percentage in T1 stage group was  $5.67\% \pm 5.00\%$ , at T2 stage was  $16.42 \pm 14.13\%$ , at T3 stage was  $45.42\% \pm 22.91\%$  and at T4 stage was  $48.33\% \pm 24.83\%$  (Table 1).

## DISCUSSION

In epidemiology, renal cell carcinoma is mostly suffered by adults, but it can also be found in children and infants aged 6 months. The incidence of renal cell carcinoma increases with age, with its peak in the sixth decade with a median age of 55 years (Murphy et al 2011). Kruskal-Wallis statistical analysis in Table 1 shows significant differences in HIF-1 $\alpha$  expression increase in various T stages of clear cell renal cell carcinoma with  $p=0.000$  ( $p=0.05$ ). There was an increase in median HIF-1 $\alpha$  expression from stage T1 to T3, and a slight decrease in the median value of HIF-1 $\alpha$  expression at T4 stage. The angiogenesis process was regulated by HIF-1 $\alpha$  and its isoform, HIF-2 $\alpha$ .

Table 1. Expression of HIF-1 $\alpha$  in percentage of tumor cells in a variety of T stages of clear cell renal cell carcinoma

| Stages | n  | HIF- $\alpha$ expression |       |                    |     |     | p      |
|--------|----|--------------------------|-------|--------------------|-----|-----|--------|
|        |    | x                        | SD    | Median             | Min | Max |        |
| T1     | 9  | 5.67                     | 5.00  | 5.00 <sup>a</sup>  | 0   | 15  | 0.000* |
| T2     | 12 | 16.42                    | 14.13 | 10.00 <sup>b</sup> | 0   | 50  |        |
| T3     | 12 | 45.42                    | 22.91 | 50.50 <sup>c</sup> | 10  | 80  |        |
| T4     | 6  | 48.33                    | 24.83 | 45.00 <sup>c</sup> | 10  | 80  |        |

Note: \* Significant at  $\alpha=0.05$ ; the same <sup>abc</sup> superscript shows no differences between groups

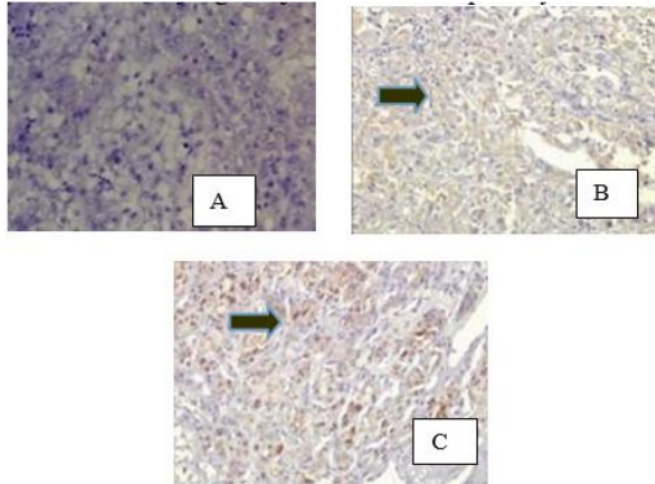


Fig. 1. Expression of HIF-1 $\alpha$  in clear cell renal cell carcinoma. A.Objective 40x. HIF-1 $\alpha$  is not in the cytoplasm (negative). B. and C. Objective 40x. HIF-1 $\alpha$  is present in the cytoplasm of tumor cells (black arrows).

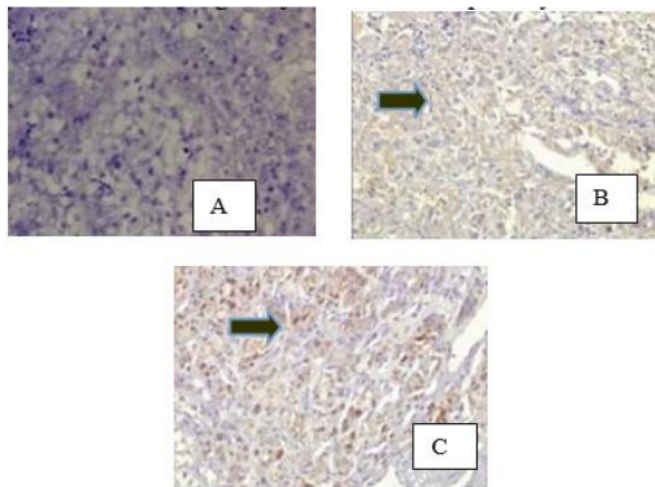


Fig. 1. Expression of HIF-1 $\alpha$  in clear cell renal cell carcinoma. A.Objective 40x. HIF-1 $\alpha$  is not in the cytoplasm (negative). B. and C. Objective 40x. HIF-1 $\alpha$  is present in the cytoplasm of tumor cells (black arrows).



Table 2. VEGF expression in the percentage of tumor cells that were present at various stages of T clear cell renal cell carcinoma

| Stages | N  | VEGF expression |       |                     |     | P   |       |
|--------|----|-----------------|-------|---------------------|-----|-----|-------|
|        |    | x               | SD    | Median              | Min |     | Max   |
| T1     | 9  | 10.56           | 11.84 | 10.00 <sup>a</sup>  | 0   | 40  | 0.000 |
| T2     | 12 | 32.08           | 22.10 | 25.00 <sup>b</sup>  | 0   | 70  |       |
| T3     | 12 | 67.50           | 24.54 | 75.00 <sup>c</sup>  | 20  | 100 |       |
| T4     | 6  | 51.67           | 25.63 | 40.00 <sup>bc</sup> | 30  | 100 |       |

Note: \* Significant at  $\alpha=0.05$ ; the same <sup>abc</sup> superscript shows no differences between groups

HIF-1 $\alpha$  has a function in the formation of blood vessels, whereas HIF-2 $\alpha$  has a function in the maturation process (Knock et al 2011). After new blood vessels are formed, the role of HIF-1 $\alpha$  is replaced by HIF-2 $\alpha$  in the maturation process, so in this study there was a slight decrease in HIF-1 $\alpha$  expression in stage T4. The Mann-Whitney statistical test revealed that there was a difference of HIF-1 $\alpha$  expression in T1 and T2-T4 stages ( $p=0.05$ ) and in the T2 and T3-T4 stages ( $p=0.05$ ).

In this study, there were 2 cases (5.12%) at T1 and T2 stages in which HIF-1 $\alpha$  antibodies were not stained (negative) with good internal control, and 37 cases (94.88%) of HIF-1 $\alpha$  antibodies were present. In the early phase of malignant progression, tumor cells were in dormant conditions in avascular areas where cell proliferation was balanced with apoptosis. This is also called as angiogenic switching, a transition from non-angiogenic state to active vascular growth (Knock et al 2011). This explains the unstaining of HIF-1 $\alpha$  antibody.

A study from Wan et al (2015) suggested that positive rate of clear cell tumor tissue with T3 and T4 stages was significantly higher than tumor tissue with T1 and T2 stages ( $X^2=6.67$ ,  $p=0.01$ ). A study by Lidgren et al (2006) found no correlation between HIF-1 $\alpha$  expression and tumor stage, core grading, tumor size or invasion of the renal vein. HIF-1 $\alpha$  expression is an independent prognostic factor. High HIF-1 $\alpha$  expression is associated with a better prognosis (Wan et al 2015).

In clear cell tumor tissue, hypoxic conditions are associated with proliferation of tumor cells and inadequate supply of oxygen, inactivation of VHL, oncogene, and growth factors. Together with macrophages, these factors contribute to tumor micro-environment that can modulate the HIF-1 $\alpha$  response. These complex interactions affect the tumor phenotype and behavior during progression, invasion and metastasis (Waldemann & Johnson 2008).

The calculation of VEGF expression in each group of samples revealed that the mean percentage of VEGF expression in T1 stage was  $10.56\% \pm 11.84\%$ , at T2 stage

was  $32.08\% \pm 22.10\%$ , at T3 stage was  $67.50\% \pm 24.54\%$ , and in T4 stage was  $51.67\% \pm 25.63\%$ . The Kruskal-Wallis statistical test analysis (Table 2) showed significant differences in VEGF expression increase in various stages of T clear cell renal cell carcinoma with  $p=0.000$  ( $p=0.05$ ), an increase in median VEGF expression values from stage T1 to T3, and a slight decrease in the median value of VEGF expression. The process of angiogenesis in tumor cells in the early phase, in which tumor cells are still in the avascular phase that grows up to the deepest part of the tumor, results in upregulation of angiogenic factor production, one of which is VEGF (Papetti & Herman 2002). After blood vessels are formed, the role of VEGF in the angiogenesis process is reduced. This explains the decrease of VEGF expression in T4 stage.

The Mann-Whitney statistical test revealed that there were significant differences in VEGF expression in T1 and T2-T4 stages ( $p=0.05$ ), and in T2 and T3 stages ( $p=0.05$ ). In this study, there were 3 cases (7.69%) at T1 and T2 stages in which VEGF antibodies were unstained (negative) with good internal control, and as many as 36 cases (92.30%) of VEGF antibodies were present. In the unstained case such as above, angiogenic switch is taking place in angiogenic process of early stage of tumor cell. The switch is the transition from nonangiogenic state to the growth of active blood vessel (Knock et al 2011). The VEGF was unstained because the tumor was still in avascular condition where it had not been activating the VEGF (Papetti & Herman 2002).

Angiogenesis is a complex process that requires the coordination of different cell activities, including endothelial cells, pericytes, fibroblasts, immune mediators, growth factors and angiogenic factors such as VEGF. These cells interact with each other and also interact with the extracellular matrix component to produce endothelial cell migration, proliferation, tube formation, and stabilization (Papetti & Herman 2002). Increased VEGF expression is associated with a hyper-vascular clear cell renal cell carcinoma, and plays a role in tumorigenesis which is associated with T stage clear cell renal cell carcinoma.

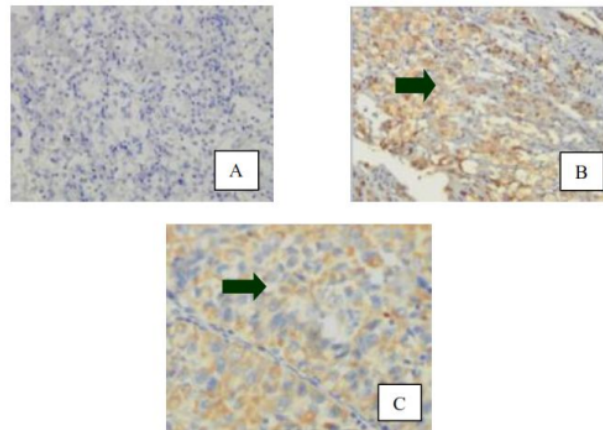


Fig. 2. VEGF expression on clear cell renal cell carcinoma. A. Objective 40x. VEGF is not in the cytoplasm (negative). B. and C. Objective 40x. VEGF is in the cytoplasm of tumor cells (black arrows).

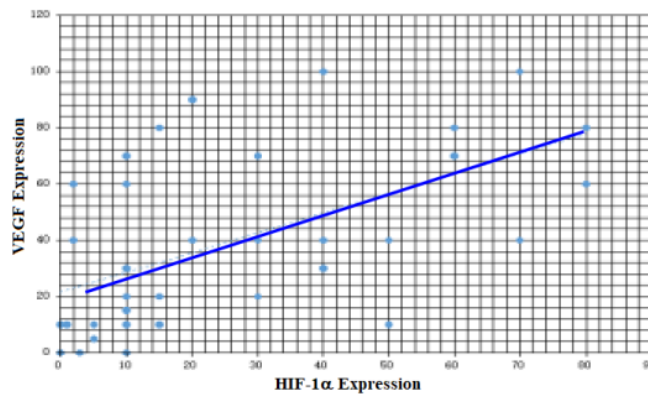


Figure 3. Expression correlation of HIF-1 $\alpha$  and VEGF at various stages of T clear cell renal cell carcinoma.

The analysis of the correlation between HIF-1 $\alpha$  and VEGF expressions with various stages of T clear cell renal cell carcinoma using Spearman test resulted that overall got correlation between HIF-1 $\alpha$  and VEGF expression at all tumor stage (T1-T4), with  $r_s=0.624$  and  $p=0000$  ( $p=0.05$ ). Fig. 3 shows a positive linear line, meaning that there is a positive correlation between HIF-1 $\alpha$  expression with VEGF. So it can be stated that the higher the stages of clear cell renal cell carcinoma, the higher the expression of HIF-1 $\alpha$  and VEGF.

This study found that in the early stages (T1 and T2) there was an increase of HIF-1 $\alpha$  and VEGF expression

up to T3 stage, then a slight decrease in HIF-1 $\alpha$  and VEGF expression in the T4 stage. In rapidly proliferating tumors, oxygen demand increases but oxygen supply decreases. This is due to the abnormal blood vessel structure in the tumor tissue. Hypoxic conditions ( $pO_2 < 7$  mmHg) inactivate VHL as a gene suppressor tumor, so HIF-1 $\alpha$  becomes stable and is transferred to the nucleus. At the core HIF-1 $\alpha$  becomes active and activates VEGF as an angiogenic factor (Vaupel 2004). Increased expression of HIF-1 $\alpha$  and VEGF in the early stages of the tumor is required for angiogenesis of tumor tissue to form new blood vessels. When the new

blood vessels are stabilized, the expression of HIF-1 $\alpha$  and VEGF decreases slightly.

A positive correlation relationship was also found between the expression of HIF-1 $\alpha$  and VEGF with various stages of T clear cell renal cell carcinoma found in this study. The higher the stage of T, the higher the expression of HIF-1 $\alpha$  and VEGF. HIF-1 $\alpha$  as transcription factor and VEGF as target gene and angiogenic factor, work together to increase angiogenesis in clear cell carcinoma and can be developed as marker of tumor and prognostic marker in clear cell renal cell carcinoma patients.

## CONCLUSION

A positive correlation between HIF-1 $\alpha$  and VEGF expression with various stages of T clear cell renal cell carcinoma was found in this study. The higher the T stage the higher the expression of HIF-1 $\alpha$  and VEGF, the worse the prognosis of the patient with the clear cell carcinoma. The accumulation of HIF-1 $\alpha$  due to VHL inactivation and VEGF overexpression is a predisposing factor for the occurrence of angiogenesis in the clear cell tissue tumor type, which contributes to tumor growth by supplying oxygen and nutrients in tumor cells. So that HIF-1 $\alpha$  and VEGF can be further developed as a prognostic marker in patients with clear cell renal cell carcinoma.

## REFERENCES

De S, Dey YN, Sarkar P, Gaidhani S (2012). An overview of angiogenesis and renal cell carcinoma. Inter-

national Journal of Nutrition, Pharmacology, and Neurological Diseases 2, 3-7

Hudes G, Rini B, Srinivas S (2008). "Antiangiogenic therapy for advanced renal cell carcinoma." Angiogenesis Foundation,1-2

Knock B, Skuli N, Simon C (2011). Hypoxia-induced angiogenesis: good and evil. *Genes and Cancer* 2, 1117-1133

Lidgren A, Hedberg Y, Grankvist K, Rasmuson T, Bergh A, Ljungberg B (2006). Hypoxia-inducible factor 1 $\alpha$  expression in renal cell carcinoma analyzed by tissue microarray. *Eur Urol* 50, 1272-1277

Murphy WM, Grignon DJ, Perlman EJ (2011). AFIP atlas of tumor pathology. Tumors of the kidney, bladder, and related urinary structure. Washington DC, Springer-Verlag, p 101-159

Pantuck, et al (2003). Pathobiology, prognosis and targeted therapy for renal cell carcinoma: Exploiting the hypoxia-induced pathway. *Clinical cancer Research* 9, 4641-4652

Papetti M, Herman IM (2002). Mechanism of normal and tumor-derived angiogenesis. *Am J Physiol Cell Physiol* 282, C947-C970

Umbas R, et al (2012). Panduan penanganan kanker ginjal. Ikatan Ahli Urologi Indonesia, 1-20

Vaupel P (2004). The role of hypoxia-induced factors in tumor progression. *The Oncologist* 9, 10-17

Wan L, et al (2015). Expression and significance of FOXP1, HIF-1 $\alpha$  and VEGF in renal clear cell carcinoma. *JBUON* 2015 20, 188-195

Waxman J (2005). Renal cell carcinoma. *Journal of Urological Cancers*, 274

Weldemann A, Johnson RS (2008). Biology of HIF-1 $\alpha$ . Nature Publishing Group, 621-627

# INCREASED HIF-1a AND VEGF EXPRESSION FOUND IN VARIOUS T STAGES OF CLEAR CELL RENAL CELL CARCINOMA

## ORIGINALITY REPORT

16%

SIMILARITY INDEX

9%

INTERNET SOURCES

12%

PUBLICATIONS

0%

STUDENT PAPERS

## PRIMARY SOURCES

- 1 Vaishali Pansare. "Increased expression of hypoxia-inducible factor 1 $\alpha$  in type I and type II endometrial carcinomas", Modern Pathology, 01/2007  
Publication 1%
- 2 [journals.plos.org](http://journals.plos.org)  
Internet Source 1%
- 3 Mojzis, J.. "Antiangiogenic effects of flavonoids and chalcones", Pharmacological Research, 200804  
Publication 1%
- 4 [jkcvhl.com](http://jkcvhl.com)  
Internet Source 1%
- 5 [www.hindawi.com](http://www.hindawi.com)  
Internet Source 1%
- 6 [oncourology.abvpress.ru](http://oncourology.abvpress.ru)  
Internet Source 1%
- 7 Heba H. Tarabay, Hassan Abol-Enein, Amira Awadalla, Wael I. Mortada, A. F. Abdel-Aziz. 1%



"Gene expression and oxidative stress markers profile associated with toxic metals in patients with renal cell carcinoma",  
Molecular Biology Reports, 2021

Publication

---

|    |  |      |
|----|--|------|
| 8  | A. Palazzo, R. Iacovelli, E. Cortesi. "Past, Present and Future of Targeted Therapy in Solid Tumors", Current Cancer Drug Targets, 2010<br>Publication | 1 %  |
| 9  | <a href="http://repository.unair.ac.id">repository.unair.ac.id</a><br>Internet Source  | 1 %  |
| 10 | <a href="http://ojs2.e-journal.unair.ac.id">ojs2.e-journal.unair.ac.id</a><br>Internet Source  | 1 %  |
| 11 | <a href="http://jeccr.biomedcentral.com">jeccr.biomedcentral.com</a><br>Internet Source  | <1 % |
| 12 | <a href="http://link.springer.com">link.springer.com</a><br>Internet Source  | <1 % |
| 13 | <a href="http://seer.cancer.gov">seer.cancer.gov</a><br>Internet Source  | <1 % |
| 14 | <a href="http://elearning.medistra.ac.id">elearning.medistra.ac.id</a><br>Internet Source  | <1 % |
| 15 | Hema Vankayala, Dongping Shi, Ulka Vaishampayan. "Chapter 5 Renal Cell Carcinoma: Clinical Presentation, Staging, and                                  | <1 % |

Prognostic Factors", Springer Science and Business Media LLC, 2012

Publication

16

[www.healio.com](http://www.healio.com)

Internet Source

<1 %

17

"The Potential Role of Intrinsic Hypoxia Markers as Prognostic Variables in Cancer", *Antioxidants & Redox Signaling*, 08/2007

Publication

<1 %

18

Kroeze, S.G.C.. "Expression of nuclear FIH independently predicts overall survival of clear cell renal cell carcinoma patients", *European Journal of Cancer*, 201012

Publication

<1 %

19

[indonesianjournalofcancer.org](http://indonesianjournalofcancer.org)

Internet Source

<1 %

20

[ajpcell.physiology.org](http://ajpcell.physiology.org)

Internet Source

<1 %

21

Cristina Battaglia, Eleonora Mangano, Silvio Biccato, Fabio Frascati et al. "Chapter 12 Molecular Portrait of Clear Cell Renal Cell Carcinoma: An Integrative Analysis of Gene Expression and Genomic Copy Number Profiling", IntechOpen, 2012

Publication

<1 %

22

[assets.researchsquare.com](http://assets.researchsquare.com)

Internet Source

<1 %

23 B.-H. Jiang. "Reactive oxygen species regulate insulin-induced VEGF and HIF-1 expression through the activation of p70S6K1 in human prostate cancer cells", *Carcinogenesis*, 01/01/2007

Publication

---

24 Hirota, K.. "Regulation of angiogenesis by hypoxia-inducible factor 1", *Critical Reviews in Oncology and Hematology*, 200607

Publication

---

25 Hsiao-Chi Tsai, Huey-En Tzeng, Chun-Yin Huang, Yuan-Li Huang et al. "WISP-1 positively regulates angiogenesis by controlling VEGF-A expression in human osteosarcoma", *Cell Death & Disease*, 2017

Publication

---

26 ML Mikkelsen, N Marcussen, M Rabjerg. "Surgically Induced Ischemia has no Impact on Protein Expression Levels of HIF - 1 $\alpha$  and Related Biomarkers in Renal Cell Carcinoma", *APMIS*, 2021

Publication

---

27 Mi-Ock Lee. "Metastasis-associated protein 1 enhances stability of hypoxia-inducible factor-1 $\alpha$  protein by recruiting histone deacetylase 1", *The EMBO Journal*, 03/22/2006

Publication

---

28

Internet Source

<1 %

29

[vdoc.pub](http://vdoc.pub)

Internet Source

<1 %

30

[www.indonesianjournalofcancer.or.id](http://www.indonesianjournalofcancer.or.id)

Internet Source

<1 %

31

Gregg L. Semenza. "Hypoxia, Clonal Selection, and the Role of HIF-1 in Tumor Progression", *Critical Reviews in Biochemistry and Molecular Biology*, 2008

Publication

<1 %

32

M. J. Plank, B. D. Sleeman. "Tumour-Induced Angiogenesis: A Review", *Journal of Theoretical Medicine*, 2003

Publication

<1 %

33

Michael M. Vickers, Daniel Y. C. Heng. "Prognostic and predictive biomarkers in renal cell carcinoma", *Targeted Oncology*, 2010

Publication

<1 %

34

Y Takakura. "Inhibition of tumor cell growth in the liver by RNA interference-mediated suppression of HIF-1 $\alpha$  expression in tumor cells and hepatocytes", *Gene Therapy*, 04/2008

Publication

<1 %

35

Zhouyan Pan, Kehua Que, Jie Liu, Guangxu Sun, Yi Chen, Lisha Wang, Yangqiu Liu, Jiaxin Wu, Yaxin Lou, Mengming Zhao. "Effects of at-home bleaching and resin infiltration treatments on the aesthetic and psychological status of patients with dental fluorosis: A prospective study", Journal of Dentistry, 2019

Publication

&lt;1 %

36

"Invasive Diagnostics and Therapy", Springer Science and Business Media LLC, 2022

Publication

&lt;1 %

37

Erdenebulgan Batmunkh. "Expression of hypoxia-inducible factor-1 alpha (HIF-1 $\alpha$ ) in patients with the gallbladder carcinoma", International Journal of Clinical Oncology, 01/16/2010

Publication

&lt;1 %

38

Gordana Đorđević. "Hypoxia inducible factor-1 $\alpha$  correlates with vascular endothelial growth factor A and C indicating worse prognosis in clear cell renal cell carcinoma", Journal of Experimental & Clinical Cancer Research, 2009

Publication

&lt;1 %

39

Lam, J.S.. "Prognostic factors and selection for clinical studies of patients with kidney cancer", Critical Reviews in Oncology and Hematology, 200803

Publication

&lt;1 %



40

Yosuke Kayama. "p53-induced inhibition of Hif-1 causes cardiac dysfunction during pressure overload", Nature, 03/22/2007

Publication

<1 %

---

Exclude quotes      On

Exclude matches      Off

Exclude bibliography      On

# INCREASED HIF-1a AND VEGF EXPRESSION FOUND IN VARIOUS T STAGES OF CLEAR CELL RENAL CELL CARCINOMA

---

GRADEMARK REPORT

---

FINAL GRADE

**/100**

GENERAL COMMENTS

**Instructor**

---

PAGE 1

---

PAGE 2

---

PAGE 3

---

PAGE 4

---

PAGE 5

---

PAGE 6

---