

Myofunctional Therapy Using Twin Block Appliance in a Class II Malocclusion Patient with ADHD

Yufta Fitriani, DDS, Mega Moeharyono Puteri, DDS, PhD,
Sindy Cornelia Nelwan, DDS, PhD and Nur Masyitah Iskandar Putri, DDS

Department of Pediatric Dentistry, Faculty of Dental Medicine, Universitas Airlangga, Surabaya, Indonesia

ABSTRACT

A 9-year-old male ADHD patient with class II dentoskeletal malocclusion came to the Pediatric Department of Universitas Airlangga, Surabaya, with a chief complaint of a protrusive look. The patient had a behavior disorder of ADHD (Attention Deficit Hyperactivity Disorder), in which its symptoms may be challenging in dental treatment since it heavily depends on the patient's obedience and case selection. References and similar studies of myofunctional therapy in Class II Malocclusion Patients with ADHD are still scarce. Most patients with class II malocclusion present with hyperactive perioral muscle and altered tongue position. Hence, myofunctional appliance is a reliable treatment choice. A special rule where the patient was asked to focus on the operator's instruction for 10 minutes and then a 5-minute break, was applied to this patient to overcome ADHD symptoms as a behavior management strategy. This is in line with a theory stating that children with ADHD are prone to distraction, causing them to have a shorter duration of focus, limited sustained attention span, poor impulse control, and motor overactivity compared to normal children. This strategy gave a positive result in maintaining the cooperation of the patient using the twin block for 6 months which is lead to positive progress in malocclusion correction.

Keywords: ADHD, Class II Malocclusion, Myofunctional Therapy, Twin Block Appliance

INTRODUCTION

One of the most common behavior disorders found in children, that even persists into adulthood, is Attention Deficit Hyperactivity Disorder (ADHD).¹ The ADHD prevalence around the world is about 5,3%.² Data obtained from 2002 to 2004 state that the prevalence of ADHD in Indonesia is at least 10% in the children population and adolescents aged 3-18 years, and the data for 2009 showed an increase to 15.8% in that age range.³ Attention Deficit Hyperactivity Disorder has three main symptoms, namely inattention, hyperactivity, and impulsivity, or the combination of them. These symptoms often lead to difficulties in the dental care of children with ADHD.² Most patients with class II malocclusion present with hyperactive perioral muscle and altered tongue position. Class II malocclusion is a problem found in one third of normal patients presenting for orthodontic treatment.⁴ Removable orthodontic treatment, such as myofunctional appliance, on children with ADHD, is challenging for a dentist since the success of the procedure heavily depends on the patient's obedience and case selection. In reviewing some literature, the authors found only about myofunctional therapy in Class II Malocclusion or management behavior of ADHD patients in dental treatment. References and similar studies of myofunctional therapy in Class II Malocclusion Patients with ADHD are still scarce,⁴ motivating the authors to publish this case.

Corresponding author: Mega Moeharyono Puteri, DDS, PhD
Department of Pediatric Dentistry
Faculty of Dental Medicine
Universitas Airlangga
Surabaya, Indonesia
Email: mega-m-p@fkg.unair.ac.id

CASE REPORT

A nine-year-old male Javanese patient, a deuto melayu race, came accompanied by his mother to the Pediatric Dental Clinic of Universitas Airlangga with a chief complaint of protrusive and crowded front teeth. The patient was diagnosed with a behavioral disorder of ADHD 2 years ago and regularly visited the child psychiatry clinic for intensive treatment until now.

Intra- and extraoral examination showed class II malocclusion, convex profile, lip incompetence (Figure 1), Ektomorf profile but still normal at his age, transitional dentition, poor oral hygiene, 11 mm overjet, 6 mm overbite, mandibular anterior crowding, a positive curve of Spee, right molar relationship distoclusion and edge-to-edge left molar (Figure 2). The patient looked had a bad habit of biting lower lip and deny other types of bad habits. Soft tissue analysis showed that the patient's soft tissue profile was categorized as protrusive. But the patient's pronunciation wasn't affected by the protrusive condition. The mother looked the same as the protrusive profile, and she explained that she and the patient have the protrusive looks in the family.

Based on the mother's explanation, the patient had poor impulse control, motor overactivity compared to normal children, prone to distraction, had a shorter duration of focus, limited sustained attention span, and also impulsive. Due to these characteristics, the patient has difficulty focusing on learning in school. But there is not any mental, cognitive, or developmental aberration as explained by the patient's doctor in the Psychiatry Department.

Based on the supporting examination using cephalometry, the patient was in the prepubertal growth phase / Cervico Vertebrae Maturation (CVM) stage 1 (Figure 3).

CASE MANAGEMENT

The patient's skeletal growth was in the prepubertal phase (CVM stage 1), indicating a potential for modification toward class I skeletal growth.⁵ Class II malocclusion is often followed by muscle hyperactivity around the mandible and tongue thrust.⁶ Accordingly, in this case, myofunctional therapy was selected as the treatment and a twin block appliance was used. Treating a child with ADHA and needing corrective orthodontic intervention requires a team

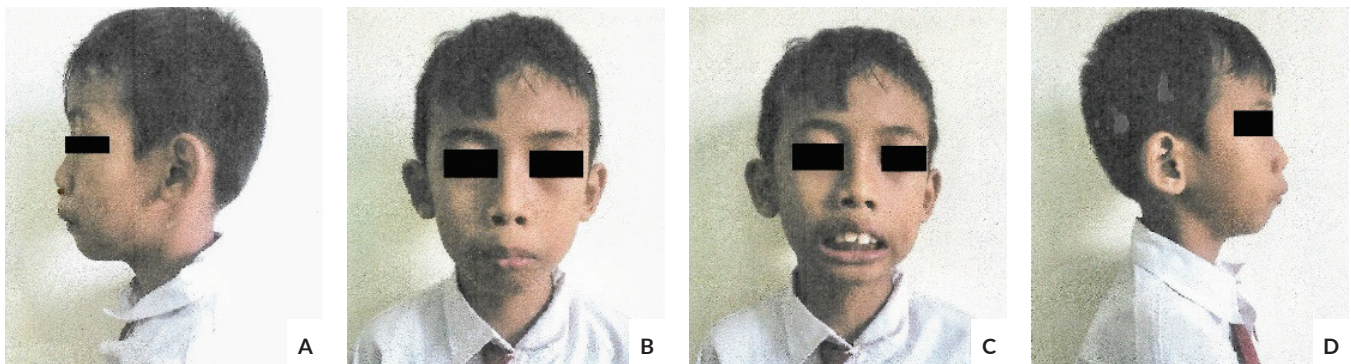


Figure 1. Pre-treatment extraoral photo. (A) left-side view, (B) (C) frontal view, (D) right-side view.

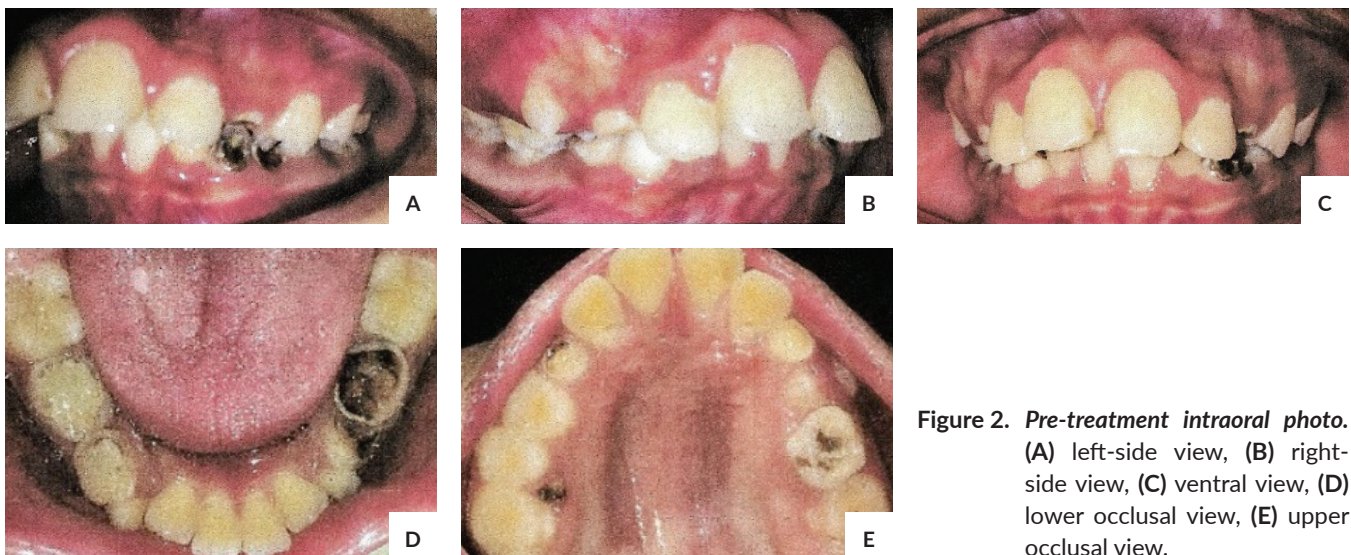


Figure 2. Pre-treatment intraoral photo. (A) left-side view, (B) right-side view, (C) ventral view, (D) lower occlusal view, (E) upper occlusal view.

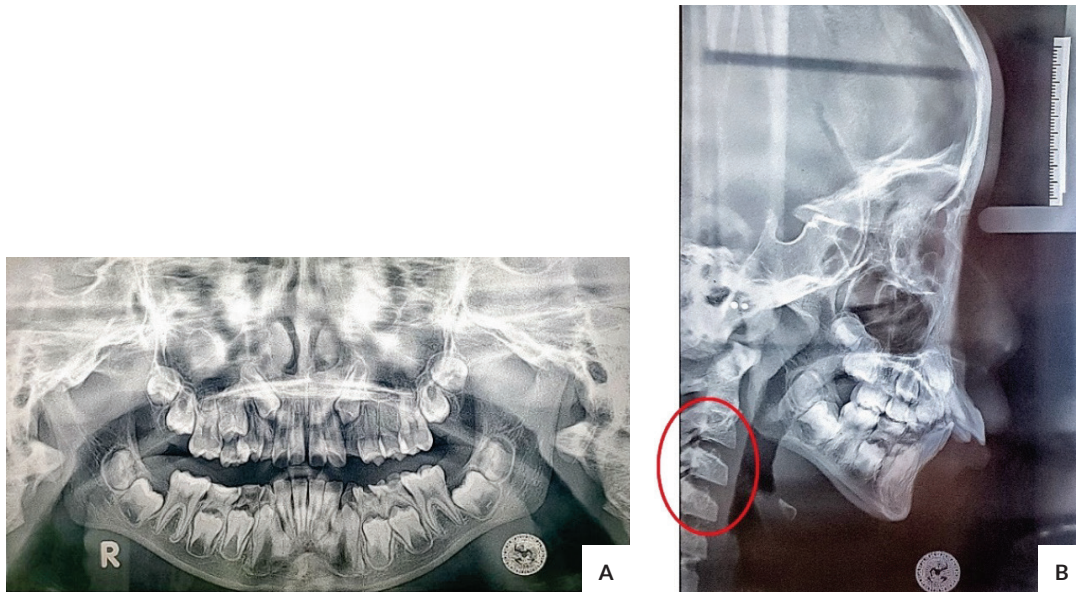


Figure 3. Supporting photo. (A) panoramic (B) cephalometry.

approach involving the dental team, behavioral specialist, and particularly the cooperation and supervision of the guardians.

Correction of Class II malocclusion may be approached by growth modification (functional), dental camouflage, and surgical orthodontics.⁷ Twin block appliance was selected because it is simpler than other myofunctional appliances especially for an ADHD patient who prone to distraction. After all, they have a shorter duration of focus,

limited sustained attention span, poor impulse control, and motor overactivity compared to normal children, so the cooperativity of wearing a removable myofunctional appliance is so much tricky for this kind of patient.² Twin block is a reliable treatment choice for this prepubertal's growth phase. The adjustment and patient follow-up were made every month by reducing the occlusal side of the mandible block to stimulate the teeth development in the vertical direction. The patient's skeletal growth was directed to class I by locking the mandible to anterior with the inclined plane of the twin block (Figure 4). The patient was asked to wear the twin block appliance for 24 hours a day for six months. The mother was instructed by the operator to recheck the position of the twin block every day.

Table 1. Comparison between Pre- and Post-treatment skeletal analysis value

Parameter	Normal value	Pre-treatment patient	Post-treatment patient	Criteria
SNA	83.5 ± 2°	90°	90°	Skeletal Analysis
SNB	81 ± 2°	79°	83°	
ANB	2.5 ± 2°	11°	7°	
A - M line	2 ± 2 mm	9 mm	8 mm	
B - M line	-1 ± 2 mm	0 mm	0 mm	
Wits	1 ± 2 mm	9 mm	4 mm	
Go - Gn - Sn	32° ± 3°	35°	35°	
FMA	26° ± 3°	34°	30°	
I - SN	109° ± 6°	119°	114°	Dental Analysis
I - MP	96° ± 5°	89°	97°	
I - I	125° ± 5°	112°	120°	
Naso labial angle	93° ± 3°	110°	110°	Soft tissue analysis
Lower lip to - E line	1 ± 1 mm	11 mm	8 mm	

- SNA : Sella-Nasion-Subspinale (A point)
- SNB : Sella-Nasion-Supramentale (B point)
- ANB : A point/subspinale-Nasion-Supramentale
- FMA : Frankfurt-Mandibular-Angle
- MP : Mandibular-Plane
- M line : Mandibular line
- Go-Gn-Sn : Gonion-Gnathion-SellaNasion
- SN : Sella-Nasion

At the end of the sixth month, a positive result was obtained. The patient's protrusive profile decreased; it becomes a 5 mm overjet and 4 mm overbite, end-to-end right molar relation and neutroclusion in the left (Figure 5). The treatment was planned to be continued using fixed orthodontic to optimize the result. The skeletal treatment exhibited quite significant progress, as shown in the comparison between Pre- and Post-treatment skeletal analysis values (Table 1).

DISCUSSION

Patients with ADHD exhibit different challenges for Pediatric dentistry, particularly related to treatments using myofunctional appliances, which require high cooperation.² ADHD has three main symptoms, i.e., inattention, hyperactivity, impulsivity, or the combination of them. These symptoms often lead to difficulties in the dental care of children with ADHD.² To overcome these problems, a spec le was applied, where the patient was asked to focus

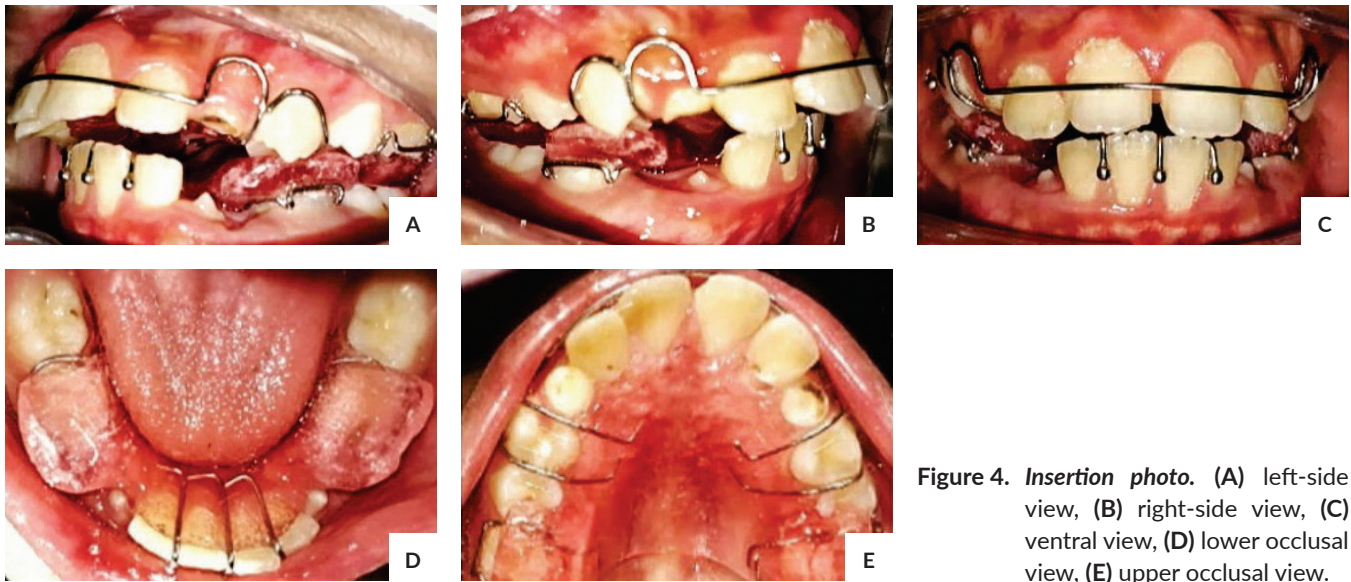


Figure 4. *Insertion photo.* (A) left-side view, (B) right-side view, (C) ventral view, (D) lower occlusal view, (E) upper occlusal view.

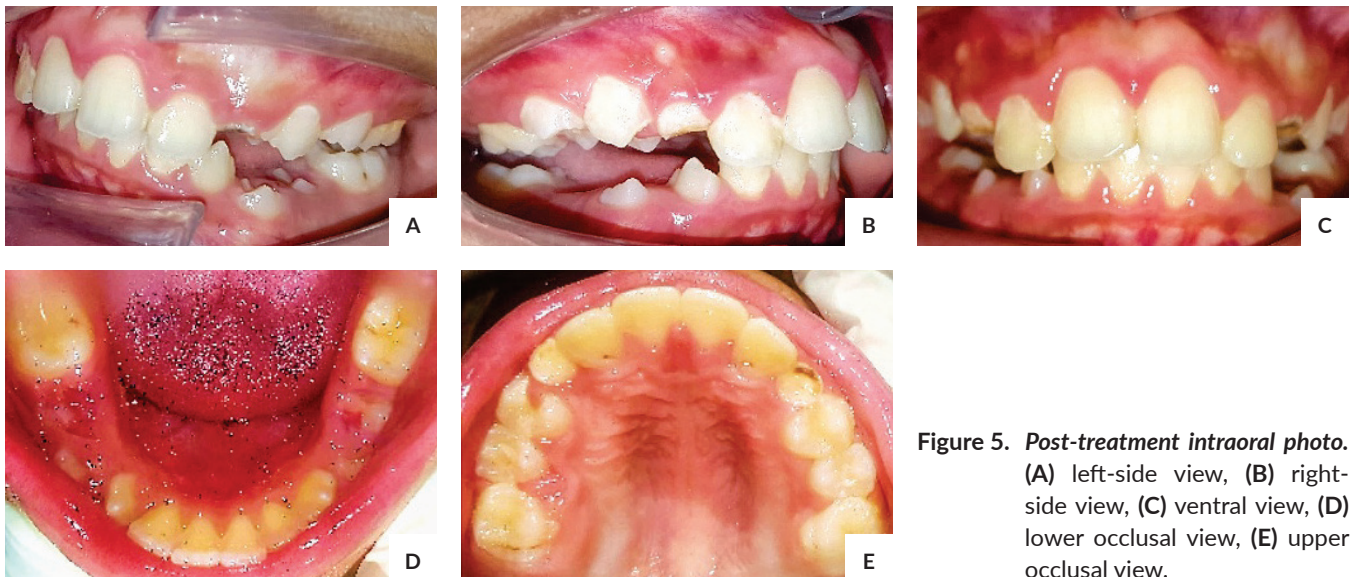


Figure 5. *Post-treatment intraoral photo.* (A) left-side view, (B) right-side view, (C) ventral view, (D) lower occlusal view, (E) upper occlusal view.

on the operator's instruction for 10 minutes and was given 5 minutes break. This is in line with a theory stating that children with ADHD are prone to distraction, causing them to have a shorter duration of focus, limited sustained attention span, poor impulse control, and motor overactivity compared to normal children.⁸ Children with ADHD of primary school age present with the inability to sustain attention beyond ten minutes while undertaking moderately challenging activities, premature changes of activity, and appearing to be forgetful, disorganized, and distracted by the environment.⁹ Treatment of choice for the patient is the twin block appliance which is a removable appliance that's relatively easy for the patient to take off and might disrupt the function of the appliance.

In this case, the parent's role in ensuring the patient follows the operators' instructions, such as that the patient

must wear the appliance regularly and properly following the operator's instructions to ensure placing the appliance precisely in the oral cavity, is very important. With a thorough evaluation, proper behavior management techniques, and the parents' supervision, this treatment strategy may yield positive results. The parent plays a pivotal external role in modifying the children's cooperative ability. According to the parental personality theory, the character of the patient's parent was categorized as appropriate, as they exhibit positive behavior toward dental care. Besides, they facilitated positive interaction between children and the dentist to control the patient's behavior.¹⁰ Proper time selection (i.e., in the morning) and a dental chair near a television served as a distraction when the patient's focus began to decrease to follow the operator's instruction along with the dental treatment. This successful treatment was also supported by

regular therapy (improvement therapy of focusing capability) four times a month in the child psychiatry clinic so that the patient's ADHD symptom was properly managed.

Maxillofacial morphology is significantly affected by the masticatory muscles.¹¹ Most of class II skeletal malocclusion in patients is followed by perioral muscle disorders.⁶ Twin block is an effective myofunctional appliance for patients in a growing phase.² This appliance works by using the strength of perimandibular muscles. It directs the mandible to move toward the anterior by using neuromuscular strength of masticatory muscle around mandible (m. masseter, m. temporalis, m. Pterygoid Lateralis, m. Pterygoid medialis), thus leading to orthopedic changes.²

The masticatory muscle mechanism in mandible correction toward the anterior locks the mandible in the inclined plane of the twin block. Such a condition can increase the neuromuscular stress; this stress is transmitted to basalis, leading to changes in the internal and external structure of basal bone. There was an increase in mandibular condyle volume, mandible length, and condyle distance by stimulating the mandible growth direction forwards and backward. All of them were reflected in condyle volume increasing. This skeletal change can increase the SNB value and decrease the ANB value (orthopaedic correction) in class II malocclusion therapy.¹²

Among various removable and fixed functional appliances, the twin-block and Herbst appliance, respectively, are most efficient in correcting a Class II malocclusion. Moreover, removable appliances are considered uncomfortable and unesthetic by many patients and require patient compliance.

The patient's ADHD symptoms often lead to difficulty for the operator. This is in line with a theory stating that children with ADHD are prone to distraction, causing them to have a shorter duration of focus, limited sustained attention span, poor impulse control, and motor overactivity compared to normal children.⁸ However, in this case, the twin block yields a positive result in this class II malocclusion of the patient with ADHD. This positive result was obtained from the synergy of parents' positive character in their child's dental care and proper behavior management as discussed above to control the ADHD symptoms.

CONCLUSION

Patients with ADHD exhibit different challenges for Pediatric dentistry, particularly related to treatments using myofunctional appliances. In this Case Report myofunctional therapy yields positive results in class II malocclusion of a patient with ADHD with a thorough evaluation, 10 minutes treatment, and 5 minutes breaking rules as management behavior and also supported by the parents' supervision.

Acknowledgment

The authors thank the parent of this patient for permitting to publish this case and to the Pediatric Department, Faculty of Dental Medicine, Universitas Airlangga, Surabaya, Indonesia for the support in the case publication.

Statement of Authorship

All authors participated in the data collection and analysis and approved the final version submitted.

Author Disclosure

All authors declared no conflicts of interest.

Funding Source

No funding support.

REFERENCES

1. Shivanna V, Mallenahalli Y. Behavioral Management in Child with Attention Deficit Hyperactive Disorder- Review. *J Dent Oral Heal* 2016 June;2.
2. Sinha S, Praveen P, Rani SP, Anantharaj A. Pedodontic Considerations in a Child with Attention Deficit Hyperactivity Disorder: Literature Review and a Case Report. *Int J Clin Pediatr Dent* 2018 Sept;11: 254-9.
3. Karunia A. Pengaruh Psikoedukasi tentang Pengetahuan ADHD terhadap Kemampuan Guru dalam Melakukan Deteksi Dini Masalah ADHD pada Siswa dan Keterampilan Intervensi Kelas. *INSAN* 2016 Juni;01:1-11.
4. Tariq M, Maheshwari S, Asif S, Qamar Y, Pathak S. Effect of Twin Block Appliance on a Growing Patient – A Case Report. *Inter Ped Dent* 2018 Apr;1:61-4.
5. Perinetti G, Primo J, Franchi L, Contardo L. Treatment Effects of Removable Functional Appliances in Pre-Pubertal and Pubertal Class II Patients : A Systematic Review and Meta- Analysis of Controlled Studies 2015 Mar;1-35.
6. Nishi, Shamima Easmin; Basri, Rehana; Rahman, Norma Ab; Khurseed Alam M. Association between muscle activity and overjet in class II malocclusion with surface electromyography. *J Orthod Sci* 2018 Apr;7.
7. Chowdhary S. Management of severe Class II malocclusion with sequential modified twin block and fixed orthodontic appliances. *APOS Trends Orthod* 2016 Dec;6:113-8.
8. Afolabi OE. Attention-Deficit Hyperactivity Disorder (ADHD) in Children: A Move towards Developmental Perspectives. *Int J Sch Cogn Psychol* 2016 Apr;3.
9. Ougrin D, Chatterton S, Banarsee R. Attention deficit hyperactivity disorder (ADHD): Review for primary care clinicians. *London J Prim Care (Abingdon)* 2010 Mar;45-51.
10. Jain V, Sarkar S, Saha S, Halder S. Basic Behaviour Guidance Factors and Techniques for Effective Child Management in Dental Clinic - An Update Review. 2016 June;3:177-82.
11. Evans C. The Relationship between Caries and Malocclusion in Chinese Migrant Workers' Children in Shanghai. *Chinese J Dent Res* 2016 June;18:103-10.
12. Zou J, Meng M, Law CS, Rao Y, Zhou X. Common dental diseases in children and malocclusion. *Int J Oral Sci* 2018 Mar;1-7.

INFORMED CONSENT
(SURAT PERSETUJUAN TINDAKAN)

Surat pernyataan ini menjelaskan bahwa,

Nama : [REDACTED]
Tempat/Tanggal lahir : [REDACTED]
Nomor KTP : [REDACTED]
Alamat : [REDACTED]
[REDACTED]

Sebagai orang tua dari pasien,

Nama : [REDACTED]
Tempat/Tanggal lahir : [REDACTED]
Alamat : [REDACTED]
[REDACTED]


Memberikan pernyataan bersedia dengan rencana perawatan dan memberikan persetujuan untuk dokter gigi untuk mendokumentasikan dan menerbitkan foto perawatan anak saya tersebut baik foto sebelum dan sesudah perawatan tanpa disertai identitas pasien untuk keperluan penerbitan jurnal setelah menerima penjelasan medis dari dokter gigi yang merawat. Saya membuat persetujuan ini dalam kondisi sadar dan sejujurnya serta tanpa paksaan dari pihak manapun.


Surabaya, 30 September 2020

Orang tua,

Dokter Gigi,

Saksi,


(.....)


[REDACTED]


([REDACTED])