

Distribution of dense bone island in the jaw based on the classification of radiopaque areas and their location on panoramic radiographs

by Eha Renwi Astuti

Submission date: 09-Apr-2023 03:30PM (UTC+0800)

Submission ID: 2059420657

File name: rtikel_6_Distribution_of_dense_bone_island_in_teh_jaw_based.pdf (445.12K)

Word count: 3305

Character count: 16850

<http://jurnal.pdgi.or.id/index.php/jrdi/index>

Distribution of dense bone island in the jaw based on the classification of radiopaque areas and their location on panoramic radiographs

Yunita Savitri^{1*}, Eha Renwi Astuti¹ , Aga Satria Nurrachman¹ ,
Sri Wigati Mardi Mulyani¹, Dina Karimah Putri¹, Diana Lilik Zainiyah², Hilda Majidah²

ABSTRACT

Objectives: This study is aimed to find out the distribution of DBI in the jaw based on the classification of radiopaque areas and their location using panoramic radiographs at RSKGMP Universitas Airlangga Surabaya.

Materials and Methods: This research was a descriptive observational study with total sampling method. The study used secondary data from panoramic radiographs at the RSKGMP Airlangga University Surabaya during 2018–2021, which had a DBI appearance, and analyzed them based on the classification of radiopaque areas and locations. The results of the analysis are then presented in the form of tables and pie charts.

Results: Classification of DBI based on radiopaque areas was found in type 5 separate (47.81%), type 4

apical (29.82%), type 3 apical and interradicular (17.54%), type 1 interradicular (3.07%), and the least in type 2 interradicular and separate (1.75%). The most common locations of the lesions were in the premolar region (42.54%), the molar region (27.63%), the canine region (12.28%), the canine-premolar region (8.33%), the premolar-molar region (6.58%), and the least common location in the incisor and incisor-canine regions (1,32%).

Conclusion: Classification of DBI based on the most common radiopaque area was found to be type 5 separate, with the most lesion locations in the premolar region. While the least classification was found in type 2 interradicular and separate, the incisive and incisive-canine regions had the fewest lesion locations.

Keywords: Dense bone island, distribution, jaw, panoramic radiographs, health service

Cite this article: Savitri Y, Astuti ER, Nurrachman AS, Mulyani SWM, Putri DK, Zainiyah DL, Majidah H. Distribution of dense bone island in the jaw based on the classification of radiopaque areas and their location on panoramic radiographs. Jurnal Radiologi Dentomaksilofasia Indonesia 2022;6(2)65-8. <https://doi.org/10.32793/jrdi.v6i2.874>

INTRODUCTION

Dense bone island (DBI), also known as periapical enostosis and idiopathic osteosclerosis, is the most common asymptomatic lesion found in the mandible around the roots of premolars and molars. Most cases of DBI are discovered incidentally during radiographic examinations, such as periapical and panoramic radiographs that are performed to diagnose other diseases.^{1,2} Panoramic radiography is one of the most frequently used radiographic techniques in dentistry which produces an overall view of the maxilla and mandible as well as surrounding tissues and are used as a first step to detect and obtain information for further treatment steps.³ Therefore, panoramic radiographs can be used to see the presence of DBI in the jaw.

The cause of DBI itself is still unclear, but it is thought to have a relationship with the blood supply and the presence of internal pressure that affects the formation of jaw bone mass. DBI can also be thought of as a type of bone development that is unrelated to local stimuli.^{2,4} On the radiograph, DBI appears as a localized radiopaque mass with well-defined boundaries.⁵ DBI can be

round, elliptical, or irregular in shape, varying in size from 2-3 mm to 1-2 cm in diameter and unrelated to tooth vitality.¹ DBI can occur at the root apex, between roots or in separate locations far from the teeth, especially in the premolar or molar region.⁵ These lesions are more common in adults as well as in the female sex.^{2,6} According to the study by Tolentino *et al.*,⁷ conducted on 20 samples, the description of DBI based on age, sex, size, shape, and location of the jaws and teeth differ from one individual to another.

Based on the classification of radiopaque areas, DBI was classified into five types: type 1 interradicular (lesions located between the roots and interrelated with the lamina dura of adjacent teeth), type 2 interradicular and separate (lesions located between the roots and not interrelated with the lamina dura of adjacent teeth), type 3 apical and interradicular (lesion located at the apex and showing significant extension between roots), type 4 apical (lesion located around the root apex), and type 5 separate (lesion located apically and clearly separated from the tooth and lamina dura).^{1,4} Based on previous studies, the most



This work is licensed under a Creative Commons Attribution 4.0 International License, which permits use, distribution and reproduction in any medium or format, provided that the original work is properly cited, the use is non-commercial and no modifications or adaptations are made.

¹Department of Dentomaxillofacial Radiology, Faculty of Dental Medicine, Universitas Airlangga, Surabaya, Indonesia 60132

²Faculty of Dental Medicine, Universitas Airlangga, Surabaya, Indonesia 60132

*Correspondence to:
Yunita Savitri
✉ yunita-s@fkg.unair.ac.id

Received on: May 2022
Revised on: July 2022
Accepted on: July 2022

common types were type 4 apical and type 5 separate. Based on the results of study by Sisman *et al.*¹ showed type 4 apical as the most common type found (51.6%), followed by type 5 separate (22.9%). In the study of Jain *et al.*⁸, a slight difference was shown where type 5 separate was the most common type (49.3%), followed by type 4 apical (32.4%).

DBI itself can cause complications in the jaw, such as root resorption and changes in tooth position, which can cause complications in orthodontic treatment.⁹⁻¹¹ The impact of DBI on orthodontic treatment is the difficulty of achieving adequate space closure and root tips. DBI that is in contact with adjacent teeth in orthodontic treatment can complicate treatment because it causes damage to adjacent teeth so that the length of treatment becomes prolonged.¹²

DBI with root resorption is a rare case, is self-limiting and does not require further action or treatment.¹⁰ Further investigation is needed, especially if multiple DBI cases are found, because it may be associated with *Gardner syndrome*, which is an autosomal dominant disease characterized by bone malformations and soft tissue tumor development associated with mutations in the adenomatous polyposis coli (APC) gene.¹³ *Gardner syndrome* that is not treated has a 100% chance of becoming malignant.¹² In addition, research and data that discuss the classification of DBI based on radiopaque areas and locations in the jaw in Indonesia are still rarely studied. So the authors are interested and want to know how the distribution of DBI is based on the classification of radiopaque areas and locations on the jaw with panoramic radiographic observations at RSKGMP, Airlangga University Surabaya.

MATERIALS AND METHODS

This research is a descriptive observational study with a total sampling method. The research was conducted at the RSKGMP Airlangga University Surabaya in August-September 2021 and has been approved by the Health Research Ethics Commission, Faculty of Dentistry, Airlangga University with registration number 424/

HRECC.FODM/VII/2021. The population in this study is secondary data from panoramic radiographs of patients at RSKGMP Airlangga University Surabaya in the period 2018-2021, with a total of 448 panoramic radiographs. The samples used were all secondary data from panoramic radiographs taken at RSKGMP Airlangga University Surabaya during 2018-2021 which had DBI images in the jaw in the form of a localized radiopaque mass with well-defined, round, elliptical, or irregular shapes and sizes that varied with quality. Radiographs according to good quality evaluation.

Dental radiographs with deep caries or large restorations, increased lamina dura thickening around teeth with marked malposition, teeth serving as abutments for bridged or partial dentures, solitary radiopaque lesions in the edentulous region, and lesions with radiographic features resembling DBI, including periapical osseous dysplasia, periapical sclerosing osteitis, odontoma, and cementoblastoma, were excluded from the study.¹ According to the criteria, samples were analyzed based on the classification of radiopaque areas and locations by calculating the percentage. The results of the analysis were then presented in the form of tables and pie charts.

RESULTS

In this study, there were 205 panoramic radiographs that matched the criteria, with all DBI in the mandible. Table 1 shows the number of DBI found per year, which is 89 panoramic radiographs in 2018, 50 panoramic radiographs in 2019, and 66 panoramic radiographs in 2020-2021. Table 1 also shows 182 radiographs of multiple DBI lesions with one DBI lesion and 23 radiographs with two DBI lesions. The total lesions found were 228.

Figure 1 shows the distribution of DBI by five types of radiopaque areas classification. The largest percentage was found in type 5 separate, with 109 lesions (47.81%), followed by type 4 apical with 68 lesions (29.82%), type 3 apical and interradicular with 40 lesions (17.54%), and type 1 interradicular with 7 lesions (3.07%). The lowest percentage was found in type 2 interradicular and separate with 4 lesions (1.75%).

Table 1. The number of DBI in the mandible on panoramic radiographs

Year	Total Panoramic Radiography With DBI	Percentage of Number of Lesions					
		Radiograph with One Lesion	Number of lesions	Percentage	Radiography with Two Lesions	Number of lesions	Percentage
2018	89	84	84	36,84%	5	10	4,39
2019	50	43	43	18,86%	7	14	6,14%
2020-2021	66	55	55	24,12%	11	22	9,65%
Total	205	182	182	79,82%	23	46	20,18%
Total DBI Lesion		182 (79,82%)			46 (20,18%)		
		228 (100%)					

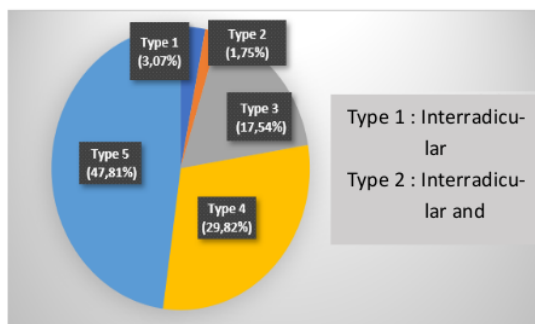


Figure 1. Distribution of DBI based on radiopaque area classification

Table 2. Distribution of DBI based on radiopaque areas classification and locations

Locations	Classification of DBI based on radiopaque areas					Total	Percentage
	Type 1	Type 2	Type 3	Type 4	Type 5		
Incisive	0	0	1	0	2	3	1,32%
Incisive-Caninus	0	0	2	0	1	3	1,32%
Caninus	0	0	1	13	14	28	12,28%
Caninus-Premolar	1	1	6	1	10	19	8,33%
Premolar	4	3	15	24	51	97	42,54%
Premolar-Molar	0	0	8	1	6	15	6,58%
Molar	2	0	7	29	25	63	27,63%
Total						228	100%

DISCUSSION

The results showed that two variations in the number of DBI lesions were found, that is panoramic radiographs with one DBI lesion and two DBI lesions. Previous studies have found one to three DBI lesions on a radiograph, with the most common variation found being one lesion.^{1,4,5,8,15,16} This study also found the same results where one DBI lesion was the most common lesion.

DBI in the jaw can be found in both the maxilla and mandible. In this study, all DBI lesions found were in the mandible (100%), with the largest locations in the premolar and molar regions and the lowest locations in the incisor-canine region. This is in accordance with the study by Verzak *et al.*¹⁴ who found 97.06% of DBI lesions were in the mandible, the study by Misirlioglu *et al.*⁴ who found 97.9% of DBI lesions were in the mandible, as well as the studies by Li *et al.*¹⁵ and Fuentes *et al.*¹⁶ who found an overall DBI lesion in the mandible.

The studies by Misirlioglu *et al.*⁴ and Farhadi *et al.*¹⁷ also found that the premolar region was the most common location of DBI lesions, although there was a study by Li *et al.*¹⁵, Verzak *et al.*¹⁴, and Jain *et al.*⁸ who found that the molar region was the most common area where DBI lesions were found. The mandibular premolar region was the most

common location for DBI to be found because the mandibular premolar region was distorted on the inside. In addition, differences in anatomy and blood supply can also affect, where the area near the mental foramen receives sufficient blood supply so that it is easier to form bone mass.^{4,14,15} The location of DBI in the premolar and molar regions may be an indication that the DBI lesion represents root residues from primary molars that have been resorbed and replaced by sclerotic bone.^{4,6,17} The location of the least number of DBIs found is also in accordance with several studies that have been carried out previously, namely in the incisive region.^{5,8,15}

Type 5 separately and type 4 apical are the two types of classification that are most commonly found compared to other types. Type 4 apical factor is one of the most common types of classification due to occlusion and traumatic movement, which can be the reason for DBI. A slight imbalance in the occlusion can provide sufficient vibrational stimulus to support bone formation.^{1,8}

In this study, the most common type of classification found was type 5 separate. These results are in accordance with studies by Azizi *et al.*⁹ and Jain *et al.*⁸ Factors that cause many of this type can be due to the absence of a stimulus effect from excessive occlusion (local stimulation) or residue

from tooth fragments, so it can support the possibility that DBI is a variation of the development of bone anatomy.^{1,15} The study by Verzak *et al.*¹⁴ also supports the theory that DBI is considered a variant of normal bone development unrelated to local stimuli.

DBI can affect treatment in dentistry. The types of classification based on radiopaque areas that have an influence on treatment in the field of dentistry are type 3 apical and interradicular and type 4 apical. A study by Sinnott & Hodges¹² showed DBI of type 3 interradicular and separated, with a size of 24 mm that intersects with adjacent teeth and extends from tooth 13 to tooth 12. The presence of DBI complicates planned orthodontic treatment and causes root resorption.

One of the orthodontic treatment cases studied by Alfahad *et al.*¹⁸ showed that type 4 apical DBI caused mesial root resorption in tooth 46 and suggested further monitoring during orthodontic treatment. The study by Dananjaya Agung & Lestari¹⁹ also found DBI with type 4 apical in the periapical area of tooth 48 that did not erupt completely (impacted), indicating that DBI could block tooth eruption even in the jaws that had sufficient space for eruption.

DBI is a harmless lesion, so it does not require treatment. However, further examination is needed if multiple cases of DBI are found because they can be associated with *Gardner syndrome*, which can potentially become malignant. As many as 80% of patients with *Gardner syndrome* show early signs of maxillofacial disease, in the form of features such as osteoma in the jaw, supernumerary teeth, and impaction that can be detected on routine panoramic radiographs. Some patients may have multiple signs, but other patients may have all of the features of *Gardner syndrome*, so the diagnosis of *Gardner syndrome* can be challenging because of the variety of clinical manifestations¹³, therefore, dentists can play a role in screening for *Gardner syndrome*. In addition, it is necessary to monitor DBI, regular radiographic reports (as in the case of orthodontic treatment), and careful treatment measures to prevent potential damage to the teeth and surrounding area.^{13,18}

CONCLUSION

Based on the results of the research conducted, it can be concluded that the most classification of DBI based on radiopaque area was found in type 5 separate with the most locations located in the premolar region. While the least classification was found in type 2 interradicular and separate with the least locations located in two locations, there were on the incisive region and the incisive-canine region.

ACKNOWLEDGMENTS

None.

FOOTNOTES

All authors have no potential conflict of interest to declare for this article. This research was registered and approved by the Research Ethics Committee with the registration number of 424/HRECC.FODM/VII/2021. All procedures conducted were in accordance with the ethical standards.

REFERENCES

- Sisman Y, Ertas ET, Ertas H, Sekerci AE. The frequency and distribution of idiopathic osteosclerosis of the jaw. *Eur J Dent.* 2011;5(4):409-414.
- Rahman F, Epsilawati L, Pramanik F, Febriani M. Temuan insidental lesi radiopak asimtomatik pada pemeriksaan radiografi panoramik: laporan 3 kasus dan ulasan pustaka Dense Bone Island (DBI). *Jurnal Radiologi Dentomaksilofasial Indonesia (JRDI).* 2019;3(2):35-40.
- White SC, Pharoah MJ. *Oral radiology: principles and interpretations*, 7th ed. St. Louis: Elsevier Mosby; 2014.
- Misirliglu M, Nalcaci R, Adisen MZ, Yilmaz S. The evaluation of idiopathic osteosclerosis on panoramic radiographs with an investigation of lesion's relationship with mandibular canal by using cross-sectional cone-beam computed tomography images. *J Oral Maxillofac Radiol.* 2013;1(2):48-54.
- Chintala L, B B, Chaitanya YC, Chaitanya, PV, Mamatha D, Sathwik G. Dense bone islands of the maxillofacial region : A radiological study. *Int. J. Appl. Dent. Sci.* 2017; 3(4):258-260.
- Yusof MYPM, Dasor MM, Ariffin F, Reduwan NH, Kamil WNWA, Mah MC. Idiopathic osteosclerosis mimicry of a tooth: case report. *Aust Dent J*;65(4):308-312. 2020.
- Tolentino E, Gusmão PH, Cardia GS, Tolentino L, Iwaki LC, Amoroso-Silva PA. Idiopathic Osteosclerosis of the Jaw in a Brazilian Population: a Retrospective Study. *Acta Stomatol Croat.* 2014;48(3):183-192.
- Jain PG, Nair P, Choudhary PJ, Sathe R, Sood M, Agrawal K. Sclerosing Lesions of the Jaw Bones: a Prevalence Study in Bhopal Population. *Int J Recent Sci Res.* 2018;9(4):25764-25769.
- Azizi Z, Mosaferi H, Safi Y, Dabirzadeh S, Vasegh Z. Prevalence of Idiopathic Osteosclerosis on Cone Beam Computed Tomography Images. *Journal of Dental School Shahid Beheshti University of Medical Science.* 2017;35(2):71-77.
- Syed AZ, Yannam SD, Pavani G. Research: Prevalence of Dense Bone Island. *Compend Contin Educ Dent.* 2017;38(9):e13-e16.
- Huang HY, Chiang CP, Kuo YS, Wu YH. Hindrance of tooth eruption and orthodontic tooth movement by focal idiopathic osteosclerosis in the mandible. *J Dent Sci.* 2019;14(3):332-334.
- Sinnott PM, Hodges S. An incidental dense bone island: A review of potential medical and orthodontic implications of dense bone islands and case report. *J Orthod.* 2020;47(3):251-256.
- Baldino ME, Koth VS, Silva DN, Figueiredo MA, Salum FG, Cherubini K. Gardner syndrome with maxillofacial manifestation: A case report. *Spec Care Dentist.* 2019;39(1):65-71.
- Verzak Z, Celap B, Modrić VE, Sorić P, Karlović Z. The prevalence of idiopathic osteosclerosis and condensing osteitis in Zagreb population. *Acta Clin Croat.* 2012;51(4):573-577.
- Li N, You M, Wang H, Ren J, Zhao S, Jiang M, Xu L, Liu Y. 2013. Bone islands of the craniomaxillofacial region. *J Cranio-Maxillary Dis.* 2013;2(1):5-9.
- Fuentes R, Arias A, Astete N, Farfán C, Garay I, Dias F. Prevalence and morphometric analysis of idiopathic osteosclerosis in a Chilean population. *Folia morphol.* 2018;77(2):272-278.
- Farhadi F, Ruhani MR, Zarandi A. Frequency and pattern of idiopathic osteosclerosis and condensing osteitis lesions in panoramic radiography of Iranian patients. *Dent Res J.* 2016;13(4):322-326.
- Alfahad S, Alostad M, Dunkley S, Anand P, Harvey S, Monteiro J. Dense bone islands in pediatric patients: a case series study. *Eur Arch Paediatr Dent.* 2021;22(4):751-757.
- Dananjaya Agung AAG, Lestari NKA. Gambaran idiopathic osteosclerosis gigi molar ketiga impaksi pada radiograf Cone Beam Computed Tomography. *Jurnal Radiologi Dentomaksilofasial Indonesia (JRDI).* 2021;5(1):17-22.

Distribution of dense bone island in the jaw based on the classification of radiopaque areas and their location on panoramic radiographs

ORIGINALITY REPORT

9%

SIMILARITY INDEX

8%

INTERNET SOURCES

6%

PUBLICATIONS

1%

STUDENT PAPERS

PRIMARY SOURCES

1	revistas.cientifica.edu.pe Internet Source	1%
2	www.thejcdp.com Internet Source	1%
3	www.hongkongpa.com.hk Internet Source	1%
4	dergipark.org.tr Internet Source	1%
5	www.journaljpri.com Internet Source	1%
6	journals.sbmua.ac.ir Internet Source	1%
7	Selin Yesiltepe, Ibrahim Sevki Bayrakdar, Kaan Orhan, Özer Çelik et al. "A DEEP-LEARNING MODEL FOR IDIOPATHIC OSTEOSCLEROSIS DETECTION ON PANORAMIC RADIOGRAPHS", Medical Principles and Practice, 2022 Publication	<1%

8	ajba.um.edu.my Internet Source	<1 %
9	animalbiotelemetry.biomedcentral.com Internet Source	<1 %
10	biomedicineonline.org Internet Source	<1 %
11	olddrji.lbp.world Internet Source	<1 %
12	Sri Wigati Mardi Mulyani, Eha Renwi Astuti, Otty Ratna Wahyuni, Diah Savitri Ernawati, Nastiti Faradilla Ramadhani. "Xerostomia Therapy Due to Ionized Radiation Using Preconditioned Bone Marrow-Derived Mesenchymal Stem Cells", European Journal of Dentistry, 2019 Publication	<1 %
13	www.aegisdentalnetwork.com Internet Source	<1 %
14	www.assumptionjournal.au.edu Internet Source	<1 %
15	Naufal Taqiyuddin, Fatma Yasmin Mahdani, Diah Savitri Ernawati, Meircurius Dwi Condro Surboyo et al. "Knowledge, Attitude, and Behavior of Clinical Dental Students in the Oral Care of HIV/AIDS Patients", Journal of Health and Allied Sciences NU, 2022	<1 %

16

Paula Mairead Sinnott, Samantha Hodges.
"An incidental dense bone island: A review of
potential medical and orthodontic
implications of dense bone islands and case
report", Journal of Orthodontics, 2020

<1 %

Publication

Exclude quotes Off

Exclude matches Off

Exclude bibliography On

Distribution of dense bone island in the jaw based on the classification of radiopaque areas and their location on panoramic radiographs

GRADEMARK REPORT

FINAL GRADE

/0

GENERAL COMMENTS

Instructor

PAGE 1

PAGE 2

PAGE 3

PAGE 4
