

Mandibular segmentation on panoramic radiographs with CNN Transfer Learning

by Eha Renwi Astuti

Submission date: 09-Apr-2023 03:28PM (UTC+0800)

Submission ID: 2059420203

File name: Artikel_8._Mandibular_segmentation_on_panoramic.pdf (690.91K)

Word count: 2028

Character count: 11459

Mandibular segmentation on panoramic radiographs with CNN Transfer Learning

Nur Nafiyah

Department of Informatics
Institut Teknologi Sepuluh Nopember
Surabaya, Indonesia
Department of Informatics, Universitas
Islam Lamongan
mynaff@unisla.ac.id

Chastine Faticah

Department of Informatics
Institut Teknologi Sepuluh Nopember
Surabaya
Surabaya, Indonesia
chastine@if.its.ac.id

Darlis Herumurti

Department of Informatics
Institut Teknologi Sepuluh Nopember
Surabaya
Surabaya, Indonesia
darlis@if.its.ac.id

Eha Renwi Astuti

Department of Dentomaxillofacial
Radiology, Faculty of Dental Medicine
Universitas Airlangga
Surabaya, Indonesia
eha-r-a@fkg.unair.ac.id

Ramadhan Hardani Putra

Department of Dentomaxillofacial
Radiology, Faculty of Dental Medicine
Universitas Airlangga
Surabaya, Indonesia
ramadhan.hardani@gmail.com

Esa Prakasa

Research Organizations in the Field of
Engineering Sciences
BRIN
Bandung, Indonesia
esa.prakasa@gmail.com

Abstract— Gender identification and age estimation can use the mandible bone on panoramic radiographs. The identification process using the system requires a segmentation stage. Mandibular segmentation is research that has been done a lot to get an accurate object result. The purpose of this study was to segment the mandible on a panoramic radiograph using transfer learning CNN (MobileNetV2, ResNet18, ResNet50). The CNN method has been done before, so we tried to use the CNN method to produce clear and complete mandibular segmentation results on panoramic radiographs. The dataset used to train the model was taken from the Dental Hospital, Airlangga University, Surabaya. There are thousands of datasets, and based on the criteria of a radiologist, the data used are 38 images. The best result of mandibular segmentation on panoramic radiographs is the MobileNetV2 method because the highest Jaccard mean value is 0.9522.

Keywords— mandibular segmentation, panoramic radiograph, MobileNetV2, ResNet18, ResNet50.

I. INTRODUCTION

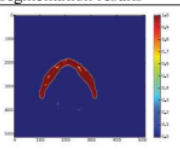

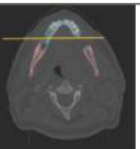
Gender identification can measuring the mandible on a victim. Gender identification can automatically using the app. One of the steps with segment the mandible of radiograph panoramic. Mandibular segmentation separates the mandible from the teeth on a panoramic radiograph [1]. Panoramic radiographic images have difficulty because the image intensity values are the same and heterogeneous. Previous studies have carried out mandibular segmentation, starting from conventional methods and based on deep learning. Several studies have attempted to develop segmentation methods to produce results that match the ground truth. Following are previous studies: Symmetric Convolutional Neural Network (SCNN) method to segment the mandible on CT scan images [2]. Another method used for mandibular segmentation on CT scanning is RCNNSeg [3], Fuzzy Connectivity [4], and CNN U-Net [5]. Another method used for segmentation in CBCT is the Conditional statistical shape model for segmenting the mandibular canal [6]; Super-voxels and graph clustering to segment the mandibular skull [7]; Recurrent SegUnet [8]; SASeg [9]. The conventional method that has been done previously is Active Contour for mandibular segmentation on panoramic radiographs [1], [10].

Previous studies, the segmentation process using the CNN method produced images that were like to ground truth. We tried to use the transfer learning Deep Learning CNN method from previous research to segment the mandible on panoramic radiographs, because previous studies have not yet segmented the mandible on panoramic radiographs using the CNN method. However, due to several previous studies using the CNN Neural Network method, the evaluation results were above 90% [2], [3], [5], [8], [9]. Therefore, this study aimed to segment the mandible using the Deep Learning CNN method (MobileNetV2, ResNet18, and ResNet50) and determine the mandibular segmentation results.

II. RELATED WORK

Mandibular segmentation has been done before to segment to help the treatment process in dentistry and the implant process. Several previous studies tried to find the correct method for segmenting the mandible. Table 1 describes several previous studies related to mandibular segmentation.

TABLE I. STATE-OF-THE-ART OF THE MANDIBULAR SEGMENTATION

Method	Image	Segmentation results
Symmetric Convolutional Neural Network (SCNN)	CT scan	 (b) SCNN-11C
RCNNSeg	CT scan	
Fuzzy Connectivity	CT scan	

U-Net CNN	CT scan	
Conditional statistical shape model	CBCT	(d)
Super-voxels and graph clustering	CBCT	
Recurrent SegUnet	CBCT	
SASeg	CBCT	
Active Contour	Panoramic Radiography	
Transfer Learning CNN	Panoramic Radiography	

III. MATERIALS AND METHODS

A. Dataset

Panoramic radiography (as in Fig. 1a) from the Academic Dental Hospital, Universitas Airlangga, Surabaya, with good quality and has been confirmed by a radiologist. In this research, the sample size used was 38 panoramic radiographs for testing [11], and 106 panoramic radiographs for modeling. The role of the radiologist is to select a dataset according to the selection criteria. Inclusion criteria: Patient age 19-72 years; Radiographic quality is good, the anatomy of the

mandible on the radiograph is clearly visible. Exclusion criteria: Unclear mandibular appearance, e.g., superimposed condylar and coronoid areas with other anatomic features; abnormalities in the mandible, e.g., growth disorders; tumors/cysts; or fracture. In addition, the role of the radiologist is to make ground truth of the mandible on panoramic radiographs. Ground truth (as in Fig. 1b) is the mandible's actual data, which has been segmented. The actual data is used as a reference for training the panoramic radiographic data to produce a model. The initial input image is the grayscale image as in Fig. 1a, the segmentation result as in Fig. 1b. The input image used in this research is an image size 224x224. The sample data has been tested like ethics by the Health Research Ethics Eligibility Commission (KKEPK) Faculty of Dentistry, Universitas Airlangga, Surabaya, with certificate number 621/HRECC.FODM/XII/2021. Fig. 2 shows the representation of the number of datasets by gender. Fig. 3 shows the representation of the number of datasets by age, ranging from 19-72. The total of data is 12 male and 26 female, with an age range of 19-72 years.

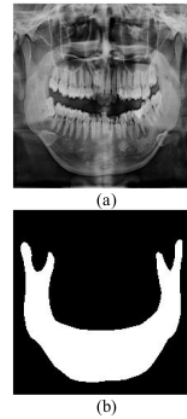


Fig. 1. (a) Panoramic radiography (b) Ground truth mandibular

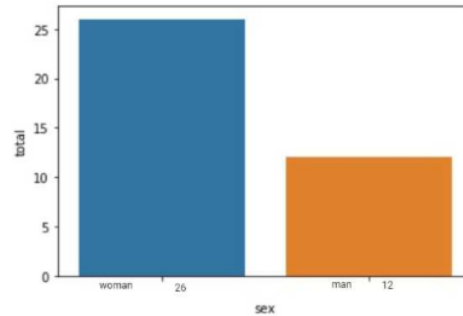


Fig. 2. Representation of dataset by gender

$$Jaccard(A, B) = \frac{|intersection(A, B)|}{|union(A, B)|} \quad (1)$$

TABLE II. CNN TRANSFER LEARNING CHARACTERISTICS

Pretrained	Size (MB)	Parameters (Millions)	Layers
MobileNetV2	13	3.5	154
ResNet18	44	11.7	71

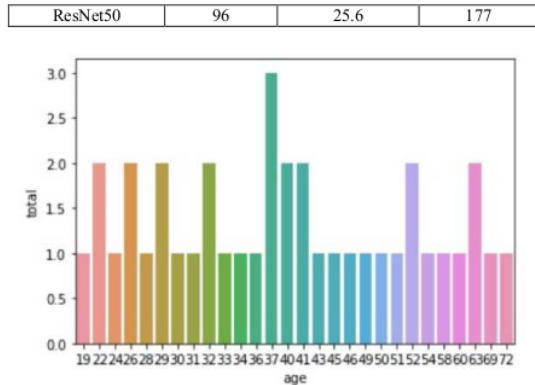


Fig. 3. Representation of dataset by age

B. CNN Transfer Learning

We propose a CNN transfer learning method (MobileNetV2, ResNet18, and ResNet50) to segment the mandible on panoramic radiographs, such as in Figure 4. The data used are panoramic radiographic images such as Figure 1a, with a size of 224x224. The segmentation results in a binary image of the mandible, as shown in Figure 1b. The method of evaluating the segmentation results using Jaccard is Equation 1. A is the segmented image, and B is the mandibular ground truth. Each transfer learning (MobileNetV2, ResNet18, and ResNet50) has a different parameter value and many layers described in Table 2. The highest number of parameters is ResNet50.

IV. RESULT AND DISCUSSION

We tested the CNN transfer learning model (MobileNetV2, ResNet18, and ResNet50) on 5 panoramic radiographs (Table 3), and the segmentation results and Jaccard values are shown in Table 4, Table 5, and Table 6. Table 7 describes the average results of Jaccard each transfer learning. From Table 7, the highest average Jaccard score is MobileNetV2 0.9522.

The MobileNetV2, ResNet18, and ResNet50 models were trained with an initial learning value=0.0001, and using the 'adam' function, the number of epochs was 30 iterations. Based on the segmentation results of MobileNetV2 (Table 4), ResNet18 (Table 5), and ResNet50 (Table 6), the superior CNN transfer learning method is MobileNetV2. As seen from the results of mandibular segmentation in Table 4, number 1 with the MobileNetV2 method, the left side of the condyle and coronoid can be seen. Meanwhile, the ResNet18 and ResNet50 methods showed that the condyle and coronoid sections were not visible (Table 5, Table 6, number 1).

TABLE III. DATA TEST

No	Image	Ground truth
1		

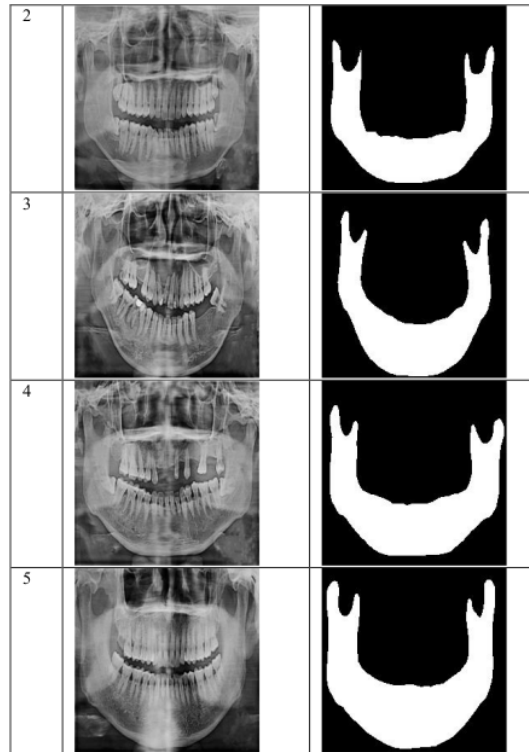








TABLE IV. RESULT MOBILENETV2 SEGMENTATION

No	Result	Jaccard
1		0.9491
2		0.919
3		0.9536

4		0.9556
5		0.9564

2		0.9072
3		0.9102
4		0.9125
5		0.9254

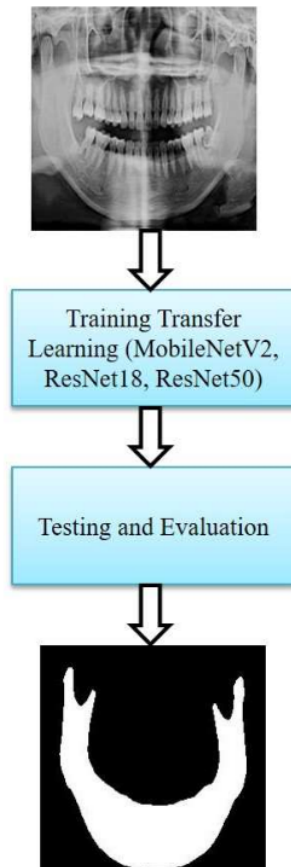


Fig. 4. Proposed a model

TABLE V. RESULT RESNET18 SEGMENTATION


No	Result	Jaccard
1		0.8886

TABLE VI. RESULT RESNET50 SEGMENTATION





No	Result	Jaccard
1		0.9228
2		0.919
3		0.9261
4		0.9443



TABLE VII. AVERAGE RESULT JACCARD

No	Method	Average
1	MobileNetV2	0.9522
2	ResNet18	0.9088
3	ResNet50	0.9315

V. CONCLUSION

We propose a CNN transfer learning method (MobileNetV2, ResNet18, and ResNet50) to segment panoramic radiographs of the mandible. They trained the model on 38 panoramic radiographic images selected by radiologists and evaluated the training model on 5 datasets of panoramic radiographic images. The evaluation results of the MobileNetV2 model have the highest Jaccard value of 0.9522. The visual results of the MobileNetV2 method of mandibular segmentation also look complete and precise in the condyle and coronoid.

Further research suggests finding a model to clarify the condyle and coronoid sections because there is a result of segmentation of the branched coronoid.

ACKNOWLEDGMENT

Thanks to the Dental and Oral Hospital of Universitas Airlangga, Surabaya providing dental radiographic panoramic data, and Universitas Islam Lamongan.

REFERENCES

- [1] A. H. Abdi, S. Kasaei, and M. Mehdizadeh, "Automatic segmentation of mandible in panoramic x-ray," *J. Med. Imaging*, 2015, doi: 10.1117/1.jmi.2.4.044003.
- [2] M. Yan, J. Guo, W. Tian, and Z. Yi, "Symmetric convolutional neural network for mandible segmentation," *Knowledge-Based Syst.*, vol. 159, 2018, doi: 10.1016/j.knosys.2018.06.003.
- [3] B. Qiu *et al.*, "Recurrent convolutional neural networks for 3d mandible segmentation in computed tomography," *J. Pers. Med.*, vol. 11, no. 6, 2021, doi: 10.3390/jpm11060492.
- [4] N. Torosdagli *et al.*, "Robust and fully automated segmentation of mandible from CT scans," 2017, doi: 10.1109/ISBI.2017.7950734.
- [5] B. Qiu *et al.*, "Automatic segmentation of the mandible from computed tomography scans for 3D virtual surgical planning using the convolutional neural network," *Phys. Med. Biol.*, vol. 64, no. 17, 2019, doi: 10.1088/1361-6560/ab2c95.
- [6] F. Abdolali, R. A. Zorofi, M. Abdolali, F. Yokota, Y. Otake, and Y. Sato, "Automatic segmentation of mandibular canal in cone beam CT images using conditional statistical shape model and fast marching," *Int. J. Comput. Assist. Radiol. Surg.*, vol. 12, no. 4, pp. 581–593, 2017, doi: 10.1007/s11548-016-1484-2.
- [7] O. Cuadros Linares, J. Bianchi, D. Raveli, J. Batista Neto, and B. Hamann, "Mandible and skull segmentation in cone beam computed tomography using super-voxels and graph clustering," *Vis. Comput.*, vol. 35, no. 10, 2019, doi: 10.1007/s00371-018-1511-0.
- [8] B. Qiu *et al.*, "Mandible Segmentation of Dental CBCT Scans Affected by Metal Artifacts Using Coarse-to-Fine Learning Model," *J. Pers. Med.*, vol. 11, no. 6, 2021, doi: 10.3390/jpm11060560.
- [9] B. Qiu *et al.*, "Robust and accurate mandible segmentation on dental CBCT scans affected by metal artifacts using a prior shape model," *J. Pers. Med.*, vol. 11, no. 5, 2021, doi: 10.3390/jpm11050364.
- [10] N. Nafi'iyah, C. Fatchah, E. Renwi Astuti, and D. Herumurti, "The Use of Pre and Post Processing to Enhance Mandible Segmentation using Active Contours on Dental Panoramic Radiography Images," 2020, doi: 10.1109/ISRITI51436.2020.9315438.
- [11] Burmansah, B. Sujanto, and M. Mukhtar, "Work-life quality, job involvement, and affective commitment of school teachers," *Int. J. Recent Technol. Eng.*, vol. 8, no. 2 Special Issue 9, 2019, doi: 10.35940/ijrte.B1034.0982S919.

Mandibular segmentation on panoramic radiographs with CNN Transfer Learning

ORIGINALITY REPORT

12%

SIMILARITY INDEX

10%

INTERNET SOURCES

11%

PUBLICATIONS

0%

STUDENT PAPERS

PRIMARY SOURCES

1	eprints.utdi.ac.id Internet Source	3%
2	repository.itelkom-pwt.ac.id Internet Source	2%
3	www.mdpi.com Internet Source	1%
4	lion.sjtu.edu.cn Internet Source	1%
5	Nur Muhammad Husnul Habib Yahya, Hadziq Fabroyir, Darlis Herumurti, Imam Kuswardayan, Siska Arifiani. "Dungeon's Room Generation Using Cellular Automata and Poisson Disk Sampling in Roguelike Game", 2021 13th International Conference on Information & Communication Technology and System (ICTS), 2021 Publication	1%
6	Shu, Qiong, He Ping Chen, and Jin Guang Gu. "Semantic Reasoning-Based Chinese Recipe	1%

Recommender System", Advanced Materials Research, 2013.

Publication

7	www.scribd.com Internet Source	1 %
8	ese.nju.edu.cn Internet Source	1 %
9	owner.polgan.ac.id Internet Source	1 %
10	www.semanticscholar.org Internet Source	1 %
11	Akbar Noto Ponco Bimantoro, Ivanda Zevi Amalia, Siti Rochimah. "How Agile Software Development Affect Software Reusability (Study Case: New Student Admissions Portal in East Java Province)", 2020 7th International Conference on Information Technology, Computer, and Electrical Engineering (ICITACEE), 2020 Publication	<1 %

Exclude quotes Off

Exclude matches Off

Exclude bibliography On

Mandibular segmentation on panoramic radiographs with CNN Transfer Learning

GRADEMARK REPORT

FINAL GRADE

/0

GENERAL COMMENTS

Instructor

PAGE 1

PAGE 2

PAGE 3

PAGE 4

PAGE 5
