

Hepatoprotective activity of sea cucumber phyllophorus sp. extract in carp (*Cyprinus carpio*)

by Laksmi Sulmartiwi

Submission date: 17-Oct-2022 02:07PM (UTC+0800)

Submission ID: 1927434876

File name: C1.69-7-11.pdf (362.73K)

Word count: 2546

Character count: 13840

Hepatoprotective Activity of Sea Cucumber *Phyllophorus* sp. Extract in Carp (*Cyprinus carpio*)

Laksmi Sulmartiwi^{1*}, Juni Triastuti², Sapto Andriyono³, Mardiah Rahma Umami⁴

^{1,2,3,4}Department of Marine, Fisheries and Marine Faculty, Universitas Airlangga
Jl. Mulyorejo Kampus C Unair - Surabaya 60115. Tel./Fax. 031-59665741

²
*Corresponding author: laksmi-s@fpk.unair.ac.id

Abstract. Many procedures continuously in aquaculture and scientific research like tagging and vaccinating cause pain, involving damaging tissue and also cause stress responses in fish. Stress responses in fish influence liver because liver have vital role to supply energy and metabolism. Histology alteration in liver is caused by stress response like changes of vacuolation hepatocyte and characteristic colour. Triterpenoid was known had hepatoprotective activity. One of marine organism contained triterpenoid was sea cucumber. Result of research showed that liver tissue in fish with injected acetic acid 5 % (in upper lip) as pain stimulus have histopathology damages such as pyknosis (medium damage level) and oedema (heavy damage level) after 8 hour injection. Injected Lidocaine 1mg/fish as analgesic drug have histopathology damages such as oedema (heavy damages level), necrosis and pyknosis (low damages level). Injected acetic acid 5 % (in upper lip) and ethanolic extract of sea cucumber *Phyllophorus* sp. dose 5 mg/50 gr body weight shown histopathology damages such as necrosis, edema (medium damage level) and pyknosis (low damage level).

INTRODUCTION

⁵ Many procedures continuously in aquaculture, fisheries and scientific research like tagging and vaccination can involve tissue damage which causes pain in fish [1]. Pain stimulus may involve stress response in fish. In vertebrae, nociceptor detect injured tissue and this signal accepted by nerve A-delta and C fibers to spinal cord which stimulate reflect response in physiological change like activation some stress responses [2]. In common carp injected by acetic acid as pain stimulus shown abnormal swimming activity (Reilly et al. 2008a) and increased or decreased code gene receptor kainite glutamatergic and cannabionid CB1 and derivated neutrophic factor in brain [3]. Stress response influence liver cause liver has vital function in energy supplied and metabolism. Alteration in histology can be observed by a change in vacuolation of hepatocyte and colour characteristic [4]. Triterpenoid known had hepatoprotective activity. Hepatoprotective effect of novel triterpenoid oligoglycoside from *Bupleurum scorzonerifolium* root known has hepatoprotective in mice liver which induced by D-galactosamine (D-Gal N) and lipopolysaccharide (LPS) [5]. One of marine organism contained triterpen glycoside was sea cucumber. There not many researches about exploration bioactive compound in sea cucumber (*Phyllophorus* sp.) as hepatoprotective in carp (*Cyprinus carpio*) which induced pain stimulus and the result of this research can development as basic effort to exploration bioactive compound from marine organism.

MATERIALS AND METHODS

Sea cucumbers *Phyllophorus* sp. were collected from East Coast Surabaya. Carps were collected from Blitar with body weight 50-60 gram. Ethanol extraction of sea cucumber was held in Laboratorium Education on Faculty of Fisheries and Marine Airlangga University. Histology preparation was held in Pathology Laboratorium Faculty of Veteriner Airlangga University. Freeze drying of sea cucumber *Phyllophorus* sp. was held in Toxoplasma Study Group Institute Tropical Disease Airlangga University.

Instruments on this research were glass jar, aeration, microscope, microtome, knife, freeze dryer FD-1EYELA made in Japan, rotary evaporator Hahn Shin HS-2005S-N made in South Korea, food processor, microtube, stopwatch, beaker glass, pH pen, thermometer, syringe Terumo 26 G and styrofoam. Materials on this research were sea cucumber *Phyllophorus* sp., ethanol, lidocaine, acetic acid, buffer formalin, plastic bag, paraffin and section sets.

Extraction of Sea cucumbers *Phyllophorus* sp.

Sea cucumbers were cleaned and gut were removed then were mashed with food processor. Sea cucumbers freeze drying into dry material. Method of extraction was maceration. Sample of sea cucumber was marinated in solution with ratio 1:3 (w/v) or well marinated with twice replications; each replication was marinated for 3x24 hours. Filtrate of maceration extract was then separated from solution by rotary evaporation at 38°C [6].

Injection treatments of *Phyllophorus* sp. extract

Treatments in this research were 5 treatments with 4 replications. Pain stimulus in was done by using injection 0,05 mL acetic acid 5% in carp fish lip [2]. Lidocaine was used as analgesic comparison with *Phyllophorus* sp. extract. [7] Shown that injected acetic acid as pain stimulus and 0.1 mL lidocaine dose 1 mg/fish as analgesic drug decreased all pain indicators (cortisol, ventilation and food behavior) in rainbow trout. Treatments of this research were (A) no injected of acetic acid, lidocaine and *Phyllophorus* sp. extract, (B) injection of 0.05 mL acetic acid 5 % in carp fish upper lip, (C) injection of 0,05 ml acetic acid 5 % and 0,1 mL lidocaine 1 mg/ fish in carp fish upper lip, (D) injection 0.05 mL acetic acid 5 % in carp fish lip and 0.1 mL *Phyllophorus* sp. extract dose 1mg/50 gr with muscularis injection, (E) injection 0.05 mL acetic acid 5 % in carp fish upper lip and 0.1 mL *Phyllophorus* sp. extract dose 5 mg/50 g with muscularis injection. Observation on this research during 8 hours, liver of carp fish collected at the end of observation.

Histopathology and Damage Observation in Liver

Observation histopathology used microscope to determine the alteration of tissue after treatment. Levels and kind of damages were evaluated by scoring of alteration histopathology with values 0, 1, 2, 3, and 4. Based on the values scoring:

- 0 : no pathology alteration in one field of view
- 1 : ≤ 25 % damage in one field of view (light level damages)
- 2 : 26-50 % damage in one field of view (medium level damages)
- 3 : 51-75 % damage in one field of view (heavy level damages)
- 4 : ≥ 75 % damage in one field of view (very heavy level damages)

Data Analysis

Analysis data used descriptive method to describe liver histopathology in carp fish.

RESULT

Result of observation histology in liver tissue shown that there was histopathology alteration after treatment injection. The alteration of histopathology in liver tissue such as pyknosis, oedema and necrosis was determined. Result of ranges scoring histopathology shown in **TABLE 1**.

TABLE 1. Ranges scoring histopathology damages in carp liver

Treatment	Histopathology damages		
	Pyknosis	Oedema	Necrosis
A	0	0	0
B	0-2	0-3	0
C	0-1	2-4	0-1
D	0-2	4	0
E	0-1	0-2	0-2

Note: (A) no injected of acetic acid, lidocaine and *Phyllophorus* sp. extract, (B) injection of 0,05 mL acetic acid 5 % in carp fish upper lip, (C) injection of 0,05 mL acetic acid 5 % and 0,1 mL lidocaine 1 mg/fish in carp fish upper lip, (D) injection 0.05 mL acetic acid 5 % in carp fish lip and 0.1 mL *Phyllophorus* sp. extract dose 1mg/50 gr with muscularis injection, (E) injection 0.05 mL acetic acid 5 % in carp fish upper lip and 0.1 mL *Phyllophorus* sp. extract dose 5 mg/50 g with muscularis injection.

Treatment A (no injected of acetic acid, lidocaine and *Phyllophorus* sp. extract) showed no histopathology damages like necrosis, pyknosis, and oedema. Treatment B (injection of 0.05 mL acetic acid 5 % in carp fish upper lip) showed histopathology damages such as pyknosis and oedema. Range damages of pyknosis at medium damages level because damages shown between 25-50 % in one field of view. Range damages of oedema at heavy damages level because damages shown between 51-75 % in one field of view. Treatment C (injection of 0.05 mL acetic acid 5 % and 0.1 mL lidocaine 1 mg/fish in carp fish upper lip) resulted histopathology damages like pyknosis, edema and necrosis. Necrosis and pyknosis at medium damages level of histopathology and oedema at very heavy damages level of histopathology. Treatment D (injection 0,05 ml acetic acid 5 % in carp fish lip and 0. mL *Phyllophorus* sp. extract dose 1mg/50 g with muscularis injection) shown histopathology damages like pyknosis and oedema. Pyknosis at medium damages level and oedema at very heavy damages level of histopathology. Treatment E (injection 0.05 mL acetic acid 5 % in carp fish upper lip and 0.1 mL *Phyllophorus* sp. extract dose 5 mg/50 g with muscularis injection) showed histopathology damages such as pyknosis, oedema and necrosis. Edema and necrosis at medium level damage of histopathology, pyknosis at low damages level of histopathology. Result of observation in liver tissue carp fish can be seen in **FIGURE 1**.

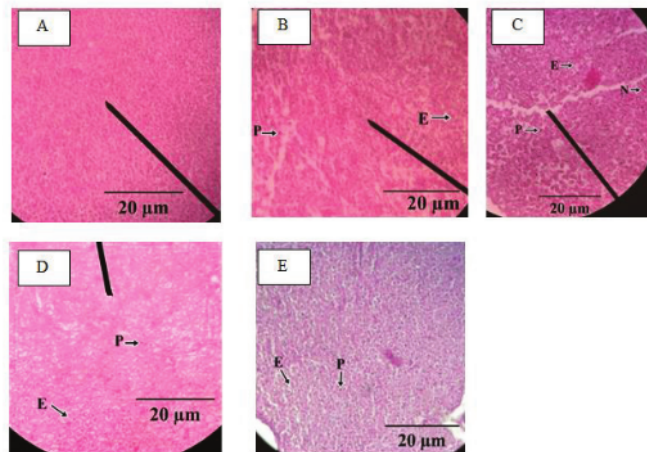


FIGURE 1. Result of observation histopathology liver tissue of carp fish (*Cyprinus carpio*). HE. 400x. Scale bar: 20 µm. Note: A (no alteration of histopathology), B (P= pyknosis, E=Edema), C (P= Pyknosis, E=Edema, N=Necrosis), D (P= Pyknosis, E=Edema), E (P= Pyknosis, E=Edema).

Water quality such as temperature, pH, ammonia and dissolved oxygen measured at end research. Temperature measured by thermometer, pH measured by pH pen, ammonia measured by ammonia test kit and oxygen measured by DO test kit. Range of water quality during the research shown at **TABLE 2**.

TABLE 2. Ranges water quality parameters during research

Parameters	Ranges
Dissolved oxygen (mg/ L ⁻¹)	6-8
Ammonia (mg/ L ⁻¹)	0,009-0,03
Temperature (°C)	29-30
pH	7,5-7,7

Discussion

The liver tissue of histology observation in treatment B acetic shown heavy damages histopathology alteration such as pyknosis and oedema. Injection of acetic acid in common carp lip as pain stimulus shown abnormal swimming ability [8] and increased or decreased regulation of code gene receptor kainite glutamatergic and cannabinoid CB1 and neuropeptide factor in brain [9]. Pyknosis was one of cell death sign at necrosis, which chromatin in nucleolus unionized and cell membrane shranked. Oedema on liver tissue may cause by acetic acid as pain stimulus. Pain stimulus stimulated major C-Polymodal fiber to produced plasma in receptor peripheral nerve. Central Nerve System then spread stimulus to peripheral nerve system to influence other area in afferent nerve and release peptide like P substance, CRGP, somatostatin and or another bioactive substances. P substance increased vascular permeability, causing edema [10].

Histopathology alteration in treatment C was pyknosis, oedema and necrosis. Pyknosis and necrosis was caused by cell adaption response from pain stimulus although at light level damages. Edema in liver tissue may need dose of lidocaine higher to response pain stimulus although lidocaine dose 1mg/ fish can decrease all pain indicators (cortisol, feed behavior and ventilation rate) in rainbow trout (9). Lidocaine used as anesthesia in fish by dipping method [11,12] also showed injection lidocaine dose 9 mg kg⁻¹ showed lower acute inflammation alteration in mice liver than mice with no lidocaine injection. (5) showed lidocaine also have hepatotoxic effect, this caused by lidocaine which can decreased epinephrine to stimulus glucose which contradicted with ion Ca²⁺ and no mediated cAMP intracellular pathway.

Histopathology alteration in treatment D was pyknosis and oedema. Pyknosis in liver tissue was found at medium level damages and edema at very heavy damages level. This might be cause by sea cucumber extract less to decrease pain stimulus to protected liver tissue from damages. Histopathology alteration in treatment E was pyknosis, edema and necrosis. Necrosis and edema at medium level damages and pyknosis at light damages level. Damages level in treatment E no showed heavy and very heavy damages level might be caused by activities one of bioactive compound of sea cucumber *Phyllophorus* sp. extracts. One of bioactive compound can decreased pain (analgesic) by acetic acid injection was triterpen glycoside. Triterpen glycoside influenced inhibition of Na⁺, K⁺, and ATP-ase in nerves system [13]. Triterpen glycoside also have inhibitory activity of receptor N-Methyl-D-Aspartate (NMDA) and nicotinic acetylcholine, which activated receptor γ -Amino Butyric Acid (GABA) (9). GABA is ionization, inhibiting neurotransmission in Central Neuron System (CNS) [14]. Inhibition of neurotransmitter in receptor decreased nerve system excitability, then caused incoordination, sedation, and anesthesia [8]. Light level damages in liver might be caused by inhibition of nerve system to decreased response pain stimulus in carp fish.

Water qualities during research supported survival rate of carp fish (*Cyprinus carpio*). Water quality factors were temperature, pH and dissolved oxygen. Temperature of water at the end research ranges 29-30°C, pH ranges 7,5-7,7, and dissolved oxygen ranges 6-8. Carp fish can survive at temperature ranges 21-28°C, pH ranges 6,1-7,6 and dissolved oxygen ranges 6,1-9,4 mg L⁻¹ [15].

CONCLUSION

Treatment with ethanolic extract of sea cucumber *Phyllophorus* sp. dose 5 mg/50 g body weight is an optimum dose as a protective in the liver tissue of carp fish (*Cyprinus carpio*) after acetic acid injection as pain stimulus.

Some damages of histopathology such as oedema and necrosis at medium level of damages and pyknosis at light level of damages were occurred.

ACKNOWLEDGEMENT

We thank to Faculty of Fisheries and Marine Airlangga University which provided a fund and supported to this research (BOPTN)

REFERENCES

1. Hastein T., Scarfe A.D., Lund V.L Science – Based Assessment of Welfare: Aquatic Animals, *Revue Scientifique et Technique* 24: 529-547. (2005).
2. Braithwaite V.A., Ebbeson L.O.E. Pain and Stress Respon in Farmed Fish. *Rev Sci Tech Off Int. Epiz.* 33 (1): 245-253. (2014).
3. Reilly S.C., Quinn J.P., Cossins A.R., Sneddon L.U. Behavioural Analysis of a Nociceptive Event in Fish: Comparisons between three species demonstrate specific responses. *Appl Anim Behav Sci.* 114: 248–259. (2008).
4. Weber E.S. Fish Analgesia: Pain, Stress, Fear Aversion, or Nociception. *Vet Clin Exot Anim Pract.* 14: 21-32. (2011).
5. Wolf J.C., Wolfe M.J. A Brief Overview Of Non-neoplastic Hepatic Toxicity In Fish. *Toxicol Pathol* 33:75-85. (2005).
6. Nimah S.W. Ma'ruf F., Trianto A. Uji bioaktivitas ekstrak teripang pasir (*Holothuria scabra*) terhadap bakteri *Pseudomonas aeruginosa* dan *Bacillus cereus*. *Jurnal perikanan* 1(2): 1-9. (2012)
7. Mettam J.J., Oulton L.J., McCrohan C.R., Sneddon L.U. The Efficacy of Three Types of Analgesic Drugs in Reducing Pain In The Rainbow Trout, *Oncorhynchus mykiss*. *Elsevier Appl Anim Behav Sci.* 133: 265-274. (2011).
8. Mihic S.J. Harris R.A. GABA and The GABAA Receptor. *Neurotrans Rev.* 21 (2): 127:131. (1997).
9. Reilly S.C., Quinn J.P., Cossins A.R., Sneddon L.U. Behavioural Analysis of a Nociceptive Event in Fish: Comparisons between three species demonstrate specific responses. *App Anim Behav Sci.* 114: 248–259. (2008).
10. Dubin A.E., Patapoutian A. Review Series Nociceptor: The Sensor of the Pain Pathway. *J Clin Invest* 120 (11):3760-3772. (2010).
11. Ross L.G., Ross B. Anesthetic and Sedative Techniques for Aquatic Animals 3rd. Blackwell Science. London. (2008).
12. Wang Y., Zhang C.L., Liu Y.F., Liang D., Luo H. Hepatoprotective Triterpenoids and Saponins of *Schefflera kwangsiensis*. *Planta Med* 80: 215-222. (2014)
13. Gorshkova I.A., Kalinin V.I., Gorshkov B.A., Stonik V.A. Two Different Modes Of Inhibition of The Rat Brain Na⁺,K⁺-ATPase by Triterpene Glycosides, Psolusosides A And B from The *Holothurian psolusfabricii*. *Comp. Biochem Physiol* 122C: 101–108. (1999).
14. Reilly S.C., Quinn J.P., Cossins A.R., Sneddon L.U. Novel Candidate Genes Identified in The Brain During Nociception in *Common Carp (Cyprinus carpio)* and *rainbow trout (Oncorhynchus mykiss)*. *Neurosci Lett* 437: 135-138. (2008).
15. Ahmad S., Venkateshwarlu M. Habitat Ecology of Cyprinid Fish Community in Relation to Environment Factors of Tungga and Bhadra Rivers, Western Ghats, Karnataka (India). *J Res Dev* 12: 65-91. (2012).

Hepatoprotective activity of sea cucumber phyllophorus sp. extract in carp (Cyprinus carpio)

ORIGINALITY REPORT

4%

SIMILARITY INDEX

0%

INTERNET SOURCES

4%

PUBLICATIONS

0%

STUDENT PAPERS

PRIMARY SOURCES

- 1 Wahyu Saptha Negoro, M. Irfan Aldy Nasution, Agung Ramadhanu, Fherly Agustin, Muhatri Muhatrii, Syahputra Amri. "Participants Evaluation of Computer-Based Writing Exam Eligibility in High School Using Simple Additive Weighting Method", 2021 IEEE 7th International Conference on Smart Instrumentation, Measurement and Applications (ICSIMA), 2021
Publication 1%
- 2 N K Portalia, L Sulmartiwi, B S Rahardja. " The growth and survival rate in lettuce aquaponic systems () of eels in various stocking densities of eel () ", IOP Conference Series: Earth and Environmental Science, 2019
Publication 1%
- 3 D. Dvornik, O.E. Edwards. "The structure of ajaconine", Tetrahedron, 1961
Publication 1%
- 4 www.iomcworld.com
Internet Source <1%

5

Mettam, J.J.. "The efficacy of three types of analgesic drugs in reducing pain in the rainbow trout, *Oncorhynchus mykiss*", *Applied Animal Behaviour Science*, 201109

Publication

<1 %

6

Hosam Toughan, Samah R. Khalil, Ashraf Ahmed El-Ghoneimy, Ashraf Awad, A.SH. Seddek. "Effect of dietary supplementation with *Spirulina platensis* on Atrazine-induced oxidative stress- mediated hepatic damage and inflammation in the common carp (*Cyprinus carpio* L.)", *Ecotoxicology and Environmental Safety*, 2018

Publication

<1 %

Exclude quotes On

Exclude matches Off

Exclude bibliography On