

# Clinical Findings And Visual Pathway Disorders Due To Tumor, What MRI can be Found?

F. Gunawan<sup>a</sup>, A. D. Sensusiaty<sup>b\*</sup>

\*Corresponding author: [anggraini-d-s@fk.unair.ac.id](mailto:anggraini-d-s@fk.unair.ac.id)

<sup>a</sup>Radiology Resident, Faculty of Medicine Universitas Airlangga, Dr. Soetomo General Academic Hospital, Surabaya, Indonesia

<sup>b</sup>Radiology Department Consultant, Faculty of Medicine Universitas Airlangga, Dr. Soetomo General Academic Hospital, Surabaya, Indonesia

---

## Abstract

The 10<sup>th</sup> most common cause of mortality for both men and women is brain and other nervous system cancer. These tumors can cause serious ocular signs and symptoms as well as neurologic complications due to increased intracranial pressure, cranial nerve disturbances, or brain compression. CT and MRI are the modalities most commonly used to evaluate visual disturbances around the visual pathway. MRI is the preferred imaging modality for evaluating tumors because it does not use X-rays but uses a magnetic field, producing clearer images

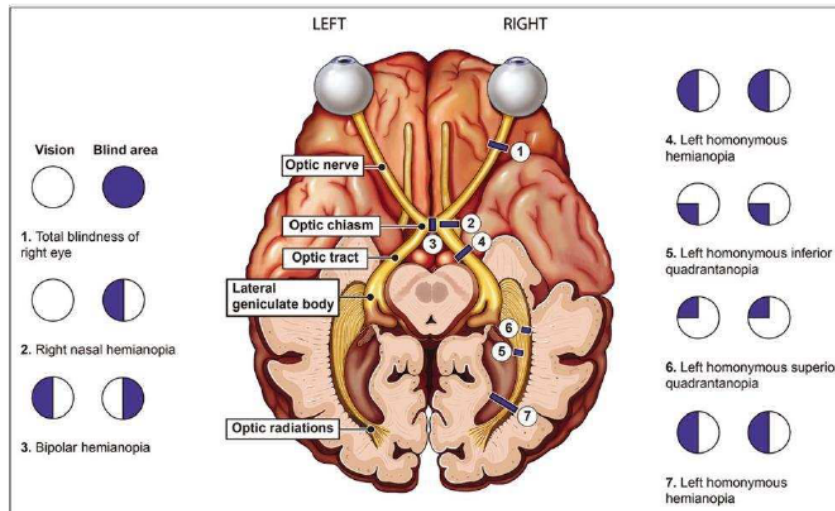
**Keywords:** visual pathway, brain tumor, MRI, visual loss

---

## 1. Main text

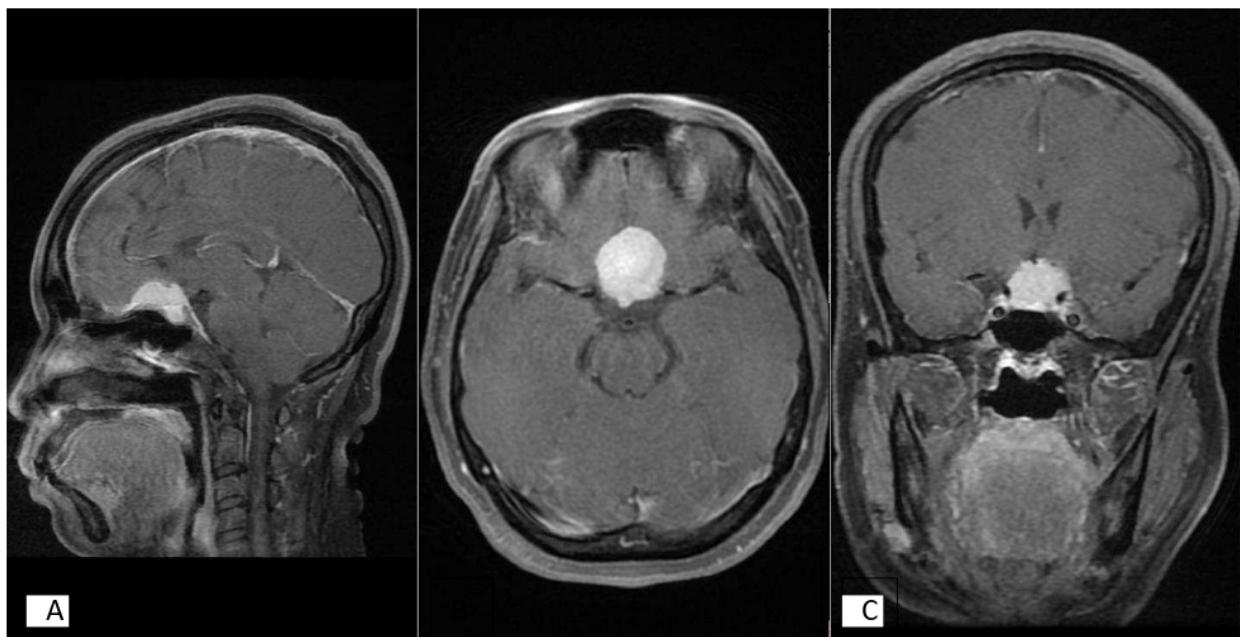
A complicated network of interconnected neurons, starting with the optic nerve in the eye and ending with the visual cortex in our forebrain, processes visual stimuli from our environment. All information is transmitted by nerve impulses that are brought on by photosensitive chemical processes in the retina. Multiple independent and parallel pathways in the nervous system code for its processing at various locations. Disruption of these pathways and their clinical manifestations provide vital diagnostics for an underlying disease<sup>1</sup>. Brain tumors can impair vision by disrupting both the afferent and efferent visual pathways. Tumor placement and increased intracranial pressure are key indicators of vision impairment (ICP). Reduced visual acuity (VA), loss of the visual field (VF), and problems with ocular movement may result from the tumor's compression of the visual pathway. Additionally, increased ICP may be brought on by obstructive hydrocephalus, the mass impact of the brain tumor, brain edema, and leptomeningeal involvement by the tumor. ICP elevation can eventually result in papilledema and optic disc atrophy, both of which can impair vision<sup>2</sup>. Symptoms can occur progressively or suddenly, including progressive or sudden loss of vision, extraocular nerve paralysis, or visual defects<sup>3</sup>. Some primary tumors can cause decompression of the visual system which can affect the structure of the visual pathway. This can be caused by space-occupying intracranial lesions<sup>4</sup>.

Ocular signs and symptoms include loss of vision, ptosis, paresis or paralysis of extraocular movements, diplopia, and changes in the optic disc. Approximately 46.8%-88.6% of patients present with neuro-ophthalmological manifestations. About 60% of patients with brain tumors first come to the ophthalmologist with eye complaints<sup>5</sup>. Some of these tumors include meningioma, pituitary adenoma, craniopharyngioma, lymphoma, and metastases.



**Figure 1.** Diagram showing each topographical location's visual pathway and field defects<sup>3</sup>

Meningiomas account for approximately 36% of all intra-cranial neoplasms, which represent the most common primary tumors of the central nervous system (CNS). These tumors originate from the meningeal membranes covering the brain, nerves, and spinal cord, arising from the arachnoid matter formed by cells in the middle meningeal layer; therefore, this type of neoplasm, although more common in the intra-cranial space, can be found throughout the neuraxis<sup>6</sup>.



**Figure 2.** Women, 50 years old with bitemporal hemianopsia. (A) Sagittal contrast-enhanced MRI shows the mass at the diaphragm sellae. (B) The mass show homogenous contras-enhancement. (C) The mass also pushes the optic chiasm

Meningioma has several subtypes which include atypical meningioma, malignant meningioma, mesenchymal meningeal tumors, hemangiopericytoma, meningiomatosis, and melanocytic lesions. Common locations of meningioma are (a) parasagittal dura, (b) convexity, (c) sphenoid wing, (d) CPA cistern, (e) olfactory groove, and (f) planum sphenoidal<sup>7</sup>.

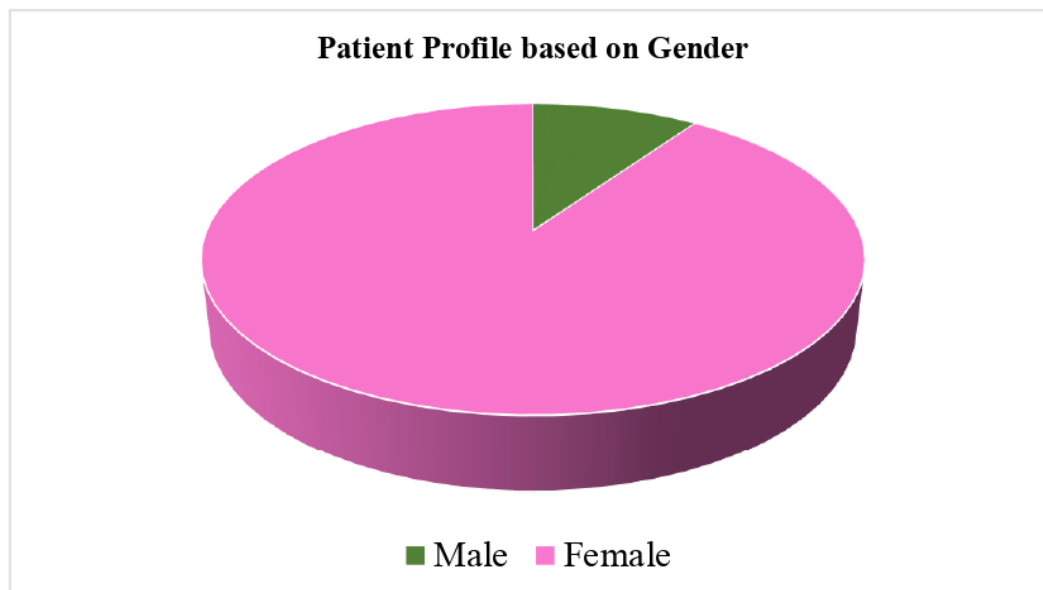
Meningiomas are usually isointense to the cortex on all magnetic resonance imaging (MRI) sequences, and more than half cause perilesional vasogenic edema. Cerebrospinal fluid (CSF) clefts are often seen between the tumor body and the brain parenchyma and may contain displaced blood vessels. CSF cysts also arise in this space, which may become proteinaceous and unsuppressed in a sequence of fluid suppression. Where at this time, calcification is reflected by the loss of signal on GRE and SWI. They almost always show a uniformly strong enhancement on post-contrast imaging and the dural tail is seen in 72% of cases, due to reactive thickening and enhancement of the dura. This is useful in some settings; for example, to differentiate cerebellopontine meningioma from schwannomas, which usually lack a dural tail<sup>8</sup>

## 2. Study Design, Location, and Timeframe

This study was a descriptive type with a retrospective approach on confirmed cases at Airlangga Hospital, Surabaya, Indonesia. Data were taken from the confirmed case's medical record at Airlangga Hospital from January 2018 to September 2022. We include 31 patients who underwent contrast-enhanced head MRI and histopathologically proven as a brain tumor. The MRI image was reviewed by 1 radiologist who was not blinded to the clinical data. Each image underwent careful evaluation by assessment of MRI findings based on location and its extension. We defined the tumor location which pushes the part of the visual pathway. Each part of the visual pathway like intraorbital, intracanal, pre-chiasm, optic chiasm, and post-chiasm will be observed by MRI involved by the tumor. The tumor can infiltrate one part of the visual pathway or more

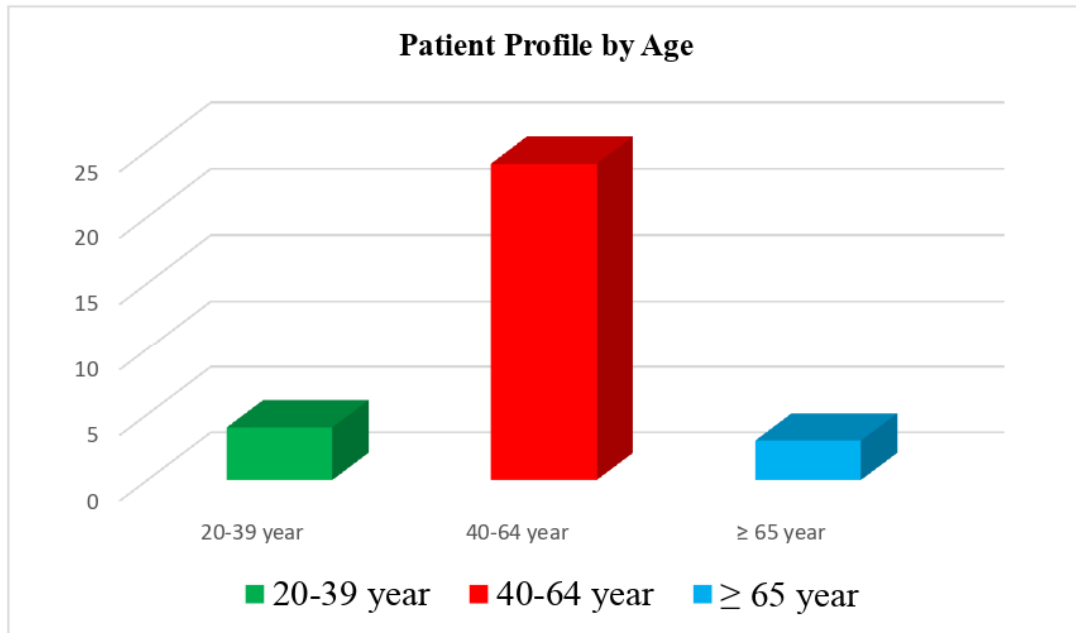
## 3. Result

Based on this study, a total sample of 31 patients was obtained, with 28 female subjects (90.3%) and 3 male subjects (9.7%).



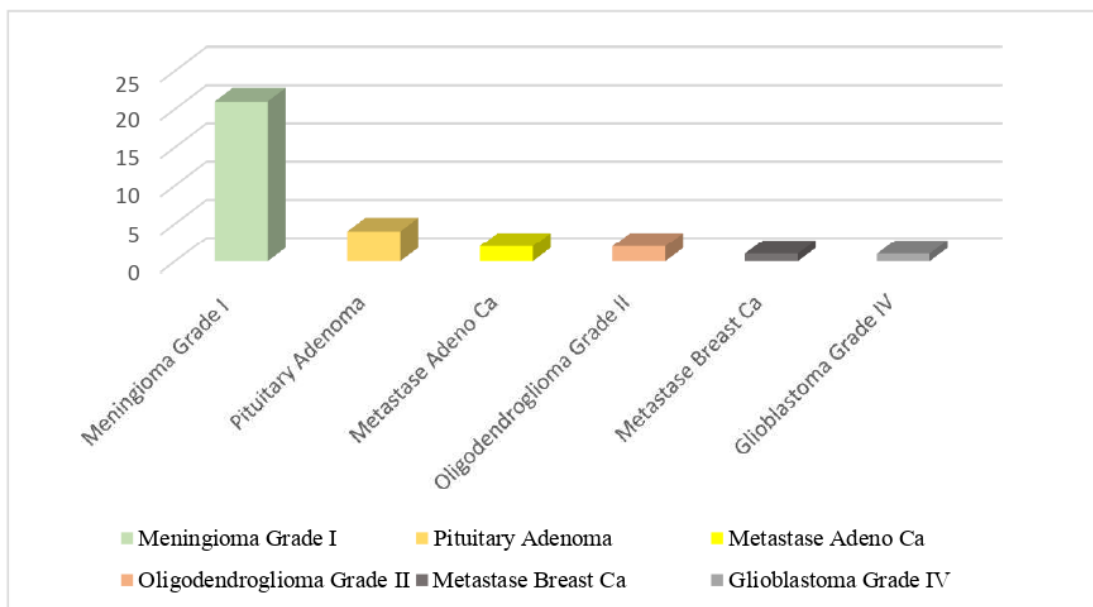
**Figure 3.** The diagram shows that the incidence in women is higher than in men

The age range of the study was between 24 years and 75 years, with an average age of 48 years, with an incidence rate in females higher than in males. 9 : 1 with 28 women and 3 men



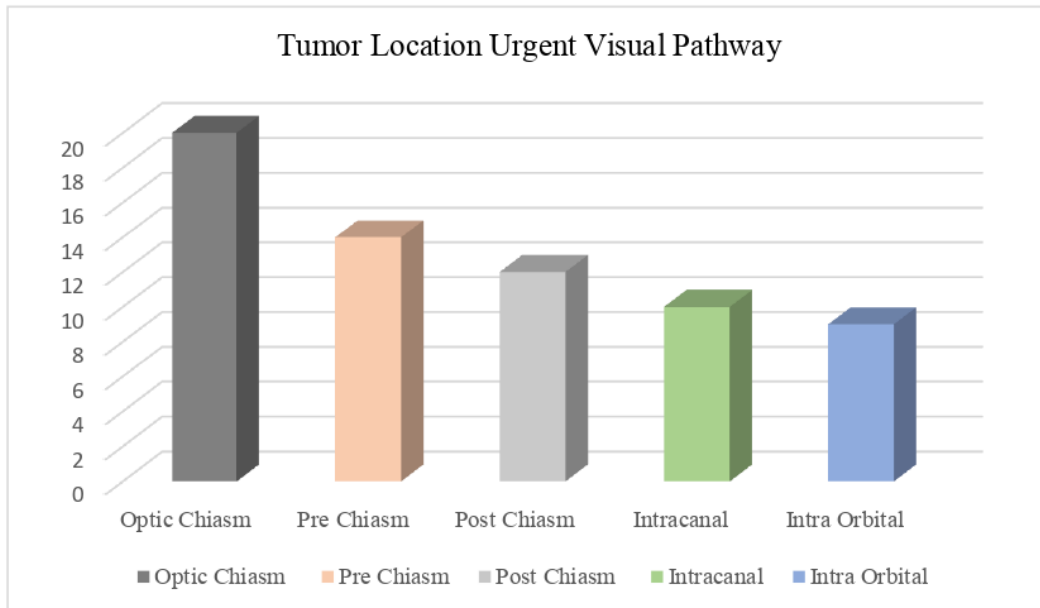
**Figure 4.** The diagram shows that the highest age occurs at the age of 40-60 years

From this study, it was found that the types of tumors that cause visual pathway disturbances based on anatomical pathology were found in 21 patients (67.7%) which were dominated by grade I meningioma.



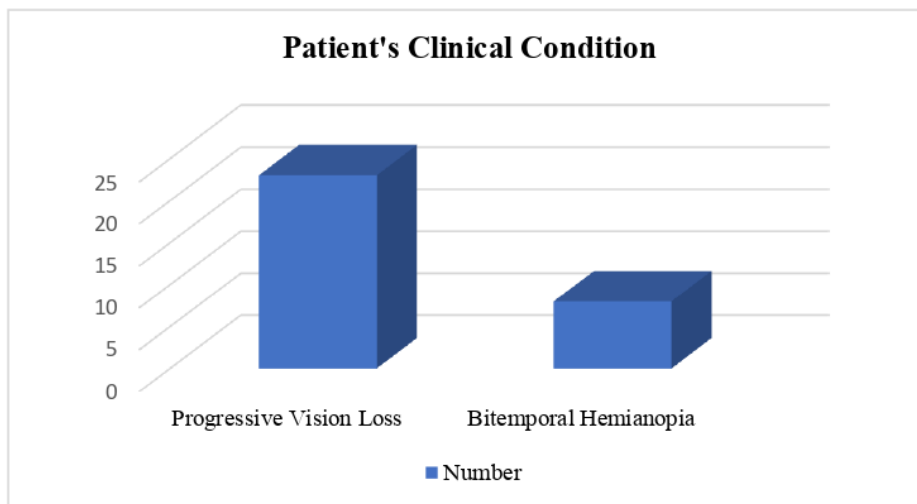
**Figure 5.** Types of Tumors that Cause Visual Pathway Disturbances

The location of the tumor that urged the most visual pathways was in the optic chiasm area in 20 patients (64.5%), pre-chiasm in 14 patients (45.2%), post-chiasm in 12 patients (38.7%), intracanal in 10 patients (32.3%), and intraorbital in 9 patients (29.0%). The results are presented in Figure 6



**Figure 6.** The location of the visual pathway pushed by the tumor

There were 8 patients (25.8%) with clinical symptoms of bitemporal hemianopsia, progressive vision loss in 23 patients (74.2%), homonymous hemianopia and cortical blindness were not found in this study sample. The results are presented in Figure 7



**Figure 7.** The number of patients who experience progressive vision loss and hemianopia bitemporal

#### 4. Discussion

The majority of tumor types that interfered with the visual pathway were meningioma grade I. Several epidemiological and pathological findings apart from a higher incidence in women suggest that sex hormones may play a role in the development of this tumor. This is due to the presence of progesterone and estrogen receptors in meningioma tissue, the possible association of the tumor with the female system, biological changes in meningioma during the menstrual cycle and pregnancy, regression occasionally reported after delivery, in vitro proliferation of meningioma cell lines in culture after exposure to estrogen and progesterone. In addition, the incidence and risk of



meningioma in patients with sex hormone-associated conditions and during the use of exogenous sex hormones for contraceptive therapy have been investigated in several studies<sup>9</sup>.

In this study, 23 people (74.2%) experienced progressive vision loss. Visual pathway or visual pathway refers to the structure that connects the eye to the visual brain. Visual pathways include the neuro-sensory retina of the eye, optic nerve, chiasm, lateral geniculate body, and visual cortex. Disturbances in the visual pathway or visual pathway will cause visual complaints which can be temporary or permanent and can be stable or progressive<sup>10</sup>.

This study found that most visual impairments are progressive in nature. Progressive visual impairment is a clinical manifestation of vision as a result of structural changes along the visual pathway or visual pathway of the human brain caused by various factors including visual cortical thickness, conditions of the optic chiasma, lateral geniculate<sup>11</sup>.

Lesions or tumors that crowd or compress the optic chiasma will produce visual symptoms that vary among patients. One of the characteristic symptoms of chiasm compression by a tumor is decreased visual acuity and visual field defects<sup>12</sup>. Meningioma is one type of tumor that is most commonly found to interfere with the physiology of the visual pathway. Displacement of the olfactory tract and optic chiasm occurs when the meningioma extends into the paranasal sinuses and nasal cavity<sup>13</sup>.

## **5. Conclusion**

We conclude that the profile of patients who experience visual pathway disturbances are women, aged between 40-64 years, with clinical features of progressive visual loss, where based on anatomical pathology examination found the type of tumor that causes meningioma grade I and most the optic chiasma.

## **Acknowledgment**

None of the authors have any conflict of interest regarding the contents of this article.

## References

1. Gupta, M., Ireland, A. C. and Bordoni, B. (2021) 'Neuroanatomy, Visual Pathway', p. 83.
2. Nuijts, M. A. et al. (2019) 'Visual impairment in children with a brain tumor (CCISS study)(still ongoing)', *BMC Ophthalmology*, 19(1), pp. 1–7.
3. Sefi-Yurdakul, Nazife. 2015. "Visual Findings as Primary Manifestations in Patients with Intracranial Tumors." *International Journal of Ophthalmology* 8(4): 800–803.
4. Müller-Forell, W. (2004) Intracranial pathology of the visual pathway, *European Journal of Radiology*. doi: 10.1016/j.ejrad.2003.09.003.
5. Deshmukh, S. et al. (2018) 'Profile of brain tumors having ocular manifestations in a Tertiary Eye Care Institute: A retrospective study', *TNOA Journal of Ophthalmic Science and Research*, 56(2), p. 71. doi: 10.4103/tjosr.tjosr\_49\_18.
6. Elefante, A. et al. (2021) 'Neuroimaging in meningiomas: old tips and new tricks', *Mini-invasive Surgery*, 2021, pp. 1–11. doi: 10.20517/2574-1225.2020.102.
7. Sensusiaty, AD (2019) 'Magnetic Resonance Imaging of Extra-axial Tumor', *Indonesian Journal of Radiology*, 3(2), pp. 53–57. doi: 10.33748/jradidn.v3i2.67.
8. Lyndon, D. et al. (2019) 'Dural masses: meningiomas and their mimics', *Insights into Imaging*, 10(1). doi: 10.1186/s13244-019-0697-7.
9. Maiuri, F. et al. (2020) 'Meningiomas in Premenopausal Women: Role of the Hormone Related Conditions', *Frontiers in Oncology*, 10(December), pp. 1–8. doi: 10.3389/fonc.2020.556701.
10. Hernowo, A. T. (2012) Visual pathway morphometry in visual field defects. University of Groningen.
11. Aguirre, G. K. et al. (2016) 'Patterns of individual variation in visual pathway structure and function in the sighted and blind', *PLoS ONE*, 11(11), pp. 1–24. doi: 10.1371/journal.pone.0164677.
12. Takahashi, M. et al. (2018) 'Compressive Lesions of the Optic Chiasm: Subjective Symptoms and Visual Field Diagnostic Criteria', *Neuro-Ophthalmology*, 42(6), pp. 343–348. doi: 10.1080/01658107.2018.1438477.
13. Kawasaki, A. et al. (2018) 'Photophobia as the Presenting Visual Symptom of', *Neuro-Ophthalmology*, 22(6), pp. 343–348. doi: 10.1080/01658107.2018.1438477.