

Palatal rugoscopy as an aid for sex determination in Tengger population, Indonesia*

by Arofi Kurniawan

Submission date: 29-Dec-2022 12:00PM (UTC+0800)

Submission ID: 1987209902

File name: scopus_12-2021_Palatal_rugae.pdf (418.08K)

Word count: 3628

Character count: 19226

Palatal rugoscopy as an aid for sex determination in Tengger population, Indonesia*

• Beshlina Fitri W.R. Prakoewa (1,2), Arofi Kurniawan (2), Aspalilah Alias (2,3), An'nisa Chusida (2), Maria Istiqomah Marini (2), Beta Novia Rizky (2) •

1 – Forensic Science Program, Post Graduate School, Universitas Airlangga, 60286 Surabaya, Indonesia

2 – Department of Forensic Odontology, Faculty of Dental Medicine, Universitas Airlangga, 60132 Surabaya, Indonesia

3 – Department of Basic Sciences and Oral Biology, Faculty of Dentistry, Universiti Sains Islam Malaysia – Malaysia

Address for correspondence:

Beshlina Fitri W.R. Prakoewa

Jl. Mayjen Prof. Dr. Moestopo No. 47 Surabaya, East Java, 60132, Indonesia

E-mail: beshlinafitri@gmail.com

Bull Int Assoc Paleodont. 2021;15(2):77-82.

Abstract

The study of Palatal rugae to determine a person's identification is known as palatal rugoscopy. The scientific basis of the Palatal rugae analysis is the distinctive and individualistic pattern as a human identifier. According to the Interpol DVI guide, Palatal rugae can be a secondary identifier because it provides supportive information in individual identification. Various studies of Palatal rugae have been conducted to explore its application in sex determination. The purpose of this research was to investigate whether if of the Palatal rugae pattern could be used to help with sex determination in the Tengger population, Indonesia. This is a cross-sectional study with a total number of 70 subjects. All subjects from the Tengger area have voluntarily participated in this study. Each participant had a maxillary dental cast made, and the Palatal rugae pattern was examined using Thomas and Kotze's categorization. The independent sample t-test in SPSS version 20.0 was used for the statistical study. The present investigation found a significant difference between males and females in the circular pattern of Palatal rugae ($p < 0.05$). The circular pattern was only found and became a characteristic of males in the Tengger population. This study can conclude that the Palatal rugae pattern shows potential aid for sex determination in the Tengger population, Indonesia.

Keywords: palatal rugae pattern; forensic odontology; Tengger population; basic education

* *Bulletin of the International Association for Paleodontology is a journal powered by enthusiasm of individuals. We do not charge readers, we do not charge authors for publications, and there are no fees of any kind. We support the idea of free science for everyone. Support the journal by submitting your papers. Authors are responsible for language correctness and content.*



Introduction

Indonesia is a vast archipelagic country, consists of more than 17.500 islands, and is located in the Ring of Fire area, prone to natural disasters. The Indonesian National Board of Disaster Management (BNPB) has reported that more than 1.500 disasters happened during 2020 (1). The effective and efficient identification method is primarily necessary in case of a mass disaster. According to the Interpol DVI Guide, 2018, there were two types of human identification methods, primary and secondary identification (1,2). The primary identifier involves DNA, fingerprints, and teeth. The secondary identifier, such as Palatal rugae, ID card, lip prints, and medical records, is considered supportive information for individual identification (3,4).

Palatal rugae are the anatomical folds in the anterior portion of the palate that are uneven and irregular elevations of the mucosa. Around the third month of life, the maxillary bone forms such elevations in the intrauterine existence. Rugae growth and development are governed by epithelial and mesenchymal interactions. The incisal papilla is found in the mid-sagittal plane, and its lateral membrane creates rugae in the transverse direction (5,6). Palatal rugae patterns have been used in many studies for various purposes, such as comparative anatomy, forensic odontology, anthropology, prosthodontics, and orthodontics (7).

Palatal rugae are used for the identification process due to their stability over time. Their design and structure are unaffected and not altered by chemicals, heat, disease, or trauma (8). Rugae are protected against injury by their internal placement in the mouth cavity, as well as by tongue and buccal fat pads, which protect them from extreme temperatures (9,10). Hence, they can be used consistently as a reference during identification. It can be of particular interest in certain conditions where fingerprints cannot be taken, such as burnt bodies or where bodies have undergone decomposition, and in edentulous cases (7,8).

Tengger people live mostly on the steep slopes of massive volcanic crater in the Tengger Mountains, making them the second smallest ethnic group on the Indonesian island of Java. The people of the Tengger tribe, or The Tenggerese, have rituals and cultural traditions that have been going on for a long time. For the sake of peace and prosperity, The Tenggerese prefer to practice endogamous marriages ritual.

This practice might have the potential to cause a unique and different pattern on their Palatal rugae (11,12).

Gondivkar et al. (2011) reported a significant association between Palatal rugae patterns and ethnicity (13). A study conducted by Kolude et al. (2016) reported that Palatal rugae helped identify the tribe but not the gender of the Nigerian population (14). Meanwhile, Saraf et al. (2011) showed the differences in Palatal rugae pattern in males and females in the Indian population (15). However, Pramanik et al. (2019) reported that no significant sex difference in the total number of rugae could be found (16).

Based on the mentioned data, differences between sexes have been studied with no definite conclusion, which indicates the need for more studies, and only a few studies of Palatal rugae patterns have been done in Indonesia. At present, no studies have ever been done on the Tengger population. Therefore, this study aimed to investigate the differences of Palatal rugae patterns as a tool for sex determination in the Tengger population.

Materials and Methods

This study has been approved by the ethical committee (No.2303/UN3.1.2.1/PPd/2016). This study was conducted with the understanding and informed consent was obtained from all individual participants.

The applicants were chosen from Kayukebek Village, Pasuruan, East Java, in a cross-sectional study with 70 samples, 36 males and 34 females. The chosen candidates were ten years old and above with normal upper arch, free from congenital abnormalities, orthodontic treatment, and prosthetics. To create a negative form, alginate was utilized as an impression material on a perforated metal tray for the maxillary arch. To make diagnostic castings, the impressions were placed into dental stone (type III). After ensuring that there were no cavities or air bubbles, the casts were maintained for interpretation.

Under suitable light and magnification, the rugae were outlined with a pointed graphite pencil to make them visible (Figure 1). A digital caliper was used to count the number of Palatal rugae on either side of the midline and measure their length according to classification Palatal rugae by Thomas and Kotze as Primary rugae (more than 5 mm), secondary rugae (3-5 mm), and fragmented rugae (under 2 mm) (17).

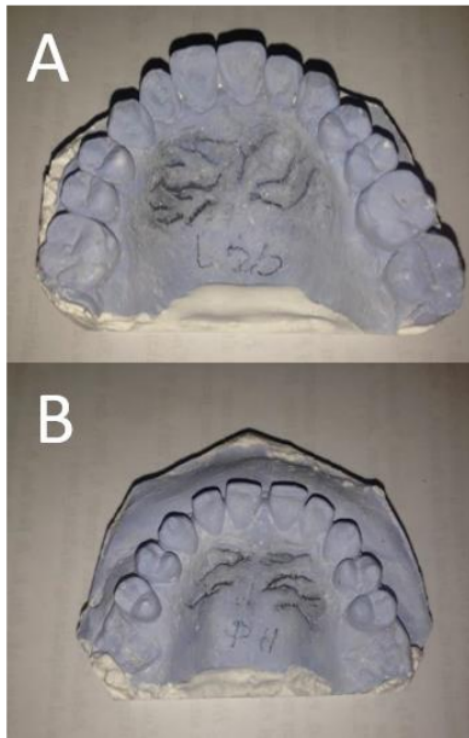


Figure 1. Palatal rugae patterns as marked and analyzed on the casts. (A) Complete cast view of male's maxilla. (B) Complete cast view of female's maxilla.

Furthermore, the pattern of individual rugae was classified into four types: curve, circular, wavy, and straight pattern (Figure 2). Unification happened when two rugae were linked at their origin or end, according to this classification. Diverging unifications were those in which two rugae started from the same precise origin but immediately diverged, whereas converging unifications were those in which distinct origins merged on the lateral parts (18).

In this study, only the Primary rugae needed to be observed and counted. The Palatal rugae were observed twice by the same observer. The data was then gathered, decrypted, and statistically evaluated using IBM SPSS Statistics 20.0 software. An Independent t-test was applied to analyze the palatal rugae.

Results

A total of 70 casts were evaluated, out of which 36 were male and 34 were females. Males have a higher number of primary Palatal rugae patterns (287) than females (256) (Figure 3).

Based on the total number, the most common pattern was the wavy pattern, followed by diverging, straight, curved, converging, and circular pattern the least. In terms of gender, males had more diverging and straight patterns than females. Females are more likely to have the curve and converging patterns. In males, the round pattern was the least common (Figure 3).

The six different Palatal rugae patterns were examined using an independent t-test with a 95% significant level ($\alpha = 0.05$). The result showed various significant levels to both sexes. Table 1 showed a statistically significant difference in a circular pattern, while there was no statistically significant difference in diverging, converging, wavy, curve, and straight patterns.

Discussion

Identification of a person is required for death certification, as well as for personal, social, and legal reasons. The most prevalent forensic identification procedures are fingerprints, dental records, and DNA. Fingerprints are limited in their effectiveness in cases when the hands have been mangled or burnt, and while teeth are more durable, dental records may also be inconclusive.

As a result, various methods must be used (19). Palatoscopy, the study of Palatal rugae pattern, are comparable to fingerprint, dental record, and DNA. Palatal rugae are highly individualistic and consistent throughout life. The quality and amount of Palatal rugae do not change throughout life, save in length due to ordinary growth, and they remain in the same place. The rugae are highly protected because of their internal position and largely remain insulated by tongue and buccal pads in the oral cavity. Hence, the rugae are well protected from trauma, diseases, or chemical aggression. However, changes in rugae can occur in some events, such as physical injuries, orthodontic treatment, finger sucking from infancy, and dentures (20,21).

Palatal rugae can survive for up to seven days after death and can endure heat, such as third degree burns. Therefore, it is possible that it can be used for forensic identification. It is a potential anatomical landmark because of its distinctiveness, stability, and resistance to degradation. Identification takes into account race, ethnicity, and regional differences (22).

The overall number of rugae was slightly lower in females than in males in this study, but not statistically significant. It was discovered that an individual did not have a single distinct pattern, but rather a blend of several patterns (23). When

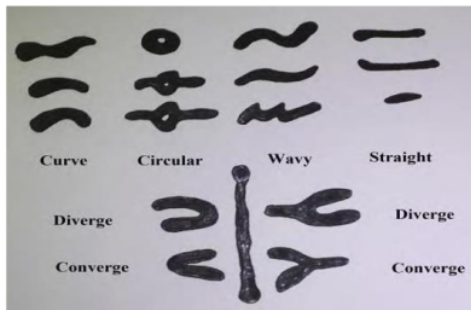


Figure 2. Thomas and Kotze classification of Palatal rugae pattern (18).

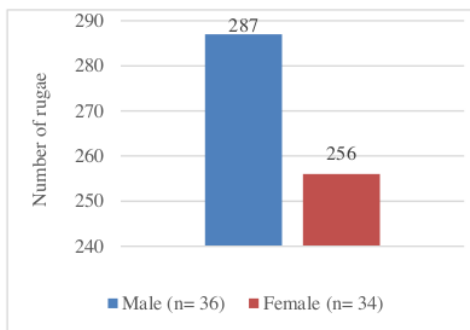


Figure 3. The total amount of all primary Palatal rugae patterns among males and females on Tengger population.

33

a total number of primary rugae was analyzed, the most common was the wavy pattern and the least was the circular pattern (Figure 4). Only the circular design demonstrated a significant difference in the overall number of Palatal rugae between the sexes (Table 1). Only males had the circular pattern, whereas both sexes had the other patterns. As a result, it can be deduced that some rugae patterns are unique to a specific population and sex. This finding was consistent with Khalid's (2016) earlier research on other population, which revealed the uniqueness of Palatal rugae that can be employed in forensic (24).

This research echoed Chopra's (2013) findings on the Indian population, which revealed a substantial variation in the circular pattern between males and females (25). On the contrary, Basman (2020) reported that no statistically significant variations in the morphologies of Palatal rugae among the

Indonesian subpopulation, with the curve shape being the most dominant in both males and females (26).

Palatal rugae growth and development in both sexes may be influenced by a genetic component (27). Humans have 23 pairs of chromosomes: 22 pairs of autosomes (numbered chromosomes) and one pair of sex chromosomes (X and Y) (28). The generation of morphological indications is influenced by genetics, which prohibits the rugae patterns from becoming conventional. Every parent's gene will be passed on to their child, according to Mendel's idea, and they will have the same personality (27,29). Kasuma et al. (2018) proved the idea in their studies, which found that the shape of Palatal rugae was more comparable between father and son than mother and son, and that the circular rugae pattern of the male kid was inherited on Minangkabau population (29). Another study conducted by Gaurav (2013) reported that environmental factors were unlikely to affect the formation of rugae and its patterns since it was genetically controlled (30). Thus, these studies showed that the circular pattern was only found in males, which was in line with this study.

Various studies on Palatal rugae have been conducted in several populations, but no studies have reported similar results. This could be due to the differences in genetic factors in each population since genetic factors determine the rugae pattern. The difference in the distribution of rugae patterns in various populations indicated that the rugae pattern is specific to certain populations due to various factors such as race and ethnicity (26). The results of this study conducted on 70 study models of maxillary jaw revealed that the Palatal rugae are unique and different between individuals, even the patterns of the rugae. The wavy pattern was found to be the most frequently in both males and females, while the circular pattern was found to be the least frequently. However, the circular was only found in males, which marked the character of males on the Tengger population.

In addition, the Tengger population is known for their endogamous marriage term. It is an ideal marriage that takes into account the search for a match in a horizontal line relative's environment, such as a cousin marriage (19). Researchers believe that the circular pattern identified only in males correlates with the existence of such a ritual and tradition. However, further studies are still needed with a larger scale population.

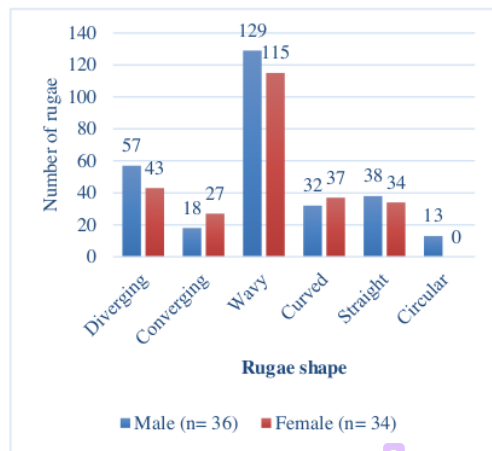


Figure 4. The total number of each primary Palatal rugae pattern among males and females on Tengger population.

Conclusion

The wavy pattern was the most common Palatal rugae pattern among the Tengger population. However, it did not show a significant difference between both sexes. The least typical Palatal rugae pattern was the circular pattern, but the result showed a statistically significant difference on both sexes since it was only found in males. It became a characteristic of males in the Tengger population. As a result, this study on the difference in Palatal rugae pattern between males and females in the Tengger people demonstrated the rugae pattern's potential as a sex determination tool. Still, this study was conducted on 70 samples only. Further studies are needed with more samples for better conclusions.

Declaration of interest:

None

Author Contribution

BF, AK, and AA conceptualized and designed the study; BF, AA, AC, MI, and BN did the definition of intellectual content; BF, AK, MI, and BN investigated and interpreted the data; BF, AK, AA, AC, MI, and BN wrote the manuscript.

References

- Kurniawan A, Agitha SRA, Ruth MSMA, Utomo H, Chusida A, Sosiawan A, et al. The applicability of Willems dental age estimation method for Indonesian children population in Surabaya. *Egypt. J Forensic Sci.* 2020;10(5):1-4.
- Firdaus, Puspitawati R, Nehemia B. Age estimation of 8- to 25-year-olds based on third molar calcification using the Demirjian method in an Indonesian population. In: *Journal of Physics: Conference Series*. IOP Publishing Ltd. 2018. p. 022005.
- Hidayati DS, Suryonegoro H, Makes BN. The accuracy of 15 – 25 years age estimation using panoramic radiograph with thevissen method in Indonesia. *J Phys: Conf Ser.* 2017;884:012140.
- Utomo H, Ruth MSMA, Wangsa LG, Salazar-Gamarrá RE, Dib LL. Simple smartphone applications for superimposing 3D imagery in forensic dentistry. *Dent J (Majalah Kedokteran Gigi).* 2020;53(1):50-6.
- Babu GS, Bharath TS, Kumar NG. Characteristics of Palatal rugae patterns in West Godavari population of India. *J Clin Diagn Res.* 2013;7(10):2356-9.
- Jadoon OK, Zaman MU, Zaman FU, Khan D, Farooq U, Seema N, et al. Analysis of Palatal rugae pattern in population of Abbottabad: A Forensic Study. *J Ayub Med Coll Abbottabad.* 2018;30(3):428-31.
- Kasuma N. *Rugae Palatina*. Andalas University Press. 2017.
- Poojya R, Shruthi CS, Rajashekar VM, Kaimal A. Palatal rugae patterns in edentulous cases, are they a reliable forensic marker? *Int J Biomed Sci.* 2015;11(3):4.
- Mohan AP, Beena VT, Paul S, Stephen MM, Johnson TK, Mohan R. Assessment of Palatal rugae patterns among different age groups: an institution-based study. *Oral Maxillofac Pathol J.* 2018;9:51-7.
- Sanjaya PR, Gokul S, Prithviraj KJ, Rajendra S. Significance of Palatal rugae: a review. *Int J Dent Update.* 2012;2:74-82.
- Savitri A. Sejarah, agama, dan tradisi Suku Tengger Gunung Bromo. *Proceeding ScieMeet.* 2010;1-18.
- Nurcahyono OH. Social capital of indigenous village communities in maintaining social harmony (case study of The Tenggerese Indigenous Community, Tosari, Pasuruan, East Java). In: *Proceedings of the International Conference on Rural Studies in Asia (ICORSIA 2018)*. Semarang, Indonesia: Atlantis Press; 2019.
- Gondivkar SM, Patel S, Gadbail AR, Gaikwad RN, Chole R, Parikh RV. Morphological study of the Palatal rugae in western Indian population. *J Forensic Leg Med.* 2011;18(7):310-2.
- Kolude B, Akinyele A, Joshua OT, Ahmed L. Ethnic and gender comparison of rugae patterns among clinical dental trainees in Ibadan, Nigeria. *Pan Afr Med J.* 2016;23:204.
- Saraf A, Bedia S, Indurkar A, Degwekar S, Bhowate R. Rugae patterns as an adjunct to sex differentiation in forensic identification. *J Forensic Odontostomatol.* 2011;29(1):14-9.



16. Pramanik A, Debnath M, Debnath M. A Comparative study of gender difference in Palatal rugae patterns among Bengali Subjects in Murshidabad. *Int J Anat Radio Surg.* 2019;8:5.
17. Pakshir F, Ajami S, Pakshir HR, Malekzadeh AR. Characteristics of Palatal rugae patterns as a potential tool for sex discrimination in a sample of Iranian children. *J Dent (Shiraz).* 2019;20(1):1–9.
18. Thomas CJ, Kotze TJ. The Palatal rugae pattern: a new classification. *J Dent Assoc S Afr.* 1983;38(3):153–7.
19. Pasiga B. Palatal rugae pattern based on lineage (pilot study for ethnic Bugise-South of Sulawesi Indonesia). *Int J Res.* 2017; 1-11
20. Patel RN, K U, Sangeeta, Patel R, Patel H, Patel N, et al. Assessing the inheritance of Palatal rugae patterns. *Int J Adv Res.* 2015;3(6):297–301.
21. Swetha S. Palatal rugae pattern in varied adult Indian population of males and females. *J Pharm Sci & Res.* 2015;7(9):736–9.
22. Kasuma N, Mukhaiyar U, Elianora D, Fitriana A, Fajrin FN, Fitri H. Palatal rugae as an alternative method in forensic identification. *J Med Assoc Thai.* 2019;102(9):962–7.
23. Pillai J, Banker A, Bhattacharya A, Gandhi R, Patel N, Parikh S. Quantitative and qualitative analysis of palatal rugae patterns in Gujarati population: a retrospective, cross-sectional study. *J Forensic Dent Sci.* 2016;8(3):126–34.
24. Khalid K, VM P. Palatal rugae patterns among a sudanese population sample. *Int J Dent Oral Sci.* 2016;3:276–80.
25. Chopra A, Gupta N, Rao N, Vashisth S. Palatal rugae and arch length: a tool in gender determination. *Univers Res J Dent.* 2013;3:54.
26. Basman RS, Suhartono AW, Hartomo BT, Auerkari El. Palatal rugae shapes in sex determination in forensic odontology. *Czas Stomatol.* 2020;73(2):87–92.
27. Kristiani S. Pewarisan karakteristik metris dan non metris gigi (Studi pada Populasi Tengger) [postdoctoral]. Universitas Airlangga. 2013; Available from: <http://lib.unair.ac.id>
28. National Human Research Institute. Chromosome. Genome.gov. Available from: <https://www.genome.gov/genetics-glossary/Chromosome>
29. Nila K. Palatal rugae pattern identification to determine family lineage in Minangkabau, West Sumatera, Indonesia. *Indian J Forensic Med Toxicol.* 2018;12(2):222–35.
30. Gaurav A. Cheiloscopy and Palatoscopy. In: Jain N, (eds). *Textbook of forensic odontology.* Panama, India: Jaypee Brothers Medical Publishers; 2013.

Table 1. Analytical result of *Palatal rugae* patterns between males and females.

<i>Palatal rugae</i> patterns	Gender	N	SD	p-value
Diverging	Male	36	1.052	0.222
	Female	34	1.109	
Converging	Male	36	0.654	0.125
	Female	34	0.913	
Wavy	Male	36	1.662	0.579
	Female	34	1.326	
Curve	Male	36	1.282	0.467
	Female	34	0.965	
Straight	Male	36	1.169	0.845
	Female	34	1.206	
Circular	Male	12	0.632	0.003*
	Female	0	0.000	

*significancy with $\alpha < 0.05$

Palatal rugoscopy as an aid for sex determination in Tengger population, Indonesia*

ORIGINALITY REPORT

20%
SIMILARITY INDEX

15%
INTERNET SOURCES

14%
PUBLICATIONS

0%
STUDENT PAPERS

PRIMARY SOURCES

1 www.ijars.net **3%**
Internet Source

2 www.ijfmt.com **2%**
Internet Source

3 Ramy Elmoazen, Mohamed Elsherbini. "Digital Anthropometric Analysis of Palatal Rugae Pattern in Qassim Population, Saudi Arabia", Journal of Applied Life Sciences International, 2017 **1%**
Publication

4 www.ijphrd.com **1%**
Internet Source

5 www.blancodesigns.com.br **1%**
Internet Source

6 innovareacademics.in **1%**
Internet Source

7 Jain, Anoop, and Ramesh Chowdhary. "Palatal rugae and their role in forensic odontology", **1%**

Journal of Investigative and Clinical Dentistry, 2013.

Publication

8	publichealthconference.co Internet Source	1 %
9	Jyothsna V Setty, Ila Srinivasan, Dandamudi Lalitha, Sunaina Pamnani, Murali K Dindukurthi, Sindura Allani. "Rugoscopy as a Gender Determination Tool and its Appositeness in Malocclusion among Adolescents Aged 13–18 Years", International Journal of Clinical Pediatric Dentistry, 2019 Publication	1 %
10	pkgm.fk.ugm.ac.id Internet Source	1 %
11	Abdulsalam Alshammari, Fathima Fazrina Farook, Lulu A Alyahya, Maha N AlHarbi et al. "The Posterior Extension of the Palatal Rugae as an Anatomical Constraint for Soft Tissue Grafts in a Saudi Arabian Population", Cureus, 2022 Publication	1 %
12	cjdr.ir Internet Source	1 %
13	Shimizu, Nobuyoshi, Shinsei Minoshima, Jun Kudoh, Kazuhiko Kawasaki, Yimin Wang, Yoshiko Shimizu, and Kosuke Sakai. "Human	1 %

Gene Mapping and Chromosome Sorting by Laser Technology.", The Keio Journal of Medicine, 1993.

Publication

14

Hajer Ayed Alhejoury, Pramod Redder Chandrappa, Dareen Khalid Aljehan, Basem Mohamed Mohsen Abuzenada. "Analysis of palatal rugae in males and females of Saudi Arabian population (Makkah province)", Journal of Advanced Clinical & Research Insights, 2018

Publication

1 %

15

Rabia Almasudi, Ganesh Somashekarachar, Nagabhushana Doggalli, Meenakshi Srinivasa Iyer, Sowmya Srinivas, Anupama Aradhya. "Evaluation and Comparison of Different Palatal Rugae Patterns between Dentulous and Edentulous Population of Mysuru City – A Preliminary Forensic Survey", Journal of Evolution of Medical and Dental Sciences, 2021

Publication

<1 %

16

www.dovepress.com

Internet Source

<1 %

17

www.bartleby.com

Internet Source

<1 %

18

Suneel G Patil, Nitin Gautam, R Gopi Krishna, Hemalatha Agastya, Lubna Mushtaq, K Vijay

<1 %

Kumar. "Association of Palatal Rugae Pattern in Gender Identification: An Exploratory Study", The Journal of Contemporary Dental Practice, 2017

Publication

19

www.editorialmanager.in

Internet Source

<1 %

20

Abeer M. Abdellatif, Salwa M. Awad, Shaza M. Hammad. "Comparative study of palatal rugae shape in two samples of Egyptian and Saudi children", Pediatric Dental Journal, 2011

Publication

<1 %

21

jamc.ayubmed.edu.pk

Internet Source

<1 %

22

jfmpr.com

Internet Source

<1 %

23

repository-tnmgrmu.ac.in

Internet Source

<1 %

24

"Patterns of palatal rugae as an indicator of identification in young adults of Nepal", 'Nepal Journals Online (JOL)'

Internet Source

<1 %

25

Nagalaxmi V, Sridevi Ugrappa, Naga Jyothi M, Lalitha Ch, Kotya Naik Maloth, Srikanth Kodangal. "Cheiloscopy, Palatoscopy and Odontometrics in Sex Prediction and Dis-

<1 %

crimination - a Comparative Study", The Open Dentistry Journal, 2015

Publication

26

Roopali Mahajan, Mohd. Arif Dar, Sanjeet Singh Risam. "PALATOSCOPY / RUGOSCOPY: A POTENTIAL TOOL IN HUMAN IDENTIFICATION", Journal of Evolution of Medical and Dental Sciences, 2014

Publication

<1 %

27

S. Kutalmış Buyuk, Huseyin Simsek, Yasin Yasa, Esra Genc, Recep Turken. "Morphological assessment of palatal rugae pattern in a Turkish subpopulation", Australian Journal of Forensic Sciences, 2017

Publication

<1 %

28

journals.viamedica.pl

Internet Source

<1 %

29

ompj.org

Internet Source

<1 %

30

www.ncbi.nlm.nih.gov

Internet Source

<1 %

31

Digjeet Kaur Monga, Sumit Bhateja, Geetika Arora. "Palatoscopy: A way to discover victim's identity in mass disaster", Journal of Oral Medicine, Oral Surgery, Oral Pathology and Oral Radiology, 2020

Publication

<1 %

32

Arofi Kurniawan, An'nisaa Chusida, Nur Atika, Tito Krisna Gianosa et al. "The Applicable Dental Age Estimation Methods for Children and Adolescents in Indonesia", International Journal of Dentistry, 2022

Publication

<1 %

33

Rabia Gezer, Mustafa Deniz, Ayşe Imge Uslu. "Morphological Characteristics and Individual Differences of Palatal Rugae", Journal of Craniofacial Surgery, 2019

Publication

<1 %

Exclude quotes Off

Exclude matches Off

Exclude bibliography On

Palatal rugoscopy as an aid for sex determination in Tengger population, Indonesia*

GRADEMARK REPORT

FINAL GRADE

/0

GENERAL COMMENTS

Instructor

PAGE 1

PAGE 2

PAGE 3

PAGE 4

PAGE 5

PAGE 6
