

www.apjr.net

ISSN 2305-0500 (Print)  
ISSN 2305-0519 (Online)  
CODEN APJRAX

# *Asian Pacific Journal of* **Reproduction**



**1**  
**2020**  
*Jan. Vol. 9*

 Wolters Kluwer

Medknow



## Editorial Board

### Editor-in-Chief

#### Yuan-hua Huang

Professor

Hainan Medical University, Haikou, China

### Executive Editor-in-Chief

#### Bo Cui, M.D., Ph.D.

Professor

Hainan Medical University, Haikou, China

### Editorial Director

#### Viroj Wiwanitkit, MD.

Professor

Department of Laboratory Medicine, Faculty of Medicine, Chulalongkorn University, Bangkok, Thailand

### Jing Li

Hainan Medical University, Haikou, China

### Managing Editors

Yan Lei, Hainan Medical University, Haikou, China

Beijia Tan, Hainan Medical University, Haikou, China

Luying Lin, Hainan Medical University, Haikou, China

### Members of Editorial Board

#### Puttaswamy Manjunath, Ph.D.

Professor

Department of Medicine, Faculty of Medicine, University of Montreal, Montreal, Canada

#### Daniel G. Cyr

Professor

Canada Research Chair in Reproductive Toxicology, INRS-Institut Armand-Frappier, Université du Québec, Canada

#### Gian Mario Tiboni

Associate Professor

Obstetrics and Gynecology, Department of Medicine and Aging Sciences University "G.d'Annunzio" Chieti Pescara, Italy

#### Stefan du Plessis

Professor

Division of Medical Physiology, Department of Biomedical Sciences, Faculty of Medicine and Health Sciences, Stellenbosch University, Tygerberg, South Africa

**Gaffari Turk**

Professor

Department of Reproduction and Artificial Insemination, Faculty of Veterinary Medicine, Firat University, Elazığ, Turkey

**Maria de Lourdes Gomes Pereira, Ph.D.**

Professor

Department of Medical Sciences, University of Aveiro, Campus Santiago, 3810-193 Aveiro, Portugal

**Fangxiang Shi, Ph.D.**

Professor

Department of Animal Reproduction and Breeding, College of Animal Science and Technology, Nanjing Agricultural University, Weigan 1, Nanjing, 210095, China

**Kristian Almstrup, Ph.D.**

Senior Scientist

Department of Growth and Reproduction, Copenhagen University Hospital, Rigshospitalet, Section GR-5064, 9 Blegdamsvej, DK-2100 Copenhagen, Denmark

**Rafiqul Islam, Ph.D.**

Principal Scientist

Animal Reproduction &amp; Gynaecology, ICAR-National Organic Farming Research Institute, Tadong, Gangtok - 737102, Sikkim, India

**Pedro Alejandro Orihuela Diaz, Ph.D.**

Associate Professor

Laboratory of Immunology of Reproduction, Faculty of Chemistry and Biology, University of Santiago, Chile

**Guilherme de Paula Nogueira, Ph.D.**

Full Professor

Animal Physiology at the Department of Basic Science, Production and Animal Health (DAPSA), at the Aracatuba Veterinary Faculty (FMVA), linked to the Sao Paulo State University (UNESP), Brazil

**Luc J Martin, Ph.D.**

Associate Professor

Department of Biology, Faculty of Science, University of Moncton, 18 Avenue Antonine Maillet, Moncton, (Nouveau-Brunswick), Canada

**Luciana Bordin, Ph.D.**

Department of Molecular Medicine-Biological Chemistry, University of Padova, Viale G. Colombo 3, 35131 Padua, Italy

**Hossein Mozdarani, Ph.D.**

Professor

Department of Medical Genetics, Faculty of Medical Sciences, Tarbiat Modares University, Tehran, Iran

**Brent M. Bany, Ph.D.**

Associate Professor

Department of Physiology, Southern Illinois University School of Medicine, Carbondale, Illinois, USA

**Asmaa Gaber Abdou**

Professor

Pathology Department, Faculty of Medicine, Menoufiya University, Egypt

**Pasquale De Franciscis, Ph.D.**

Professor

Department of Woman, Child and of General and Specialized Surgery Largo Madonna Delle Grazie 180138 Napoli, Italy

**Mostafa A. Borahay, Ph.D.**

Associate Professor

Department of Gynecology and Obstetrics, Johns Hopkins School of Medicine, Johns Hopkins Bayview Medical Center, Baltimore, USA

**Jun-qing Wu, Ph.D.**

Professor

Department of Epidemiology and Social Science on Reproduction of Shanghai Institute of Planned Parenthood Research, Shanghai, China; Fudan University, Shanghai, China

**Kampon Kaeoket, Ph.D.**

Associate Professor

Department of Clinical Sciences and Public Health, Faculty of Veterinary Science, Mahidol University, Nakhon Pathom, Thailand

**Eric Chung**

Professor

AndroUrology Centre for Sexual, Urinary and Reproductive Excellence; Department of Urology, Princess Alexandra Hospital, Brisbane, Australia

**Jens Fedder, Ph.D.**

Professor

Centre of Andrology & Fertility Clinic, Dept. D, Odense University Hospital, Odense, Denmark

**Da-jin Li, Ph.D**

Professor

Lab for Reproductive Immunology, Institute of Obstetrics & Gynecology, Fudan University Shanghai Medical College, Shanghai, China

**Liselotte Mettler**

Professor

Department of Obstetrics and Gynecology, University Clinics of Schleswig-Holstein, Kiel, Germany

**Sae Chul Kim, Ph.D.**

Professor

Director General, Myongji Medical Center, Goyang, Gyeonggi-do, Korea;

Emeritus Professor, Department of Urology College of Medicine, Chung-Ang University, Seoul, Korea;

Chairman, Korean Prostate Health Council;

Life member, Korean Academy of Science and Technology, National Academy of Medicine of Korea

**Juan F. Aller, Ph.D.**

Researcher

National Institute of Agricultural Technology, Experimental Station of Balcarce, Department of Animal Production, Animal Reproductive Biotechnology, Buenos Aires Province, Argentina

**Giulia Ricci, Ph.D.**

Aggregate Professor

Department of Experimental Medicine, Università della Campania "Luigi Vanvitelli", Via Luigi de Crechio 7, 80138- Naples, Italy

**Premendu Prakash Mathur, Ph.D.**

Professor

Department of Biochemistry & Molecular Biology, School of Life Sciences, Pondicherry University, Pondicherry-605014, India

**Marcel Leppée, Ph.D.**

Senior Researcher

Institute for Healthy Ageing, Zagreb, Croatia

**Martín Martínez-Torres**

Laboratorio de Biología de la Reproducción-Unidad de Morfofisiología, Facultad de Estudios Superiores Iztacala, Universidad Nacional Autónoma de México, México

**Antonio Gonzalez-Bulnes**

Comparative Physiology Group SGIT-INIA, Avda. Puerta de Hierro s/n 28040-Madrid, Spain

**Sandip Chattopadhyay**

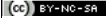



Department of Biomedical Laboratory Science and Management, Vidyasagar University, Midnapore, West Bengal, India

© Asian Pacific Journal of Reproduction | Published by Wolters Kluwer - Medknow

[Sitemap](#) | [What's New](#) | [Feedback](#) | [Disclaimer](#) | [FAQ](#)

Online since 14<sup>th</sup> Aug 2017.

Editorial and Ethics Policies

  **Open Access** |  **No Fee** |  [View mobile site](#)

ISSN: Print - 2305-0500, Online - 2305-0519



[About](#)

[Articles](#)

[Authors](#)

[Search](#)

[Contact Us](#)

[Login](#)

## Table of Contents - Current issue



**January 2020**

Volume 9 | Issue 1  
Page Nos. 1-54

Online since Tuesday, January 21, 2020

Accessed 1,634 times.

**PDF access policy**

Journal allows immediate open access to content in HTML + PDF

[View issue as eBook](#)

[Issue statistics](#)

[RSS](#)

[SUBMIT ARTICLE](#)

[POPULAR ARTICLES](#)

[JOIN AS REVIEWER](#)

[GET EMAIL ALERTS](#)

[RECOMMEND](#)

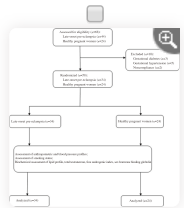
[Show all abstracts](#)

[Show selected abstracts](#)

[Export selected to](#) ▼

[Add to my list](#)

### ORIGINAL ARTICLES

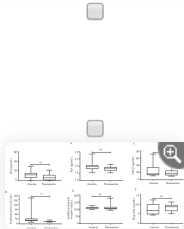


**Testosterone is a surrogate and proxy biomarker for severity of late-onset preeclampsia: A cross-sectional study** p. 1

Thabat J Al-Maiah, Ali I Al-Gareeb, Hayder M Al-kuraishy

DOI:10.4103/2305-0500.275522

[\[ABSTRACT\]](#) [\[HTML Full text\]](#) [\[PDF\]](#) [\[Mobile Full text\]](#) [\[EPub\]](#) [\[Sword Plugin for Repository\]](#)<sup>Beta</sup>

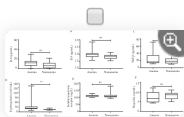


**Assessment of antioxidant status of women with polycystic ovarian syndrome** p. 9

Olufisayo Grace Oyebarji, Modupe Fisayo Asaolu

DOI:10.4103/2305-0500.275523

[\[ABSTRACT\]](#) [\[HTML Full text\]](#) [\[PDF\]](#) [\[Mobile Full text\]](#) [\[EPub\]](#) [\[Sword Plugin for Repository\]](#)<sup>Beta</sup>




**Novel genetic variants of transferrin receptor 2 exon 4 and cytokines profile of anemic and nonanemic pregnant women in Central Java, Indonesia** p. 16

Dono Indarto, Budiyantri Wiboworini, Amelya A Ayusari, Arisanty N Restuti, Isnar N Alfiah, Aniki Puspita, Yohanes C Wibowo, Yoga M Pratama

DOI:10.4103/2305-0500.275524

[\[ABSTRACT\]](#) [\[HTML Full text\]](#) [\[PDF\]](#) [\[Mobile Full text\]](#) [\[EPub\]](#) [\[Sword Plugin for Repository\]](#)<sup>Beta</sup>

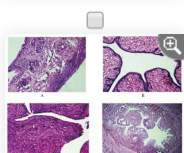


**Comparative proteomic analysis of mature and immature oocytes in domestic cats** p. 22

Bongkoch Turathum, Kulnasan Saikhun, Sittiruk Roytrakul, Chinnarat Changsangfa, Supita Tanasawet, Morakot Sroyraya, Yindee Kitiyanant

DOI:10.4103/2305-0500.275525

[\[ABSTRACT\]](#) [\[HTML Full text\]](#) [\[PDF\]](#) [\[Mobile Full text\]](#) [\[EPub\]](#) [\[Sword Plugin for Repository\]](#)<sup>Beta</sup>

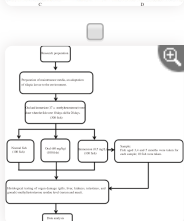


**Estrogenic activity of hydroalcoholic extract of *Clitoria ternatea* Linn. leaves on rats** p. 31

Mandeep Kaur, Avtar Chand Rana, Sunil Kumar

DOI:10.4103/2305-0500.275526

[\[ABSTRACT\]](#) [\[HTML Full text\]](#) [\[PDF\]](#) [\[Mobile Full text\]](#) [\[EPub\]](#) [\[Sword Plugin for Repository\]](#)<sup>Beta</sup>

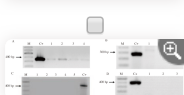


**Residual impact of 17 $\alpha$ -methyltestosterone and histopathological changes in sex-reversed Nile tilapia (*Oreochromis niloticus*)** p. 37

Dewi Nurmalita Suseno, Epy Muhammad Luqman, Mirni Lamid, Akhmad Taufiq Mukti, Muhammad Agus Suprayudi

DOI:10.4103/2305-0500.275527

[\[ABSTRACT\]](#) [\[HTML Full text\]](#) [\[PDF\]](#) [\[Mobile Full text\]](#) [\[EPub\]](#) [\[Sword Plugin for Repository\]](#)<sup>Beta</sup>

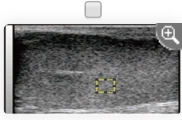


**Identification of pathogenic microorganisms of repeat breeder dairy cows and a hyperimmune treatment approach** p. 44

Seyed Morteza Aghamiri, Mohammad Rahim Ahmadi, Masoud Haghkhal, Abdollah Derakhshandeh

DOI:10.4103/2305-0500.275528

[\[ABSTRACT\]](#) [\[HTML Full text\]](#) [\[PDF\]](#) [\[Mobile Full text\]](#) [\[EPub\]](#) [\[Sword Plugin for Repository\]](#)<sup>Beta</sup>



**Seasonal changes in testicular ultrasonogram pixel-intensity and their association with semen characteristics in rams** p. 49

Mohamed Gamal Hedia, Mohamed Shehata El-Belely, Sayed Taha Ismail, Amal Mahmoud Abo El-Maaty


DOI:10.4103/2305-0500.275635

[\[ABSTRACT\]](#) [\[HTML Full text\]](#) [\[PDF\]](#) [\[Mobile Full text\]](#) [\[EPub\]](#) [\[Sword Plugin for Repository\]](#)<sup>Beta</sup>

Editorial and Ethics Policies

**BY-NC-SA** **Open Access** **No Fee** [View mobile site](#)  
ISSN: Print -2305-0500, Online - 2305-0519





## Original Article

## Asian Pacific Journal of Reproduction

Journal homepage: www.apjr.net



doi: 10.4103/2305-0500.275527

Residual impact of  $17\alpha$ -methyltestosterone and histopathological changes in sex-reversed Nile tilapia (*Oreochromis niloticus*)Dewi Nurmalita Suseno<sup>1</sup>, Epy Muhammad Luqman<sup>2</sup>, Mimi Lamid<sup>3</sup>, Akhmad Taufiq Mukti<sup>4✉</sup>, Muhammad Agus Suprayudi<sup>5</sup><sup>1</sup>Study Programme of Biotechnology of Fisheries and Marine, Universitas Airlangga, Surabaya, Indonesia<sup>2</sup>Department of Veterinary Anatomy, Faculty of Veterinary Medicine, Universitas Airlangga, Surabaya, Indonesia<sup>3</sup>Department of Feed and Nutrition, Faculty of Veterinary Medicine, Universitas Airlangga, Surabaya, Indonesia<sup>4</sup>Department of Fish Health Management and Aquaculture, Faculty of Fisheries and Marine, Universitas Airlangga, Surabaya, Indonesia<sup>5</sup>Department of Aquaculture, Bogor Agricultural University (IPB), Bogor, Indonesia

## ABSTRACT

**Objective:** To examine sex reversal both by oral and by immersion using  $17\alpha$ -methyltestosterone on the methyltestosterone residual concentration and the organ histopathology of tilapia fish.

**Methods:** This study used oral and immersion treatment methods for sex reversal of tilapia fish and used normal fish as the control and each treatment was repeated 4 times.  $17\alpha$ -methyltestosterone at dosages of 60 mg/kg feed and 0.5 mg/L were used for oral and immersion methods, respectively. In the first step, tilapia fry were reared at 100 L aquaria, with a density of 1 fish/L for 2 months. In the next step, male tilapias were reared at happa (net cage) of (2×1×1) m<sup>3</sup> size in the controlled pond, with a density of 30 fish/happa for 3 months. The methyltestosterone residual concentrations were analyzed by one-way analysis of variance and Duncan's multiple range tests, while organ histopathology was analyzed by descriptive method.

**Results:** Residual concentrations in the serum of methyltestosterone-treated fish were significantly lower than that in normal fish, especially in 4- and 5-month-old tilapias with averages of less than 5 µg/L, while in normal fish was more than 5 µg/L. In the flesh, methyltestosterone residual concentrations showed relatively no significant differences between the oral and immersion treatment groups and methyltestosterone-treated fish remained lower compared to normal fish, except in 5-month-old tilapia. Methyltestosterone-treated tilapia exhibited histopathological changes on gill, liver, kidneys, and intestine organs.

**Conclusions:** Sex reversal either by oral or by immersion has methyltestosterone residual concentration, but does not exceed the limits (5 µg/L or 5 µg/kg) of synthetic steroid on the fish body, although methyltestosterone causes histopathological changes on gill, liver, kidneys, and intestine.

**KEYWORDS:**  $17\alpha$ -methyltestosterone; Residue; Organ histopathology; Tilapia; Sex reversal method

## 1. Introduction

Sex reversal both by oral and by immersion using synthetic steroids proved to be a simple, easy, and highly effective technology[1]. Androgenic anabolic steroid hormones such as  $17\alpha$ -methyltestosterone ( $17\alpha$ -MT)[2,3] is a derivative of testosterone[4], which potentially increases sexual developmental in males[3]. The  $17\alpha$ -MT-immersed tilapia larvae produce males of 91.6%-98.3% [5,6], however, oral treatment of 60 mg/kg feed produces males of 93.7%[7], 97.7%[8], even reaches up to 100% males[9].

Synthetic steroid hormone would enter through the blood vessels in the body and then it was modulated by the brain and pituitary hormones[10]. Steroid hormone was synthesized in either the liver or the kidneys[11], and subsequently, it would produce androstenedione which consists of  $17\beta$ -estradiol and testosterone. If testosterone has increased, then the gonads would be immediately addressed to the male sex, but  $17\alpha$ -MT has characteristics that it is difficult to be absorbed within the body and it will also contaminate the environment[12].

The utility of hormones in aquaculture production was often debated by researchers due to the potential toxicity on human health (a carcinogenic and endocrine disorder) as well as the danger to the environment[1,3,13–15]. The group of anabolic steroids (including  $17\alpha$ -MT) based on the decision of the

✉ To whom correspondance may be addressed. E-mail: atm\_mlg@yahoo.com

This is an open access article distributed under the terms of the Creative Commons Attribution-Non Commercial-Share Alike 4.0 License, which allows others to remix, tweak and build upon the work non-commercially, as long as the author is credited and the new creations are licensed under the identical terms.

**For reprints contact:** reprints@medknow.com

©2020 Asian Pacific Journal of Reproduction Produced by Wolters Kluwer- Medknow. All rights reserved.

**How to cite this article:** Suseno DN, Luqman EM, Lamid M, Mukti AT, Suprayudi MA. Residual impact of  $17\alpha$ -methyltestosterone and histopathological changes in sex-reversed Nile tilapia (*Oreochromis niloticus*). Asian Pac J Reprod 2020; 9(1): 37-43.

**Article history:** Received: 21 May 2018; Revision: 15 December 2018; Accepted: 10 September 2019; Available online: 21 January 2020



Ministry of Marine Affairs and Fisheries, Republic of Indonesia (number KEP.52/MEN/2014) has been banned because of the hormones harmful to fish, environment, and human. This study expected to prove the presumption that has been the subject of debate in the fish farmer community that the use of  $17\alpha$ -MT at any dosage produces dangerous and toxic residues when consumed by humans and the released into the environment, as well as the debate among researchers and to address concerns that have existed in the community and policymakers that the use of  $17\alpha$ -MT in certain doses is still safe and does not contain dangerous residues of concern so far. So that the regulation can be revised again for the advancement of aquaculture while maintaining a sustainable environment and human health that consumes cultured fish. Therefore, the study aimed to examine sex reversal both by oral and by immersion using  $17\alpha$ -MT on the MT residual concentration and the organ histopathology changes of tilapia.

## 2. Materials and methods

### 2.1. Test animal

The test animal used was Nile tilapia (*Oreochromis niloticus*). Tilapia fry were produced by artificial fertilization and controlled incubation.

### 2.2. MT treatments

MT treatment by the oral method was started 3 days after hatching with using  $17\alpha$ -MT (Argent) dosage of 60 mg/kg feed. The oral treatment method lasted for 28 days. Immersion method using dosage of 0.5 mg/L of  $17\alpha$ -MT was conducted to 10-day-old Tilapia fry and repeated in 13-day-old Tilapia fry for 3 h, respectively[8]. Treatment groups (namely MT-treated fish, both by oral and by immersion) and normal fish as control were repeated 3 times, respectively with a density of 100 fish/replicate/treatment, so the total of fish, both treated and normal were 900 fish.

### 2.3. Fish rearing

In the initial step, fish were reared at 100 L aquaria, with a density of 1 fish/L for 2 months, separately in each treatment group. Fish was fed on commercial pellet content of 40% crude protein, 3 times daily, at satiation. Sex was determined on 2-month-old fish through manual observation of genitalia for all fish, and gonad preparation. To verify the sex from genitalia observation, gonad was obtained from 10 fish/replicate/treatment by using the squash method with acetocarmine dye according to Mukti[8]. Based on  $17\alpha$ -MT hormone treatment either by oral or by immersion and verify the sex by fish genitalia observation and followed by gonad

preparation shows male of 97%-98% and female of 2%-3%[8]. Then, male fish of 3 treatments were selected for further study.

In the next step, a total of 360 male tilapias used in this study for 3 treatments (120 fish/treatment) were reared separately at happa (net cage) of  $(2\times 1\times 1)$  m<sup>3</sup> size in the controlled pond, with the density of 30 fish per happa or replicate, respectively for 3 months. Each treatment was repeated 4 times. Fish was fed on commercial pellet content of 32% crude protein, 3 times daily, at-satiation.

### 2.4. Sampling

Fish sampling was done in the 3rd, 4th, and 5th months as much 3 fish/replicate/treatment, respectively for residue test. 3-month-old fish were used for histology preparation. Fish were anesthetized by using MS222 of 1 mg/L according to Gogal *et al*[16]. Serum (1 mL) was collected according to Atli *et al*[17], and flesh (10 g) of fish was collected to do testing of residues.

### 2.5. Measurement of MT residue

MT residue, both the serum and the flesh were measured by the sandwich enzyme-linked immunosorbent assay method using fish MT kit (cat number E0103Fi; Bioassay Technology Laboratory, Shanghai, China). Previously, the sample and the reagents were stored at a temperature of 18 °C-25 °C[3].

### 2.6. Histology preparation

Fish was carefully dissected on the abdominal part according to Wu *et al*[18] and gill, liver, kidneys, intestine, and gonad organs were collected and stored in the 50 mL tubes which consisted of buffer neutral formalin, with the ratio of 1:2 at room temperature. Histology processes were conducted according to the standard operational procedure, generally with slight modification[19]. The flow chart of the study was shown in Figure 1.

### 2.7. Statistical analysis

Data of MT residual concentrations were analyzed statistically by using analysis of variance (ANOVA) with SPSS ver.10 software. Significant ANOVA was followed by Duncan's multiple range test, while organ histopathology was analyzed descriptively. Data were expressed as mean±standard deviation (mean±SD). *P*-value < 0.05 was considered as statistical difference.

### 2.8. Ethical approval

The study was approved by the Animal Care and Use Committee of Brawijaya University; the protocol number was 985/8.8.2017.

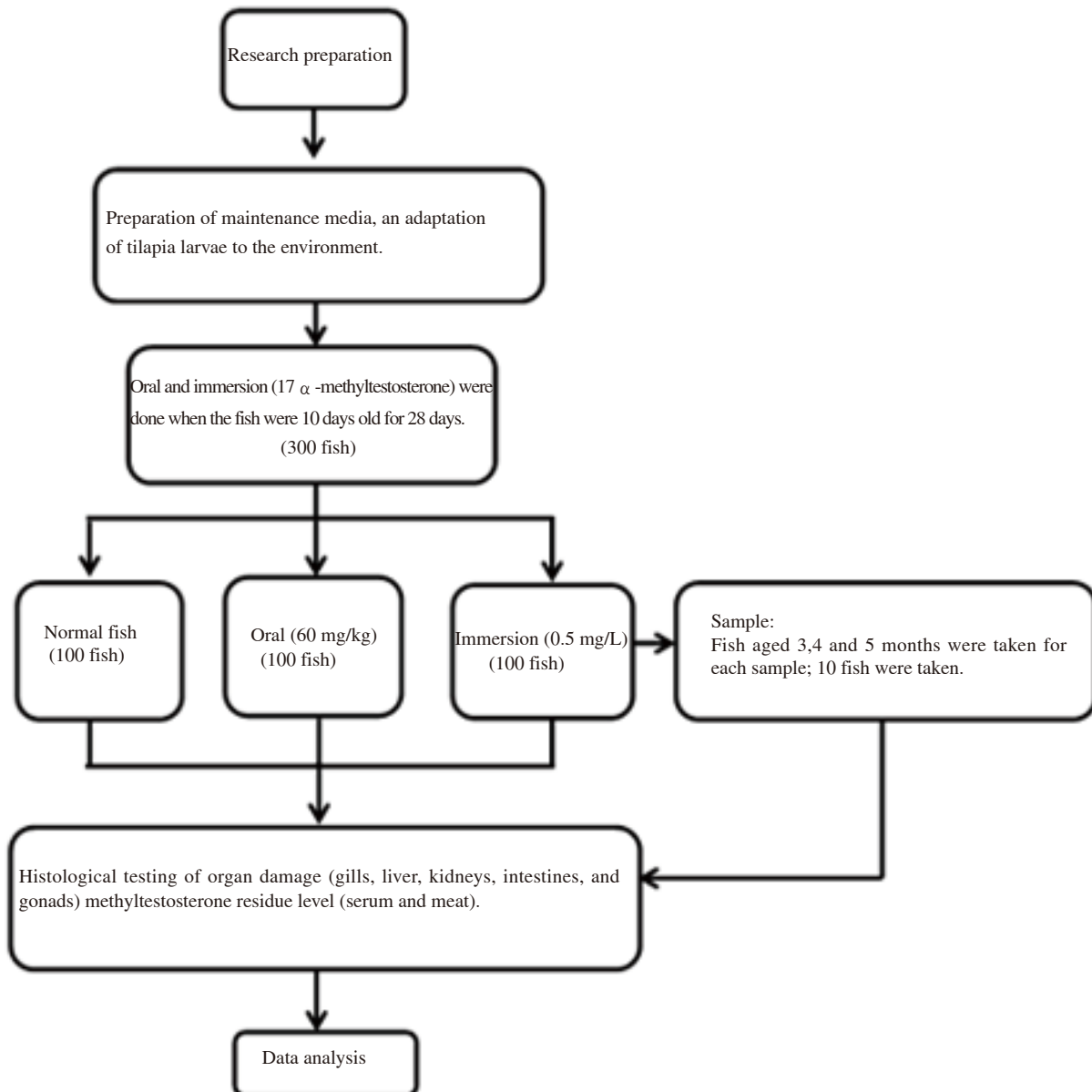


Figure 1. Flow chart of the study.

### 3. Results

#### 3.1. MT residual concentrations

MT residual concentration in the serum of MT-treated male tilapia, both by oral and by immersion, was decreased on the 4th month while increased again on the 5th month, the normal male fish was increased from the 4th month while slightly decreased on the 5th month (Table 1). On the 4th and 5th months, the MT residue concentrations were lower in both oral and immersion groups comparing with that of the normal group ( $P$  both  $<0.05$ ).

In the flesh, MT residual concentration showed relatively no significant difference between the oral and immersion treatment groups on 4th month, but the MT residual was significantly higher in the oral treatment group than that in the immersion group. MT-treated male tilapia remained lower than normal male tilapia in the 3rd and 4th months, except in the 5th month. However, the result showed that all males had increased MT residue in the 5th month comparing with that of the 4th month (Table 2).

#### 3.2. Organ histopathology

MT-treated male tilapias showed histopathology changes in gill, liver, kidneys, and intestine organs (Figure 2). In the gill, such as hyperplasia was found in the bottom secondary lamella. Hypertrophy appeared on the lamella stem due to the occurrence of containment. Clubbing occurred at the end of the primary lamella, which was caused by the existence of retention, so edema appeared on the lamella (Figure 2A). The liver showed congestion, hemorrhage, and cell atrophy (Figure 2B). Congestion was redder due to contained erythrocytes. Atrophy was shown by the reduction of cell size of Kupper, which made sinusoid widen and made vacuoles degenerate. Congestion caused sinusoidal erythrocytes to wide. Degeneration of liver cells made vacuoles enlarge. Normally, the liver organ did not have damage. Kidneys seem hemorrhage, infiltration of lymphocytes, and neutrophils, inflammation, and necrosis (Figure 2C). The infiltration presence of lymphocytes and neutrophils caused inflammation. The

intestine has look atrophy, intestinal villi hemorrhage, lymphoid follicles, and melanomacrophage (Figure 2D). The occurrence of hemorrhage led to the atrophy and melanomacrophage, so finally, it caused erosion and hemorrhage and necrosis of the intestinal villi.

On the other hand, testicular histology (Figure 3) used to

observe spermatogenesis or testicular development and may be histopathology change in different treatment of 3-month-old fish. This study showed no difference in testicular between normal fish (Figure 3A) and MT-treated fish, both oral (Figure 3B) and immersion (Figure 3C).

**Table 1.** Methyltestosterone residual concentrations ( $\mu\text{g/L}$ ) of serum in different age of male tilapia.

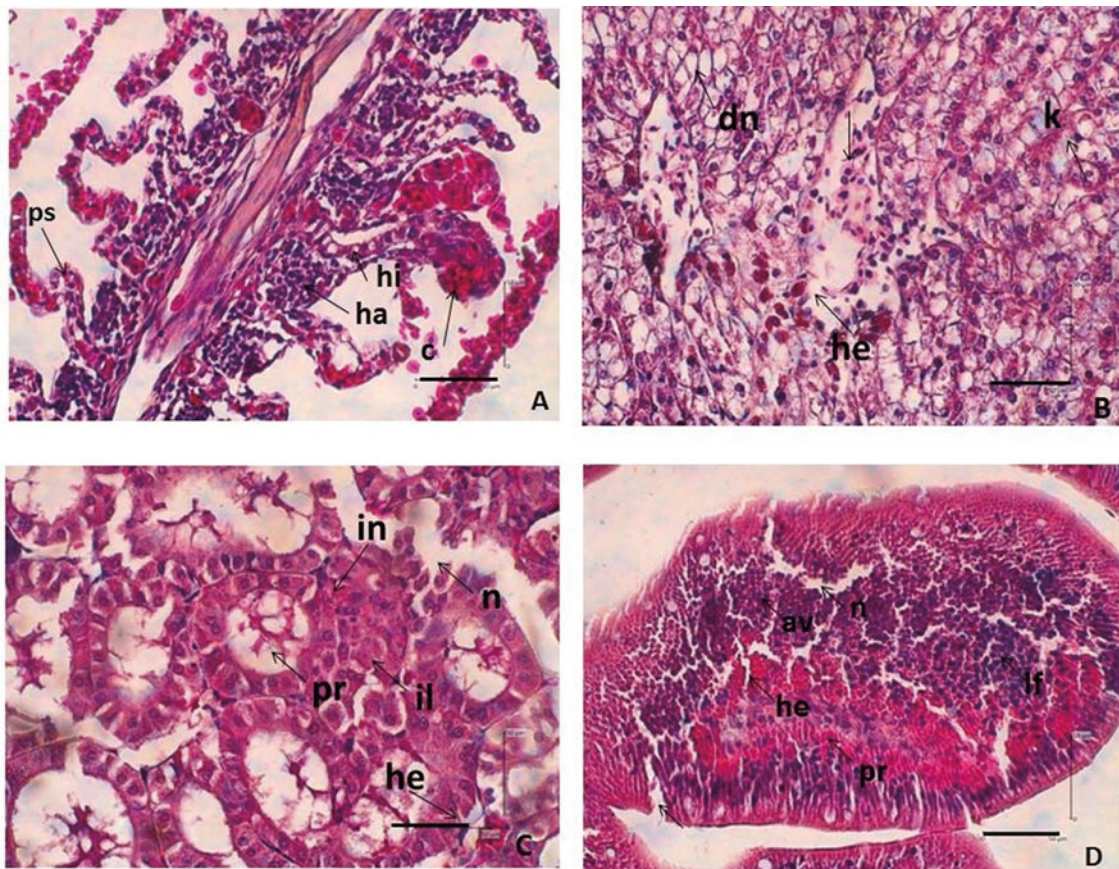
Ages of tilapia (month)	Treatments		
	Normal	Oral	Immersion
3	4.403 $\pm$ 0.058 <sup>sa</sup>	5.243 $\pm$ 0.080 <sup>b</sup>	4.431 $\pm$ 0.029 <sup>a</sup>
4	5.117 $\pm$ 0.057 <sup>c</sup>	4.171 $\pm$ 0.051 <sup>b</sup>	3.874 $\pm$ 0.038 <sup>a</sup>
5	5.105 $\pm$ 0.079 <sup>c</sup>	4.266 $\pm$ 0.050 <sup>a</sup>	4.450 $\pm$ 0.054 <sup>b</sup>

Data are expressed as mean $\pm$ SD. Different superscripts (a, b,c) in the same row show significant difference ( $P<0.05$ ).

**Table 2.** Methyltestosterone residual concentrations ( $\mu\text{g/kg}$ ) of the flesh in different age of male tilapia.

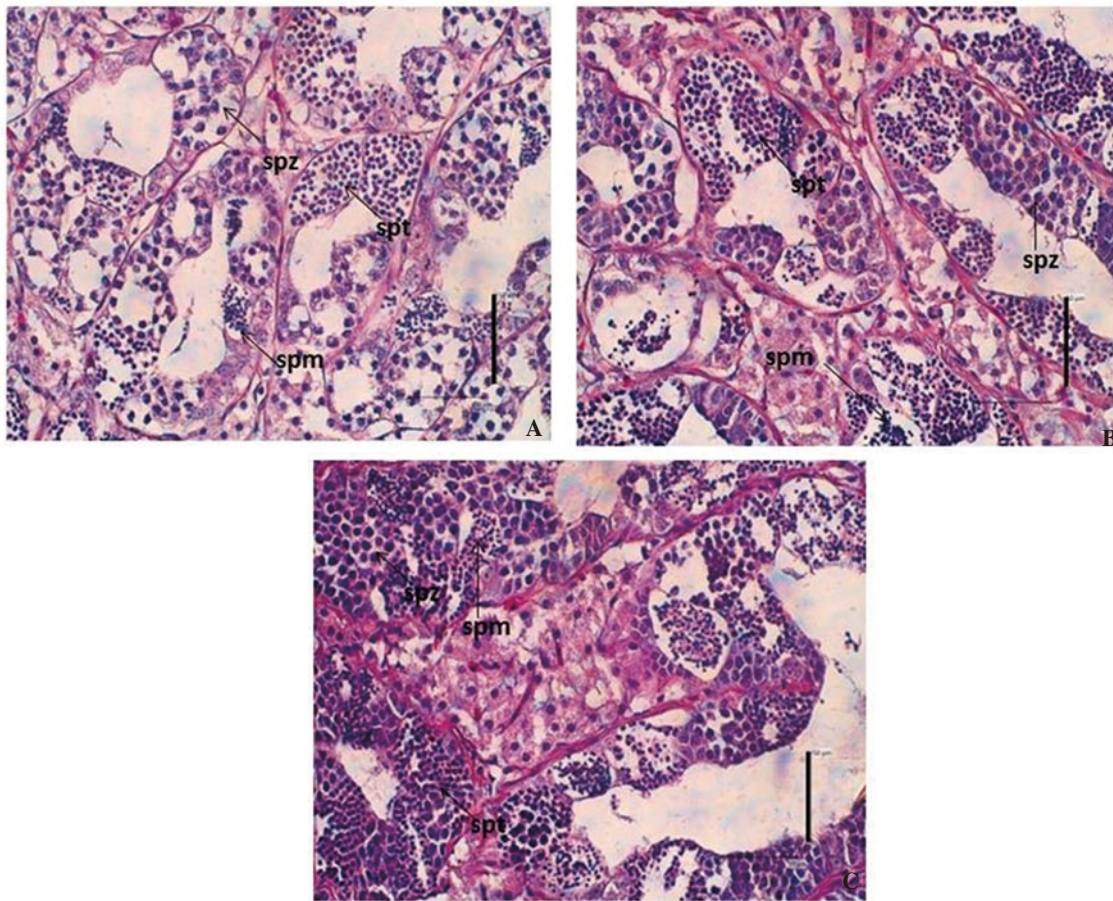
Ages of tilapia (month)	Treatments		
	Normal	Oral	Immersion
3	6.061 $\pm$ 0.094 <sup>a</sup>	5.967 $\pm$ 0.058 <sup>a</sup>	5.900 $\pm$ 0.100 <sup>a</sup>
4	6.259 $\pm$ 0.088 <sup>b</sup>	5.995 $\pm$ 0.079 <sup>a</sup>	5.898 $\pm$ 0.079 <sup>a</sup>
5	6.272 $\pm$ 0.109 <sup>a</sup>	7.099 $\pm$ 0.135 <sup>b</sup>	6.403 $\pm$ 0.088 <sup>a</sup>

Data are expressed as mean $\pm$ SD. Different superscripts (a, b,c) in the same row show significant difference ( $P<0.05$ ).



**Figure 2.** Organ histopathology of 3-month-old male tilapia fish ( $n = 3$ ) (H & E staining, scale bar = 50  $\mu\text{m}$ ). (A) gill, (B) liver, (C) kidney, and (D) intestine. Note: ha = hyperplasia; hi = hypertrophy; c = clubbing; ps = bending cell; he = haemorrhage; k = congestion; dn = degeneration of nucleus; il = infiltrating lymphocytes; in = neutrophil infiltration; n = necrosis; pr = inflammation; av = intestinal villi atrophy; lf = lymphoid follicles; pr = inflammation.





**Figure 3.** Testicular histology of 3-month-old male tilapia ( $n = 3$ ); normal fish (A), orally methyltestosterone-treated fish (B), and methyltestosterone-immersed fish (C), spm=spermatocytes; spt=spermatid; spz=spermatozoa. (H & E, bar scale = 50  $\mu$ m).

#### 4. Discussion

Hormonal activities are affected by three stereochemical aspects, *i.e.*, location of the cluster on the ring, axial and or equatorial positions, cluster, the configuration  $\alpha$  or  $\beta$ , trans and/or isomer, and cyclohexane ring conformations. Testosterone is a hormone that has a short activity time due to fast absorbance in the digestive tract and rapidly undergoes hepatic degradation. It is caused by the presence of bacteria in the gastrointestinal tract that oxidizes cluster  $17\beta$ -hydroxy to be inactive  $17\beta$ -keto. Therefore, it is necessary to add an alkyl group on 17th carbon to become  $C17\alpha$ . This prevented the conversion of  $17\beta$ -hydroxy metabolism to be  $17\beta$ -keto, so the  $17\alpha$ -MT compound has more activity in the body, but it could cause residue. The  $17\alpha$ -MT activity has half the strength of testosterone activity due to the length of C-chain alkyl groups, and then it would decrease androgenic activity. Otherwise, it would increase its toxicity.

The  $17\alpha$ -MT compounds could be transferred to live feed or water. Chemical substances had naturally incorporated into living organisms in several ways, through both the digestive and respiratory tracts[20,21]. Exposure to synthetic chemicals and their residue is a risk for human and wildlife health[3,22]. Based on serum MT concentration of males on the 3rd month, orally sex-reversed tilapia had more raising concentration than other treatments. However, in the 4th and 5th months, the MT concentration had decreased every month[3,22]. The orally MT-treated fish would contain MT only in the initial 5 months[23].

MT concentration was higher in the flesh compared to in the serum. High enough MT concentration was found in the muscle and flesh[24,25], because the MT metabolite has been absorbed into the muscle and flesh of fish, thus causing the MT to accumulate in the flesh every month. In the research of Pandian and Kirankumar[25], exogenous steroid remnants of 5  $\mu$ g/kg in fish were a too risk to humans. Endogenous testosterone hormone produced on the testes was 5.2  $\mu$ g/kg[26], whereas tilapia had endogenous testosterone and estradiol of 3  $\mu$ g/kg, respectively[25]. Normal fish have higher MT residue value than MT-treated fish as shown in this study. We suspect this is related to the reproductive cycle or period of Nile tilapia. Normally, Nile tilapia at the 4-month-old has entered the period of reproduction and spawning, so that seen an increase in hormone levels in blood serum. As is known during entering reproduction or spawning, hormone levels in the body increase and will drop back after spawning, while monosex-treated fish, although it looks the same as normal, the body's energy is preferred in increasing somatic growth compared to reproduction, so we suspect that this is one of the factors that causing male monosex-treated Nile tilapia has a larger body size than normal male tilapia.

Several limitations of this study are including: a) unable to measure specifically the MT residual concentration between introduced hormone (exogenous) and endogenously hormone by the fish, and b) unable to measure the MT residual concentration in younger fish age. Therefore, in the future, both of these limitations are our concern for further studies.

Gill layouts that were outside and directly related to water would be the first affected by the polluted water environment. The food already digested in the intestines would be circulated by blood to the liver and kidneys. The liver was the largest organ responsible for metabolism. Kidneys had functioned as a hyperosmotic regulator[27]. In 3-month-old fish, the toxicity to organs is still visible.

The early stage of damage caused by gill irritation has accompanied the increasing of the mucous cells at the bottom of epithelia with causing a thickening of the secondary lamella epithelium so that the secondary lamella enlarges due to the secondary lamella attached. Gill lamella looked larger than normal which was caused by cell enlargement (hypertrophy), and it looked unclear between the primary and secondary lamellas. According to previous studies[17,28,29], hyperplasia may occur due to chemical stimuli from pollutants, environmental pollution, parasites, and bacterial infections. Contamination has characterized by a very dense accumulation of red blood cells in the blood vessels, which would block blood vessels (congestion), while edema of lamella looks like an empty white space that causes blocking. Clubbing occurred because of the thickening of epithelial tissue located near to the lamella bottom (basal hyperplasia), and then the whole room of interlamellar was filled by new cells which showed like a baseball bat[27,30].

Degeneration was the early stage of vacuole damage in the liver. Vacuole degeneration was reversible, so when exposed to toxic substances and end administration of MT, cells could be returned to normal. Necrosis could not be cured, so if it exposed the tissue activity continuously, then it would decrease cell activity, causing the cells to lose some parts even to death[31,32]. Congestion was preceded by degeneration of liver cells in which an enlarged vacuole was filled with erythrocytes that cause sinusoid to widen that accumulated blood and hemorrhage. According to the research of Robert[30], congestion occurred by the entry of toxic substances into the heart. Hemorrhage was the flow of red blood cells out of the central vein.

Sinusoidal and central venous damage occurred due to numerous blockages of blood vessels in the stomach and central intestine[33,34], which causes a greater concentration of toxic substances in this area and causes damage to the central vein. A sinusoid is a small capillary that separated the fundamental of the structural unit with tubule or trabeculae (biliary hepatocytes surrounded by central parenchyma)[33,35]. The liver had an enzyme for drug metabolism which is one of the most damaged organs but is very resistant to viral or bacterial infections and foreign substances that enter through the absorption in the intestine. It was known that nearly 80% of the liver cells were damaged. But, it was still capable of regenerating and could even be cured if the damage was lost or destroyed[34].

The infected kidneys were swelling, which was an indication of an inflammatory process that may cause necrosis[35]. Inflammation was an indication of increased lymphocytes and macrophage or neutrophil cell numbers. Kidneys were pollutant-responsive organ to indicate histopathological damage. Therefore, the kidneys were the targeted organ for the biomonitoring approach[36]. Changes that often occurred in the kidney are inflammation, necrosis, thickening of the core, hyperplasia, hypertrophy epithelial cells, hydropic vacuolation, and renal tubular regression[35–37].

The intestine damage is signed by inflammation. The inflammation or swelling of cells has a reversible characteristic that exposed to the

toxic substances in a short period, the cell would return to normal, but if exposed to the toxic substances for a long time, the cell was not able to tolerate damage caused by toxin substances[38]. Melanomacrophage was caused by inflammation which was followed by erosion of the intestinal villi, hemorrhage, and atrophy leading to necrosis. Erosion and villus of the intestine with considerable damage would disturb the absorption of important substances so that that fish would suffer from malnutrition. In intestinal organs, there were cell swelling, microvillicell membrane fused, lysis, intestinal vacuum and intestinal villi erosion which suffered severe injuries to rupture caused by toxic substances[21]. Acute intestinal conditions were caused by viruses, parasites, bacteria, algae, and intestinal mucosa. Toxic chemicals could be removed by using mucous epithelial cells that coiled together with the thickening chromatin and cytoplasmic eosinophils[30]. MT concentrations of serum and flesh have not exceeded the limit (5 µg/L or 5 µg/kg) due to the estimated residual synthetic steroid in the fish body of 5 µg/kg. Influences on histopathology of gill, liver, kidneys, and intestine organs are found with varying degrees of damage because there are remaining synthetic hormones left in the body that cause organ damage. Further work is another safer natural material to replace the performance of the alkyl group as well as the histopathological figure of the 4- and 5-month-old fish to determine whether there is a recovery in the fish organ after the cessation of synthetic hormone.

## Conflict of interest statement

The authors declare that there is no conflict of interest.

## Authors' contributions

Dewi Nurmalita Suseno contributes to literature search, clinical and experimental studies, data analysis, and manuscript preparation. Epy Muhammad Luqman contributes to arrange the definition of intellectual content, data analysis, and manuscript review. Mirni Lamid contributes to arrange definition of intellectual content and statistical analysis. Akhmad Taufiq Mukti contributes to conceptualization, research design, arrange definition of intellectual content, data acquisition and analysis, and manuscript editing and review. Muhammad Agus Suprayudi contributes to arrange the definition of intellectual content, manuscript review, and guarantor.

## References

- [1] Dergal NB, Scippo ML, Degand G, Gennotte V, Melard C, Abi-Ayad SMEA. Monitoring of 17  $\alpha$ -methyltestosterone residues in tilapia *Oreochromis niloticus* flesh and experimental. *Int J Biosci* 2016; **9**: 101-113.
- [2] Kang JI, Yokota H, Oshima Y, Tsuruda Y, Shimasaki Y, Honjo T. The effects of methyltestosterone on the sexual development and reproduction of adult medaka *Oryzias latipes*. *Aquat Toxicol* 2008; **87**: 37-46.
- [3] Risto U, H Musliu Z, Dimzoska Biljana S, Stojkovic ED, Aleksandra T, Velimir S. Validation of screening method for the determination of methyltestosterone in fish. *Mac Vet Rev* 2013; **36**: 19-23.

- [4] Fragakaki GA, Angelis SY, Koupparis M, Tsantili-Kakoulidou A, Kokotos G, Georgakopoulos C. Structural characteristics of anabolic androgenic steroids contributing to binding to the androgen receptor and their anabolic and androgenic activities: Applied modifications in the steroidal structure. *Steroids* 2009; **74**: 172-197.
- [5] Afpriyaningrum MD, Soelistyowati DT, Alimuddin, Zairin JRM, Setiawati M, Hardiantho D. Masculinization of Nile tilapia through immersion of larvae at 36 °C temperature and residue level of 17  $\alpha$  -methyltestosterone in fish body. *Omni-Akuatika* 2016; **12**: 106-113.
- [6] Srisakultiew P, Kamornrat W. Immersion of 17  $\alpha$  -methyltestosterone dose and duration on tilapia masculinization. *J Fish Sci* 2013; **7**: 302-308.
- [7] Celik I, Guner Y, Celik P. Effect of orally administered 17  $\alpha$  -methyltestosterone at different doses on the sex reversal of the Nile tilapia *Oreochromis niloticus* L. 1758. *J Anim Vet Adv* 2011; **10**: 853-857.
- [8] Mukti AT. *Triploidy and sex dimorphism, their reproductive and production performances in Nile tilapia Oreochromis niloticus*. Dissertation. Bogor Agricultural University (IPB); 2016.
- [9] Popma TJ, Green BW. *Sex reversal of tilapia in earthen ponds*. Research Report. International Center for Aquaculture and Aquatic Environments Research and Development Series No. 35. Alabama: Auburn University; 1990.
- [10] Rivero-Wendt GLC, Oliveira R, Monteiro SM, Domingues I, Soares MVMA, Grisolia KC. Steroid androgen 17  $\alpha$  -methyltestosterone induces malformations and biochemical alterations in zebrafish embryos. *Environ Toxicol Pharmacol* 2016; **44**: 107-113.
- [11] El-Greisy ZA, El-Gamal AE. Monosex production of tilapia, *Oreochromis niloticus* using different doses of 17  $\alpha$  -methyltestosterone with respect to the degree of sex stability after one year of treatment. *Egypt J Aquat Toxicol Res* 2012; **38**: 59-66.
- [12] Streck G. Chemical and biological analysis of estrogenic, progestogenic and androgenic steroids in the environment. *TrAC Trends Analyt Chem* 2009; **28**: 635-652.
- [13] Khalil WKB, Hasheesh WS, Marie MAS, Abbas HH, Zahran EA. Assessment the impact of 17  $\alpha$  -methyltestosterone hormone on growth, hormone concentration, molecular, and histopathological changes in muscles and testis of Nile tilapia *Oreochromis niloticus*. *Life Sci J* 2011; **8**: 329-344.
- [14] Barbosa IR, Lopes S, Oliveira R, Domingues I, Soares AMVM, Nogueira AJA. Determination of 17  $\alpha$  -methyltestosterone in freshwater samples of tilapia farming by high-performance liquid chromatography. *Am J Analyt Chem* 2013; **4**: 207-211.
- [15] Kefi AS, Kang'Ombe J, Kassam D, Katongo C. Effect of 17  $\alpha$  -methyltestosterone on hematology and histology of liver and heart of *Oreochromis andersonii* Castelnau, 1861. *J Mar Sci Res Dev* 2013; **3**: 1-7.
- [16] Gogal MR, Phillips SR, Bringolf R, Guo LT, Steven DH. Anesthetic activity of acetylated MS-222 in tilapia (*Oreochromis niloticus*). *J Vet Sci* 2017; **4**: 1-6.
- [17] Atli G, Ariyurek YS, Kanak GE, Canli M. Alterations in the serum biomarkers belonging to different metabolic systems of fish (*Oreochromis niloticus*) after Cd and Pb exposures. *Environ Toxicol Pharmacol* 2015; **40**: 508-515.
- [18] Wu JL, Zhang JL, Du XX, Shen YJ, Lao X, Zhang ML, et al. Evaluation of the distribution of adipose tissues in fish using magnetic resonance imaging (MRI). *Aquaculture* 2015; **448**: 112-122.
- [19] Priosoeryanto BO, Ersu IM, Tiuria R, Handayani SU. The description of the *Oreochromis mossambicus* gills, gut, and muscle histopathology originating from Ciampoa region, Bogor. *Ind J Vet Sci Med* 2010; **11**: 1-8.
- [20] Sudarwin. *A special analysis of the heavy metals (Pb and Cd) pollution on the sedimentary basins of the landfills trash Jatibarang, Semarang*. Thesis. Diponegoro University; 2008.
- [21] Maharajan A, Kitto MR, Paruruckumani PS, Ganapiriya V. Histopathology biomarker responses in Asian sea bass *Lates calcarifer* Bloch exposed to copper. *J Basic Applied Zool* 2016; **77**: 21-30.
- [22] Budd MA, Banh QQ, Domingos AJ, Jerry RD. Sex control in fish: Approaches, challenges, and opportunities for aquaculture. *J Mar Sci Eng* 2015; **3**: 329-355.
- [23] Liu S, Wang L, Qin F, Zheng Y, Li M, Zhang Y, et al. Gonadal development and transcript profiling of steroidogenic enzymes in response to 17  $\alpha$  -methyltestosterone in the rare minnow *Gobiocypris rarus*. *J Steroid Biochem Molecul Biol* 2014; **143**: 223-232.
- [24] Sayed AEDH, Moneeb RH. Hematological and biochemical characters of monosex tilapia *Oreochromis niloticus* Linnaeus, 1758 cultivated using methyltestosterone. *J Basic Appl Zool* 2015; **72**: 36-42.
- [25] Pandian TJ, Kirankumar S. Recent advances in hormonal induction of sex reversal in fish. *J Appl Aqua* 2003; **13**: 205-230.
- [26] Jamieson BGM. *Reproductive biology and phylogeny of fishes*. Volume 8B. New York: CRC Science Publishers; 2009.
- [27] Yuniar V. *The toxicity of mercury (Hg) on survival rate, growth, blood, and organ damage of Nile tilapia Oreochromis niloticus*. Thesis. Bogor Agricultural University (IPB); 2009.
- [28] Zulfahmi I, Affandi R, Batu LTFD. Changes in the structure of gill and liver histology in tilapia fish *Oreochromis niloticus* Linnaeus, 1758 exposure to mercury. *J Edukasi Sains Biol* 2015; **IV**: 25-31.
- [29] Mulyani FAM, Widyaningrum P, Utami NR. Toxicity test of microanatomy and change of the gills structure in Nile tilapia *Oreochromis niloticus* strain Larasati being lead acetate. *J MIPA* 2014; **37**: 1-6.
- [30] Robert RJ. *Fish pathology*. 4th ed. New York: Wiley-Blackwell Publishing Ltd; 2012.
- [31] Sipahutar WL, Aliza D, Winaruddin, Nazaruddin. Histopathological of tilapia *Oreochromis niloticus* gill maintained in heat temperature. *J Medik Vet* 2013; **7**: 19-21.
- [32] Sofiana ED, Widjiati, Luqman EM, Samik A. Influence of bark mangosteen *Garcinia mangostana* L. extracts on alveolar type II cell necrosis of the lungs in pregnant neonatal mice *Mus musculus* being cigarette smoke. *J Medik Vet* 2015; **8**: 131-136.
- [33] Fricke NF, Stentford GD, Feist SW, Lang T. Liver histopathology in baltic eelpout *Zoarces viviparus*: A baseline study for use in marine environmental monitoring. *Mar Environ Res* 2012; **82**: 1-14.
- [34] Marrison J. *Fish histology and histopathology*. West Virginia: USFWS-NCTC; 2007.
- [35] Ratnawati A, Purwaningsih U, Kurniasih. Histopathological of *Edwardsiella tarda* alleged as the cause death of goldfish *Carassius auratus* chef Koch's postulates. *J Sci Vet* 2013; **31**: 55-65.
- [36] Cuevas N, Zorita J, Franco J, Coasta PM, Larreta J. Multi-organ histopathology in gobies for estuarine environmental risk assessment: A case study in the Ibaizabal estuary (SE Bay of Biscay). *Estuarine Coastal Shelf Sci* 2016; **179**: 145-154.
- [37] Costa PM, Caeiro S, Diniz MS, Lobo J, Martins M, Ferreira AM, et al. A description of chloride cell and kidney tubule alterations in the flatfish *Solea senegalensis* exposed to moderately contaminated sediments from the Sado estuary (Portugal). *J Sea Res* 2015; **64**: 465-472.
- [38] Mahasri G, Kusnoto K, Insivitatwati E. The hematology and histopathology of koi fish *Cyprinus carpio koi* gill, gut, and brain orally infected *Myxobolus koi*. *J Ilmiah Perik Kel* 2015; **7**: 225-234.