

## BUKTI KORESPONDENSI

### Jurnal Internasional Bereputasi

Judul Artikel : The Effect of Exposure Calcium Carbonat from Blood Cockle (Anadara Granosa) Shells to the Expression of the NF- $\kappa$  $\beta$  on Dentin Pulp Complex.

Penulis : Widya Saraswati, Nina Dhaniar, **Dian Agustin Wahjuningrum**, Nunik Nuraini, Anuj Bhardwaj

Jurnal : Journal of International Dental and Medical Research  
Volume · 14 · Number · 2 ·

Penerbit : Ektodermal Displazi Grubu

|   |   |                                  |
|---|---|----------------------------------|
| 1 | Manuscript was submitted to Journal " <b>Journal of International Dental and Medical Research</b> " (ID: D20_1366)  | <b>Received: 8 Desember 2020</b> |
|   | Your manuscript entitled " The Effect of Exposure Calcium Carbonat From Blood Cockle (Anadara Granosa) Shells To The Expression Of The NF- $\kappa$ $\beta$ On Dentin Pulp Complex " has been successfully submitted to the JIDMR by e-mail and will be considered for publication in "Journal of International Dental and Medical Research".     |                                  |
| 2 | <b>Revision need</b>  | <b>Received: 21 Januari 2021</b> |
|   | Please send to the your revised article which titled " The Effect of Exposure Calcium Carbonat From Blood Cockle (Anadara Granosa) Shells To The Expression Of The NF- $\kappa$ $\beta$ On Dentin Pulp Complex", as soon as possible due to coming issue JIDMR 2021; 14(1) almost is full, other way your articles could be publish another issue |                                  |
| 3 | Revision need 2   | <b>Received: 23 Januari 2021</b> |
|   | Please add "Conclusion" section to the your revised article which titled " The Effect of Exposure Calcium Carbonat From Blood Cockle (Anadara Granosa) Shells To The Expression Of The NF- $\kappa$ $\beta$ On Dentin Pulp Complex", as soon as possible.   |                                  |
| 5 | Decision: <b>Accepted for Publication</b>   | <b>25 Januari 2021</b>           |
| 6 | <b>Published online</b>   | <b>29 Januari 2021</b>           |
| 7 | <b>Published on Journal of International Dental and Medical Research Volume · 14 · Number · 2</b>   | <b>29 Januari 2021</b>           |

---

**D20\_1366\_Dian\_Agustin\_Wahjuningrum\_Indonesia / Submission confirmation**

3 pesan

---

izzet yavuz <izzetyavuz@hotmail.com>  
Kepada: agustin wahjuningrum Dian <dian-agustin-w@fkg.unair.ac.id>

8 Desember 2020 21.01

Dear Prof. Dr. Dian Agustin Wahjuningrum,

Your manuscript entitled " The Effect of Exposure Calcium Carbonat From Blood Cockle (Anadara Granosa) Shells To The Expression Of The NF- $\kappa$ B On Dentin Pulp Complex " has been successfully submitted to the JIDMR by e-mail and will be considered for publication in "**Journal of International Dental and Medical Research**".

We are sending your article for a peer-review and when we receive an evaluation we will inform you.

Thank for considering the manuscript for submission to the **Journal of International Dental and Medical Research**.

Please feel free to contact me with any questions or concerns.

Best Regards,

**Prof. Dr. Izzet YAVUZ**  
**Editor-in-Chief and General Director**  
**Journal of International Dental and Medical Research ISSN 1309 - 100X**  
<http://www.jidmr.com/journal/>  
**MSc, PhD, Professor, Pediatric Dentistry**  
**Dicle University, Faculty of Dentistry**  
**21280 Diyarbakir, TURKEY**  
E-mail: [izzetyavuz@hotmail.com](mailto:izzetyavuz@hotmail.com), [iyavuz@dicle.edu.tr](mailto:iyavuz@dicle.edu.tr)  
**ECTODERMAL DYSPLASIA GROUP - TURKEY**  
<http://www.ektodermaldisplazi.com>

---

**Gönderen:** agustin wahjuningrum Dian <dian-agustin-w@fkg.unair.ac.id>

**Gönderildi:** 7 Aralık 2020 Pazartesi 17:52

**Kime:** izzet yavuz <izzetyavuz@hotmail.com>

**Konu:** manuscript

Dear Prof Izzet,  
I would like to publish in JIDMR. I attach a manuscript.  
Thank you so much for your support  
Warm regards  
Dian

---

**agustin wahjuningrum Dian** <dian-agustin-w@fkg.unair.ac.id>  
Kepada: izzet yavuz <izzetyavuz@hotmail.com>

8 Desember 2020 21.19

Dear Prof Izzet,  
I would like to say thank you for your support. I attach a manuscript. (Word)

Warm regards  
Dian

[Kutipan teks disembunyikan]



**Manuskrip WIDYA S-IJDMR.docx**  
195K

---

izzet yavuz <izzetyavuz@hotmail.com>  
Kepada: agustin wahjuningrum Dian <dian-agustin-w@fkg.unair.ac.id>

8 Desember 2020 21.30

Thanks for immediate reply.

All the best.

**Prof. Dr. Izzet YAVUZ**

**Editor-in-Chief and General Director**

**Journal of International Dental and Medical Research ISSN 1309 - 100X**

**<http://www.jidmr.com/journal/>**

***MSc, PhD, Professor, Pediatric Dentistry***

***Dicle University, Faculty of Dentistry***

**21280 Diyarbakir, TURKEY**

E-mail: [izzetyavuz@hotmail.com](mailto:izzetyavuz@hotmail.com), [iyavuz@dicle.edu.tr](mailto:iyavuz@dicle.edu.tr)

**ECTODERMAL DYSPLASIA GROUP - TURKEY**

**<http://www.ektodermaldisplazi.com>**

---

**Gönderen:** agustin wahjuningrum Dian <dian-agustin-w@fkg.unair.ac.id>

**Gönderildi:** 8 Aralık 2020 Salı 17:19

**Kime:** izzet yavuz <izzetyavuz@hotmail.com>

**Konu:** Re: D20\_1366\_Dian\_Agustin\_Wahjuningrum\_Indonesia / Submission confirmation

[Kutipan teks disembunyikan]

---

**It: D20\_1366\_Dian\_Agustin\_Wahjuningrum\_Indonesia / Revision needs**

2 pesan

---

izzet yavuz <izzetyavuz@hotmail.com>

21 Januari 2021 01.55

Kepada: "dian-agustin-w@fkg.unair.ac.id" <dian-agustin-w@fkg.unair.ac.id>

Dear **Prof. Dr. Dian Agustin Wahjuningrum,**

Please send to the your revised article which titled "**The Effect of Exposure Calcium Carbonat From Blood Cockle (Anadara Granosa) Shells To The Expression Of The NF-K $\beta$  On Dentin Pulp Complex**", as soon as possible due to coming issue JIDMR 2021; 14(1) almost is full, other way your articles could be publish another issue.

You can send your article after revisions, you must complete your process up to 7 days for coming issue.

Sincerely yours.

**Prof. Dr. Izzet YAVUZ**

**Editor-in-Chief and General Director**

**Journal of International Dental and Medical Research ISSN 1309 - 100X**

<http://www.jidmr.com/journal/>

Gönderen: izzet yavuz

Gönderildi: 10 Ocak 2021 Pazar 19:48

Kime: agustin wahjuningrum Dian <dian-agustin-w@fkg.unair.ac.id>

Konu: D20\_1366\_Dian\_Agustin\_Wahjuningrum\_Indonesia / Revision needs

Dear **Prof. Dr. Dian Agustin Wahjuningrum,**

Your article looks well designed which titled "**The Effect of Exposure Calcium Carbonat From Blood Cockle (Anadara Granosa) Shells To The Expression Of The NF-K $\beta$  On Dentin Pulp Complex**", but it should be revise especially references section according to the JIDMR guideline <http://www.jidmr.com/journal/author-guidelines/> .

Referencess citations should be at the and upside of sentences without brackets as a numerically superscript.

All of the references section should be unique with a same character (Year; volume(No): page number).

You can send your article after revisions, you must complete your process up to 7 days.

Sincerely yours.

**Prof. Dr. Izzet YAVUZ**

**Editor-in-Chief and General Director**

**Journal of International Dental and Medical Research ISSN 1309 - 100X**

<http://www.jidmr.com/journal/>

**MSc, PhD, Professor, Pediatric Dentistry**

**Dicle Üiversity, Faculty of Dentistry**

**21280 Diyarbakir, TURKEY**

E-mail: izzetyavuz@hotmail.com, iyavuz@dicle.edu.tr

**agustin wahjuningrum Dian** <dian-agustin-w@fkg.unair.ac.id>  
Kepada: izzet yavuz <izzetyavuz@hotmail.com>

22 Januari 2021 17.54

Dear Prof Izzet  
Thank you for reminding me. I already revised. Thank You so much for your support.  
warm regards  
Dian

[Kutipan teks disembunyikan]



**Manuskrip IJDMR Wd-revisi.docx**  
638K

---

**D20\_1366\_Dian\_Agustin\_Wahjuningrum\_Indonesia / Revision needs2**

2 pesan

izzet yavuz <izzetyavuz@hotmail.com>

23 Januari 2021 16.57

Kepada: agustin wahjuningrum Dian <dian-agustin-w@fkg.unair.ac.id>

Dear **Prof. Dr. Dian Agustin Wahjuningrum**,

Please add "Conclusion" section to the your revised article which titled "**The Effect of Exposure Calcium Carbonat From Blood Cockle (Anadara Granosa) Shells To The Expression Of The NF-K $\beta$  On Dentin Pulp Complex**", as soon as possible.

Sincerely yours.

**Prof. Dr. Izzet YAVUZ**

**Editor-in-Chief and General Director**

**Journal of International Dental and Medical Research ISSN 1309 - 100X**

<http://www.jidmr.com/journal/>

**MSc, PhD, Professor, Pediatric Dentistry**

**Dicle Üiversity, Faculty of Dentistry**

**21280 Diyarbakir, TURKEY**

E-mail: [izzetyavuz@hotmail.com](mailto:izzetyavuz@hotmail.com), [iyavuz@dicle.edu.tr](mailto:iyavuz@dicle.edu.tr)

**ECTODERMAL DYSPLASIA GROUP - TURKEY**

<http://www.ektodermaldisplazi.com>

---

**Gönderen:** agustin wahjuningrum Dian <dian-agustin-w@fkg.unair.ac.id>

**Gönderildi:** 22 Ocak 2021 Cuma 13:54

**Kime:** izzet yavuz <izzetyavuz@hotmail.com>

**Konu:** Re: D20\_1366\_Dian\_Agustin\_Wahjuningrum\_Indonesia / Revision needs

Dear Prof Izzet

Thank you for reminding me. I already revised. Thank You so much for your support.

warm regards

Dian

---

Pada tanggal Kam, 21 Jan 2021 pukul 01.55 izzet yavuz <izzetyavuz@hotmail.com> menulis:

Dear **Prof. Dr. Dian Agustin Wahjuningrum**,

Please send to the your revised article which titled "**The Effect of Exposure Calcium Carbonat From Blood Cockle (Anadara Granosa) Shells To The Expression Of The NF-K $\beta$  On Dentin Pulp Complex**", as soon as possible due to coming issue JIDMR 2021; 14(1) almost is full, other way your articles could be publish another issue.

You can send your article after revisions, you must complete your process up to 7 days for coming issue.

Sincerely yours.

**Prof. Dr. Izzet YAVUZ**

**Editor-in-Chief and General Director**  
**Journal of International Dental and Medical Research ISSN 1309 - 100X**  
<http://www.jidmr.com/journal/>

Gönderen: izzet yavuz

Gönderildi: 10 Ocak 2021 Pazar 19:48

Kime: agustin wahjuningrum Dian <dian-agustin-w@fkg.unair.ac.id>

Konu: D20\_1366\_Dian\_Agustin\_Wahjuningrum\_Indonesia / Revision needs

Dear **Prof. Dr. Dian Agustin Wahjuningrum**,

Your article looks well designed which titled " **The Effect of Exposure Calcium Carbonat From Blood Cockle (Anadara Granosa) Shells To The Expression Of The NF- $\kappa$ B On Dentin Pulp Complex** ", but it should be revise especially references section according to the JIDMR guideline <http://www.jidmr.com/journal/author-guidelines/> .

Referens citations should be at the and upside of sentences without brackets as a numerically superscript.

All of the references section should be unique with a same character (Year; volume(No): page number).

You can send your article after revisions, you must complete your process up to 7 days.

Sincerely yours.

**Prof. Dr. Izzet YAVUZ**

**Editor-in-Chief and General Director**

**Journal of International Dental and Medical Research ISSN 1309 - 100X**

<http://www.jidmr.com/journal/>

**MSc, PhD, Professor, Pediatric Dentistry**

**Dicle Üniversitesi, Faculty of Dentistry**

**21280 Diyarbakir, TURKEY**

E-mail: izzetyavuz@hotmail.com, iyavuz@dicle.edu.tr

**ECTODERMAL DYSPLASIA GROUP - TURKEY**

<http://www.ektodermaldisplazi.com>

---

agustin wahjuningrum Dian <dian-agustin-w@fkg.unair.ac.id>

24 Januari 2021 17.01

Kepada: izzet yavuz <izzetyavuz@hotmail.com>

Dear Prof Izzet

Thank you for your support. I already added the conclusion in the manuscript.

warm regards

Dian

[Kutipan teks disembunyikan]



Manuskrip IJDMR Wd-revisi (1) (1).docx

583K

**D20\_1366\_Dian\_Agustin\_Wahjuningrum\_Indonesia / Accept letter**

2 pesan

izzet yavuz <izzetyavuz@hotmail.com>

25 Januari 2021 02.09

Kepada: agustin wahjuningrum Dian <dian-agustin-w@fkg.unair.ac.id>

**Subject:** Your article has been accepted for Publication. (**Widya Saraswati, Nina Dhaniar, Dian Agustin Wahjuningrum, Nunik Nuraini, Anuj Bhardwaj, “The Effect of Exposure Calcium Carbonat From Blood Cockle (Anadara Granosa) Shells To The Expression Of The NF-κβ On Dentin Pulp Complex”**)

Dear Prof. Dr. Dian Agustin Wahjuningrum,

It's a great pleasure for me to inform you that your manuscript which titled **“The Effect of Exposure Calcium Carbonat From Blood Cockle (Anadara Granosa) Shells To The Expression Of The NF-κβ On Dentin Pulp Complex ”** has been accepted and will be finalized for **issue 2021; volume 14 number 2** which will be released either late June 2021 or early July 2021.

Send us Transfer of Copyright Agreement please, it is necessarily before sending manuscript to press <http://www.jidmr.com/journal/>, [http://www.ektodermaldisplazi.com/journal/documents/Transfer\\_of\\_Copyright\\_Agreement.doc](http://www.ektodermaldisplazi.com/journal/documents/Transfer_of_Copyright_Agreement.doc).

Before sending manuscript to press, I will send to you the press ready copy for your final checking.

Sincerely yours.

Open access and publication process charges for your article is 750 US\$.

You must complete your article charges process for your accepted article up to **30 days**, in case of late charges transfer then your accepted article will be publish other any issue.

Sincerely yours.

**1- By bank transfer to the my account (as 750 US\$).**

**Please carefully fill in transaction form and indicate at the “Remittance Information” section over the transaction or swift bill (pay slip) section to the; Full Account Beneficiary Name, Account IBAN number and **your article ID number** .**

Please inform JIDMR money order date when you did.

|   |  |
|---|--|
| FINANCIAL INSTITUTION<br><b>Vakıf Bank</b>                        | BANK CODE/ABA # <b>Vakıf Bank 015</b>                    |
| BRANCH<br><b>Dicle Universitesi (Diyarbakir)(S0527)Bağlı Şube</b> | ACCOUNT HOLDER / BENEFICIARY NAME#<br><b>izzet yavuz</b> |
| CITY/STATE/ZIP/COUNTRY  | SWIFT CODE <b>TVBATR2A</b>                               |
|   | BIC CODE <b>XXX</b>                                      |
|   | IBAN / ACCOUNT NUMBER #                                  |



**Prof. Dr. Izzet YAVUZ**

**Editor-in-Chief and General Director**

**Journal of International Dental and Medical Research ISSN 1309 - 100X**

<http://www.jidmr.com/journal/>

**MSc, PhD, Professor, Pediatric Dentistry**

**Dicle University, Faculty of Dentistry**

**21280 Diyarbakir, TURKEY**

E-mail: [izzetyavuz@hotmail.com](mailto:izzetyavuz@hotmail.com), [iyavuz@dicle.edu.tr](mailto:iyavuz@dicle.edu.tr)

**ECTODERMAL DYSPLASIA GROUP - TURKEY**

<http://www.ektodermaldisplazi.com>



1257 Accept letter for paper D20\_1366\_Dian\_Agustin\_Wahjuningrum\_Indonesia.doc  
402K

---

**agustin wahjuningrum Dian** <[dian-agustin-w@fkg.unair.ac.id](mailto:dian-agustin-w@fkg.unair.ac.id)>  
Kepada: **widya saraswati** <[widya-s@fkg.unair.ac.id](mailto:widya-s@fkg.unair.ac.id)>

25 Januari 2021 18.49

[Kutipan teks disembunyikan]



1257 Accept letter for paper D20\_1366\_Dian\_Agustin\_Wahjuningrum\_Indonesia.doc  
402K

---

**D20\_1366\_Dian\_Agustin\_Wahjuningrum\_Indonesia 2021;14(2)**

1 pesan

---

izzet yavuz <izzetyavuz@hotmail.com>

29 Januari 2021 23.05

Kepada: agustin wahjuningrum Dian <dian-agustin-w@fkg.unair.ac.id>

Dear **Prof. Dr. Dian Agustin Wahjuningrum**,

Thank you very much for complete to the publication process.

Your article " **The Effect of Exposure Calcium Carbonat From Blood Cockle (Anadara Granosa) Shells To The Expression Of The NF- $\kappa$  $\beta$  On Dentin Pulp Complex** ", will be publish at the for issue 2021; volume 14 number 2 which will be released either late **June 2021 or early July 2021.**

Before sending manuscript to press, I will send to you the press ready copy for your final checking.

Sincerely yours.

**Prof. Dr. Izzet YAVUZ**

**Editor-in-Chief and General Director**

**Journal of International Dental and Medical Research ISSN 1309 - 100X**

**<http://www.jidmr.com/journal/>**

**MSc, PhD, Professor, Pediatric Dentistry**

**Dicle Üiversity, Faculty of Dentistry**

**21280 Diyarbakir, TURKEY**

**E-mail: izzetyavuz@hotmail.com, iyavuz@dicle.edu.tr**

**ECTODERMAL DYSPLASIA GROUP - TURKEY**

**<http://www.ektodermaldisplazi.com>**

# The Effect of Exposure Calcium Carbonat From Blood Cockle (*Anadara Granosa*) Shells To The Expression Of The NF- $\kappa$ B On Dentin Pulp Complex

Widya Saraswati<sup>1</sup>, Nina Dhaniar<sup>2</sup>, Dian Agustin Wahjuningrum<sup>1</sup>, Nunik Nuraini<sup>2</sup>, Anuj Bhardwaj<sup>3,4</sup>

<sup>1</sup>Staff Department of Conservative Dentistry, Faculty of Dental Medicine, Universitas Airlangga

<sup>2</sup>Student of Specialistic Program of Conservative Dentistry, Faculty of Dental Medicine, Universitas Airlangga

<sup>3</sup>Diplomate, Indian Board of Endodontic. Professor & Post Graduate Guide, Department of Conservative Dentistry and Endodontics, College of Dental Science and Hospital, Rau-Indore, India.

<sup>4</sup>Adjunct Professor at Department of Conservative Dentistry, Faculty of Dental Medicine, Universitas Airlangga, Surabaya, Jawa Timur, Indonesia

Corresponding Author: Dian Agustin Wahjuningrum, Staff of Conservative Dentistry Departement, Faculty of Dental Medicine, Universitas Airlangga, Jl. Prof. DR. Moestopo No 47, Surabaya 60132, Indonesia. E-mail: dian-agustin-w@fkg.unair.ac.id

## INTRODUCTION

Caries is one of the most clinical cases found in Conservative and Endodontic Clinic of RSGMP FKG Universitas Airlangga. Raharjo (2016) found 105 caries cases of 169 men (62.13%) and 146 cases of 251 women (58.17%) in 420 RSGMP FKG Universitas Airlangga patients<sup>1</sup>. Pulpitis reversible is a clinical diagnosis of a mild to moderate pulp inflammation caused by a stimulus, that the pulp can reverse back to its normal condition when the stimulus was removed. Large caries teeth diagnosed in pulpitis reversible need a pulp protective material that has the anti-inflammation trait and good biocompatibility<sup>2</sup>.

One of the treatments done in pulpitis reversible is pulp capping. Pulp capping aims to preserve the vitality of the pulp. Calcium hydroxide has been considered the gold standard for pulp capping materials for decades. Calcium hydroxide will stimulate the formation of tertiary dentin, which can protect the pulp with the newly formed hard tissues<sup>3</sup>. Calcium hydroxide has antibacterial properties from the breaking down calcium and hydroxyl. The hydroxyl ion has a high pH which can cause the death of bacteria in the cavity<sup>4</sup>. However, calcium hydroxide has a weakness, that it dissolves easily in oral cavity fluid. The fluid from the oral cavity can dissolve calcium hydroxide when it reacts with it and creates a tunnel defect. The tunnel defect can increase the risk of marginal leakage and sensitivity of the pulp<sup>5</sup>.

Blood clam (*Anadara granosa*) is an economic resource and it is easy to find in Indonesia. All minerals contained in the blood clamshells are 98.7% calcium carbonate, 0.05% Mg, 0.9% Na, 0.02% P and 0,2% others. There is a high content of calcium carbonate (CaCO<sub>3</sub>) in the blood clamshells. It is a source of calcium and it has good biocompatibility to be used as a bone repair material. Calcium carbonate is insoluble in water and it gives negative results in in-vitro genotoxicity studies<sup>6</sup>. Calcium carbonate that was synthesized by hydrothermal process produced 72% hydroxyapatite (HA) and 21% Tricalcium Phosphate (TCP). Therefore, the blood clamshells are expected to be an alternative pulp protective material for initiating the dentin tissue deposition so that the healing process occurs by the formation of reactionary dentin. The blood clamshells have anti-inflammatory properties and good biocompatibility, good strength and stability in the wet dentine filled with intratubular fluid.

Dentin which is mechanically traumatized, will increase the Nuclear Factor – Kappa Beta (NF- $\kappa$ B) in the nucleus. It stimulates and increases the production of pro-inflammatory cytokines.

NF- $\kappa$ B can induce cytokines that regulate the immune responses such as Interleukin – 1 Beta (IL- 1 $\beta$ ) and other adhesive molecules that stimulate the movement of leukocytes into the inflamed area so that it can prolong the pulp healing process if it is not controlled<sup>6</sup>. Acute inflammation is an essential step in initiating the healing process. Inflammation which is not handled properly can lead into chronic inflammation. NF- $\kappa$ B will be found in the acute inflammatory phase, 0-3 days after the injury occurs. The NF- $\kappa$ B level can regulate the inflammatory response so that the process can continue to become chronic which also affects the expression of IL-1 $\beta$ <sup>8</sup>. Mild or moderate intensity injury will be responded by a brief inflammatory response followed by reactionary dentinogenesis. Although the level of dentin secretion is reduced in adult teeth, the metabolic activity of odontoblasts can be regulated in response to injury.

In the previous studies, blood clam shell extract was shown to have the highest cell bioavailability at 6.75 mg/ml and the lowest at 54 mg/ml<sup>9</sup>. Other research states that blood clam shells derived bone graft is effective in accelerating the healing process of alveolar bones after tooth extraction<sup>10</sup>, but there is no research yet on the role of blood clam shells derived calcium carbonate in the process of pulp inflammation. Thus, this study is expected to reveal the expression of NF- $\kappa$ B, in odontoblast on day 1, 3 and 7 after administration of blood clam shells derived calcium carbonate, so that blood clamshells can be considered as an alternative pulp protecting material in large carious lesions.

## **MATERIAL AND METHODS**

This study was approved by the Health Research Ethical Clearance Commission of Faculty of Dental Medicine Universitas Airlangga (255/HRECC.FODM/V/2020). The preliminary study was done to determine the amount of the blood clamshells derived calcium carbonate (powder) and aquades (liquid) to be mixed for the main research. 10 samples of blood clamshells derived calcium carbonate divided into 5 groups. Group A, the mixture ratio of powder and liquid is 1:1, Group B 2:1, Group C 3:1, Group D 3:2, and Group E 4:1. The blood clam shell extract and aquades were mixed and the setting time was recorded.

The samples of this study were 30 *Rattus norvegicus strain wistar* rats in randomized post- test only control groups. The rats had to be male, healthy and weight 300-350g. The rats divided into 6 groups of rats consist of 5 random samples each. Each of the rats was given 0,2cc/kg combine anaesthesia of Ketamine HCl and Diazepam (100mg:10mg). Cavity preparation is performed in the occlusal side of the right upper molar using 0,84mm low-speed diamond bur. The depth of the preparation should be around 1mm. Group 1-3, the control group, was treated with Resin Modified Glass Ionomer Cement/RMGIC (Cention N, Ivoclar Vivadent, Liechtenstein) without calcium carbonate application. Group 4-6, the experimental group, were treated with blood clamshells derived calcium carbonate suspension and sealed with RMGIC. The

calcium carbonate suspension was smeared into the cavity using a fine micro brush. The teeth in each group were extracted after 1, 3 and 7 days accordingly.

The rats were euthanized and the right maxilla bones were removed around 12mm. the teeth were immersed in 10% buffered formalin solution for 24 hours. After 24 hours, the solution was replaced with ethylene-diamine tetra acetic acid (EDTA) and renewed every day for 60 days at room temperature, for the decalcification. The teeth then washed with Phosphate Buffer saline (PBS) 3-5 times to clean from contamination then fixased to 10% formalin. The paraffin block was cut by a rotary microtome as thick as 6µm and then it was incubated. The HE and immunohistochemical staining using anti NF-κβ p65 antibody monoclonal. The slides were counterstained, mounted and sealed using cover glass and observed under a light microscope.

## RESULTS

Table 1. Ratio and Setting time

| Groups | Powder: Liquid Ratio | Mixed/ Not Mixed | Consistency          | Setting time |
|--------|----------------------|------------------|----------------------|--------------|
| A      | 1:1                  | mixed            | watery               | No setting   |
| B      | 2:1                  | mixed            | watery               | No setting   |
| C      | 3:1                  | mixed            | Soluble (mixed well) | 26 seconds   |
| D      | 3:2                  | mixed            | Soluble (mixed well) | 17 minutes   |
| E      | 4:1                  | not mixed        | not mixed            | No setting   |

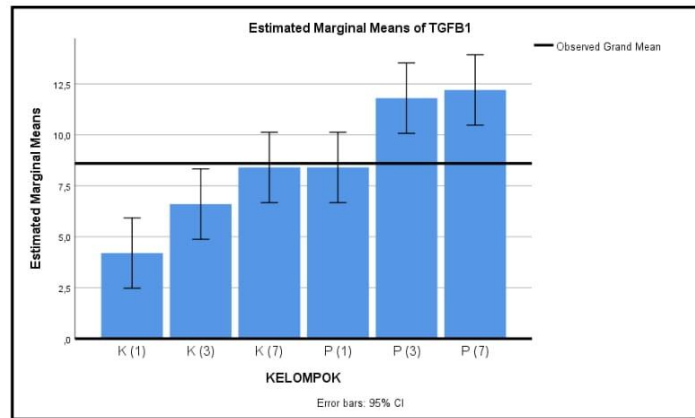
The research data shows the setting time of each group. In research groups A and B, the mixing that occurred showed a consistency that was watery, so it could not be set. For groups C and D, the perfect mixing was achieved with an average setting time of 26 seconds and 17 minutes. Group E did not have perfect mixing because less liquid.

The expression of NF-κβ p65, shown in Table 2 in Mean and standar deviation and Bar Charts in Figure 1

Table 2. The expression of NF-κβ p65

| Expressions | Variable       | n | Mean ± SD     | Min – Max |
|-------------|----------------|---|---------------|-----------|
| NF-κβ p65   | Control (+) D1 | 5 | 4,20 + 2.608  | 5 – 11    |
|             | Control (+) D3 | 5 | 6,60 + 2.608  | 9 – 16    |
|             | Control (+) D7 | 5 | 8,40 + 1.817  | 12 – 16   |
|             | CaCO3 D1       | 5 | 8,40 + 1.225  | 2 – 5     |
|             | CaCO3 D3       | 5 | 11,80 + 1.225 | 3 – 7     |
|             | CaCO3 D7       | 5 | 12,20 + 1.517 | 4 – 8     |

Fig 1. Mean and SD of NF- $\kappa$ B p65

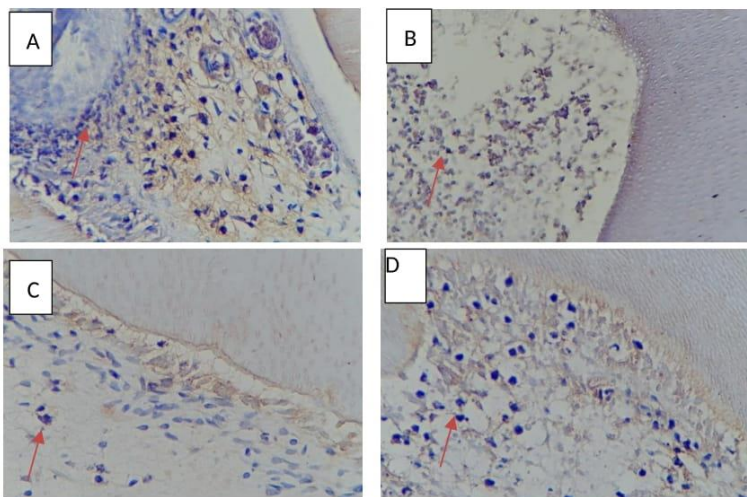


Initial data analysis carried out was the data normality test to determine whether the data were normally distributed or not analytically using the Kolmogorov-Smirnov test (sample > 50) or Shapiro Wilk (sample  $\leq$  50). Based on the normality test data for Shapiro Wilk for NF- $\kappa$ B p65, control group and CaCO<sub>3</sub> treatment on days 1, 3, and 7 obtained  $p > 0.05$ . so it can be concluded that all of these data are normally distributed. Furthermore, the homogeneity test was carried out using the Levene test to determine whether the data variants were homogeneous or heterogeneous. This test is also needed to determine further data analysis using parametric or non-parametric tests. Based on the results of the Levene test, the data is considered homogeneous if  $p > 0.05$ . In this study, the results obtained consecutively on the 1st, 3rd and 7th day with  $p > 0.05$  for NF- $\kappa$ B p65. Based on the results of the data normality test and the homogeneity of the NF- $\kappa$ B p65, the data were obtained with normal and homogeneous distributions, so that the next statistical test was carried out using the parametric test.

Table 10. Significant Value of NF- $\kappa$ B p65 on Tukey HSD Test

| Groups               | Control (+)<br>Day 1 | Control (+)<br>Day 3 | Control (+)<br>Day 7 | CaCO3<br>Day 1 | CaCO3<br>Day 3 | CaCO3<br>Day 7 |
|----------------------|----------------------|----------------------|----------------------|----------------|----------------|----------------|
| Control (+)<br>Day 1 | -                    | 0.007*               | 0.000*               | 0.014*         | 0.425          | 0.616          |
| Control (+)<br>Day 3 | 0.007*               | -                    | 0.712                | 0,000*         | 0,000*         | 0,000*         |
| Control (+)<br>Day 7 | 0.000*               | 0.712                | -                    | 0,000*         | 0,000*         | 0,000*         |
| CaCO3<br>Day 1       | 0.014*               | 0,000*               | 0,000*               | -              | 0.519          | 0.340          |
| CaCO3<br>Day 3       | 0.425                | 0,000*               | 0,000*               | 0.519          | -              | 1.000          |
| CaCO3<br>Day 7       | 0.616                | 0,000*               | 0,000*               | 0.340          | 1.000          | -              |

Based on Table 10 the p value for comparison of NF- $\kappa$ B p65 expression between the control (+) and CaCO3 treatment groups on day 1 is 0.014; 3rd 0.000; 7th 0.000. These results indicate that there is a significant difference between the control (+) and CaCO3 treatment groups on days 1, 3 and 7 with a significance value of  $p < 0.05$ .



NF- $\kappa$ B p65 expression by immunohistochemistry examination at 400x magnification. The red arrow show the cells that positively express NF- $\kappa$ B p65, purple and round shape (A : control group, B: Treatment group at day-1 ; C: treatment group at day-3 ; D: treatment group at day-7)

## DISCUSSION

In this study, there were significant differences between each group in which the expression of NF- $\kappa$ B was higher in the control group compared to the calcium carbonate treatment group. The high expression of NF- $\kappa$ B in the control group could be caused by injury caused by the resin content of RMGIC contacting the cavities directly. When the tooth is being prepared, there will be an inflammatory process in the odontoblast cells as a response to the tooth's defense. Reactive Oxygen Species (ROS) are produced for physiological purposes by leukocytes and macrophages in the body's defense mechanisms. At physiological pH, superoxide is rapidly dismutated to hydrogen peroxide (H<sub>2</sub>O<sub>2</sub>) by superoxide dismutase. Hydrogen peroxide is a biologically active ROS. Hydrogen peroxide can activate transcription factors by separating the NF- $\kappa$ B bonds and Kappa Beta Inhibitor (I $\kappa$ B). NF- $\kappa$ B is a transcription factor that regulates the transcription of many genes that play a role in immune and inflammatory responses. NF- $\kappa$ B has an important role in immune and inflammatory responses through the regulation of genes responsible for producing pro-inflammatory cytokines, adhesion molecules, chemokines, growth factors, inducible enzymes, such as cyclo-oxygenase 2 (COX2), and inducible nitric oxide synthase (iNOS)<sup>7</sup>.

Dentin is the main hard tissue of the tooth that is formed by odontoblasts, which stem from neural crest-derived odontogenic mesenchymal cells. Odontoblasts are responsible for the production of physiological primary and secondary dentin. Odontoblasts are terminally differentiated cells that are subject to a long-lived secretory condition and mediate dentinogenic activity. Reactionary dentin is formed as an adaptive secretory response when the occurrence of moderate dentin injury stimulates odontoblast generation. Tertiary dentinogenesis can occur in response to tissue injury, and data indicate that infection and inflammation strongly impact on the repair processes within the dental tissue. Reactionary dentinogenesis occurs in response to a relatively mild dental tissue injury, such as during the earlier stages of dental caries, and odontoblasts lining the pulp chamber and root canal survive and up-regulate their synthetic and secretory activity. The link between inflammation and regeneration is potentially derived from the mode of action of restorative materials that promote regenerative events. Both calcium hydroxide and MTA are known to stimulate tertiary dentin bridge formation, and preceding the healing process. NF- $\kappa$ B can be expressed in the acute inflammatory phase, 0-3 days after the injury occurs, and regulate the inflammatory response so that the inflammatory process can continue to become regenerative stage<sup>8</sup>. Upregulated of NF- $\kappa$ B after exposure of calcium carbonate will increase and lead the odontoblast pulp cell to generate reactionary dentinogenesis which may also facilitate release of bioactive components from dentin extra cellular matrix to promote tissue repair<sup>11</sup>. Some studies showed that NF- $\kappa$ B is the key signaling pathways in the



proinflammatory and healing responses. To enhance bone formation in vivo, biomaterials such as hydroxyapatite (HA), tricalcium phosphates (TCP), or biphasic calcium phosphates (BCP), a mixture of HA and TCP, are frequently used as scaffolds for bone grafting. All these materials, include calcium carbonate are highly enriched with Ca and their capacity to induce bone formation seems to differ depending on the amount of Ca. Mizuno *et al* showed Ca released from CH stimulated fibronectin gene expression in dental pulp cells, a mechanism that may induce differentiation of these cells to become mineralized tissue forming cells. Pulp–dentin tissue regeneration is the series of healing progression from an inflammatory response, immune signaling, and cellular interaction accompanying tissue restoration upon infectious exposure. Application of calcium carbonate is expected to be an innovative treatment in opening up new pathways for the regenerative dentin process through regulation of NF- $\kappa$ B activation<sup>12</sup>.

## REFERENCES

1. Rahardjo, A.K., Widjiastuti, I., Prasetyo, E.A. Prevalensi Karies Gigi Posterior Berdasarkan Kedalaman, Usia dan Jenis Kelamin di RSGM FKG UNAIR Tahun 2014. Prevalence of Posterior Teeth Caries by The Depth of Cavity, Age and Gender at RSGM FKG UNAIR in 2014. *Conservative Dentistry Journal* 2016;6(2): 7–12
2. Garg, N. dan Garg, A. *Textbook of Operative Dentistry*. 3rd ed. New Delhi: Jaypee Brothers Medical Publishers; 2015:220-4
3. Laslami, K., Dhomm, S., Karami, M., et al. Direct Pulp Capping with Bioactive Material: Biodentine. *Econicon Dental Science* 2017;13(2): 75–83.
4. Arandi, N.Z. Calcium Hydroxide Liners: A Literature Review. *Clinical, Cosmetic and Investigational Dentistry* 2017;9:67–72
5. Noort, R.V. *Introduction to Dental Materials*. 4th ed. Edinburgh: Mosby Elsevier; 2013;108, 118, 128-30.
6. Al Omari, M.M.H., Rashid, I.S., Qinna, N.A., et al. Calcium Carbonate. *Profiles of Drug Substances, Excipients, and Related Methodology* 2016;41:131-2.
7. Nirwana, I., Agustantina, T.H., Soekartono, R.H. NF- $\kappa$ B Expressions on Rat Dental Pulp Mechanically Exposed After Pomegranate Fruit Extract Administration. *Journal of International Dental and Medical Research* 2017;10(1): 123–7.
8. Lin, T.H., Pajarinen, J., Lu, L., *et al*. NF- $\kappa$ B as a Therapeutic Target in Inflammatory-Associated Bone Diseases. *Adv Protein Chem Struct Biol* 2017;107: 117–54.
9. Nastiti, A.D., Widyastuti, W., and Laihada, F.M. Biokompatibilitas Hidroksiapatit Ekstrak Cangkang Kerang Darah ( *Anadara granosa* ) Terhadap Sel Punca Mesenkimal Sebagai Bahan Graft Tulang Alveol. *DENTA Jurnal Kedokteran Gigi Universitas Hang Tuah Surabaya* 201;9(2): 122
10. Sari, R.P. Mekanisme Kerja Bone Graft Dari Cangkang Kerang Darah (*Anadara Granosa*) Dan Teripang Emas (*Stichopus Hermannii*) Pada Penyembuhan Tulang Alveolar Pasca Pencabutan Gigi. Program Studi Kedokteran Jenjang Doktor Fakultas Kedokteran Universitas Airlangga. Surabaya. 2018:6-12
11. Goldberg M, Six N, Decup F, *et al*. Bioactive Molecules And The Future of Pulp Therapy. *Am J Dent* 2003;16:66–76
12. Mizuno M and Banzai Y. Calcium Ion Release From Calcium Hydroxide Stimulated Fibronectin Gene Expression In Dental Pulp Cells And The Differentiation Of Dental Pulp Cells To Mineralized Tissue Forming Cells by Fibronectin. *Int Endod J* 2008;41(11):933–8.

## The Effect of Exposure Calcium Carbonat from Blood Cockle (*Anadara Granosa*) Shells to the Expression of the NF- $\kappa$ B on Dentin Pulp Complex

Widya Saraswati<sup>1</sup>, Nina Dhaniar<sup>2</sup>, Dian Agustin Wahjuningrum<sup>1\*</sup>, Nunik Nuraini<sup>2</sup>, Anuj Bhardwaj<sup>3,4</sup>

1. Staff Department of Conservative Dentistry, Faculty of Dental Medicine, Universitas Airlangga.
2. Student of Specialistic Program of Conservative Dentistry, Faculty of Dental Medicine, Universitas Airlangga.
3. Diplomate, Indian Board of Endodontic. Professor & Post Graduate Guide, Department of Conservative Dentistry and Endodontics, College of Dental Science and Hospital, Rau-Indore, India.
4. Adjunct Professor at Department of Conservative Dentistry, Faculty of Dental Medicine, Universitas Airlangga, Surabaya, Jawa Timur, Indonesia.

### Abstract

Calcium hydroxide as the gold standard pulp capping material, has a weakness, that it dissolves easily in oral cavity fluid. It creates a tunnel defect and increase the risk of sensitivity of the pulp. Blood clam (*Anadara granosa*) is an economic resource and easy to find in Indonesia. The blood clam shells, which is high content of calcium carbonate ( $\text{CaCO}_3$ ), have anti-inflammatory properties and good biocompatibility, good strength and stability in the wet dentine. Therefore, the blood clamshells are expected to be an alternative pulp protective material for initiating the dentin tissue deposition so that the healing process occurs by the formation of reactionary dentin.

This study is expected to reveal the expression of NF- $\kappa$ B, in odontoblast after administration of blood clam shells derived calcium carbonate, so that blood clamshells can be considered as an alternative pulp protecting material in large carious lesions.

The samples of this study were 30 *Rattus norvegicus* strain wistar rats divided into 6 groups of rats consist of 5 random samples each. Cavity preparation around 1 mm is performed in the occlusal side of the right upper molar of rats. Group 1-3, the control group, was treated with RMGIC without calcium carbonate application. Group 4-6, the experimental group, were treated with blood clam shells derived calcium carbonate suspension and sealed with RMGIC. The teeth in each group were extracted after 1, 3 and 7 days accordingly then preparat slide was made. The HE and immunohistochemical stained using anti NF- $\kappa$ B p65 antibody monoclonal. The slides were counterstained, mounted and sealed using cover glass and observed under a light microscope.

There were significant differences between each group in which the expression of NF- $\kappa$ B was higher in the control group compared to the calcium carbonate treatment group.

Application of calcium carbonat from blood cockle (*Anadara Granosa*) shells decrease the expression of the NF- $\kappa$ B. It showed that calcium carbonat induced the healing process, triggered and led the odontoblast pulp cell to generate reactionary dentinogenesis by decreasing the NF- $\kappa$ B number.

Experimental article (J Int Dent Med Res 2021; 14(2): 549-553)

**Keywords:** Blood cockle shells, calcium carbonat, NF- $\kappa$ B, inflammation, healing process, odontoblast, dentin tertiary.

**Received date:** 08 December 2020

**Accept date:** 24 January 2021

### Introduction

Caries is one of the most clinical cases found in Conservative and Endodontic Clinic of RSGMP FKG Universitas Airlangga. Raharjo

(2016) found 105 caries cases of 169 men (62.13%) and 146 cases of 251 women (58.17%) in 420 RSGMP FKG Universitas Airlangga patients<sup>1</sup>. Pulpitis reversible is a clinical diagnosis of a mild to moderate pulp inflammation caused by a stimulus, that the pulp can reverse back to its normal condition when the stimulus was removed. Large caries teeth diagnosed in pulpitis reversible need a pulp protective material that has the anti-inflammation trait and good biocompatibility<sup>2</sup>.

#### \*Corresponding author:

Dian Agustin Wahjuningrum,  
Staff of Conservative Dentistry Departement, Faculty of Dental  
Medicine, Universitas Airlangga, Jl. Prof. DR. Moestopo No 47,  
Surabaya 60132, Indonesia.  
E-mail: dian-agustin-w@fkg.unair.ac.id

One of the treatments done in pulpitis reversible is pulp capping. Pulp capping aims to preserve the vitality of the pulp. Calcium hydroxide has been considered the gold standard for pulp capping materials for decades. Calcium hydroxide will stimulate the formation of tertiary dentin, which can protect the pulp with the newly formed hard tissues<sup>3</sup>. Calcium hydroxide has antibacterial properties from the breaking down calcium and hydroxyl. The hydroxyl ion has a high pH which can cause the death of bacterias in the cavity<sup>4</sup>. However, calcium hydroxide has a weakness, that it dissolves easily in oral cavity fluid. The fluid from the oral cavity can dissolve calcium hydroxide when it reacts with it and creates a tunnel defect. The tunnel defect can increase the risk of marginal leakage and sensitivity of the pulp<sup>5</sup>.

Blood clam (*Anadara granosa*) is an economic resource and it is easy to find in Indonesia. All minerals contained in the blood clamshells are 98.7% calcium carbonate, 0.05% Mg, 0.9% Na, 0.02% P and 0,2% others. There is a high content of calcium carbonate (CaCO<sub>3</sub>) in the blood clamshells. It is a source of calcium and it has good biocompatibility to be used as a bone repair material. Calcium carbonate is insoluble in water and it gives negative results in in-vitro genotoxicity studies<sup>6</sup>. Calcium carbonate that was synthesized by hydrothermal process produced 72% hydroxyapatite (HA) and 21% Tricalcium Phosphate (TCP). Therefore, the blood clamshells are expected to be an alternative pulp protective material for initiating the dentin tissue deposition so that the healing process occurs by the formation of reactionary dentin. The blood clamshells have anti-inflammatory properties and good biocompatibility, good strength and stability in the wet dentine filled with intratubular fluid.

Dentin which is mechanically traumatized, will increase the Nuclear Factor – Kappa Beta (NF- $\kappa$ B) in the nucleus. It stimulates and increases the production of pro-inflammatory cytokines.

NF- $\kappa$ B can induce cytokines that regulate the immune responses such as Interleukin – 1 Beta (IL- 1 $\beta$ ) and other adhesive molecules that stimulate the movement of leukocytes into the inflamed area so that it can prolong the pulp healing process if it is not controlled<sup>6</sup>.

Acute inflammation is an essential step in initiating the healing process. Inflammation which is not handled properly can lead into chronic inflammation. NF- $\kappa$ B will be found in the acute inflammatory phase, 0-3 days after the injury occurs. The NF- $\kappa$ B level can regulate the inflammatory response so that the process can continue to become chronic which also affects the expression of IL-1 $\beta$ <sup>8</sup>. Mild or moderate intensity injury will be responded by a brief inflammatory response followed by reactionary dentinogenesis. Although the level of dentin secretion is reduced in adult teeth, the metabolic activity of odontoblasts can be regulated in response to injury.

In the previous studies, blood clam shell extract was shown to have the highest cell bioavailability at 6.75 mg/ml and the lowest at 54 mg/ml<sup>9</sup>. Other research states that blood clam shells derived bone graft is effective in accelerating the healing process of alveolar bones after tooth extraction<sup>10</sup>, but there is no research yet on the role of blood clam shells derived calcium carbonate in the process of pulp inflammation. Thus, this study is expected to reveal the expression of NF- $\kappa$ B, in odontoblast on day 1, 3 and 7 after administration of blood clam shells derived calcium carbonate, so that blood clamshells can be considered as an alternative pulp protecting material in large carious lesions.

## Materials and methods

This study was approved by the Health Reasearch Ethical Clearance Commision of Faculty of Dental Medicine Universitas Airlangga (255/HRECC.FODMM/2020). The preliminary study was done to determine the amount of the blood clamshells derived calcium carbonate (powder) and aquades (liquid) to be mixed for the main research. 10 samples of blood clamshells derived calcium carbonate divided into 5 groups. Group A, the mixture ratio of powder and liquid is 1:1, Group B 2:1, Group C 3:1, Group D 3:2, and Group E 4:1. The blood clam shell extract and aquades were mixed and the setting time was recorded.

The samples of this study were 30 *Rattus norvegicus* strain wistar rats in randomized post- test only control groups. The rats had to be male, healthy and weight 300-350g. The rats divided into 6 groups of rats consist of 5 random samples each. Each of the rats was given 0,2cc/kg combine anaesthesia of

Ketamine HCl and Diazepam (100mg:10mg). Cavity preparation is performed in the occlusal side of the right upper molar using 0,84mm low-speed diamond bur. The depth of the preparation should be around 1mm. Group 1-3, the control group, was treated with Resin Modified Glass Ionomer Cement/RMGIC (Cention N, Ivoclar Vivadent, Liechtenstein) without calcium carbonate application. Group 4-6, the experimental group, were treated with blood clamshells derived calcium carbonate suspension and sealed with RMGIC.

The calcium carbonate suspension was smeared into the cavity using a fine micro brush. The teeth in each group were extracted after 1, 3 and 7 days accordingly.

The rats were euthanized and the right maxilla bones were removed around 12mm. the teeth were immersed in 10% buffered formalin solution for 24 hours. After 24 hours, the solution was replaced with ethylene-diamine tetra acetic acid (EDTA) and renewed every day for 60 days at room temperature, for the decalcification. The teeth then washed with Phosphate Buffer saline (PBS) 3-5 times to clean from contamination then fixated to 10% formalin. The paraffin block was cut by a rotary microtome as thick as 6µm and then it was incubated. The HE and immunohistochemical staining using anti NF-κβ p65 antibodi monoclonal. The slides were counterstained, mounted and sealed using cover glass and observed under a light microscope.

**Results**

| Groups | Powder: Liquid Ratio | Mixed/ Not Mixed | Consistency          | Setting time |
|--------|----------------------|------------------|----------------------|--------------|
| A      | 1:1                  | mixed            | watery               | No setting   |
| B      | 2:1                  | mixed            | watery               | No setting   |
| C      | 3:1                  | mixed            | Soluble (mixed well) | 26 seconds   |
| D      | 3:2                  | mixed            | Soluble (mixed well) | 17 minutes   |
| E      | 4:1                  | not mixed        | not mixed            | No setting   |

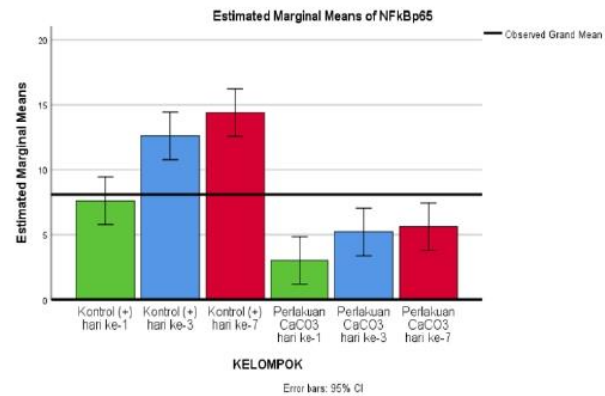
**Table 1.** Ratio and Setting time.

The research data shows the setting time of each group. In research groups A and B, the mixing that occurred showed a consistency that was watery, so it could not be set. For groups C and D, the perfect mixing was achieved with an average setting time of 26 seconds and 17 minutes. Group E did not have perfect mixing because less liquid.

The expression of NF-κβ p65, shown in Table 2 in Mean and standar deviation and Bar Charts in Figure 1.

| Expressions | Variable             | n | Mean  | ± SD    | Min – Max |
|-------------|----------------------|---|-------|---------|-----------|
| NF-κβ p65   | Control (+) D1       | 5 | 7.60  | + 2.608 | 5 – 11    |
|             | Control (+) D3       | 5 | 12.60 | + 2.702 | 9 – 16    |
|             | Control (+) D7       | 5 | 14.40 | + 1.817 | 12 – 16   |
|             | CaCO <sub>3</sub> D1 | 5 | 3.00  | + 1.225 | 2 – 5     |
|             | CaCO <sub>3</sub> D3 | 5 | 5.20  | + 1.643 | 3 – 7     |
|             | CaCO <sub>3</sub> D7 | 5 | 5.60  | + 1.517 | 4 – 8     |

**Table 2.** The expression of NF-κβ p65.



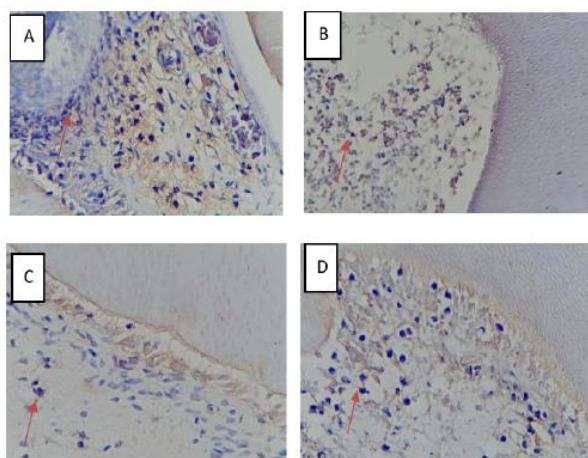
**Figure 1.** Mean and SD of NF-κβ p65.

Initial data analysis carried out was the data normality test to determine whether the data were normally distributed or not analytically using the Kolmogorov-Smirnov test (sample > 50) or Shapiro Wilk (sample ≤ 50). Based on the normality test data for Shapiro Wilk for NF-κβ p65, control group and CaCO<sub>3</sub> treatment on days 1, 3, and 7 obtained p > 0.05. so it can be concluded that all of these data are normally distributed. Furthermore, the homogeneity test was carried out using the Levene test to determine whether the data variants were homogeneous or heterogeneous. This test is also needed to determine further data analysis using parametric or non-parametric tests. Based on the results of the Levene test, the data is considered homogeneous if p > 0.05. In this study, the results obtained consecutively on the 1st, 3rd and 7th day with p > 0.05 for NF-κβ p65. Based on the results of the data normality test and the homogeneity of the NF-κβ p65, the data were obtained with normal and homogeneous distributions, so that the next statistical test was carried out using the parametric test.

| Groups                     | Control (+)<br>Day 1 | Control (+)<br>Day 3 | Control (+)<br>Day 7 | CaCO <sub>3</sub><br>Day 1 | CaCO <sub>3</sub><br>Day 3 | CaCO <sub>3</sub><br>Day 7 |
|----------------------------|----------------------|----------------------|----------------------|----------------------------|----------------------------|----------------------------|
| Control (+)<br>Day 1       | -                    | 0.007*               | 0.000*               | 0.014*                     | 0.425                      | 0.616                      |
| Control (+)<br>Day 3       | 0.007*               | -                    | 0.712                | 0,000*                     | 0,000*                     | 0,000*                     |
| Control (+)<br>Day 7       | 0.000*               | 0.712                | -                    | 0,000*                     | 0,000*                     | 0,000*                     |
| CaCO <sub>3</sub><br>Day 1 | 0.014*               | 0,000*               | 0,000*               | -                          | 0.519                      | 0.340                      |
| CaCO <sub>3</sub><br>Day 3 | 0.425                | 0,000*               | 0,000*               | 0.519                      | -                          | 1.000                      |
| CaCO <sub>3</sub><br>Day 7 | 0.616                | 0,000*               | 0,000*               | 0.340                      | 1.000                      | -                          |

**Table 3.** Significant Value of NF-κβ p65 on Tukey HSD Test.

Based on Table 10 the p value for comparison of NF-κβ p65 expression between the control (+) and CaCO<sub>3</sub> treatment groups on day 1 is 0.014; 3rd 0.000; 7th 0.000. These results indicate that there is a significant difference between the control (+) and CaCO<sub>3</sub> treatment groups on days 1, 3 and 7 with a significance value of  $p < 0.05$ .



**Figure 2.** NF-κβ p65 expression by immunohistochemistry examination at 400x magnification. The red arrow show the cells that positively express NF-κβ p65, purple and round shape (A : control group, B: Treatment group at day-1 ; C: treatment group at day-3 ; D: treatment group at day-7).

NF-κβ p65 expression by immunohistochemistry examination at 400x magnification. The red arrow show the cells that positively express NF-κβ p65, purple and round shape (A : control group, B: Treatment group at day-1; C: treatment group at day-3; D: treatment group at day-7)

### Discussion

In this study, there were significant differences between each group in which the expression of NF-κβ was higher in the control group compared to the calcium carbonate treatment group. The high expression of NF-κβ in the control group could be caused by injury caused by the resin content of RMGIC contacting the cavities directly. When the tooth is being prepared, there will be an inflammatory process in the odontoblast cells as a response to the tooth's defense. Reactive Oxygen Species (ROS) are produced for physiological purposes by leukocytes and macrophages in the body's defense mechanisms. At physiological pH, superoxide is rapidly dismutase to hydrogen peroxide (H<sub>2</sub>O<sub>2</sub>) by superoxide dismutase. Hydrogen peroxide is a biologically active ROS. Hydrogen peroxide can activate transcription factors by separating the NF-κβ bonds and Kappa Beta Inhibitor (I $\kappa$ B). NF-κβ is a transcription factor that regulates the transcription of many genes that play a role in immune and inflammatory responses. NF-κβ has an important role in immune and inflammatory responses through the regulation of genes responsible for producing pro-inflammatory cytokines, adhesion molecules, chemokines, growth factors, inducible enzymes, such as cyclo-oxygenase 2 (COX2), and inducible nitric oxide synthase (iNOS)<sup>7</sup>.

Dentin is the main hard tissue of the tooth that is formed by odontoblasts, which stem from neural crest-derived odontogenic mesenchymal cells. Odontoblasts are responsible for the production of physiological primary and secondary dentin. Odontoblasts are terminally differentiated cells that are subject to a long-lived secretory condition and mediate dentinogenic activity. Reactionary dentin is formed as an adaptive secretory response when the occurrence of moderate dentin injury stimulate odontoblast generation.

Tertiary dentinogenic can occur in response to tissue injury, and data indicate that infection and inflammation strongly impact on the repair processes within the dental tissue. Reactionary dentinogenesis occurs in response to a relatively mild dental tissue injury, such as during the earlier stages of dental caries, and odontoblasts lining the pulp chamber and root canal survive and up-regulate their synthetic and secretory activity. The link between inflammation and regeneration is potentially derived from the mode of action of restorative materials that promote regenerative events. Both calcium hydroxide and MTA are known to stimulate tertiary dentin bridge formation, and preceding the healing process. NF- $\kappa$ B can be expressed in the acute inflammatory phase, 0-3 days after the injury occurs, and regulate the inflammatory response so that the inflammatory process can continue to become regenerative stage<sup>8</sup>. Decreasing numbers of NF- $\kappa$ B after exposure of calcium carbonat will increase and lead the odontoblast pulp cell to generate reactionary dentinogenesis which may also facilitate release of bioactive components from dentin extra cellular matrix to promote tissue repair<sup>11</sup>. Some studies showed that NF- $\kappa$ B is the key signaling pathways in the proinflammatory and healing responses. To enhance bone formation in vivo, biomaterials such as hydroxyapatite (HA), tricalcium phosphates (TCP), or biphasic calcium phosphates (BCP), a mixture of HA and TCP, are frequently used as scaffolds for bone grafting. All these materials, include calcium carbonate are highly enriched with Ca and their capacity to induce bone formation seems to differ depending on the amount of Ca. Mizuno *et al* showed Ca released from CH stimulated fibronectin gene expression in dental pulp cells, a mechanism that may induce differentiation of these cells to become mineralized tissue forming cells. Pulp-dentin tissue regeneration is the series of healing progression from an inflammatory response, immune signaling, and cellular interaction accompanying tissue restoration upon infectious exposure. Application of calcium carbonat is expected to be an innovative treatment in opening up new pathways for the regenerative dentin process through regulation of NF- $\kappa$ B activation<sup>12</sup>.

## Conclusions

This study showed that application of calcium carbonat from blood cockle (*Anadara Granosa*) shells decrease the expression of the NF- $\kappa$ B. It showed that calcium carbonat induced the healing process, triggered and led the odontoblast pulp cell to generate reactionary dentinogenesis by decreasing the NF- $\kappa$ B number.

## Acknowledgements

The authors thank the Ministry of Research, Technology, and Higher Education, Indonesia, for financing this study.

## Declaration of Interest

The authors report no conflict of interest.

## References

1. Rahardjo, A.K., Widjastuti, I., Prasetyo, E.A. Prevalensi Karies Gigi Posterior Berdasarkan Kedalaman, Usia dan Jenis Kelamin di RSGM FKG UNAIR Tahun 2014. Prevalence of Posterior Teeth Caries by The Depth of Cavity, Age and Gender at RSGM FKG UNAIR in 2014. *Conservative Dentistry Journal* 2016;6(2): 7–12.
2. Garg, N. dan Garg, A. *Textbook of Operative Dentistry*. 3rd ed. New Delhi: Jaypee Brothers Medical Publishers; 2015:220-4.
3. Laslami, K., Dhoun, S., Karami, M., et al. Direct Pulp Capping with Bioactive Material: Biodentine. *Ecronicon Dental Science* 2017;13(2): 75–83.
4. Arandi, N.Z. Calcium Hydroxide Liners: A Literature Review. *Clinical, Cosmetic and Investigational Dentistry* 2017;9:67–72
5. Noort, R.V. *Introduction to Dental Materials*. 4th ed. Edinburgh: Mosby Elsevier; 2013;108, 118, 128-30.
6. Al Omari, M.M.H., Rashid, I.S., Qinna, N.A., et al. Calcium Carbonate. *Profiles of Drug Substances, Excipients, and Related Methodology* 2016;41:131-2.
7. Nirwana, I., Agustantina, T.H., Soekartono, R.H. NF- $\kappa$ B Expressions on Rat Dental Pulp Mechanically Exposed After Pomegranate Fruit Extract Administration. *Journal of International Dental and Medical Research* 2017;10(1): 123–7.
8. Lin, T.H., Pajarinen, J., Lu, L., et al. NF- $\kappa$ B as a Therapeutic Target in Inflammatory-Associated Bone Diseases. *Adv Protein Chem Struct Biol* 2017;107: 117–54.
9. Nastiti, A.D., Widyastuti, W., and Laihada, F.M. Biokompatibilitas Hidroksiapatit Ekstrak Cangkang Kerang Darah ( *Anadara granosa* ) Terhadap Sel Punca Mesenkimal Sebagai Bahan Graft Tulang Alveol. *DENTA Jurnal Kedokteran Gigi Universitas Hang Tuah Surabaya* 2011;9(2): 122.
10. Sari, R.P. Mekanisme Kerja Bone Graft Dari Cangkang Kerang Darah (*Anadara Granosa*) Dan Teripang Emas (*Stichopus Hermanni*) Pada Penyembuhan Tulang Alveolar Pasca Pencabutan Gigi. Program Studi Kedokteran Jenjang Doktor Fakultas Kedokteran Universitas Airlangga. Surabaya. 2018:6-12.
11. Goldberg M, Six N, Decup F, et al. Bioactive Molecules And The Future of Pulp Therapy. *Am J Dent* 2003;16:66–76.
12. Mizuno M and Banzai Y. Calcium Ion Release From Calcium Hydroxide Stimulated Fibronectin Gene Expression In Dental Pulp Cells And The Differentiation Of Dental Pulp Cells To Mineralized Tissue Forming Cells by Fibronectin. *Int Endod J* 2008;41(11):933–8.