

# The Effect of Exposure Calcium Carbonat from Blood Cockle (Anadara Granosa) Shells to the Expression of the NF- $\kappa$ $\beta$ on Dentin Pulp Complex

*by Dian Agustin Wahjuningrum*

---

**Submission date:** 18-Nov-2021 12:51PM (UTC+0800)

**Submission ID:** 1706299776

**File name:** 16-D20\_1366\_Dian\_Agustin\_Wahjuningrum\_Indonesia.pdf (927.7K)

**Word count:** 3110

**Character count:** 16784

## The Effect of Exposure Calcium Carbonat from Blood Cockle (*Anadara Granosa*) Shells to the Expression of the NF- $\kappa$ B on Dentin Pulp Complex

Widya Saraswati<sup>1</sup>, Nina Dhaniar<sup>2</sup>, Dian Agustin Wahjuningrum<sup>1\*</sup>, Nunik Nuraini<sup>2</sup>, Anuj Bhardwaj<sup>3,4</sup>

### Abstract

Calcium hydroxide as the gold standard pulp capping material, has a weakness, that it dissolves easily in oral cavity fluid. It creates a tunnel defect and increase the risk of sensitivity of the pulp. Blood clam (*Anadara granosa*) is an economic resource and easy to find in Indonesia. The blood clam shells, which is high content of calcium carbonate ( $\text{CaCO}_3$ ), have anti-inflammatory properties and good biocompatibility, good strength and stability in the wet dentine. Therefore, the blood clamshells are expected to be an alternative pulp protective material for initiating the dentin tissue deposition so that the healing process occurs by the formation of reactionary dentin.

This study is expected to reveal the expression of NF- $\kappa$ B, in odontoblast after administration of blood clam shells derived calcium carbonate, so that blood clamshells can be considered as an alternative pulp protecting material in large carious lesions.

The samples of this study were 30 *Rattus norvegicus* strain wistar rats divided into 6 groups of rats consist of 5 random samples each. Cavity preparation around 1 mm is performed in the occlusal side of the right upper molar of rats. Group 1-3, the control group, was treated with RMGIC without calcium carbonate application. Group 4-6, the experimental group, were treated with blood clam shells derived calcium carbonate suspension and sealed with RMGIC. The teeth in each group were extracted after 1, 3 and 7 days accordingly then preparat slide was made. The HE and immunohistochemical stained using anti NF- $\kappa$ B p65 antibody monoclonal. The slides were counterstained, mounted and sealed using cover glass and observed under a light microscope.

There were significant differences between each group in which the expression of NF- $\kappa$ B was higher in the control group compared to the calcium carbonate treatment group.

Application of calcium carbonat from blood cockle (*Anadara Granosa*) shells decrease the expression of the NF- $\kappa$ B. It showed that calcium carbonat induced the healing process, triggered and led the odontoblast pulp cell to generate reactionary dentinogenesis by decreasing the NF- $\kappa$ B number.

Experimental article (J Int Dent Med Res 2021; 14(2): 549-553)

**Keywords:** Blood cockle shells, calcium carbonat, NF- $\kappa$ B, inflammation, healing process, odontoblast, dentin tertiary.

Received date: 08 December 2020

Accept date: 24 January 2021

### Introduction

Caries is one of the most clinical cases found in Conservative and Endodontic Clinic of RSGMP FKG Universitas Airlangga. Raharjo

(2016) found 105 caries cases of 169 men (62.13%) and 146 cases of 251 women (58.17%) in 420 RSGMP FKG Universitas Airlangga patients<sup>1</sup>. Pulpitis reversible is a clinical diagnosis of a mild to moderate pulp inflammation caused by a stimulus, that the pulp can reverse back to its normal condition when the stimulus was removed. Large caries teeth diagnosed in pulpitis reversible need a pulp protective material that has the anti-inflammation trait and good biocompatibility<sup>2</sup>.

\*Corresponding author:  
Dian Agustin Wahjuningrum,

E-mail: dian-agustin-w@fkg.unair.ac.id

One of the treatments done in pulpitis reversible is pulp capping. Pulp capping aims to preserve the vitality of the pulp. Calcium hydroxide has been considered the gold standard for pulp capping materials for decades. Calcium hydroxide will stimulate the formation of tertiary dentin, which can protect the pulp with the newly formed hard tissues<sup>3</sup>. Calcium hydroxide has antibacterial properties from the breaking down calcium and hydroxyl. The hydroxyl ion has a high pH which can cause the death of bacterias in the cavity<sup>4</sup>. However, calcium hydroxide has a weakness, that it dissolves easily in oral cavity fluid. The fluid from the oral cavity can dissolve calcium hydroxide when it reacts with it and creates a tunnel defect. The tunnel defect can increase the risk of marginal leakage and sensitivity of the pulp<sup>5</sup>.

Blood clam (*Anadara granosa*) is an economic resource and it is easy to find in Indonesia. All minerals contained in the blood clamshells are 98.7% calcium carbonate, 0.05% Mg, 0.9% Na, 0.02% P and 0,2% others. There is a high content of calcium carbonate (CaCO<sub>3</sub>) in the blood clamshells. It is a source of calcium and it has good biocompatibility to be used as a bone repair material. Calcium carbonate is insoluble in water and it gives negative results in in-vitro genotoxicity studies<sup>6</sup>. Calcium carbonate that was synthesized by hydrothermal process produced 72% hydroxyapatite (HA) and 21% Tricalcium Phosphate (TCP). Therefore, the blood clamshells are expected to be an alternative pulp protective material for initiating the dentin tissue deposition so that the healing process occurs by the formation of reactionary dentin. The blood clamshells have anti-inflammatory properties and good biocompatibility, good strength and stability in the wet dentine filled with intratubular fluid.

Dentin which is mechanically traumatized, will increase the Nuclear Factor – Kappa Beta (NF- $\kappa$ B) in the nucleus. It stimulates and increases the production of pro-inflammatory cytokines.

NF- $\kappa$ B can induce cytokines that regulate the immune responses such as Interleukin – 1 Beta (IL- 1 $\beta$ ) and other adhesive molecules that stimulate the movement of leukocytes into the inflamed area so that it can prolong the pulp healing process if it is not controlled<sup>6</sup>.

Acute inflammation is an essential step in initiating the healing process. Inflammation which is not handled properly can lead into chronic inflammation. NF- $\kappa$ B will be found in the acute inflammatory phase, 0-3 days after the injury occurs. The NF- $\kappa$ B level can regulate the inflammatory response so that the process can continue to become chronic which also affects the expression of IL-1 $\beta$ <sup>8</sup>. Mild or moderate intensity injury will be responded by a brief inflammatory response followed by reactionary dentinogenesis. Although the level of dentin secretion is reduced in adult teeth, the metabolic activity of odontoblasts can be regulated in response to injury.

In the previous studies, blood clam shell extract was shown to have the highest cell bioavailability at 6.75 mg/ml and the lowest at 54 mg/ml<sup>9</sup>. Other research states that blood clam shells derived bone graft is effective in accelerating the healing process of alveolar bones after tooth extraction<sup>10</sup>, but there is no research yet on the role of blood clam shells derived calcium carbonate in the process of pulp inflammation. Thus, this study is expected to reveal the expression of NF- $\kappa$ B, in odontoblast on day 1, 3 and 7 after administration of blood clam shells derived calcium carbonate, so that blood clamshells can be considered as an alternative pulp protecting material in large carious lesions.

## Materials and methods

This study was approved by the Health Research Ethical Clearance Commission of Faculty of Dental Medicine Universitas Airlangga (255/HRECC.FODMM/2020). The preliminary study was done to determine the amount of the blood clamshells derived calcium carbonate (powder) and aquades (liquid) to be mixed for the main research. 10 samples of blood clamshells derived calcium carbonate divided into 5 groups. Group A, the mixture ratio of powder and liquid is 1:1, Group B 2:1, Group C 3:1, Group D 3:2, and Group E 4:1. The blood clam shell extract and aquades were mixed and the setting time was recorded.

The samples of this study were 30 Rattus norvegicus strain wistar rats in randomized post-test only control groups. The rats had to be male, healthy and weight 300-350g. The rats divided into 6 groups of rats consist of 5 random samples each. Each of the rats was given 0,2cc/kg combine anaesthesia of

Ketamine HCl and Diazepam (100mg:10mg). Cavity preparation is performed in the occlusal side of the right upper molar using 0,84mm low-speed diamond bur. The depth of the preparation should be around 1mm. Group 1-3, the control group, was treated with Resin Modified Glass Ionomer Cement/RMGIC (Cention N, Ivoclar Vivadent, Liechtenstein) without calcium carbonate application. Group 4-6, the experimental group, were treated with blood clamshells derived calcium carbonate suspension and sealed with RMGIC.

The calcium carbonate suspension was smeared into the cavity using a fine micro brush. The teeth in each group were extracted after 1, 3 and 7 days accordingly.

The rats were euthanized and the right maxilla bones were removed around 12mm. the teeth were immersed in 10% buffered formalin solution for 24 hours. After 24 hours, the solution was replaced with ethylene-diamine tetra acetic acid (EDTA) and renewed every day for 60 days at room temperature, for the decalcification. The teeth then washed with Phosphate Buffer saline (PBS) 3-5 times to clean from contamination then fixased to 10% formalin. The paraffin block was cut by a rotary microtome as thick as 6µm and then it was incubated. The HE and immunohistochemical staining using anti NF-κβ p65 antibody monoclonal. The slides were counterstained, mounted and sealed using cover glass and observed under a light microscope.

**Results**

| Groups | Powder: Liquid Ratio | Mixed/ Not Mixed | Consistensy          | Setting time |
|--------|----------------------|------------------|----------------------|--------------|
| A      | 1:1                  | mixed            | watery               | No setting   |
| B      | 2:1                  | mixed            | watery               | No setting   |
| C      | 3:1                  | mixed            | Soluble (mixed well) | 26 seconds   |
| D      | 3:2                  | mixed            | Soluble (mixed well) | 17 minutes   |
| E      | 4:1                  | not mixed        | not mixed            | No setting   |

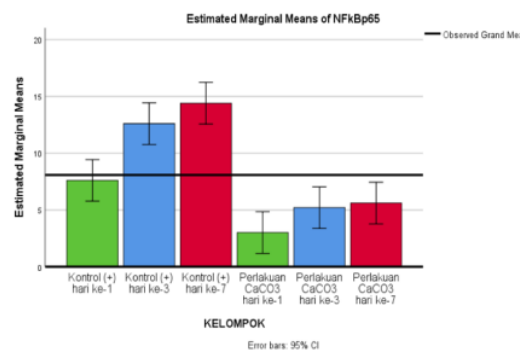
**Table 1.** Ratio and Setting time.

The research data shows the setting time of each group. In research groups A and B, the mixing that occurred showed a consistency that was watery, so it could not be set. For groups C and D, the perfect mixing was achieved with an average setting time of 26 seconds and 17 minutes. Group E did not have perfect mixing because less liquid.

The expression of NF-κβ p65, shown in Table 2 in Mean and standar deviation and Bar Charts in Figure 1.

| Expressions | Variable             | n | Mean  | ± SD    | Min – Max |
|-------------|----------------------|---|-------|---------|-----------|
| NF-κβ p65   | Control (+) D1       | 5 | 7.60  | + 2.608 | 5 – 11    |
|             | Control (+) D3       | 5 | 12.60 | + 2.702 | 9 – 16    |
|             | Control (+) D7       | 5 | 14.40 | + 1.817 | 12 – 16   |
|             | CaCO <sub>3</sub> D1 | 5 | 3.00  | + 1.225 | 2 – 5     |
|             | CaCO <sub>3</sub> D3 | 5 | 5.20  | + 1.643 | 3 – 7     |
|             | CaCO <sub>3</sub> D7 | 5 | 5.60  | + 1.517 | 4 – 8     |

**Table 2.** The expression of NF-κβ p65.



**Figure 1.** Mean and SD of NF-κβ p65.

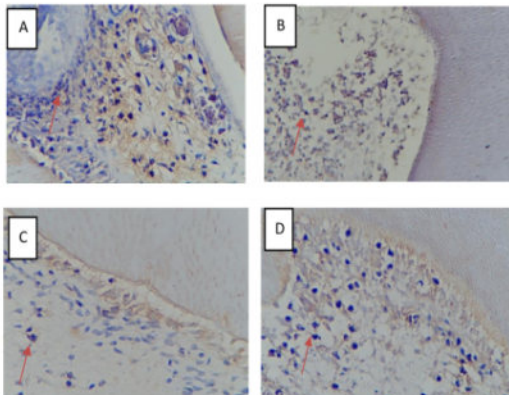
Initial data analysis carried out was the data normality test to determine whether the data were normally distributed or not analytically using the Kolmogorov-Smirnov test (sample > 50) or Shapiro Wilk (sample ≤ 50). Based on the normality test data for Shapiro Wilk for NF-κβ p65, control group and CaCO<sub>3</sub> treatment on days 1, 3, and 7 obtained p > 0.05. so it can be concluded that all of these data are normally distributed. Furthermore, the homogeneity test was carried out using the Levene test to determine whether the data variants were homogeneous or heterogeneous. This test is also needed to determine further data analysis using parametric or non-parametric tests. Based on the results of the Levene test, the data is considered homogeneous if p > 0.05. In this study, the results obtained consecutively on the 1st, 3rd and 7th day with p > 0.05 for NF-κβ p65. Based on the results of the data normality test and the homogeneity of the NF-κβ p65, the data were obtained with normal and homogeneous distributions, so that the next statistical test was carried out using the parametric test.



| Groups                     | Control (+)<br>Day 1 | Control (+)<br>Day 3 | Control (+)<br>Day 7 | CaCO <sub>3</sub><br>Day 1 | CaCO <sub>3</sub><br>Day 3 | CaCO <sub>3</sub><br>Day 7 |
|----------------------------|----------------------|----------------------|----------------------|----------------------------|----------------------------|----------------------------|
| Control (+)<br>Day 1       | -                    | 0.007*               | 0.000*               | 0.014*                     | 0.425                      | 0.616                      |
| Control (+)<br>Day 3       | 0.007*               | -                    | 0.712                | 0,000*                     | 0,000*                     | 0,000*                     |
| Control (+)<br>Day 7       | 0.000*               | 0.712                | -                    | 0,000*                     | 0,000*                     | 0,000*                     |
| CaCO <sub>3</sub><br>Day 1 | 0.014*               | 0,000*               | 0,000*               | -                          | 0.519                      | 0.340                      |
| CaCO <sub>3</sub><br>Day 3 | 0.425                | 0,000*               | 0,000*               | 0.519                      | -                          | 1.000                      |
| CaCO <sub>3</sub><br>Day 7 | 0.616                | 0,000*               | 0,000*               | 0.340                      | 1.000                      | -                          |

**Table 3.** Significant Value of NF-κβ p65 on Tukey HSD Test.

Based on Table 10 the p value for comparison of NF-κβ p65 expression between the control (+) and CaCO<sub>3</sub> treatment groups on day 1 is 0.014; 3rd 0.000; 7th 0.000. These results indicate that there is a significant difference between the control (+) and CaCO<sub>3</sub> treatment groups on days 1, 3 and 7 with a significance value of p < 0.05.



**Figure 2.** NF-κβ p65 expression by immunohistochemistry examination at 400x magnification. The red arrow show the cells that positively express NF-κβ p65, purple and round shape (A : control group, B: Treatment group at day-1 ; C: treatment group at day-3 ; D: treatment group at day-7).

NF-κβ p65 expression by immunohistochemistry examination at 400x magnification. The red arrow show the cells that positively express NF-κβ p65, purple and round shape (A : control group, B: Treatment group at day-1; C: treatment group at day-3; D: treatment group at day-7)

### Discussion

In this study, there were significant differences between each group in which the expression of NF-κβ was higher in the control group compared to the calcium carbonate treatment group. The high expression of NF-κβ in the control group could be caused by injury caused by the resin content of RMGIC contacting the cavities directly. When the tooth is being prepared, there will be an inflammatory process in the odontoblast cells as a response to the tooth's defense. Reactive Oxygen Species (ROS) are produced for physiological purposes by leukocytes and macrophages in the body's defense mechanisms. At physiological pH, superoxide is rapidly dismutase to hydrogen peroxide (H<sub>2</sub>O<sub>2</sub>) by superoxide dismutase. Hydrogen peroxide is a biologically active ROS. Hydrogen peroxide can activate transcription factors by separating the NF-κβ bonds and Kappa Beta Inhibitor (I $\kappa$ B). NF-κβ is a transcription factor that regulates the transcription of many genes that play a role in immune and inflammatory responses. NF-κβ has an important role in immune and inflammatory responses through the regulation of genes responsible for producing pro-inflammatory cytokines, adhesion molecules, chemokines, growth factors, inducible enzymes, such as cyclo-oxygenase 2 (COX2), and inducible nitric oxide synthase (iNOS)<sup>7</sup>.

Dentin is the main hard tissue of the tooth that is formed by odontoblasts, which stem from neural crest-derived odontogenic mesenchymal cells. Odontoblasts are responsible for the production of physiological primary and secondary dentin. Odontoblasts are terminally differentiated cells that are subject to a long-lived secretory condition and mediate dentinogenic activity. Reactionary dentin is formed as an adaptive secretory response when the occurrence of moderate dentin injury stimulate odontoblast generation.

Tertiary dentinogenic can occur in response to tissue injury, and data indicate that infection and inflammation strongly impact on the repair processes within the dental tissue. Reactionary dentinogenesis occurs in response to a relatively mild dental tissue injury, such as during the earlier stages of dental caries, and odontoblasts lining the pulp chamber and root canal survive and up-regulate their synthetic and secretory activity. the link between inflammation and regeneration is potentially derived from the mode of action of restorative materials that promote regenerative events. Both calcium hydroxide and MTA are known to stimulate tertiary dentin bridge formation, and preceding the healing process. NF- $\kappa$ B can be expressed in the acute inflammatory phase, 0-3 days after the injury occurs, and regulate the inflammatory response so that the inflammatory process can continue to become regenerative stage<sup>8</sup>. Decreasing numbers of NF- $\kappa$ B after exposure of calcium carbonat will increase and lead the odontoblast pulp cell to generate reactionary dentinogenesis which may also facilitate release of bioactive components from dentin extra cellular matrix to promote tissue repair<sup>11</sup>. Some studies showed that NF- $\kappa$ B is the key signaling pathways in the proinflammatory and healing responses. To enhance bone formation in vivo, biomaterials such as hydroxyapatite (HA), tricalcium phosphates (TCP), or biphasic calcium phosphates (BCP), a mixture of HA and TCP, are frequently used as scaffolds for bone grafting. All these materials, include calcium carbonate are highly enriched with Ca and their capacity to induce bone formation seems to differ depending on the amount of Ca. Mizuno *et al* showed Ca released from CH stimulated fibronectin gene expression in dental pulp cells, a mechanism that may induce differentiation of these cells to become mineralized tissue forming cells. Pulp-dentin tissue regeneration is the series of healing progression from an inflammatory response, immune signaling, and cellular interaction accompanying tissue restoration upon infectious exposure. Application of calcium carbonat is expected to be an innovative treatment in opening up new pathways for the regenerative dentin process through regulation of NF- $\kappa$ B activation<sup>12</sup>.

## Conclusions

This study showed that application of calcium carbonat from blood cockle (*Anadara Granosa*) shells decrease the expression of the NF- $\kappa$ B. It showed that calcium carbonat induced the healing process, triggered and led the odontoblast pulp cell to generate reactionary dentinogenesis by decreasing the NF- $\kappa$ B number.

## Acknowledgements

The authors thank the Ministry of Research, Technology, and Higher Education, Indonesia, for financing this study.

## Declaration of Interest

The authors report no conflict of interest.

## References

1. Rahardjo, A.K., Widjiastuti, I., Prasetyo, E.A. Prevalensi Karies Gigi Posterior Berdasarkan Kedalaman, Usia dan Jenis Kelamin di RSGM FKG UNAIR Tahun 2014. Prevalence of Posterior Teeth Caries by The Depth of Cavity, Age and Gender at RSGM FKG UNAIR in 2014. *Conservative Dentistry Journal* 2016;6(2): 7-12.
2. Garg, N. dan Garg, A. *Textbook of Operative Dentistry*. 3rd ed. New Delhi: Jaypee Brothers Medical Publishers; 2015:220-4.
3. Laslami, K., Dhoun, S., Karami, M., et al. Direct Pulp Capping with Bioactive Material: Biodentine. *Ecronicon Dental Science* 2017;13(2): 75-83.
4. Arandi, N.Z. Calcium Hydroxide Liners: A Literature Review. *Clinical, Cosmetic and Investigational Dentistry* 2017;9:67-72.
5. Noort, R.V. *Introduction to Dental Materials*. 4th ed. Edinburgh: Mosby Elsevier; 2013:108, 118, 128-30.
6. Al Omari, M.M.H., Rashid, I.S., Qinna, N.A., et al. Calcium Carbonate. *Profiles of Drug Substances, Excipients, and Related Methodology* 2016;41:131-2.
7. Nirwana, I., Agustantina, T.H., Soekartono, R.H. NF- $\kappa$ B Expressions on Rat Dental Pulp Mechanically Exposed After Pomegranate Fruit Extract Administration. *Journal of International Dental and Medical Research* 2017;10(1): 123-7.
8. Lin, T.H., Pajarinen, J., Lu, L., et al. NF- $\kappa$ B as a Therapeutic Target in Inflammatory-Associated Bone Diseases. *Adv Protein Chem Struct Biol* 2017;107: 117-54.
9. Nastiti, A.D., Widyastuti, W., and Laihah, F.M. Biobabilitas Hidroksiapatit Ekstrak Cangkang Kerang Darah ( *Anadara granosa* ) Terhadap Sel Punca Mesenkimal Sebagai Bahan Graft Tulang Alveol. *DENTA Jurnal Kedokteran Gigi Universitas Hang Tuah Surabaya* 2019(2): 122.
10. Sari, R.P. Mekanisme Kerja Bone Graft Dari Cangkang Kerang Darah (*Anadara Granosa*) Dan Teripang Emas (*Stichopus Hermanni*) Pada Penyembuhan Tulang Alveolar Pasca Pencabutan Gigi. Program Studi Kedokteran Jenjang Doktor Fakultas Kedokteran Universitas Airlangga. Surabaya. 2018:6-12.
11. Goldberg M, Six N, Decup F, et al. Bioactive Molecules And The Future of Pulp Therapy. *Am J Dent* 2003;16:66-76.
12. Mizuno M and Banzai Y. Calcium Ion Release From Calcium Hydroxide Stimulated Fibronectin Gene Expression In Dental Pulp Cells And The Differentiation Of Dental Pulp Cells To Mineralized Tissue Forming Cells by Fibronectin. *Int Endod J* 2008;41(11):933-8.

# The Effect of Exposure Calcium Carbonat from Blood Cockle (Anadara Granosa) Shells to the Expression of the NF- $\kappa$ $\beta$ on Dentin Pulp Complex

## ORIGINALITY REPORT

**21** %  
SIMILARITY INDEX

**13** %  
INTERNET SOURCES

**18** %  
PUBLICATIONS

**%**  
STUDENT PAPERS

## PRIMARY SOURCES

- 1** Paul R. Cooper, Michelle J. Holder, Anthony J. Smith. "Inflammation and Regeneration in the Dentin-Pulp Complex: A Double-edged Sword", Journal of Endodontics, 2014  
Publication **4** %
- 2** Minju Song, Bo Yu, Sol Kim, Marc Hayashi et al. "Clinical and Molecular Perspectives of Reparative Dentin Formation", Dental Clinics of North America, 2017  
Publication **3** %
- 3** [www.ektodermaldisplazi.com](http://www.ektodermaldisplazi.com)  
Internet Source **3** %
- 4** [www.nature.com](http://www.nature.com)  
Internet Source **1** %
- 5** [www.ncbi.nlm.nih.gov](http://www.ncbi.nlm.nih.gov)  
Internet Source **1** %
- 6** [www.mdpi.com](http://www.mdpi.com)  
Internet Source **1** %

7

C. Yi, S. R. Wang, S. Y. Zhang, S. J. Yu, C. X. Jiang, M. H. Zhi, Y. Huang. "Effects of recombinant human growth hormone on acute lung injury in endotoxemic rats", *Inflammation Research*, 2006

Publication

1 %

8

Intan Nirwana, Priyawan Rachmadi, Devi Rianti. "Potential of pomegranate fruit extract (*Punica granatum* Linn.) to increase vascular endothelial growth factor and platelet-derived growth factor expressions on the post-tooth extraction wound of *Cavia cobaya*", *Veterinary World*, 2017

Publication

1 %

9

Ratna Restapaty, Rahmi Hidayati, Vebruati Vebruati. "Influence of Blog Media on Improving the Essay Writing Skills of S-1 Pharmacy Study Program Students of STIKES Borneo Lestari", *KnE Social Sciences*, 2021

Publication

1 %

10

[www.science.gov](http://www.science.gov)

Internet Source

1 %

11

[www.hindawi.com](http://www.hindawi.com)

Internet Source

1 %

12

Rosmamuhamadani Ramli, Ainaa Zafirah Omar Arawi, Mohd. Muzamir Mahat, Ahmad Faiza Mohd., Mohd Fakharul Zaman Raja

1 %



Yahya. "Effect of silver (Ag) substitution nano-hydroxyapatite synthesis by microwave processing", 2011 International Conference on Business, Engineering and Industrial Applications, 2011

Publication

13

[www.tandfonline.com](http://www.tandfonline.com)

Internet Source

<1 %

14

[repository.unair.ac.id](http://repository.unair.ac.id)

Internet Source

<1 %

15

Norman So. "Depth electrode investigations in patients with bitemporal epileptiform abnormalities", *Annals of Neurology*, 05/1989

Publication

<1 %

16

[manu45.magtech.com.cn](http://manu45.magtech.com.cn)

Internet Source

<1 %

17

Elaine Zanchin Baldissera, Adriana Fernandes da Silva, Ana Paula Neutzling Gomes, Adriana Etges et al. "Tenascin and Fibronectin Expression after Pulp Capping with Different Hemostatic Agents: A Preliminary Study", *Brazilian Dental Journal*, 2013

Publication

<1 %

18

Takashi Okiji, Kunihiro Yoshida. "Reparative Dentinogenesis Induced by Mineral Trioxide Aggregate: A Review from the Biological and

<1 %

# Physicochemical Points of View", International Journal of Dentistry, 2009

Publication

19

arthritis-research.biomedcentral.com

Internet Source

<1 %

20

hangtuah.ac.id

Internet Source

<1 %

21

Nadia Alice Vieira da Motta, Arthur Eugen Kümmerle, Elisabeth Marostica, Caroline Fernandes dos Santos et al. "Anti-atherogenic Effects of a New Thienylacylhydrazone Derivative, LASSBio-788, in Rats Fed a Hypercholesterolemic Diet", Journal of Pharmacological Sciences, 2013

Publication

<1 %

Exclude quotes Off

Exclude matches Off

Exclude bibliography On

# The Effect of Exposure Calcium Carbonat from Blood Cockle (Anadara Granosa) Shells to the Expression of the NF- $\kappa$ $\beta$ on Dentin Pulp Complex

---

GRADEMARK REPORT

---

FINAL GRADE

**/0**

GENERAL COMMENTS

**Instructor**

---

PAGE 1

---

PAGE 2

---

PAGE 3

---

PAGE 4

---

PAGE 5

---