

## BUKTI KORESPONDENSI

### Jurnal Internasional Bereputasi

Judul Artikel : Evaluation of Root Anatomy and Canal Configuration of Human Permanent Maxillary First Molar Using Cone-Beam Computed Tomography: A Systematic Review.

Penulis : Sourabh Barbhui, Rajesh Shetty, Poonam Joshi, Vini Mehta, Ankita Mathur, Tanvi Sharma, Damini Chakraborty, Priyanka Porwal, Aida Meto, **Dian Agustin Wahjuningrum**, Alexander Maniangat Luke and Ajinkya M. Pawar

Jurnal : International Journal of Environmental Research Public Health Vol. 19 No.16 Tahun 2022 Doi : 10.3390/ijerph191610160

Penerbit : Multidisciplinary Digital Publishing Institute (MDPI)

1	Manuscript was submitted to Journal “ <b>Int. J. Environ. Res. Public Health</b> ” (ID: <b>ijerph-1851381</b> )	<b>Received: 21 Juli 2022</b>
	Decision: Thank you very much for uploading the following manuscript to the MDPI submission system. One of our editors will be in touch with you soon	
2	<b>Assistant Editor Assigned (ID: ijerph-1851381)</b> was assigned to editor	<b>Received: 22 Juli 2022</b>
	Decision: Your manuscript has been assigned to Cynthia Mei for further processing who will act as a point of contact for any questions related to your paper	
3	<b>Revision 1 (ID: ijerph-1851381)</b> was reviewed	<b>Received: 05 Agustus 2022</b>
	Decision: Major revision (Due date 15 August 2022)	
4.	<b>Manuscript Resubmitted (Received)</b>	<b>09 Agustus 2022</b>
5.	<b>Funding Information Confirmation (APC Invoice)</b>	<b>14 Agustus 2022</b>
6.	Decision: <b>Accepted for Publication</b>	<b>14 Agustus 2022</b>
7	<b>Payment Commitment Letter &amp; Final Proofread</b>	<b>15 Agustus 2022</b>
8	<b>Published online</b>	<b>16 Agustus 2022</b>
9	<b>Published on International Journal of Environmental Research Public Health Vol. 19 No.16 Tahun 2022 10.3390/ijerph191610160</b>	<b>16 Agustus 2022</b>



▼ User Menu ?

- Home
- Manage Accounts
- Change Password
- Edit Profile
- Logout

▼ Submissions Menu ?

- Submit Manuscript
- Display Submitted Manuscripts
- Display Co-Authored Manuscripts
- English Editing
- Discount Vouchers
- Invoices
- LaTeX Word Count

▼ Reviewers Menu ?

- Reviews
- Volunteer Preferences

▼ Academic Editor Menu ?

- Editor Profile
- Decisions
- Pre-check Decisions
- Special Issues

Article Information Overview

Manuscript ID **ijerph-1851381**

Status Website online

DOI [10.3390/ijerph191610160](https://doi.org/10.3390/ijerph191610160)

Publication Certificate [Download Publication Certificate \(PDF\)](#) ▼

Banner [Download Banner \(PDF\)](#)

Website Links [Abstract](#) [HTML version](#) [PDF version](#) [Manuscript](#)

Article type Systematic Review

Title Evaluation of Root Anatomy and Canal Configuration of Human Permanent Maxillary First Molar Using Cone-Beam Computed Tomography: A Systematic Review

Journal *International Journal of Environmental Research and Public Health*

Volume 19

Issue 16

Section [Digital Health](#)

Special Issue [Clinical and Experimental Approaches in Dental Health](#)

**Abstract** The aim of this paper is to review the literature on root canal configuration (RCC) and the frequency of occurrence of a second mesiobuccal canal (MB) in human permanent maxillary first molars where cone-beam computed tomography (CBCT) is used. Online electronic databases such as PubMed-Medline, Embase, Scopus and Cochrane Library were searched using appropriate keywords from the earliest available date until 12th June 2022, without restriction on language. In the mesiobuccal root, type I was the most frequent (33.29%), followed by types II and IV (27.18% and 26.36%, respectively). Moreover, 68.2% of maxillary first molars had a second MB canal. For both the distobuccal and palatal roots, type I was the most prevalent, with 99.08% and 97.83% occurrence, respectively. All other types were infrequent. Type I RCC is most frequent in all the roots of the maxillary first molars. Hence, care must be taken during biomechanical preparation of the MB roots.

**Keywords** canal configuration; root canal; Vertucci classification; permanent mandibular first molar; CBCT



*data*

Data is of paramount importance to scientific progress, yet most research data drowns in supplementary files or remains private. Enhancing the transparency of the data processes will help to render scientific research results reproducible and thus more accountable. Co-submit your methodical data processing articles or data descriptors for a linked data set in *Data* journal to make your data more citable and reliable.

- Deposit your data set in an online repository, obtain the DOI number or link to the deposited data set.
- Download and use the [Microsoft Word template](#) or [LaTeX template](#) to prepare your data article.
- Upload and send your data article to the [Data journal here](#).

## Author Information

Submitting Author Dian Agustin Wahjuningrum

Corresponding Authors Dian Agustin Wahjuningrum, Alexander Maniangat Luke, Ajinkya M. Pawar

Author #1 Sourabh Barbhai

Affiliation 1. Department of Conservative Dentistry & Endodontics, Dr. D.Y. Patil Dental College and Hospital, Dr. D.Y. Patil Vidyapeeth, Pimpri, Pune 411018, Maharashtra, India

E-Mail [sourabhsb96@gmail.com](mailto:sourabhsb96@gmail.com) (co-author email has not been published)

Author #2 Rajesh Shetty

Affiliation 1. Department of Conservative Dentistry & Endodontics, Dr. D.Y. Patil Dental College and Hospital, Dr. D.Y. Patil Vidyapeeth, Pimpri, Pune 411018, Maharashtra, India

E-Mail [rajeshendo@gmail.com](mailto:rajeshendo@gmail.com) (co-author email has not been published)

Author #3 Poonam Joshi

Affiliation 1. Department of Conservative Dentistry & Endodontics, Dr. D.Y. Patil Dental College and Hospital, Dr. D.Y. Patil Vidyapeeth, Pimpri, Pune 411018, Maharashtra, India

E-Mail [dr.poonampande@gmail.com](mailto:dr.poonampande@gmail.com) (co-author email has not been published)

Author #4 Vini Mehta

Affiliation 2. Department of Public Health Dentistry, Dr. D.Y. Patil Dental College and Hospital, Dr. D.Y. Patil Vidyapeeth, Pimpri, Pune 411018, Maharashtra, India

E-Mail [vini.mehta@statsense.in](mailto:vini.mehta@statsense.in) (co-author email has not been published)

Author #5 Ankita Mathur

Affiliation 3. STAT SENSE, Srushti 10, Sector 1 D, Amba Township Pvt. Ltd., Trimandir, Adalaj 382421, Gujarat, India

E-Mail [amathur@statsense.in](mailto:amathur@statsense.in) (co-author email has not been published)

Author #6 Tanvi Sharma

Affiliation 3. STAT SENSE, Srushti 10, Sector 1 D, Amba Township Pvt. Ltd., Trimandir, Adalaj 382421, Gujarat, India

E-Mail [tan.sharma2@gmail.com](mailto:tan.sharma2@gmail.com) (co-author email has not been published)

Author #7 Damini Chakraborty

Affiliation 4. Bhowal's Dental and Implant Clinic, Bengal GreenField Heights, Galaxy-6FS, beside Apollo Pharmacy, DJ Block (Newtown), Newtown, Kolkata 700136, West Bengal, India

E-Mail [dchakraborty09@gmail.com](mailto:dchakraborty09@gmail.com) (co-author email has not been published)

Author #8 Priyanka Porwal

Affiliation 3. STAT SENSE, Srushti 10, Sector 1 D, Amba Township Pvt. Ltd., Trimandir, Adalaj 382421, Gujarat, India

E-Mail [priyanka@statsense.in](mailto:priyanka@statsense.in) (co-author email has not been published)

Author #9 Aida Meto

Affiliation 5. Department of Dentistry, Faculty of Dental Sciences, University of Aldent, 1007 Tirana, Albania

E-Mail [aida.meto@ual.edu.al](mailto:aida.meto@ual.edu.al) (co-author email has not been published)

Author #10 Dian Agustin Wahjuningrum

Affiliation 6. Department of Conservative Dentistry, Faculty of Dental Medicine, Universitas Airlangga, Surabaya 60132, East Java, Indonesia

E-Mail [dian-augustin-w@fkg.unair.ac.id](mailto:dian-augustin-w@fkg.unair.ac.id) (corresponding author email)

Author #11 Alexander Maniangat Luke

Affiliation 7. Department of Clinical Sciences, College of Dentistry, Ajman University, Ajman 346, United Arab Emirates  
8. Centre of Medical and Bio-allied Health Sciences Research, Ajman University, Ajman 346, United Arab Emirates

E-Mail [a.luke@ajman.ac.ae](mailto:a.luke@ajman.ac.ae) (corresponding author email)

Author #12 Ajinkya M. Pawar

Affiliation 9. Department of Conservative Dentistry and Endodontics, Nair Hospital Dental College, Mumbai 400008, Maharashtra, India

E-Mail [ajinkya@drpawars.com](mailto:ajinkya@drpawars.com) (corresponding author email)

#### Manuscript Information

Received Date 21 July 2022

Revised Date 9 August 2022

Accepted Date 14 August 2022

Published Date 16 August 2022

Submission to First Decision (Days) 23

Submission to Publication (Days) 25

Round of Revision 1

Size of PDF 611 KiB

Word Count 4749

Page Count 13

Figure Count 1

Table Count 3

Reference Count 76

Citations 2

#### Editor Decision

Decision Accept in current form

Decision Date 14 August 2022

#### Review Report

Reviewer 1 [Review Report \(Round 1\)](#)

Reviewer 2 [Review Report \(Round 1\)](#) [Review Report \(Round 2\)](#)

Reviewer 3 [Review Report \(Round 1\)](#)



## APC information

Journal APC: 2,500.00 CHF

Total Payment Amount: 2,500.00 CHF

## Previously Published Papers

- Pawar, B.A.; Pawar, A.M.; Bhardwaj, A.; Wahjuningrum, D.A.; Rahardjo, A.K.; Luke, A.M.; Metzger, Z.; Kfir, A. Effect of Adaptive, Rotary, and Manual Root Canal Instrumentation in Primary Molars: A Triple-Armed, Randomized Controlled Clinical Trial. *Biology* **2021**, *10*, 42. doi: [10.3390/biology10010042](https://doi.org/10.3390/biology10010042)
- Shinde, O.; Pawar, A.M.; Banga, K.S.; Atram, J.; Wahjuningrun, D.A. Endodontic Emergencies in Mumbai City during COVID-19 Lockdown and Different Phases of Unlock. *Int. J. Environ. Res. Public Health* **2021**, *18*, 7314. doi: [10.3390/ijerph18147314](https://doi.org/10.3390/ijerph18147314)
- Pawar, A.M.; Bhardwaj, A.; Banga, K.S.; Singh, G.; Kfir, A.; Luke, A.M.; Dinata, V.; Wahjuningrun, D.A. Deficiencies in Root Canal Fillings Subsequent to Adaptive Instrumentation of Oval Canals. *Biology* **2021**, *10*, 1074. doi: [10.3390/biology10111074](https://doi.org/10.3390/biology10111074)
- Thakur, B.; Bhardwaj, A.; Wahjuningrum, D.A.; Luke, A.M.; Shetty, K.P.; Pawar, A.M.; Reda, R.; Seracchiani, M.; Zanza, A.; Testarelli, L. Incidence of Post-Operative Pain following a Single-Visit Pulpectomy in Primary Molars Employing Adaptive, Rotary, and Manual Instrumentation: A Randomized Clinical Trial. *Medicina* **2023**, *59*, 355. doi: [10.3390/medicina59020355](https://doi.org/10.3390/medicina59020355)
- Shetty, V.; Yelke, S.; Wahjuningrum, D.A.; Luke, A.M.; Testarelli, L.; Giardino, L.; Pawar, A.M. Post-Operative Quality of Life after Single-Visit Root Canal Treatment Employing Three Different Instrumentation Techniques—An Institutional Randomized Clinical Trial. *J. Clin. Med.* **2023**, *12*, 1535. doi: [10.3390/jcm12041535](https://doi.org/10.3390/jcm12041535)
- Khanvilkar, U.; Patil, H.; Bandekar, S.; Kshirsagar, S.; Pawar, A.M.; Wahjuningrum, D.A.; Pagnoni, F.; Reda, R.; Zanza, A.; Testarelli, L. Pushout Bond Strength of Root Fillings after Irrigation of Root Canals Utilizing Sodium Hypochlorite, Chlorhexidine, and Homeopathic Mother Tincture (*Arnica Montana*). *Clin. Pract.* **2023**, *13*, 305-314. doi: [10.3390/clinpract13010028](https://doi.org/10.3390/clinpract13010028)

## Related Papers Published in MDPI Journals

- Pham, K.V. A Comparison of Cone Beam Computed Tomography and Periapical Digital Radiography for Evaluation of Root Canal Preparation. *Appl. Sci.* **2021**, *11*, 6599. doi: [10.3390/app11146599](https://doi.org/10.3390/app11146599)
- Lee, K.J.; Jeon, H.H.; Boucher, N.; Chung, C.-H. Transverse Analysis of Maxilla and Mandible in Adults with Normal Occlusion: A Cone Beam Computed Tomography Study. *J. Imaging* **2022**, *8*, 100. doi: [10.3390/jimaging8040100](https://doi.org/10.3390/jimaging8040100)

If you have any questions or concerns, please do not hesitate to contact [ijerph@mdpi.com](mailto:ijerph@mdpi.com).

~ User Menu ?

- Home
- Manage Accounts
- Change Password
- Edit Profile
- Logout

~ Submissions Menu ?

- Submit Manuscript
- Display Submitted Manuscripts
- Display Co-Authored Manuscripts
- English Editing
- Discount Vouchers
- Invoices
- LaTeX Word Count

~ Reviewers Menu ?

- Reviews
- Volunteer Preferences

~ Academic Editor Menu ?

- Editor Profile
- Decisions
- Pre-check Decisions
- Special Issues

Journal **IJERPH** (ISSN 1660-4601)  
 Manuscript ID **ijerph-1851381**  
 Type **Systematic Review**  
 Title **Evaluation of Root Anatomy and Canal Configuration of Hu-man Permanent Maxillary First Molar Using Cone Beam Computed Tomography: A Systematic Review**  
 Authors **Sourabh Barbhai , Rajesh Shetty , Poonam Joshi , Vini Mehta , Ankita Mathur , Tanvi Sharma , Damini Chakraborty , Priyanka Porwal , Aida Meto , Dian Agustin Wahjuningrum \* , Alexander Maniangat Luke \* , Ajinkya M. Pawar \***  
 Section **Digital Health**  
 Special Issue **Clinical and Experimental Approaches in Dental Health**  
 Abstract **To review the literature on root canal configuration (RCC) and the frequency of occurrence of a second mesiobuccal canal (MB) in human permanent maxillary first molars where cone-beam, computed tomography (CBCT) is used. Online electronic databases such as PubMed-Medline, Embase, Scopus, and Cochrane Library were searched using appropriate keywords from the earliest available date until 12th June 2022 without restriction on language. In the mesiobuccal root, Type I was the most frequent (33.29%), followed by Types II and IV (27.18% and 26.36%, respectively). Moreover, 68.2% of maxillary first molars had a second MB canal. For both distobuccal and palatal roots, Type I was the most prevalent, with 99.08% and 97.83% occurrence, respectively. All other types were infrequent. Type I RCC is most frequent in all the roots of the maxillary first molars. Hence, care must be taken during biomechanical preparation of the MB roots.**

The coverletter for this review report has been saved in the database. You can safely close this window.

Authors' Responses to Reviewer's Comments (Reviewer 1)

**Author's Notes** **Point 1:** A well-written introduction and a very well-done literature review The subject of the article does not match the subject of the journal. The issues raised are generally known and do not add anything new to the subject of the problem

**Response 1:** The main aim of this study was to analyze the available studies on the prevalence of root canal configuration of maxillary first molar teeth assessed using CBCT to help dentists identify the root anatomy and subsequently perform endodontic treatment successfully. Generally, radiographs which are used are not accurate.

Review Report Form

Quality of English Language  English very difficult to understand/incomprehensible  
 Extensive editing of English language and style required  
 Moderate English changes required  
 English language and style are fine/minor spell check required  
 I am not qualified to assess the quality of English in this paper

	Yes	Can be improved	Must be improved	Not applicable
Does the introduction provide sufficient background and include all relevant references?	<input checked="" type="checkbox"/>	<input type="checkbox"/>	<input type="checkbox"/>	<input type="checkbox"/>
Are all the cited references relevant to the research?	<input checked="" type="checkbox"/>	<input type="checkbox"/>	<input type="checkbox"/>	<input type="checkbox"/>
Is the research design appropriate?	<input checked="" type="checkbox"/>	<input type="checkbox"/>	<input type="checkbox"/>	<input type="checkbox"/>
Are the methods adequately described?	<input checked="" type="checkbox"/>	<input type="checkbox"/>	<input type="checkbox"/>	<input type="checkbox"/>
Are the results clearly presented?	<input checked="" type="checkbox"/>	<input type="checkbox"/>	<input type="checkbox"/>	<input type="checkbox"/>
Are the conclusions supported by the results?	<input checked="" type="checkbox"/>	<input type="checkbox"/>	<input type="checkbox"/>	<input type="checkbox"/>

**Comments and Suggestions for Authors** A well-written introduction and a very well-done literature review The subject of the article does not match the subject of the journal. The issues raised are generally known and do not add anything new to the subject of the problem

Submission Date **21 July 2022**  
 Date of this review **28 Jul 2022 18:13:19**

▼ User Menu ?

- Home
- Manage Accounts
- Change Password
- Edit Profile
- Logout

▼ Submissions Menu ?

- Submit Manuscript
- Display Submitted Manuscripts
- Display Co-Authored Manuscripts
- English Editing
- Discount Vouchers
- Invoices
- LaTeX Word Count

▼ Reviewers Menu ?

- Reviews
- Volunteer Preferences

▼ Academic Editor Menu ?

- Editor Profile
- Decisions
- Pre-check Decisions
- Special Issues

Journal [IJERPH \(ISSN 1660-4601\)](#)

Manuscript ID [ijerph-1851381](#)

Type [Systematic Review](#)

Title [Evaluation of Root Anatomy and Canal Configuration of Hu-man Permanent Maxillary First Molar Using Cone Beam Computed Tomography: A Systematic Review](#)

Authors [Sourabh Barbhui](#) , [Rajesh Shetty](#) , [Poonam Joshi](#) , [Vini Mehta](#) , [Ankita Mathur](#) , [Tanvi Sharma](#) , [Damini Chakraborty](#) , [Priyanka Porwal](#) , [Aida Meto](#) , [Dian Agustin Wahjuningrum \\*](#) , [Alexander Maniangat Luke \\*](#) , [Ajinkya M. Pawar \\*](#)

Section [Digital Health](#)

Special Issue [Clinical and Experimental Approaches in Dental Health](#)

Abstract To review the literature on root canal configuration (RCC) and the frequency of occurrence of a second mesiobuccal canal (MB) in human permanent maxillary first molars where cone-beam, computed tomography (CBCT) is used. Online electronic databases such as PubMed-Medline, Embase, Scopus, and Cochrane Library were searched using appropriate keywords from the earliest available date until 12th June 2022 without restriction on language. In the mesiobuccal root, Type I was the most frequent (33.29%), followed by Types II and IV (27.18% and 26.36%, respectively). Moreover, 68.2% of maxillary first molars had a second MB canal. For both distobuccal and palatal roots, Type I was the most prevalent, with 99.08% and 97.83% occurrence, respectively. All other types were infrequent. Type I RCC is most frequent in all the roots of the maxillary first molars. Hence, care must be taken during biomechanical preparation of the MB roots.

Review Report Form

- Quality of English Language  English very difficult to understand/incomprehensible  
 Extensive editing of English language and style required  
 Moderate English changes required  
 English language and style are fine/minor spell check required  
 I am not qualified to assess the quality of English in this paper

	Yes	Can be improved	Must be improved	Not applicable
Does the introduction provide sufficient background and include all relevant references?	<input checked="" type="radio"/>	<input type="radio"/>	<input type="radio"/>	<input type="radio"/>
Are all the cited references relevant to the research?	<input checked="" type="radio"/>	<input type="radio"/>	<input type="radio"/>	<input type="radio"/>
Is the research design appropriate?	<input checked="" type="radio"/>	<input type="radio"/>	<input type="radio"/>	<input type="radio"/>
Are the methods adequately described?	<input checked="" type="radio"/>	<input type="radio"/>	<input type="radio"/>	<input type="radio"/>
Are the results clearly presented?	<input checked="" type="radio"/>	<input type="radio"/>	<input type="radio"/>	<input type="radio"/>
Are the conclusions supported by the results?	<input checked="" type="radio"/>	<input type="radio"/>	<input type="radio"/>	<input type="radio"/>

Comments and Suggestions for Authors Dear Authors,  
 Thank you for your detailed response and adjustment.

Submission Date 21 July 2022  
 Date of this review 09 Aug 2022 15:45:28

~ User Menu ?

- [Home](#)
- [Manage Accounts](#)
- [Change Password](#)
- [Edit Profile](#)
- [Logout](#)

~ Submissions Menu ?

- [Submit Manuscript](#)
- [Display Submitted Manuscripts](#)
- [Display Co-Authored Manuscripts](#)
- [English Editing](#)
- [Discount Vouchers](#)
- [Invoices](#)
- [LaTeX Word Count](#)

~ Reviewers Menu ?

- [Reviews](#)
- [Volunteer Preferences](#)

~ Academic Editor Menu ?

- [Editor Profile](#)
- [Decisions](#)
- [Pre-check Decisions](#)
- [Special Issues](#)

Journal [IJERPH \(ISSN 1860-4601\)](#)  
 Manuscript ID [ijerph-1851381](#)  
 Type [Systematic Review](#)  
 Title [Evaluation of Root Anatomy and Canal Configuration of Hu-man Permanent Maxillary First Molar Using Cone Beam Computed Tomography: A Systematic Review](#)  
 Authors [Sourabh Barbhai](#) , [Rajesh Shetty](#) , [Poonam Joshi](#) , [Vini Mehta](#) , [Ankita Mathur](#) , [Tanvi Sharma](#) , [Damini Chakraborty](#) , [Priyanka Porwal](#) , [Aida Meto](#) , [Dian Agustin Wahjuningrum \\*](#) , [Alexander Mariangat Luke \\*](#) , [Ajinkya M. Pawar \\*](#)  
 Section [Digital Health](#)  
 Special Issue [Clinical and Experimental Approaches in Dental Health](#)  
 Abstract To review the literature on root canal configuration (RCC) and the frequency of occurrence of a second mesiobuccal canal (MB) in human permanent maxillary first molars where cone-beam, computed tomography (CBCT) is used. Online electronic databases such as PubMed-Medline, Embase, Scopus, and Cochrane Library were searched using appropriate keywords from the earliest available date until 12th June 2022 without restriction on language. In the mesiobuccal root, Type I was the most frequent (33.29%), followed by Types II and IV (27.18% and 28.36%, respectively). Moreover, 68.2% of maxillary first molars had a second MB canal. For both distobuccal and palatal roots, Type I was the most prevalent, with 99.08% and 97.83% occurrence, respectively. All other types were infrequent. Type I RCC is most frequent in all the roots of the maxillary first molars. Hence, care must be taken during biomechanical preparation of the MB roots.

The coverletter for this review report has been saved in the database. You can safely close this window.

Authors' Responses to Reviewer's Comments (Reviewer 3)

**Author's Notes** **Point 1:** The quality assessment of the included studies should have used STARD guidelines. Please reassess the quality of the included studies using this tool since they are concerned about diagnostic accuracy.  
  
**Response 1:** Included studies in this review doesn't have the evidence to show variations in measurement of diagnostic accuracy. None of the included papers depict diagnostic accuracy for CBCT in the form of sensitivity and specificity.  
  
**Point 2:** The discussion lacks implications for future research.  
  
**Response 2:** We have added implications for future research at the end of the discussion.  
  
**Point 3:** The authors should recommend a protocol to identify the root canals based on their observation.  
  
**Response 3:** We have added protocol to identify the root canals in the discussion.

Review Report Form

Quality of English Language  English very difficult to understand/incomprehensible  
 Extensive editing of English language and style required  
 Moderate English changes required  
 English language and style are fine/minor spell check required  
 I am not qualified to assess the quality of English in this paper

	Yes	Can be improved	Must be improved	Not applicable
Does the introduction provide sufficient background and include all relevant references?	<input checked="" type="checkbox"/>	<input type="checkbox"/>	<input type="checkbox"/>	<input type="checkbox"/>
Are all the cited references relevant to the research?	<input checked="" type="checkbox"/>	<input type="checkbox"/>	<input type="checkbox"/>	<input type="checkbox"/>
Is the research design appropriate?	<input checked="" type="checkbox"/>	<input type="checkbox"/>	<input type="checkbox"/>	<input type="checkbox"/>
Are the methods adequately described?	<input checked="" type="checkbox"/>	<input type="checkbox"/>	<input type="checkbox"/>	<input type="checkbox"/>
Are the results clearly presented?	<input checked="" type="checkbox"/>	<input type="checkbox"/>	<input type="checkbox"/>	<input type="checkbox"/>
Are the conclusions supported by the results?	<input checked="" type="checkbox"/>	<input type="checkbox"/>	<input type="checkbox"/>	<input type="checkbox"/>

**Comments and Suggestions for Authors** The authors conducted a systematic review to summarise the evidence on the prevalence of root canal configuration of maxillary first molar teeth assessed using CBCT to help dentists identify the root anatomy and subsequently perform endodontic treatment successfully.

The study has a clear aim and PICO statement. The authors identified 35 studies and concluded that Type I RCC is most frequent in all the roots of the maxillary first molars.

Overall, the manuscript reads well. Here are some points to improve the clarity:

- 1- The quality assessment of the included studies should have used STARD guidelines. Please reassess the quality of the included studies using this tool since they are concerned about diagnostic accuracy.
- 2- The discussion lacks implications for future research.
- 3- The authors should recommend a protocol to identify the root canals based on their observation.

Submission Date [21 July 2022](#)  
 Date of this review [03 Aug 2022 18:53:23](#)

---

## [IJERPH] Manuscript ID: ijerph-1851381 - Submission Received

2 pesan

---

**Editorial Office** <ijerph@mdpi.com>

21 Juli 2022 pukul 11.55

Balas Ke: ijerph@mdpi.com

Kepada: Dian Agustin Wahjuningrum <dian-agustin-w@fkg.unair.ac.id>

Cc: Sourabh Barbhai <sourabhsb96@gmail.com>, Rajesh Shetty <rajeshendo@gmail.com>, Poonam Joshi <dr.poonampande@gmail.com>, Vini Mehta <vini.mehta@statsense.in>, Ankita Mathur <amathur@statsense.in>, Tanvi Sharma <tan.sharma2@gmail.com>, Damini Chakraborty <dchakraborty09@gmail.com>, Priyanka Porwal <priyanka@statsense.in>, Aida Meto <aida.meto@ual.edu.al>, Alexander Maniangat Luke <a.luke@ajman.ac.ae>, "Ajinkya M. Pawar" <ajinkya@drpawars.com>

Dear Dr. Wahjuningrum,

Thank you very much for uploading the following manuscript to the MDPI submission system. One of our editors will be in touch with you soon.

Journal name: International Journal of Environmental Research and Public Health

Manuscript ID: ijerph-1851381

Type of manuscript: Systematic Review

Title: Evaluation of Root Anatomy and Canal Configuration of Hu-man Permanent Maxillary First Molar Using Cone Beam Computed Tomography: A Systematic Review

Authors: Sourabh Barbhai, Rajesh Shetty, Poonam Joshi, Vini Mehta, Ankita Mathur, Tanvi Sharma, Damini Chakraborty, Priyanka Porwal, Aida Meto, Dian Agustin Wahjuningrum \*, Alexander Maniangat Luke \*, Ajinkya M. Pawar \*

Received: 21 July 2022

E-mails: sourabhsb96@gmail.com, rajeshendo@gmail.com, dr.poonampande@gmail.com, vini.mehta@statsense.in, amathur@statsense.in, tan.sharma2@gmail.com, dchakraborty09@gmail.com, priyanka@statsense.in, aida.meto@ual.edu.al, dian-agustin-w@fkg.unair.ac.id, a.luke@ajman.ac.ae, ajinkya@drpawars.com

Submitted to section: Digital Health,

[https://www.mdpi.com/journal/ijerph/sections/Digital\\_Health](https://www.mdpi.com/journal/ijerph/sections/Digital_Health)

Clinical and Experimental Approaches in Dental Health

[https://www.mdpi.com/journal/ijerph/special\\_issues/clinical\\_experimental\\_approaches\\_dental](https://www.mdpi.com/journal/ijerph/special_issues/clinical_experimental_approaches_dental)

You can follow progress of your manuscript at the following link (login required):

[https://susy.mdpi.com/user/manuscripts/review\\_info/d8b741c871c3b2e1a9db88a80579efdf](https://susy.mdpi.com/user/manuscripts/review_info/d8b741c871c3b2e1a9db88a80579efdf)

The following points were confirmed during submission:

1. IJERPH is an open access journal with publishing fees of 2500 CHF for an accepted paper (see <https://www.mdpi.com/about/apc/> for details). This manuscript, if accepted, will be published under an open access Creative Commons CC BY license (<https://creativecommons.org/licenses/by/4.0/>), and I agree to pay the Article Processing Charges as described on the journal webpage (<https://www.mdpi.com/journal/ijerph/apc>). See <https://www.mdpi.com/about/openaccess> for more information about open access publishing.

Please note that you may be entitled to a discount if you have previously received a discount code or if your institute is participating in the MDPI Institutional Open Access Program (IOAP), for more information see <https://www.mdpi.com/about/ioap>. If you have been granted any other special discounts for your submission, please contact the IJERPH editorial office.

2. I understand that:

a. If previously published material is reproduced in my manuscript, I will provide proof that I have obtained the necessary copyright permission. (Please refer to the Rights & Permissions website: <https://www.mdpi.com/authors/rights>).

b. My manuscript is submitted on the understanding that it has not been published in or submitted to another peer-reviewed journal. Exceptions to this rule are papers containing material disclosed at conferences. I confirm that I will inform the journal editorial office if this is the case for my manuscript. I confirm that all authors are familiar with and agree with submission of the contents of the manuscript. The journal editorial office reserves the right to contact all authors to confirm this in case of doubt. I will provide email addresses for all authors and an institutional e-mail address for at least one of the co-authors, and specify the name, address and e-mail for invoicing purposes.

If you have any questions, please do not hesitate to contact the IJERPH editorial office at [ijerph@mdpi.com](mailto:ijerph@mdpi.com)

Kind regards,  
IJERPH Editorial Office  
St. Alban-Anlage 66, 4052 Basel, Switzerland  
E-Mail: [ijerph@mdpi.com](mailto:ijerph@mdpi.com)  
Tel. +41 61 683 77 34  
Fax: +41 61 302 89 18

\*\*\* This is an automatically generated email \*\*\*

---

**Cynthia Mei** <[cynthia.mei@mdpi.com](mailto:cynthia.mei@mdpi.com)>

22 Juli 2022 pukul 16.22

Kepada: Aida Meto <[aida.meto@ual.edu.al](mailto:aida.meto@ual.edu.al)>

Cc: [ijerph@mdpi.com](mailto:ijerph@mdpi.com), [sourabhsb96@gmail.com](mailto:sourabhsb96@gmail.com), [dr.poonampande@gmail.com](mailto:dr.poonampande@gmail.com), [vini.mehta@statsense.in](mailto:vini.mehta@statsense.in), [tan.sharma2@gmail.com](mailto:tan.sharma2@gmail.com), [dchakraborty09@gmail.com](mailto:dchakraborty09@gmail.com), [agustin.wahjuningrum Dian <dian-agustin-w@fkg.unair.ac.id>](mailto:agustin.wahjuningrum.Dian@fkg.unair.ac.id)

Dear Dr. Aida,

Thank you for your prompt reply.

Could you please help to ask the other authors to sign this file? Also please clarify the detailed COI in this file. I also cc them in this email. Thank you for your support and work.

Look forward to hearing from you.

Kind regards,  
Cynthia Mei  
Section Managing Editor  
E-Mail: [cynthia.mei@mdpi.com](mailto:cynthia.mei@mdpi.com)  
IJERPH: <http://www.mdpi.com/journal/ijerph/>

We are pleased to announce that IJERPH has been ranked with an improved Impact Factor of 4.614.

IJERPH (IF: 4.614, ISSN 1660-4601) is calling for Special Issue Proposals for the Summer of 2022:  
<https://www.mdpi.com/journalproposal/sendproposalspecialissue/ijerph>. To request further information, please contact the IJERPH Editorial Office ([cynthia.mei@mdpi.com](mailto:cynthia.mei@mdpi.com)).

Topical Advisory Panel is open for application. Welcome to join us!  
[https://www.mdpi.com/journal/ijerph/topical\\_advisory\\_panel\\_application](https://www.mdpi.com/journal/ijerph/topical_advisory_panel_application)

IJERPH is seeking nominations and applications for the position of Section Editor-in-Chief (SEIC) for the following Sections:

<https://www.mdpi.com/journal/ijerph/announcements/3712>

New Section Announcement—"Health-Related Quality of Life and Well-Being"

More information regarding this Section can be found via the following link:

[https://www.mdpi.com/journal/ijerph/sections/health-related\\_quality\\_of\\_life\\_and\\_well-being](https://www.mdpi.com/journal/ijerph/sections/health-related_quality_of_life_and_well-being)

Disclaimer: MDPI recognizes the importance of data privacy and protection. We treat personal data in line with the General Data Protection Regulation (GDPR) and with what the community expects of us. The information contained in this message is confidential and intended solely for the use of the individual or entity to whom they are addressed. If you have received this message in error, please notify me and delete this message from your system. You may not copy this message in its entirety or in part, or disclose its contents to anyone.

On 2022/7/22 17:16, Aida Meto wrote:

CAUTION - EXTERNAL: This email originated from outside of MDPI organisation. BE CAUTIOUS especially to click links or open attachments.

Dear Dr. Mei, thank you very much for your support in these steps to make a successful Special Issue!

Please, find as attachment the statement signed! If it is necessary for another document, please feel free to contact me!  
Best regards, Aida Meto

On Fri, Jul 22, 2022 at 9:50 AM Cynthia Mei <[cynthia.mei@mdpi.com](mailto:cynthia.mei@mdpi.com) <<mailto:cynthia.mei@mdpi.com>>> wrote:

Dear Dr. Aida,

Thank you for your notice.

After checked by Editorial Office, we would like to ask you to sign this disclosure file: <https://res.mdpi.com/data/mdpi-disclosure-form.pdf> <<https://res.mdpi.com/data/mdpi-disclosure-form.pdf>> and add a detailed statement in Col part since Dr. Ankita Mathur, Dr. Tanvi Sharma and Dr. Priyanka Porwal are from company. Hope you can understand. This manuscript is under peer-review now and your manuscript ijerph-1821953 is sent to major revision today.

All the best wishes to your work and have a nice weekend.

Kind regards, Cynthia Mei Section Managing Editor E-Mail: [cynthia.mei@mdpi.com](mailto:cynthia.mei@mdpi.com) <<mailto:cynthia.mei@mdpi.com>>  
IJERPH: <http://www.mdpi.com/journal/ijerph/> <<http://www.mdpi.com/journal/ijerph/>>

We are pleased to announce that IJERPH has been ranked with an improved Impact Factor of 4.614.

IJERPH (IF: 4.614, ISSN 1660-4601) is calling for Special Issue Proposals for the Summer of 2022:

<https://www.mdpi.com/journalproposal/sendproposalspecialissue/ijerph>

<<https://www.mdpi.com/journalproposal/sendproposalspecialissue/ijerph>>.

To

request further information, please contact the IJERPH Editorial Office ([cynthia.mei@mdpi.com](mailto:cynthia.mei@mdpi.com) <<mailto:cynthia.mei@mdpi.com>>).

Topical Advisory Panel is open for application. Welcome to join us! [https://www.mdpi.com/journal/ijerph/topical\\_advisory\\_panel\\_application](https://www.mdpi.com/journal/ijerph/topical_advisory_panel_application)



<[https://www.mdpi.com/journal/ijerph/topical\\_advisory\\_panel\\_application](https://www.mdpi.com/journal/ijerph/topical_advisory_panel_application)>

IJERPH is seeking nominations and applications for the position of Section Editor-in-Chief (SEiC) for the following Sections: <https://www.mdpi.com/journal/ijerph/announcements/3712> <<https://www.mdpi.com/journal/ijerph/announcements/3712>>

New Section Announcement—"Health-Related Quality of Life and Well-Being" More information regarding this Section can be found via the following link: [https://www.mdpi.com/journal/ijerph/sections/health-related\\_quality\\_of\\_life\\_and\\_well-being](https://www.mdpi.com/journal/ijerph/sections/health-related_quality_of_life_and_well-being)

<[https://www.mdpi.com/journal/ijerph/sections/health-related\\_quality\\_of\\_life\\_and\\_well-being](https://www.mdpi.com/journal/ijerph/sections/health-related_quality_of_life_and_well-being)>

Disclaimer: MDPI recognizes the importance of data privacy and protection. We treat personal data in line with the General Data Protection Regulation (GDPR) and with what the community expects of us. The information contained in this message is confidential and intended solely for the use of the individual or entity to whom they are addressed. If you have received this message in error, please notify me and delete this message from your system. You may not copy this message in its entirety or in part, or disclose its contents to anyone.

On 2022/7/21 14:12, Aida Meto wrote:

CAUTION - EXTERNAL: This email originated from outside of MDPI organisation. BE CAUTIOUS especially to click links or open attachments.

Hello dear Dr. Mei, here is the other article submitted to our Special Issue. I am waiting other two papers to submit next weeks, from my colleagues. In any case I will forward you the emails of submission to let you know about them.

Wish you a beautiful day and all the best, Aida

----- Forwarded message ----- From: \*Editorial Office\* <[ijerph@mdpi.com](mailto:ijerph@mdpi.com)> <<mailto:ijerph@mdpi.com>>

<<mailto:ijerph@mdpi.com>>>> Date: Thu, 21 Jul 2022 at

6:55 AM Subject: [IJERPH] Manuscript ID: ijerph-1851381 - Submission Received To: Dian Agustin Wahjuningrum <[dian-agustin-w@fkg.unair.ac.id](mailto:dian-agustin-w@fkg.unair.ac.id)

<<mailto:dian-agustin-w@fkg.unair.ac.id>

<<mailto:dian-agustin-w@fkg.unair.ac.id>>>> Cc: Sourabh Barbhai

<[sourabhsb96@gmail.com](mailto:sourabhsb96@gmail.com)> <<mailto:sourabhsb96@gmail.com>>

<<mailto:sourabhsb96@gmail.com>> <<mailto:sourabhsb96@gmail.com>>>>, Rajesh Shetty

<[rajeshendo@gmail.com](mailto:rajeshendo@gmail.com)> <<mailto:rajeshendo@gmail.com>>

<<mailto:rajeshendo@gmail.com>> <<mailto:rajeshendo@gmail.com>>>>, Poonam

Joshi

<[dr.poonampande@gmail.com](mailto:dr.poonampande@gmail.com)> <<mailto:dr.poonampande@gmail.com>>

<<mailto:dr.poonampande@gmail.com>

<<mailto:dr.poonampande@gmail.com>>>>, Vini

Mehta <[vini.mehta@statsense.in](mailto:vini.mehta@statsense.in)> <<mailto:vini.mehta@statsense.in>

<<mailto:vini.mehta@statsense.in>> <<mailto:vini.mehta@statsense.in>>>>,

Ankita Mathur <[amathur@statsense.in](mailto:amathur@statsense.in)> <<mailto:amathur@statsense.in>

<<mailto:amathur@statsense.in>> <<mailto:amathur@statsense.in>>>>,

Tanvi Sharma <[tan.sharma2@gmail.com](mailto:tan.sharma2@gmail.com)

<<mailto:tan.sharma2@gmail.com>> <<mailto:tan.sharma2@gmail.com>>>>,

Damini Chakraborty <[dchakraborty09@gmail.com](mailto:dchakraborty09@gmail.com)

<<mailto:dchakraborty09@gmail.com>

<<mailto:dchakraborty09@gmail.com>>

<<mailto:dchakraborty09@gmail.com>>>>, Priyanka Porwal

<[priyanka@statsense.in](mailto:priyanka@statsense.in)> <<mailto:priyanka@statsense.in>

<<mailto:priyanka@statsense.in>> <<mailto:priyanka@statsense.in>>>>, Aida

Meto

<[aida.meto@ual.edu.au](mailto:aida.meto@ual.edu.au)> <<mailto:aida.meto@ual.edu.au>

<<mailto:aida.meto@ual.edu.au>> <<mailto:aida.meto@ual.edu.au>>>>, Alexander

Maniangat Luke <[a.luke@ajman.ac.ae](mailto:a.luke@ajman.ac.ae)> <<mailto:a.luke@ajman.ac.ae>

<<mailto:a.luke@ajman.ac.ae>> <<mailto:a.luke@ajman.ac.ae>>>>,



Ajinkya M. Pawar <ajinkya@drpawars.com <mailto:ajinkya@drpawars.com> <mailto:ajinkya@drpawars.com <mailto:ajinkya@drpawars.com>>>

Dear Dr. Wahjuningrum,

Thank you very much for uploading the following manuscript to the MDPI submission system. One of our editors will be in touch with you soon.

Journal name: International Journal of Environmental Research and Public Health Manuscript ID: ijerph-1851381

Type of manuscript: Systematic Review Title: Evaluation of Root Anatomy and Canal Configuration of Human Permanent Maxillary First Molar Using Cone

Beam Computed Tomography: A Systematic Review Authors: Sourabh Barbhai, Rajesh Shetty, Poonam Joshi, Vini Mehta, Ankita Mathur, Tanvi Sharma, Damini Chakraborty, Priyanka Porwal, Aida Meto, Dian

Agustin Wahjuningrum \*, Alexander Maniangat Luke \*, Ajinkya M. Pawar \* Received: 21 July 2022 E-mails:

sourabhsb96@gmail.com

<mailto:sourabhsb96@gmail.com>

<mailto:sourabhsb96@gmail.com <mailto:sourabhsb96@gmail.com>>,

rajeshendo@gmail.com <mailto:rajeshendo@gmail.com>

<mailto:rajeshendo@gmail.com <mailto:rajeshendo@gmail.com>>,

dr.poonampande@gmail.com <mailto:dr.poonampande@gmail.com>

<mailto:dr.poonampande@gmail.com

<mailto:dr.poonampande@gmail.com>>, vini.mehta@statsense.in <mailto:vini.mehta@statsense.in>

<mailto:vini.mehta@statsense.in

<mailto:vini.mehta@statsense.in>>, amathur@statsense.in <mailto:amathur@statsense.in>

<mailto:amathur@statsense.in <mailto:amathur@statsense.in>>,

tan.sharma2@gmail.com <mailto:tan.sharma2@gmail.com>

<mailto:tan.sharma2@gmail.com <mailto:tan.sharma2@gmail.com>>,

dchakraborty09@gmail.com <mailto:dchakraborty09@gmail.com>

<mailto:dchakraborty09@gmail.com

<mailto:dchakraborty09@gmail.com>>, priyanka@statsense.in <mailto:priyanka@statsense.in>

<mailto:priyanka@statsense.in <mailto:priyanka@statsense.in>>,

aida.meto@ual.edu.al <mailto:aida.meto@ual.edu.al>

<mailto:aida.meto@ual.edu.al <mailto:aida.meto@ual.edu.al>>,

dian-agustin-w@fkg.unair.ac.id <mailto:dian-agustin-w@fkg.unair.ac.id>

<mailto:dian-agustin-w@fkg.unair.ac.id

<mailto:dian-agustin-w@fkg.unair.ac.id>>, a.luke@ajman.ac.ae <mailto:a.luke@ajman.ac.ae>

<mailto:a.luke@ajman.ac.ae <mailto:a.luke@ajman.ac.ae>>,

ajinkya@drpawars.com <mailto:ajinkya@drpawars.com>

<mailto:ajinkya@drpawars.com <mailto:ajinkya@drpawars.com>>

Submitted to section: Digital Health,

[https://www.mdpi.com/journal/ijerph/sections/Digital\\_Health](https://www.mdpi.com/journal/ijerph/sections/Digital_Health)

<[https://www.mdpi.com/journal/ijerph/sections/Digital\\_Health](https://www.mdpi.com/journal/ijerph/sections/Digital_Health)

<[https://www.mdpi.com/journal/ijerph/sections/Digital\\_Health](https://www.mdpi.com/journal/ijerph/sections/Digital_Health)

<[https://www.mdpi.com/journal/ijerph/sections/Digital\\_Health](https://www.mdpi.com/journal/ijerph/sections/Digital_Health)

Clinical and Experimental Approaches in Dental Health

[https://www.mdpi.com/journal/ijerph/special\\_issues/clinical\\_experimental\\_approaches\\_dental](https://www.mdpi.com/journal/ijerph/special_issues/clinical_experimental_approaches_dental)

<[https://www.mdpi.com/journal/ijerph/special\\_issues/clinical\\_experimental\\_approaches\\_dental](https://www.mdpi.com/journal/ijerph/special_issues/clinical_experimental_approaches_dental)

<[https://www.mdpi.com/journal/ijerph/special\\_issues/clinical\\_experimental\\_approaches\\_dental](https://www.mdpi.com/journal/ijerph/special_issues/clinical_experimental_approaches_dental)

<[https://www.mdpi.com/journal/ijerph/special\\_issues/clinical\\_experimental\\_approaches\\_dental](https://www.mdpi.com/journal/ijerph/special_issues/clinical_experimental_approaches_dental)

You can follow progress of your manuscript at the following link (login required):

[https://susy.mdpi.com/user/manuscripts/review\\_info/d8b741c871c3b2e1a9db88a80579efdf](https://susy.mdpi.com/user/manuscripts/review_info/d8b741c871c3b2e1a9db88a80579efdf)

<[https://susy.mdpi.com/user/manuscripts/review\\_info/d8b741c871c3b2e1a9db88a80579efdf](https://susy.mdpi.com/user/manuscripts/review_info/d8b741c871c3b2e1a9db88a80579efdf)>

<[https://susy.mdpi.com/user/manuscripts/review\\_info/d8b741c871c3b2e1a9db88a80579efdf](https://susy.mdpi.com/user/manuscripts/review_info/d8b741c871c3b2e1a9db88a80579efdf)>

<[https://susy.mdpi.com/user/manuscripts/review\\_info/d8b741c871c3b2e1a9db88a80579efdf](https://susy.mdpi.com/user/manuscripts/review_info/d8b741c871c3b2e1a9db88a80579efdf)>>

The following points were confirmed during submission:

1. IJERPH is an open access journal with publishing fees of 2500 CHF for an accepted paper (see

<https://www.mdpi.com/about/apc/>

<<https://www.mdpi.com/about/apc/>>

<<https://www.mdpi.com/about/apc/>

<<https://www.mdpi.com/about/apc/>>> for details). This manuscript, if

accepted, will be published under an open access Creative Commons CC BY license (<https://creativecommons.org/licenses/by/4.0/>

<<https://creativecommons.org/licenses/by/4.0/>>

<<https://creativecommons.org/licenses/by/4.0/>

<<https://creativecommons.org/licenses/by/4.0/>>>), and I agree to pay the Article Processing Charges as described on the journal webpage

(<https://www.mdpi.com/journal/ijerph/apc>

<<https://www.mdpi.com/journal/ijerph/apc>>

<<https://www.mdpi.com/journal/ijerph/apc>

<<https://www.mdpi.com/journal/ijerph/apc>>>). See

<https://www.mdpi.com/about/openaccess>

<<https://www.mdpi.com/about/openaccess>>

<<https://www.mdpi.com/about/openaccess>

<<https://www.mdpi.com/about/openaccess>>> for more information about open access publishing.

Please note that you may be entitled to a discount if you have previously received a discount code or if your institute is participating in the MDPI Institutional Open Access Program (IOAP), for more information see <https://www.mdpi.com/about/ioap>

<<https://www.mdpi.com/about/ioap>>

<<https://www.mdpi.com/about/ioap>

<<https://www.mdpi.com/about/ioap>>>. If you have been granted any other special discounts for your submission, please contact the IJERPH editorial office.

2. I understand that:

a. If previously published material is reproduced in my manuscript, I will provide proof that I have obtained the necessary copyright permission. (Please refer to the Rights & Permissions website: <https://www.mdpi.com/authors/rights>

<<https://www.mdpi.com/authors/rights>>

<<https://www.mdpi.com/authors/rights>

<<https://www.mdpi.com/authors/rights>>>).

b. My manuscript is submitted on the understanding that it has not been published in or submitted to another peer-reviewed journal. Exceptions to this rule are papers containing material disclosed at conferences. I confirm that I will inform the journal editorial office if this is the case for my manuscript. I confirm that all authors are familiar with and agree with submission of the contents of the manuscript. The journal editorial office reserves the right

---

## [IJERPH] Manuscript ID: ijerph-1851381 - Assistant Editor Assigned

1 pesan

---

Cynthia Mei <cynthia.mei@mdpi.com>

22 Juli 2022 pukul 14.54

Balas Ke: cynthia.mei@mdpi.com

Kepada: Dian Agustin Wahjuningrum <dian-agustin-w@fkg.unair.ac.id>

Cc: Cynthia Mei <cynthia.mei@mdpi.com>, Sourabh Barbhui <sourabhsb96@gmail.com>, Rajesh Shetty <rajeshendo@gmail.com>, Poonam Joshi <dr.poonampande@gmail.com>, Vini Mehta <vini.mehta@statsense.in>, Ankita Mathur <amathur@statsense.in>, Tanvi Sharma <tan.sharma2@gmail.com>, Damini Chakraborty <dchakraborty09@gmail.com>, Priyanka Porwal <priyanka@statsense.in>, Aida Meto <aida.meto@ual.edu.al>, Alexander Maniangat Luke <a.luke@ajman.ac.ae>, "Ajinkya M. Pawar" <ajinkya@drpawars.com>, IJERPH Editorial Office <ijerph@mdpi.com>

Dear Dr. Wahjuningrum,

Your paper has been assigned to Cynthia Mei, who will be your main point of contact as your paper is processed further.

Journal: International Journal of Environmental Research and Public Health

Manuscript ID: ijerph-1851381

Title: Evaluation of Root Anatomy and Canal Configuration of Hu-man Permanent Maxillary First Molar Using Cone Beam Computed Tomography: A Systematic Review

Authors: Sourabh Barbhui, Rajesh Shetty, Poonam Joshi, Vini Mehta, Ankita Mathur, Tanvi Sharma, Damini Chakraborty, Priyanka Porwal, Aida Meto, Dian Agustin Wahjuningrum \*, Alexander Maniangat Luke \*, Ajinkya M. Pawar \*

Received: 21 July 2022

E-mails: sourabhsb96@gmail.com, rajeshendo@gmail.com, dr.poonampande@gmail.com, vini.mehta@statsense.in, amathur@statsense.in, tan.sharma2@gmail.com, dchakraborty09@gmail.com, priyanka@statsense.in, aida.meto@ual.edu.al, dian-agustin-w@fkg.unair.ac.id, a.luke@ajman.ac.ae, ajinkya@drpawars.com

You can find it here:

[https://susy.mdpi.com/user/manuscripts/review\\_info/d8b741c871c3b2e1a9db88a80579efdf](https://susy.mdpi.com/user/manuscripts/review_info/d8b741c871c3b2e1a9db88a80579efdf)

Best regards,

Cynthia Mei

Section Managing Editor

E-Mail: cynthia.mei@mdpi.com

IJERPH: <http://www.mdpi.com/journal/ijerph/>

We are pleased to announce that IJERPH has been ranked with an improved Impact Factor of 4.614.

IJERPH (IF: 4.614, ISSN 1660-4601) is calling for Special Issue Proposals for the Summer of 2022:

<https://www.mdpi.com/journalproposal/sendproposalspecialissue/ijerph>. To request further information, please contact the IJERPH Editorial Office (cynthia.mei@mdpi.com).

Topical Advisory Panel is open for application. Welcome to join us!

[https://www.mdpi.com/journal/ijerph/topical\\_advisory\\_panel\\_application](https://www.mdpi.com/journal/ijerph/topical_advisory_panel_application)

IJERPH is seeking nominations and applications for the position of Section Editor-in-Chief (SEiC) for the following Sections:

<https://www.mdpi.com/journal/ijerph/announcements/3712>

to contact all authors to confirm this in case of doubt. I will provide email addresses for all authors and an institutional e-mail address for at least one of the co-authors, and specify the name, address and e-mail for invoicing purposes.

If you have any questions, please do not hesitate to contact the IJERPH editorial office at [ijerph@mdpi.com](mailto:ijerph@mdpi.com) <<mailto:ijerph@mdpi.com>> <<mailto:ijerph@mdpi.com>> <<mailto:ijerph@mdpi.com>>>

Kind regards, IJERPH Editorial Office St. Alban-Anlage 66, 4052 Basel, Switzerland

<<https://www.google.com/maps/search/St.+Alban-Anlage+66,+4052+Basel,+Switzerland?entry=gmail&source=g>

<<https://www.google.com/maps/search/St.+Alban-Anlage+66,+4052+Basel,+Switzerland?entry=gmail&source=g>>>

**E-Mail:** [ijerph@mdpi.com](mailto:ijerph@mdpi.com) <<mailto:ijerph@mdpi.com>> <<mailto:ijerph@mdpi.com>> <<mailto:ijerph@mdpi.com>>>

[Kutipan teks disembunyikan]

---

## [IJERPH] Manuscript ID: ijerph-1851381 - Major Revisions(by 15 August 2022)

1 pesan

---

**IJERPH Editorial Office** <ijerph@mdpi.com>

5 Agustus 2022 pukul 14.32

Balas Ke: cynthia.mei@mdpi.com

Kepada: Dian Agustin Wahjuningrum <dian-agustin-w@fkg.unair.ac.id>

Cc: Sourabh Barbhai <sourabhsb96@gmail.com>, Rajesh Shetty <rajeshendo@gmail.com>, Poonam Joshi <dr.poonampande@gmail.com>, Vini Mehta <vini.mehta@statsense.in>, Ankita Mathur <amathur@statsense.in>, Tanvi Sharma <tan.sharma2@gmail.com>, Damini Chakraborty <dchakraborty09@gmail.com>, Priyanka Porwal <priyanka@statsense.in>, Aida Meto <aida.meto@ual.edu.al>, Alexander Maniangat Luke <a.luke@ajman.ac.ae>, "Ajinkya M. Pawar" <ajinkya@drpawars.com>, IJERPH Editorial Office <ijerph@mdpi.com>

Dear Dr. Wahjuningrum,

Thank you again for your manuscript submission:

Manuscript ID: ijerph-1851381

Type of manuscript: Systematic Review

Title: Evaluation of Root Anatomy and Canal Configuration of Human Permanent Maxillary First Molar Using Cone Beam Computed Tomography: A Systematic Review

Authors: Sourabh Barbhai, Rajesh Shetty, Poonam Joshi, Vini Mehta, Ankita Mathur, Tanvi Sharma, Damini Chakraborty, Priyanka Porwal, Aida Meto, Dian Agustin Wahjuningrum \*, Alexander Maniangat Luke \*, Ajinkya M. Pawar \*

Received: 21 July 2022

E-mails: sourabhsb96@gmail.com, rajeshendo@gmail.com, dr.poonampande@gmail.com, vini.mehta@statsense.in, amathur@statsense.in, tan.sharma2@gmail.com, dchakraborty09@gmail.com, priyanka@statsense.in, aida.meto@ual.edu.al, dian-agustin-w@fkg.unair.ac.id, a.luke@ajman.ac.ae, ajinkya@drpawars.com

Submitted to section: Digital Health,

[https://www.mdpi.com/journal/ijerph/sections/Digital\\_Health](https://www.mdpi.com/journal/ijerph/sections/Digital_Health)

Clinical and Experimental Approaches in Dental Health

[https://www.mdpi.com/journal/ijerph/special\\_issues/clinical\\_experimental\\_approaches\\_dental](https://www.mdpi.com/journal/ijerph/special_issues/clinical_experimental_approaches_dental)

Your manuscript has now been reviewed by experts in the field. Please find your manuscript with the referee reports at this link:

<https://susy.mdpi.com/user/manuscripts/resubmit/d8b741c871c3b2e1a9db88a80579efdf>

Please revise the manuscript according to the referees' comments and upload the revised file by 15 August 2022.

Please use the version of your manuscript found at the above link for your revisions.

- (I) Please check that all references are relevant to the contents of the manuscript.
- (II) Any revisions to the manuscript should be marked up using the "Track Changes" function if you are using MS Word/LaTeX, such that any changes can be easily viewed by the editors and reviewers.
- (III) Please provide a cover letter to explain, point by point, the details of the revisions to the manuscript and your responses to the referees' comments.
- (IV) If you found it impossible to address certain comments in the review reports, please include an explanation in your rebuttal.
- (V) The revised version will be sent to the editors and reviewers.

If one of the referees has suggested that your manuscript should undergo extensive English revisions, please address this issue during revision.

**New Section Announcement—“Health-Related Quality of Life and Well-Being”**

More information regarding this Section can be found via the following link:

[https://www.mdpi.com/journal/ijerph/sections/health-related\\_quality\\_of\\_life\\_and\\_well-being](https://www.mdpi.com/journal/ijerph/sections/health-related_quality_of_life_and_well-being)

Disclaimer: MDPI recognizes the importance of data privacy and protection. We treat personal data in line with the General Data Protection Regulation (GDPR) and with what the community expects of us. The information contained in this message is confidential and intended solely for the use of the individual or entity to whom they are addressed. If you have received this message in error, please notify me and delete this message from your system. You may not copy this message in its entirety or in part, or disclose its contents to anyone.

---

**[IJERPH] Manuscript ID: ijerph-1851381 - Manuscript Resubmitted**

1 pesan

---

**IJERPH Editorial Office** <ijerph@mdpi.com>

9 Agustus 2022 pukul 20.14

Balas Ke: Cynthia Mei <cynthia.mei@mdpi.com>, IJERPH Editorial Office <ijerph@mdpi.com>

Kepada: Dian Agustin Wahjuningrum <dian-agustin-w@fkg.unair.ac.id>

Cc: Sourabh Barbhai <sourabh96@gmail.com>, Rajesh Shetty <rajeshendo@gmail.com>, Poonam Joshi <dr.poonampande@gmail.com>, Vini Mehta <vini.mehta@statsense.in>, Ankita Mathur <amathur@statsense.in>, Tanvi Sharma <tan.sharma2@gmail.com>, Damini Chakraborty <dchakraborty09@gmail.com>, Priyanka Porwal <priyanka@statsense.in>, Aida Meto <aida.meto@ual.edu.al>, Alexander Maniangat Luke <a.luke@ajman.ac.ae>, "Ajinkya M. Pawar" <ajinkya@drpawars.com>

Dear Dr. Wahjuningrum,

Thank you very much for resubmitting the modified version of the following manuscript:

Manuscript ID: ijerph-1851381

Type of manuscript: Systematic Review

Title: Evaluation of Root Anatomy and Canal Configuration of Hu-man Permanent Maxillary First Molar Using Cone Beam Computed Tomography: A Systematic Review

Authors: Sourabh Barbhai, Rajesh Shetty, Poonam Joshi, Vini Mehta, Ankita Mathur, Tanvi Sharma, Damini Chakraborty, Priyanka Porwal, Aida Meto, Dian Agustin Wahjuningrum \*, Alexander Maniangat Luke \*, Ajinkya M. Pawar \*

Received: 21 July 2022

E-mails: sourabh96@gmail.com, rajeshendo@gmail.com, dr.poonampande@gmail.com, vini.mehta@statsense.in, amathur@statsense.in, tan.sharma2@gmail.com, dchakraborty09@gmail.com, priyanka@statsense.in, aida.meto@ual.edu.al, dian-agustin-w@fkg.unair.ac.id, a.luke@ajman.ac.ae, ajinkya@drpawars.com

Submitted to section: Digital Health,

[https://www.mdpi.com/journal/ijerph/sections/Digital\\_Health](https://www.mdpi.com/journal/ijerph/sections/Digital_Health)

Clinical and Experimental Approaches in Dental Health

[https://www.mdpi.com/journal/ijerph/special\\_issues/clinical\\_experimental\\_approaches\\_dental](https://www.mdpi.com/journal/ijerph/special_issues/clinical_experimental_approaches_dental)

[https://susy.mdpi.com/user/manuscripts/review\\_info/d8b741c871c3b2e1a9db88a80579efdf](https://susy.mdpi.com/user/manuscripts/review_info/d8b741c871c3b2e1a9db88a80579efdf)

A member of the editorial office will be in touch with you soon regarding progress of the manuscript.

Kind regards,

IJERPH Editorial Office

Postfach, CH-4020 Basel, Switzerland

Office: St. Alban-Anlage 66, CH-4052 Basel

Tel. +41 61 683 77 34 (office)

E-mail: ijerph@mdpi.com

<https://www.mdpi.com/journal/ijerph/>

\*\*\* This is an automatically generated email \*\*\*

Do not hesitate to contact us if you have any questions regarding the revision of your manuscript. We look forward to hearing from you soon.

Kind regards,  
Cynthia Mei  
Section Managing Editor  
E-Mail: [cynthia.mei@mdpi.com](mailto:cynthia.mei@mdpi.com)  
IJERPH: <http://www.mdpi.com/journal/ijerph/>

We are pleased to announce that IJERPH has been ranked with an improved Impact Factor of 4.614.

IJERPH (IF: 4.614, ISSN 1660-4601) is calling for Special Issue Proposals for the Summer of 2022:

<https://www.mdpi.com/journalproposal/sendproposalspecialissue/ijerph>. To request further information, please contact the IJERPH Editorial Office ([cynthia.mei@mdpi.com](mailto:cynthia.mei@mdpi.com)).

Topical Advisory Panel is open for application. Welcome to join us!  
[https://www.mdpi.com/journal/ijerph/topical\\_advisory\\_panel\\_application](https://www.mdpi.com/journal/ijerph/topical_advisory_panel_application)

IJERPH is seeking nominations and applications for the position of Section Editor-in-Chief (SEiC) for the following Sections:  
<https://www.mdpi.com/journal/ijerph/announcements/3712>

New Section Announcement—"Health-Related Quality of Life and Well-Being"  
More information regarding this Section can be found via the following link:  
[https://www.mdpi.com/journal/ijerph/sections/health-related\\_quality\\_of\\_life\\_and\\_well-being](https://www.mdpi.com/journal/ijerph/sections/health-related_quality_of_life_and_well-being)

Disclaimer: MDPI recognizes the importance of data privacy and protection. We treat personal data in line with the General Data Protection Regulation (GDPR) and with what the community expects of us. The information contained in this message is confidential and intended solely for the use of the individual or entity to whom they are addressed. If you have received this message in error, please notify me and delete this message from your system. You may not copy this message in its entirety or in part, or disclose its contents to anyone.



---

## [IJERPH] Manuscript ID: ijerph-1851381 - Revised Version Received

1 pesan

---

**IJERPH Editorial Office** <ijerph@mdpi.com>

9 Agustus 2022 pukul 20.27

Balas Ke: shirley.li@mdpi.com

Kepada: Dian Agustin Wahjuningrum <dian-agustin-w@fkg.unair.ac.id>

Cc: Sourabh Barbhai <sourabhsb96@gmail.com>, Rajesh Shetty <rajeshendo@gmail.com>, Poonam Joshi <dr.poonampande@gmail.com>, Vini Mehta <vini.mehta@statsense.in>, Ankita Mathur <amathur@statsense.in>, Tanvi Sharma <tan.sharma2@gmail.com>, Damini Chakraborty <dchakraborty09@gmail.com>, Priyanka Porwal <priyanka@statsense.in>, Aida Meto <aida.meto@ual.edu.al>, Alexander Maniangat Luke <a.luke@ajman.ac.ae>, "Ajinkya M. Pawar" <ajinkya@drpawars.com>, IJERPH Editorial Office <ijerph@mdpi.com>

Dear Dr. Wahjuningrum,

Thank you very much for providing the revised version of your paper:

Manuscript ID: ijerph-1851381

Type of manuscript: Systematic Review

Title: Evaluation of Root Anatomy and Canal Configuration of Human Permanent Maxillary First Molar Using Cone Beam Computed Tomography: A Systematic Review

Authors: Sourabh Barbhai, Rajesh Shetty, Poonam Joshi, Vini Mehta, Ankita Mathur, Tanvi Sharma, Damini Chakraborty, Priyanka Porwal, Aida Meto, Dian Agustin Wahjuningrum \*, Alexander Maniangat Luke \*, Ajinkya M. Pawar \*

Received: 21 July 2022

E-mails: sourabhsb96@gmail.com, rajeshendo@gmail.com, dr.poonampande@gmail.com, vini.mehta@statsense.in, amathur@statsense.in, tan.sharma2@gmail.com, dchakraborty09@gmail.com, priyanka@statsense.in, aida.meto@ual.edu.al, dian-agustin-w@fkg.unair.ac.id, a.luke@ajman.ac.ae, ajinkya@drpawars.com

Submitted to section: Digital Health,

[https://www.mdpi.com/journal/ijerph/sections/Digital\\_Health](https://www.mdpi.com/journal/ijerph/sections/Digital_Health)

Clinical and Experimental Approaches in Dental Health

[https://www.mdpi.com/journal/ijerph/special\\_issues/clinical\\_experimental\\_approaches\\_dental](https://www.mdpi.com/journal/ijerph/special_issues/clinical_experimental_approaches_dental)

[https://susy.mdpi.com/user/manuscripts/review\\_info/d8b741c871c3b2e1a9db88a80579efdf](https://susy.mdpi.com/user/manuscripts/review_info/d8b741c871c3b2e1a9db88a80579efdf)

We will continue processing your paper and will keep you informed about the status of your submission.

Kind regards,

Ms. Shirley Li

Assistant Editor

Email: shirley.li@mdpi.com

IJERPH is recruiting Volunteer Reviewers:

<https://susy.mdpi.com/volunteer/journals/review>.

IJERPH (IF: 4.614, ISSN 1660-4601) is calling for Special Issue Proposals:

<https://www.mdpi.com/journalproposal/sendproposalspecialissue/ijerph>.

Topical Advisory Panel is open for application:

[https://www.mdpi.com/journal/ijerph/topical\\_advisory\\_panel\\_application](https://www.mdpi.com/journal/ijerph/topical_advisory_panel_application).

IJERPH is seeking nominations and applications for the position of Section Editor-in-Chief (SEiC) for the following Sections:

<https://www.mdpi.com/journal/ijerph/announcements/4096>

MDPI Branch Office, Tianjin

Room 1804, Block A, Lujiazui Financial Plaza, Hongqiao District, 300131

Tianjin, China

--

MDPI

IJERPH Editorial Office  
St. Alban-Anlage 66, 4052 Basel, Switzerland  
E-Mail: [ijerph@mdpi.com](mailto:ijerph@mdpi.com)  
<http://www.mdpi.com/journal/ijerph/>

---

Disclaimer: The information contained in this message is confidential and intended solely for the use of the individual or entity to whom they are addressed. If you have received this message in error, please inform us by an email reply and then delete the message. You may not copy this message in its entirety or in part, or disclose its contents to anyone.

---

## [IJERPH] Manuscript ID: ijerph-1851381 - Funding Information Confirmation

1 pesan

---

IJERPH Editorial Office <ijerph@mdpi.com>

14 Agustus 2022 pukul 10.22

Balas Ke: ijerph@mdpi.com, cynthia.mei@mdpi.com

Kepada: Sourabh Barbhui <sourabhsb96@gmail.com>, Rajesh Shetty <rajeshendo@gmail.com>, Poonam Joshi <dr.poonampande@gmail.com>, Vini Mehta <vini.mehta@statsense.in>, Ankita Mathur <amathur@statsense.in>, Tanvi Sharma <tan.sharma2@gmail.com>, Damini Chakraborty <dchakraborty09@gmail.com>, Priyanka Porwal <priyanka@statsense.in>, Aida Meto <aida.meto@ual.edu.al>, Dian Agustin Wahjuningrum <dian-agustin-w@fkg.unair.ac.id>, Alexander Maniangat Luke <a.luke@ajman.ac.ae>, "Ajinkya M. Pawar" <ajinkya@drpawars.com>  
Cc: IJERPH Editorial Office <ijerph@mdpi.com>, Cynthia Mei <cynthia.mei@mdpi.com>

Dear Authors,

When you submitted, you chose No Funding in the system. Your manuscript has now been accepted. Please carefully check and ensure that the funding information is correct in any places where it appears in your manuscript.

Manuscript ID: ijerph-1851381

Type of manuscript: Systematic Review

Title: Evaluation of Root Anatomy and Canal Configuration of Hu-man Permanent Maxillary First Molar Using Cone Beam Computed Tomography: A Systematic Review

Authors: Sourabh Barbhui, Rajesh Shetty, Poonam Joshi, Vini Mehta, Ankita Mathur, Tanvi Sharma, Damini Chakraborty, Priyanka Porwal, Aida Meto, Dian Agustin Wahjuningrum \*, Alexander Maniangat Luke \*, Ajinkya M. Pawar \*

Received: 21 July 2022

E-mails: sourabhsb96@gmail.com, rajeshendo@gmail.com, dr.poonampande@gmail.com, vini.mehta@statsense.in, amathur@statsense.in, tan.sharma2@gmail.com, dchakraborty09@gmail.com, priyanka@statsense.in, aida.meto@ual.edu.al, dian-agustin-w@fkg.unair.ac.id, a.luke@ajman.ac.ae, ajinkya@drpawars.com

Submitted to section: Digital Health,

[https://www.mdpi.com/journal/ijerph/sections/Digital\\_Health](https://www.mdpi.com/journal/ijerph/sections/Digital_Health)

Clinical and Experimental Approaches in Dental Health

[https://www.mdpi.com/journal/ijerph/special\\_issues/clinical\\_experimental\\_approaches\\_dental](https://www.mdpi.com/journal/ijerph/special_issues/clinical_experimental_approaches_dental)

You can check it at:

[https://susy.mdpi.com/user/manuscripts/review\\_info/d8b741c871c3b2e1a9db88a80579efdf](https://susy.mdpi.com/user/manuscripts/review_info/d8b741c871c3b2e1a9db88a80579efdf)

If you have any questions or if you require any modifications, please contact us.

Kind regards,  
Submission System

**[IJERPH] Manuscript ID: ijerph-1851381 - Payment Commitment Letter**

1 pesan

Cynthia Mei &lt;cynthia.mei@mdpi.com&gt;

15 Agustus 2022 pukul 16.02

Balas Ke: Cynthia Mei &lt;cynthia.mei@mdpi.com&gt;

Kepada: Sourabh Barbhui <sourabhsb96@gmail.com>, Rajesh Shetty <rajeshendo@gmail.com>, Poonam Joshi <dr.poonampande@gmail.com>, Vini Mehta <vini.mehta@statsense.in>, Ankita Mathur <amathur@statsense.in>, Tanvi Sharma <tan.sharma2@gmail.com>, Damini Chakraborty <dchakraborty09@gmail.com>, Priyanka Porwal <priyanka@statsense.in>, Aida Meto <aida.meto@ual.edu.al>, Dian Agustin Wahjuningrum <dian-agustin-w@fkg.unair.ac.id>, Alexander Maniangat Luke <a.luke@ajman.ac.ae>, "Ajinkya M. Pawar" <ajinkya@drpawars.com>  
Cc: MDPI Billing <billing@mdpi.com>, Cynthia Mei <cynthia.mei@mdpi.com>, Sherry Cao <sherry.cao@mdpi.com>, Bonnie Wang <bonnie.wang@mdpi.com>, Florence Wang <florence.wang@mdpi.com>, Robert Zhao <robert.zhao@mdpi.com>, Weldon Luo <weldon.luo@mdpi.com>, IJERPH Editorial Office <ijerph@mdpi.com>, Sourabh Barbhui <sourabhsb96@gmail.com>, Rajesh Shetty <rajeshendo@gmail.com>, Poonam Joshi <dr.poonampande@gmail.com>, Vini Mehta <vini.mehta@statsense.in>, Ankita Mathur <amathur@statsense.in>, Tanvi Sharma <tan.sharma2@gmail.com>, Damini Chakraborty <dchakraborty09@gmail.com>, Priyanka Porwal <priyanka@statsense.in>, Aida Meto <aida.meto@ual.edu.al>, Alexander Maniangat Luke <a.luke@ajman.ac.ae>, "Ajinkya M. Pawar" <ajinkya@drpawars.com>

Dear Authors,

Congratulations on the acceptance of your manuscript. In order to accelerate the publication of the manuscript, we kindly request that the author to whom the invoice is addressed sign and either stamp or fingerprint the following letter within 2 days to confirm your commitment to paying the article processing charge (APC) to MDPI. This will enable us to publish your paper before the payment is made. Please note that the signature should be handwritten, and the due date should be within one month. All the blanks should be filled.

Please click here to login and upload the Payment Commitment Letter:

<https://susy.mdpi.com/user/invoices>

(If you do not have an account, you can click here to register:

<https://susy.mdpi.com/user/register>)

Manuscript ID: ijerph-1851381

Type of manuscript: Systematic Review

Title: Evaluation of Root Anatomy and Canal Configuration of Hu-man Permanent Maxillary First Molar Using Cone Beam Computed Tomography: A Systematic Review

Authors: Sourabh Barbhui, Rajesh Shetty, Poonam Joshi, Vini Mehta, Ankita Mathur, Tanvi Sharma, Damini Chakraborty, Priyanka Porwal, Aida Meto, Dian Agustin Wahjuningrum \*, Alexander Maniangat Luke \*, Ajinkya M. Pawar \*

Thank you in advance for your cooperation.

Only official emails sent by MDPI (@mdpi.com) are valid. Please check that the sender's email is affiliated with @mdpi.com. We do not authorise any third party to provide email services. MDPI is the sole service provider, and therefore cannot be held liable for actions performed by any third party.

We look forward to hearing from you soon.

Kind regards,

Cynthia Mei

Section Managing Editor

E-Mail: [cynthia.mei@mdpi.com](mailto:cynthia.mei@mdpi.com)IJERPH: <http://www.mdpi.com/journal/ijerph/>

We are pleased to announce that IJERPH has been ranked with an improved Impact Factor of 4.614.

---

**[IJERPH] Manuscript ID: ijerph-1851381 - APC Invoice**

3 pesan

---

**MDPI Billing** <billing@mdpi.com>

14 Agustus 2022 pukul 10.29

Balas Ke: shuai.zhang@mdpi.com

Kepada: dian-agustin-w@fkg.unair.ac.id

Cc: Cynthia Mei <cynthia.mei@mdpi.com>, Billing Dpt <billing@mdpi.com>, IJERPH Editorial Office <ijerph@mdpi.com>

Dear Dr. Wahjuningrum,

Please find attached the invoice for your recently accepted paper. Follow this link to adjust the currency, change the address, or add comments, as necessary:

<https://susy.mdpi.com/user/manuscript/d8b741c871c3b2e1a9db88a80579efdf/invoice/1789315>.

For immediate payment by credit card, visit <https://payment.mdpi.com/1789315>.

If you would like to use a different method of payment, click here:

<https://www.mdpi.com/about/payment>. Please include the invoice ID (ijerph-1851381) as reference in any transaction.

APC invoice amount: 2500.00 CHF

Manuscript ID: ijerph-1851381

Type of manuscript: Systematic Review

Title: Evaluation of Root Anatomy and Canal Configuration of Human Permanent Maxillary First Molar Using Cone Beam Computed Tomography: A Systematic Review

Authors: Sourabh Barbhai, Rajesh Shetty, Poonam Joshi, Vini Mehta, Ankita Mathur, Tanvi Sharma, Damini Chakraborty, Priyanka Porwal, Aida Meto, Dian Agustin Wahjuningrum \*, Alexander Maniangat Luke \*, Ajinkya M. Pawar \*

Received: 21 July 2022

E-mails: sourabh96@gmail.com, rajeshendo@gmail.com, dr.poonampande@gmail.com, vini.mehta@statsense.in, amathur@statsense.in, tan.sharma2@gmail.com, dchakraborty09@gmail.com, priyanka@statsense.in, aida.meto@ual.edu.au, dian-agustin-w@fkg.unair.ac.id, a.luke@ajman.ac.ae, ajinkya@drpawars.com

Submitted to section: Digital Health,

[https://www.mdpi.com/journal/ijerph/sections/Digital\\_Health](https://www.mdpi.com/journal/ijerph/sections/Digital_Health)

Clinical and Experimental Approaches in Dental Health

[https://www.mdpi.com/journal/ijerph/special\\_issues/clinical\\_experimental\\_approaches\\_dental](https://www.mdpi.com/journal/ijerph/special_issues/clinical_experimental_approaches_dental)

We will publish your accepted paper in open access format immediately upon receipt of the article processing charge (APC) and completion of the editing process.

If you encounter any problems revising the invoice or cannot access the link, please contact [invoices@mdpi.com](mailto:invoices@mdpi.com)

Only official emails sent by MDPI (@mdpi.com) are valid. Please check that the sender's email is affiliated with @mdpi.com. We do not authorise any third party to provide email services. MDPI is the sole service provider, and therefore cannot be held liable for actions performed by any third party.

Thank you very much for your support of open access publishing.

Kind regards,  
Shuai Zhang

MDPI Billing Team

IJERPH (IF: 4.614, ISSN 1660-4601) is calling for Special Issue Proposals for the Summer of 2022:

<https://www.mdpi.com/journalproposal/sendproposalspecialissue/ijerph>. To request further information, please contact the IJERPH Editorial Office (cynthia.mei@mdpi.com).

Topical Advisory Panel is open for application. Welcome to join us!

[https://www.mdpi.com/journal/ijerph/topical\\_advisory\\_panel\\_application](https://www.mdpi.com/journal/ijerph/topical_advisory_panel_application)

IJERPH is seeking nominations and applications for the position of Section Editor-in-Chief (SEiC) for the following Sections:

<https://www.mdpi.com/journal/ijerph/announcements/3712>


New Section Announcement—"Health-Related Quality of Life and Well-Being"

More information regarding this Section can be found via the following link:

[https://www.mdpi.com/journal/ijerph/sections/health-related\\_quality\\_of\\_life\\_and\\_well-being](https://www.mdpi.com/journal/ijerph/sections/health-related_quality_of_life_and_well-being)

Disclaimer: MDPI recognizes the importance of data privacy and protection. We treat personal data in line with the General Data Protection Regulation (GDPR) and with what the community expects of us. The information contained in this message is confidential and intended solely for the use of the individual or entity to whom they are addressed. If you have received this message in error, please notify me and delete this message from your system. You may not copy this message in its entirety or in part, or disclose its contents to anyone.

---


 **Payment\_Commitment\_Letter-ijerph-1851381.pdf**

25K

MDPI  
St. Alban-Anlage 66  
4052 Basel, Switzerland  
Tel.: +41 61 683 77 34

Please check our Billing FAQ: [https://www.mdpi.com/about/apc\\_faq](https://www.mdpi.com/about/apc_faq)  
E-mail Accounting: [invoices@mdpi.com](mailto:invoices@mdpi.com)  
<http://www.mdpi.com/>

---

 Invoice\_MDPI\_ijerph-1851381\_2500.00CHF.pdf  
31K

---

agustin wahjuningrum Dian <[dian-agustin-w@fkg.unair.ac.id](mailto:dian-agustin-w@fkg.unair.ac.id)>  
Kepada: [shuai.zhang@mdpi.com](mailto:shuai.zhang@mdpi.com)

15 Agustus 2022 pukul 13.46

Dear Shuai Zhang  
Thank you so much for your support. Would you like to change currency to USD to make an easier payment in my office.  
warm regards

Dr. Dian Agustin Wahjuningrum, drg., SpKG(K)  
Fakultas Kedokteran Gigi Universitas Airlangga  
Scopus ID 57205320764  
Google Scholar ID mmNqITkAAAAJ

[Kutipan teks disembunyikan]

---

Shuai.Zhang <[shuai.zhang@mdpi.com](mailto:shuai.zhang@mdpi.com)>  
Kepada: agustin wahjuningrum Dian <[dian-agustin-w@fkg.unair.ac.id](mailto:dian-agustin-w@fkg.unair.ac.id)>  
Cc: invoices <[invoices@mdpi.com](mailto:invoices@mdpi.com)>, lanmei xie <[lanmei.xie@mdpi.com](mailto:lanmei.xie@mdpi.com)>

15 Agustus 2022 pukul 16.19

Dear Dr. Wahjuningrum,

Thank you for your message and support of open access.

Please find attached the revised invoice.

Let me know if you have any questions.

Best regards  
Shuai Zhang

MDPI Billing Team

MDPI  
St. Alban-Anlage 66  
4052 Basel, Switzerland  
Tel.: +41 61 683 77 34

Please check our Billing FAQ: [https://www.mdpi.com/about/apc\\_faq](https://www.mdpi.com/about/apc_faq)  
E-mail Accounting: [invoices@mdpi.com](mailto:invoices@mdpi.com)  
<http://www.mdpi.com/>

[Kutipan teks disembunyikan]

---

 Invoice\_MDPI\_ijerph-1851381\_2654.68USD.pdf

32K



---

## [IJERPH] Manuscript ID: ijerph-1851381 - Final Proofreading Before Publication

1 pesan

---

**IJERPH Editorial Office** <ijerph@mdpi.com>

15 Agustus 2022 pukul 17.15

Balas Ke: Qin Cai <qin.cai@mdpi.com>

Kepada: Dian Agustin Wahjuningrum <dian-agustin-w@fkg.unair.ac.id>

Cc: Sourabh Barbhai <sourabhsb96@gmail.com>, Rajesh Shetty <rajeshendo@gmail.com>, Poonam Joshi <dr.poonampande@gmail.com>, Vini Mehta <vini.mehta@statsense.in>, Ankita Mathur <amathur@statsense.in>, Tanvi Sharma <tan.sharma2@gmail.com>, Damini Chakraborty <dchakraborty09@gmail.com>, Priyanka Porwal <priyanka@statsense.in>, Aida Meto <aida.meto@ual.edu.al>, Alexander Maniangat Luke <a.luke@ajman.ac.ae>, "Ajinkya M. Pawar" <ajinkya@drpawars.com>, IJERPH Editorial Office <ijerph@mdpi.com>, qin.cai@mdpi.com, Cynthia Mei <cynthia.mei@mdpi.com>

Dear Dr. Wahjuningrum,

We invite you to proofread your manuscript to ensure that this is the final version that can be published and confirm that you will require no further changes:

At MDPI, we believe in the fast dissemination of sound, valid scientific knowledge. Once accepted for publication, we aim to ensure that research is published as soon as possible.

Please upload the final proofed version of your manuscript within 24 hours, and please remember that we are able to be flexible with this timeframe should you alert us. If you need more time, please inform the Assistant Editor of the expected date that you will be able to return the proofread version.

Manuscript ID: ijerph-1851381

Type of manuscript: Systematic Review

Title: Evaluation of Root Anatomy and Canal Configuration of Human Permanent Maxillary First Molar Using Cone Beam Computed Tomography: A Systematic Review

Authors: Sourabh Barbhai, Rajesh Shetty, Poonam Joshi, Vini Mehta, Ankita Mathur, Tanvi Sharma, Damini Chakraborty, Priyanka Porwal, Aida Meto, Dian Agustin Wahjuningrum \*, Alexander Maniangat Luke \*, Ajinkya M. Pawar \*

Received: 21 July 2022

E-mails: sourabhsb96@gmail.com, rajeshendo@gmail.com, dr.poonampande@gmail.com, vini.mehta@statsense.in, amathur@statsense.in, tan.sharma2@gmail.com, dchakraborty09@gmail.com, priyanka@statsense.in, aida.meto@ual.edu.al, dian-agustin-w@fkg.unair.ac.id, a.luke@ajman.ac.ae, ajinkya@drpawars.com

Submitted to section: Digital Health,

[https://www.mdpi.com/journal/ijerph/sections/Digital\\_Health](https://www.mdpi.com/journal/ijerph/sections/Digital_Health)

Clinical and Experimental Approaches in Dental Health

[https://www.mdpi.com/journal/ijerph/special\\_issues/clinical\\_experimental\\_approaches\\_dental](https://www.mdpi.com/journal/ijerph/special_issues/clinical_experimental_approaches_dental)

Please read the following instructions carefully before proofreading:

1) Download the manuscript from the link provided at the end of this message and upload the final proofed version via the second link. If you experience any difficulties, please contact the IJERPH Editorial Office.

2) Please use Microsoft Word's built-in track changes function to highlight any changes you make, or send a comprehensive list of changes in a separate document. Note that this is the \*last chance\* to make textual changes to the manuscript. Some style and formatting changes may have been made by the production team, please do not revert these changes.

3) All authors must agree to the final version. Check carefully that authors' names and affiliations are correct, and that funding sources are correctly acknowledged. Incorrect author names or affiliations are picked up by indexing databases, such as the Web of Science or PubMed, and can be difficult to correct.

After proofreading, final production will be carried out. Note that changes to the position of figures and tables may occur during the final steps. Changes can be made to a paper published online only at the discretion of the Editorial Office.

Please download the final version of your paper for proofreading here:

<https://susy.mdpi.com/user/manuscripts/proof/file/d8b741c871c3b2e1a9db88a80579efdf>

and upload here:

<https://susy.mdpi.com/user/manuscripts/resubmit/d8b741c871c3b2e1a9db88a80579efdf>

This manuscript includes supplementary materials, which you can find at the second link, above. Please note that citations and references in Supplementary files are permitted provided that they also appear in the reference list of the main text. Please ensure that you proofread your supplementary materials and upload them together with the manuscript.

We look forward to hearing from you soon.

Kind regards,  
Ms. Qin Cai  
Production Editor  
E-Mail: [qin.cai@mdpi.com](mailto:qin.cai@mdpi.com)



# CERTIFICATE OF PUBLICATION



Certificate of publication for the article titled:

Evaluation of Root Anatomy and Canal Configuration of Human Permanent Maxillary First Molar Using Cone-Beam Computed Tomography: A Systematic Review

Authored by:

Sourabh Barbhai; Rajesh Shetty; Poonam Joshi; Vini Mehta; Ankita Mathur; Tanvi Sharma;  
Damini Chakraborty; Priyanka Porwal; Aida Meto; Dian Agustin Wahjuningrum; Alexander Maniangat Luke;  
Ajinkya M. Pawar

Published in:

*Int. J. Environ. Res. Public Health* **2022**, Volume 19, Issue 16, 10160



# Evaluation of Root Anatomy and Canal Configuration of Human Permanent Maxillary First Molar Using Cone-Beam Computed Tomography: A Systematic Review

Sourabh Barbhai <sup>1</sup>, Rajesh Shetty <sup>1</sup>, Poonam Joshi <sup>1</sup>, Vini Mehta <sup>2</sup>, Ankita Mathur <sup>3</sup>, Tanvi Sharma <sup>3</sup>, Damini Chakraborty <sup>4</sup>, Priyanka Porwal <sup>3</sup>, Aida Meto <sup>5</sup>, Dian Agustin Wahjuningrum <sup>6,\*</sup>, Alexander Maniangat Luke <sup>7,8,\*</sup> and Ajinkya M. Pawar <sup>9,\*</sup>

<sup>1</sup> Department of Conservative Dentistry & Endodontics, Dr. D.Y. Patil Dental College and Hospital, Dr. D.Y. Patil Vidyapeeth, Pimpri, Pune 411018, Maharashtra, India  
<sup>2</sup> Department of Public Health Dentistry, Dr. D.Y. Patil Dental College and Hospital, Dr. D.Y. Patil Vidyapeeth, Pimpri, Pune 411018, Maharashtra, India  
<sup>3</sup> STAT SENSE, Srushti 10, Sector 1 D, Amba Township Pvt. Ltd., Trimandir, Adalaj 382421, Gujarat, India  
<sup>4</sup> Bhowal's Dental and Implant Clinic, Bengal GreenField Heights, Galaxy-6FS, beside Apollo Pharmacy, DJ Block (Newtown), Newtown, Kolkata 700136, West Bengal, India  
<sup>5</sup> Department of Dentistry, Faculty of Dental Sciences, University of Aldent, 1007 Tirana, Albania  
<sup>6</sup> Department of Conservative Dentistry, Faculty of Dental Medicine, Universitas Airlangga, Surabaya 60132, East Java, Indonesia  
<sup>7</sup> Department of Clinical Sciences, College of Dentistry, Ajman University, Ajman 346, United Arab Emirates  
<sup>8</sup> Centre of Medical and Bio-Allied Health Sciences Research, Ajman University, Ajman 346, United Arab Emirates  
<sup>9</sup> Department of Conservative Dentistry and Endodontics, Nair Hospital Dental College, Mumbai 400008, Maharashtra, India  
\* Correspondence: dian-augustin-w@fkg.unair.ac.id (D.A.W.); a.luke@ajman.ac.ae (A.M.L.); ajinkya@drpawars.com (A.M.P.)

## Citation:

Academic Editors: Paul B. Tchounwou and Takaaki Tomofuji

Received:

Accepted:

Published:

**Publisher's Note:** MDPI stays neutral with regard to jurisdictional claims in published maps and institutional affiliations.



**Copyright:** © 2022 by the author. Licensee MDPI, Basel, Switzerland. This article is an open access article distributed under the terms and conditions of the Creative Commons Attribution (CC BY) license (<https://creativecommons.org/licenses/by/4.0/>)

**Abstract:** The aim of this paper is to review the literature on root canal configuration (RCC) and the frequency of occurrence of a second mesiobuccal canal (MB) in human permanent maxillary first molars where cone-beam computed tomography (CBCT) is used. Online electronic databases such as PubMed-Medline, Embase, Scopus and Cochrane Library were searched using appropriate keywords from the earliest available date until 12th June 2022, without restriction on language. In the mesiobuccal root, type I was the most frequent (33.29%), followed by types II and IV (27.18% and 26.36%, respectively). Moreover, 68.2% of maxillary first molars had a second MB canal. For both the distobuccal and palatal roots, type I was the most prevalent, with 99.08% and 97.83% occurrence, respectively. All other types were infrequent. Type IRCC is most frequent in all the roots of the maxillary first molars. Hence, care must be taken during biomechanical preparation of the MB roots.

**Keywords:** canal configuration; root canal; Vertucci classification; permanent mandibular first molar; CBCT

## 1. Introduction

Dental caries is among the most common chronic diseases [1]. If left untreated it can progress and infect the pulp and, subsequently, the periapical tissues, leading to irreversible pulpitis or apical periodontitis, respectively. The treatment of choice is root canal therapy. The main aim of this therapy is to remove bacteria and infected materials from the pulp and periapical tissues and replace them with biocompatible material [2–4]. According to Siqueira JF et al. and Lin LM et al., complex root anatomy is the primary cause of endodontic treatment failure [5,6]. Among various races, and different individuals within the same race, the morphology of the pulp canal varies momentarily [7]. Thus, knowledge of the root canal's configuration is essential for endodontic success [8].



96  
97  
98  
99  
00  
01  
02  
03  
04  
05  
06  
07  
08  
09  
10  
11  
12  
13  
14  
15  
16  
17  
18  
19  
20  
21  
22  
23  
24  
25  
26  
27  
28  
29  
30  
A root may contain a simple canal that tapers and terminates into the apical foramen, or the configuration can be more complex, with multiple interconnecting canals, lateral branches and multiple foramina. Classifications of root canal configurations (RCCs) have been given by several authors. Weine was the first to classify canals present in one root into four types [9]. In 1984, Vertucci analyzed the canal anatomy and gave a classification with eight different types of canals [10]. Later, Sert and Bayirli added additional types to the Vertucci classification, giving a total of XXIII types of root canal configuration [11]. Recently, in 2017, Ahmed H et al. developed a new code system to classify root canals that also includes the number of roots present [12].

To navigate through these complex canal systems, proper radiographic aid is crucial. Radiography is essential in the diagnosis, treatment planning and success of endodontic therapy [13]. However, conventional radiographs only provide a two-dimensional view, resulting in the incomplete detection of root canals [14,15]. However, a detailed three-dimensional view of a tooth, along with its surrounding anatomical structure, is possible with the help of cone-beam computed tomography (CBCT) [16,17]. Blattner T et al. reported that CBCT acts as a much superior imaging method when compared with traditional radiographs in the diagnosis of second mesiobuccal canals [18]. In a study by Matherne et al. in 2008, it was found that while using digital radiographs, endodontists failed to detect at least one root in 40% of the tooth when compared with using CBCT [19]. Additionally, using CBCT as a methodology for in vivo studies aids in obtaining a greater number of samples, as it helps the analysis of full dentition of several patients collected from a specific population in a consecutive manner, thus allowing for adequate statistical analysis [20,21]. In human dentition, maxillary first molars are the second-most common teeth to undergo root canal treatment, immediately after the mandibular first molars [22]. Additionally, performing endodontic treatment of the mesiobuccal root of maxillary first molars is a challenge due to the significant prevalence of additional canals and morphological variations [23].

The main aim of this systemic review is to analyze the available studies on the prevalence of root canal configuration of maxillary first molar teeth assessed using CBCT to help dentists to successfully identify the root anatomy, and subsequently to perform endodontic treatment successfully.

## 31 32 33 34 35 36 37 38 39 40 41 42 43 44 45 46 47 48 **2. Materials and Methods**

This systematic review was conducted in accordance with the Preferred Reporting Items for Systematic Reviews and Meta-Analysis (PRISMA) statement guidelines [24]. The study protocol was registered and approved on the International Prospective Register of Systematic Reviews PROSPERO (Reg. No: CRD42021259436) before the start of the study.

### *2.1. Focused Question*

What is the prevalence of root canal configuration and frequency of occurrence of a second mesiobuccal canal in the human permanent maxillary first molars where cone-beam computed tomography (CBCT) is used?

### *2.2. Inclusion Criteria*

In vivo studies discussing the anatomy and canal configuration of permanent maxillary first molars were included. Only studies that used an in vivo CBCT methodology were included. The context included all of the in vivo studies carried out using CBCT, without excluding any country in the world. The population consisted of patients who had been subjected to CBCT, regardless of its diagnostic purposes. The primary outcome for this systematic review was to check the prevalence of root canal configurations of permanent maxillary first molars based on the Vertucci classification.

### 2.3. Exclusion Criteria

- Studies using any classifications other than Vertucci.
- Case reports, case series and reviews were excluded.

### 2.4. Search Strategy and Data Collection

A literature search was performed in four major electronic databases—PubMed-MEDLINE, Cochrane Library, Embase and Scopus—along with additional sources, such as Google Scholar, major journals, unpublished studies, conference proceedings and cross references. A comprehensive search to identify studies related to root anatomy and the canal morphology of permanent maxillary first molar teeth was conducted until 12 June 2022, utilizing keywords such as “Vertucci classification”, “maxillary first molars”, “root anatomy” and “root canal configuration”. No additional filters or language restrictions were kept while conducting the searches. Two authors independently carried out the literature search, reviewed the study articles and extracted data. The screening was performed in two stages. First, the titles and abstracts of all of the articles were reviewed, followed by full text screening. Those studies that fulfilled the selection criteria were processed for data extraction. Non-English language publications were translated into the English language using Google Translate [25]. The information was independently extracted by the two authors using specially-designed data-extraction forms utilizing Microsoft Excel software. Any disagreement was resolved by discussion between the authors. For each selected study, the following data were then extracted from a standard form (when available): author and year of publication, sample size, population, root number, root canal configuration, CBCT model and CBCT settings.

### 2.5. Quality Assessment

The checklist given by Martins JNR et al. in Preferred Reporting Items for Epidemiologic Cross-sectional Studies on Root and Root Canal Anatomy Using Cone-beam Computed Tomographic Technology was used for quality assessment [26]. The quality of the included articles was evaluated across 6 domains: title, keywords, aim, methodology, results and discussion. Two authors individually evaluated each topic in the abovementioned domains and gave a score of 1 (reported) or 0 (not reported) for each of the included articles.

## 3. Results

### 3.1. Search Selection and Results

After extensive searching, a total of 533 studies were identified, out of which 421 were duplicates. The remaining 112 studies underwent title and abstract screening, and 51 studies were selected for full text screening. Sixteen studies were excluded after full text screening. Thus, a total of 35 studies that met our inclusion criteria were processed for data extraction [27–61] (Figure 1).

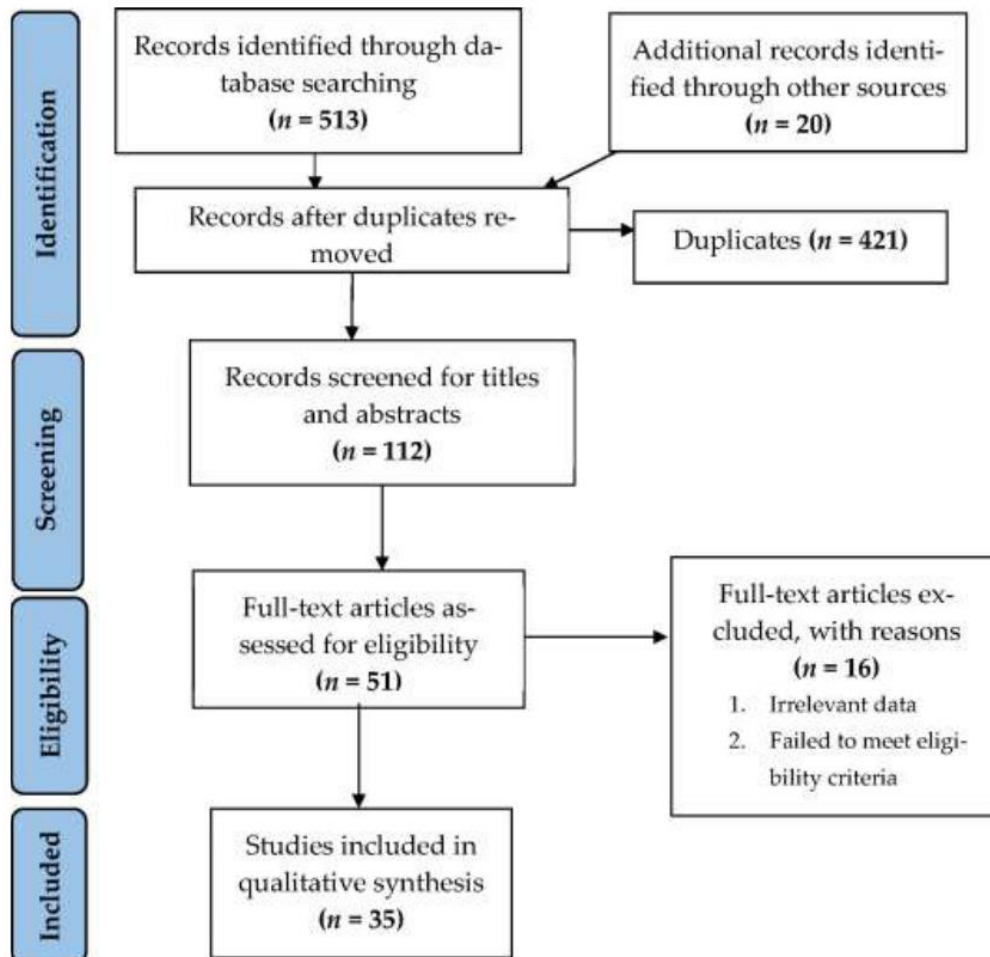


Figure 1. Flowchart summarizing the article selection process (n—number of studies).

### 3.2. Study Characteristics

The 35 included studies were conducted across the globe, with wide demographic variations, and a total of 17278 permanent maxillary first molar teeth were identified. Nearly all the studies were conducted on adult populations, except for two [45,48]. One study was based on variations in RCC among various age groups, and one of the selected age groups was younger than twenty years [45]. The second study was conducted among children of age groups ranging between 9 and 12 years. All studies provided details of CBCT specifications except for the study by Raja M et al., where details about the CBCT were not available [51]. The details of CBCT software, setting, field of view (FOV), voxel size and visualization software are shown in Table 1.

**Table 1.** Cone-beam computed tomography parameter values of each study.

Study/Year of Publication	Country	CBCT Model	Voxel Size	FOV	Settings CBCT	Software Visualization
Zang R et al./2011 [27]	China	3D Accuotomo scanner (Morita, Kyoto, Japan)	0.125 mm	40 mm × 60 mm	80 kV and 5.0 mA, time 17 s	i-Dixel one volume viewer 1.5.0 and a Dell Precision 15400 workstation (Dell, Round Rock, TX, USA)
Kim Y et al./2012 [28]	Korea	Dinnova system (Willmed, Gwangmyeong, Korea)	0.167-mm <sup>3</sup>	10 cm	80 kVp, 9.0 mA	OnDemand3D software (Cybermed, Seoul, Korea)
Tocci L et al./2013 [29]	Italy	NewTom VGi Vertical Cone Beam (Verona, Italia)	0.3 mm	243 cm	110 Kvp, 1–20 mAs, 15 mSv	NA
Guo J et al./2014 [30]	USA	Sirona Galileos device (Sirona Dental Systems, Inc, Long Island City, NY, USA)	0.3/0.15 mm.	15 cm	85 kV and 5 mA	The Digital Imaging and Communications in Medicine (DICOM) format images were exported from Galileos and imported into InVivo Dental Application 5.1.6 software (Anatomage Inc., San Jose, CA, USA).
Altunsoy M et al./2014 [31]	Turkey	CBCT scanner (ICAT Vision; Imaging Science International, Hatfield, USA)	0.3 mm	NA	120 kVp, and 18.5 mA, 8 s	NA
Abarca J. et al./2015 [32]	Italy	Gendex CB500 imaging system	0.2 mm	286 A	120 kVp and 5 mA and 0.2 mm thickness of the cut	iCATVision software v 1.8.1.10 in a darkroom on 21" LCD monitors with a resolution of 1280 × 1024 pixels.
Kalender A et al./2015 [33]	Italy	Newtom 3G: Quantitative Radiology s.r.l, Verona, Italy	NA	9 inch	NA	NNT 4.6, QR Verona, Italy
Naseri M et al./2016 [34]	Iran	NewTom VGi (QR Company, Verona, Italy)	200 µm	8 × 12 cm	110 kVp and exposure time of 3.6 s	NewTom NNT software version 5.3 (Quantitative Radiology, Verona, Italy)
Tian X et al./2018 [35]	China	NewTom VG; QR Sirona, Italy	0.16 mm	500 cm <sup>2</sup> (20 × 25 cm)	110 kVp and 10 s	NNT software version 2.21 (ImageWorks, Elmsford, NY, USA)
Martins J.N.R et al./2016(I) [36]	Portugal	Planmeca scanner (Planmeca ProMax, Planmeca, Finland)	0.2 mm	NA	80 kv, 15 mA, 12 s	Planmeca Romexis, Planmeca
Al-Kadhumi et al./2017 [37]	Malaysia	NA	NA	NA	NA	One Data Viewer software (J. Morita Manufacturing Corp).
Perez Met al./2017 [38]	Spain	9300 3D CBCT (Carestream Dental Atlanta, GA, USA)	0.18 mm	10 × 10 cm	90 kV, 4 mA, 8 s	Carestream software (CS 3D Imaging software 6.1.4)
Zand V et al./2017 [39]	Iran	NewTom GI CBCT (Verona/Italy)	NA	NA	110 kVp, 18 s	NNT viewer software program
Ghobasby et al./2017 [40]	Egypt	Cranex 3D (Soredex Tuusula, Finland)	133-µm	NA	80 kVp, 9.0 mA	NA
Al-Shehri et al./2017 [41]	Saudi Arabia	1. I-CAT (Imaging Science International, Hatfield, PA, USA), 2. Galileos (Sirona Dental Systems, Bensheim, Germany), 3. Carestream CS9300 (Carestream Health, Inc., Rochester, NY, USA).	0.3 mm (14-bit grayscale)	NA	85 kV, 5–7 mA	OnDemand3D software (Cybermed, Seoul, Korea)
Wang H et al./2017 [42]	China	Planmeca Romexis CBCT scanner (Planmeca, Finland)	200 µm	400 NA	84 kV and 14 mA, 12 s, the minimum slice thickness was 0.2 mm.	The CBCT images were 3D-reconstructed by using a patented Feldkamp reconstruction algorithm, analysed with inbuilt software and ran in a 32-bit Windows 7 system.
Khademi A et al./2017[43]	Iran	Galileos (Sirona Dental Systems Inc., Bensheim, Germany)	150 µm	150 × 150 or 75 × 150 mm	85 kVp, 42 mA	SIDEXIS XG software version 3.7 (Sirona Dental System GmbH, Bensheim, Germany).



Ghoncheh Z/2017 [44]	412 418 419	NewTom VG CBCT system (Image Works Verona, Italy)	0.3 mm	414 (11 × 16 cm)	110 kV, 1–20 mA, 3.6–5.4 s.	NNT Viewer software (NNT 2.21; Image Works, Verona, Italy).	
Martins J.N.R et al./2018(II) [45]	420 421 432	Planmeca Promax, Planmeca, Helsinki, Finland	0.20 mm	NA	80 kV, 15 mA, 12 s	Romexis visualization software (Planmeca)	
Martins J.N.R et al./2018(III) [46]	China Portugal	Kodak 9500 Planmeca Promax	0.2 mm	Full Arch	90 kV, 10 mA, 10.8 s 80 kV, 15 mA, 12 s	CS 900 3D imaging Planmeca Romexis	
Razmus et al./2014 [47]	441 442 443	Moscow 3D eXam (Kavo Biberach, Germany)	0.3 mm	23 cm	110 kV, 1.6–20 s	g I-CAT viewer software (version 10, Hatfield, England).	
Ratanajirasul et al./2018 [48]	452 453 454	3D Accuitomo CBCT machine (J Morita Manufacturing Corp, Kyoto, Japan)	0.25 mm × 0.24 mm	100.025 × 100.025	80 kVp, 5 mA, 11.2 s	g One Volume Viewer software (J Morita Manufacturing Corp)	
Martins J.N.R et al./2018(IV) [49]	455 468	Portugal Planmeca Promax	0.2 mm		80 kV, 15 mA, 12 s	Planmeca Romexis	
Alves C et al./2018 [50]	469 473 474 475 476 477 478	476 477 478 479 480 481 482 483 484 485 486 487	Prexion 3D Elite model XP68 (PreXion Inc., San Mateo, California, USA),	0.15 mm (for FOV 8) and 0.11 mm (for FOV 5)	90 Kvp and 4 mAs	3D software PreXion Image Analysis System (PreXion Inc. San Mateo, California, USA)	
Raja M et al./2018 [51]	493 499	India NA	NA	502 503 504 505	5 [5.6 cm × 5.2 cm (partial jaw)] or 8 [8.1 cm × 7.5 cm (full jaw)]	The CBCT scanner was set at a constant slice thickness of 0.25 μm/slice	
Pan YJ et al./2019 [52]	500 501 513 514	515 516 517 519 520	Malaysia KaVo 3D eXam imaging system (Imaging Sciences International, Hatfield, PA, USA).	0.25 mm	NA	121 kVp, 5 mA, 5.2 s	eXam Vision software version 1.9.3.13 (KaVo Dental GmbH, Biberach, Germany)
Mohara N et al./2019 [53]	527 528	518 521 522	Brazil a 3D Accuitomo 80 CBCT (J. Morita, Kyoto, Japan)	NA	40 mm or 60 mm	90 KVA, 8 mA, 18 s	i-Dixel (J Morita, Tokyo, Japan)
Candeiro GT et al./2019 [54]	529 530	531 532 533	Portugal Prexion 3D imaging vice (Prexion, Inc., San Mateo, USA)	0.125 mm	NA	90 kVp and 4 mA	(Prexion, Inc., San Mateo, USA) was used on a Dell Precision T5400 (Dell, Round Rock, TX, USA)
Soh N et al./2019 [55]	538 548 549	540 541 542	India NA				
Al Mheideb et al./2019 [56]	550 551 552 553 554	555 556 557 558 559	United Arab Emirates Planmeca ProMax CBCT scanner (Planmeca Oy, Helsinki, Finland)	0.4 mm	16 × 11 cm	120 kVp, 18.54 mA, 3.9 s	iMAC computer ([27-in. screen size with Retina 5 K display, 5120 × 2880 resolution with support for 1 billion colors, 500 nits brightness], Apple, USA) in a room with controlled lighting using the Horos DICOM viewer
Alsaket YM et al./2020 [57]		Jordan Carestream Dental, Rochester, NY, USA	NA	NA	NA	NA	NA
Liu Y et al./2020 [58]		China NewTom VG scanner (QR srl, Verona, Italy)	0.125 mm	Small	NA	NA	3D reconstructed with an open source software platform 3D Slicer 4.8.1 from Slicer web site
Popovic M et al./2020 [59]		Serbia Orthophos XG 3D device (Sirona Dental Systems GmbH, Bensheim, Germany)	160 μm	0.16 mm	NA	NA	GALAXIS v1.9.4 (Sirona Dental Systems GmbH, Bensheim, Germany)
Al-Saedi A et al./2020 [60]		Iraq Gendex (GXDP-7000) CBCT machine (Hatfield, PA, USA)	200 μm	80.0 × 80.0 × 80.0 mm	90 kV, 10 mA, 13 s	NA	Software GxPicture; Kavo Dental, Biberach a der Riss, Germany built into the Invivo 5 dental viewer (Anatomage, San Jose, CA, USA) and run on a 64-bit Windows 7 system (Microsoft Corporation, Redmond, WA, USA)
Nikkerdar N et al./2020 [61]		Iran New Tom VGi CBCT system (QR SRL Co., Verona, Italy)	0.15 mm	120 × 80 mm	110 kVp, 10 mA, 5.4 s	NA	NNT Viewer version 7.2 software on a 12.5-inch laptop (Asus) with 1080 × 1920 p resolution

CBCT: cone beam computed tomography, FOV: field of view, mm: millimeter, μm: micrometer, kVp: kilovoltage peak mA: milliampere, s: seconds, mSv: millisievert.

### 3.3. Outcome

In total, 35 studies presented data on the canal configuration of maxillary first molars based on the Vertucci classification [27–61]. The concurred data for most of these studies included both the percentage of occurrence and the number of cases. For a few studies, only the percentage of occurrence was given, and the exact value of the number of teeth for each specific canal type was calculated from the given percentage and sample size (number of teeth) taken for the study. To draw a definite conclusion among the myriad of data extracted from the studies and to interpret the data properly, each type's total percentage was calculated for the mesiobuccal (MB), second mesiobuccal (MB2), distobuccal (DB) and palatal (P) canals separately.

### 3.4. Prevalence of Canal Configuration of Mesiobuccal Root Based on Vertucci Classification

Different studies, 31 of them, have reported the root canal configurations of the mesiobuccal root of the maxillary first molar [27–31,33–49,51–56,58,59,61]. The data from the studies were pooled to find the mean of all eight types of canal configurations based on Vertucci classification. Among them, type I was the most frequent, with 33.29%, followed by types II and IV with 27.18% and 26.36%, respectively.

### 3.5. Prevalence of Canal Configuration of the Second Mesiobuccal Root Based on Vertucci Classification

Only four studies reported the canal configuration of the second mesiobuccal root. Type II was seen to be the most frequent with 37.4%, followed by type IV and type I with 22.9% and 20.3%, respectively [32,50,57,60].

### 3.6. Prevalence of Canal Configuration of the Distobuccal Root Based on Vertucci Classification

Another 23 studies reported the canal configuration of the distobuccal root of the maxillary first molar [28–31,33–36,38,40,41,44–49,51–53,55,56,61]. Out of these, type I was the most prevalent, with a range from 97.83% to 99.08% occurrence.

### 3.7. Frequency of Occurrence of Second Mesiobuccal Canal

Additionally, 25 studies reported the presence of a second mesiobuccal canal. Out of the 12056 teeth, a total of 8223 teeth showed the occurrence of MB2 canals, i.e., 68.2% occurrence [27–30,32,35–37,39,40–44,46–48,50–57] (Table 2).

**Table 2.** Prevalence of MB2 canals in maxillary first molars.

Study/Year of Publication	Sample Size (n)	Population	MB2 Canals n(%)
Zang R et al./2011 [27]	299	China	155(52%)
Kim Y et al./2012 [28]	814	Korea	510(62.65%)
Tocci L et al./2013 [29]	161	Italy	62(40.3%)
Guo J et al./2014 [30]	628	USA	428(68.2%)
Abarca J. et al./2015 [32]	802	Chile	802 (73.44%)
Tian X et al./2016 [35]	1536	China	820 (53.9%)
Martins J.N.R et al./2016(I) [36]	421	Malaysia	191(45.6%)
Al-Kadhim A et al./2017 [37]	494	Portugal	350(71.05%)
Zand V et al./2017 [39]	156	Iran	86(55.11%)
Ghobasby A et al./2017 [40]	605	Egypt	451(74.5%)
Al-Shehri S et al./2017 [41]	330	Saudi Arabia	195(55.6%)
Wang H et al./2017 [42]	939	China	641(68.3%)
Khademi A et al./2017 [43]	389	Iran	272(70.2%)
Ghoncheh Z/2017 [44]	337	Iran	155(46%)
Martins J.N.R et al./2018(III) [46]	239	China	552(67.35%)
Razmuvo S et al./2018 [47]	410	Moscow	382(59.8%)
Ratanajirasut et al./2018 [48]	476	Thai	303(63.6%)

Alves CRG et al./2018 [50]	362	Brazil	247(68.23%)
Raja M et al./2018 [51]	500	Indian	400(80%)
Pan YJ et al./2019 [52]	344	Malaysia	125(36.3%)
Mohara NT et al./2019 [53]	326	Brazil	209(64.22%)
Candeiro GTM et al./2019 [54]	700	Brazil	337(48.21%)
Soh N et al./2019 [55]	66	India	20(30%)
Al Mheiri E et al./2019 [56]	522	United Arab Emirates	418(80.1%)
Alsaket YM et al./2020 [57]	200	Jordan	174(87%)
<b>Total</b>	<b>12056</b>		<b>8223(68.2%)</b>

### 3.8. Quality Assessment

All included studies reported the following domains: aim of the study, morphology concept, assessment methodology, sample size and generalizability of the outcomes. Future research was the least reported domain, followed by the strengths and limitations of the study design. In the title, all studies mentioned CBCT but failed to indicate the type of study being conducted, except for one study by Kalender et al. which mentioned both [33] (Table 3).

**Table 3.** Specific preferred reporting items for cross-sectional studies on root and root canal anatomy using cone-beam computed tomography (CBCT).

Sr. No.	Section Item	Total (n)	Percentage (%)
1	Title	33	94.29
<b>Introduction</b>			
2	Keywords	32	91.43
3	Aim	35	100.00
<b>Methods</b>			
4	Participants (in vivo assessment)	33	94.29
5	CBCT	33	94.29
6	Morphology concept & assessed teeth (variables)	35	100.00
7	Assessment	35	100.00
8	Observers	27	77.14
9	Potential sources of bias	21	60.00
10	Final sample size	35	100.00
11	Reliability	25	71.43
12	Statistical analysis	33	94.29
13	Ethics committee Results	24	68.57
14	Primary Outcomes	34	97.14
15	Other analysis	28	80.00
16	Visual documentation Support	31	88.57
<b>Discussion</b>			
17	Outcome interpretation	35	100.00
18	Strength & limitations	23	65.71
19	Generalizability	35	100.00
20	Future research	5	14.29

## 4. Discussion

Before discussing the results, it must be noted that all the studies had variable CBCT settings and specifications. This, along with the demographic variations in the samples across the studies, will have some influence on the results. Among the studies included for this systematic review, three rooted maxillary first molars were most commonly reported. A similar finding was reported by Peris R et al. [62]. Some studies reported the presence of roots as being one, two and four, although these were infrequent [28,29,35,41,44,48]. Only three studies reported the RCC of maxillary molars with four roots, while only one study by Tian et al. in a Chinese population reported the RCC of the

maxillary first molar with only one root [35,44,48]. Al-Shehri S et al. also reported the presence of fused roots along with RCC among maxillary first molars [41].

The main outcome of this systematic review was to determine the prevalence of RCC among maxillary first molars. Most studies reported a higher prevalence of Vertucci types I, II and IV in the mesiobuccal root. After pooling the data from all the studies, type I was observed as the most prevalent type in MB roots, with 33.29% occurrence. Types II and IV had similar prevalence rates of 27.18% and 26.36%, respectively. Our findings are similar to those of other studies, which show type I to be the most prevalent, followed by types II and IV [63,64]. In a comparative study by Peris R et al. on Sri Lankan and Japanese populations, the same trend was seen for the Japanese population, but for Sri Lanka, the second most common was type V [62]. In two studies, type V was reported to have a higher frequency of occurrence [27,42]. Both of these studies were conducted on the Chinese population. In the study by Zang et al., among 299 tooth samples, 70% had type V, making it the most prevalent RCC type [27]. In the rest of the studies, other RCC types were infrequent and had a very low percentage of occurrence [28–41,43–61]. Among 15196 teeth samples, only 0.36% of mesiobuccal roots were reported to have root canal configurations outside of the Vertucci classification, and only 9 studies out of 35 reported this finding [28,33,35,41,46,48,49,53]. In particular, four studies reported the root canal configuration of the second mesiobuccal canal [32,50,51,60]. All of them reported type II as the most frequently occurring RCC, followed by type III and type I. Among the four studies, a sample size of 2019 teeth, was present, of which 37.4% were type II [32,50,51,60]. None of the studies reported findings for type VIII.

The root canal configuration of the distobuccal and palatal roots was less complex. Both of these roots mostly had a single root canal. All studies, with no exception, reported type I as the most frequent root canal configuration in both the distobuccal and palatal roots. All other types were infrequent. Among the 11660 tooth samples, 97.83% of palatal roots and 99.08% of distobuccal roots had type I RCC. Thus, in all three roots, mesiobuccal, distobuccal and palatal, type I was the most prevalent root canal configuration in maxillary first molars. This finding is similar to three other studies that highlight a higher prevalence of type I and a very low frequency of occurrence in all other types in both distobuccal and palatal roots [61,65–67].

Twenty-five authors acknowledged the presence of an additional mesiobuccal canal, and most of them reported a higher prevalence of MB2 canals [27–30,32,35–37,39–44,46–48,50–57]. In the study by Soh et al. on the Indian population, the frequency of occurrence of MB2 canals was the lowest, at only 30% [55]. Alsaket YM et al. in 2020 reported a maximum frequency of MB2 canals of 87% in their study on the population of Jordan.[57] The mean percentage of MB2 canals was 68.2%. Faraj BM in 2021 concluded that the MB2 canal was found in 53.78% of the teeth. In a study performed by Martins et al. looking at the worldwide prevalence of MB2 canals using CBCT, the overall prevalence was 73.8% [68]. Bentancourt P et al. found 69.82% of MB2 canals in their study on 1100 maxillary molars using CBCT [69]. Even though the CBCT specifications changed across the studies, the Newtom CBCT scanner was the most commonly used scanner. All the studies had a similar methodology for the assessment of the CBCT scans. Experienced endodontists or radiologists viewed the CBCT in 3 planes: axial, coronal and sagittal. For the identification of root anatomy, CBCT is a much better diagnostic tool than periapical radiography [70]. Abuabara A et al. reported that periapical radiographs can detect only 8% of MB2 canals, while with the help of CBCT, a second mesiobuccal canal can be detected in 54% of teeth [71]. Maxillary molars with 2 canals are frequently misdiagnosed, and 78.4% of MB2 canals remain unfilled.[72] Due to the higher presence of unexpected root canals in the maxillary mesiobuccal root, the chances of root canal treatment failure are higher [72,73]. However, in the distobuccal and palatal roots, the anatomy was simple. Type I RCC was highly prevalent, and the number of canals was mostly limited to one per root. Thus, the chances of missing a root canal or failed root canal therapy are lower. In this systematic review, we found that the mesiobuccal roots most commonly have type I RCC, followed

94  
95  
96 by types II and IV. Gaêta-Araujo H et al. found that most teeth without endodontic technical errors had type I RCC [74]. If technical errors are present with type I, they are due to  
97 underfilling or nonhomogenous filling [75,76].  
98

99 The sample sizes (number of teeth) among the studies varied. Thus, the percentages  
00 of studies with a small sample size (number of teeth) were higher, even though we tried  
01 to obtain a conclusive finding by calculating the percentages. Hence, pooling the data to  
02 find an overall mean percentage helped us to achieve a more conclusive result. However,  
03 our study has certain limitations. The inclusion criteria only helped to establish homogeneity  
04 among the methodologies used in various studies. However, the data collected had  
05 samples of patients from all age groups, genders and from different parts of the world,  
06 with varied ethnicities and genetic predispositions. These factors might have influenced  
07 the findings. Additionally, even though only studies using CBCT as a methodology were  
08 included, the CBCT parameters and specifications across all of the studies were not the  
09 same. In future studies, a more selective CBCT specification and data pooling based on  
10 ethnicities can be conducted to obtain more homogeneous results. The use of a limited-  
11 view CBCT device with specified resolution and lower voxel size will provide superior  
12 image quality, helping to explore the root and canal morphology more accurately. Root  
13 canal systems of maxillary first molars are complex and unpredictable. They vary among  
14 populations, and even in individuals in the same population. Cohort studies, in which the  
15 same individuals are observed over time, are necessary to analyze and describe various  
16 factors, such as age, which can determine whether MB canals narrow or calcify in a canal,  
17 and whether age can affect the number and size of the MB canals in maxillary molars.  
18  
19

## 20 5. Conclusions

21 From this systematic review, we can conclude that type I RCC is most frequent, based  
22 on the Vertucci classification of the maxillary first molars. Palatal and distobuccal roots  
23 have a more-or-less simple anatomy, with one canal and mostly type I configuration.  
24 However, the mesiobuccal root has a more complex anatomy due to the high frequency  
25 of occurrence of a second mesiobuccal canal; furthermore, in the mesiobuccal root, the  
26 occurrence of type II RCC, which is closely followed by type IV RCC, is more common.  
27 Hence, care must be taken during biomechanical preparation of the mesiobuccal roots.  
28 CBCT can act as an auxiliary to help endodontists obtain a better visualization of the anatomy  
29 of the mesiobuccal root and help in detecting additional canals, thus ensuring successful  
30 endodontic treatment.

31 **Author Contributions:** Conceptualization, S.B. and V.M.; methodology, P.J. and A.M. (Aida Meto);  
32 software, V.M.; validation, R.S., A.M. (Ankita Mathur) and D.C.; formal analysis, D.C.; investigation,  
33 T.S.; resources, P.P.; data curation, D.C.; writing—original draft preparation, V.M.; writing—review  
34 and editing, V.M.; visualization, D.C., A.M.P., D.A.W. and A.M.L.; supervision, R.S.; project administration,  
35 A.M. (Ankita Mathur). All authors have read and agreed to the published version of the  
36 manuscript.

37 **Funding:** This research received no external funding.

38 **Institutional Review Board Statement:** Page: 10  
39 Not applicable.

40 **Informed Consent Statement:** Not applicable.

41 **Data Availability Statement:** The reported systematic review and meta-analysis is registered with  
42 PROSPERO reg no.: CRD42021259436 available at [https://www.crd.york.ac.uk/prospero/export\\_details\\_pdf.php](https://www.crd.york.ac.uk/prospero/export_details_pdf.php) (accessed on 13 August 2022).  
43

44 **Conflicts of Interest:** The authors declare no conflict of interest.  
45

## 46 References

- 47 1. Selwitz, R.H.; Ismail, A.I.; Pitts, N.B. Dental Caries. *Lancet* **2007**, *369*, 51–59. [https://doi.org/10.1016/S0140-6736\(07\)60031-2](https://doi.org/10.1016/S0140-6736(07)60031-2).  
48 2. Schilder, H. Cleaning and Shaping the Root Canal. *Dent. Clin. N. Am.* **1974**, *18*, 269–296.



3. Iandolo, A.; Michele, S.; Stefano, O.; Sandro, R. 3D Cleaning, a Perfected Technique: Thermal Profile Assessment of Heated Naocl. *G. Ital. Endod.* **2017**, *31*, 58–61. <https://doi.org/10.1016/j.gien.2017.02.001>.
4. Iandolo, A.; Abdellatif, D.; Pantaleo, G.; Sammartino, P.; Amato, A. Conservative Shaping Combined with Three-Dimensional Cleaning Can Be a Powerful Tool: Case Series. *J. Conserv. Dent.* **2020**, *23*, 648–652. [https://doi.org/10.4103/JCD.JCD\\_601\\_20](https://doi.org/10.4103/JCD.JCD_601_20).
5. Antunes, H.S.; Rôças, I.N.; Alves, F.R.F.; Siqueira, J.F. Total and Specific Bacterial Levels in the Apical Root Canal System of Teeth with Post-Treatment Apical Periodontitis. *J. Endod.* **2015**, *41*, 1037–1042. <https://doi.org/10.1016/j.joen.2015.03.008>.
6. Ricucci, D.; Siqueira, J.F. Fate of the Tissue in Lateral Canals and Apical Ramifications in Response to Pathologic Conditions and Treatment Procedures. *J. Endod.* **2010**, *36*, 1–15. <https://doi.org/10.1016/j.joen.2009.09.038>.
7. Siqueira, J.F. Aetiology of Root Canal Treatment Failure: Why Well-Treated Teeth Can Fail. *Int. Endod. J.* **2001**, *34*, 1–10. <https://doi.org/10.1046/j.1365-2591.2001.00396.x>.
8. Lin, L.M.; Rosenberg, P.A.; Lin, J. Do Procedural Errors Cause Endodontic Treatment Failure? *J. Am. Dent. Assoc.* **2005**, *136*, 187–193. <https://doi.org/10.14219/jada.archive.2005.0140>.
9. Ahmed, H.A.; Abu-bakr, N.H.; Yahia, N.A.; Ibrahim, Y.E. Root and Canal Morphology of Permanent Mandibular Molars in a Sudanese Population. *Int. Endod. J.* **2007**, *40*, 766–771. <https://doi.org/10.1111/j.1365-2591.2007.1283.x>.
10. Malagnino, V.; Gallottini, L.; Passariello, P. Some Unusual Clinical Cases on Root Anatomy of Permanent Maxillary Molars. *J. Endod.* **1997**, *23*, 127–128. [https://doi.org/10.1016/S0099-2399\(97\)80260-9](https://doi.org/10.1016/S0099-2399(97)80260-9).
11. Weine, F.S.; Healey, H.J.; Gerstein, H.; Evanson, L. Canal Configuration in the Mesiobuccal Root of the Maxillary First Molar and Its Endodontic Significance. 1969. *J. Endod.* **2012**, *38*, 1305–1308. <https://doi.org/10.1016/j.joen.2012.08.005>.
12. Vertucci, F.J. Root Canal Anatomy of the Human Permanent Teeth. *Oral. Surg. Oral Med. Oral Pathol.* **1984**, *58*, 589–599. [https://doi.org/10.1016/0030-4220\(84\)90085-9](https://doi.org/10.1016/0030-4220(84)90085-9).
13. Sert, S.; Bayirli, G.S. Evaluation of the Root Canal Configurations of the Mandibular and Maxillary Permanent Teeth by Gender in the Turkish Population. *J. Endod.* **2004**, *30*, 391–398. <https://doi.org/10.1097/00004770-200406000-00004>.
14. Ahmed, H.M.A.; Dummer, P.M.H. Advantages and Applications of a New System for Classifying Roots and Canal Systems in Research and Clinical Practice. *Eur. Endod. J.* **2018**, *3*, 9–17. <https://doi.org/10.5152/eej.2017.17064>.
15. Reit, C.; Petersson, K.; Molven, O. Diagnosis of Pulpal and Periapical Disease. In *Textbook of Endodontology*; Blackwell Munksgaard: Copenhagen, Denmark, 2003; pp. 9–18.
16. Zheng, Q.; Wang, Y.; Zhou, X.; Wang, Q.; Zheng, G.; Huang, D. A Cone-Beam Computed Tomography Study of Maxillary First Permanent Molar Root and Canal Morphology in a Chinese Population. *J. Endod.* **2010**, *36*, 1480–1484. <https://doi.org/10.1016/j.joen.2010.06.018>.
17. Tu, M.-G.; Tsai, C.-C.; Jou, M.-J.; Chen, W.-L.; Chang, Y.-F.; Chen, S.-Y.; Cheng, H.-W. Prevalence of Three-Rooted Mandibular First Molars among Taiwanese Individuals. *J. Endod.* **2007**, *33*, 1163–1166. <https://doi.org/10.1016/j.joen.2007.07.020>.
18. Pinsky, H.M.; Dyda, S.; Pinsky, R.W.; Misch, K.A.; Sarment, D.P. Accuracy of Three-Dimensional Measurements Using Cone-Beam CT. *Dentomaxillofac. Radiol.* **2006**, *35*, 410–416. <https://doi.org/10.1259/dmfr/20987648>.
19. Lo Giudice, G.; Iannello, G.; Terranova, A.; Lo Giudice, R.; Pantaleo, G.; Cicciù, M. Transcrestal Sinus Lift Procedure Approaching Atrophic Maxillary Ridge: A 60-Month Clinical and Radiological Follow-Up Evaluation. *Int. J. Dent.* **2015**, *2015*, 261652. <https://doi.org/10.1155/2015/261652>.
20. Blattner, T.C.; George, N.; Lee, C.C.; Kumar, V.; Yelton, C.D.J. Efficacy of Cone-Beam Computed Tomography as a Modality to Accurately Identify the Presence of Second Mesiobuccal Canals in Maxillary First and Second Molars: A Pilot Study. *J. Endod.* **2010**, *36*, 867–870. <https://doi.org/10.1016/j.joen.2009.12.023>.
21. Matherne, R.P.; Angelopoulos, C.; Kulild, J.C.; Tira, D. Use of Cone-Beam Computed Tomography to Identify Root Canal Systems In Vitro. *J. Endod.* **2008**, *34*, 87–89. <https://doi.org/10.1016/j.joen.2007.10.016>.
22. Martins, J.N.R.; Marques, D.; Silva, E.J.N.L.; Caramês, J.; Versiani, M.A. Prevalence Studies on Root Canal Anatomy Using Cone-Beam Computed Tomographic Imaging: A Systematic Review. *J. Endod.* **2019**, *45*, 372–386.e4. <https://doi.org/10.1016/j.joen.2018.12.016>.
23. Martins, J.N.R.; Versiani, M.A. CBCT and Micro-CT on the Study of Root Canal Anatomy. In *The Root Canal Anatomy in Permanent Dentition*; Versiani, M.A., Basrani, B., Sousa-Neto, M.D., Eds.; Springer International Publishing: Cham, Switzerland, 2019; pp. 89–180.
24. Yousuf, W.; Khan, M.; Mehdi, H. Endodontic Procedural Errors: Frequency, Type of Error, and the Most Frequently Treated Tooth. *Int. J. Dent.* **2015**, *2015*, 673914. <https://doi.org/10.1155/2015/673914>.
25. Verma, P.; Love, R.M. A Micro CT Study of the Mesiobuccal Root Canal Morphology of the Maxillary First Molar Tooth. *Int. Endod. J.* **2011**, *44*, 210–217. <https://doi.org/10.1111/j.1365-2591.2010.01800.x>.
26. Moher, D.; Shamseer, L.; Clarke, M.; Ghersi, D.; Liberati, A.; Petticrew, M.; Shekelle, P.; Stewart, L.A.; PRISMA-P Group. Preferred Reporting Items for Systematic Review and Meta-Analysis Protocols (PRISMA-P) 2015 Statement. *Syst. Rev.* **2015**, *4*, 1. <https://doi.org/10.1186/2046-4053-4-1>.
27. Balk, E.M.; Chung, M.; Hadar, N.; Patel, K.; Yu, W.W.; Trikalinos, T.A.; Chang, L.K.W. *Accuracy of Data Extraction of Non-English Language Trials with Google Translate*; Report No.: 12-EHC056-EF; Agency for Healthcare Research and Quality: Rockville, MD, USA, 2012.
28. Martins, J.N.R.; Kishen, A.; Marques, D.; Nogueira Leal Silva, E.J.; Caramês, J.; Mata, A.; Versiani, M.A. Preferred Reporting Items for Epidemiologic Cross-Sectional Studies on Root and Root Canal Anatomy Using Cone-Beam Computed Tomographic Technology: A Systematized Assessment. *J. Endod.* **2020**, *46*, 915–935. <https://doi.org/10.1016/j.joen.2020.03.020>.

29. Zhang, R.; Yang, H.; Yu, X.; Wang, H.; Hu, T.; Dummer, P.M.H. Use of CBCT to Identify the Morphology of Maxillary Permanent Molar Teeth in a Chinese Subpopulation. *Int. Endod. J.* **2011**, *44*, 162–169. <https://doi.org/10.1111/j.1365-2591.2010.01826.x>.
30. Kim, Y.; Lee, S.-J.; Woo, J. Morphology of Maxillary First and Second Molars Analyzed by Cone-Beam Computed Tomography in a Korean Population: Variations in the Number of Roots and Canals and the Incidence of Fusion. *J. Endod.* **2012**, *38*, 1063–1068. <https://doi.org/10.1016/j.joen.2012.04.025>.
31. Tocci, L.; Plotino, G.; Grande, N.M.; Testarelli, L.; Messineo, D.; Ciotti, M.; Gambarini, G. Analysis of root and root canal morphology of maxillary and mandibular molars in a Caucasian population: CBCT study in vivo. *G. Ital. Endod.* **2013**, *27*, 13–20.
32. Guo, J.; Vahidnia, A.; Sedghizadeh, P.; Enciso, R. Evaluation of Root and Canal Morphology of Maxillary Permanent First Molars in a North American Population by Cone-Beam Computed Tomography. *J. Endod.* **2014**, *40*, 635–639. <https://doi.org/10.1016/j.joen.2014.02.002>.
33. Altunsoy, M.; Ok, E.; Nur, B.G.; Aglarci, O.S.; Gungor, E.; Colak, M. Root Canal Morphology Analysis of Maxillary Permanent First and Second Molars in a Southeastern Turkish Population Using Cone-Beam Computed Tomography. *J. Dent. Sci.* **2015**, *10*, 401–407. <https://doi.org/10.1016/j.jds.2014.06.005>.
34. Abarca, J.; Gómez, B.; Zaror, C.; Monardes, H.; Bustos, L.; Cantin, M. Determinación de la Morfología de la Raíz Mesial y la Frecuencia del Canal MB2 en Molares Maxilares Usando Tomografía Computadorizada de Haz Cónico. *Int. J. Morphol.* **2015**, *33*, 1333–1337. <https://doi.org/10.4067/S0717-95022015000400023>.
35. Kalender, A.; Celikten, B.; Tufenkci, P.; Aksoy, U.; Basmaci, F.; Kelahmet, U.; Orhan, K. Cone Beam Computed Tomography Evaluation of Maxillary Molar Root Canal Morphology in a Turkish Cypriot Population. *Biotechnol. Biotechnol. Equip.* **2016**, *30*, 145–150. <https://doi.org/10.1080/13102818.2015.1092885>.
36. Naseri, M.; Safi, Y.; Akbarzadeh Baghban, A.; Khayat, A.; Eftekhar, L. Survey of Anatomy and Root Canal Morphology of Maxillary First Molars Regarding Age and Gender in an Iranian Population Using Cone-Beam Computed Tomography. *Iran. Endod. J.* **2016**, *11*, 298–303. <https://doi.org/10.22037/iej.2016.8>.
37. Tian, X.-M.; Yang, X.-W.; Qian, L.; Wei, B.; Gong, Y. Analysis of the Root and Canal Morphologies in Maxillary First and Second Molars in a Chinese Population Using Cone-Beam Computed Tomography. *J. Endod.* **2016**, *42*, 696–701. <https://doi.org/10.1016/j.joen.2016.01.017>.
38. Martins, J.N.R.; Marques, D.; Mata, A.; Caramês, J. Root and Root Canal Morphology of the Permanent Dentition in a Caucasian Population: A Cone-Beam Computed Tomography Study. *Int. Endod. J.* **2017**, *50*, 1013–1026. <https://doi.org/10.1111/iej.12724>.
39. Al-Kadhim, A.H.; Rajion, Z.A.; Malik, N.A.B.; Bin Jaafar, A. Morphology of Maxillary First Molars Analyzed by Cone-Beam Computed Tomography among Malaysian: Variations in the Number of Roots and Canals and the Incidence of Fusion. *Int. Med. J. Malays.* **2017**, *16*, 2. <https://doi.org/10.31436/imjm.v16i2.322>.
40. Pérez-Heredia, M.; Ferrer-Luque, C.M.; Bravo, M.; Castelo-Baz, P.; Ruiz-Piñón, M.; Baca, P. Cone-Beam Computed Tomographic Study of Root Anatomy and Canal Configuration of Molars in a Spanish Population. *J. Endod.* **2017**, *43*, 1511–1516. <https://doi.org/10.1016/j.joen.2017.03.026>.
41. Zand, V.; Mokhtari, H.; Zonouzi, H.R.; Shojaei, S.N. Root Canal Morphologies of Mesiobuccal Roots of Maxillary Molars Using Cone Beam Computed Tomography and Periapical Radiographic Techniques in an Iranian Population. *J. Contemp. Dent. Pract.* **2017**, *18*, 745–749. <https://doi.org/10.5005/jp-journals-10024-2119>.
42. Ghobashy, A.M.; Nagy, M.M.; Bayoumi, A.A. Evaluation of Root and Canal Morphology of Maxillary Permanent Molars in an Egyptian Population by Cone-Beam Computed Tomography. *J. Endod.* **2017**, *43*, 1089–1092. <https://doi.org/10.1016/j.joen.2017.02.014>.
43. Al-Shehri, S.; Al-Nazhan, S.; Shoukry, S.; Al-Shwaimi, E.; Al-Sadhan, R.; Al-Shemmery, B. Root and Canal Configuration of the Maxillary First Molar in a Saudi Subpopulation: A Cone-Beam Computed Tomography Study. *Saudi Endod. J.* **2017**, *7*, 69. <https://doi.org/10.4103/1658-5984.205128>.
44. Wang, H.; Ci, B.-W.; Yu, H.-Y.; Qin, W.; Yan, Y.-X.; Wu, B.-L.; Ma, D.-D. Evaluation of Root and Canal Morphology of Maxillary Molars in a Southern Chinese Subpopulation: A Cone-Beam Computed Tomographic Study. *Int. J. Clin. Exp.* **2017**, *10*, 7030–7039. Available online: <https://e-century.us/files/ijcem/10/4/ijcem0045172.pdf> (accessed on 14 July 2022).
45. Khademi, A.; Zamani Naser, A.; Bahreinian, Z.; Mehdizadeh, M.; Najarian, M.; Khazaei, S. Root Morphology and Canal Configuration of First and Second Maxillary Molars in a Selected Iranian Population: A Cone-Beam Computed Tomography Evaluation. *Iran. Endod. J.* **2017**, *12*, 288–292. <https://doi.org/10.22037/iej.v12i3.13708>.
46. Ghoncheh, Z.; Zade, B.M.; Kharazifard, M.J. Root Morphology of the Maxillary First and Second Molars in an Iranian Population Using Cone Beam Computed Tomography. *J. Dent.* **2017**, *14*, 115–122. Available online: <https://www.ncbi.nlm.nih.gov/pmc/articles/PMC5694843/pdf/JOD-14-115.pdf> (accessed on 17 July 2022).
47. Martins, J.N.R.; Ordinola-Zapata, R.; Marques, D.; Francisco, H.; Caramês, J. Differences in Root Canal System Configuration in Human Permanent Teeth within Different Age Groups. *Int. Endod. J.* **2018**, *51*, 931–941. <https://doi.org/10.1111/iej.12896>.
48. Martins, J.N.R.; Gu, Y.; Marques, D.; Francisco, H.; Caramês, J. Differences on the Root and Root Canal Morphologies between Asian and White Ethnic Groups Analyzed by Cone-Beam Computed Tomography. *J. Endod.* **2018**, *44*, 1096–1104. <https://doi.org/10.1016/j.joen.2018.04.001>.
49. Razumova, S.; Brago, A.; Khaskhanova, L.; Barakat, H.; Howijieh, A. Evaluation of Anatomy and Root Canal Morphology of the Maxillary First Molar Using the Cone-Beam Computed Tomography among Residents of the Moscow Region. *Contemp. Clin. Dent.* **2018**, *9*, S133–S136. [https://doi.org/10.4103/ccd.ccd\\_127\\_18](https://doi.org/10.4103/ccd.ccd_127_18).

- 72  
73  
74  
75  
76  
77  
78  
79  
80  
81  
82  
83  
84  
85  
86  
87  
88  
89  
90  
91  
92  
93  
94  
95  
96  
97  
98  
99  
00  
01  
02  
03  
04  
05  
06  
07  
08  
09  
10  
11  
12  
13  
14  
15  
16  
17  
18  
19  
20  
21  
22  
23  
24  
25  
26  
27  
28  
29  
30  
31  
32  
33
50. Ratanajirasut, R.; Panichuttra, A.; Panmekiate, S. A Cone-Beam Computed Tomographic Study of Root and Canal Morphology of Maxillary First and Second Permanent Molars in a Thai Population. *J. Endod.* **2018**, *44*, 56–61. <https://doi.org/10.1016/j.joen.2017.08.020>.
  51. Martins, J.N.R.; Marques, D.; Francisco, H.; Caramês, J. Gender Influence on the Number of Roots and Root Canal System Configuration in Human Permanent Teeth of a Portuguese Subpopulation. *Quintessence Int.* **2018**, *49*, 103–111. <https://doi.org/10.3290/j.qi.a39508>.
  52. Gomes Alves, C.R.; Martins Marques, M.; Stella Moreira, M.; Harumi Miyagi de Cara, S.P.; Silveira Bueno, C.E.; Lascala, C.Â. Second Mesiobuccal Root Canal of Maxillary First Molars in a Brazilian Population in High-Resolution Cone-Beam Computed Tomography. *Iran. Endod. J.* **2018**, *13*, 71–77. <https://doi.org/10.22037/iej.v13i1.18007>.
  53. Raja, M.; Pradeep, S.; Mohan, M. Root canal morphology of maxillary first molar using cone-beam computed tomography in south Indian population. *J. Pharm. Res.* **2018**, *12*, 4.
  54. Pan, J.Y.Y.; Parolia, A.; Chuah, S.R.; Bhatia, S.; Mutalik, S.; Pau, A. Root Canal Morphology of Permanent Teeth in a Malaysian Subpopulation Using Cone-Beam Computed Tomography. *BMC Oral Health* **2019**, *19*, 14. <https://doi.org/10.1186/s12903-019-0710-z>.
  55. Mohara, N.T.; Coelho, M.S.; de Queiroz, N.V.; Borreau, M.L.S.; Nishioka, M.M.; de Jesus Soares, A.; Frozoni, M. Root Anatomy and Canal Configuration of Maxillary Molars in a Brazilian Subpopulation: A 125-Mm Cone-Beam Computed Tomographic Study. *Eur. J. Dent.* **2019**, *13*, 82–87. <https://doi.org/10.1055/s-0039-1688736>.
  56. de Miranda Candeiro, G.T.; Gonçalves, S.D.S.; de Araújo Lopes, L.L.; de Freitas Lima, I.T.; Alencar, P.N.B.; Iglecias, E.F.; Silva, P.G.B. Internal Configuration of Maxillary Molars in a Subpopulation of Brazil's Northeast Region: A CBCT Analysis. *Braz. Oral Res.* **2019**, *33*, e082. <https://doi.org/10.1590/1807-3107bor-2019.vol33.0082>.
  57. Soh, N. Evaluation of Root Canal Morphology of Maxillary 1st Molars Using Cone Beam Computed Tomography in Chennai Population. *J. Pharm. Sci. Res.* **2019**, *11*, 2750–2754. Available online: <https://jpsr.pharmainfo.in/Documents/Volumes/vol11issue07/jpsr11071948.pdf> (accessed on 14 July 2022).
  58. Al Mheiri, E.; Chaudhry, J.; Abdo, S.; El Abed, R.; Khamis, A.H.; Jamal, M. Evaluation of Root and Canal Morphology of Maxillary Permanent First Molars in an Emirati Population; a Cone-Beam Computed Tomography Study. *BMC Oral Health* **2020**, *20*, 274. <https://doi.org/10.1186/s12903-020-01269-2>.
  59. Alsaket, Y.; El-ma'aita, A.; Aqrabawi, J.; Alhadidi, A. Prevalence and Configuration of the Second Mesiobuccal Canal in the Permanent Maxillary First Molar in Jordanian Population Sample. *Iran. Endod. J.* **2020**, *15*, 217–220. <https://doi.org/10.22037/iej.v15i4.27692>.
  60. Liu, Y.; Yang, W.; Wang, W.; Zhu, Y.; Lin, Z.; Zhu, M. Relationship between Canal Morphology and Isthmus in Mesio-Buccal Roots of Maxillary First Molars in 9- to 12-Year-Old Children: An In-Vivo Cone-Beam Computed Tomography Analysis. *Arch. Oral Biol.* **2020**, *112*, 104645. <https://doi.org/10.1016/j.archoralbio.2019.104645>.
  61. Popović, M.; Živanović, S.; Vučićević, T.; Grujović, M.; Papić, M. Cone-Beam Computed Tomography Study of Tooth Root and Canal Morphology of Permanent Molars in a Serbian Population. *Vojnosanit. Pregl.* **2020**, *77*, 470–478. <https://doi.org/10.2298/10.2298/VSP180322100P>.
  62. Al-Saedi, A.; Al-Bakhakh, B.; Al-Taee, R.G. Using Cone-Beam Computed Tomography to Determine the Prevalence of the Second Mesiobuccal Canal in Maxillary First Molar Teeth in a Sample of an Iraqi Population. *Clin. Cosmet. Investig. Dent.* **2020**, *12*, 505–514. <https://doi.org/10.2147/CCIDE.S281159>.
  63. Nikkerdar, N.; Asnaashari, M.; Karimi, A.; Araghi, S.; Seifitabar, S.; Golshah, A. Root and Canal Morphology of Maxillary Teeth in an Iranian Subpopulation Residing in Western Iran Using Cone-Beam Computed Tomography. *Iran. Endod. J.* **2020**, *15*, 31–37. <https://doi.org/10.22037/iej.v15i1.25386>.
  64. Peiris, R. Root and Canal Morphology of Human Permanent Teeth in a Sri Lankan and Japanese Population. *Anthropol. Sci.* **2008**, *116*, 123–133. <https://doi.org/10.1537/ase.070723>.
  65. Campos Netto, P.D.A.; Dos Santos Accioly Lins, C.C.; Lins, C.V.; Lima, G.A.; Gomes Frazão, M.A. Study of the Internal Morphology of the Mesiobuccal Root of Upper First Permanent Molar Using Cone Beam Computed Tomography. *Int. J. Morphol.* **2011**, *29*, 617–621. <http://doi.org/10.4067/S0717-95022011000200053>.
  66. Buyukbayram, I.; Kartal, N. Evaluation of Complex Mesiobuccal Root Anatomy in Maxillary First Molar Teeth. *Int. J. Morphol.* **2018**, *36*, 460–464. <https://doi.org/10.4067/s0717-95022018000200460>.
  67. Rouhani, A.; Bagherpour, A.; Akbari, M.; Azizi, M.; Nejat, A.; Naghavi, N. Cone-Beam Computed Tomography Evaluation of Maxillary First and Second Molars in Iranian Population: A Morphological Study. *Iran. Endod. J.* **2014**, *9*, 190–194. Available online: <https://www.ncbi.nlm.nih.gov/pmc/articles/PMC4099950/pdf/iej-9-190.pdf> (accessed on 17 July 2022).
  68. Weng, X.-L.; Yu, S.-B.; Zhao, S.-L.; Wang, H.-G.; Mu, T.; Tang, R.-Y.; Zhou, X.-D. Root Canal Morphology of Permanent Maxillary Teeth in the Han Nationality in Chinese Guanzhong Area: A New Modified Root Canal Staining Technique. *J. Endod.* **2009**, *35*, 651–656. <https://doi.org/10.1016/j.joen.2009.02.010>.
  69. Faraj, B.M. The Frequency of the Second Mesiobuccal Canal in Maxillary First Molars among a Sample of the Kurdistan Region-Iraq Population—A Retrospective Cone-Beam Computed Tomography Evaluation. *J. Dent. Sci.* **2021**, *16*, 91–95. <https://doi.org/10.1016/j.jds.2020.06.021>.
  70. Martins, J.N.R.; Alkhwaw, M.-B.A.M.; Altaki, Z.; Bellardini, G.; Berti, L.; Boveda, C.; Chaniotis, A.; Flynn, D.; Gonzalez, J.A.; Kottoor, J.; et al. Worldwide Analyses of Maxillary First Molar Second Mesiobuccal Prevalence: A Multicenter Cone-Beam Computed Tomographic Study. *J. Endod.* **2018**, *44*, 1641–1649.e1. <https://doi.org/10.1016/j.joen.2018.07.027>.



- 34  
35  
36  
37  
38  
39  
40  
41  
42  
43  
44  
45  
46  
47  
48  
49  
50  
51  
52  
53
71. Betancourt, P.; Navarro, P.; Muñoz, G.; Fuentes, R. Prevalence and Location of the Secondary Mesiobuccal Canal in 1100 Maxillary Molars Using Cone Beam Computed Tomography. *BMC. Med. Imaging* **2016**, *16*, 66. <https://doi.org/10.1186/s12880-016-0168-2>.
  72. Sousa, T.O.; Haiter-Neto, F.; Nascimento, E.H.L.; Peroni, L.V.; Freitas, D.Q.; Hassan, B. Diagnostic Accuracy of Periapical Radiography and Cone-Beam Computed Tomography in Identifying Root Canal Configuration of Human Premolars. *J. Endod.* **2017**, *43*, 1176–1179. <https://doi.org/10.1016/j.joen.2017.02.021>.
  73. Abuabara, A.; Baratto-Filho, F.; Aguiar Anele, J.; Leonardi, D.P.; Sousa-Neto, M.D. Efficacy of Clinical and Radiological Methods to Identify Second Mesiobuccal Canals in Maxillary First Molars. *Acta Odontol. Scand.* **2013**, *71*, 205–209. <https://doi.org/10.3109/00016357.2011.654262>.
  74. Gaêta-Araujo, H.; Fontenele, R.C.; Nascimento, E.H.L.; do Carmo Chagas Nascimento, M.; Freitas, D.Q.; de Oliveira-Santos, C. Association between the Root Canal Configuration, Endodontic Treatment Technical Errors, and Periapical Hypodensities in Molar Teeth: A Cone-Beam Computed Tomographic Study. *J. Endod.* **2019**, *45*, 1465–1471. <https://doi.org/10.1016/j.joen.2019.08.007>.
  75. Nascimento, E.H.L.; Gaêta-Araujo, H.; Andrade, M.F.S.; Freitas, D.Q. Prevalence of Technical Errors and Periapical Lesions in a Sample of Endodontically Treated Teeth: A CBCT Analysis. *Clin. Oral Investig.* **2018**, *22*, 2495–2503. <https://doi.org/10.1007/s00784-018-2344-y>.
  76. Song, M.; Kim, H.-C.; Lee, W.; Kim, E. Analysis of the Cause of Failure in Nonsurgical Endodontic Treatment by Microscopic Inspection during Endodontic Microsurgery. *J. Endod.* **2011**, *37*, 1516–1519. <https://doi.org/10.1016/j.joen.2011.06.032>.



Systematic Review

# Evaluation of Root Anatomy and Canal Configuration of Human Permanent Maxillary First Molar Using Cone-Beam Computed Tomography: A Systematic Review

Sourabh Barbhai <sup>1</sup>, Rajesh Shetty <sup>1</sup>, Poonam Joshi <sup>1</sup>, Vini Mehta <sup>2</sup>, Ankita Mathur <sup>3</sup>, Tanvi Sharma <sup>3</sup>, Damini Chakraborty <sup>4</sup>, Priyanka Porwal <sup>3</sup>, Aida Meto <sup>5</sup>, Dian Augustin Wahjuningrum <sup>6,\*</sup>, Alexander Maniangat Luke <sup>7,8,\*</sup> and Ajinkya M. Pawar <sup>9,\*</sup>

<sup>1</sup> Department of Conservative Dentistry & Endodontics, Dr. D.Y. Patil Dental College and Hospital, Dr. D.Y. Patil Vidyapeeth, Pimpri, Pune 411018, Maharashtra, India

<sup>2</sup> Department of Public Health Dentistry, Dr. D.Y. Patil Dental College and Hospital, Dr. D.Y. Patil Vidyapeeth, Pimpri, Pune 411018, Maharashtra, India

<sup>3</sup> STAT SENSE, Srushti 10, Sector 1 D, Amba Township Pvt. Ltd., Trimandir, Adalaj 382421, Gujarat, India

<sup>4</sup> Bhowal's Dental and Implant Clinic, Bengal GreenField Heights, Galaxy-6FS, beside Apollo Pharmacy, DJ Block (Newtown), Newtown, Kolkata 700136, West Bengal, India

<sup>5</sup> Department of Dentistry, Faculty of Dental Sciences, University of Aldent, 1007 Tirana, Albania

<sup>6</sup> Department of Conservative Dentistry, Faculty of Dental Medicine, Universitas Airlangga, Surabaya 60132, East Java, Indonesia

<sup>7</sup> Department of Clinical Sciences, College of Dentistry, Ajman University, Ajman 346, United Arab Emirates

<sup>8</sup> Centre of Medical and Bio-allied Health Sciences Research, Ajman University, Ajman 346, United Arab Emirates

<sup>9</sup> Department of Conservative Dentistry and Endodontics, Nair Hospital Dental College, Mumbai 400008, Maharashtra, India

\* Correspondence: dian-augustin-w@fkg.unair.ac.id (D.A.W.); a.luke@ajman.ac.ae (A.M.L.); ajinkya@drpawars.com (A.M.P.)



**Citation:** Barbhai, S.; Shetty, R.; Joshi, P.; Mehta, V.; Mathur, A.; Sharma, T.; Chakraborty, D.; Porwal, P.; Meto, A.; Wahjuningrum, D.A.; et al. Evaluation of Root Anatomy and Canal Configuration of Human Permanent Maxillary First Molar Using Cone-Beam Computed Tomography: A Systematic Review. *Int. J. Environ. Res. Public Health* **2022**, *19*, 10160. <https://doi.org/10.3390/ijerph191610160>

Academic Editors: Paul B. Tchounwou and Takaaki Tomofuji

Received: 21 July 2022  
Accepted: 14 August 2022  
Published: 16 August 2022

**Publisher's Note:** MDPI stays neutral with regard to jurisdictional claims in published maps and institutional affiliations.



**Copyright:** © 2022 by the authors. Licensee MDPI, Basel, Switzerland. This article is an open access article distributed under the terms and conditions of the Creative Commons Attribution (CC BY) license (<https://creativecommons.org/licenses/by/4.0/>).

**Abstract:** The aim of this paper is to review the literature on root canal configuration (RCC) and the frequency of occurrence of a second mesiobuccal canal (MB) in human permanent maxillary first molars where cone-beam computed tomography (CBCT) is used. Online electronic databases such as PubMed-Medline, Embase, Scopus and Cochrane Library were searched using appropriate keywords from the earliest available date until 12th June 2022, without restriction on language. In the mesiobuccal root, type I was the most frequent (33.29%), followed by types II and IV (27.18% and 26.36%, respectively). Moreover, 68.2% of maxillary first molars had a second MB canal. For both the distobuccal and palatal roots, type I was the most prevalent, with 99.08% and 97.83% occurrence, respectively. All other types were infrequent. Type I RCC is most frequent in all the roots of the maxillary first molars. Hence, care must be taken during biomechanical preparation of the MB roots.

**Keywords:** canal configuration; root canal; Vertucci classification; permanent mandibular first molar; CBCT

## 1. Introduction

Dental caries is among the most common chronic diseases [1]. If left untreated it can progress and infect the pulp and, subsequently, the periapical tissues, leading to irreversible pulpitis or apical periodontitis, respectively. The treatment of choice is root canal therapy. The main aim of this therapy is to remove bacteria and infected materials from the pulp and periapical tissues and replace them with biocompatible material [2–4]. According to Siqueira JF et al. and Lin LM et al., complex root anatomy is the primary cause of endodontic treatment failure [5,6]. Among various races, and different individuals within the same race, the morphology of the pulp canal varies momentarily [7]. Thus, knowledge of the root canal's configuration is essential for endodontic success [8].

A root may contain a simple canal that tapers and terminates into the apical foramen, or the configuration can be more complex, with multiple interconnecting canals, lateral branches and multiple foramina. Classifications of root canal configurations (RCCs) have been given by several authors. Weine was the first to classify canals present in one root into four types [9]. In 1984, Vertucci analyzed the canal anatomy and gave a classification with eight different types of canals [10]. Later, Sert and Bayirli added additional types to the Vertucci classification, giving a total of XXIII types of root canal configuration [11]. Recently, in 2017, Ahmed H et al. developed a new code system to classify root canals that also includes the number of roots present [12].

To navigate through these complex canal systems, proper radiographic aid is crucial. Radiography is essential in the diagnosis, treatment planning and success of endodontic therapy [13]. However, conventional radiographs only provide a two-dimensional view, resulting in the incomplete detection of root canals [14,15]. However, a detailed three-dimensional view of a tooth, along with its surrounding anatomical structure, is possible with the help of cone-beam computed tomography (CBCT) [16,17]. Blattner T et al. reported that CBCT acts as a much superior imaging method when compared with traditional radiographs in the diagnosis of second mesiobuccal canals [18]. In a study by Matherne et al. in 2008, it was found that while using digital radiographs, endodontists failed to detect at least one root in 40% of the tooth when compared with using CBCT [19]. Additionally, using CBCT as a methodology for in vivo studies aids in obtaining a greater number of samples, as it helps the analysis of full dentition of several patients collected from a specific population in a consecutive manner, thus allowing for adequate statistical analysis [20,21]. In human dentition, maxillary first molars are the second-most common teeth to undergo root canal treatment, immediately after the mandibular first molars [22]. Additionally, performing endodontic treatment of the mesiobuccal root of maxillary first molars is a challenge due to the significant prevalence of additional canals and morphological variations [23].

The main aim of this systemic review is to analyze the available studies on the prevalence of root canal configuration of maxillary first molar teeth assessed using CBCT to help dentists to successfully identify the root anatomy, and subsequently to perform endodontic treatment successfully.

## 2. Materials and Methods

This systematic review was conducted in accordance with the Preferred Reporting Items for Systematic Reviews and Meta-Analysis (PRISMA) statement guidelines [24]. The study protocol was registered and approved on the International Prospective Register of Systematic Reviews PROSPERO (Reg. No: CRD42021259436) before the start of the study.

### 2.1. Focused Question

What is the prevalence of root canal configuration and frequency of occurrence of a second mesiobuccal canal in the human permanent maxillary first molars where cone-beam computed tomography (CBCT) is used?

### 2.2. Inclusion Criteria

In vivo studies discussing the anatomy and canal configuration of permanent maxillary first molars were included. Only studies that used an in vivo CBCT methodology were included. The context included all of the in vivo studies carried out using CBCT, without excluding any country in the world. The population consisted of patients who had been subjected to CBCT, regardless of its diagnostic purposes. The primary outcome for this systematic review was to check the prevalence of root canal configurations of permanent maxillary first molars based on the Vertucci classification.

### 2.3. Exclusion Criteria

- Studies using any classifications other than Vertucci.



- Case reports, case series and reviews were excluded.

#### 2.4. Search Strategy and Data Collection

A literature search was performed in four major electronic databases—PubMed-MEDLINE, Cochrane Library, Embase and Scopus—along with additional sources, such as Google Scholar, major journals, unpublished studies, conference proceedings and cross references. A comprehensive search to identify studies related to root anatomy and the canal morphology of permanent maxillary first molar teeth was conducted until 12 June 2022, utilizing keywords such as “Vertucci classification”, “maxillary first molars”, “root anatomy” and “root canal configuration”. No additional filters or language restrictions were kept while conducting the searches. Two authors independently carried out the literature search, reviewed the study articles and extracted data. The screening was performed in two stages. First, the titles and abstracts of all of the articles were reviewed, followed by full text screening. Those studies that fulfilled the selection criteria were processed for data extraction. Non-English language publications were translated into the English language using Google Translate [25]. The information was independently extracted by the two authors using specially-designed data-extraction forms utilizing Microsoft Excel software. Any disagreement was resolved by discussion between the authors. For each selected study, the following data were then extracted from a standard form (when available): author and year of publication, sample size, population, root number, root canal configuration, CBCT model and CBCT settings.

#### 2.5. Quality Assessment

The checklist given by Martins JNR et al. in Preferred Reporting Items for Epidemiologic Cross-sectional Studies on Root and Root Canal Anatomy Using Cone-beam Computed Tomographic Technology was used for quality assessment [26]. The quality of the included articles was evaluated across 6 domains: title, keywords, aim, methodology, results and discussion. Two authors individually evaluated each topic in the abovementioned domains and gave a score of 1 (reported) or 0 (not reported) for each of the included articles.

### 3. Results

#### 3.1. Search Selection and Results

After extensive searching, a total of 533 studies were identified, out of which 421 were duplicates. The remaining 112 studies underwent title and abstract screening, and 51 studies were selected for full text screening. Sixteen studies were excluded after full text screening. Thus, a total of 35 studies that met our inclusion criteria were processed for data extraction [27–61] (Figure 1).

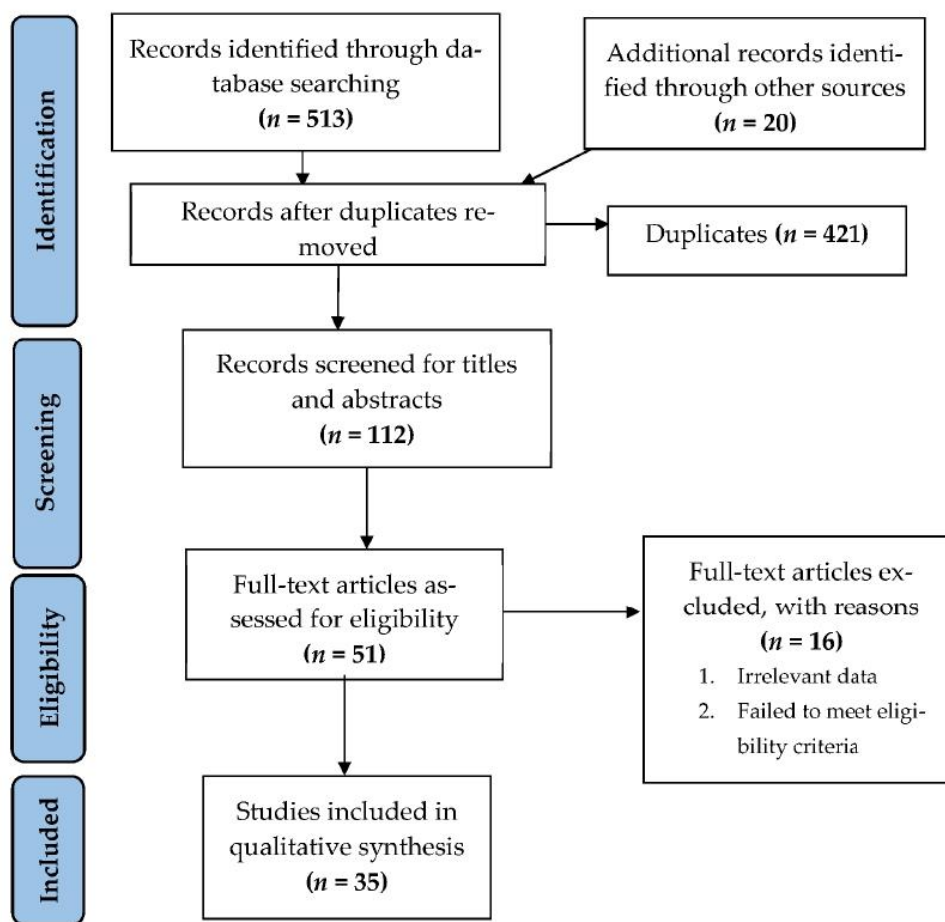


Figure 1. Flowchart summarizing the article selection process (n—number of studies).

### 3.2. Study Characteristics

The 35 included studies were conducted across the globe, with wide demographic variations, and a total of 17278 permanent maxillary first molar teeth were identified. Nearly all the studies were conducted on adult populations, except for two [45,48]. One study was based on variations in RCC among various age groups, and one of the selected age groups was younger than twenty years [45]. The second study was conducted among children of age groups ranging between 9 and 12 years. All studies provided details of CBCT specifications except for the study by Raja M et al., where details about the CBCT were not available [51]. The details of CBCT software, setting, field of view (FOV), voxel size and visualization software are shown in Table 1.

Table 1. Cone-beam computed tomography parameter values of each study.

Study/Year of Publication	Country	CBCT Model	Voxel Size	FOV	Settings CBCT	Software Visualization
Zang R et al./ 2011 [27]	China	3D Accuitomo scanner (Morita, Kyoto, Japan)	0.125 mm	40 mm or 60 mm	80 kVp and 5.0 mA, time 17 s	i-Dixel one volume viewer 1.5.0 and a Dell Precision T5400 workstation (Dell, Round Rock, TX, USA)
Kim Y et al./ 2012 [28]	Korea	Dinnova system (Willmed, Gwangmyeong, Korea)	0.167-mm <sup>3</sup>	10 cm	80 kVp, 9.0 mA	OnDemand3D software (Cybermed, Seoul, Korea).
Tocci L et al./ 2013 [29]	Italy	NewTom VGi Vertical Cone Beam (Verona, Italia)	0.3 mm	15 cm	110 Kvp, 1–20 mAs, 15 mSv	NA

Table 1. Cont.

Study/Year of Publication	Country	CBCT Model	Voxel Size	FOV	Settings CBCT	Software Visualization
Guo J et al./2014 [30]	USA	Sirona Galileos device (Sirona Dental Systems, Inc, Long Island City, NY, USA)	0.3/0.15 mm.	15 cm	85 kV and 5–7 mA	The Digital Imaging and Communications in Medicine (DICOM) format images were exported from Galileos and imported into InVivo Dental Application 5.1.6 software (Anatomage Inc., San Jose, CA, USA).
Altunsoy M et al./2014 [31]	Turkey	CBCT scanner (iCAT Vision; Imaging Science International, Hatfield, PA, USA)	0.3 mm	NA	120 kVp, and 18.54 mA, 8 s	NA
Abarca J. et al./2015 [32]	Chile	Gendex CB500 imaging system	0.2 mm	NA	120 kVp and 5 mA and 0.2 mm thickness of the cut	iCATVision software v 1.8.1.10 in a darkroom on 21" LCD monitors with a resolution of 1280 × 1024 pixels.
Kalender A et al./2015 [33]	Turkey	Newtom 3G: Quantitative Radiology s.r.l, Verona, Italy	NA	9 inch	NA	NNT 4.6, QR Verona, Italy
Naseri M et al./2016 [34]	Iran	NewTom VGi (QR SRL Company, Verona, Italy)	200 µm	8 × 12 cm	110 kVp and exposure time of 3.6 s	NewTom NNT software version 5.3 (Quantitative Radiology, Verona, Italy)
Tian X et al./2016 [35]	Chinese	NewTom VG; QR srl, Verona, Italy	0.16 mm	500 cm <sup>2</sup> (20 × 25 cm)	110 kVp and 10 mA, 18 s	NNT software version 2.21 (ImageWorks, Elmsford, NY, USA)
Martins J.N.R et al./2016(I) [36]	Portugal	Planmeca scanner (Planmeca Promax, Planmeca, Finland)	0.2 mm	NA	80 kv, 15 mA, 12 s	Planmeca Romexis, Planmeca
Al-Kadhim A et al./2017 [37]	Malaysia	NA	NA	NA	NA	One Data Viewer software (J. Morita Manufacturing Corp).
Perez M et al./2017 [38]	Spain	9300 3D CBCT unit (Carestream Dental, Atlanta, GA, USA)	0.18 mm	10 × 10 cm	90 kV, 4 mA, 8 s	Carestream software (CS 3D Imaging software 6.1.4)
Zand V et al./2017 [39]	Iran	NewTom GI CBCT (Verona /Italy)	NA	NA	110 kVp, 18 s	NNT viewer software program
Ghobasby A et al./2017 [40]	Egypt	Cranex 3D (Soredex ,Tuusula, Finland)	133-µm	NA	80 kVp, 9.0 mA	NA
Al-Shehri S et al./2017 [41]	Saudi Arabia	1. I-CAT (Imaging Science International, Hatfield, PA, USA), 2. Galileos (Sirona Dental Systems, Bensheim, Germany), 3. Carestream CS 9300 (Carestream Health, Inc., Rochester, NY, USA).	0.3 mm (14-bit grayscale)	NA	85 kV, 5–7 mA	OnDemand3D software (Cybermed, Seoul, Korea)
Wang H et al./2017 [42]	China	Planmeca Romexis 3D CBCT scanner (Planmeca, Finland)	200 µm	NA	84 kV and 14 mA, 12 s, the minimum slice thickness was 0.2 mm.	The CBCT images were 3D-reconstructed by using a patented Feldkamp reconstruction algorithm, analysed with inbuilt software and ran in a 32-bit Windows 7 system.
Khademi A et al./2017 [43]	Iran	Galileos (Sirona Dental Systems Inc., Bensheim, Germany)	150 µm	150 × 150 or 75 × 150 mm	85 kVp, 42 mA	SIDEXIS XG software version 3.7 (Sirona Dental System GmbH, Bensheim, Germany).
Ghoncheh Z./2017 [44]	Iran	NewTom VG CBCT system (Image Works, Verona, Italy)	0.3 mm	(11 × 16 cm	110 kV, 1–20 mA, 3.6–5.4 s.	NNT Viewer software (NNT 2.21; Image Works, Verona, Italy).
Martins J.N.R et al./2018(II) [45]	Portugal	Planmeca Promax, Planmeca, Helsinki, Finland	0.20 mm	NA	80 kV, 15 mA, 12 s	Romexis visualization software (Planmeca)
Martins J.N.R et al./2018(III) [46]	China	Kodak 9500	0.2 mm	Full Arch	90 kV, 10 mA, 10.8 s	CS 900 3D imaging
	Portugal	Planmeca Promax	0.2 mm	Full Arch	80 kV, 15 mA, 12 s	Planmeca Romexis
Razmuvo S et al./2018 [47]	Moscow	3D eXam (KaVo, Biberach, Germany)	0.3 mm	23 cm × 17 cm	110 kV, 1.6–20 s	g I-CAT viewer software (version 10, Hatfield, England).
Ratanajirasut et al./2018 [48]	Thai	3D Accuitomo CBCT machine (J Morita Manufacturing Corp, Kyoto, Japan	0.25 mm × 0.25 mm	100.025 × 100.025	80 kVp, 5 mA, 17.5 s	g One Volume Viewer software (J Morita Manufacturing Corp)



Table 1. Cont.

Study/Year of Publication	Country	CBCT Model	Voxel Size	FOV	Settings CBCT	Software Visualization
Martins J.N.R et al./2018(IV) [49]	Portugal	Planmeca Promax	0.2 mm		80 kV,15 mA, 12 s	Planmeca Romexis
Alves CRG et al./ 2018 [50]	Brazil	Prexion 3D Elite model XP68 (PreXion Inc., San Mateo, California, USA),	0.15 mm (for FOV 8) and 0.11 mm (for FOV 5)	5 [5.6 cm × 5.2 cm (partial jaw)] or 8 [8.1 cm × 7.5 cm (total jaw)]	90 Kvp and 4 mA, 37 s	3D software PreXion Image Analysis System (PreXion Inc. San Mateo, California, USA)
Raja M et al./2018 [51]	India	NA	NA	NA	The CBCT scanner was set at a constant slice thickness of 125 µm/slice	NA
Pan YJ et al./ 2019 [52]	Malaysia	KaVo 3D eXam imaging system (Imaging Sciences International, Hatfield, PA, USA).	0.25 mm	NA	121 kVp, 5 mA, 26.9 s	eXam Vision software version 1.9.3.13 (KaVo Dental GmbH, Biberach, Germany)
Mohara NT et al./ 2019 [53]	Brazil	a 3D Accuitemo 80 CBCT (J. Morita, Kyoto, Japan)	NA	40 mm or 60 mm	90 KVA, 8 mA, 18 s	i-Dixel (J Morita, Tokyo, Japan)
Candeiro GTM et al./2019 [54]	Brazil	Prexion 3D imaging device (Prexion, Inc., San Mateo, USA)	0.125 mm	NA	90 kVp and 4 mA	(Prexion, Inc., San Mateo, USA) was used on a Dell Precision T5400 (Dell, Round Rock, TX, USA)
Soh N et al./ 2019 [55]	India	NA				
Al Mheiri E et al./ 2019 [56]	United Arab Emirates	Planmeca ProMax CBCT scanner (Planmeca Oy, Helsinki, Finland)	0.4 mm	16 × 11 cm	120 kVp, 18.54 mA, 8.9 s	iMAC computer ([27-in. screen size with Retina 5 K display, 5120 × 2880 resolution with support for 1 billion colors, 500 nits brightness], Apple, USA) in a room with controlled lighting using the Horos DICOM viewer
Alsaket YM et al./ 2020 [57]	Jordan	Carestream Dental, Rochester, NY, USA	NA	NA	NA	NA
Liu Y et al./ 2020 [58]	China	NewTom VG scanner (QR srl, Verona, Italy)	0.125 mm	Small	NA	3D reconstructed with an open source software platform 3D Slicer 4.8.1 from Slicer web site
Popovic M et al./ 2020 [59]	Serbia	Orthophos XG 3D device (Sirona Dental Systems GmbH, Bensheim, Germany)	160 µm	0.16 mm	NA	GALAXIS v1.9.4 (Sirona Dental Systems GmbH, Bensheim, Germany)
Al-Saedi A et al./ 2020 [60]	Iraq	Gendex (GXDP-7000) CBCT machine (Hatfield, PA, USA)	200 µm	80.0 × 80.0 × 60.0 mm	90 kV,10 mA, 13 s	Software GxPicture; Kavo Dental, Biberach a der Riss, Germany built into the Invivo 5 dental viewer (Anatomage, San Jose, CA, USA) and run on a 64-bit Windows 7 system (Microsoft Corporation, Redmond, WA, USA)
Nikkerdar N et al./2020 [61]	Iran	New Tom VGi CBCT system (QR SRL Co., Verona, Italy)	0.15 mm	120 × 80 mm	110 kVp, 10 mA, 5.4 s	NNT Viewer version 7.2 software on a 12.5-inch laptop (Asus) with 1080 × 1920 p resolution

CBCT: cone beam computed tomography, FOV: field of view, mm: millimeter, µm: micrometer, kVp: kilovoltage peak mA: milliamper, s: seconds, mSv: millisievert.

### 3.3. Outcome

In total, 35 studies presented data on the canal configuration of maxillary first molars based on the Vertucci classification [27–61]. The concurred data for most of these studies included both the percentage of occurrence and the number of cases. For a few studies, only the percentage of occurrence was given, and the exact value of the number of teeth for each specific canal type was calculated from the given percentage and sample size (number of teeth) taken for the study. To draw a definite conclusion among the myriad of data extracted from the studies and to interpret the data properly, each type's total percentage was calculated for the mesiobuccal (MB), second mesiobuccal (MB2), distobuccal (DB) and palatal (P) canals separately.

### 3.4. Prevalence of Canal Configuration of Mesiobuccal Root Based on Vertucci Classification

Different studies, 31 of them, have reported the root canal configurations of the mesiobuccal root of the maxillary first molar [27–31,33–49,51–56,58,59,61]. The data from the studies were pooled to find the mean of all eight types of canal configurations based on Vertucci classification. Among them, type I was the most frequent, with 33.29%, followed by types II and IV with 27.18% and 26.36%, respectively.

### 3.5. Prevalence of Canal Configuration of the Second Mesiobuccal Root Based on Vertucci Classification

Only four studies reported the canal configuration of the second mesiobuccal root. Type II was seen to be the most frequent with 37.4%, followed by type IV and type I with 22.9% and 20.3%, respectively [32,50,57,60].

### 3.6. Prevalence of Canal Configuration of the Distobuccal Root Based on Vertucci Classification

Another 23 studies reported the canal configuration of the distobuccal root of the maxillary first molar [28–31,33–36,38,40,41,44–49,51–53,55,56,61]. Out of these, type I was the most prevalent, with a range from 97.83% to 99.08% occurrence.

### 3.7. Frequency of Occurrence of Second Mesiobuccal Canal

Additionally, 25 studies reported the presence of a second mesiobuccal canal. Out of the 12056 teeth, a total of 8223 teeth showed the occurrence of MB2 canals, i.e., 68.2% occurrence [27–30,32,35–37,39–44,46–48,50–57] (Table 2).

**Table 2.** Prevalence of MB2 canals in maxillary first molars.

Study/Year of Publication	Sample Size (n)	Population	MB2 Canals n (%)
Zang R et al./2011 [27]	299	China	155 (52%)
Kim Y et al./2012 [28]	814	Korea	510 (62.65%)
Tocci L et al./2013 [29]	161	Italy	62 (40.3%)
Guo J et al./2014 [30]	628	USA	428 (68.2%)
Abarca J. et al./2015 [32]	802	Chile	802 (73.44%)
Tian X et al./2016 [35]	1536	China	820 (53.9%)
Martins J.N.R et al./2016 (I) [36]	421	Malaysia	191 (45.6%)
Al-Kadhim A et al./2017 [37]	494	Portugal	350 (71.05%)
Zand V et al./2017 [39]	156	Iran	86 (55.11%)
Ghobasby A et al./2017 [40]	605	Egypt	451 (74.5%)
Al-Shehri S et al./2017 [41]	330	Saudi Arabia	195 (55.6%)
Wang H et al./2017 [42]	939	China	641 (68.3%)
Khademi A et al./2017 [43]	389	Iran	272 (70.2%)
Ghoncheh Z/2017 [44]	337	Iran	155 (46%)
Martins J.N.R et al./2018 (III) [46]	239	China	552 (67.35%)
Razmuvo S et al./2018 [47]	410	Moscow	382 (59.8%)
Ratanajirasut et al./2018 [48]	476	Thai	303 (63.6%)
Alves CRG et al./2018 [50]	362	Brazil	247 (68.23%)
Raja M et al./2018 [51]	500	Indian	400 (80%)
Pan YJ et al./2019 [52]	344	Malaysia	125 (36.3%)
Mohara NT et al./2019 [53]	326	Brazil	209 (64.22%)
Candeiro GTM et al./2019 [54]	700	Brazil	337 (48.21%)
Soh N et al./2019 [55]	66	India	20 (30%)
Al Mheiri E et al./2019 [56]	522	United Arab Emirates	418 (80.1%)
Alsaket YM et al./2020 [57]	200	Jordan	174 (87%)
Total	12,056		8223 (68.2%)

### 3.8. Quality Assessment

All included studies reported the following domains: aim of the study, morphology concept, assessment methodology, sample size and generalizability of the outcomes. Future research was the least reported domain, followed by the strengths and limitations of the study design. In the title, all studies mentioned CBCT but failed to indicate the type of study being conducted, except for one study by Kalender et al. which mentioned both [33] (Table 3).



**Table 3.** Specific preferred reporting items for cross-sectional studies on root and root canal anatomy using cone-beam computed tomography (CBCT).

Sr. No.	Section Item	Total (n)	Percentage (%)
1	Title	33	94.29
<b>Introduction</b>			
2	Keywords	32	91.43
3	Aim	35	100.00
<b>Methods</b>			
4	Participants (in vivo assessment)	33	94.29
5	CBCT	33	94.29
6	Morphology concept & assessed teeth (variables)	35	100.00
7	Assessment	35	100.00
8	Observers	27	77.14
9	Potential sources of bias	21	60.00
10	Final sample size	35	100.00
11	Reliability	25	71.43
12	Statistical analysis	33	94.29
13	Ethics committee Results	24	68.57
14	Primary Outcomes	34	97.14
15	Other analysis	28	80.00
16	Visual documentation Support	31	88.57
<b>Discussion</b>			
17	Outcome interpretation	35	100.00
18	Strength & limitations	23	65.71
19	Generalizability	35	100.00
20	Future research	5	14.29

#### 4. Discussion

Before discussing the results, it must be noted that all the studies had variable CBCT settings and specifications. This, along with the demographic variations in the samples across the studies, will have some influence on the results. Among the studies included for this systematic review, three rooted maxillary first molars were most commonly reported. A similar finding was reported by Peris R et al. [62]. Some studies reported the presence of roots as being one, two and four, although these were infrequent [28,29,35,41,44,48]. Only three studies reported the RCC of maxillary molars with four roots, while only one study by Tian et al. in a Chinese population reported the RCC of the maxillary first molar with only one root [35,44,48]. Al-Shehri S et al. also reported the presence of fused roots along with RCC among maxillary first molars [41].

The main outcome of this systematic review was to determine the prevalence of RCC among maxillary first molars. Most studies reported a higher prevalence of Vertucci types I, II and IV in the mesiobuccal root. After pooling the data from all the studies, type I was observed as the most prevalent type in MB roots, with 33.29% occurrence. Types II and IV had similar prevalence rates of 27.18% and 26.36%, respectively. Our findings are similar to those of other studies, which show type I to be the most prevalent, followed by types II and IV [63,64]. In a comparative study by Peris R et al. on Sri Lankan and Japanese populations, the same trend was seen for the Japanese population, but for Sri Lanka, the second most common was type V [62]. In two studies, type V was reported to have a higher frequency of occurrence [27,42]. Both of these studies were conducted on the Chinese population. In the study by Zang et al., among 299 tooth samples, 70% had type V, making it the most prevalent RCC type [27]. In the rest of the studies, other RCC types were infrequent and had a very low percentage of occurrence [28–41,43–61]. Among 15196 teeth samples, only 0.36% of mesiobuccal roots were reported to have root canal configurations outside of the Vertucci classification, and only 9 studies out of 35 reported

this finding [28,33,35,41,46,48,49,53]. In particular, four studies reported the root canal configuration of the second mesiobuccal canal [32,50,51,60]. All of them reported type II as the most frequently occurring RCC, followed by type III and type I. Among the four studies, a sample size of 2019 teeth, was present, of which 37.4% were type II [32,50,51,60]. None of the studies reported findings for type VIII.

The root canal configuration of the distobuccal and palatal roots was less complex. Both of these roots mostly had a single root canal. All studies, with no exception, reported type I as the most frequent root canal configuration in both the distobuccal and palatal roots. All other types were infrequent. Among the 11660 tooth samples, 97.83% of palatal roots and 99.08% of distobuccal roots had type I RCC. Thus, in all three roots, mesiobuccal, distobuccal and palatal, type I was the most prevalent root canal configuration in maxillary first molars. This finding is similar to three other studies that highlight a higher prevalence of type I and a very low frequency of occurrence in all other types in both distobuccal and palatal roots [61,65–67].

Twenty-five authors acknowledged the presence of an additional mesiobuccal canal, and most of them reported a higher prevalence of MB2 canals [27–30,32,35–37,39–44,46–48,50–57]. In the study by Soh et al. on the Indian population, the frequency of occurrence of MB2 canals was the lowest, at only 30% [55]. Alsaket YM et al. in 2020 reported a maximum frequency of MB2 canals of 87% in their study on the population of Jordan [57]. The mean percentage of MB2 canals was 68.2%. Faraj BM in 2021 concluded that the MB2 canal was found in 53.78% of the teeth. In a study performed by Martins et al. looking at the worldwide prevalence of MB2 canals using CBCT, the overall prevalence was 73.8% [68]. Bentancourt P et al. found 69.82% of MB2 canals in their study on 1100 maxillary molars using CBCT [69]. Even though the CBCT specifications changed across the studies, the Newtom CBCT scanner was the most commonly used scanner. All the studies had a similar methodology for the assessment of the CBCT scans. Experienced endodontists or radiologists viewed the CBCT in 3 planes: axial, coronal and sagittal. For the identification of root anatomy, CBCT is a much better diagnostic tool than periapical radiography [70]. Abuabara A et al. reported that periapical radiographs can detect only 8% of MB2 canals, while with the help of CBCT, a second mesiobuccal canal can be detected in 54% of teeth [71]. Maxillary molars with 2 canals are frequently misdiagnosed, and 78.4% of MB2 canals remain unfilled [72]. Due to the higher presence of unexpected root canals in the maxillary mesiobuccal root, the chances of root canal treatment failure are higher [72,73]. However, in the distobuccal and palatal roots, the anatomy was simple. Type I RCC was highly prevalent, and the number of canals was mostly limited to one per root. Thus, the chances of missing a root canal or failed root canal therapy are lower. In this systematic review, we found that the mesiobuccal roots most commonly have type I RCC, followed by types II and IV. Gaêta-Araujo H et al. found that most teeth without endodontic technical errors had type I RCC [74]. If technical errors are present with type I, they are due to underfilling or nonhomogenous filling [75,76].

The sample sizes (number of teeth) among the studies varied. Thus, the percentages of studies with a small sample size (number of teeth) were higher, even though we tried to obtain a conclusive finding by calculating the percentages. Hence, pooling the data to find an overall mean percentage helped us to achieve a more conclusive result. However, our study has certain limitations. The inclusion criteria only helped to establish homogeneity among the methodologies used in various studies. However, the data collected had samples of patients from all age groups, genders and from different parts of the world, with varied ethnicities and genetic predispositions. These factors might have influenced the findings. Additionally, even though only studies using CBCT as a methodology were included, the CBCT parameters and specifications across all of the studies were not the same. In future studies, a more selective CBCT specification and data pooling based on ethnicities can be conducted to obtain more homogeneous results. The use of a limited-view CBCT device with specified resolution and lower voxel size will provide superior image quality, helping to explore the root and canal morphology more accurately. Root canal systems of maxillary



first molars are complex and unpredictable. They vary among populations, and even in individuals in the same population. Cohort studies, in which the same individuals are observed over time, are necessary to analyze and describe various factors, such as age, which can determine whether MB canals narrow or calcify in a canal, and whether age can affect the number and size of the MB canals in maxillary molars.

## 5. Conclusions

From this systematic review, we can conclude that type I RCC is most frequent, based on the Vertucci classification of the maxillary first molars. Palatal and distobuccal roots have a more-or-less simple anatomy, with one canal and mostly type I configuration. However, the mesiobuccal root has a more complex anatomy due to the high frequency of occurrence of a second mesiobuccal canal; furthermore, in the mesiobuccal root, the occurrence of type II RCC, which is closely followed by type IV RCC, is more common. Hence, care must be taken during biomechanical preparation of the mesiobuccal roots. CBCT can act as an auxiliary to help endodontists obtain a better visualization of the anatomy of the mesiobuccal root and help in detecting additional canals, thus ensuring successful endodontic treatment.

**Author Contributions:** Conceptualization, S.B. and V.M.; methodology, P.J. and A.M. (Aida Meto); software, V.M.; validation, R.S., A.M. (Ankita Mathur) and D.C.; formal analysis, D.C.; investigation, T.S.; resources, P.P.; data curation, D.C.; writing—original draft preparation, V.M.; writing—review and editing, V.M.; visualization, D.C., A.M.P., D.A.W. and A.M.L.; supervision, R.S.; project administration, A.M. (Ankita Mathur). All authors have read and agreed to the published version of the manuscript.

**Funding:** This research received no external funding.

**Institutional Review Board Statement:** Not applicable.

**Informed Consent Statement:** Not applicable.

**Data Availability Statement:** The reported systematic review and meta-analysis is registered with PROSPERO reg no.: CRD42021259436 available at [https://www.crd.york.ac.uk/prospero/export\\_details\\_pdf.php](https://www.crd.york.ac.uk/prospero/export_details_pdf.php) (accessed on 13 August 2022).

**Conflicts of Interest:** The authors declare no conflict of interest.

## References

1. Selwitz, R.H.; Ismail, A.I.; Pitts, N.B. Dental Caries. *Lancet* **2007**, *369*, 51–59. [CrossRef]
2. Schilder, H. Cleaning and Shaping the Root Canal. *Dent. Clin. N. Am.* **1974**, *18*, 269–296. [CrossRef]
3. Iandolo, A.; Michele, S.; Stefano, O.; Sandro, R. 3D Cleaning, a Perfected Technique: Thermal Profile Assessment of Heated NaOCl. *G. Ital. Endod.* **2017**, *31*, 58–61. [CrossRef]
4. Iandolo, A.; Abdellatif, D.; Pantaleo, G.; Sammartino, P.; Amato, A. Conservative Shaping Combined with Three-Dimensional Cleaning Can Be a Powerful Tool: Case Series. *J. Conserv. Dent.* **2020**, *23*, 648–652. [CrossRef]
5. Antunes, H.S.; Rôças, I.N.; Alves, F.R.E.; Siqueira, J.F. Total and Specific Bacterial Levels in the Apical Root Canal System of Teeth with Post-Treatment Apical Periodontitis. *J. Endod.* **2015**, *41*, 1037–1042. [CrossRef]
6. Ricucci, D.; Siqueira, J.F. Fate of the Tissue in Lateral Canals and Apical Ramifications in Response to Pathologic Conditions and Treatment Procedures. *J. Endod.* **2010**, *36*, 1–15. [CrossRef]
7. Siqueira, J.F. Aetiology of Root Canal Treatment Failure: Why Well-Treated Teeth Can Fail. *Int. Endod. J.* **2001**, *34*, 1–10. [CrossRef]
8. Lin, L.M.; Rosenberg, P.A.; Lin, J. Do Procedural Errors Cause Endodontic Treatment Failure? *J. Am. Dent. Assoc.* **2005**, *136*, 187–193. [CrossRef]
9. Ahmed, H.A.; Abu-bakr, N.H.; Yahia, N.A.; Ibrahim, Y.E. Root and Canal Morphology of Permanent Mandibular Molars in a Sudanese Population. *Int. Endod. J.* **2007**, *40*, 766–771. [CrossRef]
10. Malagnino, V.; Gallottini, L.; Passariello, P. Some Unusual Clinical Cases on Root Anatomy of Permanent Maxillary Molars. *J. Endod.* **1997**, *23*, 127–128. [CrossRef]
11. Weine, F.S.; Healey, H.J.; Gerstein, H.; Evanson, L. Canal Configuration in the Mesiobuccal Root of the Maxillary First Molar and Its Endodontic Significance. 1969. *J. Endod.* **2012**, *38*, 1305–1308. [CrossRef] [PubMed]
12. Vertucci, F.J. Root Canal Anatomy of the Human Permanent Teeth. *Oral. Surg Oral Med. Oral Pathol.* **1984**, *58*, 589–599. [CrossRef]
13. Sert, S.; Bayirli, G.S. Evaluation of the Root Canal Configurations of the Mandibular and Maxillary Permanent Teeth by Gender in the Turkish Population. *J. Endod.* **2004**, *30*, 391–398. [CrossRef]



14. Ahmed, H.M.A.; Dummer, P.M.H. Advantages and Applications of a New System for Classifying Roots and Canal Systems in Research and Clinical Practice. *Eur. Endod. J.* **2018**, *3*, 9–17. [[CrossRef](#)] [[PubMed](#)]
15. Reit, C.; Petersson, K.; Molven, O. Diagnosis of Pulpal and Periapical Disease. In *Textbook of Endodontology*; Blackwell Munksgaard: Copenhagen, Denmark, 2003; pp. 9–18.
16. Zheng, Q.; Wang, Y.; Zhou, X.; Wang, Q.; Zheng, G.; Huang, D. A Cone-Beam Computed Tomography Study of Maxillary First Permanent Molar Root and Canal Morphology in a Chinese Population. *J. Endod.* **2010**, *36*, 1480–1484. [[CrossRef](#)]
17. Tu, M.-G.; Tsai, C.-C.; Jou, M.-J.; Chen, W.-L.; Chang, Y.-F.; Chen, S.-Y.; Cheng, H.-W. Prevalence of Three-Rooted Mandibular First Molars among Taiwanese Individuals. *J. Endod.* **2007**, *33*, 1163–1166. [[CrossRef](#)]
18. Pinsky, H.M.; Dyda, S.; Pinsky, R.W.; Misch, K.A.; Sarment, D.P. Accuracy of Three-Dimensional Measurements Using Cone-Beam CT. *Dentomaxillofac. Radiol.* **2006**, *35*, 410–416. [[CrossRef](#)]
19. Lo Giudice, G.; Iannello, G.; Terranova, A.; Lo Giudice, R.; Pantaleo, G.; Cicciù, M. Transcrestal Sinus Lift Procedure Approaching Atrophic Maxillary Ridge: A 60-Month Clinical and Radiological Follow-Up Evaluation. *Int. J. Dent.* **2015**, *2015*, 261652. [[CrossRef](#)]
20. Blattner, T.C.; George, N.; Lee, C.C.; Kumar, V.; Yelton, C.D.J. Efficacy of Cone-Beam Computed Tomography as a Modality to Accurately Identify the Presence of Second Mesiobuccal Canals in Maxillary First and Second Molars: A Pilot Study. *J. Endod.* **2010**, *36*, 867–870. [[CrossRef](#)]
21. Matherne, R.P.; Angelopoulos, C.; Kulild, J.C.; Tira, D. Use of Cone-Beam Computed Tomography to Identify Root Canal Systems In Vitro. *J. Endod.* **2008**, *34*, 87–89. [[CrossRef](#)]
22. Martins, J.N.R.; Marques, D.; Silva, E.J.N.L.; Caramês, J.; Versiani, M.A. Prevalence Studies on Root Canal Anatomy Using Cone-Beam Computed Tomographic Imaging: A Systematic Review. *J. Endod.* **2019**, *45*, 372–386.e4. [[CrossRef](#)]
23. Martins, J.N.R.; Versiani, M.A. CBCT and Micro-CT on the Study of Root Canal Anatomy. In *The Root Canal Anatomy in Permanent Dentition*; Versiani, M.A., Basrani, B., Sousa-Neto, M.D., Eds.; Springer International Publishing: Cham, Switzerland, 2019; pp. 89–180.
24. Yousuf, W.; Khan, M.; Mehdi, H. Endodontic Procedural Errors: Frequency, Type of Error, and the Most Frequently Treated Tooth. *Int. J. Dent.* **2015**, *2015*, 673914. [[CrossRef](#)]
25. Verma, P.; Love, R.M. A Micro CT Study of the Mesiobuccal Root Canal Morphology of the Maxillary First Molar Tooth. *Int. Endod. J.* **2011**, *44*, 210–217. [[CrossRef](#)] [[PubMed](#)]
26. Moher, D.; Shamseer, L.; Clarke, M.; Ghersi, D.; Liberati, A.; Petticrew, M.; Shekelle, P.; Stewart, L.A.; PRISMA-P Group. Preferred Reporting Items for Systematic Review and Meta-Analysis Protocols (PRISMA-P) 2015 Statement. *Syst. Rev.* **2015**, *4*, 1. [[CrossRef](#)] [[PubMed](#)]
27. Balk, E.M.; Chung, M.; Hadar, N.; Patel, K.; Yu, W.W.; Trikalinos, T.A.; Chang, L.K.W. *Accuracy of Data Extraction of Non-English Language Trials with Google Translate*; Report No.: 12-EHC056-EF; Agency for Healthcare Research and Quality: Rockville, MD, USA, 2012.
28. Martins, J.N.R.; Kishen, A.; Marques, D.; Nogueira Leal Silva, E.J.; Caramês, J.; Mata, A.; Versiani, M.A. Preferred Reporting Items for Epidemiologic Cross-Sectional Studies on Root and Root Canal Anatomy Using Cone-Beam Computed Tomographic Technology: A Systematized Assessment. *J. Endod.* **2020**, *46*, 915–935. [[CrossRef](#)] [[PubMed](#)]
29. Zhang, R.; Yang, H.; Yu, X.; Wang, H.; Hu, T.; Dummer, P.M.H. Use of CBCT to Identify the Morphology of Maxillary Permanent Molar Teeth in a Chinese Subpopulation. *Int. Endod. J.* **2011**, *44*, 162–169. [[CrossRef](#)] [[PubMed](#)]
30. Kim, Y.; Lee, S.-J.; Woo, J. Morphology of Maxillary First and Second Molars Analyzed by Cone-Beam Computed Tomography in a Korean Population: Variations in the Number of Roots and Canals and the Incidence of Fusion. *J. Endod.* **2012**, *38*, 1063–1068. [[CrossRef](#)] [[PubMed](#)]
31. Tocci, L.; Plotino, G.; Grande, N.M.; Testarelli, L.; Messineo, D.; Ciotti, M.; Gambarini, G. Analysis of root and root canal morphology of maxillary and mandibular molars in a Caucasian population: CBCT study in vivo. *G. Ital. Endod.* **2013**, *27*, 13–20. [[CrossRef](#)]
32. Guo, J.; Vahidnia, A.; Sedghizadeh, P.; Enciso, R. Evaluation of Root and Canal Morphology of Maxillary Permanent First Molars in a North American Population by Cone-Beam Computed Tomography. *J. Endod.* **2014**, *40*, 635–639. [[CrossRef](#)]
33. Altunsoy, M.; Ok, E.; Nur, B.G.; Aglarci, O.S.; Gungor, E.; Colak, M. Root Canal Morphology Analysis of Maxillary Permanent First and Second Molars in a Southeastern Turkish Population Using Cone-Beam Computed Tomography. *J. Dent. Sci.* **2015**, *10*, 401–407. [[CrossRef](#)]
34. Abarca, J.; Gómez, B.; Zaror, C.; Monardes, H.; Bustos, L.; Cantin, M. Determinación de la Morfología de la Raíz Mesial y la Frecuencia del Canal MB2 en Molares Maxilares Usando Tomografía Computadorizada de Haz Cónico. *Int. J. Morphol.* **2015**, *33*, 1333–1337. [[CrossRef](#)]
35. Kalender, A.; Celikten, B.; Tufenkci, P.; Aksoy, U.; Basmacı, F.; Kelahmet, U.; Orhan, K. Cone Beam Computed Tomography Evaluation of Maxillary Molar Root Canal Morphology in a Turkish Cypriot Population. *Biotechnol. Biotechnol. Equip.* **2016**, *30*, 145–150. [[CrossRef](#)]
36. Naseri, M.; Safi, Y.; Akbarzadeh Baghban, A.; Khayat, A.; Eftekhari, L. Survey of Anatomy and Root Canal Morphology of Maxillary First Molars Regarding Age and Gender in an Iranian Population Using Cone-Beam Computed Tomography. *Iran. Endod. J.* **2016**, *11*, 298–303. [[CrossRef](#)]



37. Tian, X.-M.; Yang, X.-W.; Qian, L.; Wei, B.; Gong, Y. Analysis of the Root and Canal Morphologies in Maxillary First and Second Molars in a Chinese Population Using Cone-Beam Computed Tomography. *J. Endod.* **2016**, *42*, 696–701. [CrossRef]
38. Martins, J.N.R.; Marques, D.; Mata, A.; Caramês, J. Root and Root Canal Morphology of the Permanent Dentition in a Caucasian Population: A Cone-Beam Computed Tomography Study. *Int. Endod. J.* **2017**, *50*, 1013–1026. [CrossRef]
39. Al-Kadhimi, A.H.; Rajion, Z.A.; Malik, N.A.B.; Bin Jaafar, A. Morphology of Maxillary First Molars Analyzed by Cone-Beam Computed Tomography among Malaysian: Variations in the Number of Roots and Canals and the Incidence of Fusion. *Int. Med. J. Malays.* **2017**, *16*, 2. [CrossRef]
40. Pérez-Heredia, M.; Ferrer-Luque, C.M.; Bravo, M.; Castelo-Baz, P.; Ruíz-Piñón, M.; Baca, P. Cone-Beam Computed Tomographic Study of Root Anatomy and Canal Configuration of Molars in a Spanish Population. *J. Endod.* **2017**, *43*, 1511–1516. [CrossRef]
41. Zand, V.; Mokhtari, H.; Zonouzi, H.R.; Shojaei, S.N. Root Canal Morphologies of Mesio Buccal Roots of Maxillary Molars Using Cone Beam Computed Tomography and Periapical Radiographic Techniques in an Iranian Population. *J. Contemp. Dent. Pract.* **2017**, *18*, 745–749. [CrossRef]
42. Ghobashy, A.M.; Nagy, M.M.; Bayoumi, A.A. Evaluation of Root and Canal Morphology of Maxillary Permanent Molars in an Egyptian Population by Cone-Beam Computed Tomography. *J. Endod.* **2017**, *43*, 1089–1092. [CrossRef]
43. Al-Shehri, S.; Al-Nazhan, S.; Shoukry, S.; Al-Shwaimi, E.; Al-Sadhan, R.; Al-Shemmery, B. Root and Canal Configuration of the Maxillary First Molar in a Saudi Subpopulation: A Cone-Beam Computed Tomography Study. *Saudi Endod. J.* **2017**, *7*, 69. [CrossRef]
44. Wang, H.; Ci, B.-W.; Yu, H.-Y.; Qin, W.; Yan, Y.-X.; Wu, B.-L.; Ma, D.-D. Evaluation of Root and Canal Morphology of Maxillary Molars in a Southern Chinese Subpopulation: A Cone-Beam Computed Tomographic Study. *Int. J. Clin. Exp.* **2017**, *10*, 7030–7039. Available online: <https://e-century.us/files/ijcem/10/4/ijcem0045172.pdf> (accessed on 14 July 2022).
45. Khademi, A.; Zamani Naser, A.; Bahreinian, Z.; Mehdizadeh, M.; Najarian, M.; Khazaei, S. Root Morphology and Canal Configuration of First and Second Maxillary Molars in a Selected Iranian Population: A Cone-Beam Computed Tomography Evaluation. *Iran. Endod. J.* **2017**, *12*, 288–292. [CrossRef] [PubMed]
46. Ghoncheh, Z.; Zade, B.M.; Kharazifard, M.J. Root Morphology of the Maxillary First and Second Molars in an Iranian Population Using Cone Beam Computed Tomography. *J. Dent.* **2017**, *14*, 115–122. Available online: <https://www.ncbi.nlm.nih.gov/pmc/articles/PMC5694843/pdf/JOD-14-115.pdf> (accessed on 17 July 2022).
47. Martins, J.N.R.; Ordinola-Zapata, R.; Marques, D.; Francisco, H.; Caramês, J. Differences in Root Canal System Configuration in Human Permanent Teeth within Different Age Groups. *Int. Endod. J.* **2018**, *51*, 931–941. [CrossRef] [PubMed]
48. Martins, J.N.R.; Gu, Y.; Marques, D.; Francisco, H.; Caramês, J. Differences on the Root and Root Canal Morphologies between Asian and White Ethnic Groups Analyzed by Cone-Beam Computed Tomography. *J. Endod.* **2018**, *44*, 1096–1104. [CrossRef] [PubMed]
49. Razumova, S.; Brago, A.; Khaskhanova, L.; Barakat, H.; Howijeh, A. Evaluation of Anatomy and Root Canal Morphology of the Maxillary First Molar Using the Cone-Beam Computed Tomography among Residents of the Moscow Region. *Contemp. Clin. Dent.* **2018**, *9*, S133–S136. [CrossRef]
50. Ratanajirasut, R.; Panichuttra, A.; Panmekiate, S. A Cone-Beam Computed Tomographic Study of Root and Canal Morphology of Maxillary First and Second Permanent Molars in a Thai Population. *J. Endod.* **2018**, *44*, 56–61. [CrossRef]
51. Martins, J.N.R.; Marques, D.; Francisco, H.; Caramês, J. Gender Influence on the Number of Roots and Root Canal System Configuration in Human Permanent Teeth of a Portuguese Subpopulation. *Quintessence Int.* **2018**, *49*, 103–111. [CrossRef]
52. Gomes Alves, C.R.; Martins Marques, M.; Stella Moreira, M.; Harumi Miyagi de Cara, S.P.; Silveira Bueno, C.E.; Lascala, C.Â. Second Mesio Buccal Root Canal of Maxillary First Molars in a Brazilian Population in High-Resolution Cone-Beam Computed Tomography. *Iran. Endod. J.* **2018**, *13*, 71–77. [CrossRef]
53. Raja, M.; Pradeep, S.; Mohan, M. Root canal morphology of maxillary first molar using cone-beam computed tomography in south Indian population. *J. Pharm. Res.* **2018**, *12*, 4.
54. Pan, J.Y.Y.; Parolia, A.; Chuah, S.R.; Bhatia, S.; Mutalik, S.; Pau, A. Root Canal Morphology of Permanent Teeth in a Malaysian Subpopulation Using Cone-Beam Computed Tomography. *BMC Oral Health* **2019**, *19*, 14. [CrossRef] [PubMed]
55. Mohara, N.T.; Coelho, M.S.; de Queiroz, N.V.; Borreau, M.L.S.; Nishioka, M.M.; de Jesus Soares, A.; Frozoni, M. Root Anatomy and Canal Configuration of Maxillary Molars in a Brazilian Subpopulation: A 125-Mm Cone-Beam Computed Tomographic Study. *Eur. J. Dent.* **2019**, *13*, 82–87. [CrossRef] [PubMed]
56. de Miranda Candeiro, G.T.; Gonçalves, S.D.S.; de Araújo Lopes, L.L.; de Freitas Lima, I.T.; Alencar, P.N.B.; Iglecias, E.F.; Silva, P.G.B. Internal Configuration of Maxillary Molars in a Subpopulation of Brazil's Northeast Region: A CBCT Analysis. *Braz. Oral Res.* **2019**, *33*, e082. [CrossRef]
57. Soh, N. Evaluation of Root Canal Morphology of Maxillary 1st Molars Using Cone Beam Computed Tomography in Chennai Population. *J. Pharm. Sci. Res.* **2019**, *11*, 2750–2754. Available online: <https://jpsr.pharmainfo.in/Documents/Volumes/vol11issue07/jpsr11071948.pdf> (accessed on 14 July 2022).
58. Al Mheiri, E.; Chaudhry, J.; Abdo, S.; El Abed, R.; Khamis, A.H.; Jamal, M. Evaluation of Root and Canal Morphology of Maxillary Permanent First Molars in an Emirati Population; a Cone-Beam Computed Tomography Study. *BMC Oral Health* **2020**, *20*, 274. [CrossRef] [PubMed]
59. Alsaket, Y.; El-ma'aite, A.; Aqrabawi, J.; Alhadidi, A. Prevalence and Configuration of the Second Mesio Buccal Canal in the Permanent Maxillary First Molar in Jordanian Population Sample. *Iran. Endod. J.* **2020**, *15*, 217–220. [CrossRef]



60. Liu, Y.; Yang, W.; Wang, W.; Zhu, Y.; Lin, Z.; Zhu, M. Relationship between Canal Morphology and Isthmus in Mesio-Buccal Roots of Maxillary First Molars in 9- to 12-Year-Old Children: An In-Vivo Cone-Beam Computed Tomography Analysis. *Arch. Oral Biol.* **2020**, *112*, 104645. [[CrossRef](#)]
61. Popović, M.; Živanović, S.; Vučićević, T.; Grujović, M.; Papić, M. Cone-Beam Computed Tomography Study of Tooth Root and Canal Morphology of Permanent Molars in a Serbian Population. *Vojnosanit. Pregl.* **2020**, *77*, 470–478. [[CrossRef](#)]
62. Al-Saedi, A.; Al-Bakhakh, B.; Al-Taei, R.G. Using Cone-Beam Computed Tomography to Determine the Prevalence of the Second Mesio Buccal Canal in Maxillary First Molar Teeth in a Sample of an Iraqi Population. *Clin. Cosmet. Investig. Dent.* **2020**, *12*, 505–514. [[CrossRef](#)]
63. Nikkardar, N.; Asnaashari, M.; Karimi, A.; Araghi, S.; Seifitabar, S.; Golshah, A. Root and Canal Morphology of Maxillary Teeth in an Iranian Subpopulation Residing in Western Iran Using Cone-Beam Computed Tomography. *Iran. Endod. J.* **2020**, *15*, 31–37. [[CrossRef](#)]
64. Peiris, R. Root and Canal Morphology of Human Permanent Teeth in a Sri Lankan and Japanese Population. *Anthropol. Sci.* **2008**, *116*, 123–133. [[CrossRef](#)]
65. Campos Netto, P.D.A.; Dos Santos Accioly Lins, C.C.; Lins, C.V.; Lima, G.A.; Gomes Frazão, M.A. Study of the Internal Morphology of the Mesio Buccal Root of Upper First Permanent Molar Using Cone Beam Computed Tomography. *Int. J. Morphol.* **2011**, *29*, 617–621. [[CrossRef](#)]
66. Buyukbayram, I.; Kartal, N. Evaluation of Complex Mesio Buccal Root Anatomy in Maxillary First Molar Teeth. *Int. J. Morphol.* **2018**, *36*, 460–464. [[CrossRef](#)]
67. Rouhani, A.; Bagherpour, A.; Akbari, M.; Azizi, M.; Nejat, A.; Naghavi, N. Cone-Beam Computed Tomography Evaluation of Maxillary First and Second Molars in Iranian Population: A Morphological Study. *Iran. Endod. J.* **2014**, *9*, 190–194. Available online: <https://www.ncbi.nlm.nih.gov/pmc/articles/PMC4099950/pdf/iej-9-190.pdf> (accessed on 17 July 2022).
68. Weng, X.-L.; Yu, S.-B.; Zhao, S.-L.; Wang, H.-G.; Mu, T.; Tang, R.-Y.; Zhou, X.-D. Root Canal Morphology of Permanent Maxillary Teeth in the Han Nationality in Chinese Guanzhong Area: A New Modified Root Canal Staining Technique. *J. Endod.* **2009**, *35*, 651–656. [[CrossRef](#)]
69. Faraj, B.M. The Frequency of the Second Mesio Buccal Canal in Maxillary First Molars among a Sample of the Kurdistan Region-Iraq Population—A Retrospective Cone-Beam Computed Tomography Evaluation. *J. Dent. Sci.* **2021**, *16*, 91–95. [[CrossRef](#)]
70. Martins, J.N.R.; Alkawas, M.-B.A.M.; Altaki, Z.; Bellardini, G.; Berti, L.; Boveda, C.; Chaniotis, A.; Flynn, D.; Gonzalez, J.A.; Kottoor, J.; et al. Worldwide Analyses of Maxillary First Molar Second Mesio Buccal Prevalence: A Multicenter Cone-Beam Computed Tomographic Study. *J. Endod.* **2018**, *44*, 1641–1649.e1. [[CrossRef](#)]
71. Betancourt, P.; Navarro, P.; Muñoz, G.; Fuentes, R. Prevalence and Location of the Secondary Mesio Buccal Canal in 1100 Maxillary Molars Using Cone Beam Computed Tomography. *BMC. Med. Imaging* **2016**, *16*, 66. [[CrossRef](#)]
72. Sousa, T.O.; Haiter-Neto, F.; Nascimento, E.H.L.; Peroni, L.V.; Freitas, D.Q.; Hassan, B. Diagnostic Accuracy of Periapical Radiography and Cone-Beam Computed Tomography in Identifying Root Canal Configuration of Human Premolars. *J. Endod.* **2017**, *43*, 1176–1179. [[CrossRef](#)]
73. Abuabara, A.; Baratto-Filho, F.; Aguiar Anele, J.; Leonardi, D.P.; Sousa-Neto, M.D. Efficacy of Clinical and Radiological Methods to Identify Second Mesio Buccal Canals in Maxillary First Molars. *Acta Odontol. Scand.* **2013**, *71*, 205–209. [[CrossRef](#)]
74. Gaêta-Araujo, H.; Fontenele, R.C.; Nascimento, E.H.L.; do Carmo Chagas Nascimento, M.; Freitas, D.Q.; de Oliveira-Santos, C. Association between the Root Canal Configuration, Endodontic Treatment Technical Errors, and Periapical Hypodensities in Molar Teeth: A Cone-Beam Computed Tomographic Study. *J. Endod.* **2019**, *45*, 1465–1471. [[CrossRef](#)] [[PubMed](#)]
75. Nascimento, E.H.L.; Gaêta-Araujo, H.; Andrade, M.F.S.; Freitas, D.Q. Prevalence of Technical Errors and Periapical Lesions in a Sample of Endodontically Treated Teeth: A CBCT Analysis. *Clin. Oral Investig.* **2018**, *22*, 2495–2503. [[CrossRef](#)] [[PubMed](#)]
76. Song, M.; Kim, H.-C.; Lee, W.; Kim, E. Analysis of the Cause of Failure in Nonsurgical Endodontic Treatment by Microscopic Inspection during Endodontic Microsurgery. *J. Endod.* **2011**, *37*, 1516–1519. [[CrossRef](#)] [[PubMed](#)]