

The expression of interleukin-1 β and nuclear factor erythroid-2 in the periodontitis after treatment of liquid smoke rice hull

Ira Arundina,
Theresia Indah Budhy¹,
Wisnu Setyari Juliastuti,
Meircurius Dwi Condro Surboyo²,
Anisa Nur Halimah³,
Putrisa Lestari³

Departments of Oral Biology, ¹Oral Pathology Maxillofacial, ²Oral Medicine and ³Master of Dental Science Program, Faculty of Dental Medicine, Universitas Airlangga, Surabaya, Indonesia

J. Adv. Pharm. Technol. Res.

ABSTRACT

Nonsurgical treatment such as scaling and root planing has been the main therapy of periodontal management. However, some individuals are nonresponsive with only mechanical therapy. Rice hull liquid smoke (RH-LS) with higher of phenolic compound supposed to interfere with inflammation process. Thus, the purpose of this study is to investigate the anti-inflammation properties of RH-LS for chronic periodontitis adjunct therapy by observing the expression of nuclear factor erythroid-2 (Nrf-2) and interleukin-1 β (IL-1 β). Two groups of Wistar rats were used. Control group was induced by 1×10^9 colony-forming unit (CFU)/ml *Porphyromonas gingivalis* (PG) and treated with aquadest for 2 and 7 days. Meanwhile, the other group was induced by 1×10^9 CFU/ml PG and treated with RH-LS for 2 and 7 days. Two central incisive/mandibulae were dissected and stained with immunohistochemistry for analyzed the expression of Nrf-2 and IL-1 β . Data were then analyzed statistically using independent *t*-test ($P = 0.05$). Treatment with RH-LS for 7 days showed lower expression of IL-1 β (4.00 ± 1.58) than control group (13.60 ± 2.70) and showed higher expression of Nrf-2 (11.60 ± 1.95) than control group (4.20 ± 1.64) ($P = 0.000$) ($P < 0.05$). Treatment of RH-LS for 2 days showed higher expression of Nrf-2 (2.20 ± 1.31) than control group (6.80 ± 1.92) ($P = 0.003$) ($P < 0.05$). RH-LS showed anti-inflammation properties by elevating the expression of Nrf-2 and depressing expression of IL-1 β in periodontitis induced by PG.

Key words: Chronic periodontitis, human and health, IL-1 β , liquid smoke, nuclear factor erythroid-2 and *Porphyromonas gingivalis*

INTRODUCTION

Periodontitis is a chronic inflammatory disease that causes

Address for correspondence:

Dr. Ira Arundina,
Department of Oral Biology, Faculty of Dental Medicine,
Universitas Airlangga Jln. Prof. Dr. Moestopo 47, Surabaya
60132, Indonesia.
E-mail: ira-a@fkg.unair.ac.id

Submitted: 20-Jul-2021

Revised: 02-Jan-2022

Accepted: 24-Jan-2022

Published: 07-Apr-2022

Access this article online

Quick Response Code:



Website:

www.japtr.org

DOI:

10.4103/japtr.japtr_222_21

the destruction of the tooth-supporting structures such as the gingiva, periodontal ligament, and the alveolar bone. Dental plaque or tooth biofilm is required to induce this disease, but the main cause for destruction of the periodontal tissue is the host inflammatory response.^[1,2] Periodontitis affects about 20%–50% of global population both in developing and developed countries. Periodontitis is a cause of tooth loss and is considered one of the two highest prevalence of disease in the oral cavity.^[3] This infectious

This is an open access journal, and articles are distributed under the terms of the Creative Commons Attribution-NonCommercial-ShareAlike 4.0 License, which allows others to remix, tweak, and build upon the work non-commercially, as long as appropriate credit is given and the new creations are licensed under the identical terms.

For reprints contact: WKHLRPMedknow_reprints@wolterskluwer.com

How to cite this article: Arundina I, Budhy TI, Juliastuti WS, Surboyo MD, Halimah AN, Lestari P. The expression of interleukin-1 β and nuclear factor erythroid-2 in the periodontitis after treatment of liquid smoke rice hull. *J Adv Pharm Technol Res* 2022;13:95-9.

disease is caused by mixed microbial etiology such as *Porphyromonas gingivalis* (PG) that has been associated with many cases of chronic periodontitis. PG can internalize into human gingival fibroblast *in vitro* and survive antibiotic treatment.^[4] The presence of infection from PG, either in the form of bacteria or its lipopolysaccharide (LPS) product, against the gingival epithelial tissue will be recognized by the toll-like receptor 2 (TLR2) or TLR4 and causing the activation of the nuclear factor kappa B (NF- κ B) pathway by releasing the inhibitor NF- κ B (I κ B α) thus NF- κ B will enter the nucleus. Activation of NF- κ B into the nucleus will initiate the transcription and translation processes of inflammatory mediators, including pro-inflammatory cytokines such as interleukin-1 β (IL-1 β).^[5]

The main therapy for this disease is to remove the bacterial load. Still, the pathogenic microbes become more complex time to time and trigger different host inflammatory responses in each individual, so administration of adjunct therapy to controlling bacterial infections and inflammatory processes is needed.^[6] Adjunctive therapy strategies, such as anti-inflammatory and anti-bacterial properties, like chlorhexidine gluconate.^[7] However, these materials have numerous adverse effects and most importantly an increase in bacterial resistance against antibiotics highlights the need for the development of novel adjunctive strategies for the treatment and prevention of this prevalent disease.^[8]

Traditional medicine or phototherapeutics have become a clinical interest. Because this material contains many compounds that appear to provide a variety for oral health benefits. One of the natural ingredients known to have many benefits in accelerating the healing process is liquid smoke (LS).^[8] LS is a liquid of wood smoke, which is made by condensing the smoke of the incomplete combustion of wood that is burned indirectly at high temperatures. LS contains many compounds that can be grouped into acids, carbonyl and phenol. This compound could act as an antimicrobial and antioxidant agent while giving flavor and color formers.^[9] LS can be produced from rice hull (RH), coconut shell, walnut, and oil palm shell. In Indonesia, this liquid is usually used as a traditional preservative agent for meat, chicken, fish, and processed meat.^[10]

In a previous study, RH-LS contains 161 compounds. Both in cell and animal studies showed that the RH-LS exhibited strong anti-inflammatory, anti-allergic, and antioxidative activities.^[11] However, this potential is still not explored and analyzed extensively. The anti-inflammatory effect of RH-LS inhibits the formation of cytokines such as tumor necrosis factor (TNF- α), interleukin-1 α (IL-1 α), and IL-6.^[10,12] This LS has the potential to accelerate the healing process by increasing fibroblast and collagen formation.^[10,13] These potentials may be related to several types of phenol compounds with low molecular weight. One of the compounds contained in RH-LS is 4-ethylguaiacol

and 4-methylguaiacol. In particular, these compounds significantly increase the expression and activation of the nuclear factor erythroid-2/heme oxygenase-1 (Nrf-2/HO-1) and inhibit the NF- κ B/I κ B α signaling pathway.^[5,14] These phenol compounds will increase the production and release of Nrf-2 into the nucleus and will express HO-1 which functions to prevent the phosphorylation of NF- κ B/I κ B α , thereby reducing NF- κ B activation and its translocation to the nucleus, finally suppressing the development of inflammation.^[15] Thus, the purpose of this study is to investigate the anti-inflammation properties of RH-LS for chronic periodontitis adjunct therapy by observing the expression of Nrf-2 and IL-1 β .

MATERIALS AND METHODS

Rice hull liquid smoke

The RH is used from the species *Oryza sativa*. RH liquid smoked is obtained from RH through a pyrolysis process with a burning temperature of 400°C for 8 h, then condensation is carried out using a condenser, and after that, the distillation process is carried out using a temperature of 120°–150°C.^[16]

Experimental animals

This research has received ethical permission from the Health Experiment Committee, Faculty of Dental Medicine, Universitas Airlangga in Surabaya, with registration number 160/HRECC.FODM/III/2020. The experimental animals used were male Wistar rats (*Rattus norvegicus*) aged 5–6 months with a weight ranging from 250 to 300 g. The rationale for choosing age was based on previous studies where the size of the mandibles and gingiva was considered sufficient for bacterial and application.^[17]

Periodontitis model

This study uses an induction technique which is based on previous research.^[18] In this model, a stimulus (live bacteria) is injected directly into the connective tissue between the two mandibular incisors. Each mouse was given an injection of live PG (Pg ATCC 33277) as 1×10^9 colony-forming unit (CFU) in 20- μ l phosphate-buffered saline using a 0.5-cc syringe in the gingival sulcus on the mesial side of the mandibular central incisor. Bacterial injections are carried out every 3 days for 2 weeks. On the 14th day after bacterial induction, clinical signs of periodontitis will be seen as gingiva is reddish in color and swelling of the interdental incisive central mandibular area.

Treatment with RH-LS and aquadest (control) to animals was carried out by the method described by Santos *et al.*^[19] RH-LS was slowly applied into the periodontal pocket using a 1-ml syringe and a needle (0.04 mm \times 13 mm) (Terumo, Japan) without a bevel. During the application process, the oropharyngeal region of the experimental animals was covered with sterile gauze to prevent ingested

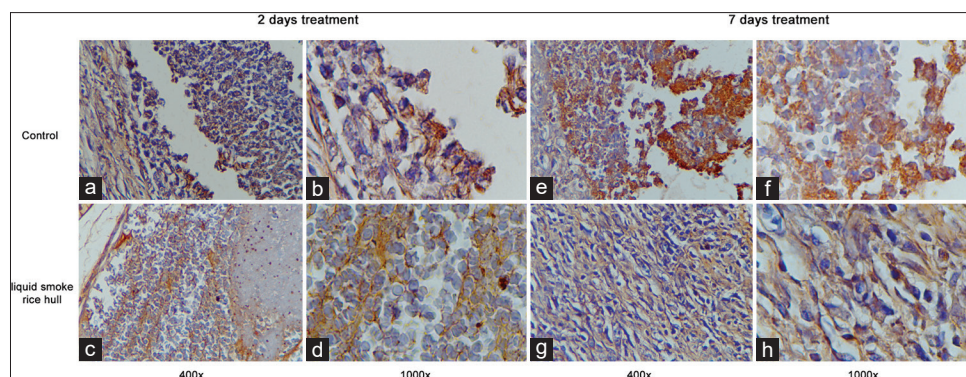


Figure 1: The expression of interleukin-1 β . (a and b) Control for 2 days; (c and d) Rice hull liquid smoke for 2 days; (e and f) Control for 7 days; (g and h) Rice hull liquid smoke for 7 days

RH-LS. This application was carried out for 2 and 7 days in each observation group. The dosage used is 20 μ L/20 g body weight.^[12]

Expression of nuclear factor erythroid-2 and interleukin-1 β

After being treated for 2 and 7 days, the rats were terminated and their central incisive and alveolar bone was subjected to biopsy before an immunohistochemistry staining to determine the expression of Nrf-2 (*anti-Nrf-2, polyclonal, antibodies-online GmbH, Germany*) and IL-1 β (*anti-IL-1 β , polyclonal, antibodies-online GmbH, Germany*). All measurements were done using light microscope (Nikon H600 Lu microscope, Nikon, Japan) with a magnification of \times 400 at five fields of view with a single-blind operator.

Statistical analysis

The data were shown in the form of mean \pm standard deviation ($X +$ standard deviation) for each group and each measurement. Then, the data were analyzed using independent *t*-test; the significance was set at $P < 0.05$.

RESULTS

Expression of interleukin-1 β

The expression of IL-1 β is presented in Figure 1. The expression of IL-1 β showed lower in the treatment of RH-LS compared to control group. Treatment with RH-LS for 2 days showed no difference compared to control group ($P = 0.070$). Only treatment for 7 days showed lower expression of IL-1 β in the treatment with RH-LS (4.00 ± 1.58) than control group (13.60 ± 2.70) ($P = 0.000$) [Figure 2].

Expression of nuclear factor erythroid-2

The expression of Nrf-2 is presented in Figure 3. The expression of Nrf-2 showed higher in the treatment of RH-LS compared to control group. Treatment with RH-LS for 2 days showed higher expression of Nrf-2 in the treatment with RH-LS (2.20 ± 1.31) compared to control group (6.80 ± 1.92) ($P = 0.003$). Treatment with RH-LS for 7 days showed higher expression of Nrf-2 in the

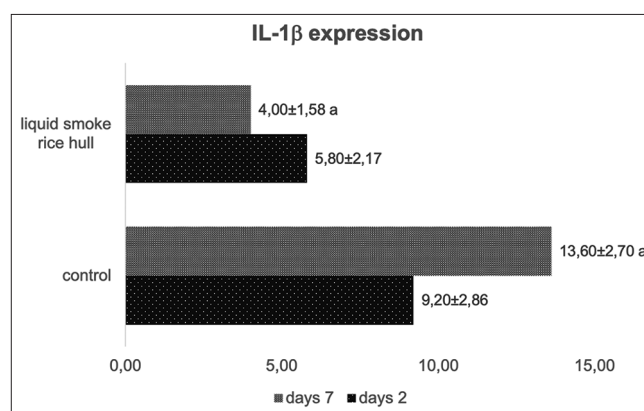


Figure 2: The expression of interleukin-1 β after 2 days and 7 days. The same character in each bar indicated significant different with independent *t*-test ($P < 0.05$)

treatment with RH-LS (11.60 ± 1.95) compared to control group (4.20 ± 1.64) ($P = 0.000$) [Figure 4].

DISCUSSION

From the research that has been conducted, treatment of RH-LS for 7 days could significantly decrease the expression of IL-1 β compared to controls. These cytokines are pro-inflammatory which usually increases at times of inflammation. The properties of IL-1 β could promote bone resorption and induce the production of tissue-degrading proteinases.^[7] Furthermore, treatment of RH-LS could increase the expression of Nrf-2 that plays a central role in regulating the antioxidant response element downstream and prevent tissue damage.^[20] There is a significant difference of expression of Nrf-2 compared to control for 2- and 7-day treatment of RH-LS. This result shows that RH-LS has anti-inflammatory and antioxidant properties.

The possible mechanism to explain is because this material contains several types of phenolic compounds with low molecular weight such as phenol, guaiacol, 4-ethyl-2-methoxy phenol, and 4-methylguaiacol.^[5,13] These phenolic compounds protect against increased oxidative

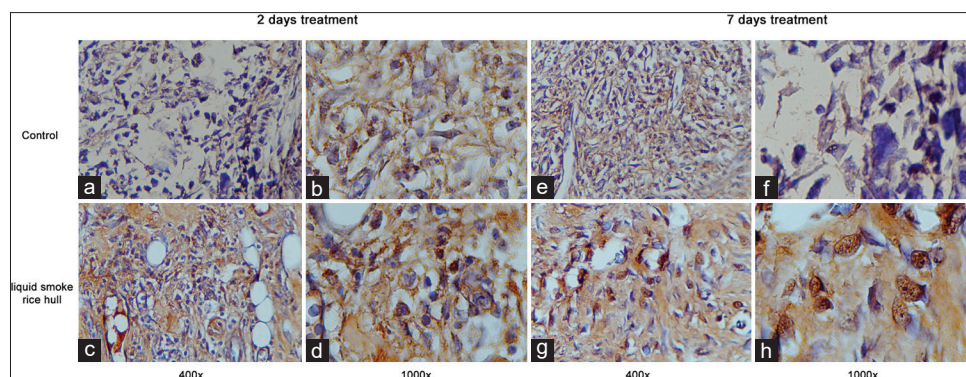


Figure 3: The expression of nuclear factor erythroid-2. (a and b) Control for 2 days; (c and d) Rice hull liquid smoke for 2 days; (e and f) Control for 7 days; (g and h) Rice hull liquid smoke for 7 days

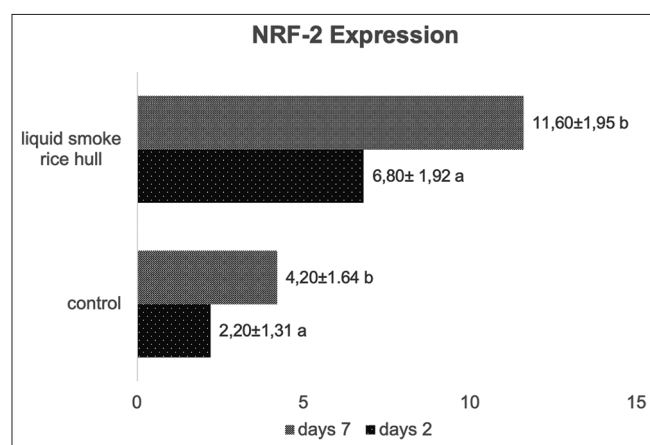


Figure 4: The expression of nuclear factor erythroid-2 after treatment for 2 days and 7 days. The same character in each bar indicated significant different with independent *t*-test ($P < 0.05$)

stress that formed during chronic periodontitis progression.^[8] The presence of a bacterial infection in gingival epithelial tissue will activate polymorphonuclear leukocyte (PMN) recruitment to the marginal lesion. At these sites, there is a sustained release of PMN enzymes and reactive oxygen species (ROS) into the extracellular environment as the host attempts to fight infection.^[21] Excessive production of ROS and a relative deficiency of antioxidants cause increased oxidative damage to proteins in the periodontium, lipid peroxidation in plasma, saliva, and gingival crevicular fluid, thus resulting tissue damage in a prolonged period of time.^[22] The antioxidant properties of RH-LS acquired by prevent the production of ROS in periodontal tissue by elevating expression of Nrf-2. Nrf-2 can upregulate Nrf2-associated antioxidant and detoxification enzymes, which enhances cytoprotective effects such as decreased inflammatory signaling and oxidative damage in tissues.^[8]

According to the previous study by Zhao *et al.*, they investigate the anti-inflammatory potential of 4-methylguaiacol on the genes and proteins related to NF- κ B and Nrf-2 signaling pathways in LPS-induced THP-1 cell model. This study shows that 4-methylguaiacol significantly inhibited the

overproduction of TNF- α , IL-1 β , IL-6, IL-8, NO, and prostaglandin E2 caused by LPS. Real-time polymerase chain reaction and western blot analyses revealed that 4-methylguaiacol was able to attenuate LPS-induced inflammatory response and inhibit the expression level of inflammatory cytokines and inflammasome by inducing Nrf-2 signaling pathway and inactivating the NF- κ B signaling pathways.^[15] This phenolic compound increases the production and release of Nrf-2 into the nucleus and will express HO-1 which functions are to prevent the phosphorylation of NF- κ B/I κ B α , thereby reducing NF- κ B activation and its translocation into the nucleus.^[23,24] This event will reduce inflammasome activation and the release of pro-inflammatory cytokines such as IL-1 β and suppress the development of inflammation.^[5]

Other than anti-inflammation and antioxidant properties, RH-LS also exhibits antibacterial properties. Another study also confirmed this condition. Kim *et al.*, RH-LS inactivated a resistant *Salmonella* strain in a dose-dependent manner with a minimum inhibitory concentration value of 1.29%. The oral feeding of RH-LS to mice infected with up to 1×10^7 CFUs of the resistant *Salmonella* strain indicates that the materials inhibited the growth of the pathogens in the digestive tract and several organs and increased the bacterial fecal count.^[25] Pilevar *et al.* combine RH-LS with *Echinophora platyloba* and investigate the anti-*Staphylococcus aureus* effect. The conducted experiments showed that liquid smoke had a better antimicrobial activity against *S aureus* than *Echinophora platyloba*.^[26] This is strengthening that RH-LS exhibits antibacterial properties.

CONCLUSION

RH-LS showed anti-inflammation properties by elevating the expression of Nrf-2 and depleting the expression of IL-1 β in periodontitis induced by PG.

Financial support and sponsorship

This work is supported by the Ministry of Higher Education 2020 in the schema Penelitian Tesis Magister (PTM) with grant number 606/UN3.14/PT/2020.

Conflicts of interest

There are no conflicts of interest.

REFERENCES

- Hajishengallis G. Immunomicrobial pathogenesis of periodontitis: Keystones, pathobionts, and host response. *Trends Immunol* 2014;35:3-11.
- Hajishengallis G. Periodontitis: From microbial immune subversion to systemic inflammation. *Nat Rev Immunol* 2015;15:30-44.
- Nazir MA. Prevalence of periodontal disease, its association with systemic diseases and prevention. *Int J Health Sci (Qassim)* 2017;11:72-80.
- Irshad M, van der Reijden WA, Crielaard W, Laine ML. *In vitro* invasion and survival of *Porphyromonas gingivalis* in gingival fibroblasts; role of the capsule. *Arch Immunol Ther Exp (Warsz)* 2012;60:469-76.
- Zhao DR, Jiang YS, Sun JY, Li HH, Luo XL, Zhao MM. Anti-inflammatory mechanism involved in 4-ethylguaiaicol-mediated inhibition of LPS-induced inflammation in THP-1 cells. *J Agric Food Chem* 2019;67:1230-43.
- Barça E, Çifcibaşı E, Çintan S. Adjunctive use of antibiotics in periodontal therapy. *J Istanbul Univ Fac Dent* 2015;49:55-62.
- Cheng R, Wu Z, Li M, Shao M, Hu T. Interleukin-1 β is a potential therapeutic target for periodontitis: A narrative review. *Int J Oral Sci* 2020;12:2.
- Bunte K, Hensel A, Beikler T. Polyphenols in the prevention and treatment of periodontal disease: A systematic review of *in vivo*, *ex vivo* and *in vitro* studies. *Fitoterapia* 2019;132:30-9.
- Budaraga IK, Arnim, Marlida Y, Bulanin U. Antioxidant properties of liquid smoke cinnamon production of variation of purification and different concentration. *Int J Sci Technol Res* 2016;5:266-73.
- Surboyo MD, Ernawati DS, Arundina I, Rahayu RP. Oral ulcer healing after treatment with distilled liquid smoke of coconut shell on diabetic rats. *J Krishna Inst Med Sci Univ* 2019;8:70-9.
- Kim SP, Kang MY, Park JC, Nam SH, Friedman M. Rice hull smoke extract inactivates *Salmonella typhimurium* in laboratory media and protects infected mice against mortality. *J Food Sci* 2012;77:M80-5.
- Kim SP, Yang JY, Kang MY, Park JC, Nam SH, Friedman M. Composition of liquid rice hull smoke and anti-inflammatory effects in mice. *J Agric Food Chem* 2011;59:4570-81.
- Surboyo MD, Arundina I, Rahayu RP. Increase of collagen in diabetes-related traumatic ulcers after the application of liquid smoke coconut shell. *Dent J (Majalah Kedokt Gigi)* 2017;71:71-5.
- Zhao D, Jiang Y, Sun J, Li H, Luo X, Zhao M, *et al.* Anti-inflammatory mechanism involved in 4-ethylguaiaicol-mediated inhibition of LPS-induced inflammation in THP-1 cells. *J Agric Food Chem* 2019;67:1230-43.
- Rui D, Song Y, Yuan J, He H, Tao X. Amelioration of 4-methylguaiaicol on LPS-induced inflammation in THP-1 cells through NF- κ B/I κ B α /AP-1 and Nrf2/HO-1 signaling pathway. *J.Funct.Foods* 2019;55:95-103.
- Salanti A, Zoia L, Orlandi M, Zanini F, Elegir G. Structural characterization and antioxidant activity evaluation of lignins from rice husk. *J Agric Food Chem* 2010;58:10049-55.
- Krismariono A. The decreasing of NF κ B level in gingival junctional epithelium of rat exposed to *Porphyromonas gingivalis* with application of 1% curcumin on gingival sulcus. *Dent J (Majalah Kedokt Gigi)* 2015;48:35.
- Zhang W, Ju J, Rigney T, Tribble G. *Porphyromonas gingivalis* infection increases osteoclastic bone resorption and osteoblastic bone formation in a periodontitis mouse model. *BMC Oral Health* 2014;14:89.
- Santos BF, Souza EQ, Brigagão MR, Lima DC, Fernandes LA. Local application of statins in the treatment of experimental periodontal disease in rats. *J Appl Oral Sci* 2017;25:168-76.
- Chiu AV, Saigh MA, McCulloch CA, Glogauer M. The role of Nrf2 in the regulation of periodontal health and disease. *J Dent Res* 2017;96:975-83.
- Cekici A, Kantarci A, Hasturk H, Van Dyke TE. Inflammatory and immune pathways in the pathogenesis of periodontal disease. *Periodontol* 2000 2014;64:57-80.
- Kurita-Ochiai T, Jia R, Cai Y, Yamaguchi Y, Yamamoto M. Periodontal disease-induced atherosclerosis and oxidative stress. *Antioxidants (Basel)* 2015;4:577-90.
- Surboyo MD, Mahdani FY, Ernawati DS, Sarasati A, Rezkita F. The macrophage responses during diabetic oral ulcer healing by liquid coconut shell smoke: An immunohistochemical analysis. *Eur J Dent* 2020;14:410-4.
- Surboyo MD, Arundina I, Rahayu RP, Mansur D, Bramantoro T. Potential of distilled liquid smoke derived from coconut (*Cocos nucifera* L) shell for traumatic ulcer healing in diabetic rats. *Eur J Dent* 2019;13:271-9.
- Kim SP, Lee SJ, Nam SH, Friedman M. Mechanism of antibacterial activities of a rice hull smoke extract (RHSE) against multidrug-resistant *Salmonella typhimurium* *in vitro* and in mice. *J Food Sci* 2018;83:440-5.
- Pilevar Z, Hosseini H, Hajimehdipoor H, Shahraz F, Alizadeh L, Khaneghah AM, *et al.* The anti-*Staphylococcus aureus* effect of combined *Echinophora platyloba* essential oil and liquid smoke in beef. *Food Technol Biotechnol* 2017;55:117-24.