

# Acute Toxicity Test of Liquid Smoke of Rice Hull (*Oryza sativa*) on Mice (*Mus Musculus*)

*by* Ira Arundina

---

**Submission date:** 26-Jul-2022 11:43AM (UTC+0800)

**Submission ID:** 1875293614

**File name:** Liquid\_Smoke\_of\_Rice\_Hull\_Oryza\_sativa\_on\_Mice\_Mus\_Musculus.pdf (508.14K)

**Word count:** 4285

**Character count:** 22076

## Acute Toxicity Test of Liquid Smoke of Rice Hull (*Oryza sativa*) on Mice (*Mus Musculus*)

Ira Arundina<sup>1\*</sup>, Tantiana<sup>1</sup>, Indeswati Diyatri<sup>1</sup>, Meircurius Dwi Condro Surboyo<sup>2</sup>, Rachma Adityasari<sup>3</sup>

1. Department of Oral Biology, Faculty of Dental Medicine, Universitas Airlangga, Surabaya – Indonesia.  
2. Department of Oral Medicine, Faculty of Dental Medicine, Universitas Airlangga, Surabaya – Indonesia.  
3. Undergraduate Student Faculty of Dental Medicine, Universitas Airlangga, Surabaya – Indonesia.

### Abstract

Liquid smoke as product of rice hull's pyrolysis is contained high phenolic compound such as phenol and guaiacol. These phenolic compound have been shown to have anti-inflammatory and antioxidant properties. Because of these properties, liquid smoke rice hull has the potential to be developed as a medicine. However, the safety of liquid smoke rice hull must be ensured to be used as a medicine.

The purpose of this study is to analyzed the effects of acute toxicity of liquid smoke rice hull (*sativa*) on mice (*Mus musculus*).

Laboratory experiment using 25 experimental mice which divided into 5 groups: control group (given aquadest), group 1, 2, 3 and 4 (given liquid smoke with a single dose by 50, 500, 5000, and 15000 mg/kg body weight orally). Symptoms of toxicity, weight changes, and the number of dead animals were noted for 7 days, whereas liver histopathology on the dead and living objects were observed after the observation period ended.

The LD50 of liquid smoke rice hull >15000mg/kg body weight. No toxicity symptoms were found in living animals. Changes in body weight in all groups tended to increase. Histopathology of the liver did not show a significant difference between the control group and the liquid smoke group (p=0.26).

Liquid smoke of rice hull (*Oryza sativa*) does not have an acute toxicity effect on mice (*Mus musculus*).

Experimental article (J Int Dent Med Res 2020; 13(1): 91-96)

**Keywords:** Liquid smoke of rice hull, acute toxicity test, LD50.

**Received date:** 15 April 2019

**Accept date:** 02 September 2019

### Introduction

Rice (*Oryza sativa*) is one of the important types of food crops, because it is a source of staple food in Indonesia.<sup>1</sup> The process of rice milling into milled rice can produce 63-67%, and by-product such as rice hull (the outer shell of rice as 15-20%), rice bran (the epidermis which produced from the rice hull stripping process as 8-12%), and groats (part of crushed rice as approximately 5%).<sup>2</sup> The by-products of the rice milling industry are generally not managed properly, so they will become a waste and can pollute the environment, in fact the by-products have useful value if managed properly, one of them is rice hull.<sup>3</sup>

The main composition of rice hull consists of cellulose, hemicellulose, and lignin. These ingredients will produce liquid smoke in the pyrolysis process. Pyrolysis is a condensation process of steam from rice hull combustion results at temperatures around 400°C without oxygen.<sup>4</sup> The chemical components of liquid smoke consist of phenol, guaiacol, and acetic acid.<sup>5,6</sup> Because of these components, liquid smoke rice hull has been shown to have antioxidant, anti-inflammatory and antimicrobial effects. According to Kim et al, liquid smoke rice hull has an anti-inflammatory effect. The topical application of 1% liquid smoke rice hull for two weeks in the ears of mice that has been applied by 12-O-Tetradecanolyphorbol-13-acetate (TPA) which is an ingredient to induce inflammation (edema) can reduce the release of biomarkers associated with the TPA-induced inflammation such as, tumor necrosis factor- $\alpha$  (TNF- $\alpha$ ), interleukin-1 $\beta$  (IL-1 $\beta$ ), interleukin-6 (IL-6), prostaglandin E<sub>2</sub> (PGE<sub>2</sub>), leukotriene B<sub>4</sub> (LTB<sub>4</sub>), and myeloperoxidase (MPO).<sup>5</sup> Liquid smoke has

#### \*Corresponding author:

Ira Arundina  
Department of Oral Biology, Faculty of Dental Medicine, Airlangga University, Jl. Mayjend. Prof. Dr. Moestopo no. 47 Surabaya 60132, Indonesia.  
E-mail: arundinaira@gmail.com

an antioxidant effect, because phenolic compounds consisting of phenol and guaiacol have the ability to arrest free radicals by providing hydrogen or electron donors and prevent oxidative damage to cells.<sup>7</sup> In addition, liquid smoke also has an antimicrobial effect because of acetic acid which is used as a processed meat preservative.<sup>8</sup> Based on the effects of liquid smoke rice hull as an antioxidant, anti-inflammatory, and antimicrobial, liquid smoke rice hull has the potential to be developed as a medicine.

The use of natural ingredients as traditional medicine in Indonesia have been used for cross generations in the health care system.<sup>9</sup> Liquid smoke has long been used by Indonesian ancestors to treat skin disease caused by fungi, viruses, and bacteria by applying it to the affected area.<sup>10</sup> Liquid smoke is also a traditional medicine used as an alternative topical agent for burn wound healing.<sup>11</sup> The use of natural ingredients as traditional medicine in society is increasingly widespread, so that research is needed in order to its use in accordance with the rules of health service and it must be accountable scientifically for the quality, safety, and efficacy of traditional medicine.<sup>12</sup>

The paradigm that develops in society today is that medicines derived from natural ingredients are harmless and have no side effects. This assumption is not entirely true. Each ingredient has the potential to be toxic, depends on how much the dose in the body.<sup>13</sup> So, the traditional medicine needs to be ensured of its safety, where acute toxicity test is the main test that must be done.<sup>14</sup> Acute toxicity test is a test to get the LD<sub>50</sub> value. Determination of LD<sub>50</sub> is the initial stage to determine the level of toxicity of liquid smoke rice hull. Therefore, this study aims to determine the LD<sub>50</sub> of liquid smoke rice hull which then will be used to determine the safety of the dose.

### Materials and methods

The protocol of this research was evaluated and approved by Ethics Committee for Health Research, Faculty of Dental Medicine, Universitas Airlangga Surabaya with registration number 285 / HRECC. FODM / X / 2018.

This research is a laboratory experimental with post-test only control group design. Experimental animals used were healthy male

mice (*Mus musculus*) in the age of 5-6 weeks with the weight of 20-30 grams. Those animals were obtained from Veterinaria Farma Center (PUSVETMA), Surabaya. Liquid smoke rice hull (*Oryza sativa*) was obtained through pyrolysis process. Pyrolysis is a condensation process of steam from rice hull combustion results at temperatures around 400°C without oxygen. Liquid smoke rice hull was made in Forest Products Research and Development Center Laboratory, Bogor.

Mice that will be used were acclimatized for 7 days with the aim of adapting experimental animals to the new environment. Mice used as experiment were divided into 5 groups; each group consisted of 5 mice. Control group was given aquadest, and group 1, 2, 3 and 4 were orally administered a single dose of liquid smoke rice hull at 50, 500, 5000, 15000 mg/kg body weight.

Experimental animals were observed individually at least in the first 4 hours after administration of the substance test and the next observation was carried out once every day for 7 days. The things observed in the observation period were: mortality of experimental animals, signs of toxicity (the condition of skin and fur, eyes, lethargy, convulsions, tremors, and diarrhea), and weight.<sup>15</sup> At the end of the study, survival animals were weighed and then sacrificed. Observations were made on histopathology liver organs using a light microscope with a magnification of 400x. Each preparation was observed through five different views. Scoring was done using parameter scores of liver tissue damage according to Table 1.<sup>16</sup> The LD<sub>50</sub> value was obtained from the number of mice deaths using the Probit-graph method. Histopathology of mice liver data were analyzed using the Kruskal-Wallis test.

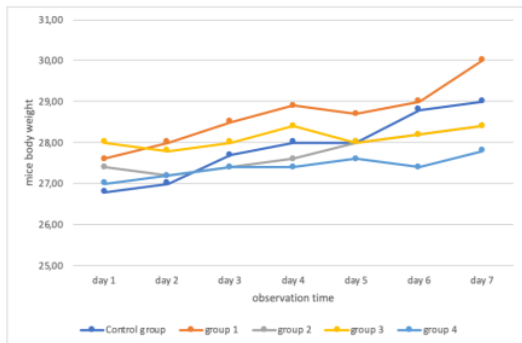
Score	Parameter				Sinusoid	Degree of damage
	Hepatocytes Nucleus	Cytoplasm	Structure	Central vein		
0	Normal	Homogenous	Regular radial	Wide, normal	Normal, complete	Normal
1	Necrosis	Homogenous	Regular radial	Wide, normal	Normal, complete	Light damaged
2	Necrosis	Homogenous	Irregular	Narrow, abnormal	Incomplete (widened/narrowed)	Moderate damaged
3	Necrosis	Steatosis	Irregular	Narrow, abnormal	Incomplete (widened/narrowed)	Severe damaged

**Table 1.** Parameter scores of liver tissue damage<sup>16</sup>

**Results**

The results of observations on the mortality of the animals after administration of the substance test and continued for 7 day showed the highest dose which is 15000 mg/kg body weight causing the death of 1 mice with a percentage of 20% (less than 50%), so it can be interpreted that the LD<sub>50</sub> value is greater from 15000 mg/kg body weight and is categorized as a relatively harmless material.

Observation of mice body weight after administration of the substance test for 7 day, showed that the average body weight in the control group until treatment group 4 tended to increase. Changes in body weight in the treatment group did not show drastic weight loss when compared with control group (Figure 1).



**Figure 1.** Changes in mice body weight after administration of the substance test for 7 days observation.

Observation symptoms of toxicity that occur in experimental animals was observed once every day for 7 days with special observations in the first 4 hours after administration of the substance test. Observation symptoms of toxicity include skin and fur, eyes, lethargy, convulsions, tremors, and diarrhea. Administration of liquid smoke up to dose of 5000 mg/kg body weight result no symptoms of toxicity were found. Meanwhile, in one mice, the administration of liquid smoke dose of 15000 mg/kg body weight was found symptom of toxicity in the form of decreased motor activity and death after administration of the substance test. This symptom occurs in death mice, but does not occur in living mice (Table 2).

The results of mice liver histopathological observations in the acute toxicity test revealed that there was some damage that occurred in the

liver of mice on the control group and the treatment group. From all the data there were no significant differences of liver tissue damage between control group and all groups (p=0.26) (Table 3).

Observation	4 hours				Day 1				Day 2				Day 3			
	C	G1	G2	G4	C	G1	G2	G4	C	G1	G2	G4	C	G1	G2	G4
Skin and Fur	N	N	N	N	N	N	N	N	N	N	N	N	N	N	N	N
Eyes	N	N	N	N	N	N	N	N	N	N	N	N	N	N	N	N
Lethargy	-	-	-	-	-	-	-	-	-	-	-	-	-	-	-	-
Convulsions	-	-	-	-	-	-	-	-	-	-	-	-	-	-	-	-
Tremors	-	-	-	-	-	-	-	-	-	-	-	-	-	-	-	-
Diarrhea	-	-	-	-	-	-	-	-	-	-	-	-	-	-	-	-

Observation	Day 4				Day 5				Day 6				Day 7			
	C	G1	G2	G4	C	G1	G2	G4	C	G1	G2	G4	C	G1	G2	G4
Skin and Fur	N	N	N	N	N	N	N	N	N	N	N	N	N	N	N	N
Eyes	N	N	N	N	N	N	N	N	N	N	N	N	N	N	N	N
Lethargy	-	-	-	-	-	-	-	-	-	-	-	-	-	-	-	-
Convulsions	-	-	-	-	-	-	-	-	-	-	-	-	-	-	-	-
Tremors	-	-	-	-	-	-	-	-	-	-	-	-	-	-	-	-
Diarrhea	-	-	-	-	-	-	-	-	-	-	-	-	-	-	-	-

**Table 2.** Result the observation symptoms of toxicity.

C: Control groups  
 G1: Group administered with 50 mg/kg body weight  
 G2: Group administered with 500 mg/kg body weight  
 G3: Group administered with 5000 mg/kg body weight  
 G4: Group administered with 15000 mg/kg body weight  
 N: Normal  
 -: not found

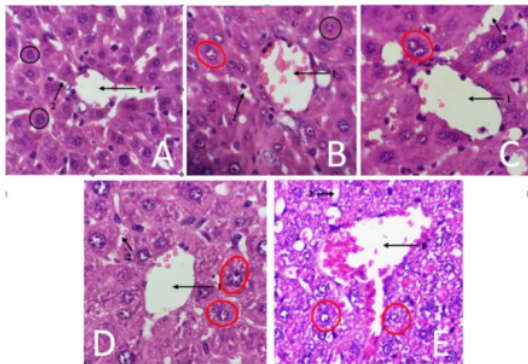
No	Treatment groups	Mean ± SD	p
1	Control group	1.84 ± 0.36	0.26
2	Group 1 (orally administered a single dose of liquid smoke rice hull at 50 mg/kg body weight)	1.80 ± 0.28	
3	Group 2 (orally administered a single dose of liquid smoke rice hull at 500 mg/kg body weight)	2.20 ± 0.20	
4	Group 3 (orally administered a single dose of liquid smoke rice hull at 5000 mg/kg body weight)	2.04 ± 0.36	
5	Group 4 (orally administered a single dose of liquid smoke rice hull at 15000 mg/kg body weight)	1.88 ± 0.64	

P= level of significance on Kruskal Wallis test (p<0.05)

**Table 3.** Data histopathology mice liver.

Histopathology result of mice liver observations are presented in Figure 2. Histopathology features mice liver in the control group (aquadest) showed normal conditions of liver structure. The visible area in the circle shows normal hepatocyte cells, which are round or oval cell forms with the nucleus in the middle of the cell. Central veins and sinusoidal are normal (Figure 2.A). Histopathology of mice liver in group 1 (dose 50 mg/kg body weight), the area in dark circles showed normal hepatocyte cells, which is round or oval cell forms with the nucleus in the middle of the cell and homogeneous cytoplasm. The area in the red circle shows that the hepatocyte cells degenerate, there is swelling in the hepatocyte cells, the cytoplasm appears pale. Normal central vein and sinusoid narrowing (Figure 2.B). Histopathology of mice liver in

group 2 (dose 500 mg/kg body weight), the area in red circle shows that the hepatocyte cells degenerate, which is seen as cell swelling, pale cytoplasm and vacuoles (empty spaces). The central vein is dilated and sinusoid is dilated (Figure 2.C). Histopathology of mice liver in group 3 (dose 5000 mg/kg body weight), the area in red circle showed that the hepatocyte cells degenerated, namely cell swelling, pale cytoplasm and vacuoles (empty spaces). The central vein is normal, but sinusoids are narrowed (Figure 2.D). Histopathology of mice liver in group 4 (dose 15000 mg/kg body weight) seen in the red circle shows that hepatocyte cells degenerate, namely cell swelling, pale cytoplasm and vacuoles (empty spaces). Central veins are widening. Sinusoid is narrowed (Figure 2.E).



**Figure 2.** Histopathological picture of mice liver with HE staining. Magnification of 400x. (A) control group, (B) 50 mg/kg body weight, (C) 500 mg/kg body weight (D) 5000 mg/kg body weight and (E) 15000 mg/kg body weight. Explanation: 1= central vein, 2 = sinusoid, ○ = normal hepatocytes, ● = hepatocytes degenerate.

Histopathology result of mice liver observations are presented in Figure 2. Histopathology features mice liver in the control group (aquadest) showed normal conditions of liver structure. The visible area in the circle shows normal hepatocyte cells, which are round or oval cell forms with the nucleus in the middle of the cell. Central veins and sinusoidal are normal (Figure 2.A). Histopathology of mice liver in group 1 (dose 50 mg/kg body weight), the area in dark circles showed normal hepatocyte cells, which is round or oval cell forms with the nucleus in the middle of the cell and homogeneous cytoplasm. The area in the red circle shows that

the hepatocyte cells degenerate, there is swelling in the hepatocyte cells, the cytoplasm appears pale. Normal central vein and sinusoid narrowing (Figure 2.B). Histopathology of mice liver in group 2 (dose 500 mg/kg body weight), the area in red circle shows that the hepatocyte cells degenerate, which is seen as cell swelling, pale cytoplasm and vacuoles (empty spaces). The central vein is dilated and sinusoid is dilated (Figure 2.C). Histopathology of mice liver in group 3 (dose 5000 mg/kg body weight), the area in red circle showed that the hepatocyte cells degenerated, namely cell swelling, pale cytoplasm and vacuoles (empty spaces). The central vein is normal, but sinusoids are narrowed (Figure 2.D). Histopathology of mice liver in group 4 (dose 15000 mg/kg body weight) seen in the red circle shows that hepatocyte cells degenerate, namely cell swelling, pale cytoplasm and vacuoles (empty spaces). Central veins are widening. Sinusoid is narrowed (Figure 2.E).

## Discussion

Determination of LD<sub>50</sub> value was done by observing and calculating the number of death mice after the substance test administration and observations continue every day for 7 days. The results showed that at the highest dose of 15000 mg/kg body weight only caused one death in five mice shortly after the substance test administration, with a percentage of 20% (less than 50%), so that the LD<sub>50</sub> value was greater than 15000 mg/kg body weight and categorized as relatively harmless substance. If acute toxicity is low, in the sense that the largest dose causes only a small number of deaths (does not fulfill 50% mortality), it can be assumed that all dangerous acute toxicity can be removed and LD<sub>50</sub> does not need to be determined. The death of one mouse may be due to cell injury that already exists before treatment. Another possibility is that the immune system in dead mice is lower than others, so it can increase susceptibility to various pathogens that enter the body.<sup>17</sup>

Toxicity symptoms which appeared were observed after the substance test administration every day during 7 days. Toxicity symptoms observation include observations of the skin and fur, eyes, lethargy, convulsions, tremors, and diarrhea. The treatment of liquid smoke up to a dose of 5000 mg/kg body weight did not reveal

any toxicity symptoms. Meanwhile in one mouse in the administration of liquid smoke the dose of 15000 mg/kg body weight showed symptoms of toxicity in the form of decreased motor activity and even death after dosing. This symptom occurs in dead mouse, but does not appear in living mice. During the observation of acute toxicity tests, body weight was observed periodically every day for 7 days. In general, changes in body weight in experimental animals will illustrate the toxicity that occurs after exposure to toxic substances. Drastic weight losses when compared to controls are usually a sign of toxicity.<sup>18</sup> In research, all the groups tend to increase of body weight during the observation. The increase in body weight of mice is in accordance with the age increase of mice and adequate feed consumption.<sup>19</sup>

As the main organ that metabolizes and detoxifies drugs and toxins in the body, the liver has the potential to suffer damage due to various chemicals. In the group 1 (dose of 50 mg/kg body weight) to group 4 (dose of 15000 mg/kg body weight) there was a degeneration (cell swelling). Cell swelling is caused by an increase in cell permeability, where cells are unable to maintain ionic and fluid homeostasis resulting in the transfer of extracellular fluid into the cell. This condition causes K<sup>+</sup> ions easily to exit the cell and vice versa Ca<sup>+</sup>, Na<sup>+</sup> ions and water easily enter the cell and cause swelling. Cell swelling is characterized by the presence of vacuoles (empty spaces). Cell swelling is the first manifestation that occurs in almost all forms of cell injury. This degeneration is reversible, meaning that if the stimulus that causes injury is removed and the cell gets good circulation, the cell will return to its original state.<sup>20,21</sup> In the groups 2 and 4, the central vein was dilated. Widening of the central vein is caused by the lysis of endothelial cells in the central vein.<sup>22</sup>

The damage that occurred in this study is probably due to the difference's responses in cellular level adaptation in animals. Cellular level adaptation is strongly influenced by immune responses and genetic structure in cells.<sup>23</sup> However, in one mice which died after the administration of liquid smoke rice hull, it was seen to have more severe damage than the other groups. This damage is caused by the immune system in dead mouse which is lower than other mice, thus increasing susceptibility to various pathogens that enter the body.<sup>24</sup> The results of

the Kruskal Wallis test for histopathology mice liver were sig > 0.05 which means there were no significant differences between the control group and the liquid smoke group. Even, this result showed the liquid smoke relatively harmless substance, but in animal model, the liquid smoke from other material, such as coconut shell, showed benefit effect as analgesic,<sup>25</sup> increased the fibroblast,<sup>11</sup> collagens,<sup>26</sup> and increased the healing process of oral ulceration.<sup>6</sup> For this reason we need to confirm the potential of liquid smoke rice hull further.

### Conclusions

This research showed that the LD<sub>50</sub> value >15000 mg/kg body weight and categorized as relatively harmless substance, there was no drastic weight loss in mice, no symptoms of toxicity during the observation period, and no significant differences in the histopathology of the liver organ in the control group with the liquid smoke group. Liquid smoke rice hull (*Oryza sativa*) does not have an acute toxicity effect on mice up to dose 15000 mg/kg body weight.

### Declaration of Interest

The authors report no conflict of interest and the article is not funded or supported by any research grant.

### References

1. Panuju DR, Mizuno K, Trisasongko BH. The dynamics of rice production in Indonesia 1961–2009. *J Saudi Soc Agric Sci* [Internet]. 2013;12(1):27–37. Available from: <http://dx.doi.org/10.1016/j.jssas.2012.05.002>
2. Chapagain AK, Hoekstra AY. The blue, green and grey water footprint of rice from production and consumption perspectives. *Ecol Econ* [Internet]. 2011;70(4):749–58. Available from: <http://dx.doi.org/10.1016/j.ecolecon.2010.11.012>
3. Suryaningsih S, Nurhilal O. Sustainable energy development of bio briquettes based on rice husk blended materials: An alternative energy source. *IOP Conf Ser J Phys*. 2018;1013(2018).
4. Risfaheri R, Hoerudin H, Syakir M. Utilization of Rice Husk for Production of Multifunctional Liquid Smoke. *J Adv Agric Technol* [Internet]. 2018;5(3):192–7. Available from: <http://www.joaat.com/index.php?m=content&c=index&a=show&catid=52&id=267>
5. Kim SP, Yang JY, Kang MY, Park JC, Nam SH, Friedman M. Composition of Liquid Rice Hull Smoke and Anti-Inflammatory Effects in Mice. *J Agric Food Chem* [Internet]. 2011 May 11;59(9):4570–81. Available from: <https://pubs.acs.org/doi/10.1021/jf2003392>
6. Surboyo MDC, Ernawati DS, Arundina I, Rahayu RP. Oral Ulcer Healing after Treatment with Distilled Liquid Smoke of Coconut Shell on Diabetic Rats. *J Krishna Inst Med Sci Univ*. 2019;8(2):70–9.

7. Costa G, Francisco V, C. Lopes M, T. Cruz M, T. Batista M. Intracellular Signaling Pathways Modulated by Phenolic Compounds: Application for New Anti-Inflammatory Drugs Discovery. *Curr Med Chem* [Internet]. 2012 Jun 1;19(18):2876–900. Available from: <http://openurl.ingenta.com/content/xref?genre=article&issn=0929-8673&volume=19&issue=18&spage=2876>.
8. Lingbeck JM, Cordero P, Bryan CAO, Johnson MG, Ricke SC, Crandall PG. Functionality of liquid smoke as an all-natural antimicrobial in food preservation. *meat Sci* [Internet]. 2014;97(2):197–206. Available from: <http://dx.doi.org/10.1016/j.meatsci.2014.02.003>
9. Widowati L, Nurhayati. The Use of Traditional Health Care Among Indonesian Family. *Heal Sci J Indones*. 2017;8(1):30–5.
10. Souza JLS de, Guimarães VB da S, Campos AD, Lund RG. Antimicrobial potential of pyrolytic extracts – a systematic review and technological prospecting. *Brazilian J Microbiol* [Internet]. 2018;49:128–39. Available from: <https://doi.org/10.1016/j.bjm.2018.07.001>
11. Tarawan VM, Mantilidewi KI, Dhini IM, Radhiyanti PT, Sutedia E. Coconut Shell Liquid Smoke Promotes Burn Wound Healing. *J Evid Based Complementary Altern Med* [Internet]. 2017 Jul 29;22(3):436–40. Available from: <http://journals.sagepub.com/doi/10.1177/2156587216674313>
12. Zhang J, Onakpoya IJ, Posadzki P, Eddouks M. The Safety of Herbal Medicine: From Prejudice to Evidence. *Evidence-Based Complement Altern Med* [Internet]. 2015;2015:1–3. Available from: <http://www.hindawi.com/journals/ecam/2015/316706/>
13. Zhou X, Li C-G, Chang D, Bensoussan A. Current Status and Major Challenges to the Safety and Efficacy Presented by Chinese Herbal Medicine. *Medicines* [Internet]. 2019 Jan 18;6(1):14. Available from: <http://www.mdpi.com/2305-6320/6/1/14>
14. Ekor M. The growing use of herbal medicines: issues relating to adverse reactions and challenges in monitoring safety. *Front Pharmacol* [Internet]. 2014;4(177):1–10. Available from: <http://journal.frontiersin.org/article/10.3389/fphar.2013.00177/abstract>
15. Aiyalu R, Ramasamy A. Acute and sub-acute Toxicity study of Aqueous extracts of *Canscora heteroclita* (L) Gilg in Rodents. *Pharmacogn J* [Internet]. 2016 Jul 1;8(4):399–410. Available from: <http://phcogj.com/article/177>
16. Singh T, Ruchi, Kumar R, Kumar V, Singh A. Evaluation of biochemical and histological effects on liver of Swiss albino mice due to acute oral toxicity of aqueous leaf extract of *Phyllanthus niruri*. *Int J Pharmacogn Phytochem Res*. 2016;8(1):85–90.
17. Erhirhie EO, Ihekwereme CP, Ilodigwe EE. Advances in acute toxicity testing: strengths, weaknesses and regulatory acceptance. *Interdiscip Toxicol* [Internet]. 2018 May 1;11(1):5–12. Available from: <http://content.sciendo.com/view/journals/intox/11/1/article-p5.xml>
18. Loha M, Mulu A, Abay SM, Ergete W, Geleta B. Acute and Subacute Toxicity of Methanol Extract of *Syzygium guineense* Leaves on the Histology of the Liver and Kidney and Biochemical Compositions of Blood in Rats. *Evidence-Based Complement Altern Med* [Internet]. 2019 Mar 10;2019:1–15. Available from: <https://www.hindawi.com/journals/ecam/2019/5702159/>
19. Wang M, Guckland A, Murfitt R, Ebeling M, Sprenger D, Foudoulakis M, et al. Relationship between magnitude of body weight effects and exposure duration in mammalian toxicology studies and implications for ecotoxicological risk assessment. *Environ Sci Eur* [Internet]. 2019;31(38):1–7. Available from: <https://doi.org/10.1186/s12302-019-0221-1>
20. Sisinta T, Bambang W, Kusnoputranto H. Cigarette Smoke Exposure and Oxidative Stress in Junior High School Children. *J Int Dent Med Res*. 2019;12(1):372–6.
21. Robinson MW, Hamon C, O'Farrelly C. Liver immunology and its role in inflammation and homeostasis. *Cell Mol Immunol* [Internet]. 2016 May 11;13(3):267–76. Available from: <http://www.nature.com/articles/cmi20163>
22. Brancatelli G, Furlan A, Calandra A, Dioguardi Burgio M. Hepatic sinusoidal dilatation. *Abdom Radiol* [Internet]. 2018;43(8):2011–22. Available from: <https://doi.org/10.1007/s00261-018-1465-8>
23. López Panqueva R del P. Morphological issues of drug induced liver disease. *Rev Colomb Gastroenterol*. 2014;29(4):449–60.
24. Kubes P, Jenne C. Immune Responses in the Liver. *Annu Rev Immunol* [Internet]. 2018 Apr 26;36(1):247–77. Available from: <https://doi.org/10.1146/annurev-immunol->
25. Surboyo MDC, Tantiana T, Arundina I. Analgesic effect of coconut shell (*Cocos nucifera* L) liquid smoke on mice. *Dent J (Majalah Kedokt Gigi)* [Internet]. 2012;45(3):156–60. Available from: <http://e-journal.unair.ac.id/index.php/MKG/article/view/819>
26. Surboyo MDC, Arundina I, Rahayu RP. Increase of collagen in diabetes-related traumatic ulcers after the application of liquid smoke coconut shell. *Dent J (Majalah Kedokt Gigi)* [Internet]. 2017;71(32):71–5. Available from: <https://e-journal.unair.ac.id/MKG/article/view/4493>

# Acute Toxicity Test of Liquid Smoke of Rice Hull (*Oryza sativa*) on Mice (*Mus Musculus*)

## ORIGINALITY REPORT

13%

SIMILARITY INDEX

9%

INTERNET SOURCES

10%

PUBLICATIONS

1%

STUDENT PAPERS

## PRIMARY SOURCES

- |   |  |    |
|---|--|----|
| 1 | <a href="http://www.scilit.net">www.scilit.net</a><br>Internet Source  | 1% |
| 2 | Gunanti Mahasri, Umi Hafidloh, Funky P. Pratama, Dicky Rahmawan, Sri Subekti, Putri D. Wulansari, Muhamad Amin. " Prevalence, intensity and histopathology of infestation on groupers reared on different aquaculture systems ", Journal of Fish Diseases, 2020<br>Publication | 1% |
| 3 | Hernani, S Yuliani, Rahmini. "Natural biopesticide from liquid rice hull smoke to control brown planthopper", IOP Conference Series: Earth and Environmental Science, 2021<br>Publication  | 1% |
| 4 | <a href="http://www.science.gov">www.science.gov</a><br>Internet Source  | 1% |
| 5 | <a href="http://publications.waset.org">publications.waset.org</a><br>Internet Source  | 1% |
| 6 | <a href="http://athmsi.org">athmsi.org</a><br>Internet Source  | 1% |



---

7	Intan Nirwana, Elly Munadziroh, Anita Yuliati, Azalia Izzah Fadhila et al. "Ellagic acid and hydroxyapatite promote angiogenesis marker in bone defect", Journal of Oral Biology and Craniofacial Research, 2022 Publication	1 %
8	Submitted to iGroup Student Paper	1 %
9	<a href="http://www.jkimsu.com">www.jkimsu.com</a> Internet Source	<1 %
10	Jhony Moreira Marcelino, Gustavo Roberto Villas Boas, Mila Cunha, Ramão Deus Júnior et al. " Determination of preclinical safety of oil obtained from Aublet (Malvaceae) seeds: histopathological, biochemical, hematological, and genetic toxicity studies in rats ", Drug and Chemical Toxicology, 2020 Publication	<1 %
11	<a href="http://repository.lppm.unila.ac.id">repository.lppm.unila.ac.id</a> Internet Source	<1 %
12	Sung Phil Kim, Jun Young Yang, Mi Young Kang, Jun Cheol Park, Seok Hyun Nam, Mendel Friedman. "Composition of Liquid Rice Hull Smoke and Anti-Inflammatory Effects in Mice", Journal of Agricultural and Food Chemistry, 2011 Publication	<1 %

---

13

[www.ncbi.nlm.nih.gov](http://www.ncbi.nlm.nih.gov)

Internet Source

&lt;1 %

14

[Repository.Unej.Ac.Id](http://Repository.Unej.Ac.Id)

Internet Source

&lt;1 %

15

Vita Murniati Tarawan, Kemala Isnainiasih Mantilidewi, Ika Miqra Dhini, Putri Teesa Radhiyanti, Endang Sutedja. "Coconut Shell Liquid Smoke Promotes Burn Wound Healing", Journal of Evidence-Based Complementary & Alternative Medicine, 2016

Publication

&lt;1 %

16

[www.tandfonline.com](http://www.tandfonline.com)

Internet Source

&lt;1 %

17

Anwarbaig C. Mirza, Shital S. Panchal. "Safety evaluation of syringic acid: subacute oral toxicity studies in Wistar rats", Heliyon, 2019

Publication

&lt;1 %

18

Elly Munadziroh, Muhammad Genadi Askandar, Anita Yuliati, Meircurius Dwi Condro Surboyo, Wan Himratul Aznita Wan Harun. "The effect of secretory leukocyte protease inhibitor amnion membrane on incisional wound healing", Journal of Oral Biology and Craniofacial Research, 2022

Publication

&lt;1 %

19

[mail.phcogj.com](http://mail.phcogj.com)

Internet Source

&lt;1 %

20	<a href="http://www.frontiersin.org">www.frontiersin.org</a> Internet Source	<1 %
21	Douglas McGregor. " Ethyl -Butyl Ether: A Toxicological Review ", Critical Reviews in Toxicology, 2008 Publication	<1 %
22	<a href="http://ejournal.kemenperin.go.id">ejournal.kemenperin.go.id</a> Internet Source	<1 %
23	<a href="http://garuda.kemdikbud.go.id">garuda.kemdikbud.go.id</a> Internet Source	<1 %
24	<a href="http://herbmedpharmacol.com">herbmedpharmacol.com</a> Internet Source	<1 %
25	<a href="http://mdpi-res.com">mdpi-res.com</a> Internet Source	<1 %
26	<a href="http://www.hindawi.com">www.hindawi.com</a> Internet Source	<1 %
27	<a href="http://bmcpharmacolotoxicol.biomedcentral.com">bmcpharmacolotoxicol.biomedcentral.com</a> Internet Source	<1 %
28	<a href="http://newdrugapprovals.org">newdrugapprovals.org</a> Internet Source	<1 %
29	<a href="http://www.ideals.illinois.edu">www.ideals.illinois.edu</a> Internet Source	<1 %
30	<a href="http://www.researchgate.net">www.researchgate.net</a> Internet Source	<1 %

31

"Evidence Based Validation of Traditional Medicines", Springer Science and Business Media LLC, 2021

Publication

---

<1 %

32

Ira Arundina, Indeswati Diyatri, Tuti Kusumaningsih, Meircurius Dwi Condro Surboyo, Elita Monica, Novitasari Mira Afanda. "The Role of Rice Hull Liquid Smoke in the Traumatic Ulcer Healing", European Journal of Dentistry, 2020

Publication

---

<1 %

33

Rini D. Ridwan, Yuliati Yuliati, Sidarningsih Sidarningsih, Fitri M. Sholihah, Mohammed Aljunaid, Dur M. Lashari. "A study of the mucoadhesive patches loaded with mangosteen peel extract in periodontitis", Journal of Taibah University Medical Sciences, 2021

Publication

---

<1 %

34

Walied Abdo, Mostafa A. Elmadawy, Ehab Yahya Abdelhiee, Mona A. Abdel-Kareem et al. "Protective effect of thymoquinone against lung intoxication induced by malathion inhalation", Scientific Reports, 2021

Publication

---

<1 %

Exclude quotes Off

Exclude matches Off

Exclude bibliography On

# Acute Toxicity Test of Liquid Smoke of Rice Hull (*Oryza sativa*) on Mice (*Mus Musculus*)

---

[GRADEMARK REPORT](#)

---

FINAL GRADE

**/0**

GENERAL COMMENTS

**Instructor**

---

PAGE 1

---

PAGE 2

---

PAGE 3

---

PAGE 4

---

PAGE 5

---

PAGE 6

---