

The effect of calcium hydroxide-propolis on the number of macrophage cells on the Wistar rat dental with pulp performance

by Setyabudi Geonharto

Submission date: 01-Apr-2023 02:56PM (UTC+0800)

Submission ID: 2052756604

File name: admin,_58-61_CDJ_10-2-2020.pdf (617.46K)

Word count: 2948

Character count: 15956

Research Report

The effect of calcium hydroxide-propolis on the number of macrophage cells on the Wistar rat dental with pulp performance

Setyabudi¹, Devi Eka Juniarti¹, Ira Widjiastuti¹, Maughfirah Shintya Fathori²

¹Department of Conservative Dentistry, Faculty of Dental Medicine, Airlangga University, Surabaya - Indonesia

²Undergraduate Student, Faculty of Dental Medicine, Airlangga University, Surabaya - Indonesia

ABSTRACT

Background: Cellular response of dental pulp to existing lesions, caused by infiltration of inflammatory cells that migrate from blood vessels to the site of injury. Macrophages are the cells that most appear when inflammation occurs. Treatment for maintaining pulp tissue vitality is called pulp capping. Calcium hydroxide as a pulp capping material has the ability to trigger the growth of dentin bridges or remineralization, but calcium hydroxide can induce migration and proliferation of inflammatory cells. Currently the field of dentistry is developing propolis as an alternative pulp capping material. That is because propolis has anti-inflammatory properties. **Purpose:** To analyze the effect of the combination of calcium hydroxide-propolis on the number of macrophage cells in the teeth of Wistar rats with pulp perforation. **Methods:** This study used 30 samples of Wistar rats which were prepared until perforation and then divided into 3 groups. The first group continued with filling with cement, the second group continued with application of calcium hydroxide and filled with cement, and the third group continued with the application of combination of calcium hydroxide and propolis and then being filled with cement. Macrophage cell is calculated histopathologically by using compound light microscope on the 3rd day with 400x magnification. **Results:** The Kruskal-Wallis test results showed significant differences in macrophages after the combination of calcium hydroxide and propolis ($p = 0.000$). The combined application of calcium hydroxide and propolis showed higher macrophages than the application of calcium hydroxide and the control group. **Conclusion:** Application of calcium hydroxide - propolis combination was proven increase the number of macrophage cells in Wistar Rats (*Rattus Norvegicus*) with pulp perforation.

Keywords: calcium hydroxide; propolis; macrophage; pulp perforation

Correspondence: Ira Widjiastuti, Department of Conservative Dentistry, Faculty of Dental Medicine, Airlangga University. Jl. Mayjen Prof. Dr. Moestopo 47, Surabaya, 60132 Indonesia. Email: ira-w@fkg.unair.ac.id

INTRODUCTION

Based on Indonesia Health Profile data in 2011 showed that the pulp disease ranked fourth out of the ten most diseases that occur in outpatients in hospitals in Indonesia with the number of visits as many as 209 637 patients. Pulpal inflammation is one of the reasons why pulp treatment needs to be done. Pulpal inflammation is caused due to irritation of the pulp tissue. The lesions that can cause inflammation in the pulp tissue are divided into three namely microbial lesions, mechanical lesions, and chemical lesions¹. The inflammatory phase begins shortly after the injury until 3 days after the wound is characterized by haemostasis and inflammation. In this phase macrophages migrate to the injured area and phagocytose necrotic tissue². During the inflammatory phase, neutrophils activate the healing process by pulling macrophages to the site of injury, which is then activated into the M1 or M2 phenotype. M2 will induce complex immunity, LPS, IL-10, and TGF- β ³.

Growth factors produced by macrophages are important in changing the inflammatory phase into a proliferation phase in wound healing⁴.

Current therapy for maintaining pulp vitality is called pulp capping. In the field of tooth conservation, calcium hydroxide becomes the gold standard pulp capping material⁵. However, calcium hydroxide has the disadvantage of causing inflammation and necrosis of the pulp surface after pulp capping, formation of porous dentin bridges, and low edge density can cause micro-leakage resulting in treatment failure⁵. To increase its effectiveness, calcium hydroxide can be combined with natural ingredients such as propolis which are known to have anti-inflammatory and antimicrobial effects⁶.

Propolis is found to be effective in reducing the entry of neutrophils into the site of inflammation, through the reduction of proinflammatory cytokines and also reducing neutrophil chemotaxis⁷. Propolis has an anti-inflammatory effect by reducing vascular permeability thereby reducing

the process of leucocytosis to the affected area⁸. In the combination of calcium hydroxide-propolis there was no toxic reaction where the study was conducted to test the biocompatibility of the paste combination of calcium hydroxide propolis in rat subcutaneous tissue and the results obtained that the paste of calcium hydroxide propolis combination was able to reduce inflammation significantly and biocompatible with mouse connective tissue. Other studies conducted by Budiarti (2018) found that the effect of administering a combination of calcium hydroxide-propolis as a *direct pulp capping* material on the Wistar rat pulp can molecularly reduce the expression of NFκB which plays a role in the inflammatory process so that pro-inflammatory cytokines will be reduced.

The combination of calcium hydroxide-propolis at a ratio of 1: 1.5 with a concentration of propolis 11.45% is known to have the ability to reduce NFκB, resulting in a decrease in pro-inflammatory cytokines as a cause of inflammatory reaction in the open pulp (Budiarti, 2018). Based on this background, a study is needed to investigate the cellular response of inflammation by observing the number of macrophage cells in *Rattus Norvegicus* pulp tissue after calcium hydroxide-propolis combination. The study was conducted on male Wistar (*Rattus norvegicus*) mice. The purpose of this study is to analysed the combined effect of calcium hydroxide-of propolis on the number of macrophages in the Wistar rat teeth with pulp perforation.

MATERIALS AND METHODS

Ethical eligibility was approved by the Ethics Committee of the Faculty of Dentistry, Airlangga University (Number: 728 / HRECC.FODM / X / 2019). This research was a laboratory study in vivo with post-test only control group using experimental animals 30 Wistar rats (*Rattus norvegicus*) healthy males age 12-16 weeks and weighing 200- 250 grams. The sample was evenly divided into three groups ($n = 10$): the control group (K) whose first molar was prepared and immediately centioned; and two treatment groups, each of which was prepared by its first molar and was given calcium hydroxide and a combination of calcium hydroxide-propolis and then closed with Cention.

Before preparation, mice were anesthetized intramuscularly on the thigh using a 0.2 cc mixture of ketamine (*Ketalar*, Warner Lambert, Ireland) and xylazine base (Rompun, Bayer Health Care AG, Germany) with a ratio of 1: 1. The molar teeth of one mouse were prepared on the occlusal surface using 0.8 mm diameter *round bur* with low speed until it reached the pulp. The depth of preparation is as big as a bur head. The perforation action on the pulp chamber is done using a sonde then checked using *paper points* (Inline®, BM Dentale S.a.s, Torno, Italy) and cleaned with saline.

Propolis extract obtained from mixing beehive of *Apis mellifera* with 96% ethanol in order to obtain a brownish viscous liquid propolis extract with a concentration of

11.45%. The combination of calcium hydroxide propolis is made by mixing calcium hydroxide powder and propolis extract in a ratio of 1:1.5 which is mixing calcium hydroxide powder (*Hydroxido de Calcio P. A*, Brazil) 0.125gr with propolis extract concentration of 11.45% in the amount of 0.1875ml. Furthermore, application was according to the treatment group then cavity closure with Cention (*Cention N*, Ivoclar Viva Dent, Germany) with a powder and liquid ratio of 4.6: 1. Application on the cavity (using a plastic filling instrument), not more than the setting time is 4 minutes.

After 3 x 24 hours, rats were decapitated by first being anesthetized with a 0.2 cc mixture of ketamine and xylazine bases with an intramuscular ratio of 1:1 on the thigh. Then the jaw was taken at the molar teeth which were then fixed with *buffered* formalin 10% and decalcified using 10% EDTA. Furthermore, the specimen is dehydrated by immersing it in a stratified alcohol followed by a purifying agent. Next the specimen was put into *xylol*-paraffin (1:1) and continued with pure paraffin I, pure paraffin II, pure paraffin III each for 60 minutes. Pure paraffin is poured into the box until it is full without air bubbles in the paraffin block, then the specimen is inserted into the paraffin block by using a sharp tweezers. The layout of the tissue is arranged so that when cut, a longitudinal cut is obtained. After the paraffin block hardens, a 4 μm thick paraffin block is cut to be painted with HE staining.

Observation of the number of macrophages was carried out using a light microscope with magnification 400 times then photo preparations were made. Neutrophil cell counts were carried out in the area under the cavity preparation with eight different visual fields, counting manually using photographs with the aid of an *ocular micrometer (graticule)*. The macrophage count results are divided into eight according to the number of visual fields to obtain the average number of neutrophil counts for each sample in each group. The average total sample count for each group is then divided by the number of samples in each group to get the average number of neutrophil counts in each group.

The results of the study were calculated on mean and standard deviations. Data analysis uses the *Shapiro-Wilk Test* to find out whether the data is normally distributed. Then the *Kruskal Wallis* test was followed by a *Post Hoc Test* (Tukey HSD) to determine significant differences between groups.

RESULTS

Table 1 shows the mean and standard deviation of macrophages in the control and treatment groups. From the calculations it was found that the average macrophage cells in the control group was 5. The average macrophage cells in treatment group 1, namely the group given calcium hydroxide, were 7.6. The average macrophage cells in treatment group 2, namely the group given a combination of calcium hydroxide-propolis, amounted to 9.7. This shows that the average number of macrophage cells in the group

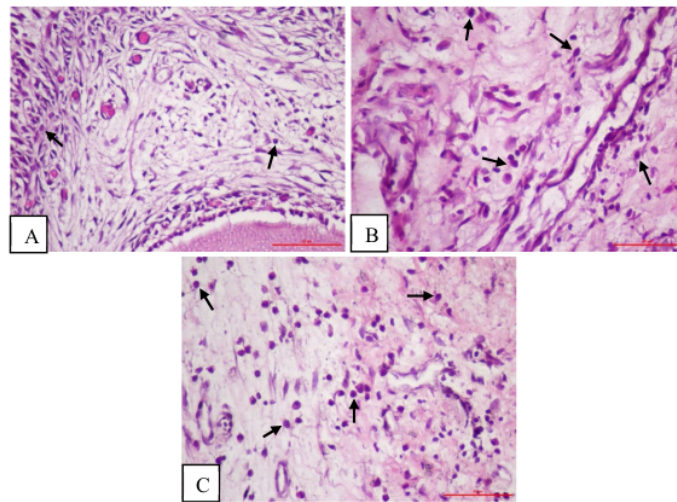


Figure 1. Overview of HPA macrophage cells on day 3 observed in pulp tissue after Centon (control) (A) administration, administration of calcium hydroxide (B), and administration of calcium hydroxide-propolis combination. Arrow pointing to macrophage with HE painting, 400x magnification.

Table 1. Average number of macrophage cells in each control group, calcium hydroxide treatment group, calcium hydroxide propolis treatment group and treatment group

Group Treatment	N	Average	Elementary school
Control	10	5.0	0.81650
Ca (OH) ₂	10	7.6	1.142984
Ca (OH) ₂ + Propolis	10	9.7	1.41814

Note: N: Number of samples; SD: Standard deviation

Table 2. Results Tukey HSD test on data number of cells macrophages inter-group

Group Treatment	Control	Calcium Hydroxide	Calcium hydroxide-propolis
Control		0.000 *	0.000 *
Ca (OH) ₂	0.000 *		0.002 *
Ca (OH) ₂ + Propolis	0.000 *	0.002 *	

given calcium hydroxide was higher than the control group. Meanwhile, the average number of macrophage cells in the group given the combination of calcium hydroxide-propolis was higher than the group given calcium hydroxide and the control group. The distribution of macrophage cells can be seen in Figure 1.

The results of the normality test showed that there was one group of data that was not normally distributed so that the non-parametric test was performed using the *Kruskal-Wallis* test. The *Kruskal-Wallis* test results showed that there were significant differences in the number of macrophages between groups ($p < 0.05$).

Post Hoc Test using Tukey HSD performed to determine significant differences between groups. Tukey HSD test results (Table 2) showed that there were significant differences ($p > 0.05$) between each group of control, a group of calcium hydroxide, and a group giving a combination of calcium hydroxide-propolis.

DISCUSSION

The inflammatory phase is characterized by the appearance of macrophages in the affected area in response to

inflammation. Monocytes will come out of blood vessels and become macrophages when they reach the site of injury. Macrophage cells are the main leukocyte cells for the body's first defence. Monocytes will develop into macrophages when they are in the tissues. When inflammation occurs, macrophage infiltration will increase especially on the 3rd day⁹. During the acute phase of inflammation, macrophages induce an inflammatory response and release proinflammatory mediators that contribute to the killing of pathogens and inflammation resolution. However, the response must be controlled to prevent tissue damage through production by the anti-inflammatory cytokine macrophages, cytokines, which will promote and accelerate the process of wound healing and tissue repair¹⁰. Based on its function, macrophages are divided into two types namely M1 which functions as pro-inflammatory and M2 which functions as anti-inflammatory. In the early inflammatory phase, macrophages play a role in phagocytosis and kill bacteria, eliminate debris and release various pro-inflammatory cytokines. At the end of the inflammatory phase, macrophages stimulate fibroblasts, endothelial cells, and keratinocytes which function to influence the accumulation of collagen, angiogenesis, and epithelialization³.

The main ingredients in propolis namely CAPE and flavonoids can inhibit the kappa B nuclear factor pathway (NFκB) which plays a role in inflammatory reactions and the release of proinflammatory cytokines (IL-1, IL-6, IL-8 and TNF-α) thus affecting the activity of inflammatory cells by inhibiting neutrophil cell chemotaxis and vascular permeability¹¹. Reduction of proinflammatory cytokines and reduction of neutrophil chemotaxis causes an increase in the number of macrophages, thus accelerating the inflammatory phase. The decreasing increase in the number of neutrophils indicates that the inflammatory phase is complete by shortening the duration of acute inflammation and stimulating macrophage activity as a second-line defence by increasing the number of macrophages to continue the phagocytic process carried out by neutrophils, so that the increase in polarized macrophages becomes macrophages with higher anti-inflammatory activity. In the administration of a combination of calcium hydroxide-propolis, in addition to the content of flavonoids and CAPE which works as an anti-inflammatory. Alkaline calcium hydroxide and propolis which are acidic will bind physically, namely hydrogen and Van Der Waals bonds so that these bonds have a neutral pH of 7.

Based on the research that has been done, the results show that application of calcium hydroxide-propolis combination can increase the number of macrophage cells in the dental pulp of Wistar rats that have pulp perforation. P Increased macrophages was significantly contained in the group given calcium hydroxide and the group given the combination calcium hydroxide-propolis compared with the control group. The increasing number of macrophages and the acceleration of macrophage infiltration, indicate the occurrence of a faster inflammatory process that affects wound healing⁴. In the treatment group with calcium hydroxide, the number of macrophage cells was lower than in the treatment group with calcium hydroxide-propolis combination. When calcium hydroxide comes into contact with perforated pulp, calcium hydroxide releases Ca²⁺ and OH⁻ ions, causing high pH levels and necrotic layers to form in the contact area. This can result in an acute inflammatory response in the pulp tissue¹².

This study proves that the administration of a combination of calcium hydroxide-propolis to the dental pulp of perforated Wistar rats can cause an increase in the number of macrophage cells on the third day after administration of mechanical trauma.

CONCLUSION

Calcium hydroxide - propolis has an effect on increasing the number of macrophage cells in the teeth of Wistar rats with pulp perforation.

REFERENCES

1. Park SH, Ye L, Love RM, Farges JC, Yumoto H. Inflammation of the Dental Pulp. *Inflamm Mediators*. 2015; 2015: 2-4.
2. Oka T, Ohta K, Kanazawa T, Nakamura KI. Interaction between macrophages and fibroblasts during wound healing of burn injuries in rats. *Kurume Med J*. 2015; 62 (3-4): 59-66.
3. Park M, Hong J. Roles of NF-κB in Cancer and Inflammatory Diseases and Their Therapeutic Approaches. *Cells*. 2016; 5 (2): 15.
4. Koh TJ, DiPietro LA. Inflammation and wound healing: the role of the macrophage. *Expert Rev Mol Med*. 2011; 13 (July 2011).
5. Brizuela C, Ormeño A, Cabrera C, Cabezas R, Silva CI, Ramírez V, et al. Direct Pulp Capping with Calcium Hydroxide, Mineral Trioxide Aggregate, and Biodentine in Permanent Young Teeth with Caries: A Randomized Clinical Trial. *J Endod*. 2017; 43 (11): 1776-80.
6. Abubakar MB, Abdullah WZ, Sulaiman SA, Ang BS. Polyphenols as key players for the antileukaemic effects of propolis. *Evidence-based Complement Altern Med*. 2014; 2014.
7. Bueno-Silva B, Franchin M, Alves C de F, Denny C, Colón DF, Cunha TM, et al. Main pathways of action of Brazilian red propolis on the modulation of neutrophils migration in the inflammatory process. *Phytomedicine*. 2016; 23 (13): 1583-90.
8. Rajoo M. The Role of Propolis in Inflammation and Orofacial Pain: A Review. *Annu Res Rev Biol*. 2014; 4 (4): 651-64.
9. Prame Kumar K, Nicholls AJ, Wong CHY. Partners in crime: neutrophils and monocytes / macrophages in inflammation and disease. *Cell Tissue Res*. 2018; 371 (3): 551-65.
10. Atri C, Guerfali FZ, Laouini D. Role of human macrophage polarization in inflammation during infectious diseases. *Int J Mol Sci*. 2018; 19 (6).
11. Freires IA, De Alencar SM, Rosalen PL. A pharmacological perspective on the use of Brazilian Red Propolis and its isolated compounds against human diseases. *Eur J Med Chem [Internet]*. 2016; 110: 267-79.
12. Baranwal R, Singh B, Dubey A, Avinash A. Review of Calcium Hydroxide Articles in Dentistry. *Chettinad Heal City Med J*. 2016; 5 (January): 30-3.

The effect of calcium hydroxide-propolis on the number of macrophage cells on the Wistar rat dental with pulp performance

ORIGINALITY REPORT

14%

SIMILARITY INDEX

13%

INTERNET SOURCES

4%

PUBLICATIONS

1%

STUDENT PAPERS

PRIMARY SOURCES

1	www.ncbi.nlm.nih.gov Internet Source	5%
2	jurnal.unimus.ac.id Internet Source	1%
3	www.researchgate.net Internet Source	1%
4	repository.unair.ac.id Internet Source	1%
5	Kusmiati, N A Setiabudhi, N W S Agustini. " Effect Of Lutein from INK On The Activities And Phagocytic Capacity On Peritoneal Macrophage Cells Of Mice Infected With ", IOP Conference Series: Earth and Environmental Science, 2020 Publication	1%
6	Submitted to Universitas Airlangga Student Paper	1%

7	Internet Source	1 %
8	www.karger.com Internet Source	1 %
9	academic.oup.com Internet Source	1 %
10	www.vma.mod.gov.rs Internet Source	1 %
11	ijest.org Internet Source	<1 %
12	www.frontiersin.org Internet Source	<1 %
13	Tansza Setiana Putri, Sunarso, Koichiro Hayashi, Kanji Tsuru, Kunio Ishikawa. "Feasibility study on surface morphology regulation of β -tricalcium phosphate bone graft for enhancing cellular response", Ceramics International, 2022 Publication	<1 %
14	www.alliedacademies.org Internet Source	<1 %
15	Claudia Brizuela, Andrea Ormeño, Carolina Cabrera, Roxana Cabezas, Carolina Inostroza Silva, Valeria Ramírez, Montse Mercade. "Direct Pulp Capping with Calcium Hydroxide, Mineral Trioxide Aggregate, and Biodentine	<1 %

inPermanent Young Teeth with Caries:
ARandomized Clinical Trial", Journal of
Endodontics, 2017

Publication

16

www.scielo.br

Internet Source

<1 %

Exclude quotes Off

Exclude matches < 10 words

Exclude bibliography On

The effect of calcium hydroxide-propolis on the number of macrophage cells on the Wistar rat dental with pulp performance

GRADEMARK REPORT

FINAL GRADE

/0

GENERAL COMMENTS

Instructor

PAGE 1

PAGE 2

PAGE 3

PAGE 4
