

Pulp tissue regeneration in the treatment of immature premolars accompanied by infection: A case report

by Setyabudi Geonharto

Submission date: 03-Apr-2023 10:53AM (UTC+0800)

Submission ID: 2054091643

File name: 95-99_CDJ_12-2-2022.pdf (693.42K)

Word count: 2567

Character count: 14024

Case Report

Pulp tissue regeneration in the treatment of immature premolars accompanied by infection: A case report

Anastasia Gabriella Djuanda¹, Eska Dianti¹, Radixtio Auzan Fepiosandi¹, Daniyal Lazuardi Ramadhan¹, Dian Agustin Wahjuningrum², Setyabudi Goenhar²

¹Resident of Conservative Dentistry, Faculty of Dental Medicine, Universitas Airlangga, Surabaya, Indonesia

²Conservative Dentistry Department, Faculty of Dental Medicine, Universitas Airlangga, Surabaya, Indonesia

ABSTRACT

Background: Young permanent teeth are one of the challenges in performing endodontic treatment. Revascularization is a good yet simple treatment option for pulp tissue regeneration to stimulate periapical lesion healing, continue root growth and restore pulp tissue function. **Purpose:** This case report describes management of pulp tissue regeneration in teeth with infection. **Case:** Female, 16 years old, came complaining of pain in the left lower back tooth accompanied by recurrent swelling. Radiograph showed an open apex with apical lesion on tooth 35. The diagnosis was pulpal necrosis accompanied by a chronic apical abscess. **Case management:** The treatment plan was revascularization and direct composite restoration. After accessing the cavity, the teeth were prepared, irrigated, and medicated with TAP, which was repeated for 2 visits. On the next visit, after the root canal was cleaned, over instrumentation was performed for bleeding and Collaplug was placed over the blood clot, covered with MTA, and composite resin for coronal sealing. Follow up was carried out for up to 9 months and was asymptomatic. Radiographs show healing of the lesion accompanied by closure of the root canal. **Conclusion:** Regenerative endodontics has been shown the successful in stimulating root canal closure to treat immature teeth.

Keywords: Regenerative endodontics; apexification; pulpal necrosis; mineral-trioxide-aggregate

Correspondence: Setyabudi Goenhar², Conservative Dentistry Department, Faculty of Dental Medicine, Universitas Airlangga, Jl. Mayjen Prof. Dr. Moestopo 47 Surabaya 60132, Surabaya, Indonesia, Email: setyabudi@fkg.unair.ac.id

INTRODUCTION

Pulpal tissue plays a very important role in tooth development because of its ability to become progenitor/stem cells (DPSCs) which have the ability to proliferate and differentiate into dentine-secreting-odontoblasts. When a tooth is traumatized and a bacterial infection (caries) can cause inflammation, and if it is not treated, pulpal necrosis and apical periodontitis can occur¹. One of the most serious problems in the event of pulpal death is when it occurs in young permanent teeth with roots that have not been covered. The occurrence of pulpal necrosis in young permanent teeth is a quite formidable challenge because the tooth structure is still thin and the roots are short, thereby increasing risk of fracture². When treating immature teeth with pulp necrosis, the main goals of treatment are to prevent and stimulate healing of apical periodontitis, stimulate root growth, and restore pulp tissue functionally, both from an immunological and sensory perspective³.

Several published cases with exposed roots indicate REP is a good treatment option that can stimulate growth and increase in root thickness and length. This procedure requires good infection control, suitable matrix for tissue

growth, and adequate coronal seal⁴⁻⁶. Good infection control can be done in various ways, such as using CaOH or Triple Antibiotic Paste (TAP)⁷.

MTA material is a type of cement with good sealing ability and good biocompatibility, and has the ability to stimulate the production of hard tissues such as dentin and cementum. This material is widely used as apexification material and sealing areas that experience perforations or boundaries between periodontal tissues. However, several studies demonstrated the ability of MTA in pulpal revascularization treatment and as sealing of pulpal sections⁸⁻⁹. In this case, we tried to treat exposed roots with revascularization measures to stimulate apical closure and used MTA as coronal sealing above. blood clot as a growth factor.

CASE

A 16-year-old woman came to the Department of Dental Conservation at RSKGM-P Airlangga University complaining of pain in her left lower back tooth and recurring swelling of the surrounding gums. She had

previously received medicine from the dentist to relieve her pain and the medicine had run out, the swelling had decreased but the patient still feels uncomfortable when used for eating. Previously there was a filling and it had been removed by the previous dentist and given a temporary filling. There was no history of trauma due to impact or biting on hard objects. There was no history of systemic abnormalities.

On clinical examination, tooth 35 was seen with temporary fillings and a sinus tract in the buccal part of the surrounding gingiva. There was no response to vitality checks. Percussion examination and bite test showed no pain response. On radiographic examination, an open apex tip was found with periapical lesions on tooth 35 (Figure 1). The diagnosis taken was pulpal necrosis accompanied by a chronic apical abscess. The treatment plan was REP with revascularization technique and composite final filling.

CASE MANAGEMENT

At the first visit, after isolation, cavity access was carried out using a round bur and 1 orifice was obtained. Then, channel negotiation and temporary length measurements are carried out using Kfile #25. The root canals were then irrigated using 1.5% NaOCl and saline and then dried using sterile paper points. Intra-canal medication using TAP then the cavity was closed using a temporary filling (Figure 2). At the next visit, the temporary filling was opened and irrigation and re-sterilization were carried out. adrenaline then the temporary filling is opened. The TAP was rinsed and the root canal was irrigated using 17% EDTA and saline. Over-instrumentation was performed using a Kfile #15 with a length of 1 mm above the working length. After the root canal was filled with blood and waiting for a blood clot to form, a resorbable matrix (Collaplug) was placed over

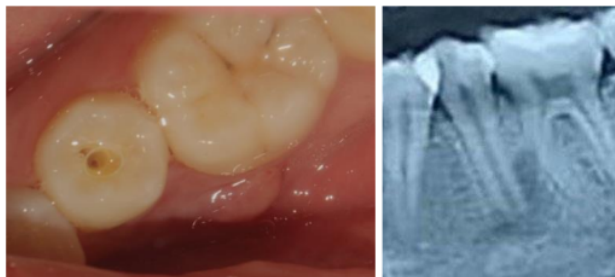


Figure 1. A. Clinical examination found a sinus tract in the buccal part between teeth 35 and 36. B. Radiograph showed an open apex of tooth 35 accompanied by a radiolucent appearance in the apical area extending to the mesial root of tooth 36.

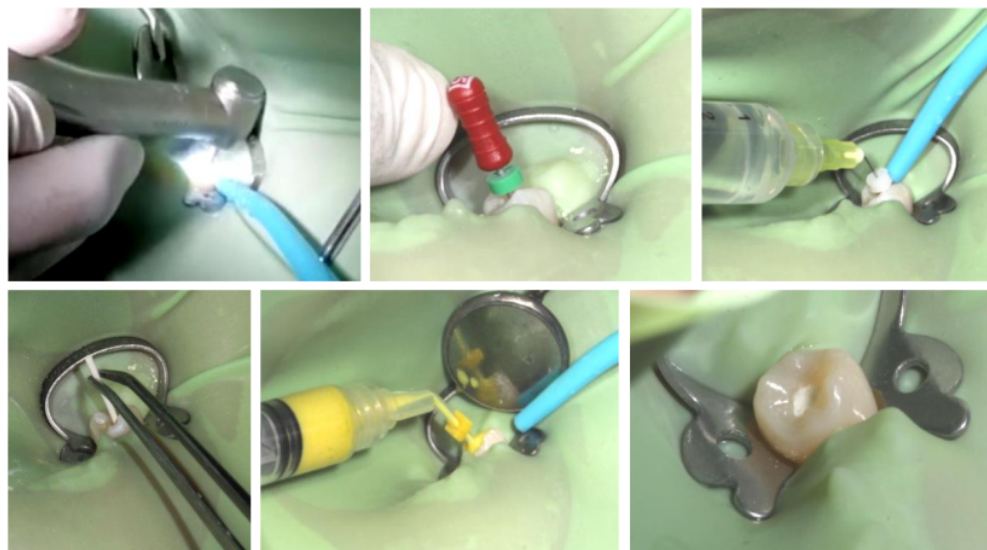


Figure 2. At the first visit. A. Access cavity at tooth 35. B. Working length measurement with Kfile #25. C. Irrigation of the root canal with 1.5% NaOCl and saline. D. The root canal is dried with sterile paper points. E. Intra-canal medication with TAP is inserted with a syringe. F. Post temporary fillings.

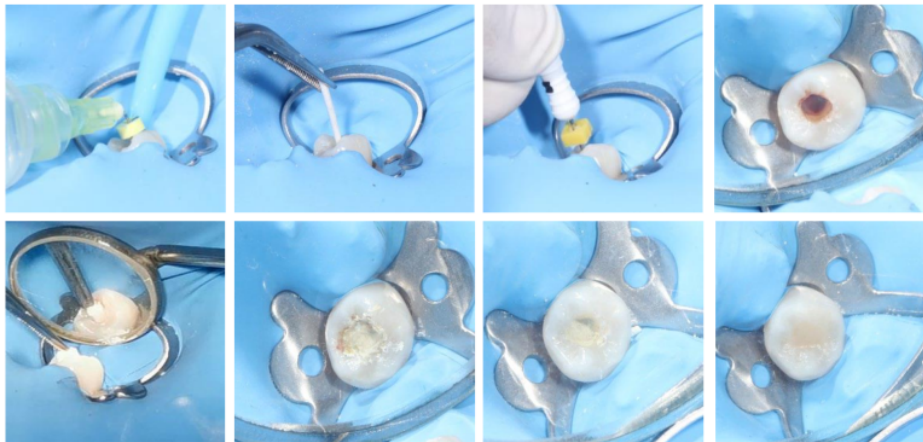


Figure 3. Visit 3. A. The temporary filling is opened, followed by root canal irrigation using EDTA to remove TAP and stimulate stem cell formation. B. Dry the root canal with a sterile paper point. C. Overinstrumentation was performed with Kfile #15 1 mm beyond the working length to induce bleeding. D. Wait for 15 minutes for a blood clot to form. E. Application of Collaplug over blood clot. F. 3 mm thick MTA application over Collaplug. G. Self-etch bonding application. H. Coronal section closed with composite resin restoration.

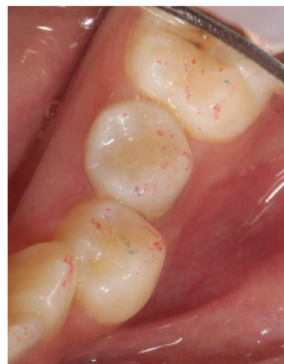

Figure 4. Final restoration after checking occlusion, finishing, and polishing of the composite.

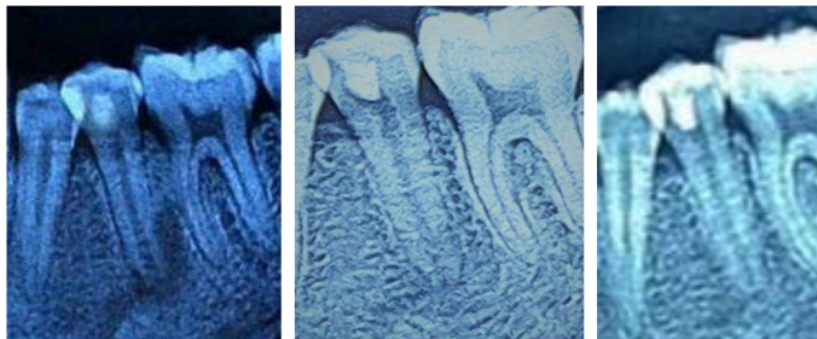


Figure 5. A. Follow up after 20 days, the patient is asymptomatic and still looks radiolucent apical. B. Follow up after 5 months, it appears that the lesion has disappeared and there has been an increase in dentin thickness C. Follow up after 9 months showed apical closure of the apical premolars and there were no symptoms in the patient.

the blood clot, then coated with MTA, and closed using composite resin as a coronal seal (Figure 3). The occlusion was examined and finishing and polishing was carried out (Figure 4). Follow up was carried out on the 20th day, 5th month and 9th month after the filling. The patient was asymptomatic. Radiographic examination showed healing of the lesion with additional thickness and root coverage after 5 months (Figure 5).

DISCUSSION

The main goals of endodontic treatment of infected teeth are (1) to disinfect the root canal system and (2) to prevent re-infection. Both of these goals will lead to good bone tissue healing and periradicular tissue regeneration. Filling the root canal with biological tissue can avoid the various disadvantages of using synthetic materials, such as the possibility of loss of seal and toxicity to the surrounding tissue. In addition, treatment using biological materials has the advantage of preserving the body's defense response against subsequent reinfection¹¹.

There are a variety of stem cells in the apical papilla where these cells have sufficient circulation to prevent cell death when pulpal necrosis occurs. Therefore, the act of creating bleeding in the periapical tissue is useful to allow stem cell influx to enter and accumulate in the disinfected root canal. These autogenous cells, along with blood clots, can facilitate the formation of pulp regeneration so that it is expected to continue the process of root tissue maturation¹². Root maturation can occur through 4 possibilities. First, stem cells of the apical papilla (SCAP) will migrate into the root canal space, differentiate into mesenchymal cells, proliferate, and differentiate into similar cells that can form dentine and cementum, covering the apical end. Second, Hertwig epithelial root sheath (HERS) that survives the inflammatory reaction can be stimulated to continue root formation¹³. Third, multipotent dental pulp stem cells present in the dentin wall, can differentiate into odontoblasts and form tertiary dentin. Fourth, stem cells originating from the periodontal ligament will proliferate and grow towards the apical end and enter the root canal¹⁴. It was found by Komada et al., that the periodontal ligament and vascular endothelial cells can grow into the root canal through the apex, displacing the blood clot, and participates in the formation of cementum-like tissue accompanied by the process of angiogenesis during the healing process¹⁵.

A mild concentration of 1.5% sodium hypochlorite (20 ml/drill for 5 minutes) is recommended followed by irrigation with saline and EDTA (20ml/channel for 5 minutes) using an irrigation needle less than 1 mm from the apical tip to reduce the risk of stem cytotoxicity. cells at the apical end. The high concentration of NaOCl will reduce the number of SCAP. The use of 17% EDTA can increase the survival of SCAP¹⁵. According to Galler (2015), EDTA can demineralize dentin which will expose the dentine matrix which will release growth factor¹⁷. Irrigation

using Chlorhexidine is not recommended because of its cytotoxicity to stem cells¹⁸.

Triple Antibiotic Paste (TAP) is recommended by AAE at a concentration of 1-5 mg/ml to keep stem cells alive. TAP contains Metronidazole, Ciprofloxacin, and Minocycline in a ratio of 1:1:1¹⁷. Collaplug is used as a matrix to hold MTA in position so that it does not fall into the root canal¹⁹. MTA was chosen because of its biocompatible effect, good sealing ability, and has conductive and inductive capabilities to stimulate dentinogenesis²⁰.

Trevino et al.¹⁸ described 5 types of tooth response to treatment with REPs. (1) Increase the thickness of the root canal wall and continue the maturation of the root canal. (2) There is no continuation of root formation with a blunt but closed apex. (3) Continued root formation with the apical foramen remaining open. (4) Calcification in the root canal. (5) A hard tissue barrier forms in the canal between the MTA and the apex¹⁴. In this case, it appeared that the regeneration procedure was successful due to continued root formation with apical closure without any symptoms¹⁵.

In conclusion, revascularization is a fairly good and promising way to continue the process of regeneration of the hard tissue in the root canal wall to reduce fracture or loss of teeth. Proper and correct disinfection can keep existing stem cells alive, and a good coronal seal is the key to the success of endodontic regenerative therapy.

REFERENCES

1. Bottino MC, Munchow EA. Current and Future Views on Biomaterial Use in Regenerative Endodontics. In: Duncan HF, Cooper PR. Clinical Approaches in Endodontic Regeneration: Current And Emerging Therapeutic Perspective. Switzerland: Springer 2019: 77
2. Andreasen JO, Borum MK, Jacobsen HL, Andreasen FM. Replantation of 400 avulsed permanent incisors. 1. Diagnosis of healing complications. Endodontics & dental traumatology. 1995; 11:51-58.
3. Kenneth MH, Anibal D, and Fabricio BT, Treatment Options: Biological Basis of Regenerative Endodontic Procedures. J Endod. 2013 March ; 39(3 Suppl): S30-S43.
4. Kenneth MH and Law A. Regenerative endodontics in Pathways of the Pulp, K. Hargreaves and S. Cohen, Eds. Canada: Elsevier 2011: 602-619
5. G. T. Huang. Apexification: the beginning of its end. International Endodontic Journal. 2009 vol. 42 no. 10 : 855-866.
6. F. Banchs and M. Trope. Revascularization of immature permanent teeth with apical periodontitis: new treatment protocol? Journal of Endodontics 2004 vol. 30 no. 4 pp. 196-200
7. American Association of Endodontics. American Association of Endodontics Clinical Considerations for a Regenerative Procedure," Accessed August 2022. <https://www.aae.org/specialty/clinical-resources/regenerative-endodontics>
8. R. K. Subay, B. Ilhan, and H. Ulukapi. Mineral trioxide aggregate as a pulpotomy agent in immature teeth: long-term case report. European Journal of Dentistry 2013 vol. 7: 133-138, 2013.

9. Lindeboom JAH, Frenken JWFH, Kroon FHM, et al. A Comparative Prospective Randomized Clinical Study Of MTA And IRM As Root-End Filling Materials In Single-Rooted Teeth In Endodontic Surgery. *Oral Surgery, Oral Medicine, Oral Pathology, Oral Radiology, and Endodontics* 2005 vol. 100 no. 4: 495–500, 2005.
10. Katsura S, Yuko F, Yasuhiro S, et al. Pulp Revascularization in Immature Permanent Tooth with Apical Periodontitis Using Mineral Trioxide Aggregate. *Case Reports in Medicine* 2014
11. Simon, S. Current Clinical Practice and Future Translation in Regenerative Endodontics. In: Duncan HF, Cooper PR. *Clinical Approaches in Endodontic Regeneration: Current And Emerging Therapeutic Perspective*. Switzerland: Springer 2019: 188-189
12. Iglesias-Linares A, Yáñez-Vico RM, Sánchez-Borrego E, et al. Stem Cells In Current Paediatric Dentistry Practice. *Archives of Oral Biology* 2013 vol. 58 no. 3: 227–238
13. Annie Zhujiang, DMD, and Sahng G. Kim, DDS, MS. Regenerative Endodontic Treatment of an Immature Necrotic Molar with Arrested Root Development by Using Recombinant Human Platelet-derived Growth Factor: A Case Report. *Journal Of Endodontic* 2016 volume 42, issue 1, p72-75
14. Gopikrishna, Grossman's Endodontic Practice. 14th edition. New Delhi: Wolters Kluwer 2021
15. Komada T, Mitomo K, Ikarashi T, et al. Periodontal Ligament Cells Are Involved in The Formation of Intracanal Cementum-Like Tissue After Regenerative Endodontic Procedures: A Mouse in situ Model. *Frontiers in Dental Medicine* 2022, 3:864406
16. Martin DE, Almeida JD, Henry MA, et al. Concentration-Dependent Effect Of Sodium Hypochlorite On Stem Cells Of Apical Papilla Survival And Differentiation. *J Endod.* 2014;40(1):51–5.
17. 17. Galler KM, Buchalla W, Hiller KD. Influence Of Root Canal Disinfectants On Growth Factor Release From Dentin. *J Endod.* 2015;41(3):363–8
18. Trevino EG, Patwardhan AN, Henry MA. Effect Of Irrigants On The Survival Of Human Stem Cells Of The Apical Papilla In A Platelet-Rich Plasma Scaffold In Human Root Tips. *J Endod.* 2011;37(8):1109–15
19. Justin R, Patil PN, Sarda AS. Review on regenerative endodontics: Past concepts, current protocols and future strategies. *IP Indian Journal of Conservative and Endodontics* 2021;6(4):205–211
20. Kenneth MH, Berman LH. *Cohen's Pathways of The Pulp*. 11th ed. Canada: Elsevier 2016

Pulp tissue regeneration in the treatment of immature premolars accompanied by infection: A case report

ORIGINALITY REPORT

19%

SIMILARITY INDEX

11%

INTERNET SOURCES

18%

PUBLICATIONS

0%

STUDENT PAPERS

PRIMARY SOURCES

1	www.hindawi.com Internet Source	4%
2	"Clinical Approaches in Endodontic Regeneration", Springer Science and Business Media LLC, 2019 Publication	2%
3	Annie Zhujiang, Sahng G. Kim. "Regenerative Endodontic Treatment of an Immature Necrotic Molar with Arrested Root Development by Using Recombinant Human Platelet-derived Growth Factor: A Case Report", Journal of Endodontics, 2016 Publication	2%
4	www.frontiersin.org Internet Source	2%
5	journal.perbanas.ac.id Internet Source	1%
6	Pranjali Naresh Patil, M Robert Justin, Aditi Subhashchandra Sarada, Lalit Dattu Darade et	1%

al. "Review on regenerative endodontics: Past concepts, current protocols and future strategies", IP Indian Journal of Conservative and Endodontics, 2021

Publication

7 Prem Lata, Ajay Chhabra, Varun Jindal, Arun Thakur. "In-Vivo Clinical Evaluation of Regenerative Endodontics in Immature Necrotic Permanent Teeth With Open Apex", Dental Journal of Advance Studies, 2018

Publication

8 Rena Setiana Primawati. "APPLICATION OF CPP-ACP REMINERALIZATION MATERIALS (TOOTH MOUSSE) ON SALIVA PH IN STUDENT", The Incisor (Indonesian Journal of Care's in Oral Health), 2022

Publication

9 Rarasmaya Indraswari, Takio Kurita, Agus Zainal Arifin, Nanik Suciati, Eha Renwi Astuti. "Multi-projection deep learning network for segmentation of 3D medical images", Pattern Recognition Letters, 2019

Publication

10 www.researchgate.net

Internet Source

11 Chueh, L.H.. "Immature Teeth With Periradicular Periodontitis or Abscess

Undergoing Apexogenesis: A Paradigm Shift",
Journal of Endodontics, 200612

Publication

12

Qian Du, Shasha Yuan, Shuangyuan Zhao, Di Fu, Yifei Chen, Yuan Zhou, Yangpei Cao, Yuan Gao, Xin Xu, Xuedong Zhou, Jinzhi He. "Coexistence of and increases biofilm virulence and periapical lesions in rats ", Biofouling, 2021

Publication

1 %

13

Diogenes, Anibal, Michael A. Henry, Fabricio B. Teixeira, and Kenneth M. Hargreaves. "An update on clinical regenerative endodontics : An update on clinical regenerative endodontics", Endodontic Topics, 2013.

Publication

1 %

Exclude quotes Off

Exclude matches < 10 words

Exclude bibliography On

Pulp tissue regeneration in the treatment of immature premolars accompanied by infection: A case report

GRADEMARK REPORT

FINAL GRADE

/0

GENERAL COMMENTS

Instructor

PAGE 1

PAGE 2

PAGE 3

PAGE 4

PAGE 5
