

Complex aesthetic treatment of patients with multiple caries

by Tamara Yuanita

Submission date: 05-Apr-2023 02:17PM (UTC+0800)

Submission ID: 2056387180

File name: complex_aesthehic_vol.12_no_1_38-44.pdf (677.56K)

Word count: 4665

Character count: 24919

Case Report

Complex aesthetic treatment of patients with multiple caries

Devi Eka Juniarti¹, Tamara Yuanita¹, Nirawati Pribadi¹, Tarsardo Marbun², Nadien Sekar Pramesti²

¹Department of Conservative Dentistry, Faculty of Dental Medicine, Universitas Airlangga, Surabaya, Indonesia

²Undergraduate Student, Faculty of Dental Medicine, Universitas Airlangga, Surabaya, Indonesia

ABSTRACT

Background: The need for dental esthetics is very important in recent years. Fulfilling aesthetic demands with both non-invasive and minimally invasive techniques can maintain tissue continuity. A 38 year old female patient came to the clinic with an esthetic complaint of maxillary anterior teeth. The following case report describes a step by step complex aesthetic treatment of a patient with multiple caries. Appealing aesthetic results will restore the patient's smile through restorative treatment in dentistry. **Purpose:** The purpose of this case report is to explain the management of complex aesthetic treatment of patients with multiple caries. **Case:** A 38-year-old female patient complained her upper front teeth is turning black. The patient complained that her teeth had hurt ± 3 months ago and sometimes felt sore. The patient wants her teeth to be treated because she feels less confident when she smiles and wants to fix these teeth. The history of treatment on the tooth in question have had root canal treatment and been filled since 8 years ago. The tooth has had braces (orthodontic) treatment and was removed ± 7 years ago. The patient stated that she had no systemic health disorder. **Case management:** The treatment of this complex case were done using root canal treatment, endodontic retreatment, direct and indirect veneer, dowel, and crown. **Conclusion:** complex aesthetic treatment of patients with multiple were done aiming for good aesthetic result

Keywords: complex aesthetic; multiple caries; endo restoration

Correspondence: Devi Eka Juniarti, Department of Conservative Dentistry, Faculty of Dental Medicine, Universitas Airlangga. Jl. Mayjend. Prof. Dr. Moestopo no. 47, Surabaya 60132, Indonesia. E-mail: devi-e-j@fkg.unair.ac.id

INTRODUCTION

The aesthetic needs in dentistry have received greater attention recently, as a result, patient demands have also increased in relation to the quality of restorations provided by dentists, especially when anterior teeth are involved.¹ This indicates that public awareness of the importance of dental care is increasing, especially anterior teeth that can support their physical appearance.² The aesthetic demands in the field of restorative dentistry are followed by the development of materials and restorative techniques. Nowadays dentistry is looking for "invisible restorations", which mimic the natural anatomy and color of teeth with minimal damage to tooth tissue. The combination of materials with biocompatible properties, enhanced restorative techniques, and principles of maintaining the structure of the remaining tooth tissue will support the achievement of a healthy, functional and aesthetic smile.¹

The most common dental disease that people suffer from is caries which can progress to pulp disease and lead to periapical disease. Dental caries is a disease that attacks the hard tissues of the teeth, namely the enamel, dentine and cementum in the form of decay on the surface of the teeth caused by the gradual dissolving of the mineral surface and continues to progress to the inside of the tooth. This process

occurs due to the activity of microorganisms that ferment carbohydrates. The process of caries is characterized by demineralization of hard tooth tissue and destruction of organic matter, this condition allows further bacterial invasion to the inside of the tooth, namely the dentin layer and reaching the pulp.⁴

Pulpal and periapical diseases can be treated with curative treatment, that is endodontic treatment. The goal of endodontic treatment is to remove the bacteria that exist in the root canal and create an unfavorable environment to support microorganisms to multiply. Common pulp diseases in the community are pulpitis and pulp necrosis. Reversible pulpitis is mild to moderate inflammation of the pulp caused by noxious stimuli.³ However, if the cause of inflammation is removed, the pulp will return to normal. Factors that lead to reversible pulpitis are cervical erosion, mild stimuli such as incipient caries, occlusal attrition, errors in operative procedures, deep curettage of the periodontium, and enamel fractures that expose the dentinal tubules.⁵ Meanwhile, pulp necrosis is a condition where the pulp is non vital, the blood vessels are no longer vital, and the pulp nerve is no longer functioning. If the pulp is completely necrotic, the tooth is asymptomatic until symptoms develop as a result of the progression of the disease process into the periradicular tissues.⁶

Most pulp necrosis occurs due to complications of acute and chronic pulpitis that is not treated properly and adequately.⁵ Pulp and periodontal disease are indicated for endodontic treatment, namely root canal treatment (RCT). RCT is one of the treatments for pulp disease by taking vital or necrotic pulp from the root canal and replacing it with a filling material.³

The space between the teeth is called the diastema. According to Keen, a diastema is defined as the presence of a space more than 0.5 mm between the proximal surfaces of adjacent teeth. The presence of a diastema during primary and mixed dentition is natural; this space is usually replaced by lateral eruptions and canines. However, in some cases, the diastema does not close spontaneously, and this can cause aesthetic, psychological, and functional disturbances. Usually the diastema creates an unpleasant appearance in the patient and, depending on the width of the diastema, it affects speech, especially the pronunciation of the 'S' sound.⁷

The main goal in treating pulpal disease and central diastema is to restore the patient's beautiful smile aesthetically. Aesthetic restoration has always played an important role for the patient's emotional and psychological well-being. A beautiful smile shows joy, enthusiasm and charisma among people.⁸ Various ways can be done to restore the central diastema of anterior teeth such as direct and indirect composite, and veneers. In modern dentistry, the esthetic anterior composite resin restoration is very important, the common treatment option for these patients is direct composite resin restoration due to its conservative, predictable, repairable and inexpensive nature.

The aim of this case report is to report the treatment of a 38-year-old female patient with complex aesthetic problems in anterior teeth with multiple caries with restorative treatment in dentistry.

CASE

A 38-year-old female patient complained her upper front teeth is turning black. The patient complained that her teeth

Table 1. Salivary test results in patients

Hydration	25 sec	•
Viscosity	Watery	•
pH	7.2	•
Quantity	5 ml/ 5 minutes	•
Buffer Capacity	10	•

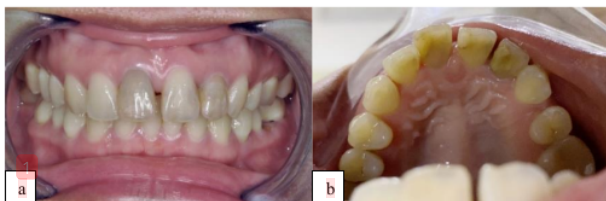


Figure 1. a) Labial view before treatment; b) Maxillary occlusal view.

had hurt ± 3 months ago and sometimes felt sore. The patient wants her teeth to be treated because she feels less confident when she smiles and wants to fix these teeth.

The history of treatment on the tooth in question have had root canal treatment and been filled since 8 years ago. The tooth has had braces (orthodontic) treatment and was removed ± 7 years ago. The patient stated that she had no systemic health disorder.

The results of intraoral examination revealed that the patient had a normal posterior cusp to fossa and anterior relation with an overbite value of 3 mm and overjet value of 4 mm. The salivary test results also showed that the quality and quantity of the patient's saliva were still within normal limits (Table 1). On objective examination, there were diastema in teeth 11, 21, 12, 13, 23, and 25 (Figure 1). In the EPT vitality test, it can be concluded that tooth 13, 12, 21, 23, and 25 is vital, and tooth 11 and 22 is non vital.

From the examination that has been carried out, a clinical diagnosis of reversible pulpitis in tooth 21, necrosis pulp with asymptomatic apical periodontitis in tooth 11, previously treated with asymptomatic apical periodontitis in tooth 22 was established. Figure 2 shows the supporting examination in radiographs showed a radiopaque image in root canal of tooth 22 with periapical abnormalities of tooth 11 and 22.

The treatment plan that will be carried out in Endodontic is Root Canal Treatment in tooth 11 and Endodontic Retreatment in tooth 22. The preparation technique used is Crown Down Pressureless and the filling technique used is Single Cone. The planned restoration treatment is an Indirect Veneer made of Emax (lithium disilicate) for tooth 12, dowel and crown made of Fiber post and Emax (lithium disilicate) for tooth 11 and 22, Direct Veneer made of composite for tooth 13, 23, 25, and crown made of Emax (lithium disilicate) for tooth 21.

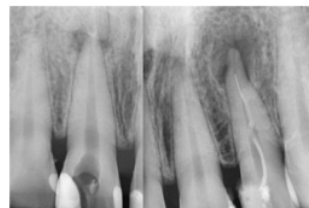


Figure 2. Periapical photos of teeth 11 (left) and 22 (right) before treatment

CASE MANAGEMENT

Treatment was completed in 4 visits, with each visit screening patients and antigen swabs first as a form of implementing health protocols during the pandemic. Both operators and assis-tant operators use level 3 personal protective equipment (PPE), treatment is carried out in a negative pressure room equipped with extraoral suction.

At visit 1, DHE and KIE were performed on the patient, and the patient received informed consent and informed consent as a form of approval for the tr-eatment to be carried out. After the saliva test was performed, the patient was instructed to rinse his mouth with 1% povidone-iodine solution for 30 seconds. The next stage is molding for study models with irreversible hydrocolloid, followed by taking Dental Photography and making Digital Smile Design and wax up dental (Figure 3).

At the second visit, the patient did not feel any complaints in the anamnesis, there were no extraoral abnormalities. The results of the intraoral examination showed that the percussion and bite test is negative. The first step is root canal treatment for tooth 11 where rubber isolation and dental suction was carried out, followed by tooth access opening. The next stage is glidepath procedure: Negotiation using #10 K-file and macro glidepath using proglider. In apical gauging, K-file #30 is obtained, followed by working length measurement using Electric Apex Locator K-file #10, and obtained the working length of tooth 11 is 23 mm.

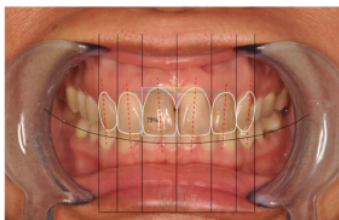


Figure 3. Digital Smile Design Analysis

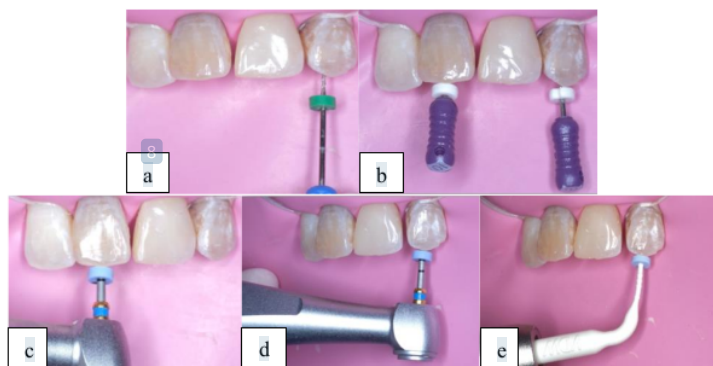

Figure 4. a) Gutta Percha retrieval with H files tooth 22; b) Determination of working length; c) Root canal preparation of tooth 11; d) Root canal preparation of tooth 22; e) Irrigation and sonic agitation.

rubber isolation and dental suction, followed by removing temporary restoration.

The next stage is irrigation sequence with NaOCl 2.5%-aquades-EDTA 17%-aquades- Chlorhexidine 2%-aquadest using a syringe with a 1 side-vent needle 30G and activation of sonic agitation using the EDDY system. The root canals were dried with endosuction and sterile paper points and the root canal is filled using the single cone technique and resin based paste and then is temporarily closed (Figure 5).

At the fourth visit, the patient did not feel any complaints in the anamnesis, there were no extraoral abnormalities. The results of the intraoral examination showed that the percussion and fistula test is negative, temporary restorative does not come off, gingiva around teeth is normal. The first step is direct veneer restoration for tooth 23 and 25. Perform composite color matching on teeth using composite try button technique and Installation of rubber dam and dental suction. The next stage is labial preparation of teeth 23 and 25 with a round end tapered diamond bur 0.5mm deep followed by etching 37% phosphoric acid, then rinse and dry (Figure 6a and 6b). Bonding is then slowly applied with airflow from a three-way syringe then light cured (Figure 6c). Palatal shell and proximal wall are made with A2 Tetric N-Ceram composite application using the silicon key technique which is made based on the wax up

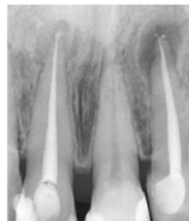


Figure 5. Obturation.

model, then light cured (Figure 6d and 6e). The next stage is Layering of A2 Tetric N-Ceram composite as enamel on the labial surface evenly, then light cured from all directions. Lastly, finishing and contouring is done using a fine finishing bur followed by finishing and polishing using soflex discs and eve diacomp (Figure 6f).

The next procedure is dental direct veneer restoration on tooth 13. First, composite color matching was carried out on the teeth using composite try button technique followed by installation of rubber dam and dental suction (Figure 7a). Labial preparation of teeth 23 and 25 is done with a round end tapered diamond bur 0.5mm deep followed by etch 37% phosphoric acid application, and then rinse and dried (Figure 7b and 7c). The next stage is bonding application with airflow from a three-way syringe slowly then light cured, followed by making palatal shell with A2 Tetric N-Ceram composite application using the silicon key technique which is made based on the wax up model, then light cured (Figure 7d and 7e). Proximal wall and incisal edge is made with composite application A1 Tetric N-Ceram, then light cured and composite is applied by layering using Tetric dentin A3.5 composite N-Ceram as dentin, then light cured (Figure 7f). The next stage is layering of A2 Tetric N-Ceram composite as enamel on the labial surface evenly, then light cured, followed by light curing from all direction. The last step is finishing and contouring using a fine finishing bur followed by finishing and polishing using soflex disc and eve diacomp (Figure 7g and 7h)

Next is dowel preparation tooth 11 and 22. First is Temporary demolition followed by selection of prefabricated post sizes based on customized templates with radiographs. 2/3 coronal guttapercha on tooth 11 is taken along 15 mm, tooth 22 for 14.5 mm long and smoothing of the root canal walls was done using peeso reamer and calibration drill. The next step is fiber pegs try on followed by application of self-etch adhesive to root canals. Cementation of fiber posts is done with self-adhesive resin cement dual cured and

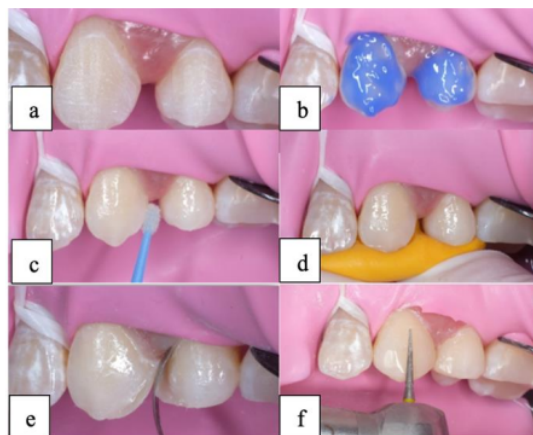

Figure 6. a) Tooth preparation (23,25); b) Tooth etch application (23,25); c) Bonding application; d) Palatal shell forming; e) Proximal wall; f) Finishing.

light curing, then core buildup is done on tooth 11,22 using dual-cured, core buildup composite, and light curing

The next step is indirect veneer 12 preparation. Starting with mock up using bis-acryl composite resins from a wax up model, determination of tooth color, and lab communication. Tooth 12 veneer preparation is done with Incisal Overlap Preparation design, and then a depth cut marker on the labial with a depth cutting bur of 0.5 mm is made. The next stage is mockup demolition, where the < 0.5mm preparation on the labial is seen, followed by labial reduction to depth marker depth. A 0.5mm incisal reduction is done using butt joint margin. Lastly, an interproximal preparation stops just before the point of contact, supragingival chamfer margin preparation in cervical and proximal is made and installation of retraction cord is done.

Next is crown preparation for tooth 11, 21, and 22. The first stage is Emax (lithium disilicate) crown preparation with deep chamfer margins, labial and incisal reduction of 1 mm with round end tapered diamond bur (Figure 8a and 8b). Installation of retraction cord is done followed by molding the working model using polyvinyl siloxane with double impression technique and antagonist impression with irreversible hydrocolloid (Figure 8c). Lastly, bite registration is made using polyvinyl siloxane followed by making temporary crowns using bis-acrylic resin (Figure 8d).

At the fifth visit, the procedure done is cementation of veneers and crowns (Figure 8e). The patient did not feel any complaints in the anamnesis, there were no extraoral abnormalities. The results of the intraoral examination

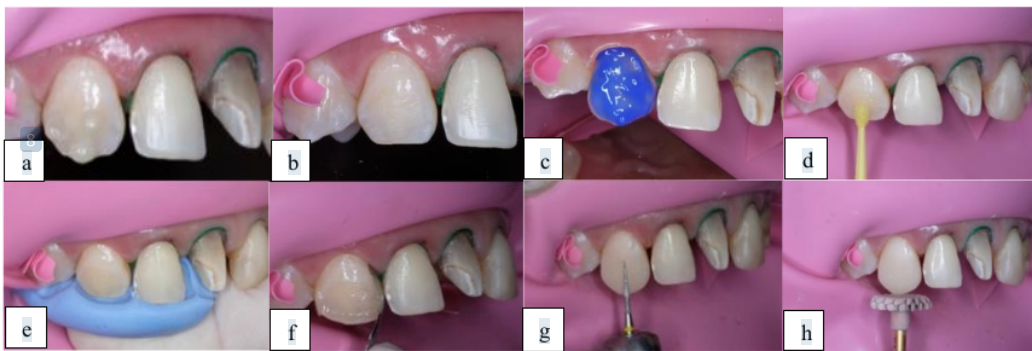


Figure 7. a) Color determination with button try technique; b) Tooth 13 preparation; c) Etch 37% phosphoric acid; d) Bonding; e) Palatal shell forming; f) Proximal wall forming; g) Finishing; h) Polishing.

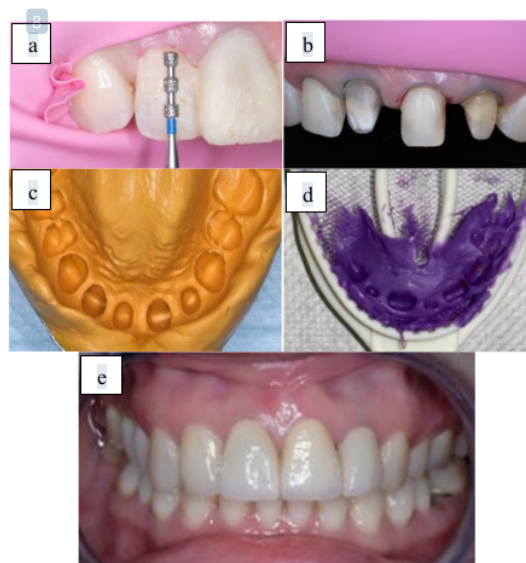


Figure 8. a) Preparation tooth 12 with depth cutting bur; b) Veneer 12 and crown 11, 12, and 21 preparation result; c) Impression result; d) Bite registration; e) Front view after cementation.

1 showed that the percussion and bite test is negative, the condition of the temporary crown (mock-up) is still good, and gingiva around teeth is normal. The first step is disassembly of the temporary crown and Emax (lithium disilicate) crown installation test for tooth 11, 21, 22 and Emax (lithium disilicate) veneer 12. Color check, margin adaptation, proximal contact and occlusion is done followed by installation of rubber dam, dental suction and isolation of neighboring teeth using teflon tape. The next stage is decontamination of the tooth surface with a rotary brush and pumice and etch 37% phosphoric acid application for 30 seconds on the tooth surface, rinse with water, dry, applicator bonding, and then light cured. Veneer surface treatment and Emax veneers (lithium disilicate) and crowns is done followed by application of hydrofluoric acid 9% for 20 seconds, rinse, dry, and silane application on inner surface for 60 seconds. Veneer and Emax (lithium disilicate) crown is cementated using resin cement light cure, then clean the rest of the cement and light curing from all directions. Lastly, remove rubberdam, check the occlusion, adapt the margin and proximal contact.

At the last visit, there was no complain on subjective examination. On objective examination, the results of the -intraoral examination showed that surrounding gingiva is normal, restoration is in good condition, the color is stable, and there was no chipping.

DISCUSSION

Dento-Facial aesthetics has been used to describe the between the face, lips, gingiva and teeth in creating an overall aesthetic outcome.^{9,10} Dental caries is the most common oral disease which is recognized as a major cause of oral pain and tooth loss.¹¹ Dental caries defined as the destruction of the dental hard tissue which is susceptible to acids which are a by-product of fermentation processes by bacteria.¹² The caries process results from an ecological imbalance in the balance between tooth minerals and oral biofilm (plaque).¹¹ If this caries progress continues, it will progress to pulp disease and then to periapical disease. Pulpal and periapical diseases can be treated with curative treatment, that is endodontic treatment.¹³

Reversible pulpitis is mild to moderate inflammation of the pulp caused by noxious stimuli.³ However, if the cause of inflammation is removed, the pulp will return to normal. Factors leading to reversible pulpitis are cervical erosion, mild stimuli such as incipient caries, occlusal attrition, errors in operative procedures, deep periodontal curettage, and enamel fractures that expose the dentinal tubules.¹⁴

Pulp necrosis is a condition where the pulp is dead, the blood vessels are no longer vital, and the pulp nerve is no longer functioning. If the pulp is completely necrotic, the tooth is asymptomatic until symptoms develop as a result of the progression of the disease process into the periradicular tissues. Most of the pulp necrosis occurs due to complications from acute and chronic pulpitis that is not treated properly and adequately.⁵

Necrotic pulp and reversible pulpitis disease are one of the indications for endodontic treatment, that is root canal treatment (RCT) by taking vital or necrotic pulp from the root canal and replacing it with a filling material.¹⁵

In this study, teeth 11 and 22 had non-vital pulp, so root canal treatment was done first. For the next treatment, the fiber posts were chosen because it has similar elasticity to dentin and aesthetic appearance. Moreover, fiber posts are stainless to the gingival edges and translucent. Its translucency allows fiber posts to be penetrated by light during cementation using dual cure cement materials. Posts and cores are cemented with an adhesive and biocompatible technique.¹⁶

11 Hargreaves et al. (2016) stated that the post in the root canal required core and coronal restorations. They should provide as many clinical properties as possible, such as maintain and repair the root, core and crown, and protect the crown edges from leakage. Thus, this post achieves dental esthetics and provides high radiographic visibility and biocompatibility.¹⁷

In this case report, E-max crown were used for 11 and 22 teeth. restoration using e-max gives very satisfactory results. E-max crowns show better clinical and radiographic results due to their physical and mechanical properties such as biocompatibility, durability, radioactivity, flexural strength and safety for patients, dentists and technicians.¹⁸

E-MAX crowns with lithium disilicate base were also used as a material for crowns for teeth 21. E-MAX crowns made from lithium silicate are the preferred type of crown because of its aesthetic appearance with high strength of 470 MPa. Its color is translucent, which ensures the closest match of the natural tooth's light properties.¹⁹

Furthermore, for the case of tooth 12, indirect veneer treatment were chosen. Veneer treatments are more conservative treatment option to repair or restore the aesthetics of the patient's teeth. Indirect veneer treatment was done with lithium disilicate materials since it has aesthetic rehabilitation.²⁰ Lithium disilicate veneer is the thinnest veneer. The fracture hardness and biaxial strength of this material are greater than other materials.²¹

And finally for the treatment of tooth 13, 23, 25, direct veneer treatment with composite materials were chosen as the treatment. Veneer restoration is a thin layer of restorative material which able to cover the outer surface of the teeth so that the teeth that have changed in color and shape will not be seen. The material used for veneers can be composite resin or porcelain.²⁰ Direct composite veneers have some advantages. for example, it needs a small amount of composite material. Thus, less tissue will be wasted and restorations can be completed in just one visit.²²

In conclusion, in recent years, aesthetic needs in dentistry have received greater attention. The treatment in this case is complex and focusing on aesthetic result especially for anterior teeth. The dowel, crown, and direct-indirect treatment were done in this case. The material used for each teeth treatment in this case is also considered. The patient discussed in this report case was aesthetically satisfied with the treatment.

REFERENCES

1. Gisely Naura Venâncio, Rosceline Rodrigues Guimarães Júnior, Sybilla Torres Dias. Conservative esthetic solution with ceramic laminates: Literature review. *RSBO*. 2015;11(2):185–91.
2. Zubaidah N. Management of anterior teeth damage caused by complex caries through aesthetic endorestitution. *Dental Journal (Majalah Kedokteran Gigi)*. 2011;44(1):30.
3. Widyastuti, Noor Hafida. *Penyakit Pulpa dan Periapikal beserta Pelaksanaannya*. Muhammadiyah University Press. 2017
4. Kumala P, I. et al., *Kamus Saku Kedokteran Dorland*. Jakarta: EGC. 2006.
5. Merry R Sibarani. Karies: Etiologi, Karakteristik Klinis dan Tatalaksana. *Majalah Kedokteran UKI*. 2014;30(1): 14-22.
6. Hargreaves K, Berman L, Rotstein I, Cohen S. Cohen's pathways of the pulp [Internet]. 12th ed. Vol. 1. Mosby; 2020 [cited 2022Nov18]. Available from: <https://www.elsevier.com/books/cohens-pathways-of-the-pulp/berman/978-0-323-67303-7>
7. Dindar, Mediha Büyükgöze; Açıköz, Ece; Atay, Meltem Tekbaş. Closure of The Midline Diastema With Direct Composite Resin Restorations After Frenectomy: Case Report And 1 Year Follow-Up. *Journal of Dentistry*, 2018, 1.1: 1-4.
8. Ardu S, Krejci I. Biomimetic direct composite stratification technique for the restoration of anterior teeth. *Quintessence international*. 2006 Mar 1;37(3).
9. Edward A. McLaren, Robert Rifkin. Macroesthetics: Facial and Dentofacial Analysis. *Oral Health*. 2005;95(11): 65-77.
10. Emil Hawary. The Art of matching anterior porcelain restoration : a clinical case report. *J Califf Dental Association*. 2014;23(3): 38-41.
11. Khushbu Yadav, Satyam Prakash. Dental Caries: A Review. *Asian Journal of Biomedical and Pharmaceutical*. 2016;6(53), 01–07.
12. Selwitz RH, Ismail AI and Pitts NB. Dental caries. *Lancet*. 2005; 369: 51-59.
13. Nyvad B and Takahashi N. Caries ecology revisited: microbial dynamics and the caries process. *Caries Res*. 2008; 42: 409- 418.
14. Aas JA, Griffen AL, Dardis SR, Lee AM, Olsen I and Dewhirst FE. Bacteria of dental caries in primary and permanent teeth in children and young adults. *J Clin Microbiol*. 2008; 46: 1407-1417.
15. Subrata A, Prahasti AE, Iskandar BO. Influence of two root canal obturation techniques with resin based sealer to Enterococcus faecalis penetration. *Journal of Indonesian Dental Association*. 2019;2(1):21.
16. Al Moaleem MM, Mobaraky AA, Madkhali HA, et al. Evaluation of maxillary anterior endodontically treated teeth restored with different types of crowns. *International Journal of Dental Research* 2017; 5(2): 163-166.
17. Hargreaves, K. M., Berman L. H. Cohen's Pathways of the Pulp 11th edition. Missouri: Elsevier. 2016, pp: 819-23, 830-31.
18. Kim Li Raymond Wai, Chow Tak Wah, Matinlinna Jukka Pekka. Ceramic dental biomaterials and CAD/CAM technology: State of the art. *Journal of prosthodontic research* 2014; 58: 208 – 16.
19. Ng CCH, Dumbrigue HB, Al-Bayat MI, Griggs JA, Wakefield CW. Influence of remaining coronal tooth structure location on the fracture resistance of restored endodontically treated anterior teeth. *The Journal of Prosthetic Dentistry*. 2006;95(4):290–6.
20. Bora Korkut. *J Dent Res Dent Clin Dent Prospects* 2013 Spring; 7(2): 105–111.
21. Schmitter M, Seydler B B. Minimally invasive lithium disilicate ceramic veneers fabricated using chairside CAD/CAM : A clinical report. *J Prosthet Dent* 2012;107:71-4.
22. McLaren EA, Figueira J, Goldstein RE. A Technique Using Calibrated Photography and Photoshop for Accurate Shade Analysis and Communication. *Compendium of continuing education in dentistry*. 2017;38(2):106–113.

Complex aesthetic treatment of patients with multiple caries

ORIGINALITY REPORT

15%

SIMILARITY INDEX

12%

INTERNET SOURCES

6%

PUBLICATIONS

0%

STUDENT PAPERS

PRIMARY SOURCES

1	zombiedoc.com Internet Source	5%
2	e-journal.unair.ac.id Internet Source	2%
3	LOUIS H. BERMAN, GARY R. HARTWELL. "Diagnosis", Elsevier BV, 2011 Publication	1%
4	Rena Setiana Primawati. "APPLICATION OF CPP-ACP REMINERALIZATION MATERIALS (TOOTH MOUSSE) ON SALIVA PH IN STUDENT", The Incisor (Indonesian Journal of Care's in Oral Health), 2022 Publication	1%
5	www.ijfmt.com Internet Source	1%
6	www.hindawi.com Internet Source	1%
7	www.mdpi.com Internet Source	1%

8	dokumen.pub Internet Source	1 %
9	Esthetic and Functional Management of Diastema, 2016. Publication	1 %
10	Romero, Mario F.. "Esthetic anterior composite resin restorations using a single shade: Step-by-step technique", Journal of Prosthetic Dentistry, 2015. Publication	<1 %
11	Restoration of Root Canal-Treated Teeth, 2016. Publication	<1 %
12	"Ronald E. Goldstein's Esthetics in Dentistry", Wiley, 2018 Publication	<1 %
13	kongre.akademikiletisim.com Internet Source	<1 %
14	worldwidescience.org Internet Source	<1 %
15	api.research-repository.uwa.edu.au Internet Source	<1 %
16	www.jidmr.com Internet Source	<1 %

Exclude quotes Off

Exclude matches < 10 words

Exclude bibliography On

Complex aesthetic treatment of patients with multiple caries

GRADEMARK REPORT

FINAL GRADE

/0

GENERAL COMMENTS

Instructor

PAGE 1

PAGE 2

PAGE 3

PAGE 4

PAGE 5

PAGE 6

PAGE 7