

Case Report

Management of root perforation: A case reportSylvia Paulina Panggono¹, Teuku Chairil Hafiz¹, Tamara Yuanita²¹Resident of Conservative Dentistry, Faculty of Dental Medicine, Universitas Airlangga, Surabaya, Indonesia²Department of Conservative Dentistry, Faculty of Dental Medicine, Universitas Airlangga, Surabaya, Indonesia**ABSTRACT**

Background: Root perforation results in the communication between root canal walls and periodontal space (external tooth surface). It is commonly caused by an operative procedural accident or pathological alteration (such as extensive dental caries, and external or internal inflammatory root resorption). The diagnosis of dental pulp and/or periapical tissue previous to root perforation is an important predictor of prognosis. **Case:** A female patient came to Dental Conservative University of Airlangga with complaints of perforated lower left molars. On the objective examination obtained negative vitality test, positive on bite test. On radiographic examination, a radiolucent on bifurcation was performed **Case management:** The tooth was treated by hemisection. Root canal treatment was carried out in the distal canals. Afterwards, the tooth was split mesio-distally. The mesial root was extracted, and the distal root was retained and restored with PFM Crown. **Discussion:** Hemisection is a useful alternative treatment to extraction to save the multi-rooted teeth by endodontic approach, which includes the root canal treatment of the remaining roots and restoring them with suitable restorative material to splinting it with the adjacent tooth to decrease the risk of displacement followed by a fixed prosthodontic prosthesis to maintain the occlusal balance. **Conclusion:** Hemisection with subsequent prosthetic rehabilitation can be a viable alternative to retain severely decayed mandibular molar.

Keyword: root perforation, root resection, compromised tooth

Correspondence: Tamara Yuanita, Conservative Dentistry and Endodontics Department, Faculty of Dental Medicine, Universitas Airlangga, Jl. Prof. Dr. Moestopo, Street 47, Surabaya, Indonesia, 60132. Email: tamara-y@fkg.unair.ac.id

INTRODUCTION

Root perforation results in the communication between root canal walls and periodontal space (external tooth surface). It is commonly caused by an operative procedural accident or pathological alteration (such as extensive dental caries, and external or internal inflammatory root resorption). Different factors may predispose to this communication, such as the presence of pulp stones, calcification, resorptions, tooth malposition (unusual inclination in the arch, tipping or rotation), an extra-coronal restoration or intracanal posts. The diagnosis of dental pulp and/or periapical tissue previous to root perforation is an important predictor of prognosis (including such issues as clinically healthy pulp, inflamed or infected pulp, primary or secondary infection, and presence or absence of intracanal post).¹

The advancement of dentistry has provided an opportunity to maintain the teeth in order to function as long as possible in the mouth. Patients prefer root canal treatment on their teeth rather than revocation, as their thinking patterns have changed, that pain can be overcome during root canal treatment. This is supported by the presence of advanced dental care techniques, and the results are quite satisfactory for the long term.² Treatment in endodontics

is divided into two conventional treatments and surgical treatment. Endodontic surgical treatment is the development of a wider treatment to avoid tooth extraction. Endodontic surgery includes incisions for drainage, apex resection, hemisection, root amputation, hemisection, bicuspidization and replantation.³ Hemisection is the removal of a root and half a double-rooted crown. In the mandibular molars of the teeth are separated in the buccal-lingual direction through bifurcation. The pathological root or periodontal tissue has been damaged and the crown is removed.⁴

CASE

A-20-year-old woman came to Conservative Department University of Airlangga with complaints of large cavities in the lower left tooth, the patient wanted her teeth treated. The tooth had been previously treated at the public health center ± 3 years ago, but the filling came off 6 months later. The patient had experienced pain in the tooth about 2 weeks ago and the patient was taking pain medication. On intraoral examination, tooth was tender on bite test. On radiographic examination, a radiolucent on bifurcation was performed (Figure 1).

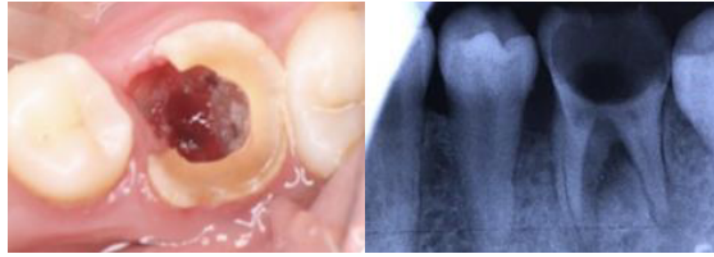

Figure 1. Intraoral and Radiograph before treatment.



Figure 2. Shaping, cleaning and obturation.

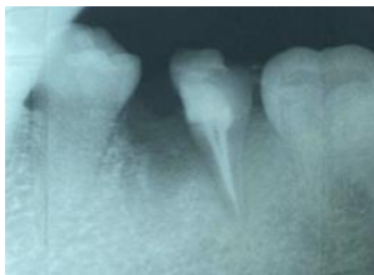


Figure 3. Post and core.

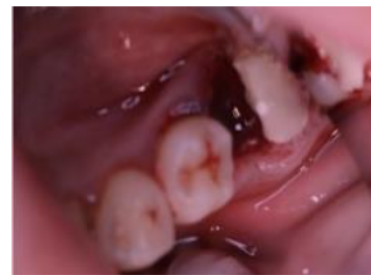

Figure 4. Hemisection.

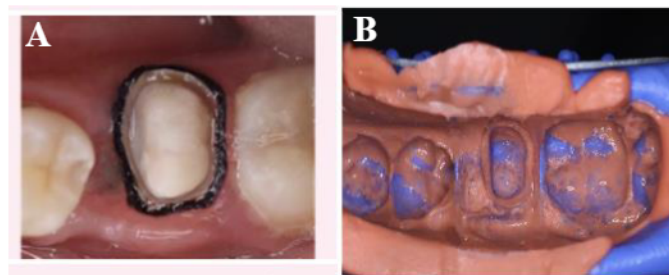


Figure 5. (A) Preparation tooth, gingival management with retraction cord. (B) Impression with PVS.

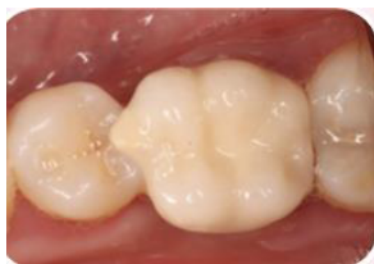

Figure 6. Final Restoration.

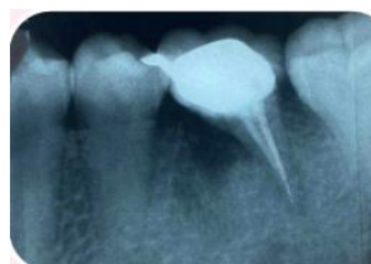

Figure 7. Radiograph post treatment.

CASE MANAGEMENT

Before starting the treatment, intraoral photo, saliva test, and periapical radiography were taken (Figure 1). The first visit was to excision gingival polip. Then, tooth 36 was isolated with rubber dam. Negotiation was performed with K-File #10 and glide path with the same instrument and *Proglider* with root canal lubricant. Working length was determined with electronic apex locator and was confirmed with periapical radiograph (DB: 17 mm, DL: 17,5 mm). ProTaper Next X2 (25/06) were used to shape the canals with crown down pressure less technique (Figure 2).

Root canal cleaning was done with the following protocol: EDTA 17 %, flused with steril aquadest and NaOCl 2.5%; and Chlorhexidine 2%, activation with Endoactivator. After that, trial guttap with Protaper Next X2, then dressing with Ca(OH)₂. The next visit, root canal was obturated with Protaper Next X2 gutta percha and resin-based sealer with single cone technique. Radiograph was taken to confirm the obturation (Figure 2). At the third visit, gutta percha on distolingual canal was reduced by 14 mm with Peeso reamer and post drill. Fabricated post was inserted on the tooth with self-adhesive resin cement. Core build up was performed with dual cure composite core material (Figure 3).

On fourth visit, before hemisection, with long tapered diamond bur, the distal and mesial roots of 36 was separated right at the furcation level. Then, the mesial root was elevated and extracted (Figure 4). Gingiva was sutured to secure bone graft and membrane in place. Periapical radiograph was taken to evaluate the hemisection procedure. The patient was given prescription of antibiotics and antiinflammatory medications as well as post-hemisection instructions. On fifth visit, Impression for working cast was made with PVS in double-step technique (Figure 5). Prepared tooth 36 was subsequently temporised. Lab instructions was then sent for PFM crown fabrication. On sixth visit, PFM crown try in & cementation: Temporary crown was removed and PFM crown was tried and evaluated for its marginal fit, proximal fit, and occlusion. Subsequently, PFM crown was cemented with GIC luting cement (Figure 6 and 7).

DISCUSSION

Hemisection is one of the arsenals within endodontics discipline which utilizes both conservative and surgery measures to retain compromised teeth.⁵ The hemisection is a useful alternative treatment to extraction to save the multi-rooted teeth by endodontic approach, which includes the root canal treatment of the remaining roots and restoring them with suitable restorative material to splinting it with the adjacent tooth to decrease the risk of displacement followed by a fixed prosthodontic prosthesis to maintain the occlusal balance.⁶ Hemisection, enabling the clinician to preserve to retain part of a compromised tooth, offers several advantages. Surrounding hard and soft tissue health can be more easily maintained with proper marginal fit, occlusion and oral hygiene. Also, periodontal ligament which

act as shock absorber and proprioception is maintained. Hemisection also offers psychological advantages over extraction because a part of tooth is still retained. In terms of financial perspective, hemisection might incur less cost to patients compared to dental implants.

The indications for tooth hemisection, according to Weine are Periodontal Indications: a) Only one root of a tooth with several roots suffers from severe vertical bone loss. b) Complete destruction of the furcation. c) The roots of adjacent teeth are too close to one another, making it difficult to maintain proper cleanliness in close quarters. d) Serious root exposure as a result of dehiscence. Contraindications: a) As alternatives to hemisection, there are strong neighboring teeth that can serve as bridge abutments. b) Inoperable root canals should be kept. c) Fusion of the roots makes separation impossible. d) Non-strategic teeth.²

Hemisection, enabling the clinician to preserve to retain part of a compromised tooth, offers several advantages. Surrounding hard and soft tissue health can be more easily maintained with proper marginal fit, occlusion and oral hygiene. Also, periodontal ligament which act as shock absorber and proprioception is maintained. Hemisection also offers psychological advantages over extraction because a part of tooth is still retained. In terms of financial perspective, hemisection might incur less cost to patients compared to dental implants. Hemisection has a very high survival rate. According to a systematic review evaluating more than hemisected. 90 teeth with up to 40 years follow-up, it was found that hemisection has a survival rate of 95%. In order to achieve such a high survival rate, several measures are needed to be strictly followed, such as Case selection: tooth to be retained has a large, long, divergent root and crown; the root to be retained does not act as a terminal abutment of a long-span fixed dental prosthesis; Endodontic treatment: access should be as small as possible; lateral condensation obturation technique must be avoided; Surgery: atraumatic extraction; removing roughness on furcal roof, eliminating root concavity for easy oral hygiene measures; socket preservation of the extraction socket; Restoration: limiting the use of endodontic post; making cuspal inclines less steep to reduce lateral forces; sanitary pontic.⁹

Evaluation post-hemisection control is not found subjective or objective symptoms, it is expected that hemisection treatment with a high enough success rate to maintain the rest of the tooth structure and functioning for as long as possible in the oral cavity. In conclusion, hemisection with subsequent prosthetic rehabilitation can be viable alternative to retain severely decayed mandibular molar.

REFERENCES

1. Estrela C, Decurcio DA, Rossi-Fedele G, Silva JA, Guedes OA, Borges ÁH. Root perforations: a review of diagnosis, prognosis and materials. *Braz Oral Res*. 2018 Oct 18;32(suppl 1):e73. doi: 10.1590/1807-3107bor-2018.vol32.0073. PMID: 30365614.

2. Walton R & Torabinejad M : Endodontics Principles and Practice 4th Edition : Saunders Elsevier, St. Louis, Missouri, 2008 : 369-372
3. Arora A, Arya A, Singhal RK, et al. Hemisection: a conservative approach. *Indian J Dent Sci.* 2017;9:206–209
4. Sharma S, Sharma R, Ahad A, Gupta ND, Mishra SK .Hemisection as a conservative management of grossly carious permanent mandibular first molar. *J Nat Sci Biol Med.* 2018;9:97–99
5. Singh M, Satish C. 2018. Hemisection in an Era of Implants. *Open Access J Dent Sci.* Vol. 3(5) , pp:1–5.
6. Babaji, Prashant, Sihag Tarun, Rampratap Vishwaib ,Senthilnathan Sivaramalingam. 2015. Hemisection: A Conservative Management of Perioontally involved Molar tooth in a young patient. *Journal of Nat Sci Biology and Medicine* Vol6, pp. 255
7. Mokbel N, Kassir AR, Naaman N, Megarbane J. 2017. Root Resection and Hemisection Revisited . Part I : A Systematic Review : 39(1), pp:11–32.
8. Singh M, Satish C. Hemisection in an Era of Implants. *Open Access J Dent Sci.* 2018;3(5):1–5.
9. CW, Ongkowijoyo, Latief Mooduto, Deavita Dinari, Riski Setyo Avianti. Hemisection of a severely decayed mandibular molar: a case report. *Conservative Dentistry Journal.* 2020;10(1):23-26