

Effect of Socket Preservation Using Crab Shell-Based Hydroxyapatite in Wistar Rats

by Michael Josef K. Kamadjaja

Submission date: 04-Jun-2021 09:19AM (UTC+0800)

Submission ID: 1600002081

File name: rvation_Using_Crab_Shell-Based_Hydroxyapatite_in_Wistar_Rats.pdf (1.45M)

Word count: 5254

Character count: 28951

8
Effect of Socket Preservation Using Crab Shell-Based Hydroxyapatite in Wistar Rats**Michael JK Kamadjaja^{1*}, Bambang AS Tumali¹, Harry Laksono¹, Nike Hendrijantini¹, Melinda L Ariani², Natasia², Tata P Mawantari²*****Correspondence:** michael-j-k-k@fkg.unair.ac.id**Received: Dec 03, 2019; Accepted: May 23, 2020****Copyright:** Kamadjaja *et al.* This is an open-access article published under the terms of Creative Commons Attribution License (CC BY). This permits anyone to copy, distribute, transmit, and adapt the work, provided the original work and source are appropriately cited.**Citation:** Kamadjaja MJK, Tumali BAS, Laksono H, Hendrijantini N, Ariani ML, *et al.* Effect of socket preservation using crab shell-based hydroxyapatite in Wistar rats. *Recent Adv Biol Med.* 2020; 6(2): 1116232. <https://doi.org/10.18639/RABM.2020.1116232>**Abstract**

Tooth extraction can cause 1.5-2 mm (vertical) and 40-50% (horizontal) alveolar bone resorption to occur for 6 months after extraction and will continue if it is not treated. Alveolar bone resorption will affect the retention, stability, and comfort in the use of dentures because adequate alveolar bone volume and structure of alveolar ridge are very important to obtain optimal function and prosthetic reconstruction. Currently, there are techniques and materials that can be used to minimize bone resorption. Preservation of alveolar ridges with crab shell-based hydroxyapatite can minimize bone resorption because it has good biocompatibility, osteoconduction, and osteoinduction. The aim of this study is to prove the effectiveness of hydroxyapatite from crab shells in increasing the area of bone trabeculae, transforming growth factor-beta 1 (TGF- β 1), and alkaline phosphatase (ALP). This laboratory research is an experimental laboratory work with a post-test group design. Crab shell-based hydroxyapatite gel (*Portunus pelagicus*) was given after the post-tooth socket extraction of the left lower central incisor of Wistar rats, observing the area of trabeculae, TGF- β 1, and ALP on the 14th day and 28th day. Hydroxyapatite is made from the calcination process of crab shells using a furnace at 1000°C for 2 h followed by sifting to powder. The powder is added with carrageenan and distilled water so that it becomes a gel preparation. The results of this study were analyzed using the One-way ANOVA test with IBM SPSS version 20. The area of trabeculae, TGF- β 1, and ALP between the control group and the treatment group showed $p < 0.05$, which means there were significant differences between the groups. The study showed that hydroxyapatite from the crab shell (*P. pelagicus*) can increase the area of trabeculae, TGF- β 1, and ALP in the post-extraction socket of Wistar rat's teeth.

Keywords: Alkaline Phosphatase (ALP); Hydroxyapatite; Trabecular area; Transforming Growth Factor-Beta 1 (TGF- β 1).**1. INTRODUCTION**

Tooth extraction can cause sockets and changes in gingival contours. In general, the tooth socket will heal normally, but the alveolar defect will only partially recover. Along with bone growth, there is also a process of resorption in the alveolar ridge [1]. The resorption of alveolar bone that occurs after tooth extraction results in damaging the periodontium and the loss of the bundle bone, especially in the buccal part, which will change the size and shape of the bone. The alveolar bone becomes low, rounded, or flat due to resorption on the surface of the alveolar bone from the vertical and palatal directions [2]. Loss of alveolar bone support will affect retention, stability, and comfort in the use of dentures; therefore, it is very important to maintain alveolar ridge after extraction [3].

Preservation of the socket after tooth extraction can reduce the problem of excessive resorption and facilitate maintenance. Socket preservation with bone graft can be a solution to maintain ridge dimensions and contours [4]. The bone graft used must be acceptable to the body or biocompatible, have good mechanical properties, and be easily manipulated. The bone graft has three basic functions: osteogenesis, osteoinduction, and osteoconduction [5]. Among the various biomaterials used as bone graft, one of the biomaterials that is often used in dentistry is hydroxyapatite [Ca₁₀(PO₄)₆(OH)] [6].

Hydroxyapatite material can be obtained from natural biological sources. Among the abundant raw materials available in Indonesia, crab shell (*Portunus pelagicus*) is the one that can be used to produce hydroxyapatite. Exports of crab meat only in fresh, frozen, or canned forms without the inclusion of the shell continue to increase every year. Apart from this increasing export of crab meat, this will too increase the wastage of crab shell. Indonesian crab shell wastage reached 151,053–302,107 tons in 2012. In Indonesia, crab shell waste has not been optimally used, and it can pollute the environment and water bodies around the factory [7]. This waste can be used as material for bone graft because the crab shell contains 15–23% of protein,

2 Original Research Article

18–32% of chitin, and high calcium that comprises 53–78% of the weight of the dry shell. Calcium and chitin from crab shells will be deacetylated so that they can be used as ingredients for hydroxyapatite synthesis [8].

Hydroxyapatite has advantages because it is biocompatible, has a crystal structure arrangement that is identical to bone, and displays osteoconduction and osteointegration [6]. The Interconnecting porous nature of the hydroxyapatite micro-architectures can accelerate vascularization, form strong bonds between bones that are important factors in the osteointegration process, and allow it to become a medium for mesenchymal stem cells and osteoblasts to adhere, live, and proliferate well in the damaged bone so as to enhance the process of bone regeneration [5]. Osteoblasts are bone-forming cells responsible for the bone matrix mineralization process which expression is controlled by several growth factors, one of which is the cytokine transforming growth factor-beta 1 (TGF- β 1) [5, 9, 10].

TGF- β 1 will stimulate bone formation by increasing osteoblast proliferation in the early stages of differentiation and increasing extracellular matrix (ECM) production, inhibiting osteoblast apoptosis, recruiting osteoblast precursors to the areas of damage by chemotactic attraction, and inhibiting proliferation of hematopoietic precursor cells [9]. The osteoblast cells will later sensitize and secrete TGF- β 1 during the proliferation phase, and the TGF- β 1 will then stimulate the osteoblasts by means of an autocrine effect [11].

At a later stage, the osteoblasts will secrete the bone matrix protein, which is alkaline phosphatase (ALP). ALP is an enzyme that stimulates bone calcification [12]. ALP activity is related to the formation of the hard tissue of teeth and bones such that ALP is widely used as a marker for bone formation. ALP prepares an alkaline atmosphere in the formed osteoid tissue so that calcium can be easily deposited in the tissue. Besides that, ALP in the bone can increase the concentration of phosphate so that calcium-phosphate bonds are formed in the form of hydroxyapatite crystals. Based on the law of mass action, the crystal eventually settles inside the bone [13].

Osteoblasts function to synthesize the organic components of the bone matrix, which can lead to the precipitation of the new organic bone elements called osteoid. When the matrix synthesis activity stops and the osteoblasts have entered the matrix, the osteoblasts change their name to osteocytes. Osteocytes are mineralized, the ossification process occurs, and there is increased in the area of the trabecular bone. An increase in trabecular area indicates the formation and mineralization of new alveolar bones [14].

2. METHOD(S)

This study has passed ethical clearance with the number 198/HRECC. FODM/V/2019 by ethical clearance commission in Faculty of Dental Medicine Universitas Airlangga. This research was conducted at the biochemical laboratory of the Faculty of Medicine, Universitas Airlangga. The crab shell-derived hydroxyapatite extraction was conducted at the Badan Penelitian dan Konsultasi Industri Surabaya, and histopathological examinations were carried out at the Biochemistry Laboratory of the Faculty of Medicine, Universitas Brawijaya and the Research Center of the Faculty of Dentistry, Universitas Airlangga. The experimental animal used in this study were 36 Wistar rats (*Rattus norvegicus*) with criteria: male, aged 3–4 months, 200–250 grams weight, healthy physical condition characterized by active movement, sparkling eyes, bright hair and with no defects in the body.

The tools used in this study were animal cages, sterile forceps for tooth extraction of mice, dental tweezers, scissors, Nierbeken 10-ml and 3-ml syringes, needle holders, silk thread 3/0, 16G needles, metal-molding tools for paraffin blocks, water baths (Medite, Germany), rotary microtomes (Accu-cut SRM 200, Japan), blade microtome (Leica 819 Low profile, USA), hot plates (Medite, Germany), thermal units to warm tissue specimens (Medite Test 99,600, Germany), dispenser unit for giving paraffin to tissue specimen (Medite Test 99,250, Germany), cool units for cooling paraffin in tissue specimen (Medite Test 99,410, Germany), HE object glass (Sail Brand Microscope), China), IHC object glass (Biogear Microscope Slide, China), cover glass (Aurora Scientific, Canada), humidity chamber to maintain moisture from preparations (Biogear Humidity Chamber, China), light microscopes to observe and cell count (Nikon Model Eclipse E200MV RS, Japan), microscopic camera (Nikon DS-Fi3, Japan), and computer (Lenovo processor i3-7100T, China). The materials used are hydroxyapatite gel extracted from crab shells (*P. pelagicus*), alcohol (Leica Surgipath Reagent Alcohol 100%, USA), 10% ether solution, ketamine, H₂O₂ (OneMed H2O2 3%, Indonesia), bone softener ([Titriplex III], USA, Netherlands), chlorine, ethylene diamine tetraacetic acid (EDTA), Mayer's hematoxylin, 10% buffered formalin (Leica Surgipath 10% neutral buffered formalin, Australia), PBS, albumin, phosphate buffered saline solution at pH 7, aquades solution, solid paraffin (Leica surgipath paraplast, USA), xylene (Fulltime Xylenes ACS, China), diaminobenzidine chromogen, HRP Excell Stain System (Biogear Scientific), monoclonal antibodies TGF- β 1 and ALP (Santa Cruz, USA), staining material for hematoxylin eosin (HE; Leica Surgipath SelecTech Hematoxylin 560 and Leica Surgipath SelecTech Eosin Phloxine 515, Australia), and immunohistochemistry (IHC) counterstaining (Path Chem 1% lithium carbonate, USA).

2.1. Preparation of Experimental Animals

The experimental animals were adapted in cages for 7 days before the research began, and each cage was filled with 9 mice with a temperature of 24°C \pm 1°C. During the adaptation process, mice were given standard feed and drink *ad libitum* (without restriction).

2.2. Production of Hydroxyapatite Gel

The process of obtaining hydroxyapatite from crab shells is by soaking crab shells (*P. pelagicus*) waste in H_2O_2 : water = 3:20 for 15 min and then soaking in chlorine (10 ml of chlorine is used for 20 l of water) for 5 min. Crab shell waste was cleaned from dirt with brush and dried at room temperature. Calcinations were performed at 1000°C temperature with an initial rate of temperature 50°C and a rise of 5°C/min and then maintained for 2 h. Hydroxyapatite gel is made from hydroxyapatite powder and carrageenan with a ratio of 2:1 [15].

2.3. Mandibular Left Incisor Extraction of Wistar Rats

The mandibular left incisor of Wistar rats was extracted. Tooth extraction was carried out under the effect of general anesthesia with ether 10% [16]. This would create the sockets, which were approximately 2 mm in diameter and 20 mm in depth, indicating that the HA did not hinder the natural bone-healing process in the socket [17].

2.4. Samples

This study used 36 samples divided into two control groups (K14 and K28) and two treatment groups (P14 and P28). Each group consisted of 9 samples. In the control group, on day 14 (K14) and day 28 (K28), no treatment was given and the post extraction socket was sutured with silk thread 3/0. In the treatment group, on day 14 (P14) and day 28 (P28), hydroxyapatite derived from crab shells was administered to the post extraction socket using a 3-ml syringe and then sutured with silk thread 3/0 [16]. In the control group on day 14 and day 28, and in the treatment group on day 14 and day 28, rats were euthanized using ketamine at lethal doses (66–88 mg/kgBB) intramuscularly (on quadriceps femoris). Furthermore, the rat's mandible was taken by incision from the corner of the mouth toward the posterior until the mandible was separated from the skull. After that, the rat's body was buried.

2.5. Tissue Preparation

Post extraction socket tissue of experimental animals was fixed with 10% formaldehyde solution. Then, decalcification was carried out using ethylene diamine tetraacetic acid (EDTA). Tissue specimens cut using a scalpel with a thickness of 0.3–0.5 mm and then dehydrated (Intelsint) and vacuumed using a tissue vacuum machine (Medite) for 30 min. Liquid paraffin was poured until the entire tissue was submerged in paraffin and then freeze it in the cooling unit. Paraffin blocks containing tissue were cut using a microtome machine (Accu-cut SRM) (3–4 μ m) [18]. The trabecular area was analyzed by HE staining, and the expression of ALP and TGF- β 1 was analyzed by IHC staining.

2.6. Observation Procedure of TGF- β 1, ALP, and Trabecular Bone Area

The magnification of the microscope used is 400 \times . The counting technique for TGF- β 1 and ALP analysis was used on a microscope with gratriculae at 8–10 field view / beta counter as wide as field of view. The trabecular bone area was measured by calculating the area of formed islands in the alveolar socket region in the histology slides by HE staining, which was measured by a light microscope with micrometer units and analyzed using the NIS-Elements D application. The numbers that appeared on this application indicate the area of trabeculae in the alveolar socket [14].

2.7. Data Analysis

Statistical analysis was performed using SPSS version 20 produced by IBM (USA). The normality distribution test was performed using Shapiro–Wilk test, and the variance homogeneity test was carried out using the Levene's statistic test. Parametric test was carried out using One-Way Anova and Post-Hoc Tukey honestly significant difference (HSD) test to prove whether there were significant differences between the control and treatment group.

3. RESULTS

The gel was applied to the socket after tooth extraction of the Wistar rat's teeth in the treatment group. In the control group, tooth sockets had not given anything and only post extraction suturing was performed. Tooth extraction sockets in the control and treatment groups were prepared onto microscope slides, and then stained with HE and IHC. The trabecular bone area was measured and the level of TGF- β 1 and ALP was counted use a light/optical microscope. The results of the study are shown in Figure 1.

Crab shells used in this study were analyzed to find out what components are present in them. From this test, the composition of hydroxyapatite was obtained at 87.11% with details of the chemical components given in Table 1.

Figures 1 and 2 showed that the highest mean of trabecular bone area in P28 was 51640.5556, which was higher than K28 that was 20570.6767; the highest level of ALP in P28 was 13.065, which is higher than K28 that was 6,064 and the highest level of TGF- β 1 in P14 was 16.33, which is higher than K14 that was 12.56. This showed the increase in the trabecular bone area, ALP, and TGF- β 1 in the treatment group, which was given hydroxyapatite gel compared to the control group that was not given any treatment.

P14 is a sign for the treatment group observed on the 14th day after incisor extraction and hydroxyapatite gel application. K14 is a sign for a control group that was not given hydroxyapatite gel and observed on the 14th day after the extraction

Figure 1: Mean of ALP and TGF-β1.

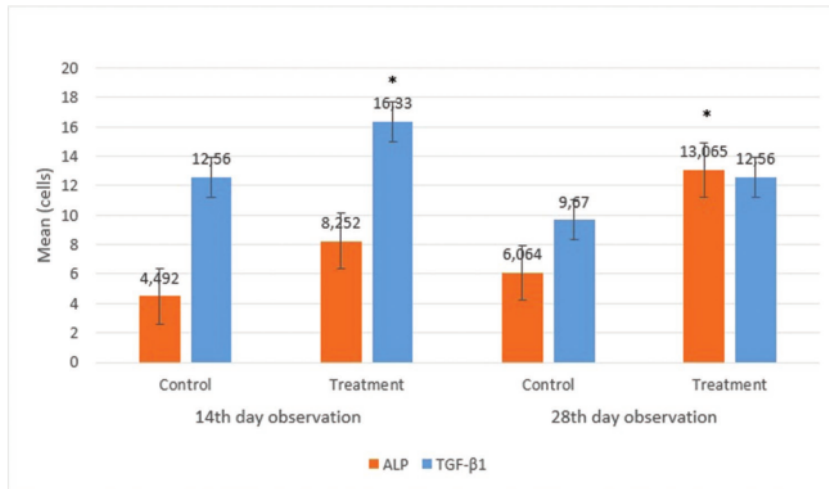
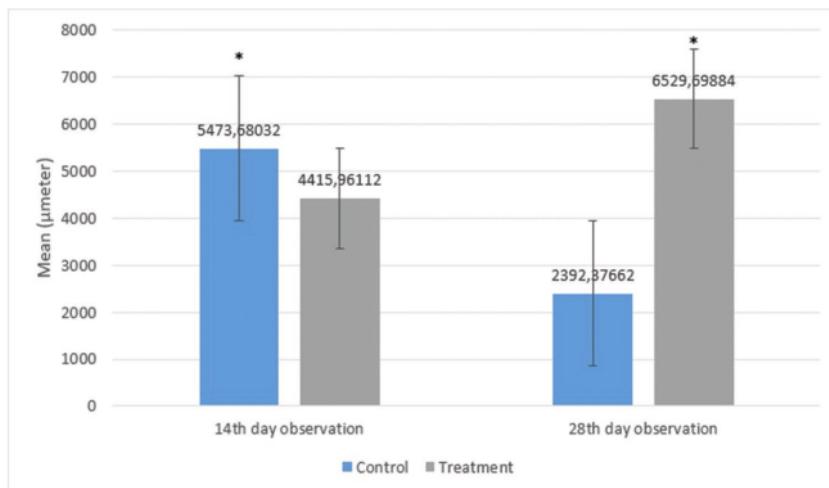


Table 1: Hydroxyapatite composition of hydroxyapatite from crab shells.

| Component | Percentage (%) |
|-----------------|----------------|
| CaO | 52.05 |
| PO ₄ | 37.82 |
| OH | 8.85 |

Figure 2: Mean of trabecular bone area.



of the incisors. P28 is a sign for the treatment group observed on the 28th day after incisor extraction and hydroxyapatite gel application. K28 is a sign for the control group that was not given any hydroxyapatite gel and observed on the 28th day after the extraction of the incisors.

Left mandibular alveolar bone preparation with HE staining, seen using a light microscope with a magnification of 400x. Viewed broad trabeculae expressed by osteoblasts that will be seen as a picture of the islands with a solid color that indicates the existence of alveolar bone regeneration process (Figure 3).

Figure 3: A. Expression of trabecular bone area in K14, B. Expression of trabecular bone area in K28, C. Expression of trabecular bone area in P14, D. Expression of trabecular bone area in P28.

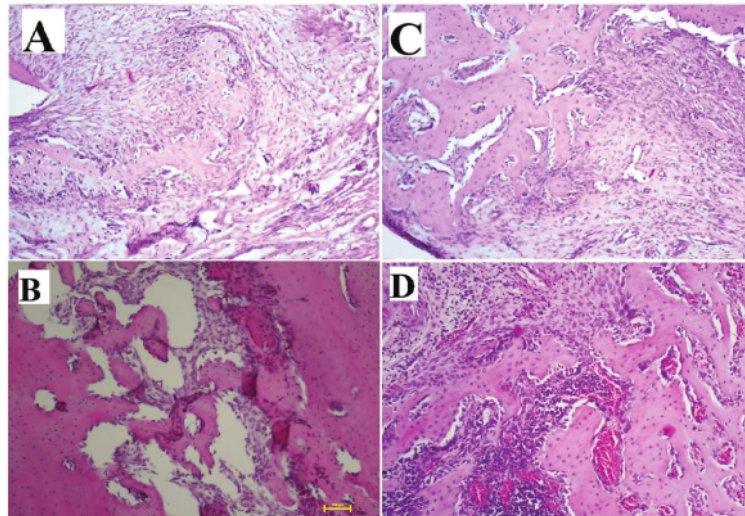


Figure 4: A. Expression of ALP in K14, B. Expression of ALP in K28, C. Expression of ALP in P14, D. Expression of ALP in P28.

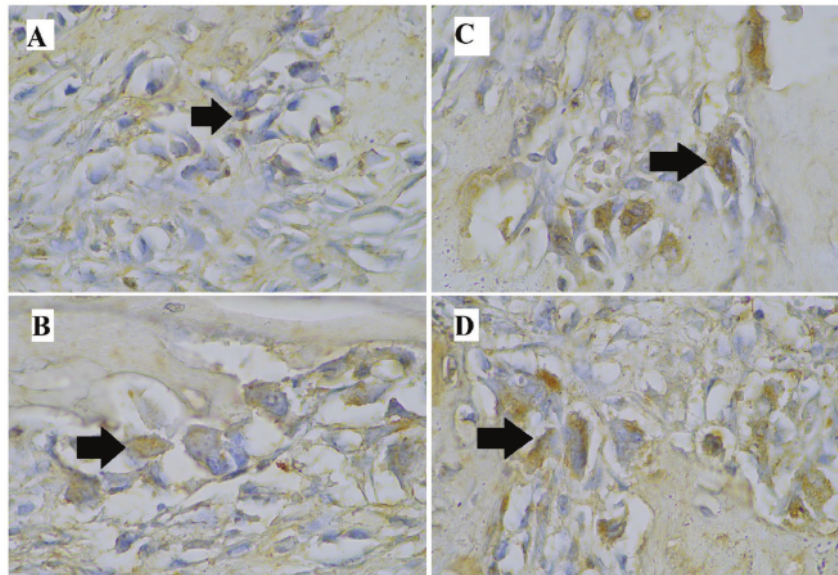
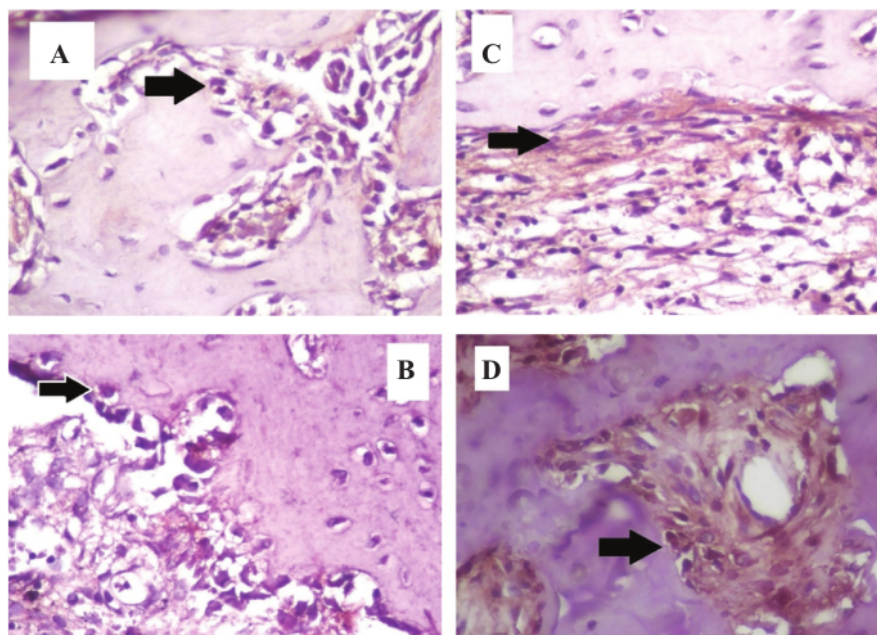


Figure 5: A. Expression of TGF- β 1 in K14, B. Expression of TGF- β 1 in K28, C. Expression of TGF- β 1 in P14, D. Expression of TGF- β 1 in P28.



Left mandibular alveolar bone preparation with IHC staining, viewed using a light microscope with 400 \times magnification. ALP expressed by osteoblasts is viewed, which will be seen as an irregular brown color in osteoblast cells that indicates the existence of alveolar bone regeneration process (Figure 4).

The left mandibular alveolar bone preparation was with IHC staining and viewed using a light microscope with 400 \times magnification. TGF β 1 expressed by osteoblasts was viewed, which will be seen as a diffused brown picture in osteoblast cells that indicates the existence of alveolar bone-regeneration process (Figure 5).

Data analysis began with the normality test of each data by using the Shapiro-Wilk test to determine the normality of the data. Shapiro-Wilk test in all the groups showed that $p > 0.05$, which indicates that all groups were normally distributed. After that, the homogeneity test of sample variation is done with the Levene Test to test the similarity of variance (homogeneous) of some samples. Homogeneity test results showed the value of $p > 0.05$ showing that the research data is homogeneous. The analysis test was conducted between treatment groups and control groups using the One-way Anova test with Post-Hoc Tukey HSD to determine differences between groups of samples.

One-way Anova test showed that significance equaled 0,000, which is smaller than 0,05 so that there are significant differences in the whole group. After that, the Post-Hoc Tukey HSD test was performed to see the significance of the trabecular bone area and the level of ALP and TGF- β 1 between the study groups. In the Post-Hoc Tukey HSD test, a value was considered to have a significant difference if $p < 0.05$. In the analysis of the research data, it was found that there were significant differences between the control group and the treatment group on the same observation day.

4. DISCUSSION

Tooth extraction is a traumatic procedure that can cause loss of alveolar bone. In general, soft tissue and hard tissue will experiencing trauma during tooth extraction. Trauma that occurs due to tooth extraction will have a natural healing process by going through the stages of the wound-healing process, which is basically divided into 3 stages: inflammation, proliferation, and remodeling. Bone-healing process after tooth extraction is generally the same as wound healing, but there is involvement of osteoblasts and osteoclasts [19].

Tooth extraction will be followed by the process of bone regeneration, which is a process of regrowth or recovery of lost/damaged bone to restore its previous architecture and function. Bone regeneration process will be followed by the process

of bone remodeling, a process that lasts a lifetime in which “old” bone is removed (bone resorption) and “new” bone is added (ossification or bone formation), which is considered a physiological renovation of the bone. There are three phases of bone remodeling: activation, resorption, and formation. In the formation phase, TGF- β 1 cytokines secreted by macrophage cells will initiate the proliferation and differentiation of osteoblast precursors into osteoblasts. TGF- β 1 and BMPs inside the bone matrix induce the main osteoblast transcription factor, Runx2, which is needed for the initiation of mesenchymal stem cell differentiation into osteoblasts [20]. TGF- β 1 will stimulate bone formation by increasing osteoblast proliferation in the early stages of differentiation, inhibiting the process of osteoblast apoptosis, recruiting osteoblast precursors to damage area with chemotactic attraction, and inhibiting hematopoietic precursor cell proliferation [9].

Osteoblasts will secrete TGF- β 1 and bone matrix proteins, such as collagen type 1 alpha 1 (COL1A1), osteocalcin (OC), and ALP [12]. ALP will break the phosphate bond and accelerate the occurrence of bone calcification. Therefore, ALP and TGF- β 1 can be good indicators in determining the rate of bone formation post tooth extraction [21]. Bone-regeneration process begins from the inflammatory stage, which occurs at around 1–3 days, which is characterized by the formation of a hematoma. This phase is like the defense phase of infection and functions like a bridge between damaged tissue and the growth of new cells, including osteoblasts and osteoclasts. Furthermore, there is a proliferation phase, which is characterized by the occurrence of epithelial and fibroblasts proliferation originating from the alveolar bone wall. After that, there is the reparative phase, which is development of reparative callus tissue in and around the location of the fracture that will be replaced by bone. Then, the remodeling phase is a gradual modification of the fracture area until the bone cortex reaches good stability, which is similar to the shape of the bone before the fracture. Bone regeneration uses the principle of osteogenesis, which is the transfer of bone-forming vital cells to the area where it will regenerate new cells. The healing process of trabecular bone is faster than compact bone [22]. An increase in trabecular area indicates the formation and mineralization of alveolar bones [14].

Minimizing excessive alveolar bone resorption can be done by socket preservation with hydroxyapatite derived from crab shell (*P. pelagicus*). The selection of male Wistar rats was done to avoid the hormonal influence in order to obtain homogeneity of the sample population. Also they are easily maintained and have a bone structure that is similar to humans so that these rats meet the criteria as experimental animals in research [23]. The result of this study proved that there was an increase in all three variables between the control group and the treatment group on the same day after application of the crab shell hydroxyapatite gel. In this study, hydroxyapatite gel is made from hydroxyapatite graft and carrageenan. The hydroxyapatite graft used was made from the crab shell of the *P. pelagicus*. *In vivo* research on the hydroxyapatite graft from the crab shell has not been carried out, but *in vitro* research has been carried out on human gingival fibroblast cell culture, and the results show that the hydroxyapatite graft has biocompatible properties against these cell [24]. The use of carrageenan aims to change the dosage form of hydroxyapatite graft into gel. Carrageenan hydrogels are biocompatible and thus can be further studied for their use in targeted biomedical applications [25].

The results showed a significant difference in TGF- β 1 expression between the control group and the treatment group given hydroxyapatite gel, both on day 14 and day 28. This happens because of the effect of hydroxyapatite gel in the treatment group. The porous hydroxyapatite mineral structure, which is interconnected and osteoconductive, will bind cytokines when bone damage occurs, and these cytokines will stimulate mesenchymal stem cells contained in pores of hydroxyapatite minerals to differentiate into osteoblasts, chondroblasts, and fibroblasts [26]. Osteoblasts and chondrocytes will produce TGF- β 1 during the healing process [11]. These cytokines play an important role in the process of differentiation and function of osteoblasts that are needed in the process of bone formation [27]. TGF- β 1 will stimulate bone formation by inducing differentiation from mesenchymal stem cells to osteoblasts. Osteoblasts will secrete TGF- β 1 during the proliferation stage, and then TGF- β 1 will again stimulate osteoblasts through the autocrine effect [11]. Level of ALP in the treatment group was higher than in the control group because hydroxyapatite has good quality of osteoconduction, osteoinduction, and osteointegration [28]. Hydroxyapatite gel in the socket will stimulate the release of cytokines from endothelial cells through inflammatory reactions. These cytokines stimulate mesenchymal cells to proliferate and differentiate to form osteoblasts [29]. Interconnected porous structure of hydroxyapatite forms a very strong bond between bones, accelerates the vascularization process, and facilitates osteoblast penetration, this structure is a good medium for osteoblast to attach to. The process of attaching osteoblasts to the surface of the bone graft matrix takes place slowly until the cells spread throughout the surface [5]. In the reparative/recovery phase, osteoblast cells will mature and carry out a matrix-formation process and then osteoblasts will secrete ALP for the mineralization process [30]. ALP will break the phosphate bond so that the phosphate ions and calcium ions will form calcium-phosphate bonds in the form of hydroxyapatite crystals, which eventually settle in the bone and accelerate the occurrence of bone calcification. Statistical analyses of the trabecular bone area on the 14th and 28th days showed a significant result in increasing post extraction trabecular bone socket. It shows that hydroxyapatite affects the process of bone regeneration. Hydroxyapatite ($\text{Ca}_{10}(\text{PO}_4)_6(\text{OH})_2$) can remineralize lost or damaged bone tissue without causing a rejection reaction by the body. Bioactive properties of hydroxyapatite can help bind them to bone tissue and provide specific biological responses that can stimulate osteoblast cells to produce new bone tissue so that it can help the process of bone regeneration [8, 31]. Analysis with SAA showed a hydroxyapatite surface area of 0.50 m²/g, a pore size of 123.20 nm, and a pore volume of 31.02 mm³/g. The analysis with SEM shows the hydroxyapatite morphology in the form of chunks with uniformly distributed pores and the result of the compressive test shows a hydroxyapatite compressive strength of 56.92 MPa [8]. Degradation of hydroxyapatite corresponds to the natural bone-degradation processes and suggests the possibility of complete resorption during bone remodeling [24].

5. CONCLUSION

12 In this study, it can be concluded that application of hydroxyapatite derived from crab shell (*P. pelagicus*) to the socket post extraction of Wistar rats increases TGF- β 1, ALP, and trabecular bone area.

Acknowledgement

No financial or material support.

Authors' Contributions

This work was carried out with the collaboration of all authors. MJJK was responsible for the experiment design, data analysis, literature search and preparation of the research report. BA, HL, and NH carried out the sample collection and literature search. ML, N, and TP performed statistical analysis. BA, HL, NH, ML, N, and TP contributed to research report and literature search work.

Conflict of Interest

None.

References

1. Kubilius M, Kubilius R, Gleiznys A. The preservation of alveolar bone ridge during tooth extraction. *Balt Dent Maxil J.* 2012; 14(1):3-11.
2. Kumar P, Vinita B, Fathima G. Bone grafts in dentistry. *J Pharm Bioallied Sci.* 2013; 5(1):125-27. doi:10.4103/0975-7406.113312
3. Barone A, Ricci M, Guirado CJ, Covani U. Bone remodelling after regenerative procedures around implants placed in fresh extraction sockets: an experimental study in Beagle dogs. *Clin Oral Implants Res.* 2011; 22(10):1131-37. doi:10.1111/j.1600-0501.2010.02084.x
4. Shakibaie MB. Comparison of the effectiveness of two different bone substitute materials for socket preservation after tooth extraction: a controlled clinical study. *Int J Periodontics Restorative Dent.* 2013; 33(2):223-28. doi:10.11607/prd.0734
5. Ardhiyanto HB. Stimulasi Osteoblas oleh Hidroksiapatit sebagai Material Bone Graft Pada Proses Penyembuhan Tulang. Thesis (2012), Jember University, Indonesia.
6. Sanabani AJ, Madfa SA, Sanabani FA. Application of calcium phosphate materials in dentistry. *Int J Biomater.* 2013. doi:10.1155/2013/876132
7. Raya I, Mayasari E, Yahya A, Syahrul M, Latunra Al. Synthesis and characterizations of calcium hydroxyapatite derived from crabs shells (*Portunus pelagicus*) and its potency in safeguard against to dental demineralizations. *Int J Biomater.* 2015; 2015(469176):1-8. doi:10.1155/2015/469176
8. Supangat D, Cahyaningrum SE. Sintesis dan Karakterisasi Hidroksiapatit dari Cangkrang Kepiting (*Scylla Serrata*) dengan Metode Pengendapan Basah. *UNESA J Chem.* 2017; 6(3):143-49.
9. Kasagi S, Chen W. TGF- β 1 on osteoimmunology and the bone component cells. *Cell Biosci.* 2013; 3(4):1-7. doi:10.1186/2045-3701-3-4
10. Chen E. Concentration-dependent, dual roles of IL-10 in the osteogenesis of human BMSCs via P38/MAPK and NF- κ B signaling pathways. *FASEB J.* 2018; 32:1-13. doi:10.1096/fj.201701256RRR
11. Sarahrudi K. Elevated transforming growth factor-beta 1 (TGF- β 1) levels in human fracture healing. *Injury.* 2011; 42(8):833-37. doi:10.1016/j.injury.2011.03.055
12. Rutkovskiy A, Stenslökken K, Vaage I. Osteoblast differentiation at a glance. *Med Sci Monit Basic Res.* 2016; 22:95-106. doi:10.12659/MSMBR.901142
13. Dietmar E, Saygili F. Cause of high bone alkaline phosphate. *J Mol Biol.* 2014; 21(2):194-97. doi:10.1080/13102818.2007.10817444
14. Naini A. Mekanisme Percepatan Regenerasi Tulang Alveolar antara Pemberian Scaffold Hydroxyapatite Gypsum Puger dengan Scaffold Hydroxyapatite Bovine sebagai Bahan Pengembangan Preservasi Soket Ridge Alveolar. Thesis (2019), Universitas Airlangga, Surabaya.
15. Kresna P. Innocencio. Biokompatibilitas Hidroksiapatit Graft dari Cangkrang Kepiting (*Portunus pelagicus*) yang Disterilisasi Sinar UV terhadap Kultur Sel Human Gingival Fibroblast. Thesis (2017), Universitas Airlangga, Surabaya.
16. Prasertiari B. Perbandingan Jumlah Fibroblas Pasca Implantasi Hidroksiapatit dan Hidroksiapatit-Chitosan pada Penyembuhan Pencabutan Gigi Marmut (*Cavia cobaya*). Thesis (2012), Universitas Airlangga, Surabaya.
17. Muntiha M. Teknik pembuatan preparat histopatologi dari jaringan hewan dengan pewarnaan hematoksin dan eosin (H&E). In "Proceeding of temu fungsional non peneliti conference", 2001, balai penelitian veteriner jalan R.E Martadinata 30, bogor, pp: 156-63.
18. Caplanis N, Lozada J, Mesquida J. Tooth extraction and site preservation. In "Principles and Practice of Single Implant and Restorations" (2014), pp: 87-106. doi:10.1016/B978-1-4557-4476-3.00006-8
19. Kenkre J, Bassett J. The bone remodelling cycle. *Ann Clin Biochem.* 2018; 55(3):308-27. doi:10.1177/0004563218759371
20. Millán J. Alkaline phosphatases. *Purinergic Signal.* 2016; 2(2):335-41. doi:10.1007/s11302-005-5435-6
21. Voss K, Montavon PM. Feline orthopedic surgery and musculoskeletal disease. In "Feline Orthopedic Surgery and Musculoskeletal Disease". (2009), pp: 129-52. doi:10.1016/B978-0-7020-2986-8.X0001-8
22. Manzoor M, Raza S. Proficient handling and restraint of the laboratory animal rat (*Rattus Norvegicus*) facilitate essential biochemical and molecular level studies in biomedical sciences. *IOSR J Pharm Biol Sci.* 2013; 6(2):21-33. e-ISSN: 2278-3008

23. Mahyudin, Rushadi F, Rantam D, Aulani'am AF. Regenerasi pada Massive Bone Defect dengan Bovine Hydroxyapatite sebagai Scaffold Mesenchymal Stem Cell (Regeneration of massive bone defect with bovine hydroxyapatite as scaffold of mesenchymal stem cells). *J Biosains Pascasarjana*. 2011; 13(3):179-95.
24. Zuo C. Osteoblastogenesis regulation signals in bone remodeling. *Osteoporos Int*. 2012; 23(6). doi:10.1007/s00198-012-1909-x
25. Kattimani V, Kondaka S, Lingamaneni K. Hydroxyapatite–Past, present, and future in bone regeneration. *Bone Tissue Regener Insights*. 2016; 7:9-19. doi:10.4137/BTRI.S36138
26. Barradas A, Yuan H, Blitterswijk CV, Habibovic P. Osteoinductive biomaterials: current knowledge of properties, experimental models and biological mechanisms. *Eur Cells Mater*. 2011; 21:407-29. doi:10.22203/ecm.v021a31
27. Cox G, Einhorn TA, Tzioupis C, Giannoudis PV. Bone-turnover markers in fracture healing. *J Bone Joint Surg*. 2010; 92(3):329-34. doi:10.1302/0301-620X.92B3
28. Pascawinata A. Perbandingan Proses Penyembuhan Tulang dengan Hidroksiapatit Mikrokristalin (Kajian pada Tulang Tibia Kelinci). *J Ked Gi*. 2013; 4(4): 236-41. ISSN 2086-0218
29. Rumpel. 2006. The biodegradation of hydroxyapatite bone graft substitutes *in vivo*. *Folia Morphol Warsz*. 65(1):43-48.
30. Popa EG. Evaluation of the *in vitro* and *in vivo* biocompatibility of carrageenan-based hydrogels. *J Biomed Mater Res Part A*. 2014; 102(11):4087-97.
31. Rakhmatia YD, Ayukawa Y, Furuhashi A, Koyano K. Carbonate apatite containing statin enhances bone formation in healing incisal extraction sockets in rats. *Materials*. 2018; 11(7):1201.

Effect of Socket Preservation Using Crab Shell-Based Hydroxyapatite in Wistar Rats

ORIGINALITY REPORT

16%

SIMILARITY INDEX

13%

INTERNET SOURCES

8%

PUBLICATIONS

0%

STUDENT PAPERS

PRIMARY SOURCES

| | | |
|---|---|----|
| 1 | repository.unair.ac.id Internet Source | 2% |
| 2 | jurnalmahasiswa.unesa.ac.id Internet Source | 1% |
| 3 | jurnal.pdgi.or.id Internet Source | 1% |
| 4 | merj.scholasticahq.com Internet Source | 1% |
| 5 | rabm.scholasticahq.com Internet Source | 1% |
| 6 | worldwidescience.org Internet Source | 1% |
| 7 | Yunia Rakhmatia, Yasunori Ayukawa, Akihiro Furuhashi, Kiyoshi Koyano. "Carbonate Apatite Containing Statin Enhances Bone Formation in Healing Incisal Extraction Sockets in Rats", Materials, 2018 Publication | 1% |

| | | |
|----|---|------|
| 8 | librarysearch.aut.ac.nz Internet Source | <1 % |
| 9 | www.ejobios.org Internet Source | <1 % |
| 10 | www.mdpi.com Internet Source | <1 % |
| 11 | A. Sjuhada Oki, N. Amalia, Tantiana. "Wound healing acceleration in inflammation phase of post-tooth extraction after aerobic and anaerobic exercise", Science & Sports, 2020 Publication | <1 % |
| 12 | hangtuah.ac.id Internet Source | <1 % |
| 13 | iopscience.iop.org Internet Source | <1 % |
| 14 | Scott A. Wilson, Lauren M. Cross, Charles W. Peak, Akhilesh K. Gaharwar. "Shear-Thinning and Thermo-Reversible Nanoengineered Inks for 3D Bioprinting", ACS Applied Materials & Interfaces, 2017 Publication | <1 % |
| 15 | docplayer.org Internet Source | <1 % |
| 16 | Juanmei Wang, Aimin Zhang, Yun Li, Jun Xu, Furong Huang, Menghua Zhao, Bufe Wu, Shaoru He. "Effect of intermittent hypoxia or | <1 % |

hyperoxia on lung development in preterm
rat neonates during constant oxygen
therapy", Journal of Cellular Biochemistry,
2019

Publication

17

iovs.arvojournals.org

Internet Source

<1 %

18

mafiadoc.com

Internet Source

<1 %

19

www.ablynx.com

Internet Source

<1 %

20

"Orthopedic Biomaterials", Springer Science
and Business Media LLC, 2017

Publication

<1 %

21

www.sicot-j.org

Internet Source

<1 %

22

ijbs.com

Internet Source

<1 %

23

benthamopen.com

Internet Source

<1 %

24

www.science.gov

Internet Source

<1 %

25

Deepak Bushan Raina, Alexandra Glencross,
Nadia Chaher, Yang Liu, Lars Lidgren, Hanna
Isaksson, Magnus Tagil. "Synthesis and
Characterization of a Biocomposite Bone

<1 %

Bandage for Controlled Delivery of Bone Active Drugs in Fracture Non-Unions", ACS Biomaterials Science & Engineering, 2020

Publication

26

Sun-Jung Yoon, Youngbum Yoo, Sang Nam, Hoon Hyun, Deok-Won Lee, Sewook Um, So Kim, Sung Hong, Dae Yang, Heung Chun. "The Cocktail Effect of BMP-2 and TGF- β 1 Loaded in Visible Light-Cured Glycol Chitosan Hydrogels for the Enhancement of Bone Formation in a Rat Tibial Defect Model", Marine Drugs, 2018

Publication

<1 %

27

fkg.unsyiah.ac.id

Internet Source

<1 %

28

Fabio Vignoletti, Mariano Sanz. "Immediate implants at fresh extraction sockets: from myth to reality", Periodontology 2000, 2014

Publication

<1 %

29

dspace.hangtuah.ac.id

Internet Source

<1 %

30

garuda.ristekbrin.go.id

Internet Source

<1 %

31

journals.lww.com

Internet Source

<1 %

32

smd.lt

Internet Source

<1 %

33

stemcellres.biomedcentral.com

Internet Source

<1 %

34

Phuong N. Dang, Samuel Herberg, Davood Varghai, Hooman Riazi et al. "Endochondral Ossification in Critical-Sized Bone Defects via Readily Implantable Scaffold-Free Stem Cell Constructs", STEM CELLS Translational Medicine, 2017

Publication

<1 %

35

Xian-Wei Li, Jie Du, Gao-Yun Hu, Chang-Ping Hu, Dai Li, Yuan-Jian Li, Xiao-Hui Li. "Fluorofenidone attenuates vascular remodeling in hypoxia-induced pulmonary hypertension of rats", Canadian Journal of Physiology and Pharmacology, 2014

Publication

<1 %

36

jeccr.biomedcentral.com

Internet Source

<1 %

Exclude quotes Off

Exclude matches < 7 words

Exclude bibliography On

Effect of Socket Preservation Using Crab Shell-Based Hydroxyapatite in Wistar Rats

GRADEMARK REPORT

FINAL GRADE

/0

GENERAL COMMENTS

Instructor

PAGE 1

PAGE 2

PAGE 3

PAGE 4

PAGE 5

PAGE 6

PAGE 7

PAGE 8

PAGE 9
