

Effect of Epigallocatechin-3-gallate (EGCG) on the number of macrophage cells in inflammation of pulp with mechanical injury

by Devi Eka Juniarti

Submission date: 04-Apr-2023 04:43PM (UTC+0800)

Submission ID: 2055488264

File name: rophage_cells_in_inflammation_of_pulp_with_mechanical_injury.pdf (530.74K)

Word count: 4122

Character count: 21877

Research Report

Effect of Epigallocatechin-3-gallate (EGCG) on the number of macrophage cells in inflammation of pulp with mechanical injury

Kun Ismiyatin¹, Devi Eka Juniarti¹, Djoko Agus Purwanto² and Adecha Ekalipta Primazafira¹

¹Department of Conservative Dentistry, Faculty of Dental Medicine, Universitas Airlangga,

²Department of Pharmaceutical Chemistry, Faculty of Pharmacy, Universitas Airlangga, Surabaya, Indonesia

ABSTRACT

Background: Pulpitis is an inflammatory pulp that can occur due to mechanical trauma that causes perforation of the pulp. Treatment of pulpitis Emergency frequently using Eugenol. High concentrations of Eugenol have a cytotoxic effect that causes local necrosis and inhibits the recovery process. An alternative consideration with Epigallocatechin 3-gallate (EGCG) which has good antioxidant properties and increases the complexity of inflammation by inhibiting the production of inducible nitric oxide synthase (iNOS) and nitric oxide so that levels migration of inflammatory cells to the area of injury will decrease and inflammation will occur shorter then initiates the proliferation so the recovery process and tissue repair will be more rapidly occurring. One of the cells that support tissue repair is macrophages. **Purpose:** this study aims to explain the effect of EGCG on the number of macrophage cells in pulp inflammation with mechanical injury. **Methods:** The study used 24 Wistar rats teeth divided into four groups, namely control (C), and 3 treatment groups T1, T2, and T3. Each group consisted of 6 rats prepared, then T1 was named EGCG hydrogel 60 ppm, T2 was given EGCG hydrogel 90 ppm, while T3 was given EGCG hydrogel 120 ppm. On the 3rd day, Wistar rats were decapitated to continue making HPA preparations. **Results:** This study showed a significant difference in each group ($p < 0.05$) using One-Way Anova analysis. **Conclusion:** EGCG hydrogel 90 ppm is effective in increasing the number of macrophage cells.

Keywords: epigallocatechin-3-gallate, hydrogels, macrophages, pulp inflammation.

Corresponding author : Kun Ismiyatin, Department of Conservative Dentistry, Faculty of Dental Medicine, Airlangga University, Jl. Mayjend Prof. Dr. Moestopo 47 Surabaya 60132, Indonesia. E-mail: kun-is@fkg.unair.ac.id.

INTRODUCTION

Pulpitis or inflammation of the pulp is experienced by many Indonesian people. Based on the results of basic health research in 2010 the prevalence of pulpitis in Indonesia is quite high. The number of pulpitis patients is approximately 160,000 within one year.¹ Based on the research of Al-Hisayat et al., (2006) showed that of 204 pulpitis teeth that had perforation, 90 teeth (44.1%) were due to mechanical trauma.²

Based on its clinical pathophysiology, pulpitis is divided into reversible pulpitis and irreversible pulpitis. Histopathologically, the pulpitis can be divided into acute and chronic pulpitis. Acute pulpitis occurs when inflammation first occurs in the pulp and has a characteristic sharp pain, whereas chronic pulpitis is pulpitis that has occurred repeatedly and has dull pain.³ Pulpitis is similar to inflammation of connective tissue in other parts of the body that causes pain where there are cells associated with inflammatory reactions namely polymorphonuclear leukocytes and mononuclear leukocytes including macrophages and lymphocytes.⁴

One of the inflammatory cells that play the most role in the inflammatory process is macrophages.⁵ In the inflammatory process, activated macrophages also have an important role as mononuclear phagocyte cells which are major in the phagocytic process of microorganisms and other foreign molecular complexes as inflammatory reactions. Macrophages have a long life span and remain in the area of inflammation which has the role of producing growth factors and tissue repair until the wound healing process is complete.⁶

In dentistry, materials from phenol groups such as eugenol are often used for emergency treatment of pulpitis by dealing with inflammation and pain that are temporary.⁷ However, eugenol has side effects including high concentrations of eugenol which can be cytotoxic which can cause local necrosis and inhibit the healing process.⁸ In addition, the pungent odor of eugenol at the dentist's office can increase the fear and anxiety of dentist care.⁹

The development of natural medicine technology from herbal plants is increasingly becoming a concern of scientists as an alternative medicine to be developed as an agent that can overcome oral and dental health problems,

one of which is pulpitis with minimal side effects.¹⁰ One of them is the content of flavonoids in a number of plants, especially green tea and several other tea plants.¹¹

Several studies have shown that EGCG is a polyphenol which is a flavonoid active compound that has good antioxidant properties and plays a role in shortening the duration of inflammation by inhibiting the production of inducible nitric oxide synthase (iNOS) and decreasing levels of Nitric Oxide so that inflammation cell inflammation to the area of injury will decrease and the inflammatory reaction will take place shorter then initiate the proliferation phase so that the healing process and tissue repair will occur more quickly. One of the cells that plays a role in tissue repair is macrophages which have a role in initiating the proliferative phase by secreting growth factors that will stimulate repair and healing.¹² In previous studies it was found that EGCG with the hydrogel dosage form has good biocompatibility and has the ability to regenerate pulp because it can induce the release of fibroblast growth factor-2 (FGF-2) and induce tissue regeneration.¹³

The study was conducted to explain the effect of EGCG as one of the polyphenol flavonoid compounds and determine the effectiveness of EGCG hydrogel in concentrations of 60 ppm, 90 ppm, 120 ppm on the number of macrophage cells that play a role in the healing process of pulpal inflammation with mechanical injury on day 3 in Wistar rats models.

MATERIALS AND METHODS

This research is an experimental laboratory with randomized post test only control group design. This study used a sample of 24 male Wistar (*Rattus norvegicus*) rats, body weight 200-300 grams, age 3 months. The material used in this study is EGCG hydrogel which is the result of extraction from green tea EGCG (Xi'An Rongsheng Biotechnology Co., Ltd., Shaanxi, China) dissolved with polyethylene glycol (PEG) hydrogel base (mixture of 80% PEG 400 (Schuchardt OHG, Germany) with 20% PEG 4000 (Sigma-Aldrich, St.Louis, USA) with 60 ppm, 90 ppm, and 120 ppm concentrations. EGCG hydrogel was applied topically to experimental animals. Trial animals were randomly divided into 4 groups, 1 control group of 6 rats each and 3 treatment groups of 6 rats each. This study was approved by the Ethics Commission of the Faculty of Dentistry, Airlangga University (Number: 411 / HRECC.FODM / VI / 2019).

Before cavity preparation, rats were anesthetized intramuscularly with 0.2 ml of a mixture of 0.5 ml of ketamine (Kepro B.V., Deventer, Holland) and 0.5 Xyla[®]xylazine (PT. Tekad Mandri Citra, Bandung, Indonesia). The maxillary first molar was prepared on the occlusal surface using a diamond round bur of 0.8 mm Edenta (Edenta[®] Corp, Switzerland) with depth to reach the pulp base (about 1.5 mm), followed by a sonde (Compact German Stainless Steel, Germany) until the perforation was marked by bleeding and performed checking with Inline[®] paper points (B.M Dentale S.A.S, Torno, Italy). EGCG hydrogel extract

was measured using a Acura[®]micropipette (Acura Manual 825, Socorex Isba Sa, Switzerland) then applied to the cavity base using a TPC[®]microbrush (TPCAdvances Tech. Inc, USA). In the treatment group 1,2, and 3 respectively EGCG hydrogel concentrations of 60 ppm, 90 ppm and 120 ppm were applied on the basis of the tooth cavity which had been prepared with a microbrush. Furthermore, the cavity was overtaken with a temporary lift Gold Label[®]Glass Ionomer Cement (GC Corp, Tokyo, Japan).²

On the 3rd day, the rats were decapitated and the jaws taken in the molar teeth were then fixed with Polysciences[®]10% buffered formalin (Polysciences Inc, US) and decalcified using RPI[®]10% EDTA (RPI Corp, USA) pH 7.4. Then preparations are made for histopathological examination under a microscope with Hematoxylin-Eosin (HE) staining. The preparation is seen under a microscope with 400x magnification and by placing the scale then counted macrophage cells using double blind technique.

Data on the number of macrophage cells from each group were tested for normality using data test Data on the number of macrophage cells in each group were tested for data normality using the Kolmogorov Smirnov test (one-sample K-S). Data is normally distributed if the p value (asymptotic sig.) > 0.05. Data that were normally distributed were carried out by Independent T-Test to determine the significance of the differences between the control and treatment groups, with a significance value (p < 0.05). Then the results of the treatment group research data were carried out homogeneity tests using the Levene's Test followed by the One-way ANOVA test to find out the distribution of the data. Data that were normally distributed were forwarded with Tukey HSD to determine differences between treatment groups, meaningful differences were marked by sig values smaller than 0.005 (p < 0.005).

RESULTS

The results of this laboratory experimental research are regarding the number of macrophage cells after the application of EGCG hydrogel. Macrophages with HE staining microscopically appear as round mononuclear cells with oval or kidney-shaped nuclei that are eccentric with a cytoplasm containing medium density. Data obtained from histopathological readings (HPA) shows the dominance of macrophage cells.

Table 1. Mean results and standard deviations in the number of macrophage cells in the control and treatment groups

Group	n	Mean and Standard Deviation ($\bar{x} \pm SD$)
C	6	5.33 ± 0.816
T1	6	7.33 ± 1.211
T2	6	11.16 ± 1.471
T3	6	11.83 ± 1.169

Notes: n = Number of samples; C = given injury without treatment; T1 = treated with 60 ppm EGCG hydrogel; T2 = treated with 90 ppm EGCG hydrogel; T3 = treated with 120 ppm EGCG hydrogel.

Table 2. Results of *Post Hoc Statistics Test for Tukey HSD Test* on macrophage cell count

	C	T1	T2	T3
C		0.040*	0.000*	0.000*
T1			0.000*	0.000*
T2				0.768
T3				

Note: (*): there are significant differences

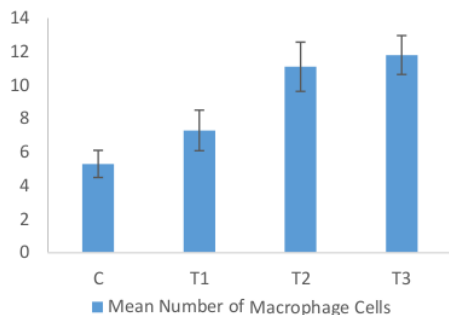


Figure 1. Graph of Average Number of Macrophage Cells in each group. C (Control): injury without treatment, T1 (Treatment 1): treated with EGCG hydrogel 60 ppm, T2 (Treatment 2): Treated with EGCG hydrogel 90 ppm, T3 (Treatment 3): Treated with EGCG hydrogel 120 ppm.

Based on Table 1, it appears that there are differences in mean macrophage cells in the control group and the treatment group. In the treatment group by giving EGCG hydrogels with concentrations of 60 ppm, 90 ppm, and 120 ppm can increase the number of macrophage cells. To clarify the number of macrophages for each group can be seen in Figure 1.

Kolmogorov Smirnov test results on the number of macrophage cells showed a significance value between the control and treatment groups that is equal to 0.894. This value is greater than the significance level (α) = 0.05 which means that the data on the number of se macrophages in each treatment are normally distributed.

Homogeneity test was continued using the *Levene's Test* obtained $p > 0.05$ which means homogeneous data. To see the differences between treatment groups, a *One-Way ANOVA* test was obtained, $p = 0,000$ ($p < 0.05$) which showed that there were significant differences between the concentration groups. Followed by the *Tukey HSD Post-Hoc Test* to find out each sample group.

Results showed statistically significant differences between the control group with treatment group 1, control group with treatment group 2, control control group with treatment group 3, treatment group 1 with treatment group 2, and treatment group 1 with treatment group 3.

DISCUSSION

The research conducted is an experimental laboratory study and aims to analyze the concentration of EGCG hydrogels that are effective in increasing the number of

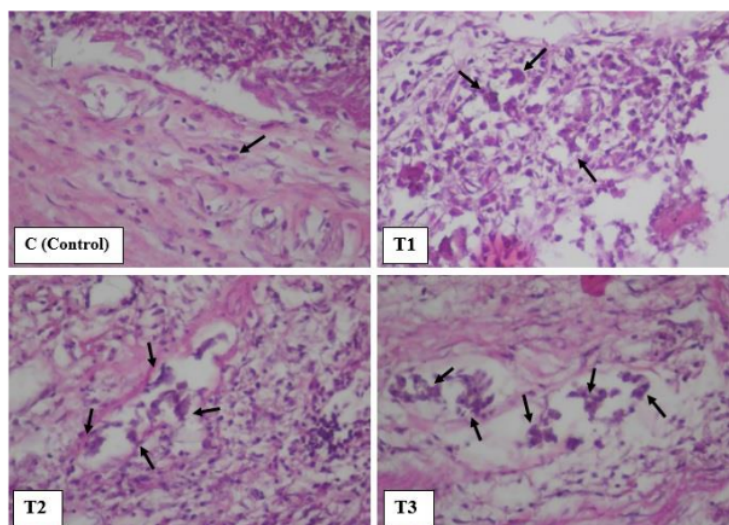


Figure 2. Histopathological picture of macrophage cells in each group. 400x magnification with 4 visual fields. Figure (C) is the distribution of macrophage cells (arrows) in the control group given injury without treatment on day 3; (T1) is the distribution of macrophage cells in the treatment group given EGCG hydrogel 60 ppm on day 3; (T2) treatment group with EGCG hydrogel 90 ppm on day 3; (T3) the treatment group with EGCG hydrogel 120 ppm on day 3.

macrophage cells from dental pulp tissue in inflammation of the *Wistar rat* tooth pulp. This research was carried out on the maxillary first molars of *Wistar rats* by preparation using a handpiece with a diamond bur of 0.8 mm Edenta (Edenta® Corp, Switzerland) and the cavity was irrigated with a sterile saline solution after which it was dried with a cotton pellet. Preparation is carried out until the dentinal tubules open with minimal damage until they reach the pulp roof and then evaluate the bleeding using aInLine® paper points (B.M Dentale S.A.S, Torno, Italy). The presence of blood indicates that the preparation has reached the roof of the pulp.¹⁴ Preparations were made to obtain perforations due to mechanical trauma and then topical extract of *epigallocatechin-3-gallate* (EGCG) was applied and a filling was carried out to avoid contamination of food. Consideration of selection of experimental animals of male *Wistar rats* (*Rattus norvegicus*) because the biological reaction of the healing process of pulp tissue is similar to human teeth and minimizes hormonal influences during treatment which can affect the results of research.¹⁵

Herbal plants are widely used in the development of natural medicine technology as an alternative medicine, one of which is green tea. EGCG is the main polyphenol and is found most widely in green tea and has a role as an antioxidant, anti-inflammatory and anti-atherogenic agent.¹⁶ EGCG is also included in flavonoids because it is a phenol derivative that is synthesized in a certain amount but widely distributed and has a role in wound healing.¹⁷ EGCG is rich in phenolic hydroxyl groups (OH) so it has many beneficial health activities.¹⁸

The purpose of the application of EGCG hydrogel is as an alternative to the use of eugenol in pulpitis emergencies with the function of overcoming inflammation and pain caused by mechanical trauma and the form of hydrogel preparation is chosen because of its ability to regulate drug release and protect the drug content from the external environment and has good spreadability.¹⁴ In this study using 98% pure EGCG extract in the form of white powder made in the form of hydrogel preparations with concentrations of 60 ppm, 90 ppm, 120 ppm.

High antioxidants in EGCG play a role in shortening the duration of inflammation by inhibiting the production of iNOS and decreasing NO levels and accelerating the initiation of the proliferation phase and the healing process and tissue repair. One of the cells that play a role in tissue repair is macrophages.¹² Macrophages which have anti-inflammatory properties act as markers that the initial (acute) inflammatory phase has been completed by passing apoptosis of PMN cells that have finished carrying out their duties in first-line defense in tissues affected by lesions. An important role of macrophages in the process of tissue healing is the production of growth factors needed to initiate the proliferation of fibroblast cells that play a role in the process of healing and tissue repair.¹⁹

Based on the results of group research on day 3 showed a difference between the control group (C) with the treatment (T1) given 60 ppm EGCG hydrogel. The data shows the mean number of macrophages at T1 is higher than the

control with the number of T1 = 7.3 and C = 5.3. The results of the research in groups T2 (EGCG 90 ppm) and T3 (EGCG 120 ppm) showed that the average number was higher than the control group and T1 with the average number T2 = 11.1 and T3 = 11.3. This proves that the application of EGCG hydrogels can increase the number of macrophage cells.

Increased macrophages can be observed on the 3rd day after treatment because on the 3rd day is the end of the inflammatory stage leading to the beginning of the fibroblastic stage and this is when active macrophages produce growth factors. A significant increase in the number of macrophage cells may be due to the application of EGCG extracts in the form of hydrogel preparations containing active compounds in the form of polyphenols in flavonoid content. Flavonoids have immunomodulatory capabilities that can increase IL-2 production. IL-2 stimulates the proliferation and differentiation of T cells into Th1 (*T helper 1*) which will affect SMAF (*Specific Macrophage Activating Factor*), such as multiple molecules including IFN- γ which can activate macrophages. Active macrophages function to carry out phagocytosis, repair cytokines, repair tissues and produce growth factors that are important in the process of tissue healing.¹⁷

Polyphenols in EGCG are also included in the active compounds of flavonoids that are radical scavenger and have good antioxidant properties and play a role in shortening the duration of inflammation by inhibiting the production of *inducible nitric oxide synthase* (iNOS) and reducing levels of *Nitrite Oxide* (NO) so that migration of inflammatory cells to the area of injury will decrease and the inflammatory reaction will be shorter.²⁰

According to the results of statistical tests, there were significant differences between the C (control) group and the T1 (EGCG 60 ppm) group, T2 (90 ppm EGCG) and T3 (120 ppm EGCG) group. There was a significant difference between group T1 (EGCG 60 ppm) with group T2 (EGCG 90 ppm) and group T1 (EGCG 60 ppm) and group T3 (EGCG 120 ppm). Meanwhile, there was no significant difference between the T2 group (90 ppm EGCG) and the T3 group (120 ppm EGCG).

Significant differences in the number of macrophages between the control and treatment groups indicate the effect of the administration of EGCG hydrogels. Significant differences between groups C (control) with groups T1 (EGCG 60 ppm), T2 (EGCG 90 ppm) and T3 (EGCG 120 ppm) indicate that there is an acceleration of activation and infiltration of macrophages in tissues affected by lesions in the treatment group given EGCG extract (hydrogel). With the increasing number of macrophages and the acceleration of macrophage infiltration, the radical scavenging process occurs quickly so that neutrophils are quickly replaced by macrophages and the acceleration of the inflammatory process that leads to healing and tissue repair.¹⁹

Significant differences between the control group and T1 (EGCG with 60 ppm) indicate that EGCG with a concentration of 60 ppm has a significant effect in increasing the number of macrophage cells. The insignificant difference in T2 and T3 groups is shown by the number of macrophages

in the two groups is almost the same. It was seen that the groups given EGCG hydrogels with concentrations of 90 and 120 ppm had the same effect in increasing the number of macrophages. This shows that EGCG hydrogel with a concentration of 60 ppm is effective in increasing the number of macrophages shown by the significance of the control while at concentrations 90 and 120 ppm have the same effectiveness range in increasing the number of macrophage cells indicated by the results of significance that are not significant.

The insignificant difference between the number of macrophage cells at concentrations of 90 ppm and 120 ppm is closely related to the antioxidant properties possessed by EGCG which can induce the process of autophagi. Several studies have shown that high concentrations of EGCG (100 µM) inhibit autophagi which leads to apoptosis in macrophage cell lines (Raw cells 264.7) and cancer cells. Conversely, low concentrations of EGCG (10 µM) induce autophagi which facilitates the degradation of damaged cells that lead to anti-inflammatory action and play a role in maintaining homeostasis in cell differentiation and tissue remodeling.²¹

This study proves that the extract of EGCG hydrogel has the benefit of increasing the number of macrophage cells on the 3rd day of inflammation of the pulp with mechanical injury by shortening inflammation and accelerating the proliferative process so that tissue repair quickly occurs so that inflammation is not sustainable which can lead to inflammation in pulp necrosis.

Research conducted at this time still has many shortcomings and certainty, among others, research conducted on male *Wistar rats* (*Rattus norvegicus*) with a limited amount. The dynamics of research ratios only apply between groups with different concentrations over a period of 3 days and do not explain the ratios between different time periods. In carrying out this study there are limitations to using only biomarkers at the cellular level in rat models, so the results of this study are unable to explain the facts about the molecular mechanisms involved in pulp inflammation with mechanical injury in *Wistar rats* models. The conclusion of this research is EGCG hydrogel with a concentration of 90 ppm effective and has a significant influence in increasing the number of macrophage cells in pulp inflammation with mechanical injury.

REFERENCES

- Riset Kesehatan Dasar Kementerian Kesehatan (Kemenkes). Jakarta: Badan Penelitian dan Pengembangan Kesehatan Depkes RI. 2013.
- Nirwana I. Aktivitas Ekstrak Buah Delima (*Punica granatum* linn) sebagai Material Pulp Capping Terhadap Ekspresi IL-6, IL-10, TGFβ-1 dan Kolagen Tipe 1 Pada Gigi Perforasi Mekanik. Surabaya: Universitas Airlangga; 2012.
- Giuroiu C, Căruntu I, Lozaneanu L, Melian A, Vataman M, Andrian S. Dental Pulp: Correspondences and Contradictions between Clinical and Histological Diagnosis. *BioMed Research International*. 2015;2015:1-7.
- Enggardipta R, Haniastuti T, Handajani J. Efek eugenol terhadap jumlah sel inflamasi pada pulpa gigi molar tikus Sprague Dawley. *Majalah Kedokteran Gigi Indonesia*. 2016;2(2):70.
- Ariel A, Maridonneau-Parini I, Rovere-Querini P, Levine J, Mühl H. Macrophages in inflammation and its resolution. *Frontiers in Immunology*. 2012;3:3.
- Ågren M. Wound healing biomaterials. 1st ed. Duxford: Woodhead Publishing is an imprint of Elsevier; 2016.
- Escobar-García M, Rodríguez-Contreras K, Ruiz-Rodríguez S, Piedant-Pérez M, Cerda-Cristerna B, Pozos-Guillén A. Eugenol Toxicity in Human Dental Pulp Fibroblasts of Primary Teeth. *Journal of Clinical Pediatric Dentistry*. 2016;40(4):312-318.
- Deshpande A, Verma S and Macwan C. Allergic Reaction Associated with the use of Eugenol Containing Dental Cement in a Young Child. *Austin J Dent*. 2014;1(2): 1007. ISSN:2381-9189.
- Toet A, Smeets M, van Dijk E, Dijkstra D, van den Reijen L. Effects of Pleasant Ambient Fragrances on Dental Fear: Comparing Apples and Oranges. *Chemosensory Perception*. 2010;3(3-4):182-189.
- Santoso H, Budiarti L, Carabelly A. . Perbandingan aktivitas antijamur ekstrak etanol jahe putih kecil (*Zingiber officinale* Var. *Amarum*) 30% dengan chlorhexidine glukonat 0,2% terhadap *Candida albicans* in vitro. *Dentino (JurKedGigi)*. 2014;2(2):126.
- Novita D. Karakterisasi Morfologi, Anatomi, dan Kandungan Fitokimia Tanaman *Handeleum (Graptophyllum pictum (L) Griff)*. Tesis. 2011. p.2
- Sherwood L. Fisiologi Manusia: dari sel ke sistem. Edisi 6. Jakarta:EGC 2011; p.450.
- Silna E, Krishnakumar K, Smitha K, Anoop Narayanan V, Dineshkumar B. Hydrogels In Topical Drug Delivery – A Review. *International Journal of Innovative Drug Discovery*. 2016;6(2):87.
- Ismiyatin K, Wahlyuo S, Purwanto DA, Rahayu RP, Soetojo A, Mukono IS. 'Effect of Topical Epigallocatechin-Gallate on Lipopolysaccharide-induced Pulpal Inflammation in Rat Models', *Iranian Endodontic Journal*. 2018; 13(4), 528–533
- Dammaschke T, Stratman U, Fisher RJ, Sagher E. Proliferation of rat molar pulp cells after direct pulp capping with dentine adhesive and calcium hydroxide, *Clinical Oral Investigations*. 2010; (5):559.
- Mereles D, Hunstein W. Epigallocatechin-3-gallate (EGCG) for Clinical Trials: More Pitfalls than Promises?. *International Journal of Molecular Sciences*. 2011; 12(9), pp.5592-5603
- Kurnia P, Ardhiyanto H, Suhartini. Potensi Ekstrak Teh Hijau (*Camellia sinensis*) Terhadap Peningkatan Jumlah Sel Fibroblas Socket Pasca Pencabutan Gigi paa Tikus Wistar. *e-Jurnal Pustaka Kesehatan*. 2015; 3(1), p.126.
- Shi M., Shi Y.-L., Li X.-M., Yang R., Cai Z.-Y., Li Q.-S., Ma S.-C., Ye J.-H., Lu J.-L., Liang Y.-R., et al. Food-Grade Encapsulation Systems for (–)-Epigallocatechin Gallate. *Molecules*. 2018. Vol;23 p. 445.
- Koh T, DiPietro, L. Inflammation and wound healing: The role of the macrophage. *NIH Public Access Author Manuscript*. 2013; 13(23), pp.3-5.
- Murray P, Wynn T. Protective and pathogenic functions of macrophages activation. *Nature Reviews Immunology*. 2011. Vol.11 No.11. pp723-737.
- Hashimoto K, Sakagami H. Induction of Apoptosis by Epigallocatechin Gallate and Autophagy Inhibitors in a Mouse Macrophage-like Cell Line. *Anticancer Research*. 2008; 28(1);p.1717

Effect of Epigallocatechin-3-gallate (EGCG) on the number of macrophage cells in inflammation of pulp with mechanical injury

ORIGINALITY REPORT

13%

SIMILARITY INDEX

11%

INTERNET SOURCES

7%

PUBLICATIONS

0%

STUDENT PAPERS

PRIMARY SOURCES

- 1 Albert J. Czaja. "Evolving paradigm of treatment for autoimmune hepatitis", *Expert Review of Clinical Immunology*, 2017
Publication 1%
- 2 repository.unair.ac.id
Internet Source 1%
- 3 Rena Setiana Primawati. "APPLICATION OF CPP-ACP REMINERALIZATION MATERIALS (TOOTH MOUSSE) ON SALIVA PH IN STUDENT", *The Incisor (Indonesian Journal of Care's in Oral Health)*, 2022
Publication 1%
- 4 seaninstitute.org
Internet Source 1%
- 5 www.spandidos-publications.com
Internet Source 1%
- 6 Hendri Busman, Sutyarso ., Salman Farisi, Yulianty .. "Regulation of Integrin β 3 Protein 1%

Secretion on Implantation Embryo of Mouse (Mus musculus L.) Induced by Oil Atsiri of Purple Nutsedge Tubers (Cyperus rotundus L.)", Annual Research & Review in Biology, 2019

Publication

7	Sri Wigati Mardi Mulyani, Eha Renwi Astuti, Otty Ratna Wahyuni, Diah Savitri Ernawati, Nastiti Faradilla Ramadhani. "Xerostomia Therapy Due to Ionized Radiation Using Preconditioned Bone Marrow-Derived Mesenchymal Stem Cells", European Journal of Dentistry, 2019	1 %
<hr/>		
8	idoc.pub Internet Source	1 %
<hr/>		
9	journals.lib.unb.ca Internet Source	1 %
<hr/>		
10	ppjp.ulm.ac.id Internet Source	1 %
<hr/>		
11	docplayer.net Internet Source	<1 %
<hr/>		
12	healthdocbox.com Internet Source	<1 %
<hr/>		
13	www.researchgate.net Internet Source	<1 %

14	www.intechopen.com Internet Source	<1 %
15	Katharina Spanel-Borowski, Albert M. Ricken. "Evidence for the maintenance of macrophage-like cells in long-term bovine granulosa cell cultures", Cell and Tissue Research, 1997 Publication	<1 %
16	oamjms.eu Internet Source	<1 %
17	repository.iainpurwokerto.ac.id Internet Source	<1 %
18	www.myfoodresearch.com Internet Source	<1 %
19	link.springer.com Internet Source	<1 %
20	pdfs.semanticscholar.org Internet Source	<1 %
21	www.research.manchester.ac.uk Internet Source	<1 %
22	teses.usp.br Internet Source	<1 %
23	www.diva-portal.org Internet Source	<1 %

24

jurnal.untan.ac.id

Internet Source

<1 %

25

uilis.unsyiah.ac.id

Internet Source

<1 %

26

www.slideshare.net

Internet Source

<1 %

Exclude quotes Off

Exclude matches < 10 words

Exclude bibliography On

Effect of Epigallocatechin-3-gallate (EGCG) on the number of macrophage cells in inflammation of pulp with mechanical injury

GRADEMARK REPORT

FINAL GRADE

/0

GENERAL COMMENTS

Instructor

PAGE 1

PAGE 2

PAGE 3

PAGE 4

PAGE 5
