

Tightening and Loosening of the Abutment Screw Negatively Affects Implant Osseointegration in the Early Healing Stage in Rat Tibiae

by Ratri Maya Sitalaksmi

Submission date: 06-Dec-2022 12:39PM (UTC+0800)

Submission ID: 1972869737

File name: t_Osseointegration_in_the_Early_Healing_Stage_in_Rate_Tibiae.pdf (310.36K)

Word count: 3280

Character count: 17174

Tightening and Loosening of the Abutment Screw Negatively Affects Implant Osseointegration in the Early Healing Stage in Rat Tibiae

Kenta Shobara, DDS, PhD⁴*

Toru Ogawa, DDS, PhD⁵

Division of Advanced Prosthetic Dentistry, Tohoku University Graduate School of Dentistry, Sendai, Japan.

Ratri M. Sitalaksmi, DDS, PhD

Division of Advanced Prosthetic Dentistry, Tohoku University Graduate School of Dentistry, Sendai, Japan; Department of Prosthodontics, Faculty of Dental Medicine, Universitas Airlangga, Surabaya, Indonesia.

Akiyo Ito, DDS

Makiko Miyashita, DDS, PhD

Aya Shibamoto, DDS, PhD

Keiichi Sasaki, DDS, PhD

Division of Advanced Prosthetic Dentistry, Tohoku University Graduate School of Dentistry, Sendai, Japan.

* The first and second authors contributed equally to this study.

Purpose: To examine the effect of tightening and loosening the dental implant screw on implant osseointegration in an elderly rat model. **Materials and Methods:** Titanium dental implants were inserted in the bilateral tibiae of 34 elderly Wistar rats (1 year and 3 months old). Rats were randomly divided into five groups: control (no loading); immediate loading (IL) (vertical load [3 Hz for 15 minutes/day] immediately after implantation); early loading (EL) (load started on postoperative day 7); five times abutment removal (R5) (tightening and loosening of the abutment screw once per day for 5 days each week); and two times abutment screw removal (R2) (tightening and loosening of the abutment screw once per day for 2 days each week). After 4 weeks, the rats were euthanized, and the bone structure surrounding the dental implants was evaluated using microcomputed tomography analysis. **Results:** Osseointegration failed more frequently in the EL, R2, and R5 groups than in the control and IL groups ($P = .06$). The EL, R2, and R5 groups also tended to have lower relative gray values than the control and IL groups. **Conclusion:** Tightening and loosening the abutment screw might negatively affect dental implant osseointegration in the early healing stage in older adults. *Int J Prosthodont* 2019 (5 pages). doi: 10.11607/ijp.6398

Dental implants are widely used as an established treatment method for defective prostheses. Dental implant treatment is considered successful if there is good osseointegration and stability.¹⁻³ Furthermore, the healing period after dental implant placement must be considered, including the timing of the application of loading on the implant. In clinical practice, immediate loading and early loading have recently been widely applied to improve patient quality of life by shortening the treatment period.⁴⁻⁶ Although this early loading protocol has not been evaluated in many long-term clinical studies, it is considered to be a viable treatment option with a high degree of clinical evidence.^{7,8} However, immediate and early loading protocols are not based on biologic evidence, and immediate or early loading is not recommended in certain conditions.^{9,10}

The mechanical loading conditions affect the osseointegration of the dental implant and the peri-implant bone structure.¹¹⁻¹³ Previous animal studies have used various experimental loading conditions in accordance with the target loading condition

Correspondence to:

Dr Toru Ogawa

Division of Advanced Prosthetic
Dentistry, Tohoku University
Graduate School of Dentistry
4-1 Seiryō-machi, Aoba-ku, Sendai,
Miyagi, 980-8575, Japan
Fax: +81 22 717 8371
Email: ogat-thk@umin.ac.jp

Submitted February 22, 2019;

accepted August 25, 2019.

©2020 by Quintessence

Publishing Co Inc.

doi: 10.11607/ijp.6398 1

and animal model, and so various loading devices have been used to evaluate the effect of experimental loading on the peri-implant bone response.^{14–17}

Various load types are applied to the dental implant after implantation, including forces during chewing, awake and sleep bruxism, and loads applied by the dentist during some steps of the implant treatment process in the clinic. After the dental implant is inserted, there are several stages in which the dentist must attach and detach implant parts that are fixed with screws—for example, screw tightening and loosening is performed during placement of a healing abutment, impression coping, provisional restoration and abutment, and final superstructure. The load applied during the tightening and loosening of the abutment screw might affect the osseointegration, as the mechanical stress is directly transferred between the dental implant surface and the peri-implant bone corresponding with the screw thread. The authors' hypothesis was that tightening and loosening the abutment screw during the treatment process after dental implant insertion would negatively affect the implant osseointegration.

To test the hypothesis, adverse conditions for osseointegration and bone healing were simulated by using a dental implant model in elderly rats. Two types of loading were applied: a mechanical vertical load, as occurs during daily functions (such as mastication), and a rotational load due to tightening and loosening of the abutment screw, as occurs during the dental implant treatment process in the clinic.

The aim of the present study was to determine the effects of the previously mentioned vertical and rotational loading conditions (simulating mastication and the treatment process, respectively) on dental implant osseointegration and peri-implant bone healing.

MATERIALS AND METHODS

The present study was carried out at the Institute for Animal Experimentation at Tohoku University Graduate School of Medicine under the approval of the Institutional Animal Care and Use Committee of the Tohoku University Environmental & Safety Committee (approval number 2015DnA-004-1).

Seventeen male Wistar rats were used in the present study. Elderly rats (1 year and 3 months old) were used to simulate unfavorable bone conditions. A straight-type pure titanium dental implant (SETiO Plus, GC) with a diameter of 3.0 mm and a length of 12 mm was inserted in both tibiae in each rat.

The surgery was performed under gas anesthesia (2.5% isoflurane) (Escain, Mylan) under aseptic conditions. A skin incision was made on the medial side of the tibia, and both cortices were perforated with a surgical drill at a low rotational speed under constant

saline cooling. The dental implant was inserted until the implant head was exposed by about 5 mm (Fig 1a). The implant was placed approximately 10 mm distal to the knee joint. The skin was closed with resorbable sutures, leaving the dental implant head protruding.

The experimental groups were randomly classified into the following five groups in accordance with the loading type and timing of the load application. A custom-made handheld device was used to apply a vertical load with a low frequency (3 Hz) to simulate mastication, while a rotational load was applied manually with dental instruments to simulate tightening and loosening of the abutment screw during the dental implant treatment process in the clinic.

The groups were as follows:

- Control group: No load (n = 8 implants)
- Immediate loading (IL) group: Vertical load applied immediately after implant insertion (n = 6 implants)
- Early loading (EL) group: Vertical load applied from the seventh day after implant insertion (n = 6 implants)
- Five times abutment removal (R5) group: Tightening and loosening of the abutment screw once daily for 5 days per week (n = 7 implants)
- Two times abutment removal (R2) group: Tightening and loosening of the abutment screw once daily for 2 days per week (n = 7 implants)

Under isoflurane inhalation anesthesia, the load in the IL and EL groups was applied with a custom-made loading apparatus (Fig 1b), which was used to apply a vertical load of 3 Hz with an amplitude of 5 mm for 15 minutes a day (simulating a chewing force). In the R5 and R2 groups, an abutment screw was tightened (approximately 5 N of torque) and loosened manually using dental instruments (Skill Driver Plus, Torque Wrench, GC) once daily five and two days per week, respectively. An abutment (Conical Abutment IN, height 1.3 mm, GC) was used to apply this rotational load (Fig 1c).

Four weeks after dental implant insertion, the rats were euthanized and the bone structure of the cortical bone surrounding the implant was evaluated with microcomputed tomography (microCT) (200 kV and 100 μ A, Scan Xmate-D225, Comscan Tecno) (Fig 1d). After three-dimensional reconstruction, a sagittal slice along the axis of the tibia and dental implant was selected for analysis (Fig 2). The region of interest was set as a 0.4 × 0.4-mm square in the peri-implant cortical bone. A relative gray (RG) value (where water = 0 and dental implant = 100) was calculated for the evaluation.¹⁵ Cases in which there was no bone around the dental implant and the implant was covered with soft tissue were defined as osseointegration failure.

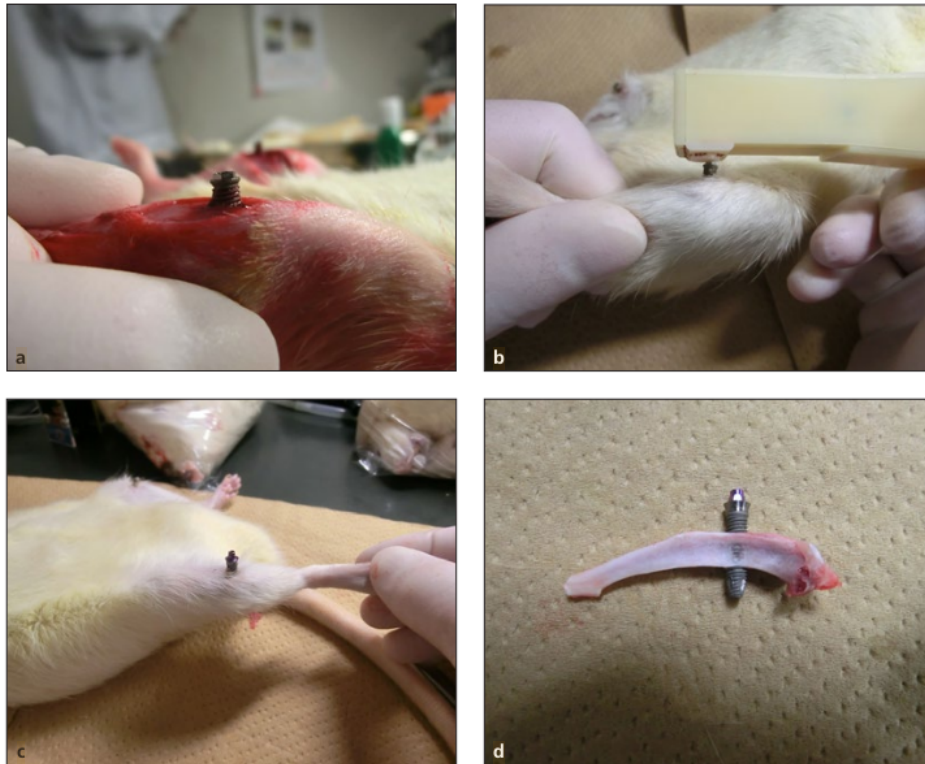


Fig 1 Photographs showing an example of a dental implant being inserted into a rat tibia. (a) The implant head is exposed by about 5 mm. (b) The custom-made loading apparatus used to apply a vertical load. (c) The abutment screw attached to the implant. (d) The tibia and implant retrieved after euthanasia of the animal.

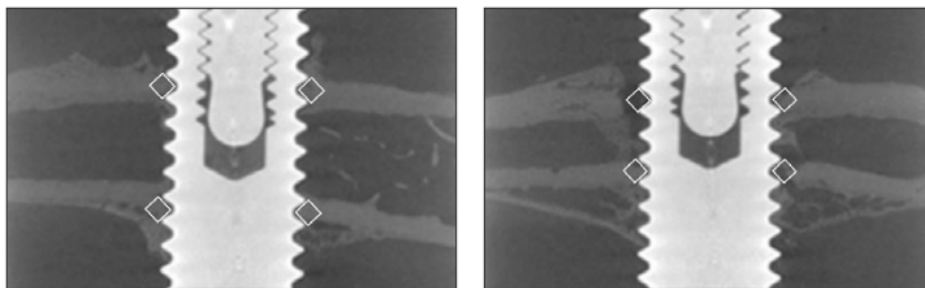


Fig 2 Representative microCT images used in the evaluation from the (a) control group and the (b) five times abutment removal group. The region of interest was set as a 0.4 × 0.4-mm square in the cortical bone adjacent to the implant surface.

8
Statistical analyses were conducted using SPSS 21.0 (IBM). Chi-square test was used to analyze the success or failure of dental implant osseointegration in each group. In addition, Kruskal-Wallis test and Dunn test were used to compare the RG values among groups in microCT image analysis. The significance level was set at $P < .05$.

RESULTS

Failure to osseointegrate occurred in 14 of 34 implantations. There was a marginally significant difference in the success/failure ratio of osseointegration between groups (chi-square test, $P = .06$) (Table 1).

Table 1 Number of Implants with Successful and Failed Implant Osseointegration in Each Group

Group	Control	IL	EL	R5	R2
Osseointegration	7	5	2	3	2
No osseointegration	1	1	4	4	5

C = control; IL = immediate loading; EL = early loading; R5 = five-times abutment removal; R2 = two-times abutment removal.

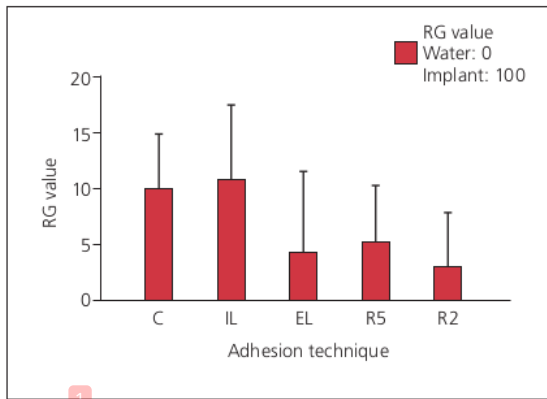


Fig 3 Relative gray (RG) values of the cortical bone around the implant in each group. C = control; IL = immediate loading; EL = early loading; R5 = five times abutment removal; R2 = two times abutment removal.

Figure 3 shows the RG values of the cortical bone around the dental implants. The RG value of the R2 group was significantly lower than that of the control group ($P < .05$). The EL, R2, and R5 groups tended to have lower RG values than the control and IL groups; however, these differences were not statistically significant.

DISCUSSION

The main reason for the high failure rate (14 of 34 dental implants) in the present study was considered to be the use of elderly rats (comparable to middle to older age in humans) as a model of adverse bone conditions. Therefore, although previous clinical research has reported a high success rate of dental implant treatment even in older adults,^{18–21} there may still be a high risk of osseointegration failure when the implant is applied in the compromised bone conditions that are common in older adults. These adverse bone conditions are due to less bone quantity and quality and a decrease in bone metabolism, such as happens in osteoporosis. However, a prospective cohort study investigating dental implant therapy in patients aged 60 years or older found that the dental implant success and survival rates in older

adults are comparable to those of the general population if the factors contributing to implant failure are controlled prior to implant placement.¹⁹

The present results indicate that tightening and loosening of the abutment screw (with force acting in the opposite direction to the dental implant thread) might adversely affect the success of osseointegration. The RG value of the R2 group was significantly lower than that of the control group, and the success/failure ratio of osseointegration in the R2 group was the lowest among all groups. These results suggest that the loading condition applied in the R2 group had a greater adverse effect on dental implant osseointegration than the loading conditions in the other groups. In daily clinical practice, the loading situation in the R2 group often occurs during the dental implant treatment process, such as during replacement of the cover screw with the healing screw, during impression of the provisional superstructure using impression coping, and during replacement of the provisional superstructure with the final superstructure.^{22,23} Although the present study used an adverse elderly rat model, care should be taken to minimize these loading conditions during the dental implant treatment process, especially in the early healing stage.^{10,11} Furthermore, extra care should be taken in patients with compromised bone, such as in older adult patients with osteoporosis. Since the RG value results assessed with microCT might be related to the bone remodeling response under a specific loading condition,^{10,14–17} further detailed investigation into the timing and frequency of the unfavorable loading is needed.

Although there was no significant difference between the EL and IL groups in the present study, both the success rate of dental implant osseointegration and the RG value of the EL group were relatively low compared to the IL group. This suggests that the timing of the loading may affect dental implant osseointegration.¹⁰ This seems to be related to the change in the stability of the dental implant during the time from the initial fixation immediately after implantation to the establishment of secondary fixation from the dip; that is, there may be a risk of overloading near the dip. If the stability decreases below a critical level during the healing process, a functionally loaded dental implant becomes unstable and fails.²

CONCLUSIONS

To preserve the osseointegration and stability of the dental implant, dentists should pay attention to the load being applied during the attachment and detachment of the abutment screw in the early stage of peri-implant bone healing, as it might adversely affect the implant osseointegration, particularly in older adults.



ACKNOWLEDGMENTS

The authors thank Kelly Zammit, BVSc, from Edanz Group (www.edanzediting.com/ac) for editing a draft of this manuscript. This study was partially supported by a Grant-in-Aid for Scientific Research (C) from the Ministry of Education, Culture, Sports, Science and Technology, Japan (grant numbers 15K11148 and 16K11581). The authors have no conflicts of interest related to this study.

REFERENCES

- Rao PL, Gill A. Primary stability: The password of implant integration. *J Dent Implants* 2012;2:103–109.
- Simunek A, Kopecka D, Brazda T, Strnad I, Capek L, Slezak R. Development of implant stability during early healing of immediately loaded implants. *Int J Oral Maxillofac Implants* 2012;27:619–627.
- Javed F, Ahmed HB, Crespi R, Romanos GE. Role of primary stability for successful osseointegration of dental implants: Factors of influence and evaluation. *Interv Med Appl Sci* 2013;5:162–167.
- Chrcanovic BR, Albrektsson T, Wennerberg A. Immediate nonfunctional versus immediate functional loading and dental implant failure rates: A systemic review and meta-analysis. *J Dent* 2014;42:1052–1059.
- Singh JP, Gupta AK, Dhiman RK, Roy Chowdhury SK. Comparative study of immediate functional loading and immediate non-functional loading of monocortical implants. *Med J Armed Forces India* 2015;71(suppl 2):s333–s339.
- Barone A, Covani U, Cornelini R, Gherlone E. Radiographic bone density around immediately loaded oral implants. *Clin Oral Implants Res* 2003;14:610–615.
- Xu L, Wang X, Zhang Q, Yang W, Zhu W, Zhao K. Immediate versus early loading of flapless placed dental implants: A systematic review. *J Prosthet Dent* 2014;112:760–769.
- Romanos G, Froum S, Hery C, Cho SC, Tarnow D. Survival rate of immediately vs delayed loaded implants: Analysis of the current literature. *J Oral Implantol* 2010;36:315–324.
- Su M, Shi B, Zhu Y, et al. Comparison of implant success rates with different loading protocols: A meta-analysis. *Int J Oral Maxillofac Implants* 2014;29:344–352.
- Yamamoto M, Ogawa T, Yokoyama M, Koyama S, Sasaki K. Influence of immediate and early loading on bone metabolic activity around dental implants in rat tibiae. *Clin Oral Implants Res* 2014;25:1084–1090.
- Isidor F. Influence of forces on peri-implant bone. *Clin Oral Implants Res* 2006;17(suppl 2):s8–s18.
- Naert I, Duyck J, Vandamme K. Occlusal overload and bone/implant loss. *Clin Oral Implants Res* 2012;23(suppl):s95–s107.
- Yoda N, Zheng K, Chen J, et al. Bone morphological effects on post-implantation remodeling of maxillary anterior buccal bone: A clinical and biomechanical study. *J Prosthodont Res* 2017;61:393–402.
- Ogawa T, Zhang X, Naert I, et al. The effect of whole-body vibration on peri-implant bone healing in rats. *Clin Oral Implants Res* 2011;22:302–307.
- Shibamoto A, Ogawa T, Duyck J, Vandamme K, Naert I, Sasaki K. Effect of high-frequency loading and parathyroid hormone administration on peri-implant bone healing and osseointegration. *Int J Oral Sci* 2018;10:6.
- Yamamoto M, Ogawa T, Yokoyama M, et al. Na¹⁸F accumulates on the compressive side of peri-implant bone under immediate loading. *Odontology* 2018;106:232–237.
- Wang S, Ogawa T, Zheng S, et al. The effect of low-magnitude high-frequency loading on peri-implant bone healing and implant osseointegration in Beagle dogs. *J Prosthodont Res* 2018;62:497–502.
- Esposito M, Ardebili Y, Worthington HV. Interventions for replacing missing teeth: Different types of dental implants. *Cochrane Database Syst Rev* 2014;(7):CD003815.
- Compton SM, Clark D, Chan S, Kuc I, Wubie BA, Levin L. Dental implants in the elderly population: A long-term follow-up. *Int J Oral Maxillofac Implants* 2017;32:164–170.
- Srinivasan M, Meyer S, Mombelli A, Müller F. Dental implants in the elderly population: A systematic review and meta-analysis. *Clin Oral Implants Res* 2017;28:920–930.
- Jemt T. Implant failures and age at the time of surgery: A retrospective study on implant treatment in 2,915 partially edentulous jaws. *Clin Implant Dent Relat Res* 2019;21:686–692.
- Koutouzis T, Koutouzis G, Gadalla H, Neiva R. The effect of healing abutment reconnection and disconnection on soft and hard peri-implant tissues: A short-term randomized controlled clinical trial. *Int J Oral Maxillofac Implants* 2013;28:807–814.
- Palaska I, Tsaousoglou P, Vouros I, Konstantinidis A, Menexes G. Influence of placement depth and abutment connection pattern on bone remodeling around 1-stage implants: A prospective randomized controlled clinical trial. *Clin Oral Implants Res* 2016;27:e47–e56.

Tightening and Loosening of the Abutment Screw Negatively Affects Implant Osseointegration in the Early Healing Stage in Rate Tibiae

ORIGINALITY REPORT

19%

SIMILARITY INDEX

15%

INTERNET SOURCES

18%

PUBLICATIONS

3%

STUDENT PAPERS

PRIMARY SOURCES

- 1 www.nature.com 3%
Internet Source
- 2 Miou Yamamoto, Toru Ogawa, Masayoshi Yokoyama, Shigeto Koyama, Keiichi Sasaki. "Influence of immediate and early loading on bone metabolic activity around dental implants in rat tibiae", *Clinical Oral Implants Research*, 2014 1%
Publication
- 3 complete.bioone.org 1%
Internet Source
- 4 Jingyu Qi, Makiko Miyashita, Toru Ogawa, Hideki Naito, Keiichi Sasaki. "Resonance frequency analysis for evaluation of the connecting condition between fixed prostheses and their abutment teeth: An invitro and finite element analysis study", *The Journal of Prosthetic Dentistry*, 2022 1%
Publication

5	T. OGAWA. "Functional properties and regional differences of human masseter motor units related to three-dimensional bite force", <i>Journal of Oral Rehabilitation</i> , 10/2006 Publication	1 %
6	lirias.kuleuven.be Internet Source	1 %
7	www.mdpi.com Internet Source	1 %
8	Aya Shibamoto, Toru Ogawa, Joke Duyck, Katleen Vandamme, Ignace Naert, Keiichi Sasaki. "Effect of high-frequency loading and parathyroid hormone administration on peri-implant bone healing and osseointegration", <i>International Journal of Oral Science</i> , 2018 Publication	1 %
9	www.j3.jstage.jst.go.jp Internet Source	1 %
10	Yoshinori Shimamoto, Hirotsugu Maruyama, Natsumi Maeda, Taku Manabe et al. "EP1155: THE USEFULNESS OF AN INFLAMMATION-BASED SCORE IN MALIGNANT TRANSFORMATION OF IPMNS", <i>Gastroenterology</i> , 2022 Publication	1 %
11	Shuhua Wang, Toru Ogawa, Sheng Zheng, Makiko Miyashita, Taichi Tenkumo, Zhiyuan	1 %

Gu, Wenhai Lian, Keiichi Sasaki. "The effect of low-magnitude high-frequency loading on peri-implant bone healing and implant osseointegration in Beagle dogs", Journal of Prosthodontic Research, 2018

Publication

12

www.researchsquare.com

Internet Source

1 %

13

Liang, Yong-Qiang, Meng-Chun Qi, Jiang Xu, Juan Xu, Hua-Wei Liu, Wei Dong, Jin-Yuan Li, and Min Hu. "Low-magnitude high-frequency loading, by whole-body vibration, accelerates early implant osseointegration in ovariectomized rats", Molecular Medicine Reports, 2014.

Publication

<1 %

14

ar.iarjournals.org

Internet Source

<1 %

15

vbn.aau.dk

Internet Source

<1 %

16

Miou Yamamoto, Toru Ogawa, Masayoshi Yokoyama, Yoshihito Funaki et al. "Na¹⁸F accumulates on the compressive side of peri-implant bone under immediate loading", Odontology, 2017

Publication

<1 %

17	Xiaolei Zhang, Antonia Torcasio, Katleen Vandamme, Toru Ogawa, G. Harry van Lenthe, Ignace Naert, Joke Duyck. "Enhancement of Implant Osseointegration by High-Frequency Low-Magnitude Loading", PLoS ONE, 2012 Publication	<1 %
18	"Atlas of Immediate Dental Implant Loading", Springer Science and Business Media LLC, 2019 Publication	<1 %
19	issuu.com Internet Source	<1 %
20	onlinelibrary.wiley.com Internet Source	<1 %
21	acikerisim.baskent.edu.tr Internet Source	<1 %
22	head-face-med.biomedcentral.com Internet Source	<1 %
23	mau.diva-portal.org Internet Source	<1 %
24	open.library.ubc.ca Internet Source	<1 %
25	uilis.unsyiah.ac.id Internet Source	<1 %

26

Wei Zhao, Yi Tang, Yang Yang, Min Wang, Haiyang Yu. "Low-Magnitude, High-Frequency Vibration Promotes Osteogenic Differentiation via Intensifying miRNA-335-5p Expression", Journal of Environmental Pathology, Toxicology and Oncology, 2019

Publication

<1 %

27

Yoshiki Ikeda, Tomoka Hasegawa, Tomomaya Yamamoto, Paulo Henrique Luiz de Freitas et al. "Histochemical examination on the peri-implant bone with early occlusal loading after the immediate placement into extraction sockets", Histochemistry and Cell Biology, 2018

Publication

<1 %

28

docksci.com

Internet Source

<1 %

29

www.karger.com

Internet Source

<1 %

30

Balkaya, Mehmet Cudi. "Investigation of Influence of Different Implant Size and Placement on Stress Distribution With 3-Dimensional Finite Element Analysis :", Implant Dentistry, 2014.

Publication

<1 %

Exclude quotes Off

Exclude matches Off

Exclude bibliography On

Tightening and Loosening of the Abutment Screw Negatively Affects Implant Osseointegration in the Early Healing Stage in Rate Tibiae

GRADEMARK REPORT

FINAL GRADE

/0

GENERAL COMMENTS

Instructor

PAGE 1

PAGE 2

PAGE 3

PAGE 4

PAGE 5
