



Journal of Prosthodontic Research

Official Journal of Japan Prosthodontic Society



Review article

Effectiveness of the Socket Shield Technique in Dental Implant: A Systematic Review

Toru Ogawa^{a,b,1*}, Ratri M. Sitalaksmi^{b,c,1}, Makiko Miyashita^b, Kenji Maekawa^{a,d}, Masahiro Ryu^{a,c}, Aya Kimura-Ono^{a,d}, Takeshi Suganuma^{a,f}, Takeshi Kikutani^{a,g}, Masanori Fujisawa^{a,h}, Katsushi Tamaki^{a,i}, Takuo Kuboki^{a,d}

^a Research Planning and Promotion Committee, Japan Prosthodontic Society

^b Division of Advanced Prosthetic Dentistry, Tohoku University Graduate School of Dentistry, Sendai, Japan

^c Department of Prosthodontics, Faculty of Dental Medicine, Universitas Airlangga, Surabaya, Indonesia

^d Department of Oral Rehabilitation and Regenerative Medicine, Okayama University Graduate School of Medicine, Dentistry and Pharmaceutical Sciences, Okayama, Japan

^e Department of Removable Prosthodontics and Gerodontology, Tokyo Dental College, Tokyo, Japan

^f Department of Special Needs Dentistry, Division of Temporomandibular Disorders and Orofacial Pain, Showa University School of Dentistry, Tokyo, Japan

^g Division of Rehabilitation for Speech and Swallowing Disorders, the Nippon Dental University, Tama Oral Rehabilitation Clinic, Tokyo, Japan

^h Division of Fixed Prosthodontics, Department of Restorative & Biomaterials Sciences, Meikai University School of Dentistry, Sakado, Japan

ⁱ Department of Prosthodontic Dentistry for Function of TMJ and Occlusion, Kanagawa Dental University, Yokosuka, Kanagawa, Japan

Abstract

Purpose: Dental implant therapy is a common clinical treatment for missing teeth. However, the esthetic result is not as satisfactory as expected in some cases, especially in the anterior maxillary area. Poor esthetic results are caused by inadequate preparation of the hard and soft tissues in this area before treatment. The socket shield technique may be an alternative for a desirable esthetic outcome in dental implant treatments.

Study selection: In the present systematic review, PubMed-Medline, Google Scholar, and ScienceDirect were searched for clinical studies published from January 2000 to December 2018.

Results: Twenty studies were included, comprising one randomized controlled trial, two cohort studies, 14 clinical human case reports, and three retrospective case series. In total, 288 patients treated with the socket shield technique with immediate implant placement and follow-up between 3–60 months after placement were included. A quality assessment showed that 12 of the 20 included studies were of good quality. Twenty-six of the 274 (9.5%) cases developed complications or adverse effects related to the socket shield technique. Most studies reported implant survival without the complications (90.5%); most of the cases that were followed up for more than 12 months after implant placement achieved a good esthetic appearance. The failure rate was low without the complications, although there were some failures due to failed implant osseointegration, socket shield mobility and infection, socket shield exposure, socket shield migration, and apical root resorption.

Conclusions: The socket shield technique can be used in dental implant treatment, but it remains difficult to predict the long-term success of this technique until high-quality evidence becomes available.

Keywords: Dental implants, Socket shield technique, Alveolar ridge preservation, Root submergence technique

Received 22 April 2020, Accepted 16 October 2020, Available online 9 March 2021

1. Introduction

Dental implant therapy is currently a common treatment option for patients with missing teeth because of its overall good treatment outcome. After implant placement, attention must be paid to not only the establishment of osseointegration but also the esthetics of the surrounding area, particularly the anterior maxillary area. The implant is usually placed after tooth extraction; this action changes the contour of the hard and soft

tissue in the surrounding area and the pontic area[1–3]. Regarding hard tissue, there is more alveolar ridge resorption on the buccal aspect than on the lingual aspect; therefore, alveolar bone support is required to achieve esthetically pleasing soft tissue contours[2,4]. To achieve a natural appearance of emergence of the prosthesis, it is necessary to attain sufficient hard and soft tissue dimensions via the socket preservation technique or alveolar ridge preservation.

Alveolar ridge preservation is a procedure that emerged in the mid-1980s and is used to preserve ridge volume by placing the graft material in a tooth socket after extraction, with or without the application of a barrier membrane or soft tissue. This preservation procedure is often used in dental practice owing to its conceptual attractiveness and technical simplicity with continuous evaluation[5–7]; multiple studies have evaluated the efficacy of this procedure[7]. Alveolar ridge preservation can be achieved with three types of grafts: soft tissue, hard tissue, or a combination of soft and hard tissue[5]. Biomaterials have also been used for grafting; these include autogenous, allogeneic, xenogeneic, and alloplastic bone grafts,

* Corresponding author at: Division of Advanced Prosthetic Dentistry, Tohoku University Graduate School of Dentistry, 4-1 Seiryomachi, Aoba-ku, Sendai, Miyagi, 980-8575, Japan.

E-mail address: ogat-thk@umin.ac.jp, toru.ogawa.d7@tohoku.ac.jp (T. Ogawa).

¹ The first and second authors contributed equally.

and other materials such as platelet-rich plasma, platelet-rich fibrin, bone morphogenetic protein, Emdogain, and cell therapy[6,7].

Alveolar ridge preservation varies depending on the procedure or material used. In guided bone regeneration, a barrier membrane is used to direct the growth of new bone and gingival tissue for better esthetic appeal or prosthetic restoration. In connective tissue grafting, connective tissue is used as the graft. The technique in which only part of the root is extracted is called partial extraction therapy, this comprises the socket shield and pontic shield techniques. The present review discusses the socket shield technique of the partial extraction therapy.

The root submergence technique was developed to preserve the alveolar ridge and soft tissue of the oral cavity, and its use has increased recently for prosthesis implantation. This technique is usually used in the anterior maxillary region, which requires consideration from an esthetic viewpoint. The root submergence technique was first introduced in 1953 and continued to be developed until the socket shield technique that enabled immediate implant placement was introduced in 2007. In 2015, this technique was combined with socket grafting to preserve the ridge at the pontic site[8]. The socket shield technique was first described by Hürzeler et al.[9] in 2010, and the evidence regarding this technique was systematically reviewed by Ghapure et al.[1] in 2017. Since then, a lot of new evidence regarding the socket shield technique has been published. Therefore, we performed an updated systematic review that included newly available evidence.

The partial extraction therapy aims to prevent the resorption of alveolar bone after tooth extraction; herein the buccal fragment of the tooth is preserved to prevent buccal cortical bone resorption[8]. The socket shield technique combined with immediate implant placement has the potential to preserve the natural appearance, and is considered minimally invasive because it does not require flap elevation or second-stage surgery, a periosteal-releasing incision, or the additional use of autogenous bone chips and a barrier membrane[2,10]. Several studies have reported modifications of this procedure to attain superior results[1,2,11].

Some of the cases included in the present review developed complications, such as infection, socket shield exposure, and migration, causing implant failure; however, these failures did not occur because of the procedure itself[11]. One study reported failure of the socket shield technique caused by tooth fragment luxation or movement[12]. On the other hand, another study reported a decrease in the failure rate of the socket shield technique by the use of 3D imaging/CBCT in the planning stage[8]. Buccal resorption is prevented by a shield comprising a crescent-shaped root with 1-mm thickness in the buccal area, while this approach is less invasive for the patient, the technique requires significant surgical skill[2]. Overall, there is still a lack of consensus regarding the long-term and esthetic outcomes of the socket shield technique.

The aim of the present systematic review was to systematically analyze the literature to understand the viability of the socket shield technique and to draw conclusions about its clinical outcome. The primary objective was to determine whether the socket shield technique achieves long-term clinical success in implant treatment. The secondary objective was to determine whether the socket shield technique improves the esthetics of the anterior area in fixed dental prosthesis treatment.

2. Material and Methods

This systematic literature review was conducted in accordance with the Preferred Reporting Items for Systematic reviews and Meta-Analyses guidelines. To prepare and structure this review, the focused question was elaborated using the population, intervention, comparison, and outcome (PICO) format, as detailed below.

Population: Subjects with immediate implant placement in the maxilla or mandible using the socket shield technique, with follow-up after implant placement.

Intervention or exposure: Dental implant therapy using the socket shield technique.

Comparison: Other implant placement methods not using the socket shield technique.

Outcome: Survival of the implant and adverse effects of the socket

shield technique.

2.1. Focused question (PICO)

Is there a difference in implant survival, esthetic result, and complications between immediate implant placement using the socket shield technique and immediate implant placement without using this technique?

2.2. Information sources and search protocol

An electronic search was performed to identify relevant studies. PubMed-Medline, Google Scholar, and ScienceDirect were searched for studies published in English from January 2000 to December 2018. This literature review was conducted in accordance with PRISMA guidelines. The search terms were “root submergence technique,” “socket shield technique,” “dental implant,” and “immediate implant” in various combinations. The reference lists of similar or recommended articles were also manually searched.

2.3. Inclusion and exclusion criteria

Studies were included if they met the following criteria: (1) case report, case control, cohort study, retrospective case series, randomized controlled trial (2) use of the socket shield principle, and (3) implant immediately placed after tooth extraction. Exclusion criteria were: (1) follow-up of less than 3 months after implant placement, and (2) animal experiments.

2.4. Screening and selection of articles

Two of the review authors (OT and SR) assessed the title, abstract, and full-text availability of all studies identified in the electronic search. Articles were included based on the title and abstract and the inclusion and exclusion criteria. All articles were independently assessed for relevance, eligibility, data extraction, quality assessment, and risk of bias.

2.5. Assessment of complications and adverse effects

For clinical studies, the outcomes assessed were implant osseointegration, shield exposure, shield mobility, shield infection, shield migration, and soft tissue contour. The radiologic outcome was buccal/crestal bone loss. The included studies were analyzed for complications and adverse effects reported by their respective authors. Data tables, radiographs, and clinical images presented in these studies were also analyzed to identify overlooked/missed complications.

2.6. Data collection process

Predefined data collection spreadsheets were used for the assessment of each article. Collected data included the author’s names, publication year, sample size, time and area of implant placement, loading protocol, complications and adverse effects, and follow-up duration. Evaluations were carried out independently by two reviewers (OT and SR) and confirmed by consensus.

2.7. Quality assessment of individual studies

The quality of each included study was assessed by two independent evaluators (OT and SR), and any potential disagreements were resolved by consensus. The included studies were evaluated using the “Checklist for Case Reports, Case Series, Cohort Studies and Randomized Controlled Trials, in the Joanna Briggs Institute (JBI) Critical Appraisal tools” (<http://joannabriggs-webdev.org/research/critical-appraisal-tools.html>). To assess the quality of the studies, the included studies were rated using the checklist for each article type. Based on the overall appraisal, the studies were classified as good (total score more than 66.7%), moderate (total score 33.4–66.6%), and poor (total score less than 33.3%).

2.8. Data synthesis for meta-analysis

The heterogeneity of the data was assessed to determine whether a meta-analysis could be performed. The level of agreement between the reviewers regarding relevant factors in the studies was determined using kappa statistics. Data were analyzed using SPSS software (SPSS Statistics for Windows, version 23.0; IBM Corp., Armonk, NY).

3. Results

The initial search strategy using various combinations of keywords retrieved 209 articles (Fig. 1). The titles, abstracts, and full-text availability of all articles were screened, and duplicate articles were removed. Articles published in languages other than English were discarded. After screening, 39 articles remained. Full-text versions of these 39 articles were assessed for eligibility. Of these, 19 articles were excluded; two articles described the socket shield technique but did not include any follow-up after implant placement; two articles described the socket shield technique but did not use the tooth root as the shield; five articles described the socket shield technique in a step-by-step manner; eight articles described the root submergence technique; two articles were literature reviews.

3.1. Study characteristics and outcomes

A total of 20 studies were included in the present systematic review. Regarding the distribution of the available literature in accordance with the hierarchy of evidence, one was a randomized controlled trial (RCT) [22], two were cohort studies [13,17], 14 were clinical human case reports [2,9,12,14-16,18-21,23-26], and three were retrospective case series [11,27,28]. Details of the studies are provided in Table 1.

Overall, 248 of the 274 implants exhibited clinical success without complications or adverse effects during follow-up. Immediate implant placement was performed with the socket shield technique using the root fragment; except for a few cases, most of the implants were installed in the anterior region of the maxilla. The reported complications and adverse effects are listed in Table 2. The most common complication or adverse effect of the socket shield technique was shield internal exposure (46%), followed by failure of implant osseointegration (19%), shield external exposure (15%), shield mobility and infection (12%), shield migration (4%), and apical root resorption (4%). Most of the complications and adverse effects occurred within 12 months postoperatively, and most were successfully resolved [11]. Exposure of the shield through the soft tissue occurred because the remaining tooth had sharp edges [8], while infection was caused by tooth debris from the extraction or preparation procedures making contact with the implant surface [29]. Therefore, to avoid or decrease the occurrence of complications in the socket shield technique, clinicians should choose a healthy remaining root with no evidence of pathology [14].

Most of the studies are articles that are relatively low in the evidence hierarchy, such as case reports and case series without a control group. However, one RCT compared a socket shield technique group with a control group and reported the esthetic outcome of the technique [22]. In this RCT, the mean horizontal and vertical bone loss values in the socket shield technique group were significantly lower than those in the conventional implantation group after 7 months of follow-up, and all 20 cases had no postoperative complications [22].

3.2. Quality assessment of individual studies

The quality assessment performed using the JBI Critical Appraisal tools indicated that 12 articles were classified as good quality (one RCT, two cohort studies, two retrospective case series, and seven case reports), eight were classified as moderate (one retrospective case series, and seven case reports), and none were classified as poor (Table 1).

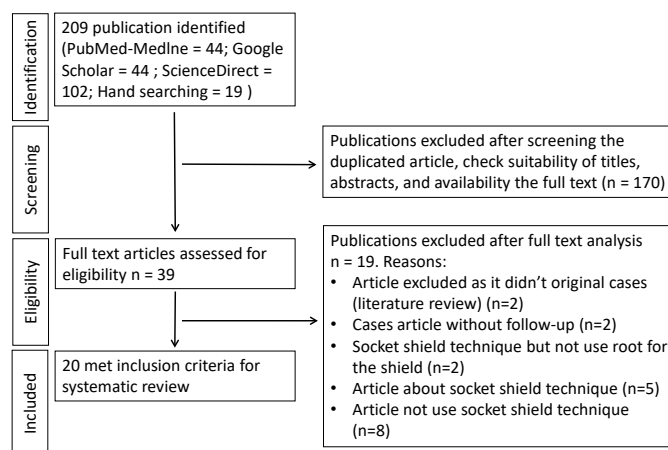


Fig. 1. Flowchart of the study design.

3.3. Data synthesis for meta-analysis

A meta-analysis could not be performed due to the absence of homogeneity among the studies and the absence of randomized controlled trials. However, a percentage-wise statistical distribution of complications and adverse effects was performed (Table 2). Kappa statistics showed a high level of agreement between the reviewers (> 0.80).

4. Discussion

Implant placement in the esthetic zone is very challenging, and the results are affected by the placement timing, topography of the alveolar socket, soft and hard tissue dimensions, surgeon skill level, implant position and design, and patient behavior [2]. Therefore, to reduce the failure rate of the socket shield technique, it is important to know the indications and contraindications that determine which roots can be used. The indications for the socket shield technique are the presence of vertical fractures, an unrestorable tooth or a tooth requiring extraction, immediate implant placement, and ridge preservation specifically to prevent buccal-palatal collapse and to preserve the papillae or soft tissue around the implant [30-33]. Contraindications for the socket shield technique are remaining roots with pulp or apical pathologies, periodontal disease, and traumatic occlusion [8,30,32].

Most of the included articles reported that the socket shield technique achieved good esthetic results; the longest follow-up period was approximately 5 years after implantation, and the socket shield technique achieved very satisfactory results [27,28]. Of the 20 included articles, only one reported complications or adverse effects of the socket shield technique [11]. In that study [11], if the implant failed to osseointegrate, the clinicians checked whether the socket shield was still intact. If the shield was still intact, the implant was replaced; if it was not intact, it was removed and the implant was replaced. Of the five cases with implant osseointegration failure, the socket shield was still intact in two cases, while the socket shield had to be removed in three cases [11]. In the three cases with infection, the socket shield had to be removed and the implant was replaced [11]; this method of infection treatment was also used in another study [8]. To avoid infection, clinicians must ensure that there is no remaining root debris after extraction [29]. Furthermore, prevention of contamination and maintenance of the periodontal tissue during wound healing are important in achieving osseointegration [34]. In the 12 cases of shield internal exposure, eight were managed with no treatment (only observation), while four had the exposed root portion reduced with a diamond bur. In the four cases of external shield exposure, the coronal aspect of all shields was reduced to enable soft tissue closure; two of these cases required additional connective tissue graft augmentation to assist with soft tissue healing. To avoid shield exposure, the socket shield must be free of sharp edges, as this may result in shield exposure through the

Table 1. Details of the included studies that evaluated the socket shield technique.

No.	Authors (year)	Sample Size	Time of Implant Placement	Area of Implant Placement	Implant Loading Protocol	Complications and Adverse Effects	Quality assessment	Follow-up after implant placement
1	Hurzeler et al. ⁹ (2010)	1 implant	Immediate	Mandibula the third and fourth pre-molar	Immediate	None	Moderate	6 months
2	Kan et al. ¹⁴ (2013)	1 implant	Immediate	Maxillary right central incisor	Immediate	None	Good	12 months
3	Al-Dary ²³ (2013)	1 implant	Immediate	Maxillary single rooted teeth	Immediate	None	Moderate	5 months
4	Siompas et al. ^{28*} (2014)	46 implants	Immediate	Maxillary anterior region	Immediate	1 case of apical root resorption	Moderate	24–60 months (median 40 months)
5	Troiano et al. ¹⁸ (2014)	10 implants	Immediate	Maxillary and mandibula anterior region	Delayed by 3 months	None	Moderate	6 months
6	Baumer et al. ¹⁶ (2015)	1 implant	Immediate	Mandibula the third and fourth pre-molar	Delayed by 6 months	None Mean labial loss of 0.88 mm from before the implant bed preparation to the placement of the final restoration was considered acceptable in this case	Moderate	> 5 months
7	Gluckman et al. ¹⁹ (2015)	1 implant	Immediate	Maxillary central incisor	Immediate	None	Good	12 months
8	Al-Dary ²⁴ (2015)	1 implant	Immediate	Maxillary premolar	Delayed by 4 months	None	Moderate	4 months
9	Baumer et al. ^{27*} (2017)	10 implants	Immediate	Maxillary first premolar	Delayed by 5 months	None -mean loss of buccal tissue -0.37 mm (range -0.66 to -0.16 mm) [^] -average mid-facial recession -0.33 mm [^] -mean loss of mesial marginal bone 0.33 mm, distal 0.17 mm	Good	51–63 months (mean 58 months)
10	Roe et al. ¹⁵ (2017)	1 implant	Immediate	Maxillary right central incisor	Immediate	None	Good	24 months
11	Barakat et al. ^{22*} (2017)	10 implants	Immediate	Maxillary single rooted teeth	Delayed by 4 months	None -Mean probing depth 1.73 mm (control 2.12 mm) -Horizontal bone loss 0.1 mm (control 0.34 mm) -Vertical bone loss 0.44 mm (control 1.61 mm)	Good	7 months
12	Aslan et al. ² (2018)	1 implant	Immediate	Maxillary right central incisor	Immediate	None	Moderate	12 months
13	Gluckman et al. ^{11*} (2018)	128 implants	Immediate	Maxillary and mandibular anterior and premolar region	N/A	-5 cases of implant osseointegration failure -3 cases of socket shield mobility and infection -12 cases of socket shield internal exposure -4 cases of socket shield external exposure -1 case of socket shield migration	Good	≥ 12 months (range 1–4 years)
14	Pardo et al. ¹² (2018)	1 implant	Immediate	Maxillary lateral incisor	Delayed by 3 months	None	Moderate	6 months
15	Hinze et al. ^{13*} (2018)	17 implants	Immediate	Maxillary anterior and premolar region	Immediate	None -soft tissue (buccal) contour changes -0.07 mm (range -0.37 to 0.32 mm) [^] -level of gingival margin 0.17 mm (range -0.84 to 1.58 mm) [^]	Good	3 months
16	Han et al. ^{17*} (2018)	40 implants	Immediate	Maxillary and mandibular anterior region	Immediate	None	Good	12 months
17	Dohiem et al. ²⁰ (2018)	1 implant	Immediate	Maxillary canine	Delayed by 4 months	None	Good	24 months

Table 1. (Continued)

No.	Authors (year)	Sample Size	Time of Implant Placement	Area of Implant Placement	Implant Loading Protocol	Complications and Adverse Effects	Quality assessment	Follow-up after implant placement
18	Walid ²¹ (2018)	1 implant	Immediate	Maxillary first premolar	Delayed by 6 months	None (average 3 deviation analysis was minimal) -Volumetric alveolar bone changes (-0.052 mm) [^] - -5.07% volume loss in the coronal zone [^] - -2.45% volume gain in the middle zone [^] - -1.44% volume gain in the apical zone [^] -Volumetric ridge contour changes (-0.122 mm) [^] - -27.05% volume loss in the coronal zone [^] - -6% volume loss in the middle zone [^] - -3.8% volume loss in the apical zone [^]	Good	6 months
19	Guo et al. ²⁵ (2018)	1 implant	Immediate	Maxillary central incisor	Delayed by 6 months	None	Good	24 months
20	Mattar ²⁶ (2018)	1 implant	Immediate	Maxillary lateral incisor	Delayed by 6 months	None	Good	24 months

*prospective cohort study, +retrospective case series, #RCT study.

[^]this value was obtained by comparing measurements before and after surgery.

Table 2. Frequency and percentage distribution of the complications and adverse effects of the socket shield technique.

Complications and Adverse Effects	Reported Cases, n (%)
Of the 274 included cases in which the socket shield technique was used, the total incidence of complications and adverse effects was 9.5% (26 of 274 cases).	
- Implant osseointegration failure at 1–4 months postoperatively	5 (19%)
- Socket shield mobility and infection at 1 month postoperatively	3 (12%)
- Socket shield internal exposures at 3–9 months postoperatively	12 (46%)
- Socket shield externally exposed at 1–12 months postoperatively	4 (15%)
- Socket shield migration at 9 months postoperatively	1 (4%)
- apical root resorption at 24 months postoperatively	1 (4%)

soft tissues[8]. In cases with shield migration, the implant was restored without reduction of the socket shield. Mattar[26] addressed the issue of shield migration, including the prediction of this complication and the suggested treatment.

The main outcome measures for the socket shield technique were implant survival, biological complications, and prosthetic complications[17]; these measures can be divided into those detected via clinical and radiographic examination (CBCT)[28]. The implant is said to have “survived” if it is still present and functional at 1 year after placement[17]; however, nine of the 20 included articles had a follow-up period of less than 1 year. Therefore, implant survival after using the socket shield technique needs further investigation in studies with a follow-up of longer than 1 year, as one article reported that bone loss in the implant area occurred more than 10 years after implantation with the socket shield technique[35]. Reported biological and prosthetic complications include postoperative pain or swelling, mobilization of the shield or implant, peri-implantitis, marginal bone loss, and shield resorption[17,28].

It is difficult to conclude that the socket shield technique enhances the esthetic outcome, as most of the studies are case reports or case series with no control group for comparison. However, one RCT (good quality) had a control group[22]. This RCT reported that the socket shield technique appears to be a safe technique with which to preserve alveolar bone, as the horizontal and vertical bone loss was significantly decreased compared with conventional implantation. Thus, the socket shield technique is a minimally invasive approach with good esthetic outcomes[22].

5. Limitations of this systematic review

Thirteen articles included in the present review were case reports of only one patient each[2,9,12,14–16,19–21,23–26]. Therefore, case selection bias is likely to have occurred, where the authors may have only presented cases with successful outcomes. Nine of the included case reports had a short follow-up of < 12 months[9,12,13,16,18,21–24], which does not enable the complete evaluation of failures and complications of the socket shield technique. Thus, there is a high possibility that the number of complications, adverse effects, and failures is under-reported. In addition, most of the included articles showed very promising results within 1 year postoperatively, which suggests that the socket shield procedure might be a sensitive technique that requires surgical expertise[1,2]. Furthermore, the articles included in the present review only provide descriptive assessments of cases and are limited in their interpretation of results, determination of prognosis, and extrapolation of findings. Thus, there is a possibility of operator bias and under-reported complications in individual articles. Although there is a lack of research-based evidence regarding the socket shield technique, within the limitations of the current review, this technique can be considered a possible treatment option to improve the stability and esthetics of the implant and preserve the remaining soft and hard tissues.

6. Conclusion

The present review of the available literature suggests that there is a need for more evidence supporting the use of the socket shield technique. The failure rate of the socket shield technique is low, although failures such as failed implant osseointegration, socket shield mobility and infection, socket shield exposure, socket shield migration, and apical root resorption have been reported. The socket shield technique is minimally invasive and requires substantial surgical skill. This technique can be used in dental implant treatment; however, it is still difficult to predict its long-term success until high-quality evidence becomes available. Case reports of the socket shield technique with short follow-up durations are insufficient for the determination of long-term clinical prognosis. Future studies with a higher LOE, such as randomized controlled trials and well-designed prospective cohort studies, are required to fully establish the biologic plausibility and clinical success of the socket shield technique.

References

- [1] Gharpure AS, Bhatavadekar NB. Current evidence on the socket-shield technique: a systematic review. *J Oral Implantol* 2017;43:395–403.
- [2] Aslan S. Improved volume and contour stability with thin socket-shield preparation in immediate implant placement and provisionalization in the esthetic zone. *Int J Esthet Dent* 2018;13:172–83.
- [3] Wong KM, Chneh CM, Ang CW. Modified root submergence technique for multiple implant-supported maxillary anterior restorations in a patient with thin gingival biotype: a clinical report. *J Prosthet Dent* 2012;107:349–52.
- [4] Salama M, Ishikawa T, Salama H, Funato A, Garber D. Advantages of the root submergence technique for pontic site development in esthetic implant therapy. *Int J Periodontics Restor Dent* 2007;27:521–27.
- [5] Jung RE, Ioannidis A, Hämmerle CHF, Thoma DS. Alveolar ridge preservation in the esthetic zone. *Periodontol* 2000;77:165–75.
- [6] Maiorana C, Poli PP, Deflorian M, Testori T, Mandelli F, Nagursky H, et al. Alveolar socket preservation with demineralised bovine bone mineral and a collagen matrix. *J Periodontal Implant Sci* 2017;47:194–210.
- [7] Avila-Ortiz G, Elangovan S, Kramer KWO, Blanchette D, Dawson DV. Effect of alveolar ridge preservation after tooth extraction: a systematic review and meta-analysis. *J Dent Res* 2014;93:950–8.
- [8] Gluckman H, Salama M, Du Toit J. Partial extraction therapies (PET) part 2: procedures and technical aspects. *Int. J. Periodontics Restorative Dent.* 37, 377–85 (2017).
- [9] Hürzeler MB, Zühr O, Schupbach P, Rebele SF, Emmanouilidis N, Fickl S. The socket-shield technique: a proof-of-principle report. *J Clin Periodontol* 2010;37:855–62.
- [10] Mattiola A, Bosshardt D, Schminlin PR. The rigid-shield technique: a new contour and clot stabilizing method for ridge preservation. *Dent J* 2018;6:E21.
- [11] Gluckman H, Salama M, Du Toit J. A retrospective evaluation of 128 socket-shield cases in the esthetic zone and posterior sites: partial extraction therapy with up to 4 years follow-up. *Clin Implant Dent Relat Res* 2018;20:122–9.
- [12] Esteve-Pardo G, Esteve-Colomina L. Clinical application of the socket-shield concept in multiple anterior teeth. *Case Rep Dent* 2018;2018:9014372.
- [13] Hinze M, Janousch R, Goldhahn S, Schlee M. Volumetric alterations around single-tooth implants using the socket-shield technique: preliminary results of a prospective case series. *Int J Esthet Dent* 2018;13:146–70.
- [14] Kan JY, Rungcharassaeng K. Proximal socket shield for interimplant papilla preservation in the esthetic zone. *Int J Periodontics Restor Dent* 2013;33:e24–31.
- [15] Roe P, Kan JYK, Rungcharassaeng K. Residual root preparation for socket-shield procedures: a facial window approach. *Int J Esthet Dent* 2017;12:324–35.
- [16] Bäumer D, Zühr O, Rebele S, Schneider D, Schupbach P, Hürzeler M. The socket-shield technique: first histological, clinical, and volumetric observations after separation of the buccal tooth segment - a pilot study. *Clin Implant Dent Relat Res* 2015;17:71–82.
- [17] Han CH, Park KB, Mangano FG. The modified socket shield technique. *J Craniofac Surg* 2018;29:2247–54.
- [18] Troiano M, Benincasa M, Sánchez P, Guirado JLC. Bundle bone preservation with Root-T-Belt: a case study. *Ann. Oral Maxillofacial Surgery* 2014;2:7.
- [19] Gluckman H, Du Toit J, Salama M. The socket-shield technique to support the buccofacial tissues at immediate implant placement. *Int Dent - African Ed* 2015;5:6–14.
- [20] Dohiem M, Abd el nabi N. Immediate implant placement in canine region using root membrane technique with follow up 2 years case report. *Futur Dent J* 2018;4:43–6.
- [21] Abdullatif Walid M. 3-dimensional volumetric analysis of double socket-shield for maximum tissue preservation at immediate implant replacement of multi-rooted teeth, a case report. *Int J Dent Sci Res* 2018;6:58–66.
- [22] Barakat DA, Hassan RS, Eldibany RM. Evaluation of the socket shield technique for immediate implantation. *Alexandria Dent J* 2017;42:155–61.
- [23] Al-Dary HH. The socket shield technique: a case report. *Smile Dent J* 2013;8:32–6.
- [24] Al-Dary H, Al-Hadidi A. The socket shield technique using bone trephine: a case report. *Int J Dent Oral Sci* 2015;1–5.
- [25] Guo T, Nie R, Xin X, Wang H, Qi M, Yu K, et al. Tissue preservation through socket-shield technique and platelet-rich fibrin in immediate implant placement: a case report. *Medicine (Baltimore)* 2018;97:e13175.
- [26] Mattar AA. Socket shield technique with immediate implant placement to preserve thin buccal bone: A case report. *Int J Dent Oral Heal* 2018;4:117–22.
- [27] Bäumer D, Zühr O, Rebele S, Hürzeler M. Socket shield technique for immediate implant placement – clinical, radiographic and volumetric data after 5 years. *Clin Oral Implants Res* 2017;28:1450–8.
- [28] Siormpas KD, Mitsias ME, Kotsiotou-Siormpa E, Garber D, Kotsakis GA. Immediate implant placement in the esthetic zone utilizing the “root-membrane” technique: clinical results up to 5 years postloading. *Int J Oral Maxillofac Implants* 2014;29:1397–405.
- [29] Pal A, Singh D, Bhandari A, Rawat P, Swarnakar TK, Swarnakar A. The socket shield technique. *Int J Curr Res* 2018;10:67200–4.
- [30] Anas B, Shenoy KK. Socket shield technique - A neoteric approach in ridge preservation. *Sch J Dent Sci* 2017;4:125–28.
- [31] Mujawar S, Devkar N, Vibhute A, Deshpande M, Budruk V. Socket shield technique: a review. *Int J Recent Sci Res* 2018;9:27612–5.
- [32] Gluckman H, Salama M, Du Toit J. Partial extraction therapies (PET) part 1: maintaining alveolar ridge contour at pontic and immediate implant sites. *Int J Periodontics Restorative Dent* 2016;681–7.
- [33] Guirado JLC, Troiano M, Lopez-Lopez PJ, Ramirez-Fernandes MP, De Val JEMS, Marin JMG, et al. Different configuration of socket shield technique in peri-implant bone preservation: An experimental study in dog mandible. *Annals of Anatomy* 2016;109–15.
- [34] Parlar A, Bosshardt DD, Unsal B, Cetiner D, Haytac C, Lang NP. New formation of periodontal tissues around titanium implants in a novel dentin chamber model. *Clin Oral Impl Res* 2005;259–67.
- [35] Nevins ML, Langer L, Schupbach P. Late dental implant failure associated with retained root fragments: case reports with histologic and SEM analysis. *Int J Periodontics Restorative Dent* 2018;9:15.



Copyright: This is an open-access article distributed under the terms of Creative Commons Attribution License 4.0 (CCBY 4.0), which allows users to distribute and copy the material in any format so long as attribution is given to the author(s).