

# Management of a complete denture in the flat mandibular ridge using a semi-adjustable articulator along with an effective suction method

*by Ratri Maya Sitalaksmi*

---

**Submission date:** 14-Dec-2022 09:26AM (UTC+0800)

**Submission ID:** 1980664695

**File name:** djustable\_articulator\_along\_with\_an\_effective\_suction\_method.pdf (919.17K)

**Word count:** 4042

**Character count:** 21761

## Management of a complete denture in the flat mandibular ridge using a semi-adjustable articulator along with an effective suction method

Muhammad Dimas Aditya Ari<sup>1</sup>, Harry Laksono<sup>1</sup>, Valerian Laksono<sup>2</sup>, Real Akbar Aucky Sanjaya<sup>3</sup>, Tasya Regita Pramesti<sup>3</sup>, Ratri Maya Sitalaksmi<sup>1</sup>

<sup>1</sup>Department of Prosthodontics, Faculty of Dental Medicine, Universitas Airlangga, Surabaya, Indonesia

<sup>2</sup>Resident of Prosthodontics, Faculty of Dental Medicine, Universitas Airlangga, Surabaya, Indonesia

<sup>3</sup>Undergraduate Student, Faculty of Dental Medicine, Universitas Airlangga, Surabaya, Indonesia

### ABSTRACT

**Background:** Complete dentures can improve the quality of life of edentulous patients. The selection of a suitable articulator and an impression technique is important to construct a stable and retentive complete denture with good occlusion. The use of a semi-adjustable articulator ensures that the dentures can be constructed such that their movement closely resembles the patient's physiological movements. The effective suction method can ensure the development of the border seal according to the patient's anatomical condition. The use of a semi-adjustable articulator along with an effective suction method is expected to provide good results in the construction of a complete denture. **Purpose:** This report aimed to describe the management of individual complete dentures in the flat mandibular ridge using a semi-adjustable articulator along with an effective suction method. **Case:** A 69-year-old female patient came with a chief complaint of her old dentures being unusable and wanted new dentures made. The patient's general condition was good, and the last extraction was done three months prior to the patient's arrival. The mandibular posterior alveolar ridge showed dextral tapering and sinistral flatness. **Case Management:** A complete denture with an acrylic base was fabricated using a semi-adjustable articulator along with an effective suction method. **Conclusion:** Flat ridge case management using a semi-adjustable articulator with an effective suction method can improve complete denture retention and stability.

**Keywords:** complete denture; effective suction method; semi-adjustable articulator

Correspondence: Muhammad Dimas Aditya Ari, Faculty of Dental Medicine, Universitas Airlangga, Jl. Mayjen Prof. Dr. Moestopo No. 47 Surabaya, 60132, Indonesia. E-mail: [dimasadityadrg@fkg.unair.ac.id](mailto:dimasadityadrg@fkg.unair.ac.id)

### INTRODUCTION

The prevalence of tooth loss has increased in the past few decades, especially in elderly patients. The loss of teeth causes a decrease in the masticatory, phonetic and aesthetic functions of the patient, thus resulting in a reduction of the patient's quality of life.<sup>1</sup> A replacement of the missing teeth with complete dentures is needed to restore the patient's masticatory, phonetic and aesthetic functions, which can improve the patient's quality of life.<sup>2</sup>

Retention and stability are important factors in the successful fabrication of complete dentures. Retention and stability of mandibular dentures is relatively difficult to achieve due to the surface area of the mandible being much

smaller than that of the maxilla and the active movement of muscles resulting from the presence of the tongue and floor of the mouth.<sup>3</sup> This makes obtaining a border seal more difficult in the lower jaw compared to that in the upper jaw. An effective suction method can be used to generate an adequate border seal for the dentures to be more retentive and stable, which is not easily achievable by conventional methods.<sup>4</sup> In the case of flat ridges, maximum retention and stability must be achieved in order to increase the comfort and function of the complete denture. This case report aims to describe the management of individual complete dentures in the flat mandibular ridge using a semi-adjustable articulator along with effective suction methods.

## CASE

A 69-year-old female patient arrived at the Prosthodontic Specialist Clinic at the Universitas Airlangga Dental Hospital to get a new complete denture made. The patient was seeking an improvement in the dental appearance and masticatory functions because her old dentures were no longer usable due to the extraction of the remaining teeth. The general condition of the patient was good, there was no history of systemic disease, and the last extraction was performed approximately three months prior to the patients arrival.

No abnormalities were found on extraoral clinical examination. The patient profile is shown in Figure 1. Intraoral clinical examination (Figure 2) revealed the missing maxillary and mandibular teeth to be accompanied by remnants of the root of the 12th tooth. The ridge could be seen to be ovoid in the maxilla and anterior mandible,

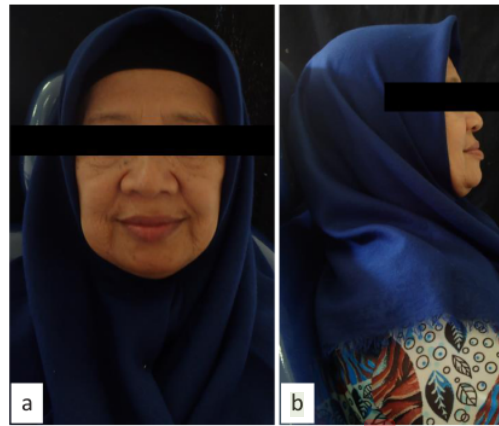


Figure 1. Patient profile: (a) front view, (b) side view.

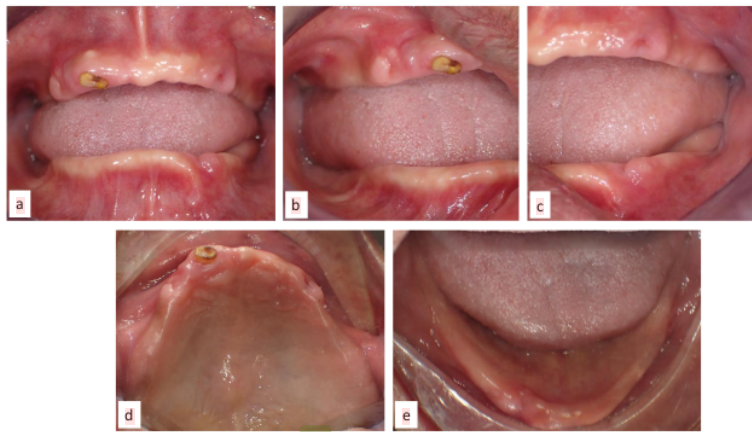


Figure 2. Clinical intraoral examination of the patient: (a) frontal, (b) right side, (c) left side, (d) maxillary occlusal and (e) mandibular occlusal.

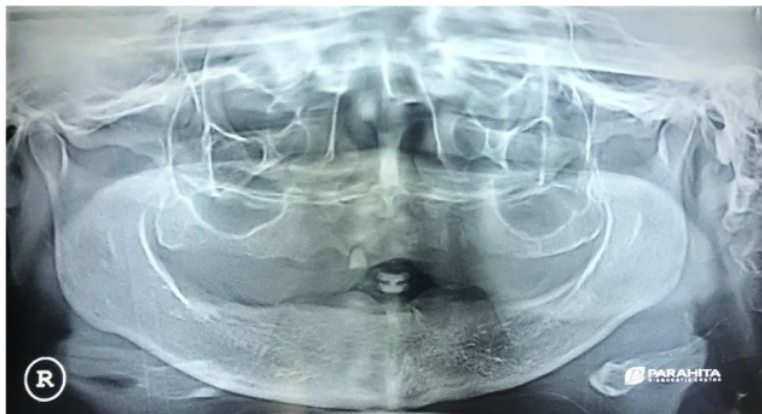

Figure 3. Panoramic radiograph.

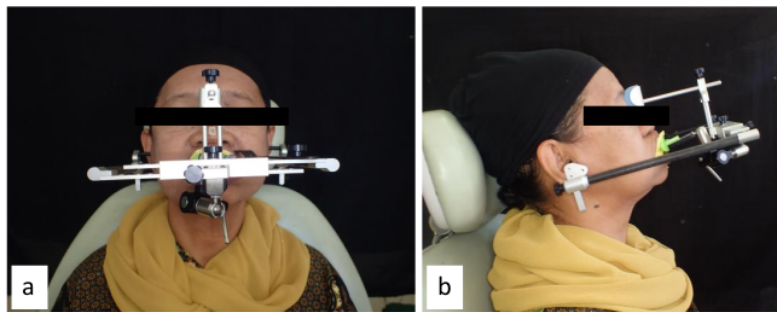
tapering on the right posterior of the mandible (Cawood and Howell classification of edentulous jaws class IV) and flat on the left posterior of the mandible (Cawood and Howell classification of edentulous jaws class V). A normal ridge relation was seen, and no exostosis was found. The retro-mylohyoid area was deep. Radiographic examination (Figure 3) showed a radiopaque appearance in the region of the tooth, the impression of the remaining roots and the maxillary and mandibular edentulous ridges. The diagnosis obtained from all examinations performed was chronic apical periodontitis e.c gangrene radix of tooth 12 and edentulous ridge of the maxilla and mandible.

### CASE MANAGEMENT

Treatment of this case was carried out by making complete dentures with an acrylic base using an effective suction method. The treatment began with the informed consent of the patient and continued with the preliminary impression of the upper and lower jaws using the Accu-Tray (Accu-Dent<sup>®</sup>) stock tray with an irreversible hydrocolloid

(alginate) impression material and was followed by the pouring of gypsum type III (dental stone) to obtain study models. Subsequently, the patient was referred for a radiograph. From the results of all examinations, the operator established a diagnosis, made a treatment plan, and developed a denture design. The patient was referred for the extraction of the remaining root of tooth 12.

Prosthetic treatment was initiated by measuring the patient's preliminary vertical dimension occlusion (VDO) using the Niswonger method. Subsequently, a preliminary bite registration was carried out using an irreversible hydrocolloid material that was applied to the centric tray. The centric tray was inserted into the patient's mouth and the patient was instructed to close the mouth slowly until the predetermined VDO was reached. Next, the facebow transfer was attached to the patient using the Universal Transferbow System (UTS). The study model was mounted on a semi-adjustable articulator (Stratos 300<sup>®</sup>) with the aid of the centric tray and was further developed with the manufacture of maxillary and mandibular individual trays with bite rim mounts (Figure 4).



**Figure 4.** The first facebow transfer with the Universal Transferbow System (UTS) Stratos300<sup>®</sup> and centric tray: (a) frontal view and (b) lateral view.



**Figure 5.** Results of intraoral gothic arch tracing on the maxillary registration plate.






Figure 6. Mounting the working cast on the semi-adjustable articulator from frontal (a) and lateral (b) sides.

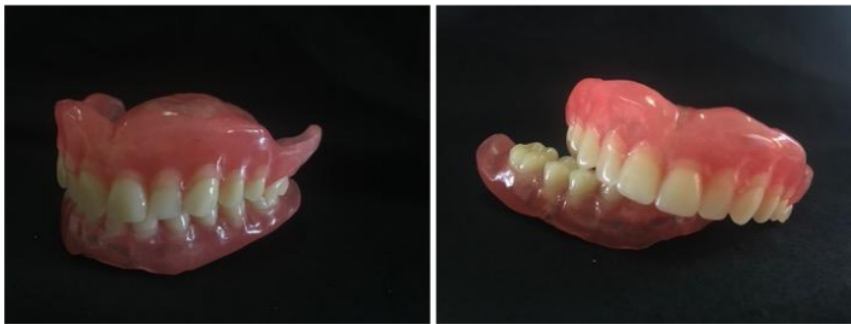

Figure 7. Polished acrylic complete denture ready for patient insertion.

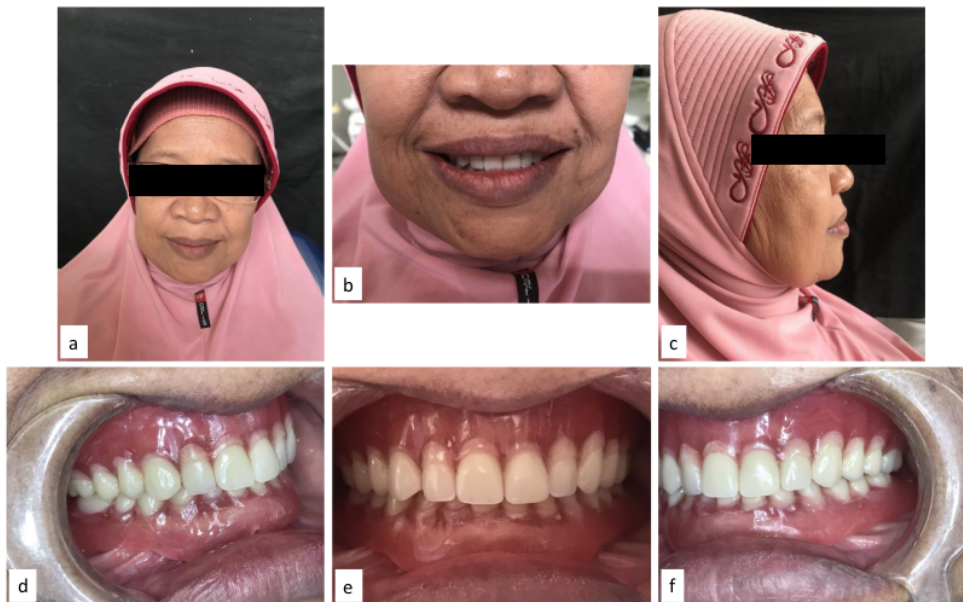

Figure 8. Acrylic complete denture used in the patient looks clinically extraoral from the frontal (a) and lateral (c) sides when the patient smiles (b) and looks clinically intraoral from the right lateral side (d), frontal (e) and left lateral side (f).

The stability, flange, median lines and alignment on individual trays were checked. Border molding was then performed on the maxilla, starting with applying adhesive material to all edges of the maxillary individual tray, which was followed by injection of polyvinyl siloxane medium body material on all its edges. The maxillary individual tray was intraorally inserted, and the patient was instructed to say 'ah' firmly in an open mouth position. Mandibular individual trays were inserted into the patient's mouth and then the patient was instructed to close her mandibula. The patient was instructed to pronounce the words 'wee' and 'woo' while maintaining the last position. The patient was then instructed to perform a thumb sucking motion and wait for the material to set. Subsequently, the individual tray was removed, and all excess border molding material was cut and eliminated. The procedure was continued by performing border molding on the mandibular ridge. The same procedure was repeated for the maxilla except that the patient was instructed to stick the tongue forward and right and perform a motion of swallowing saliva.

The next step was to acquire the final impression of the maxillary and mandibular ridge to obtain a working cast. Adhesive material was applied to the anatomical surface of the individual tray followed by an injection of polyvinyl siloxane light body material. The individual tray was inserted intraorally, and the patient was instructed to perform the same movements as done for border molding. The impression was initiated with the maxilla and the excess material was cut after the setting of the material. The impression then continued with the same procedure for the mandible.

The VDO was corrected by replacing the bite rims mounts on the maxillary individual tray with a maxillary registration plate and the bite rims mounts on the mandibular individual tray with a mandibular registration plate having a gothic arch registration stylus with pliers. The patient's VDO was measured using the Niswonger method and the individual trays were then placed on the maxillary and mandibular ridge. The VDO was adjusted by rotating the stylus on the individual tray. After getting the right VDO, the stylus was locked by dripping liquid wax.

The horizontal relation was determined using a gothic arch traced with an M-gnathometer. The maxillary registration plate was given a marker and the patient was instructed to practice opening and closing the mouth in a consistent position that had been given a marker as the starting point. The patient was instructed to move the mandible anteriorly (protrusive movement) beginning from the starting point and returning to it several times. Similar movements were also performed for the right (right lateral movement) and the left side (left lateral movement). Gothic arch tracing was confirmed by examining the results of the mandibular movements recorded on the marker on the maxillary registration plate as shown in Figure 5.

A transparent plastic fixation was installed with one of its holes located at the starting point so that when the patient closed her mouth, the stylus was locked in

the correct starting point position. Once locked, O-bite® polyvinyl siloxane medium body bite registration material was injected in the gap formed between the maxillary and mandibular registration plates. The patient's median, canine and smile lines were assigned on individual trays with the marker. Subsequently, a facebow transfer was performed on the patient using the UTS and was followed by the selection of the type and colour of the elements of the teeth.

The final impression was boxed and poured with gypsum type III (dental stone) to get a working cast. The maxillary working cast was mounted on a semi-adjustable Stratos 300® articulator using a facebow transfer guide. The working cast of the mandibular was mounted using a bite registration guide (Figure 6). The denture elements were arranged with the setting of a two-dimensional template based on the centric occlusion, protrusive movement and lateral movement. Complete denture wax was used for a trial denture for the patient. The patient's profile, retention, stability and occlusion were checked.

The complete denture wax was subjected to contouring, flasking, packing, and initial polishing (Figure 7). The denture was tried in for the patient and the patient's profile, retention, stability and occlusion were checked. Subsequently, an insertion of the denture was performed (Figure 8). This was followed by a session of information and advice for the patient.

## DISCUSSION

At the patient's initial visit, a preliminary impression was performed to produce a study cast that was used to assist clinicians in conducting examinations, establishing a diagnosis and determining a treatment plan, and for being the basis for making custom impression trays.<sup>5</sup> The preliminary impression was made using the Accu-tray (Accu-Dent®) stock tray with alginate material. The Accu-tray has advantages over conventional stock trays owing to the extra flange that duplicates the depth of the vestibule and the extended distal part that duplicates the retromolar pad area more efficiently.<sup>6</sup> Irreversible hydrocolloid material was chosen because it can produce a good impression with detailed anatomical landmarks and has a lower cost.<sup>5,7</sup> However, this material often exerts excessive pressure on the patient's vestibule, resulting in an inaccurate model. The pressure on the vestibule usually results in an overextended study model.<sup>8</sup>

The impressions made with irreversible material are susceptible to damage from water content in the surrounding environment. If the impression is placed in a wet environment, the mold absorbs the water, which results in the occurrence of syneresis, whereas if the impression is placed in a dry environment, it releases its water content, resulting in the occurrence of an imbibition process. Therefore, the preliminary impression must be filled with gypsum immediately to avoid any changes in the dimensions.<sup>9</sup> According to the ANSI/ADA specification



no. 25, gypsum type I and II are capable of reproducing grooves with a width of 75mm, while gypsum type III, IV and V are capable of reproducing grooves with a width of 50mm. Therefore, gypsum type III, IV and V are capable of producing more accurate duplication as compared to that produced by type I and II. Gypsum type III has a compressive strength lesser than gypsum type IV and V.<sup>10</sup> Material needed to produce a study model has to be accurate, however, it does not require very high strength. Therefore, gypsum type III (dental stone) was chosen as the material of choice for filling the preliminary mold.

The use of a centric tray also facilitates the process of making complete dentures. The centric tray can be used to obtain an initial VDO on the patient. This provides the operator with a reference to the patient's VDO, which results in minimal adjustment being required at the stage of determining the occlusion. In addition, the use of a centric tray can assist the operator in mounting the study cast in the articulator in a centric relation, which can enable an analysis related to the patient's occlusion relationship to be carried out.<sup>4</sup>

The cast was mounted on the articulator with the aim to simulate the relationship and the movement of the patient's jaw extraorally. Articulators are classified into three types, namely non-adjustable, semi-adjustable and fully-adjustable articulators.<sup>11</sup> In this case, a semi-adjustable articulator (Stratos 300<sup>®</sup>) was used because some plane orientations and angles on the semi-adjustable articulator could be adjusted according to the anatomical conditions and physiology of the patient. This facilitated the production of dentures that had occlusion and articulation (individualized prosthesis) similar to that of the patient, which resulted in an increase in the patient comfort.<sup>4,5</sup>

A facebow transfer was used for this case in addition to the semi-adjustable articulator. According to *The Glossary of Prosthodontics Terms* (2017), facebow transfer is a process of transferring the spatial relationship of the maxillary arch to anatomical points on an articulator using certain instruments.<sup>12</sup> The facebow transfer on the patient was expected to result in the orientation of the maxillary study model to the axis of rotation of the articulator being close to that between the patient's maxilla and the patient's transverse horizontal axis, namely the TMJ. This allows the turning radius of the articulator to be more similar to the patient's arc closure, thereby minimizing errors.<sup>13</sup>

Several factors influence the success of denture prosthesis, such as the retention and stability of the denture, which can both be achieved properly if the denture has an adequate border seal.<sup>14</sup> According to *The Glossary of Prosthodontic Terms*, 9th Edition, a border seal is the contact of the denture edge against the underlying tissue to prevent air or any other materials from entering the denture.<sup>12</sup> To obtain an adequate border seal, the final impression must be ensured to be accurate at the boundaries of the movable and immovable mucosa. If the edge does not reach the movable and immovable mucosa and underextends the mucosal margin, the denture bearing area

will be reduced and a border seal will not form. If the edge exceeds the border of the moving and immovable mucosa (overextension), the muscle movement will result in the denture breaking the border seal.<sup>15</sup>

Individual trays and border molding are required to obtain a precise denture border area at the boundaries of the movable and immovable mucosa.<sup>16,17</sup> Peri-compound wax is a material that is often used for this purpose. However, this material needs to be used in sectional parts and is, therefore, considered time consuming and uncomfortable for the patient.<sup>18</sup> An alternative method to obtain an adequate border seal is to perform a functional impression using polyvinyl siloxane material along with an effective suction method. The impression is initiated with the maxillary arch because the surface area of the maxillary denture base is wider than that of the mandible, which makes it easier for the impression material to displace. If the displacement occurs in the individual trays, the predetermined occlusal position cannot be reproduced accurately.<sup>4</sup> The impression obtained using the effective suction method is almost the same as that obtained by the close mouth method. This method mainly involves the patient performing a suction movement with their mouth during the impression. This allows for an adequate denture border seal to be obtained due to the active movement of muscle trimming performed by the patient. This impression method is a patient-oriented method for obtaining an adequate denture border seal and a more stable and retentive complete denture.<sup>4,19</sup>

The individual tray used for this case was also equipped with an M-gnathometer. The M-gnathometer is an instrument used to assist in tracing the intraoral gothic arch. Gothic arch tracing is a scalable method in which the entire range of mandibular movement is recorded on a registration plate to determine the horizontal relation of the jaws. Gothic arch tracing helps the operator to obtain a stable tapping point that is at the right point of occlusion and to determine an accurate horizontal relationship. The use of gothic arch tracing can minimize the presence of occlusal discrepancies that subsequently need to be corrected after the acrylic dentures are inserted into the patient's mouth. This gothic arch tracing procedure facilitated the fabrication of the complete denture with optimal aesthetics, function, and phonetics.<sup>20–23</sup> From this case report, it can be concluded that flat ridge case management using a semi-adjustable articulator along with an effective suction method can be used to manufacture individual complete dentures.

## REFERENCES

1. Emami E, de Souza RF, Kabawat M, Feine JS. The impact of edentulism on oral and general health. *Int J Dent.* 2013; 2013: 498305.
2. Kaushik K, Dhawan P, Tandan P, Jain M. Oral health-related quality of life among patients after complete denture rehabilitation: A 12-month follow-up study. *Int J Appl basic Med Res.* 2018; 8(3): 169–73.
3. Jain P, Rathee M. Stability in mandibular denture. *StatPearls.* Treasure Island (FL): StatPearls Publishing; 2022.

4. Abe J, Kokubo K, Sato K. Mandibular suction-effective denture and BPS: a complete guide. Quintessence Pub; 2012. p. 291.
5. Rahn AO, Ivanhoe JR, Plummer KD. Textbook of complete dentures. 6th ed. USA: PMPH-USA; 2009. p. 446.
6. Saini V, Singla R. Biofunctional prosthetic system: A new era complete denture. *J Pharm Bioallied Sci.* 2011; 3(1): 170–2.
7. Rao S, Chowdhary R, Mahoorkar S. A systematic review of impression technique for conventional complete denture. *J Indian Prosthodont Soc.* 2010; 10(2): 105–11.
8. Johnson T, Wood DJ. Techniques in complete denture technology. UK: Wiley-Blackwell; 2012. p. 112.
9. McCabe JF, Walls A. Applied dental materials. 9th ed. UK: Wiley-Blackwell; 2008. p. 312.
10. Sakaguchi RL, Powers JM. Craig's restorative dental materials. Thirteenth. Sakaguchi RL, Powers JM, editors. Saint Louis: Mosby; 2012. p. 150–2.
11. Gross M. The science and art of occlusion and oral rehabilitation. UK: Quintessence Publishing; 2015. p. 544.
12. Driscoll CF, Freilich MA, Guckes AD, Knoernschild KL, McGarry TJ, Goldstein G, Goodacre C, Guckes A, Mor S, Rosenstiel S, Vanblarcom C. The Glossary of Prosthodontic Terms: Ninth Edition. *J Prosthet Dent.* 2017; 117(5S): e1–105.
13. Shillingburg Jr. HT, Sather DA, Wilson Jr. EL, Cain JR, Mitchell DL, Blanco LJ, Kessler JC. Fundamentals of fixed prosthodontics. 4th ed. USA: Quintessence Publishing; 2012. p. 584.
14. Patel J, Jablonski RY, Morrow LA. Complete dentures: an update on clinical assessment and management: part 1. *Br Dent J.* 2018; 225(8): 707–14.
15. Pridana S, Danial Nasution I, Nasution I, Welda Utami Ritonga P. Effect of border molding materials and techniques on peripheral tissue morphology and retention of denture bases in edentulous patients at RSGM USU. *Int J Oral Heal Dent.* 2019; 5(1): 14–9.
16. Kaur S, Datta K, Gupta SK, Suman N. Comparative analysis of the retention of maxillary denture base with and without border molding using zinc oxide eugenol impression paste. *Indian J Dent.* 2016; 7(1): 1–5.
17. Özkan YK. Complete Denture Prosthodontics. Cham: Springer International Publishing; 2018. p. 290.
18. Qureshi I, Rashid S, Qureshi S, Rehman AU. Critical evaluation of material and procedures used for the functional peripheral moulding. *J Pakistan Dent Assoc.* 2010; 19(2): 129–32.
19. Gosavi S, Nalawade K, Gosavi S. Use of innovative suction device to improve the retention in denture wearer patients - A pilot study. *Int J Appl Dent Sci.* 2016; 2(2): 24–7.
20. Abe J, Iwaki K, Sudo T, Kokubo K. Mandibular suction-effective denture "the professional": clinical and laboratory technique for class I/II/III with aesthetics. Tokyo: Quintessence Publishing; 2019. p. 188.
21. Rubel B, Hill EE. Intraoral gothic arch tracing. *N Y State Dent J.* 2011; 77(5): 40–3.
22. Hayakawa I. Principles and practices of complete dentures: creating the mental image of a denture. Tokyo: Quintessence Publishing; 1999. p. 255.
23. Zarb GA, Hobkirk J, Eckert S, Jacob R. Prosthodontic treatment for edentulous patients: Complete dentures and implant-supported prostheses. 13th ed. St. Louis: Elsevier Health Sciences; 2012. p. 466.



# Management of a complete denture in the flat mandibular ridge using a semi-adjustable articulator along with an effective suction method

## ORIGINALITY REPORT

10%

SIMILARITY INDEX

6%

INTERNET SOURCES

8%

PUBLICATIONS

0%

STUDENT PAPERS

## PRIMARY SOURCES

- 1 Ade Wulandari, Ni Putu Sumartini, H Ahmad. "Model of Anticipation Guidance Through Family Centered Care (FCC) to Increase Family Competence in Newborn Baby", Jurnal Kesehatan Prima, 2020  
Publication 2%
- 2 Manish Kinra, Divia Chugh, Inderjit Gowdar, Shoaib Khan, Mohammed Kola, Bavika Sachdeva. "Making of Primary Impression Made Easy for Severely Resorbed Mandibular Ridge – A Clinical Case Report", British Journal of Medicine and Medical Research, 2017  
Publication 1%
- 3 [www.dovepress.com](http://www.dovepress.com)  
Internet Source 1%
- 4 Nanik Zubaidah, Ruslan Effendy, Adioro Soetojo, Tri Estiyaningsih, Muhammad Iqbal Tanzil, Khusnul Khotimah. "Difference of Chemical Bonds Between UDMA Bonding

Agents with Ethanol Solvent and Acetone Solvent on Dentin Collagen", Pesquisa Brasileira em Odontopediatria e Clínica Integrada, 2021

Publication

---

|    |   |      |
|----|---|------|
| 5  | <a href="http://www.mdpi.com">www.mdpi.com</a><br>Internet Source   | 1 %  |
| 6  | M. Ziad Al - Ani, Robin J.M. Gray.<br>"Temporomandibular Disorders", Wiley, 2021<br>Publication   | 1 %  |
| 7  | <a href="http://healthdocbox.com">healthdocbox.com</a><br>Internet Source   | <1 % |
| 8  | <a href="http://j-ips.org">j-ips.org</a><br>Internet Source   | <1 % |
| 9  | Thai-Yen Ling, Chun-Lin Chen, Yen-Hua Huang, I-Hua Liu, Shuan Shian Huang, Jung San Huang. "Identification and Characterization of the Acidic pH Binding Sites for Growth Regulatory Ligands of Low Density Lipoprotein Receptor-related Protein-1", Journal of Biological Chemistry, 2004<br>Publication | <1 % |
| 10 | <a href="http://www.elsevier.es">www.elsevier.es</a><br>Internet Source   | <1 % |
| 11 | <a href="http://ojs.brazilianjournals.com.br">ojs.brazilianjournals.com.br</a><br>Internet Source   | <1 % |

---

12 Hedaiat Moradpoor, Fatemeh Salari, Behnaz Ebadian, Sahar Raissi, Mohammadjavad Shirani. "Patient Satisfaction with Occlusal Scheme of Conventional Complete Dentures: A Randomized Clinical Trial (Part II)", Journal of Oral Rehabilitation, 2018  
Publication <1 %

---

13 [actamedicaphilippina.upm.edu.ph](http://actamedicaphilippina.upm.edu.ph)  
Internet Source <1 %

---

14 [www.ejmcm.com](http://www.ejmcm.com)  
Internet Source <1 %

---

15 "The Glossary of Prosthodontic Terms", The Journal of Prosthetic Dentistry, 2017  
Publication <1 %

---

16 Marwa Mohammed Ali, Nadia Khalifa, Mohammed Nasser Alhajj. "Quality of life and problems associated with obturators of patients with maxillectomies", Head & Face Medicine, 2018  
Publication <1 %

---

17 [www.e-jyms.org](http://www.e-jyms.org)  
Internet Source <1 %

---

18 Carolina S López, Constanza H Saka, Gabriel Rada, Daniela D Valenzuela. "Impact of fixed implant supported prostheses in edentulous patients: protocol for a systematic review", BMJ Open, 2016 <1 %

19 [repositorio.cespu.pt](https://repositorio.cespu.pt) <1 %  
Internet Source

---

20 Joana Mendes, José Manuel Mendes, Pedro Barreiros, Carlos Aroso, António Sérgio Silva. "Retention Capacity of Original Denture Adhesives and White Brands for Conventional Complete Dentures: An In Vitro Study", *Polymers*, 2022 <1 %  
Publication

---

21 *Removable Partial Dentures*, 2016. <1 %  
Publication

---

22 "Atlas of Immediate Dental Implant Loading", Springer Science and Business Media LLC, 2019 <1 %  
Publication

---

Exclude quotes Off

Exclude matches Off

Exclude bibliography On



# Management of a complete denture in the flat mandibular ridge using a semi-adjustable articulator along with an effective suction method

---

GRADEMARK REPORT

---

FINAL GRADE

**/0**

GENERAL COMMENTS

**Instructor**

---

PAGE 1

---

PAGE 2

---

PAGE 3

---

PAGE 4

---

PAGE 5

---

PAGE 6

---

PAGE 7

---