

# Combination of Moringa oleifera leaf extract and demineralized freeze-dried bovine bone xenograft (DFDBBX) on woven bone area post tooth extraction

*by Ratri Maya Sitalaksmi*

---

**Submission date:** 24-Feb-2023 02:05PM (UTC+0800)

**Submission ID:** 2021868429

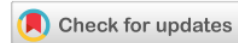**File name:** ra\_leaf\_extract\_and\_demineralized\_freeze-dried\_bovine\_-WJARR.pdf (1,018.78K)

**Word count:** 2822

**Character count:** 15148



(RESEARCH ARTICLE)



## Combination of *Moringa oleifera* leaf extract and demineralized freeze-dried bovine bone xenograft (DFDBBX) on woven bone area post tooth extraction

Utari Kresnoadi \*, Phara Aster Chandra Adventia and Ratri Maya Sitalaksmi

Department of Prosthodontics, Faculty of Dental Medicine, Universitas Airlangga, Surabaya, Indonesia.

World Journal of Advanced Research and Reviews, 2023, 17(02), 494–499

Publication history: Received on 28 December 2022; revised on 06 February 2023; accepted on 09 February 2023

Article DOI: <https://doi.org/10.30574/wjarr.2023.17.2.0225>

### Abstract

**Background:** Tooth extraction is one of the most frequently performed procedures in dental practice. Resorption without bone regeneration can change the maxillary and mandibular bone structure, resulting lack of retention, stability, and comfort of the denture. Hence, adequate regeneration of alveolar bone is considered an important factor for successful dentures. *Moringa oleifera* is a plant rich in flavonoids, saponins, alkaloids and tannins.

**Purpose:** This study aims to find out the effect of induction from combination of *Moringa oleifera* extract and demineralized freeze-dried bovine bone xenograft (DFDBBX) on woven bone area post tooth extraction procedure.

**Methods:** *Cavia cobaya* was divided into eight groups, each group consists of seven. The lower incisors of Fifty-six *Cavia cobaya* were extracted. The first group (control group) was given polyethylene glycol, the second group with DFDBBX, the third group with *Moringa* leaf extract, and the fourth group with a combination of DFDBBX and *Moringa* leaf extract. *Cavia cobaya* were sacrificed on day 7 and 14. Histopathological examinations of woven bone area was observed under a 400x magnification light microscope. Kruskal-Wallis and Mann-Whitney tests were performed to analyze the data.

**Results:** There was a significant difference in woven bone area between the groups ( $P < 0.05$ ). The highest mean of woven bone area was found in the combination group on both day 7 and 14.

**Conclusion:** The combination of *Moringa* leaf extract and DFDBBX could effectively formed new woven bone during the alveolar bone regeneration.

**Keywords:** Demineralized freeze-dried bovine bone xenograft; *Moringa oleifera*; Woven bone; Bone regeneration; Medicine

### 1. Introduction

Tooth extraction is one of the most frequently performed procedures in dental practice. Tooth extraction is carried out because of terminal condition or unresponsive response towards current treatment, such as severe caries, periodontal disease, impaction, fracture, teeth affected by cysts or tumors [1]. Traumatic tooth extraction leads to unfavorable healing process, resulting excessive bone resorption that will interfere future denture treatment [2]. *Moringa* is a tropical plant that is easy to grow and develop in Indonesia, however, the use of *Moringa* for health purpose at this time is still very limited.

Alveolar bone resorption after tooth extraction can be reduced by preservation measures, namely by adding materials that can stimulate bone healing or regenerative materials such as bone grafts. Bone graft has osteogenic, osteoinductive

\* Corresponding author: Utari Kresnoadi

and osteoconductive properties which help stimulate bone healing. There are four categories of bone grafts according to their origin, namely, autograft, allograft, xenograft and alloplastic graft [3]. Demineralized freeze-dried bovine bone xenograft (DFDBBX) is a bone graft material that is often used in dentistry.

DFDBBX is a type of xenograft derived from bovine bone. Based on research conducted by Kresnodi et al, it is known that the combination of *Moringa* leaf extract and DFDBBX has fairly good osteoinduction properties[4]. DFDBBX will function as a scaffold or framework in the growth of new bone originating from the formation of osteoblasts of the socket. Whereas the anti-inflammatory properties in *Moringa* leaves will suppress the inflammatory response in the socket after tooth extraction[1]. Therefore, this study was aimed to determine the induction effect of the combination of *Moringa oleifera* and DFDBBX extracts on the growth of woven bone of the alveolar bone socket.

---

20

## 2. Material and methods

All procedures carried out in this study have gone through an ethical clearance process issued by the Ethics Commission of the Faculty of Dentistry, Universitas Airlangga, Surabaya with number 555/HRECC.FODM/VIII/2022.

This study was a laboratory experimental study on experimental animals (*Cavia cobaya*) with a randomized post-test control group design. Inclusion criteria for the *Cavia cobaya* animal sample were male, body weight of 300 - 350 grams, 3 months old, healthy and active. This study comprised of 4 groups; each group consist of 7. After left incisor of mandible was extracted, the animals were received materials according to their group. The details from each groups was described as follows; group I: socket was given 25 grams of polyethylene glycol (PEG) and examined on day 7, group II: socket was given 25 grams of PEG and examined on day 14, group III: socket was given 0.5 gram DFDBBX and 24.5 gram PEG and examined on day 7, Group IV: socket was given 0.5 gram DFDBBX and 24 .5 gram of PEG and examined on the day 14, group V: socket was given 0.5 gram of *Moringa oleifera* extract and 24.5 gram of PEG and examined on day 7, group VI: socket was given 0.5 gram of *Moringa oleifera* extract and 24.5 gram of PEG and examined on day 14, group VII: socket was given 0.5 gram of DFDBBX, 0.5 gram of extract *Moringa oleifera*, and 24 grams of PEG and examined on day 7, group VIII : socket was given 0.5 gram of DFDBBX, 0.5 gram of *Moringa oleifera* extract and 24 gram of PEG and examined on day 14.

The research procedure involved the preparation of *Moringa oleifera* extract by mixing 0.5 gram of dry extract of *Moringa oleifera* and 24.5 gram of PEG which acts as a carrier of the extract. DFDBBX is a cancelous bovine xenograft which is produced by BATAN Research Tissue Bank. The area of woven bone was observed and counted under a light microscope with Hematoxylin Eosin (HE) staining.

Data analysis was carried out by Shapiro Wilk and Levene test. Kruskal-Wallis test followed by Mann Whitney test was done to determine the significant difference between groups. All statistical test was done using IBM Statistical Package for the Social Sciences, Statistics for Windows, version 24.0. (Armonk, NY: IBM Corp).

---

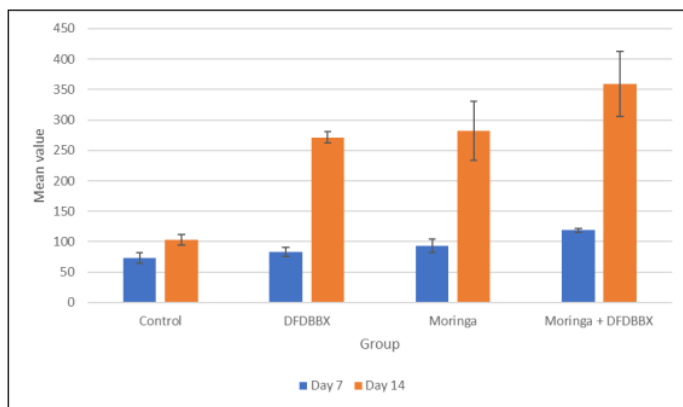
## 3. Results

Figure 1 shows the most widespread area of woven bone was the combination group, both on day 7 and day 14. Meanwhile, there was only very small growth in the area of woven bone from control group, both on the 7th and 14th days.

**Table 1** Results of the Mann Whitney test on day 7.

	Control	DFDBBX	<i>Moringa</i>	DFDBBX + <i>Moringa</i>
Control	-	0.025*	0.018*	0.002*
DFDBBX	0.025*	-	0.142	0.002*
<i>Moringa</i>	0.018*	0.142	-	0.006*
DFDBBX + <i>Moringa</i>	0.002*	0.002*	0.006*	-

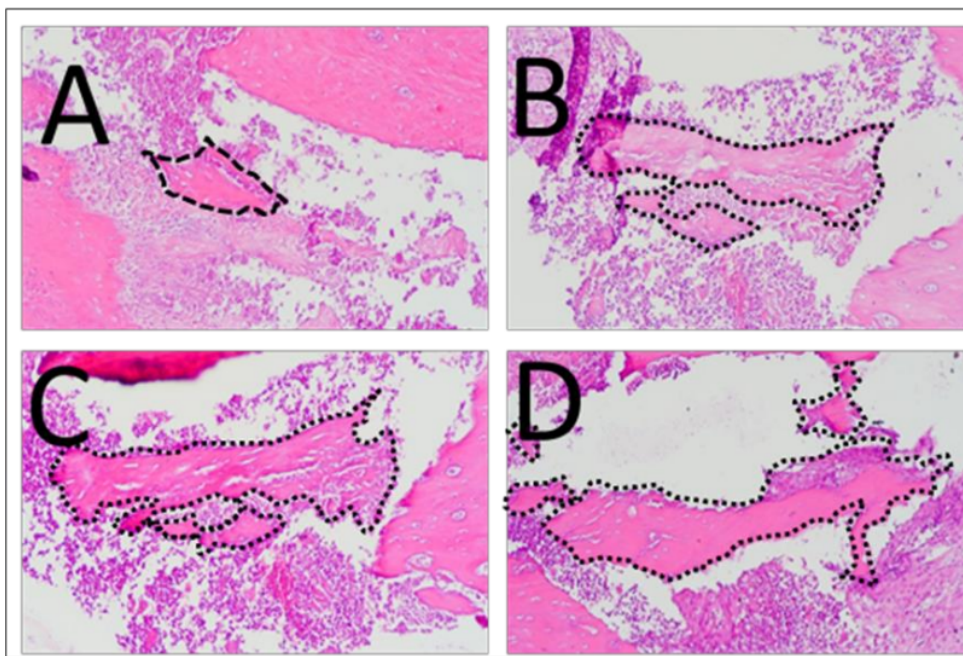
Asterisk (\*) symbol represents p value less than 0.05



**Figure 1** Mean value of woven bone area from each group

10 Based on the results of the Kruskal-Wallis test, a significant value of 0.000 was obtained, which is less than 0.05 ( $p < 0.05$ ).

12 Table 1 shows that there was a significant difference ( $p < 0.05$ ) between the control group and the other groups. There was a significant difference with a value of 0.025 ( $p < 0.05$ ) between the DFDBBX group and the control group. P value of 0.002 ( $p < 0.01$ ) was found between control group and combination group, meanwhile there was no significant difference between DFDBBX and Moringa group ( $p = 0.142$ ). The following is figure of hematoxylin eosin staining of the woven bone socket of *Cavia cobaya*'s tooth extraction on day 7 under a binocular light microscope with 100x magnification (Figure 2).



**Figure 2** Hematoxylin eosin staining of woven bone area on tooth socket after tooth extraction (day 7). A: control group, B: DFDBBX group, C: Moringa group, D: combination group. New woven bone area is shown with a black dot. Based on the results of the Kruskal-Wallis test, a significant value of 0.000 was obtained, which is less than 0.05 ( $p < 0.05$ ).



**Table 2** Results of the Mann Whitney test on day 14.

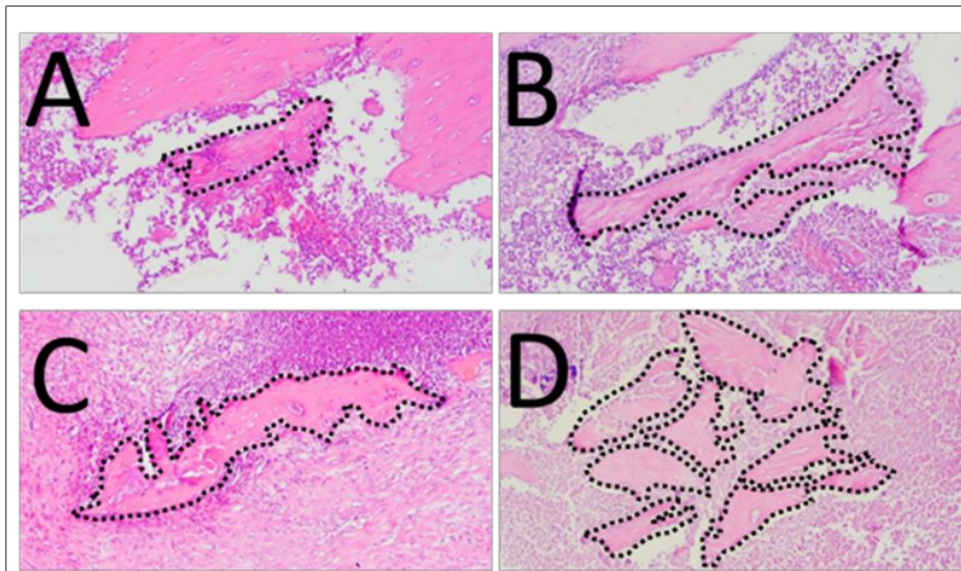
	<b>Control</b>	<b>DFDBBX</b>	<b>Moringa</b>	<b>DFDBBX + Moringa</b>
Control	-	0.002*	0.002*	0.002*
DFDBBX	0.002*	-	0.848	0.002*
Moringa	0.002*	0.848	-	0.048*
DFDBBX + Moringa	0.002*	0.002*	0.048*	-

Asterisk (\*) symbol represents p value less than 0.05

Table 2 shows that there was a significant difference ( $p < 0.05$ ) between the control group and the other groups. There was a significant difference with a value of 0.002 ( $p < 0.05$ ) between the DFDBBX group and the control group. P value of 0.002 ( $p < 0.01$ ) was found between control group and combination group, meanwhile there was no significant difference between DFDBBX and Moringa group ( $p = 0.848$ ).

Based on the Mann-Whitney test, significant results were obtained, namely  $p < 0.05$  in almost all sample groups, except for the DFDBBX and Moringa group ( $p = 0.848$ ).

The following is figure of hematoxylin eosin staining of the woven bone socket of *Cavia cobaya*'s tooth extraction on day 14 under a binocular light microscope with 100x magnification (Figure 3).



**Figure 3** Hematoxylin eosin staining of woven bone area on tooth socket after tooth extraction (day 14). A: control group, B: DFDBBX group, C: Moringa group, D: combination group. New woven bone area is shown with a black dot

#### 4. Discussion

The manufacture of dentures, whether removable dentures, fixed dentures, or implants, requires strong bone support to ensure that dentures can function effectively. However, post-extraction bone resorption can cause significant problems in denture fabrication. The retention factor that prevents the denture from falling out is strongly influenced by several anatomical factors, especially the prominent ridges. In order to maintain promising ridge conditions, resorption resulting from tooth extraction must be minimized [4]. Alveolar bone plays an important role in maintaining an ideal prosthetic reconstruction. Damage to bone tissue, resulting from tooth extraction, can cause atrophy of the alveolar bone and the healing process that occurs can cause bone deformity. In other words, alveolar bone must be maintained during the healing process [5].

Based on the results above, there was an increase in the area of woven bone in each group, both on day 7 and day 14. The average area of woven bone from lowest to highest order is as follows, (1) control group, (2) DFDBBX group, (3) *Moringa oleifera* group, (4) *Moringa oleifera* and DFDBBX groups. Judging from that sequence, the highest average woven bone area was in the combination group of *Moringa oleifera* and DFDBBX extracts. This was due to the presence of flavonoids in *Moringa oleifera* which were able to inhibit osteoclast resorption and stimulate osteoblast differentiation and cell mineralization. This statement was also supported by the presence of kaempferol which was capable of inhibiting enzymes, cyclooxygenase-2, which leads to inhibition of prostaglandin synthesis, and ultimately reduced PGE-2 and macrophage infiltration. PGE-2 plays a role in the formation of osteoclasts both directly and through the receptor activator of nuclear factor kappa-B (RANK) ligand, resulting in the differentiation of osteoclast precursors into mature osteoclasts [6].

Bone graft has osteogenic, osteoinductive and osteoconductive properties which help stimulate bone healing. There are four categories of bone grafts namely, autograft, allograft, xenograft and alloplastic graft [3]. DFDBBX has osteoconductive capabilities that can accelerate bone formation in tooth extraction sockets and reduce alveolar bone resorption through blood clot stabilization, scaffold formation, and external sources for minerals and collagen [7].

The lowest expression of woven bone was seen in the control group. If a comparison was made between day 7 and day 14, the area of woven bone on the day 14 was wider than day 7. *Moringa* leaf extract group and combination group of day 14 showed an increase in the area of woven bone compared to the control group. Based on research conducted by Kresnoadi *et al.*, the combination group leads to successful post-extraction socket preservation by accelerating alveolar bone regeneration. This is supported by the results of a study which stated that the group induced by the combination of *Moringa oleifera* extract and DFDBBX produced the highest TGF- $\beta$ 1 and osteocalcin [6]. This was supported by the presence of flavonoids, saponins, alkaloids and tannins. Flavonoids contained in *Moringa* leaf extract can stimulate osteoblast proliferation and differentiation. This is also supported by research which reveals that administration of flavonoid compounds taken from *Moringa* leaf extract can help osteoblast differentiation and lead to bone formation. Meanwhile, saponins have the effect of osteogenic activity which helps the proliferation and differentiation of osteoblasts [8].

Without any post-extraction preservation measures, there will be a 50% reduction in alveolar ridge volume within 12 months [9]. In the initial healing stage (2nd week), the socket that was given xenograft material that were covered by connective tissue and lined by multinucleated cells. Meanwhile, the socket that was not given graft material showed newly formed woven bone that occupied by most of the bone socket [10]. Flavonoids contained in *Moringa oleifera* are known to target prostaglandins which were observed in the acute inflammatory phase and pain perception. Furthermore, flavonoids, tannins and saponins contribute to the analgesic, anti-inflammatory and anti-oxidant activities of the plant leaf extract [11].

---

## 5. Conclusion

The induction of the combination of *Moringa oleifera* extract and DFDBBX after tooth extraction was able to increase the area of woven bone in alveolar bone socket on day 7 and day 14.

---

## Compliance with ethical standards

### *Disclosure of conflict of interest*

No conflict of interest.

### *Statement of ethical approval*

All procedures carried out in this study have gone through an ethical clearance process issued by the Ethics Commission of the Faculty of Dentistry, Universitas Airlangga, Surabaya with number 555/HRECC.FODM/VIII/2022.

---

## References

- [1] S. Soekobagiono, A. Alfiandy, A. Dahlan, RANKL expressions in preservation of surgical tooth extraction treated with *Moringa (Moringa oleifera)* leaf extract and demineralized freeze-dried bovine bone xenograft, Dental Journal (Majalah Kedokteran Gigi). 50 (2018) 149–153. <https://doi.org/10.20473/j.djmk.v50.i3.p149-153>.

- [2] U. Kresnoadi, L.C. Lunardhi, B. Agustono, Propolis extract and bovine bone graft combination in the expression of VEGF and FGF2 on the preservation of post extraction socket, J Indian Prosthodont Soc. 20 (2020) 417–423. [https://doi.org/10.4103/JIPS.JIPS\\_106\\_20](https://doi.org/10.4103/JIPS.JIPS_106_20).
- [3] D. Rahmawati, A. Hidroksiapatit Sebagai Bone Filler Pasca Pencabutan Gigi Dyah Rahmawati, B. Irawan, Hydroxyapatite Application As A Bone Filler After Tooth Extraction, Jurnal Material Kedokteran Gigi. 9 (2021) 39–46. <https://doi.org/10.32793/JMKG.V9I2.460>.
- [4] U. Kresnoadi, R.P. Rahayu, M.D. Ariani, S. Soesanto, The Potential of Natural Propolis Extract Combined with Bovine Bone Graft in Increasing Heat Shock Protein 70 and Osteocalcin on Socket Preservation, Eur J Dent. 14 (2020) 031–037. <https://doi.org/10.1055/s-0040-1701921>.
- [5] T.S.Y. Prabowo, U. Kresnoadi, H.E. Hidayati, Effective dose of propolis extract combined with bovine bone graft on the number of osteoblasts and osteoclasts in tooth extraction socket preservation, Dental Journal (Majalah Kedokteran Gigi). 53 (2020) 40. <https://doi.org/10.20473/j.djmk.v53.i1.p40-44>.
- [6] U. Kresnoadi, P.N. Rahmania, H.U. Caesar, E. Djulaeha, B. Agustono, M.D.A. Ari, The role of the combination of *Moringa oleifera* leaf extract and demineralized freeze-dried bovine bone xenograft (xenograft) as tooth extraction socket preservation materials on osteocalcin and transforming growth factor-beta 1 expressions in alveolar bone of *Cavia cobaya*, J Indian Prosthodont Soc. 19 (2019) 120–125. [https://doi.org/10.4103/JIPS.JIPS\\_251\\_18](https://doi.org/10.4103/JIPS.JIPS_251_18).
- [7] A. Horváth, N. Mardas, L.A. Mezzomo, I.G. Needleman, N. Donos, Alveolar ridge preservation. A systematic review, Clin Oral Investig. 17 (2013) 341–363. <https://doi.org/10.1007/S00784-012-0758-5>.
- [8] E. Rodríguez-Carballo, B. Gámez, F. Ventura, p38 MAPK Signaling in Osteoblast Differentiation, Front Cell Dev Biol. 4 (2016). <https://doi.org/10.3389/FCELL.2016.00040>.
- [9] M. Nizar, U. Kresnoadi, S. Soekobagiono, The effect of propolis extract and bovine bone graft combination on the number of osteoclast and osteoblast as an effort to preserve post-extraction socket (on *Cavia cobaya*), Dental Journal (Majalah Kedokteran Gigi). 53 (2020) 10. <https://doi.org/10.20473/j.djmk.v53.i1.p10-15>.
- [10] G. Pagni, G. Pellegrini, W. v. Giannobile, G. Rasperini, Postextraction Alveolar Ridge Preservation: Biological Basis and Treatments, Int J Dent. 2012 (2012). <https://doi.org/10.1155/2012/151030>.
- A.A. Adedapo, O.O. Falayi, A.A. Oyagbemi, Evaluation of the analgesic, anti-inflammatory, anti-oxidant, phytochemical and toxicological properties of the methanolic leaf extract of commercially processed *Moringa oleifera* in some laboratory animals, J Basic Clin Physiol Pharmacol. 26 (2015) 491–499. <https://doi.org/10.1515/JBCPP-2014-0105>.

# Combination of Moringa oleifera leaf extract and demineralized freeze-dried bovine bone xenograft (DFDBBX) on woven bone area post tooth extraction

## ORIGINALITY REPORT

16%

SIMILARITY INDEX

14%

INTERNET SOURCES

11%

PUBLICATIONS

0%

STUDENT PAPERS

## PRIMARY SOURCES

1	<a href="http://www.mdpi.com">www.mdpi.com</a> Internet Source	2%
2	<a href="http://www.scilit.net">www.scilit.net</a> Internet Source	2%
3	<a href="http://www.degruyter.com">www.degruyter.com</a> Internet Source	1%
4	<a href="http://garuda.ristekdikti.go.id">garuda.ristekdikti.go.id</a> Internet Source	1%
5	Luciano Bastos de Carvalho. "Exploring accounting hybrid skills in a serious games\` environment", Universidade de Sao Paulo, Agencia USP de Gestao da Informacao Academica (AGUIA), 2022 Publication	1%
6	<a href="http://academicjournals.org">academicjournals.org</a> Internet Source	1%
7	<a href="http://prosiding.respati.ac.id">prosiding.respati.ac.id</a> Internet Source	1%



8	<a href="http://benthamopen.com">benthamopen.com</a> Internet Source	1 %
9	<a href="http://cancerjournal.net">cancerjournal.net</a> Internet Source	1 %
10	<a href="http://repo.poltekkesdepkes-sby.ac.id">repo.poltekkesdepkes-sby.ac.id</a> Internet Source	1 %
11	<a href="http://archive.org">archive.org</a> Internet Source	1 %
12	<a href="http://journals.unizik.edu.ng">journals.unizik.edu.ng</a> Internet Source	1 %
13	<a href="http://www.science.gov">www.science.gov</a> Internet Source	1 %
14	<a href="http://journal.fk.unpad.ac.id">journal.fk.unpad.ac.id</a> Internet Source	1 %
15	Etiene de Andrade Munhoz. "Concepts and challenges of alveolar ridge preservation and augmentation", World Journal of Stomatology, 2016 Publication	1 %
16	<a href="http://repository.unhas.ac.id">repository.unhas.ac.id</a> Internet Source	1 %
17	<a href="http://estudogeral.sib.uc.pt">estudogeral.sib.uc.pt</a> Internet Source	<1 %
18	Mahnama, Ali, Mohammad Tafazzoli-Shadpour, Farideh Geramipannah, and	<1 %

Mohammad Mehdi Dehghan. "Verification of the mechanostat theory in mandible remodeling after tooth extraction: Animal study and numerical modeling", Journal of the Mechanical Behavior of Biomedical Materials, 2013.

Publication

---

19

[journals.sbmu.ac.ir](http://journals.sbmu.ac.ir)

Internet Source

<1 %

---

20

"Poster", Journal Of Clinical Periodontology, 2015.

Publication

<1 %

---

Exclude quotes Off

Exclude matches Off

Exclude bibliography On

# Combination of Moringa oleifera leaf extract and demineralized freeze-dried bovine bone xenograft (DFDBBX) on woven bone area post tooth extraction

---

GRADEMARK REPORT

---

FINAL GRADE

**/0**

GENERAL COMMENTS

**Instructor**

---

PAGE 1

---

PAGE 2

---

PAGE 3

---

PAGE 4

---

PAGE 5

---

PAGE 6

---