



## Source details

### Gynecology and Minimally Invasive Therapy

Open Access ⓘ

Scopus coverage years: from 2012 to Present

Publisher: Wolters Kluwer Health

ISSN: 2213-3070 E-ISSN: 2213-3089

Subject area: Medicine: Obstetrics and Gynecology

Source type: Journal

CiteScore 2021 ⓘ  
**1.7**

SJR 2021 ⓘ  
**0.373**

SNIP 2021 ⓘ  
**0.875**

[View all documents >](#) [Set document alert](#) [Save to source list](#) [Source Homepage](#)

[CiteScore](#) [CiteScore rank & trend](#) [Scopus content coverage](#)

#### i Improved CiteScore methodology ×

CiteScore 2021 counts the citations received in 2018-2021 to articles, reviews, conference papers, book chapters and data papers published in 2018-2021, and divides this by the number of publications published in 2018-2021. [Learn more >](#)

#### CiteScore 2021 ▼

$$1.7 = \frac{308 \text{ Citations 2018 - 2021}}{182 \text{ Documents 2018 - 2021}}$$

Calculated on 05 May, 2022

#### CiteScoreTracker 2022 ⓘ

$$1.3 = \frac{232 \text{ Citations to date}}{175 \text{ Documents to date}}$$

Last updated on 05 July, 2022 - Updated monthly

#### CiteScore rank 2021 ⓘ

Category	Rank	Percentile
Medicine		
Obstetrics and Gynecology	#115/188	39th

[View CiteScore methodology >](#) [CiteScore FAQ >](#) [Add CiteScore to your site](#)

**Communication Studies**

Explore free-to-view research

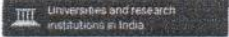
Review of Communication, Volume 21, Issue 4 (2021)

Instant access

OPEN

**Gynecology and Minimally Invasive Therapy**

COUNTRY	SUBJECT AREA AND CATEGORY	PUBLISHER	H-INDEX
India	Medicine Obstetrics and Gynecology	Wolters Kluwer Medknow Publications	<b>14</b>



PUBLICATION TYPE	ISSN	COVERAGE	INFORMATION
Journals	22133070, 22133089	2012-2021	Homepage How to publish in this journal gmit.apage@gmail.com

**SCOPE**

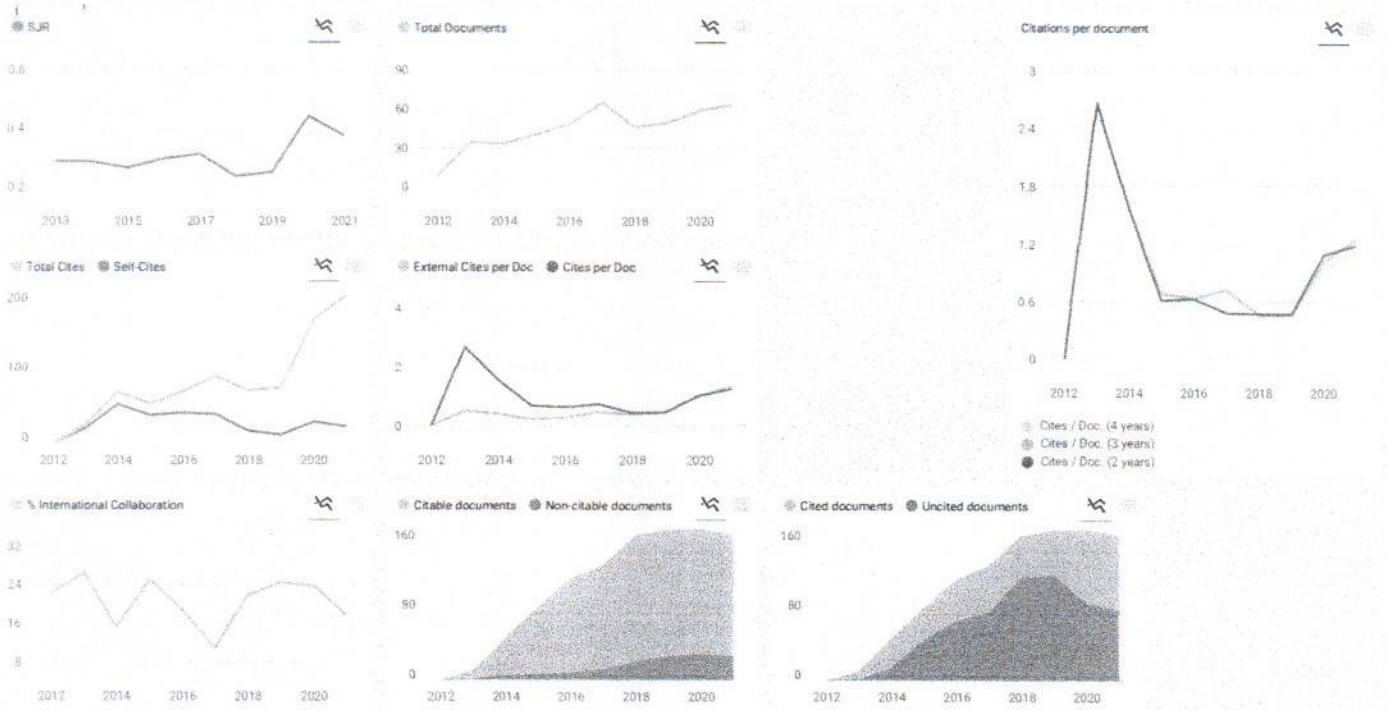
*Gynecology and Minimally Invasive Therapy (GMIT) is the official peer-reviewed journal of APAGE in 2012, and publish quarterly GMIT publishes original research and review papers on minimally invasive therapies in women's health and related scientific fields of study. In 2015, GMIT began working with APAGE ASurg to provide a collection of medical and surgical videos online, searchable and categorized. This journal allows practical physicians to view or share the latest innovation and operative instructions with high-quality multimedia content of clear practical and educational value.*

Join the conversation about this journal

Quartiles

**FIND SIMILAR JOURNALS**

Journal of Minimally Invasive Gynecology	Gynecological Surgery	Journal of Gynecologic Surgery	Gynecologic and Obstetric Investigation	Journal of Gynecology Obstetrics and Human
79%	70%	65%	49%	49%



Gynecology and Minimally Invasive Therapy



Show this widget in your own website

Just copy the code below and paste within your html code.  
 <a href="https://www.scimagojr.com/journalsearch.php?q=21100317204&tip">https://www.scimagojr.com/journalsearch.php?q=21100317204&tip</a>

SCImago Graphica

Explore, visually communicate and make sense of data with our new data visualization tool.



Metrics based on Scopus® data as of April 2022

**Shaimaa** @shaimaah

I need to publish my research how much the cost and the time factor to get the acceptance letter

Reply



**Elena Corera** @elencorera

SCImago Team

Dear Shaimaa,

thank you very much for your comment, unfortunately we cannot help you with your request. We suggest you check author's instructions in journal website. You can find that information in SJR website <https://www.scimagojr.com>

Best Regards,  
 SCImago Team

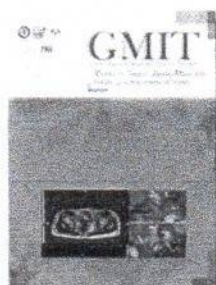
Leave a comment

Name

Email



## Table of Contents



January-March 2022  
Volume 11 | Issue 1  
Page Nos. 1-79


Online since Monday, February 14, 2022

Accessed 18,983 times.

### PDF access policy

Journal allows immediate open access to content in  
HTML + PDF

 View issue as eBook

 Issue statistics

 RSS

[Next Issue](#)

[Previous Issue](#)

[SUBMIT ARTICLE](#)

[POPULAR ARTICLES](#)

[JOIN AS REVIEWER](#)

[GET EMAIL ALERTS](#)

[RECOMMEND](#)

[Show all abstracts](#) [Show selected abstracts](#) [Export selected to](#) [Add to my list](#)

### PERSPECTIVE ARTICLE



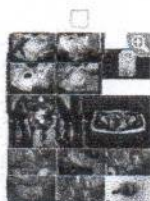#### A proposed high-intensity focused ultrasound training program in Hong Kong

p. 1

W S Felix Wong, Peng Hao Wong, Man Hin Lee, Thomas Li, Lian Zhang, Chyi-Long Lee  
DOI:10.4103/GMIT.GMIT\_40\_21

[ABSTRACT] [HTML Full text] [PDF] [Mobile Full text] [EPub] [Sword Plugin for Repository]<sup>Beta</sup>

### REVIEW ARTICLE



#### Successful Management of a Noncommunicating Rudimentary Uterine Horn Pregnancy by Laparoscopic Surgery: A Case Report and Literature Review

p. 7

Wataru Isono, Akira Tsuchiya, Michiko Honda, Ako Saito, Hiroko Tsuchiya, Reiko Matsuyama, Akihisa Fujimoto, Osamu Nishii  
DOI: 10.4103/GMIT.GMIT\_157\_20

[ABSTRACT] [HTML Full text] [PDF] [Mobile Full text] [EPub] [Sword Plugin for Repository]<sup>Beta</sup>

### ORIGINAL ARTICLES

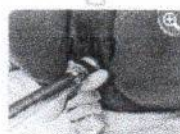

#### The impact of laparoscopic versus laparotomy for lymphovascular space invasion of early cervical cancer: A multicenter retrospective study

p. 17

Wei Huang, Yina Wang, Fanchun Yang, Ning Luo, Guihai Ai, Yuliang Wu, Zhongping Cheng  
DOI:10.4103/GMIT.GMIT\_121\_20

[ABSTRACT] [HTML Full text] [PDF] [Sword Plugin for Repository]<sup>Beta</sup>

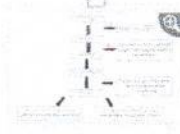


#### Treating vaginal relaxation syndrome using erbium: Yttrium aluminum garnet fractional laser: A retrospective study

p. 23

Trisnartami Setyaningrum, Brahma Askandar Tjokroprawiro, M Yulianto Listiawan, Budi Santoso, Cita Rosita Sigit Prakoeswa  
DOI:10.4103/GMIT.GMIT\_141\_20

[ABSTRACT] [HTML Full text] [PDF] [Sword Plugin for Repository]<sup>Beta</sup>



#### Severity of cystocele and risk factors of postoperative stress urinary incontinence after laparoscopic sacrocolpopexy for pelvic organ prolapse

p. 28

Hirotsuka Sato, Hirokazu Abe, Atsushi Ikeda, Tomoaki Miyagawa, Sachiyo Tsukada  
DOI:10.4103/GMIT.GMIT\_2\_21

[ABSTRACT] [HTML Full text] [PDF] [Mobile Full text] [EPub] [Sword Plugin for Repository]<sup>Beta</sup>



#### Spectrum of Ectopic Pregnancies at a Tertiary Care Center of Northern India: A Retrospective Cross-sectional Study

p. 36

Manju Lata Verma, Uma Singh, Vandana Solanki, Rekha Sachan, Pushp Lata Sankhwar  
DOI:10.4103/GMIT.GMIT\_1\_21

[ABSTRACT] [HTML Full text] [PDF] [Mobile Full text] [EPub] [Sword Plugin for Repository]<sup>Beta</sup>



#### Assessment of pain at different steps of diagnostic hysteroscopy using room temperature normal saline versus warmed normal saline solution as distension medium: A randomized controlled trial

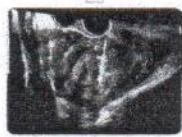p. 41

Shikha Sharma, Kallol Kumar Roy, Rakhi Rai, Rinchen Zangmo, Neena Malhotra, Anamika Das

DOI: 10.4103/GMIT.GMIT\_5\_21

[ABSTRACT] [HTML Full text] [PDF] [Mobile Full text] [EPub] [Sword Plugin for Repository]<sup>Beta</sup>

## SHORT COMMUNICATION

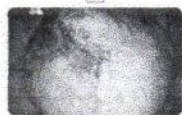**Ultrasound-guided needle biopsy for preoperative assessment of uterine fibroids: Our experience and a review of the literature** p. 47

Carlo Alboni, Ludovica Camacho Mattos, Stefania Malmusi, Maria Cristina Galassi, Fabio Facchinetti, Mohamed Mabrouk

DOI: 10.4103/GMIT.GMIT\_31\_20

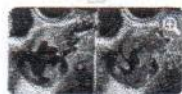[ABSTRACT] [HTML Full text] [PDF] [Mobile Full text] [EPub] [Sword Plugin for Repository]<sup>Beta</sup>

## CASE REPORTS

**Laparoscopic management of a large extragonadal teratoma** p. 51

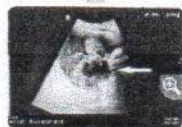Akmal Zulayfa Mohd Zahid, Noorneza Abdul Rahman, Zeti Rahayu Karim, Effat Omar

DOI: 10.4103/GMIT.GMIT\_146\_20

[ABSTRACT] [HTML Full text] [PDF] [Mobile Full text] [EPub] [Sword Plugin for Repository]<sup>Beta</sup>**A Case Report of a Patient with Spontaneously Resolving Unruptured Uterine Artery Pseudoaneurysm after Surgery for Miscarriage during the Early Stages of Pregnancy Using Manual Vacuum Aspiration** p. 54

Toshiyuki Kakinuma, Kaoru Kakinuma, Yoshimasa Kawarai, Tomoyuki Ohta, Michitaka Ohwada, Hirokazu Tanaka, Kaoru Yanagida

DOI: 10.4103/GMIT.GMIT\_33\_20

[ABSTRACT] [HTML Full text] [PDF] [Mobile Full text] [EPub] [Sword Plugin for Repository]<sup>Beta</sup>**An unusual presentation of a corpus luteum rupture** p. 57

Parth Godhiwala, Himanshi Agarwal, Sourya Acharya, Neema Acharya, Vivek Lahane

DOI: 10.4103/GMIT.GMIT\_135\_20

[ABSTRACT] [HTML Full text] [PDF] [Sword Plugin for Repository]<sup>Beta</sup>**Diagnostic laparoscopy for ovarian tumor due to salmonella infection** p. 61

Tamaki Tanaka, Yoshiaki Ota, Rikiya Sano, Koichiro Shimoya, Takuya Moriya, Mitsuru Shiota

DOI: 10.4103/GMIT.GMIT\_92\_20

[ABSTRACT] [HTML Full text] [PDF] [Mobile Full text] [EPub] [Sword Plugin for Repository]<sup>Beta</sup>**Giant Nabothian Cyst Mimicking a Huge Cervical Fibroid: Challenging Aspects in Laparoscopic Hysterectomy** p. 64

Devi Balasubramaniam, Saranya Ravi, Kavitha Yogini

DOI: 10.4103/GMIT.GMIT\_47\_20

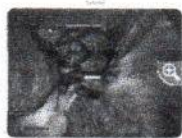[ABSTRACT] [HTML Full text] [PDF] [Mobile Full text] [EPub] [Sword Plugin for Repository]<sup>Beta</sup>**Incidentally diagnosed type 2 Youssef's syndrome with migrated postcesarean postpartum intrauterine contraceptive device** p. 67

Vibha Mishra, Himanshu Pandey, Shashank Shekhar, Charu Sharma

DOI: 10.4103/GMIT.GMIT\_107\_20

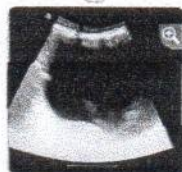[ABSTRACT] [HTML Full text] [PDF] [Mobile Full text] [EPub] [Sword Plugin for Repository]<sup>Beta</sup>

## CLINICAL IMAGES

**Isolated fallopian tube torsion with gangrenous necrosis** p. 70

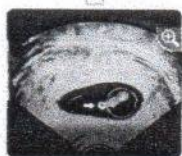
Abu Atileh Luay, Shazia Khan, Kuan- Gen Huang

DOI: 10.4103/GMIT.GMIT\_106\_20

[HTML Full text] [PDF] [Mobile Full text] [EPub] [Sword Plugin for Repository]<sup>Beta</sup>**A rare case of cystic degenerated fibroid masquerading as an ovarian mass** p. 71

Vijayan Sharmila, Thirunavukkarasu Arun Babu

DOI: 10.4103/GMIT.GMIT\_16\_21

[HTML Full text] [PDF] [Mobile Full text] [EPub] [Sword Plugin for Repository]<sup>Beta</sup>**Calcified yolk sac appearance: From sonography to embryoscopy** p. 74

António De Pinho, Elisa Soares, Ana Portela Carvalho, Cristina Oliveira

DOI: 10.4103/GMIT.GMIT\_30\_21

[HTML Full text] [PDF] [Mobile Full text] [EPub] [Sword Plugin for Repository]<sup>Beta</sup>

VIDEO ARTICLE



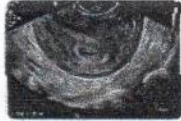**Laparoscopic excision of severe deep infiltrating endometriosis**

p. 76

Hnin Thazin Htut, Hsin- Mei Liu, Chyi- Long Lee

DOI:10.4103/GMIT.GMIT\_26\_21

[HTML Full text] [PDF] [Mobile Full text] [EPub] [Sword Plugin for Repository]<sup>Beta</sup>



**Hysteroscopy is a useful diagnostic and therapeutic tool for the treatment of angular pregnancy**

p. 78

Jody Paige Goh, Zheng Yuan Ng, Mohamed Siraj Shahul Hameed

DOI:10.4103/GMIT.GMIT\_120\_20

[ABSTRACT] [HTML Full text] [PDF] [Mobile Full text] [EPub] [Sword Plugin for Repository]<sup>Beta</sup>

## Editorial Board

### Editor-in-Chief

Chyi-Long Lee, M.D., Ph.D.,  
 Professor,  
 Department of Obstetrics and Gynecology,  
 Chang Gung Memorial Hospital at Linkou and Chang Gung University College of Medicine,  
 Taoyuan, Taiwan  
 Email: gmit.Chyilonglee@gmail.com

### Associate Editor-in-Chief

Zhongping Cheng, M.D., Ph.D.,  
 Professor,  
 Department of Obstetrics and Gynecology,  
 Shanghai Tenth People's Hospital, Tongji University,  
 Shanghai, China

Bernard Chern, M.D.,  
 Chairman,  
 Division of Obstetrics and Gynaecology,  
 KK Women's and Children's Hospital,  
 Singapore

Akira Iwase, M.D., Ph.D.,  
 Professor,  
 Department of Obstetrics and Gynecology,  
 Gunma University Graduate School of Medicine,  
 Gunma, Japan

Peng-Hui Wang, M.D., Ph.D.,  
 Professor,  
 Department of Obstetrics and Gynecology,  
 National Yang-Ming University, Taipei Veterans General Hospital,  
 Taipei, Taiwan

### Managing Editor

Chih-Feng Yen, M.D., Ph.D.,  
 Associate Professor,  
 Department of Obstetrics and Gynecology,  
 Chang Gung Memorial Hospital,  
 Taoyuan, Taiwan

### Associate Managing Editor

Deh-Ching Ding, M.D., Ph.D.,  
 Professor,  
 Department of Obstetrics and Gynecology,  
 Buddhist Tzu Chi General Hospital and Tzu Chi University,  
 Hualien, Taiwan

### Editorial Board

Duk-Soo Bae, M.D., Ph.D.,  
 Professor,  
 Department of Obstetrics and Gynecology,  
 Samsung Medical Center, Sungkyunkwan University School of Medicine,  
 Seoul, South Korea

Maria Jesusa Banal-Silao, M.D., F.P.O.G.S., F.P.S.R.E.I., F.P.S.G.E., F.P.S.U.O.G.,  
 Associate Professor,  
 Department of Obstetrics and Gynecology,  
 University of the Philippines-Philippine General Hospital,  
 Manila, Philippines

Joong Sub Choi, M.D., Ph.D.,  
 Professor,  
 Department of Obstetrics and Gynecology,  
 Hanyang University Medical Center,

### About the journal

[SUBMIT ARTICLE](#)
[POPULAR ARTICLES](#)
[JOIN AS REVIEWER](#)
[GET EMAIL ALERTS](#)
[RECOMMEND](#)



Seoul, South Korea

Danny Chou, M.D.,  
Department of Obstetrics and Gynecology,  
St. George Private Hospital,  
Kogarah, Australia

Hua Duan, M.D., Ph.D.  
Professor,  
Beijing Obstetrics and Gynecology Hospital and Capital Medical University,  
Beijing, China

Wai-leng Fong, M.D.,  
Department of Obstetrics and Gynecology,  
Centro Hospitalar Conde de São Januário,  
Macau, China

Teófilo Guerra, M.D.,  
Department of Obstetrics and Gynecology,  
University Hospital of Valley d'Hebron,  
Barcelona, Spain

Bianca C. De Guia, M.D.,  
Department of Obstetrics and Gynecology,  
University of the Philippines-Philippine General Hospital,  
Manila, Philippines

Maria Antonia E. Habana, M.D., MSc, F.P.O.G.S., F.P.S.R.M., F.P.S.G.E.,  
Professor  
Department of Obstetrics and Gynecology,  
University of the Philippines College of Medicine,  
Manila, Philippines

Wachyu Hadisa Putra, M.D., Ph.D.,  
Professor,  
University of Indonesia,  
Jakarta, Indonesia

Kuan-Gen Huang, M.D.,  
Assistant Professor,  
Department of Obstetrics and Gynecology,  
Chang Gung Memorial Hospital and Chang Gung University,  
Taoyuan, Taiwan

Kuan-Hui Huang, M.D.,  
Assistant Professor,  
Department of Obstetrics and Gynecology,  
Kaohsiung Chang Gung Memorial Hospital and Shu-Zen Junior College of Medicine and Management,  
Kaohsiung, Taiwan

Amruta Jaiswal, M.D.,  
Department of Obstetrics and Gynecology,  
India Health Action Trust,  
Karnataka, India

Somchai Kovitchareonkul, M.D.,  
The Bangkok Christian Hospital,  
Bangkok, Thailand

Byung Seok Lee, M.D., Ph.D.,  
Professor,  
Department of Obstetrics and Gynecology,  
Yonsei University College of Medicine,  
Seoul, South Korea

Zhiqing Liang, M.D., Ph.D.  
Professor,  
Department of Obstetrics and Gynecology,  
Southwest Hospital and Third Military Medical University,  
Chongqing, China

Cheng Yu Long, M.D., Ph.D.,  
Professor,  
Department of Obstetrics and Gynecology,  
Kaohsiung Municipal Hsiao-Kang Hospital and Kaohsiung Medical University Memorial Hospital,  
Kaohsiung, Taiwan

Jeffrey Low, F.R.A.N.Z.C.O.G., F.R.C.O.G., M.Med.(O&G), F.A.M.S.(O&G),  
Associate Professor,  
Department of Obstetrics and Gynecology,  
National University Hospital,  
Singapore

Javier F. Magriña, M.D.,  
Professor of Obstetrics-Gynecology,  
Mayo Clinic-Phoenix,

Arizona, USA

Peter J. Maher, M.B.B.S., F.R.A.N.Z.C.O.G., F.R.C.O.G.,  
Clinical Professor,  
Department of Obstetrics and Gynaecology,  
Mercy Hospital for Women, University of Melbourne,  
Melbourne, Australia

Hirotsuka Nishi, M.D., Ph.D.,  
Professor,  
Department of Obstetrics and Gynecology,  
Tokyo Medical University,  
Tokyo, Japan

Doris Ng, M.B.Ch.B, F.H.K.A.M., F.H.K.C.O.G., M.R.C.O.G.  
Department of Obstetrics and Gynecology,  
Union Hospital,  
Hong Kong

Carlos Fernandez Ossadey, M.D.,  
Clínica Las Condes,  
Santiago, Chile

Alaa Owais, M.D.,  
Assistant professor,  
Department of Obstetrics and Gynecology,  
Muta university,  
Karak, Jordan

Hyung Moo Park, M.D, Ph.D.,  
College of Medicine, Chung-Ang University,  
Seoul, Korea

Osama Shawki, M.D.,  
Professor,  
Department of Obstetrics and Gynecology,  
Cairo University,  
Giza, Egypt

Tanitra Tantitamit, M.D.,  
Department of Obstetrics and Gynecology,  
HRH Princess Maha Chakri Sirindhorn Medical Center,  
Nakornnayok, Thailand

Rakesh Sinha, M.D.,  
Beams Hospitals Private Limited,  
Mumbai, India

Pao-Ling Torng, M.D., Ph.D.,  
Associate Professor,  
Department of Obstetrics and Gynecology,  
National Taiwan University Hospital and National Taiwan University,  
Taipei, Taiwan

Rafael F. Valle, M.D.,  
Professor,  
Department of Obstetrics and Gynecology,  
Northwestern University Feinberg School of Medicine,  
Chicago, Illinois, USA

Keong Wong, M.D.,  
Department of Obstetrics and Gynecology,  
Centro Hospitalar Conde de Sao Januario,  
Macau, China

Ming-Ping Wu, M.D., Ph.D.,  
Associate Professor,  
Department of Obstetrics & Gynecology,  
Chi Mei Foundation Hospital, College of Medicine, Taipei Medical University,  
Tainan, Taiwan

Jehn-Hsiahn Yang, M.D.,  
Professor,  
Department of Obstetrics & Gynecology,  
National Taiwan University,  
Taipei, Taiwan

#### Advisory Editorial Board

Gautam Nand Alahbadia, M.D., D.N.B., F.N.A.M.S.,  
Consultant Reproductive Medicine & Infertility,  
MMC Millennium Medical Center LLC (MMC IVF),  
Dubai, United Arab Emirate

Chih-Ping Chen, M.D., Ph.D.,  
Professor  
Department of Obstetrics & Gynecology,

MacKay Memorial Hospital, National Yang-Ming University,  
Taipei, Taiwan

Yasuyoshi Hayashi, M.D., Ph.D.,  
Professor,

Department of Obstetrics & Gynecology,  
Kawasaki Municipal Hospital,  
Kawasaki, Japan

Jinghua Leng, M.D.,  
Professor,

Department of Obstetrics and Gynecology,  
Peking Union Medical College Hospital,  
Beijing, China

Eric Tat Choi Lee, M.B.B.S., M.R.C.O.G., F.R.C.O.G.,

Department of Obstetrics and Gynecology,  
Cancer Hospital (Caritas),  
Hong Kong, China

Keen Whye Lee, M.D.,

Department of Obstetrics and Gynecology,  
KW Lee Clinic and Surgery for Women,  
Singapore

Wu-Chow Lin, M.D.,

Assistant Professor,  
Department of Obstetrics and Gynecology,  
China Medical University Hospital, Medicine in China Medical University,  
Taichung, Taiwan

C.Y. Liu, M.D.,

Department of Obstetrics and Gynecology,  
Chattanooga Women's Laser Center,  
Chattanooga, Tennessee, USA

Prashant Mangeshkar, M.D., M.B.B.S.,

Professor,  
Department of Obstetrics and Gynecology,  
Center for Gynecological Endoscopic Surgery, Bombay Hospital,  
Mumbai, India

Takeshita Murakami, M.D., Ph.D.,

Professor,  
Department of Obstetrics and Gynecology,  
Shiga University of Medical Science,  
Shiga, Japan

Joo-Hyun Nam, M.D., Ph.D.,

Professor,  
Department of Obstetrics and Gynecology,  
University of Ulsan Asan Medical Center,  
Seoul, South Korea

Yutaka Oeuga, M.D., Ph.D.,

Professor,  
Department of Obstetrics and Gynecology,  
The University of Tokyo,  
Tokyo, Japan

Mitsuru Shiota, M.D., Ph.D.,

Professor,  
Department of Obstetrics and Gynecology,  
Kinki University Faculty of Medicine,  
Osaka, Japan

Angela G. Sison-Aguilar, M.D., M.B.A.(Health), F.P.O.G.S., F.P.S.R.E.I., F.I.F.E.P.A.G., F.P.S.G.E.,

Associate Professor,  
Department of Obstetrics and Gynecology,  
University of the Philippines-Philippine General Hospital,  
Manila, Philippines

Sevellaraja Supermaniam, M.D.,

Department of Obstetrics and Gynecology,  
Mahkota Medical Centre,  
Melaka, Malaysia

Toshiyuki Takeshita, M.D., Ph.D.,

Professor,  
Department of Obstetrics and Gynecology,  
Nippon Medical School Hospital,  
Tokyo, Japan

Osamu Tsutsumi, M.D., Ph.D.,

Professor,  
Department of Obstetrics and Gynecology,

Sanno Hospital,  
Tokyo, Japan

Togas Tulandi, M.D., F.R.C.S.C., F.A.C.O.G.,  
Professor,  
Department of Obstetrics and Gynecology,  
McGill University, Jewish General Hospital,  
Montreal, Quebec, Canada

Wu Shun Felix Wong, M.D.,  
Professor,  
Department of Obstetrics and Gynecology,  
The University of New South Wales, Women & Babies Medical Centre,  
Hong Kong, China

Enlan Xia, M.D., Ph.D.,  
Professor,  
Department of Obstetrics and Gynecology,  
Fu Xing Hospital, Capital Medical University,  
Beijing, China



Pong-Mo Yuen, F.R.C.O.G.,  
Department of Obstetrics and Gynecology,  
Hong Kong Sanatorium and Hospital,  
Hong Kong, China

© Gynecology and Minimally Invasive Therapy | Published by Wolters Kluwer - Medknow

[Sitemap](#) | [What's New](#) | [Feedback](#) | [Disclaimer](#) | [Privacy Notice](#) | [FAQ](#)

Online since 20<sup>th</sup> February 2018

[Editorial and Ethics Policies](#)

 **Open Access**  **No Fee** [View mobile site](#)

ISSN: Print - 2213-3070, Online - 2213-3099

# Treating Vaginal Relaxation Syndrome Using Erbium: Yttrium Aluminum Garnet Fractional Laser: A Retrospective Study

Trisniartami Setyaningrum<sup>1,2</sup>, Brahmana Askandar Tjokropawiro<sup>3\*</sup>, M. Yulianto Listiawan<sup>2</sup>, Budi Santoso<sup>3</sup>, Cita Rosita Sigit Prakoeswa<sup>2</sup>

<sup>1</sup>Post Graduate Doctoral Program, Faculty of Medicine, Universitas Airlangga, Departments of <sup>2</sup>Dermatology and Veneorolgy and <sup>3</sup>Obstetric and Gynecology, Faculty of Medicine, Dr. Soetomo General Academic Hospital, Universitas Airlangga, Surabaya, Indonesia

## Abstract

**Objectives:** Vaginal relaxation syndrome (VRS) comprises vaginal laxity and stress urinary incontinence (SUI). Laser vaginal tightening (LVT) therapy using a fractional erbium:yttrium aluminum garnet (Er:YAG) 2.940 nm laser may represent a nonsurgical option for both complaints. This study evaluates the effectiveness and side effects of fractional Er:YAG laser therapy in VRS patients. The improvement in VRS was evaluated.

**Materials and Methods:** This is a retrospective study analyzing the medical records of patients treated with fractional Er:YAG laser therapy in our private clinic in Surabaya, Indonesia. Objective questions were asked to rate patients' satisfaction with the results of the therapy, namely dissatisfaction, and mild, moderate, or strong satisfaction. Statistical analysis used, data were input into tables in Microsoft Excel.

**Results:** Twenty-four VRS patients (54% with vaginal laxity, 33% with SUI, and 13% with vaginal laxity and SUI) were studied. Most of the patients were 36–45-year-old and had 2 children, and 79% of the patients had had a vaginal delivery. After 3 LVTs, mild satisfaction was observed in 15% of patients, moderate satisfaction was noted in 54% of patients, and high satisfaction was noted in 31% of patients. Among 11 patients with SUI, 36% recovered after the first LVT, and 100% recovered after the second LVT therapy. One patient experienced mild fluor albus as a side effect.

**Conclusion:** LVT therapy with a fractional Er:YAG laser was determined to be effective and safe as a treatment for VRS.

**Keywords:** Erbium:yttrium aluminum garnet fractional laser, stress urinary incontinence, vaginal laxity, vaginal relaxation syndrome

## INTRODUCTION

Vaginal relaxation syndrome (VRS) involves loosening of the vagina (vaginal laxity) as women age (menopause) and is also influenced by pregnancy and multiple vaginal deliveries.<sup>[1]</sup> VRS is described as a medical condition, in which one experiences the loss of optimal vaginal structure. Patients typically present with vaginal laxity or loss of vaginal tightness, which causes reduced friction during sexual intercourse, resulting in decreased or loss of sexual satisfaction both in women and partners.<sup>[1,2]</sup>

The exact incidence of VRS is unclear but is estimated to be approximately 25%–63% in sexually active adults.<sup>[3]</sup> Vaginal laxity is experienced by 38% of women and is related to parity,

symptoms of prolapse and stress urinary incontinence (SUI), decreased vaginal sensation, and worsening sexual experience.<sup>[4]</sup> The international urogynecologist association conducted a survey of members around Europe, North America, South America, Asia, Australia, and Africa. The survey revealed that 83% of patients had complaints of vaginal laxity, and 95% claimed that this condition impairs their sexual activity.<sup>[5]</sup>

Various known VRS therapies are available, ranging from Kegel exercises and pharmacological agents (hormonal,

**Address for correspondence:** Dr. Brahmana Askandar Tjokropawiro, Department of Obstetric and Gynecology, Faculty of Medicine, Dr. Soetomo General Academic Hospital, Universitas Airlangga, Jl. Prof. Dr. Moestopo 47, Surabaya 60132, East Java, Indonesia. E-mail: brahmanaaskandar@gmail.com

### Article History:

Submitted: 08-Dec-2020

Revised: 20-Apr-2021

Accepted: 06-May-2021

Published: 14-Feb-2022

### Access this article online

#### Quick Response Code:



Website:  
[www.e-gmit.com](http://www.e-gmit.com)

DOI:  
10.4103/GMIT.GMIT\_141\_20

This is an open access journal, and articles are distributed under the terms of the Creative Commons Attribution-NonCommercial-ShareAlike 4.0 License, which allows others to remix, tweak, and build upon the work non-commercially, as long as appropriate credit is given and the new creations are licensed under the identical terms.

**For reprints contact:** WKHLRPMedknow\_reprints@wolterskluwer.com

**How to cite this article:** Setyaningrum T, Tjokropawiro BA, Listiawan MY, Santoso B, Prakoeswa CR. Treating vaginal relaxation syndrome using erbium: Yttrium aluminum garnet fractional laser: A retrospective study. *Gynecol Minim Invasive Ther* 2022;11:23-7.

cream, or tightening spray) to minimally invasive and invasive surgical approaches. Surgical procedures offer satisfactory results; however, these procedures are associated with more risks, such as scar tissue, nerve damage, and loss of sensation. Furthermore, patients who undergo surgical procedures need longer recovery times. This concern encourages clinical researchers to develop noninvasive or minimally invasive methods with good efficacy and safety as well as shorter recovery periods for VRS therapy.<sup>[1,6,7]</sup>

Recently, laser therapy has been proposed as an alternative surgery-related method for VRS given its ability to minimize deep tissue damage. Laser therapy utilizes a specific wavelength that is highly water absorbent, namely, a CO<sub>2</sub> (10,600 nm) laser and an erbium: yttrium aluminum garnet (Er:YAG) (2940 nm) laser. The use of produced energy that is fractionated into microbeams (fractional) results in better control, therefore achieving better success and shorter recovery period; this procedure is widely known as laser vaginal tightening (LVT). LVT therapy aims to restore the quality of vaginal muscles by tightening the complex structures that support the vulvovaginal area.<sup>[8,9]</sup>

The use of LVT therapy is popular for VRS; likewise, we applied this method for VRS patients in our private clinic. To date, in Indonesia, there have been no reports on the outcome of LVT therapy in VRS focused on vaginal laxity or SUI or regarding patient satisfaction, effectiveness, or safety. This retrospective study aims to evaluate the effectiveness and safety of LVT therapy with a fractional Er:YAG laser at 2940 nm in VRS patients in our private clinic. The effectiveness is appraised based on the number of patients who sought repeated therapy, patient satisfaction based on interviews during follow-up sessions, and the improvement of SUI in this study.

## MATERIALS AND METHODS

Ethical clearance was obtained with reference number 0094/LOE/301.4.2/VIII/2020. Consent was obtained from the patients.

### Study design and patients

This retrospective descriptive study collected data from the medical records of patients who were treated for VRS with LVT therapy at a private clinic between 2014 and 2019.

The study enrolled 24 patients who presented with symptoms of vaginal laxity, SUI, or vaginal laxity and SUI. Inclusion criteria were patients who underwent fractional Er:YAG laser treatment of the vagina and had complete medical reports. Patients were excluded if their medical records were incomplete.

### Treatment procedure

One doctor performed all laser therapies. A fractional Er:YAG 2940 nm laser (Intimalase® XS Dynamis, Fotona, Slovenia)

was used to perform laser therapy on the vaginal mucosa. The patient's vagina was examined using a speculum, and the vaginal canal and vaginal introitus were then disinfected using betadine. Topical anesthesia was administered to the vaginal opening for 5 min.

The laser, consisting of an R11 hanpiece and circular GC adapter [Figure 1], was then attached to specially designed speculum and inserted into the vagina. The laser parameters were 3 J/cm<sup>2</sup> fluence, 7 mm spot size, 1.6 Hz frequency, and three passes for the vagina. The speculum was removed, and using a PS03 handpiece with a standard strait adapter [Figure 2], the laser was applied to the vaginal introitus with a fluence of 10 J/cm<sup>2</sup>, 2 mm spot size, 1.6 Hz frequency, and one pass. No follow-up therapy was conducted after initial laser therapy, which was completed in approximately 5 min.

Following the therapy, the patient was instructed not to have sexual intercourse for 7 days and was scheduled for a follow-up laser treatment 1 month later to see the result of the treatment. LVT was performed once, twice, and three times. No medication was given post therapy.

### Patient satisfaction

We assessed patient satisfaction of the laser therapy by asking patients questions about their satisfaction with their vaginal tightness, namely if there was a sense of dissatisfaction or satisfaction (graded as mild, moderate, or strong satisfaction). Dissatisfaction was defined to be no change experienced by the patient after laser therapy; mild satisfaction if more friction or sensation was experienced during sexual intercourse; moderate satisfaction if there was more friction, sensation and a better orgasm; and strong satisfaction if there was friction, strong sensation, and more orgasms experienced during sexual intercourse. Participants were approached face to face.

### Statistical analysis

The acquired data were input into Microsoft Excel tables and analyzed.

## RESULTS

From the obtained data, this study comprised 24 subjects with VRS. The subjects' ages ranged from 29 to 63 years, and the majority was aged between 36 and 45 years (55%). Most children were housewives (71%). Most children had 2 children. Specifically, 14 children (60%) had 2 children, whereas 16% of subjects had 3 children. The most common type of childbirth was vaginal delivery, which was noted in 79% of children. The most common complaint was vaginal laxity in 54% of subjects. Other complaints included SUI in 33% of children and vaginal laxity with SUI in 13% of children. In total, 42% of subjects underwent 3 LVT

treatments. Out of the 24 subjects, 1 complained of the occurrence of mild, nonitching fluor albus after the first LVT. On examination, there was a minimum amount of colorless, nonitching fluor albus [Table 1].

Of these 24, three patients did not return for follow-up and could not be contacted. Among these three patients, the initial main complaint was vaginal laxity [Table 2]. Of the remaining 21 patients who returned for follow-up after 1 LVT, 14 complained of vaginal laxity, and 11 complained of SUI. Among the 14 patients who complained of vaginal laxity, one patient claimed no improvement, 4 reported mild satisfaction, 6 noted moderate satisfaction, and 3 indicated high stated satisfaction [Table 3]. Among those with complaints of SUI (11 patients), 2 claimed that the complaint remained, five patients experienced improvement, and three patients recovered [Table 4].

Among the patients who underwent 2 LVTs, four patients did not return and could not be contacted [Table 2]. These four patients had the initial complaint of vaginal laxity with subsequent mild satisfaction in two patients and improvement of SUI in two patients. Of the 13 patients who returned for follow-up, 12 patients complained of vaginal laxity, and five patients complained of SUI. Among the 12 patients with vaginal laxity, two patients recovered from SUI after the first LVT; however, they returned for the second LVT due to newly occurring vaginal laxity [Table 3]. After the second LVT, the patients' satisfaction in terms of vaginal tightness was moderate in eight patients and high in two patients. The aforementioned five patients with SUI all recovered after the second LVT [Table 4].

There were 13 VRS patients who underwent 3 LVTs. All of these patients underwent follow-up. Among these 13 patients, there were 13 complaints. In terms of vaginal tightness, two patients claimed mild, 7 claimed moderate, and 4 claimed high satisfaction [Table 3].

## DISCUSSION

In this study, most subjects were of reproductive age. It is estimated that 25%–63% of the sexually active adult population experiences vaginal laxity.<sup>[3]</sup> The damage to the optimal vaginal structure in VRS is mainly due to pregnancy and repeated vaginal delivery.<sup>[10]</sup> This study evaluated LVT therapy in VRS patients who complained of vaginal laxity and/or SUI. The LVT outcomes that will be discussed are those after one, two, and three rounds of therapy. Most patients presented with the complaint of vaginal laxity. This finding is in accordance with the pathophysiology of vaginal laxity, in which the vaginal introitus is stretched during vaginal childbirth, resulting in reduced sensation and satisfaction during sexual intercourse.<sup>[11,12]</sup> The pathophysiology is also related to elevated levator muscles, trauma (avulsion), or overdistension of the levator ani muscle.<sup>[11,13]</sup>

**Table 1: Baseline patient data**

	Total	%
Number of VRS patients	24	100
Age:		
26-35 years	7	29
36-45 years	13	55
46-55 years	2	8
56-65 years	2	8
Number of children:		
0	1	4
1	4	16
2	14	60
3	4	16
4	1	4
Type of childbirth:		
Vaginal delivery	38	54
Caesarean section	10	33
Menopausal Status	2	8
Hormon replacement therapy	0	0
Main complaint:		
Vaginal laxity	13	54
SUI	8	33
Vaginal laxity and SUI	3	13
Number of LVT procedure:		
1	7	29
2	4	17
3	10	42
6	2	8
8	1	4

**Table 2: VRS patients who underwent 1, 2, or 3 LVT procedures**

	1 LVT	2 LVT	3 LVT
Patients who did not return for follow-up	3 (12,5%)	4 (24%)	0 (0%)
Patients who returned for follow-up	21 (87,5%)	13 (76%)	13 (100%)
Total	24 (100%)	17 (100%)	13 (100%)

**Table 3: Complaints of vaginal laxity in patients undergoing follow-up after 1, 2, and 3 LVTs**

	1 LVT	2 LVT	3 LVT
No improvement (vaginal tightness)	1 (7%)	0	0
Mild satisfaction (vaginal tightness)	4 (29%)	0	2 (15%)
Moderate satisfaction (vaginal tightness)	6 (43%)	8 (66%)	7 (54%)
High satisfaction (vaginal tightness)	3 (21%)	2 (17%)	4 (31%)
Newly occurring vaginal laxity	0	2 (17%)	0
Total	14 (100%)	12 (100%)	13 (100%)

Another complaint that was encountered in this study was SUI. SUI represents one of many problems that are related to vaginal laxity and is experienced by 38% of women.<sup>[4]</sup> Most patients underwent LVT three times due to less than expected

initial results and the subsequent need for repeated procedures. Alternatively, patients were advised by the physician to undergo LVT at least thrice to achieve better results with a 1-month interval between procedures.

Out of the VRS patients who underwent 1 and 2 LVTs, 7 children discontinued therapy (did not return for a follow-up), and these four patients could not be contacted. Presumably, the patients were already content with the achieved result or discontinued treatment due to the long distance between their house and the clinic (out of town). Alternatively, these patients may be continuing the therapy somewhere else or discontinued treatment due to the expense.

This finding highlights various levels of outcome in terms of vaginal tightness after 1, 2, and 3 LVTs, in which a large number of patients claimed moderate satisfaction. Repeated LVT suggests that patients were content with the results and willing to maintain vaginal tightness to maintain the quality of their sexual life. A study on 30 Korean women (mean age 41.7 years) with VRS and vaginal atrophy conducted 4 LVT sessions with a 1–2-week interval between sessions. Based on the perineometer and histological biopsy results, a significant increase in vaginal wall relaxation was noted in all children after 2 months of therapy. In terms of vaginal tightening, 70% of children claimed satisfaction, and 70, 6% of partners agreed that there was an improvement in vaginal tightness. Based on

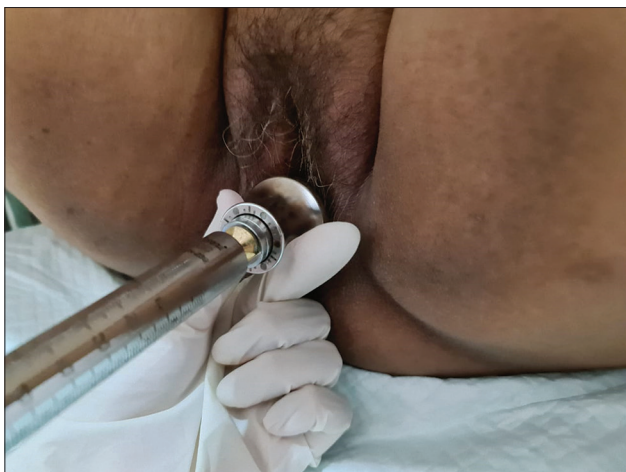histological observation, post-LVT treatment, the epithelium was thicker, and the lamina propria was denser.<sup>[8]</sup> In another study by Gaspar *et al.*, Er:YAG laser therapy was compared to long-term estriol followed by Er:YAG laser therapy in 50 women with vaginal atrophy. Both groups exhibited improvement in vaginal atrophy; however, the results in the laser group were better and longer-lasting.<sup>[14]</sup> The Er:YAG laser interacts with water and subsequently heats tissues until evaporation and ablation occur. The resulting thermal damage to the epidermal and dermal layers stimulates neocollagenesis, tissue rejuvenation, and skin tightening.<sup>[15]</sup>

The complaints of SUI in this study subsided after 1 and 2 LVTs. SUI can be treated using a vaginal erbium laser.<sup>[16]</sup> In a previous study of 175 women diagnosed with SUI, therapy using an Er:YAG laser was performed on 66% of patients, an average of 2.5 times, over a period of 2 months. After each session, patients were subjected to a clinical examination and assessed using the International Consultation on Incontinence Modular Questionnaire, Incontinence Severity Index, and Visual Analog Scale. The results showed a significant improvement in 77% of patients diagnosed with SUI.<sup>[17]</sup> SUI is frequently found in women, in which there is a loss of collagen in the anterior vaginal wall and pubocervical fascia. Collagen is a key element of the pelvic floor that forms >80% of protein and endopelvic fascia.<sup>[18-20]</sup> Er:YAG laser therapy increases tissue temperature, stimulating collagen reforming and neoangiogenesis, leading to the improvement of mild to moderate SUI.<sup>[20]</sup>

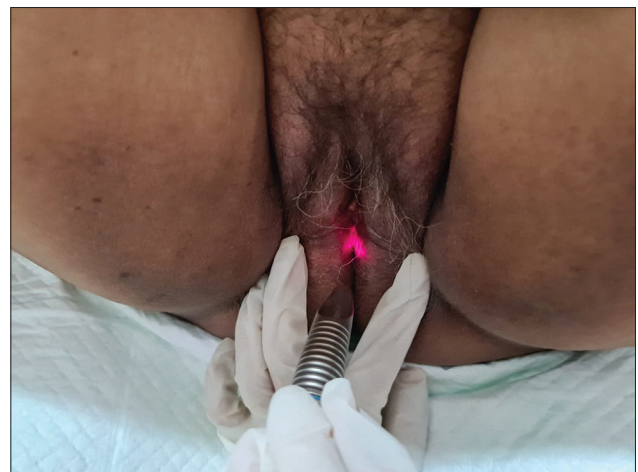
One side effect was noted in this study, namely, a mild, nonitching fluor albus in one patient after the 1<sup>st</sup> LVT. After administration of 100 mg doxycyclin twice a day for 7 weeks, the fluor albus subsided. The observed fluor albus was a nonspecific genital infection, which was possibly due to poor hygiene and sanitation. The fractional Er:YAG laser is

**Table 4: Complaints of SUI in patients undergoing follow-up after 1 and 2 LVTs**

	1 LVT	2 LVT
SUI remains/no improvement	2 (18%)	0
SUI improved	5 (46%)	0
Complete recovery on SUI	4 (36%)	5 (100%)
Total	11 (100%)	5 (100%)



**Figure 1:** Probe of fractional erbium: yttrium aluminium garnet laser for vagina



**Figure 2:** Probe of fractional erbium: yttrium aluminium garnet for vaginal introitus



an ablative laser in which mild wound fractions are induced on the affected mucosal surface; therefore, hygiene is crucial to prevent infection. Theoretically, there are no possible side effects of fractional Er:YAG lasers in vaginal therapy because the fractional Er:YAG laser is less penetrative than the fractional CO<sub>2</sub> laser, thus minimizing side effects. There was a reported case of bleeding and pain during sexual intercourse after CO<sub>2</sub> laser therapy in vaginal laxity treatment.<sup>[21]</sup> The known reported side effect in LVT with a fractional Er:YAG laser was minimal discomfort.<sup>[1]</sup>

## CONCLUSION

Studies of fractional laser therapy on complaints of vaginal laxity, SUI, or both are still rare. This study was limited by the lack of a thorough clinical examination, which could have included histopathology. LVT therapy that utilizes a fractional Er:YAG laser to treat VRS with complaints of vaginal laxity and SUI yielded satisfactory results, in which patients with vaginal laxity who underwent 1–3 LVT procedures claimed contentedness in terms of vaginal tightness, ranging from mild to high satisfaction. In terms of SUI, the patients recovered after the 1<sup>st</sup>–2<sup>nd</sup> LVT. Although mild fluor albus was observed as a side effect, the administration of antibiotics successfully resolved the problem; therefore, this method is considered safe.

## Financial support and sponsorship

Nil.

## Conflicts of interest

There are no conflicts of interest.

## REFERENCES

- Gaviria JE. Vaginal Tightening (LVT) – Evaluation of a novel noninvasive laser treatment for vaginal relaxation syndrome. *J LAHA* 2012;2012:59-66.
- Manzini C, Friedman T, Turel F, Dietz HP. Vaginal laxity: What measure of levator ani distensibility is the most predictive? *Ultrasound Obstet Gynecol* 2019;55:683-7.
- Addis IB, Van Den Eeden SK, Wassel-Fyr CL, Vittinghoff E, Brown JS, Thom DH, *et al.* Sexual activity and function in middle-aged and older women. *Obstet Gynecol* 2006;107:755-64.
- Campbell P, Krychman M, Gray T, Vickers H, Money-Taylor J, Li W, *et al.* Self-reported vaginal laxity-prevalence, impact, and associated symptoms in women attending a urogynecology clinic. *J Sex Med* 2018;15:1515-7.
- Pauls RN, Fellner AN, Davila GW. Vaginal laxity: A poorly understood quality of life problem; a survey of physician members of the International Urogynecological Association (IUGA). *Int Urogynecol J* 2012;23:1435-48.
- Goodman MP. Female genital cosmetic and plastic surgery: A review. *J Sex Med* 2011;8:1813-25.
- Dobbeleir JM, Landuyt KV, Monstrey SJ. Aesthetic surgery of the female genitalia. *Semin Plast Surg* 2011;25:130-41.
- Lee MS. Treatment of vaginal relaxation syndrome with an erbium: YAG laser using 90° and 360° scanning scopes: A pilot study and short-term results. *Laser Ther* 2014;23:129-38.
- Gold M, Andriessen A, Bader A, Alinsod R, French ES, Guerette N, *et al.* Review and clinical experience exploring evidence, clinical efficacy, and safety regarding nonsurgical treatment of feminine rejuvenation. *J Cosmet Dermatol* 2018;17:289-97.
- Kwon TR, Kim JH, Seok J, Kim JM, Bak DH, Choi MJ, *et al.* Fractional CO<sub>2</sub> laser treatment for vaginal laxity: A preclinical study. *Lasers Surg Med* 2018;50:940-7.
- Dietz HP, Wilson PD, Milsom I. Maternal birth trauma: Why should it matter to urogynaecologists? *Curr Opin Obstet Gynecol* 2016;28:441-8.
- Farage MA, Maibach HI. Morphology and physiological changes of genital skin and mucosa. *Curr Probl Dermatol* 2011;40:9-19.
- Kamisan Atan I, Gerges B, Shek KL, Dietz HP. The association between vaginal parity and hiatal dimensions: A retrospective observational study in a tertiary urogynaecological centre. *BJOG* 2015;122:867-72.
- Gaspar A. Comparison of new minimally invasive Er: YAG laser treatment and hormonal replacement therapy in the treatment of vaginal atrophy. *Climacteric* 2014;17:48-108.
- Ibrahim O, Dover JS. Fundamentals of laser and light based treatments. In: Kang S, Amagai M, Bruckner AL, Enk AH, Margolis DJ, McMichael AJ, *et al.*, editors. *Fitzpatrick's Dermatology*. 1. 09<sup>th</sup> ed. New York: McGraw-Hill; 2019. p. 3820-33.
- Gambacciani M, Torelli MG, Martella L, Bracco GL, Casagrande AG, Albertin E, *et al.* Rationale and design for the Vaginal Erbium Laser Academy Study (VELAS): An international multicenter observational study on genitourinary syndrome of menopause and stress urinary incontinence. *Climacteric* 2015;18 Suppl 1:43-8.
- Ogrinc UB, Senčar S, Lenasi H. Novel minimally invasive laser treatment of urinary incontinence in women. *Lasers Surg Med* 2015;47:689-97.
- Keane DP, Sims TJ, Abrams P, Bailey AJ. Analysis of collagen status in premenopausal nulliparous women with genuine stress incontinence. *Br J Obstet Gynaecol* 1997;104:994-8.
- Rechberger T, Postawski K, Jakowicki JA, Gunja-Smith Z, Woessner JF Jr. Role of fascial collagen in stress urinary incontinence. *Am J Obstet Gynecol* 1998;179:1511-4.
- Gambacciani M, Palacios S. Laser therapy for the restoration of vaginal function. *Maturitas* 2017;99:10-5.
- Gordon C, Bell S, Hauser H, Krychman ML. A case series of patient complications following vaginal laser treatment for atrophy [17M]. *Obstet Gynecol* 2019;133:145S.