

# Efficacy of Amniotic Membrane Stem Cell Conditioned Medium (AMSC-CM) and Vitamin C Following CO2 Fractional Laser for Photoaging Therapy

*by* Trisniartami Setyaningrum

---

**Submission date:** 11-Feb-2023 09:55AM (UTC+0800)

**Submission ID:** 2011332567

**File name:** .\_Efficacy\_of\_Amniotic\_Membrane\_Stem\_Cell\_Conditioned\_Medium.pdf (208.19K)

**Word count:** 3473

**Character count:** 19178

## ORIGINAL ARTICLE

# Efficacy of Amniotic Membrane Stem Cell Conditioned Medium (AMSC-CM) and Vitamin C Following CO<sub>2</sub> Fractional Laser for Photoaging Therapy

Trisniartami Setyaningrum<sup>1,2</sup>, Vidyani Adiningtyas<sup>2</sup>, Riyana Noor Oktaviyanti<sup>2</sup>, Menul Ayu Umborowati<sup>2</sup>, Muhammad Yulianto Listiawan<sup>2</sup>, Budi Santoso<sup>3</sup>, Cita Rosita Sigit Prakoeswa<sup>2,4</sup>

<sup>1</sup> Post Graduate Doctoral Program, Faculty of Medicine, Universitas Airlangga, 60132 Surabaya, Indonesia

<sup>2</sup> Department of Dermatology and Veneorlogy, Faculty of Medicine, Universitas Airlangga, Dr. Soetomo General Academic Hospital, Jawa Timur 60286 Surabaya, Indonesia

<sup>3</sup> Department of Obstetric and Gynecology, Faculty of Medicine, Universitas Airlangga, Dr. Soetomo General Academic Hospital, Jawa Timur 60286 Surabaya, Indonesia

<sup>4</sup> Cell & Tissue Bank - Regenerative Medicine, Dr. Soetomo General Academic Hospital/ Faculty of Medicine, Universitas Airlangga, 60132 Surabaya, Indonesia

### ABSTRACT

**Introduction:** Skin aging, particularly photoaging, is a widely experienced problem. The therapies for photoaging are continuously evolving. For example, the application of topical antioxidants, such as vitamin C, has been widely used with satisfactory outcomes. Stem cell therapy, including amniotic membrane stem cell-conditioned medium (AMSC-CM), is a promising alternative because it contains growth factors and cytokines that aid wound healing and skin rejuvenation. The aim of this study was to evaluate the efficacy of AMSC-CM and vitamin C combination therapy following CO<sub>2</sub> fractional laser as laser-assisted drug delivery for photoaging treatment. **Methods:** This was an analytical experimental study conducted on 30 patients with photoaged skin treated with AMSC-CM and vitamin C. The treatment was repeated three times with an interval of 4 weeks. The final evaluation included Janus skin analysis to assess wrinkles, pores, spots, and skin tone. **Results:** Among the 30 participants with photoaged skin who met the inclusion criteria, the mean age was 50.53 (± 5.39) years and the mean Glogau score was 2.77 (± 0.43). The treatment resulted in significant improvements (*P* < .05) on wrinkles from evaluation I to evaluations II and evaluation I to evaluations III, pores from evaluation I to evaluation II, and spots from evaluation I to evaluation II. **Conclusion:** Clinical improvements were observed on the participants' photoaged skin in terms of wrinkles, pores, and spots after the combined topical therapy of AMSC-CM and vitamin C following CO<sub>2</sub> fractional laser therapy.

**Keywords:** Photoaging, Amniotic membrane stem cell-conditioned medium, Vitamin C, Laser fractional CO<sub>2</sub>

### Corresponding Author:

Cita Rosita Sigit Prakoeswa, Sp.KK(K)  
Email: cita-rosita@fk.unair.ac.id  
Tel: +6231 5501609

### INTRODUCTION

A number of factors, both intrinsic and extrinsic, can induce skin aging. Intrinsic factors are the result of continuous cellular processes and are influenced by genetics, whereas extrinsic factors are environmental, including ultraviolet (UV) and infrared radiation, air pollution, cigarette smoke, alcohol, sunlight, medications, stress, and diet. Skin aging is most frequently caused by the accumulation of UV exposure (photoaging) on unprotected skin areas, such as the face, neck, hands,

arms, and lower legs. More than 80% of skin aging is caused by chronic exposure to UV radiation. UVA and UVB contribute to skin aging and the occurrence of skin cancer. The clinical manifestations of photoaging include rough wrinkles, rough skin texture, reduced skin moisture, pale skin, appearance of pigmentation spots, loss of skin elasticity, and telangiectasia (1,2,3).

The therapy for photoaging varies, including the use of sun protection, such as clothes, hats, sunglasses, and sunscreens (4). Topical retinoid-based agents and other topical agents, including alpha-hydroxy acid, are first-line therapy for photoaging. Antioxidants, such as vitamin C (ascorbic acid), either oral or topical, are also used in the therapy of photoaging. Other therapies include chemical surgery, electrosurgery,

microdermabrasion, microneedling, Botox injection, filler injection, radiofrequency, ultrasound, intense pulsed light, and lasers, both ablative and non-ablative (5,6).

Stem cell-based therapy has recently been studied as a promising therapy for photoaging. Amniotic membrane stem cells (AMSCs) are a type of stem cell acquired from the unused placental amniotic membrane after childbirth; foetal tissues are rich in mesenchymal stem cells (7). The AMSC-conditioned medium (CM) contains various growth factors and cytokines and has been reported to increase the proliferation and migration of dermal fibroblasts and epidermal keratinocytes and the synthesis of collagen and fibroblasts. Studies that have evaluated the use of AMSC-CM on photoaged patients after YAG erbium fractional laser 2940 nm have reported clinical improvements in terms of skin pigment, moisture, and elasticity (8,9).

The application of the combination of AMSC-CM and vitamin C after microneedling in photoaged skin has been studied and the results show clinical improvements in wrinkles, UV spots, and pores. Topical vitamin C is an antioxidant that promotes depigmentation and collagen synthesis, whereas microneedling facilitates molecule penetration, thereby aiding drug absorption (10).

The CO<sub>2</sub> fractional laser is an ablative laser that can be utilised to treat photoaged skin. Moreover, this fractional laser creates microscopic columnar holes in the treated tissue (microscopic treatment zone), which ease the absorption of topical medications, in a process known as laser-assisted drug delivery (LADD). LADD effectively aids the absorption of topical medications into the dermis (11,12,13).

The aim of this study was to evaluate the efficacy of topical AMSC-CM combined with vitamin C on photoaging after CO<sub>2</sub> fractional laser therapy.

## METHODS AND MATERIALS

### Research design and subject

This was an experimental study with a pre- and post-test study design. A topical mixture of AMSC-CM and vitamin C was applied after CO<sub>2</sub> fractional laser therapy (Fraxis Duo, Ilooda, Suwon, Korea) three times with an interval of 4 weeks. The CO<sub>2</sub> fractional laser was used for LADD. The participants, who were patients with photoaged skin at the outpatient clinic of the Dermatology and Venereology Department, Dr. Soetomo General Academic Hospital Surabaya, Indonesia, were acquired by consecutive sampling. The inclusion criteria were patients with a Glogau score of II-III who had used tretinoin (0.25%) cream prior to therapy. The exclusion criteria were a history of keloid scars; active eczema; herpes simplex infection; a history of Botox injection, filler injection, chemical

peels, or microdermabrasion; the use of cream or oral antioxidants; and uncooperative behaviour. The final number of participants was 30. Based on the formula calculation, with standard deviation 2,43 (14).

$$n = 2 \left\{ \frac{Z\alpha + Z\beta}{(x1-x2)} s \right\}^2 = 30$$

n : sample size

zα = magnitude 1.96 at the level of significance α = 0.05

zβ = magnitude 0.842

s = standard deviation = 2.43 (14)

x1-x2 = the difference between the minimum mean which is considered significant, the amount is 1,75

### Preparation of AMSC-CM and vitamin C mixture

AMSC-CM is a liquid culture product of AMSC that contains cytokines and growth factors that aid in wound healing and skin rejuvenation. In this study, the AMSC-CM was acquired from the Tissue Bank and Regenerative Medicine Department, Dr. Soetomo General Academic Hospital, Surabaya, Indonesia. The AMSC-CM and vitamin C mixture consisted of 3 mL of AMSC-CM and 0.09 g of sodium ascorbyl phosphate. Three millilitres of the AMSC-CM and vitamin C mixture was applied to the whole face (10).

### Procedure

This research was approved by the ethical committee of Dr. Soetomo General Academic Hospital, Surabaya, Indonesia. The ethical clearance number is 0616/KEPK/Ix/2018. All participants received an explanation regarding the study procedure and signed informed consent and medical approval forms. Priming therapy with tretinoin cream (0.025%) and sunscreen (sun protection factor 30) was applied for 2 weeks prior to AMSC-CM and vitamin C treatment. Tretinoin cream (0.025%) was initiated 1 week after treatment. Tretinoin as a priming before laser action to reduce the side effects of hyperpigmentation after laser treatment and tretinoin is the standard therapy for antiaging. The baseline skin conditions, including wrinkles, spots, pores, and skin tones, were evaluated using the Janus 3D Facial Analysis System prior to treatment (evaluation I). The AMSC-CM and vitamin C mixture was applied after treatment with a CO<sub>2</sub> fractional laser for LADD. The laser parameter was 6.6–10 mJ with 1 stack, 1 pass, and 1 mm distance. The therapy was performed three times with an interval of 4 weeks. All participants were provided sunscreen to apply every morning to afternoon and tretinoin cream (0.025%) to apply every night. The progressive changes in wrinkles, spots, and pores were evaluated 4 weeks after the first treatment, before the second treatment (evaluation II), and 4 weeks after the third treatment (evaluation III).

### Statistical analysis

The accumulated data were analysed using SPSS software version 21 (SPSS, Chicago, IL, USA), with the

level of significance set at  $P < .05$ .

## RESULTS

This study was conducted on 30 women with photoaged skin who met the inclusion criteria. The mean age was 50.53 (SD 5.39) and the mean baseline Glogau score was 2.77 (SD 0.43). All patients work indoors; the most common outdoor activity was motorbike riding (100%), followed by morning exercise (50%; Table I).

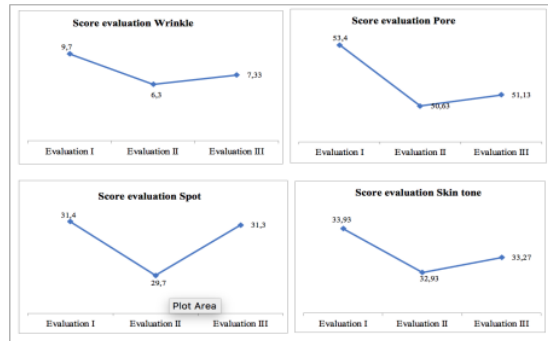
**Table I.** Patient characteristics

Variable	Total n = 30 n (%)	Mean (SD)
Age		50.53 (5.39)
- Min-max: (years)	42–63	
Glogau score		2.77 (0.43)
- II	6 (20)	
- III	24 (80)	
Occupation		
- Indoor	30 (100)	
- Outdoor	0 (0)	
Outdoor activity		
- Motorbike mobility	30 (100)	
- Sport	15 (50)	
- Morning exercise	4 (13.3)	
- Swimming	3 (10)	
- Gardening	12 (40)	
- Grocery shopping at the market		

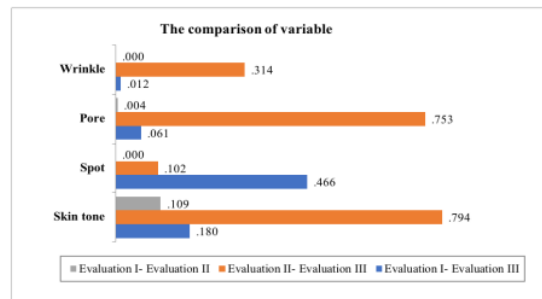
SD = Standard deviation

Figures 1 and 2 illustrate the clinical improvements in photoaging manifestations after AMSC-CM and vitamin C therapy following CO<sub>2</sub> fractional laser therapy. In terms of wrinkles, there were significant improvements ( $P = .000$ ) from evaluation I (baseline) to evaluation II ( $9.7 \pm 4.51$  vs.  $6.3 \pm 3.11$ ) and significant improvements ( $P = .012$ ) from evaluation I to evaluation III ( $9.7 \pm 4.51$  vs.  $7.33 \pm 3.99$ ). There was no significant improvement in pores ( $P = .061$ ) between evaluation I and evaluation III ( $53.4 \pm 5.88$  vs.  $51.13 \pm 4.98$ ); however, a significant improvement was observed ( $P = .004$ ) from evaluation I to evaluation II ( $53.4 \pm 5.88$  vs.  $50.63 \pm 4.89$ ). Spots did not significantly improve ( $P = .466$ ) between evaluation I and evaluation III ( $31.4 \pm 6.32$  vs.  $31.3 \pm 7.79$ ), although a significant improvement ( $P = .000$ ) was observed between evaluation I and evaluation II ( $31.4 \pm 6.32$  vs.  $29.57 \pm 6.63$ ). In terms of skin tone, none of the evaluations exhibited significant improvements,

whether between evaluation I and evaluation III ( $P = .180$ ), evaluation II and evaluation III ( $P = .794$ ), or evaluation I and evaluation II ( $P = .109$ ).



**Figure 1:** Score Evaluation Wrinkle, Pore, Spot and Skin tone



**Figure 2:** Comparison p-value of variables between evaluations

## DISCUSSION

In this study, we found significant improvement in the wrinkles appearance on the period of evaluation I to II and evaluation I to III, improvement of pore size from evaluation I to II, improvement in dark spots on the evaluation I to II, while skin tone did not improve significantly in all of our patients. Most of the patients were in Glasgow III scale, where the wrinkle, pore size and dark spot were dominant, that could be the reason our AMSC-CM and vitamin C therapy following CO<sub>2</sub> fractional laser may showed significant improvement, especially in evaluation I to evaluation II. Meanwhile, the period of evaluation II to evaluation III didn't show significant improvement in wrinkle, pore, spot and skin tone. Our result also showed throughout evaluation I to III the only significant improvement of all variable studied was the wrinkle appearance, even though if the parameters studied independently on each evaluation, all improvements occurred in each evaluation, either in wrinkle, pore, spot or skin tone. The skin types in

this study were Fitzpatrick IV and V skin types, that is caused by the effect of sun exposure in our country (Indonesia) which is located on the equator, it leads into insignificant results in skin tone improvement. Previous study conducted by Zhu and colleagues evaluated the efficacy of Botulinum Toxin Type A (BTX-A) therapy combined with fractional CO<sub>2</sub> laser on facial rejuvenation, the results of melanin index did not show significant changes between the two sides of the face at baseline, one, two, and twelve weeks after treatment (15).

The manifestations of photoaging investigated in this study were wrinkles, enlarged pores, spots or pigmentation dots, and skin tone or blanched skin because, clinically, photoaging appears as rough or soft wrinkles, pigmentation spots, actinic lentiginosities, rough texture, paleness, and telangiectasias. The main difference between Asian and Caucasian skin is related to its melanocytic function. The Asian skin type is highly pigmented; therefore, its response to UV differs from that of the Caucasian skin type. In aging skin of the Asian skin type, pigment changes are more visible than wrinkle appearance. Histological changes in photoaged skin include epidermal thinning (in acute sunlight exposure, the initial response is epidermal thickening), increased intraepidermal melanin deposition, epidermal Langerhans cell depletion, decreased collagen I, III, and VII levels, increased matrix metalloproteinase levels, elastotic material accumulation, and the presence of glycosaminoglycans in the dermal layer. Furthermore, photoaged skin has typical manifestations, such as the presence of a periappendageal inflammatory infiltrate that consists of lymphocytes and neutrophils, decrease in the number of blood vessels in the dermal papillary layer, and development of thick and tortuous blood vessels (6,16).

Recently, cell-based therapy, which utilises stem cells and growth factors, has been used as a strategy to restore damaged tissue, including for skin rejuvenation. Stem cells offer tissue regeneration properties through a paracrine mechanism, via the synthesis and secretion of various extracellular matrix proteins, cytokines, growth factors, and other bioactive proteins that participate in the healing process (17). The human umbilical cord blood-derived mesenchymal stem cell-conditioned medium (USC-CM) contains multiple growth factors for skin rejuvenation, such as epithelial growth factor, basic fibroblast growth factor, platelet-derived growth factor, hepatocyte growth factor, collagen type 1, and, importantly, a rejuvenation factor, growth differentiation factor-11. The topical application of USC-CM exhibits anti-wrinkle property by significantly increasing the dermal density (18). Prakoeswa et al. conducted a study using 60 patients with photoaged skin who were treated with the topical application of the AMSC-PM and vitamin C mixture after microneedling treatment and observed significant improvement in terms of wrinkles, ultraviolet

spots, and pores (10). Another study by Widianingsih et al. in nine patients with photoaged skin who were treated with topical AMSC-PM after erbium:yttrium aluminium garnet fractional laser therapy also showed improvements in terms of pores and UV spots compared with the control group that was not treated with AMSC-PM (19).

Topical vitamin C (L-ascorbic acid) is a form of biologically active vitamin C that acts as both a preventive and photoprotective antioxidant. Vitamin C neutralises the oxidative stress damage caused by UV exposure, pollution, and smoking. Additionally, vitamin C is a key cofactor in collagen biosynthesis, vital for prolyl hydroxylase and lysyl hydroxylase enzymes, and has a substantial role in wound healing. Serum vitamin C has been shown to penetrate the epidermal layer. Normally, the skin contains plenty of vitamin C, which acts as an antioxidant for overall skin health. However, under certain stresses, such as those caused by a fractional laser, the amount of skin antioxidants decreases. Based on this premise, we supplied additional vitamin C to the skin to expedite wound healing. Furthermore, serum antioxidants at a low pH can inhibit the growth of *Candida albicans* after laser therapy (20,21).

Hydrophilic molecules larger than 500 Da have less capability to penetrate the stratum corneum. Most growth factors weigh more than 20 kDa; thus, the penetration of a pharmacologically effective amount into the epidermal layer is difficult (15). Therefore, in this study, we used a CO<sub>2</sub> fractional laser for LADD to aid the administration of the topical agent, an AMSC-CM and vitamin C mixture, to penetrate the dermis. Therapy with a CO<sub>2</sub> fractional laser induces the transdermal delivery of vitamin C, as observed with conventional CO<sub>2</sub> lasers, but causes less skin peeling, thereby reducing the incidence of side effects (22). The limitation in this study is the absence of histopathological examination on the research subjects to see more clearly the changes in the structure of the skin after receiving AMSC-CM and vitamin C therapy mixture after treatment with a CO<sub>2</sub> fractional laser.

## CONCLUSION

The application of topical AMSC-CM and vitamin C after CO<sub>2</sub> fractional laser therapy results in significant improvements in wrinkles, pores, and spots in patients with photoaged skin.

## Acknowledgements

This study was supported by the research mandate of Universitas Airlangga.

## REFERENCES

1. Tobin DJ. Introduction to skin aging. *J Tissue Viability*. 2017;26(1):37-46.

2. Wang AS, Dreesen O. Biomarkers of Cellular Senescence and Skin Aging. *Front Genet.* 2018;9:247.
3. Weihermann AC, Lorencini M, Brohem CA, de Carvalho CM. Elastin structure and its involvement in skin photoageing. *Int J Cosmet Sci.* 2017;39(3):241-7.
4. Wang SQ, Balagula Y, Osterwalder U. Photoprotection: a review of the current and future technologies. *Dermatol Ther.* 2010;23(1):31-47.
5. Baumann L. How to Use Oral and Topical Cosmeceuticals to Prevent and Treat Skin Aging. *Facial Plast Surg Clin North Am.* 2018;26(4):407-13.
6. Griffiths CE. Drug treatment of photoaged skin. *Drugs Aging.* 1999;14(4):289-301.
7. Sato C, Yamamoto Y, Funayama E, Furukawa H, Oyama A, Murao N, et al. Conditioned Medium Obtained from Amnion-Derived Mesenchymal Stem Cell Culture Prevents Activation of Keloid Fibroblasts. *Plastic and Reconstructive Surgery.* 2018;141(2):390-8.
8. Prakoeswa CRS, Pratiwi FD, Herwanto N, Citrashanty I, Indramaya DM, Murtiastutik D, et al. The effects of amniotic membrane stem cell-conditioned medium on photoaging. *J Dermatolog Treat.* 2019;30(5):478-82.
9. Praharsini IGAA, Indira IGAAE, Prakoeswa CRS, Adiguna MS, Rusyati LM, Umborowati MA, et al. Efficacy of amniotic membrane topical stem cell-conditioned medium combined with YAG erbium fractional laser 2940 nm in photoaging skin. 2020;14(2):4.
10. Prakoeswa CRS, Effendi ZF, Herwanto N, Ervianty E, Rantam FA. Efficacy of topical application of a mixture of amniotic membrane stem cell metabolic products and vitamin C after microneedling treatment in patients with photoaging. *Journal of Pakistan Association of Dermatologists.* 2020;30:485-9.
11. Manstein D, Joachim Laubach H. Fractional Photothromolysis. In: Nouri K, editor. *Lasers in Dermatology and Medicine.* London: Springer; 2011. p. 123-47.
12. Ibrahim O, Dover JS. Fundamentals of Laser and Light Based Treatments. In: Kang S, Amagai M, Bruckner AL, Enk AH, Margolis DJ, McMichael AJ, et al., editors. *Fitzpatrick's Dermatology.* 1. 09 ed. new York: McGraw-Hill; 2019. p. 3820-33.
13. Wenande E, Anderson RR, Haedersdal M. Fundamentals of fractional laser-assisted drug delivery: An in-depth guide to experimental methodology and data interpretation. *Advanced Drug Delivery Reviews.* 2020;153:169-84.
14. Tan J, Lei Y, Ouyang HW, Gold MH. The Use of the Fractional CO<sup>2</sup> Laser Resurfacing in the Treatment of Photoaging in Asians: Five Years Long-Term Results. *Lasers in Surgery and Medicine* 2014. 46:750–756.
15. Zhu J, Ji X, Li M, Chen X, Liu J, Zhang J, Luo D, Zhou B. The Efficacy and Safety of Fractional CO<sup>2</sup> Laser Combined with Topical Type A Botulinum Toxin for Facial Rejuvenation: A Randomized Controlled Split-Face Study. *BioMed Research International.* 2016;3853754
16. Chung JH. Photoaging in Asians. *Photodermatol Photoimmunol Photomed.* 2003;19(3):109-21.
17. Lee HJ, Lee EG, Kang S, Sung JH, Chung HM, Kim DH. Efficacy of microneedling plus human stem cell conditioned medium for skin rejuvenation: a randomized, controlled, blinded split-face study. *Ann Dermatol.* 2014;26(5):584-91.
18. Kim YJ, Seo DH, Lee SH, Lee SH, An GH, Ahn HJ, et al. Conditioned media from human umbilical cord blood-derived mesenchymal stem cells stimulate rejuvenation function in human skin. *Biochem Biophys Rep.* 2018;16:96-102.
19. Widianingsih NPS, Setyaningrum T, Prakoeswa CRS. The efficacy and safety of fractional erbium yag laser combined with topical amniotic membrane stem cell (AMSC) metabolite product for facial rejuvenation: A controlled, split-face study. *Dermatology Reports.* 2019;11(s1).
20. Lintner K, Gerstein F, Solish N. A serum containing vitamins C & E and a matrix-repair tripeptide reduces facial signs of aging as evidenced by Primos® analysis and frequently repeated auto-perception. *J Cosmet Dermatol.* 2020.
21. Waibel JS, Mi QS, Ozog D, Qu L, Zhou L, Rudnick A, et al. Laser-assisted delivery of vitamin C, vitamin E, and ferulic acid formula serum decreases fractional laser postoperative recovery by increased beta fibroblast growth factor expression. *Lasers Surg Med.* 2016;48(3):238-44.
22. Hsiao CY, Huang CH, Hu S, Ko YS, Sung HC, Chen CC, et al. Fractional carbon dioxide laser treatment to enhance skin permeation of ascorbic acid 2-glucoside with minimal skin disruption. *Dermatol Surg.* 2012;38(8):1284-93.

# Efficacy of Amniotic Membrane Stem Cell Conditioned Medium (AMSC-CM) and Vitamin C Following CO2 Fractional Laser for Photoaging Therapy

## ORIGINALITY REPORT

11%

SIMILARITY INDEX

8%

INTERNET SOURCES

7%

PUBLICATIONS

5%

STUDENT PAPERS

## PRIMARY SOURCES

1	Submitted to Universitas Airlangga Student Paper	3%
2	<a href="http://blog.balimedicaljournal.org">blog.balimedicaljournal.org</a> Internet Source	2%
3	Hee Jung Lee, Eo Gin Lee, Sangjin Kang, Jong-Hyuk Sung, Hyung-Min Chung, Dong Hyun Kim. "Efficacy of Microneedling Plus Human Stem Cell Conditioned Medium for Skin Rejuvenation: A Randomized, Controlled, Blinded Split-Face Study", <i>Annals of Dermatology</i> , 2014 Publication	1%
4	<a href="http://vdoc.pub">vdoc.pub</a> Internet Source	1%
5	<a href="http://www.nlm.medscape.idmu.unboundmedicine.unbound">www.nlm.medscape.idmu.unboundmedicine.unbound</a> Internet Source	1%
6	<a href="http://medic.upm.edu.my">medic.upm.edu.my</a> Internet Source	1%

7	<a href="http://jpad.com.pk">jpad.com.pk</a> Internet Source	1 %
8	<a href="http://pure.rug.nl">pure.rug.nl</a> Internet Source	<1 %
9	<a href="http://docplayer.net">docplayer.net</a> Internet Source	<1 %
10	Huan Xue, Shuzhan Shen, Guorong Yan, Yuling Yang, Jiandan Li, Ziwei Kang, Yajing Cao, Xiuli Wang, Peiru Wang. "A dose - dependent protective effect of n - 3 PUFAs in photoaging by promoting collagen production through MAPK pathway in SKH - 1 mouse model", <i>Journal of Cosmetic Dermatology</i> , 2022 Publication	<1 %
11	European Handbook of Dermatological Treatments, 2015. Publication	<1 %
12	<a href="http://c-www.balimedicaljournal.org">c-www.balimedicaljournal.org</a> Internet Source	<1 %
13	<a href="http://doaj.org">doaj.org</a> Internet Source	<1 %
14	"Daily Routine in Cosmetic Dermatology", Springer Science and Business Media LLC, 2017 Publication	<1 %



15

Lixue Wang, Komal K. Abhange, Yi Wen, Yundi Chen, Fei Xue, Guosheng Wang, Jinlong Tong, Chuandong Zhu, Xia He, Yuan Wan.

"Preparation of Engineered Extracellular Vesicles Derived from Human Umbilical Cord Mesenchymal Stem Cells with Ultrasonication for Skin Rejuvenation", ACS Omega, 2019

Publication

<1 %

16

"Lasers, Lights and Other Technologies", Springer Science and Business Media LLC, 2018

Publication

<1 %

17

Loubna Mazini, Luc Rochette, Gabriel Malka. "Chapter 2 Adipose-Derived Stem Cells (ADSCs) and Growth Differentiation Factor 11 (GDF11): Regenerative and Antiaging Capacity for the Skin", IntechOpen, 2020

Publication

<1 %

Exclude quotes Off

Exclude matches Off

Exclude bibliography On

# Efficacy of Amniotic Membrane Stem Cell Conditioned Medium (AMSC-CM) and Vitamin C Following CO2 Fractional Laser for Photoaging Therapy

---

GRADEMARK REPORT

---

FINAL GRADE

**/100**

GENERAL COMMENTS

**Instructor**

---

PAGE 1

---

PAGE 2

---

PAGE 3

---

PAGE 4

---

PAGE 5

---