

Melanocyte count on leukotrichia in vitiligo using S100 protein immunohistochemistry before and after phototherapy: A case report

by Putri Hendria Wardhani

Submission date: 11-Feb-2023 10:04AM (UTC+0800)

Submission ID: 2011337507

File name: anocyte_count_on_leukotrichia_in_vitiligo_using_S100_protein.pdf (372.16K)

Word count: 1510

Character count: 8363

Melanocyte count on leukotrichia in vitiligo using S100 protein immunohistochemistry before and after phototherapy: A case report

Putri Hendria Wardhani^{#*}, Cita Rosita Sigit Prakoeswa^{*}, M. Yulianto Listiawan^{*}, Linda Astari^{*}, Iskandar Zulkarnain^{*}, Dwi Murtiastutik^{*}, Trisniartami Setyaningrum^{*}

[#] Post Graduate Doctoral Program, Faculty of Medicine, Universitas Airlangga, Indonesia.

^{*} Department of Dermatology and Venereology, Faculty of Medicine, Universitas Airlangga, Dr. Soetomo General Hospital, Surabaya, Indonesia.

Abstract

Vitiligo is the most common depigmentation disease with complex pathogenesis that is not well understood and therapeutic outcomes are often unsatisfactory. Leukotrichia in vitiligo is often associated with poor prognosis for vitiligo treatment. Until now narrowband ultraviolet B (NB-UVB) is considered the most effective and safe treatment for vitiligo. Evaluation of therapy by looking at the amount of melanocytes that can be seen with S100 protein immunohistochemistry will become more objective and accurate. Melanocyte count in four non segmental vitiligo patient with leukotrichia were evaluated. The patient was given only NB-UVB therapy twice a week for eight times. Skin biopsy was done before and after therapies using immunohistochemistry staining. The number of S100 protein in vitiligo patients with leukotrichia after NB-UVB therapy increased. Leukotrichia is a poor indicator for treatment response in vitiligo, but this case report showed that leukotrichia did not contribute to the lack of response upon medical treatment.

Key words

Melanocyte, phototherapy, S100 protein, vitiligo.

Introduction

Vitiligo is the most common depigmentation disease and the clinical manifestation is milk colored white macules. It is an acquired disease with complex pathogenesis that is not well understood so the evolution of the disease is unpredictable and the outcome of therapy is often unsatisfactory, this leads to a decrease in quality of life, anxiety, lack of confidence, and psychosocial stigma.^{1,2} Vitiligo accounts for 0.3-0.5% of the world's population. The prevalence

of vitiligo has shown an increase over the past few decades.^{1,3}

The principle of vitiligo therapy is to facilitate the repopulation of active melanocytes that can migrate, and perform the biosynthesis of melanin to the vitiligo patches. Until now Narrowband UVB (NB-UVB) is considered to be most effective and safe for vitiligo therapy.¹ Clinicians evaluate the results of vitiligo therapy only with clinical repigmentation percentage which is very subjective.^{1,4} This case report is trying to prove an evaluation that is more objective so that can help clinicians evaluate the result of therapy. The objective evaluation of repigmentation is important for clinicians as an indicator of success or failure of therapy. Evaluation of therapy by looking at the amount of melanocytes will become more objective and accurate.

Address for correspondence

Dr. Putri Hendria Wardhani.

Department of Dermatology and Venereology, Faculty of Medicine, Universitas Airlangga, Dr. Soetomo General Hospital, Jl. Mayjen Prof. Dr. Moestopo No. 6-8 Surabaya 60131, Indonesia.

Ph: +62315501609

Email: putri_h_w@yahoo.com

S100 protein is a cytoplasmic protein that will be expressed by melanocyte, very well known that S100 protein has a high sensitivity on melanocyte so it can help to visualize the amount of melanocyte.^{5,6} The S100 protein is a good marker in the diagnosis of melanocytic lesions but the diagnostic uses are limited by its broad expression, these antibodies not only describe melanocytes but also several other cell types, such as Schwann cells and Langerhans cells. Melanocyte will appear in the basal epidermis with long dendrites containing cytoplasm that surround keratinocytes.^{5,7}

Melanocyte in the hair follicle is one of the major sources of repigmentation in vitiligo. Leukotrichia is complete depigmentation with significant bleaching hair, often associated with absent of melanocyte. Leukotrichia in nonsegmental vitiligo may contribute to the lack of response to medical treatment, poor prognosis for vitiligo treatment.⁸

In this case report the amount of S100 protein in vitiligo patient with leukotrichia lesions prior to NB-UVB therapy is compared with amount after NB-UVB therapy.

Case report

Four non segmental vitiligo patient with leukotrichia were evaluated, all patients met the requirements and agreed to participate by signing information for consent, informed consent and medical action approval sheets. This case report was conducted from May 2017 until August 2017 at Dermatology and Venereology Outpatient Clinic, Dr. Soetomo General Hospital Surabaya. Each patient was recorded, then each patient was given only NB-UVB therapy twice a week for eight times and 3 mm biopsy was performed before and after NB-UVB therapy. S100 protein immunohistochemistry were performed to calculate the amount of S100

protein in five fields of view, one view per millimeter, the results were compared. S100 protein score data were obtained using the modified Remmele method, where the Remmele scale (Immuno Reactive Score/ IRS) index was the result of multiplication of immunoreactive cell percentage scores with color intensity scores on immunoreactive cells. Data for each sample is the average IRS value observed in 5 (five) View Fields (LP) at 1000x magnification.

Data in **Table 1** shows that all vitiligo patients with leukotrichia still have melanocyte and the amount increased after NB-UVB therapy. NB-UVB therapy there were at most twelve melanocytes in two fields of view and at least eight melanocytes. Before NB-UVB therapy there were at most six melanocytes in two fields of view, while after The amount of S100 protein in all vitiligo patients with leukotrichia after NB-UVB therapy increased compared to before NB-UVB therapy as we can see in **Figure 1 and 2**.

Table 1 The amount of S100 protein before and after NB-UVB

| | <i>S100 Protein Before NB-UVB</i> | <i>S100 Protein After NB-UVB</i> |
|-----------|-----------------------------------|----------------------------------|
| Patient 1 | 3 | 8 |
| Patient 2 | 3 | 8 |
| Patient 3 | 2 | 8 |
| Patient 4 | 6 | 12 |

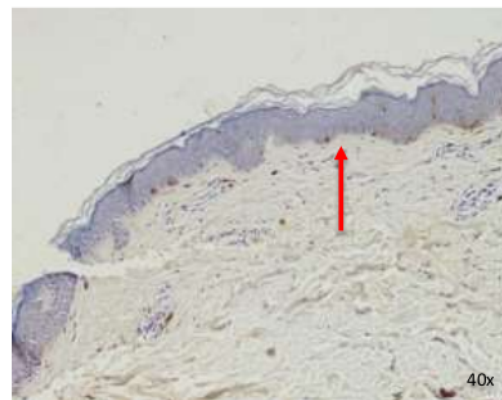


Figure 1 S100 protein before NB-UVB therapy in vitiligo with leukotrichia (40x magnifications).

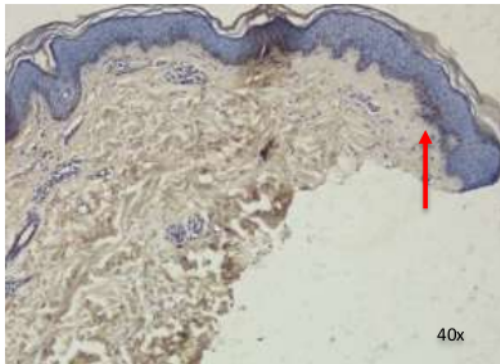


Figure 2 S100 Protein after NB-UVB therapy in vitiligo with leukotrichia (40x magnifications).

Discussion

Leukotrichia or complete depigmentation in hair in vitiligo due to decreased melanocytes in the hair bulb is often used as an indicator of prognosis for therapeutic response.² Lee and his colleagues stated that leukotrichia in vitiligo can contribute to the low response to therapy given,⁹ but this study showed that all of the vitiligo patients with leukotrichia still have melanocyte and the amount increased after NB-UVB therapy. NB-UVB itself can induce the activation of transcription to synthesize melanin found in melanosomes and is exported to keratinocytes.^{10,11} This is in line with the results of this case report that the amount of melanocytes using S100 protein after NB-UVB therapy increased compared to the amount before NB-UVB therapy. The clinical picture of the patient in **Figure 3 and 4** shows significant improvement as well.

Conclusion

Leukotrichia is known as poor indicator for treatment response in vitiligo, but this study showed that leukotrichia may not contribute to the lack of response upon medical treatment, and evaluation of therapy by looking at the amount of melanocytes that can be seen with S100 protein immunohistochemistry will become

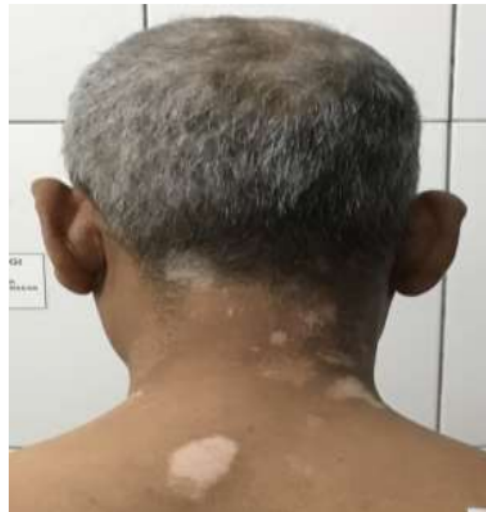

Figure 3 Vitiligo with leukotrichia before NB-UVB therapy.

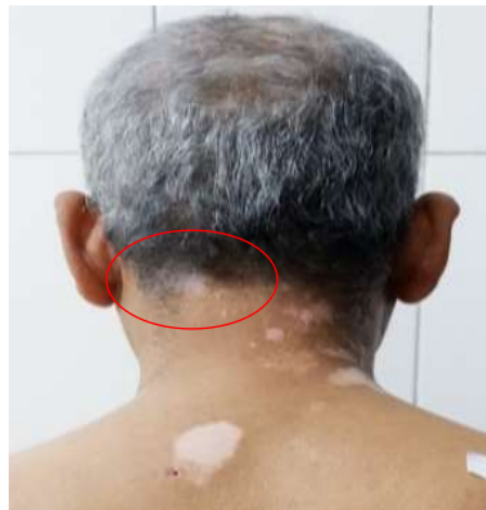

Figure 4 Vitiligo with leukotrichia after NB-UVB therapy.

more objective and accurate, but still need a further research.

References

1. Birlea SA, Spritz RA, Norris DA. Vitiligo. Dalam: Wolff K, Goldsmith LA, Katz SI, Gilchrest BA, Leffel DJ, editors. Fitzpatrick's Dermatology General

- Medicine. 8th Ed. New York: McGraw Hill Co. 2013. p.792-803.
2. Kutlubay Z, Karakus O, Engin B, Serdaroglu S. Vitiligo as autoimmun disease. *J Turk Acad Dermatol* 2012; **6(2)**: 126r1.
 3. Alikhan MD, Felsten LM, Daly M, Petronic-Rosic V. Vitiligo: A comprehensive overview. *J Am Acad Dermatol* 2011; **65**: 473-91.
 4. Park HY, Yaar M. Biology of melanocytes. Dalam: Wolff K, Goldsmith LA, Katz SI, Gilchrest BA, Leffel DJ, editors. Fitzpatrick's Dermatology in General Medicine 8th Ed. New York: McGraw Hill Co. 2013. p.792-803.
 5. Nybakken GE, Sargen M, Abraham R, Zhang PJ, Ming M, Xu X. MITF accurately highlight epidermal melanocytes in atypical intraepidermal melanocytic proliferations. *Am J Dermatopathol* 2013; **35(1)**: 25-9.
 6. Bastonini E, Kovacs D, Picardo M. Skin pigmentation and pigmentary disorders: focus on epidermal/ dermal cross-talk. *Ann Dermatol* 2016; **28(3)**: 279-89.
 7. Halawi A., Abbas O, Mahalingam M. S100 proteins and the skin: a review. *JEADV* 2013.1-10.
 8. Listiawan MY, Rimadhani M, Sandhika W. Jumlah dan fungsi melanosit leukotrihia pada vitiligo berdasarkan pemeriksaan imunohistokimia S100 dan Microphthalmia Associated Transcription Factor (MITF). *Berkala Ilmu Kesehatan Kulit dan Kelamin* 2016; **28(3)**: 182-5.
 9. Lee DY, Kim CR, Park JH, Lee JH. The incidence of leukotrichia in segmental vitiligo: implication of poor response to medical treatment. *Int J Dermatol*. 2011; **50(8)**: 925-7.
 10. Lee CH, Wu SB, Hong CH, Yu HS, Wei YH. Molecular mechanisms of UV-induced apoptosis and its effects on skin residential cells: the implication in UV-based phototherapy. *Int J Mol Sci* 2013; **14**: 6414-35.
 11. Videira IFS, Magina S, Moura DFL. Mechanisms regulating melanogenesis. *An Bras Dermatol* 2013; **88(1)**: 76-83.

Melanocyte count on leukotrichia in vitiligo using S100 protein immunohistochemistry before and after phototherapy: A case report

ORIGINALITY REPORT

11%

SIMILARITY INDEX

7%

INTERNET SOURCES

9%

PUBLICATIONS

7%

STUDENT PAPERS

PRIMARY SOURCES

- | | | |
|---|--|----|
| 1 | Submitted to Chulalongkorn University Student Paper | 3% |
| 2 | Submitted to Pennsylvania College of Technology Student Paper | 2% |
| 3 | medicopublication.com Internet Source | 2% |
| 4 | Achmad Fahmi, Heri Subianto, Nur Setiawan Suroto, Budi Utomo, Riyanarto Sarno, Agus Turchan, Abdul Hafid Bajamal. "Stereotactic aspiration of spontaneous intracerebral hematoma: Case series", International Journal of Surgery Case Reports, 2020 Publication | 1% |
| 5 | Moftah, Nayera H., Rasha A. H. El-Barbary, Mona A. Ismail, and Nancy A. M. Ali. "Effect of narrow band-ultraviolet B on CD4+ CD25high FoxP3+ T-lymphocytes in the peripheral blood of vitiligo patients : Effect of NB-UVB on Tregs | 1% |

in vitiligo", Photodermatology
Photoimmunology & Photomedicine, 2014.

Publication

6

Billy Jiwandono. "PROFILE OF LEPROSY IN
CHILDREN FROM 2014-2018 IN DR. SOETOMO
GENERAL HOSPITAL SURABAYA", Jurnal
Kesehatan dan Kedokteran, 2022

Publication

1 %

7

repub.eur.nl

Internet Source

1 %

Exclude quotes Off

Exclude matches Off

Exclude bibliography On

Melanocyte count on leukotrichia in vitiligo using S100 protein immunohistochemistry before and after phototherapy: A case report

GRADEMARK REPORT

FINAL GRADE

/100

GENERAL COMMENTS

Instructor

PAGE 1

PAGE 2

PAGE 3

PAGE 4
