

Management Of Non-Vital Teeth Discoloration With The Internal Bleaching : A Case Report

by Dewi Fitria

Submission date: 31-Jan-2020 08:52AM (UTC+0800)

Submission ID: 1249025606

File name: AS_8_2020_DEWI_FITRIA_ANUGRAHATI_PPDGS_KONSERVASI_UNAIR_2018.pdf (437.79K)

Word count: 2262

Character count: 12442

2 Management Of Non-Vital Teeth Discoloration With The Internal Bleaching : A Case Report

Dewi Fitria Anugrahati⁴, Rizky Ernawati¹, Sukaton², Kun Ismiyatin²

¹Resident of Conservative Dentistry Department, Faculty of Dental Medicine, Universitas Airlangga, Surabaya, Indonesia.

²Staff of Conservative Dentistry Department, Faculty of Dental Medicine, Universitas Airlangga, Surabaya, Indonesia.

Corresponding Author: Kun Ismiyatin, Staff of Conservative Dentistry Department, Faculty of Dental Medicine, Universitas Airlangga. Jl. Prof. Dr. Moestopo No. 47, Surabaya 60132, Indonesia. Telp: +6231 5030255,

Fax: +6231 5020256 E-mail: kumis@fkg.unair.ac.id

Abstract:

Background: Tooth discoloration due to intra coronal bleeding after trauma can cause aesthetic disturbances and appearance. Internal bleaching is a non-invasive method to restore tooth color which is performed after endodontic treatment by placing a strong oxidizing agent in the pulp chamber. **Objective:** The aim of this study was to report the success of internal bleaching procedure to restore discolored teeth due to trauma. **Case report:** A 44-year-old female came to Conservative Dentistry Universitas Airlangga with chief complaint of the upper right insisor tooth looks darker than the adjacent teeth. The patient had fallen 10 years ago from her motorcycle and her tooth had been painful and then the pain disappeared. In intra oral clinical examination, it showed that tooth 11 had discoloured, vitality test of tooth 11 showed no response to electric pulp test. Radiographic view showed that radiolucen in periapical area and no fracture was found. **Case Management:** At the first visit, treatment of single visit root canal using rotary instrument and gave dressing calcium hydroxide. A week later on the second visit, internal bleaching with hydrogen peroxide 35% was done. After bleaching, calcium hydroxide was applied to neutralize the oxidizing agent and then re-evaluated for the color. At the third visit, it showed that the tooth colour was obtain as desire from C3 to A3 (Vitapan Classical). **Conclusion:** The internal bleaching procedure on the traumatized tooth was the best option to restore the function and aesthetics according to the original tooth colour and also provided benefits in terms of saving time, lower price, and maximum results.

Keywords: non-vital teeth, internal bleaching, discoloration

INTRODUCTION

Discoloration of teeth can be caused by intrinsic, extrinsic or a combination of both. The occurrence of discoloration is caused by the incorporation of intrinsic chromatogenic materials into dentine and enamel during odontogenesis or after the eruption of teeth.¹ The intrinsic cause of discoloration in pre-erupted teeth is the provision of tetracycline or high number of fluoride exposure. In addition, it also can be caused by hereditary diseases such as amelogenesis

imperfecta and dentinogenesis imperfecta.² After the eruption of teeth, the main cause of discoloration is the pulp necrosis, the deposition of the blood component to the dentine tubules after trauma or pulpectomy, and secondary dentine deposition due to gingivitis or iatrogenic.^{2,3} Foods and beverages such as coffee, tea, red wine, carrots, oranges, and tobacco are primarily responsible for extrinsic stains.³

Teeth whitening offers a conservative and aesthetic solution and is an option because it is not invasive, such as crowns or porcelain veneer. The

non-vital teeth whitening technique puts the oxidizing agent inside the pulp chamber in direct contact with dentine. Chemicals which are often used as bleach are hydrogen peroxide 35%⁴ Walking bleach technique is a bleaching method by placing the active ingredient in the pulp chamber, followed by closing the tooth cavities. The results obtained depends on the etiology of discoloration and for a satisfactory result bleaching can be carried out for two to four times the application.⁴ The case report aims to demonstrate the success of non-vital teeth whitening that has discoloration after⁶ the endodontic treatment performed using a walking bleach technique with a good prognosis and without side effects.

1 CASE REPORT

A 44-year-old female came to Conservative Dentistry and Endodontics Clinic Airlangga University with chief complaint of the upper right insisor tooth looks darker than the adjacent teeth. Patient had fallen 10 years ago from her motorcycle and her tooth had been painful and then the pain disappeared. The patient wants her tooth colour same as the adjacent teeth. Patient does not have a history of systemic diseases.

Extra oral examination shows symmetrical face, no abnormalities of the lips, the left and right mandibular glands are unaffected and painless. Intra-oral examination showed that crown of tooth 11 is darker in colour than the adjacent teeth. Hygiene of the oral cavity is good, it shows an overview of radiolucency on periapical area. Examination of negative percussion test, negative bite test and negative palpation.

Radiographic view after endodontic treatment shows the radiopaque depiction of the crown to the apex which means that it fills the hermetic root canal. There is widening of lamina dura, alveolar bone resorption and radiolucency in periapical area which are smaller than before endodontic treatment.

On the first visit, the patient was given an explanation of the procedure to be performed. The cost of treatment, side effects can occur, possible outcome to be achieved, failures and complications about the use of bleaching material understood by the patient and then carried out the signing of informed consent. The next step was to do single visit root canal treatment using rotary instrument and given dressing calcium hydroxide.

A week later on the second visit, internal bleaching with hydrogen peroxide 35% was carried

out for 7 days. Previously, it was carried out tooth colour recording before treatment at¹ intra oral photographs. Previously, the tooth was cleaned using a rotary brush and pumice powder to obtain the actual colour. The tooth colour was matched using Vitapan classical shade guide. In this case, the initial colour was C3 and the colour which want to achieve was A² colour.

The working area was isolated with rubber dam and coronal access was carried out by reopening the temporary patch using a rounded diamond bur. The root canal filler material was ejected to a depth of 2 mm below the CEJ by using a hot plugger that has been given a stopper to provide a place for cervical seal material. The depth of filler intake was confirmed again using periodontal probe. Tooth 11 cavity was irrigated with sterile aquadest until clean and dried. The cervical seal was made by applying 2 mm thick glass ionomer cement² following the cervical stripe outline. The resultant shape from a facial view is the "bobsled tunnel" outline. The outline from the proximal view resembles a "ski-slope".⁵ After the cervical seal dried, the bleaching material in the form of hydrogen peroxide gel 35% (1) (Palescence Endo, Ultradent Product Inc., USA) was applied to the labial part, then the pulp chamber was given with cotton pellet and covered with glass ionomer cement. The patient was instructed to control 1 week later.

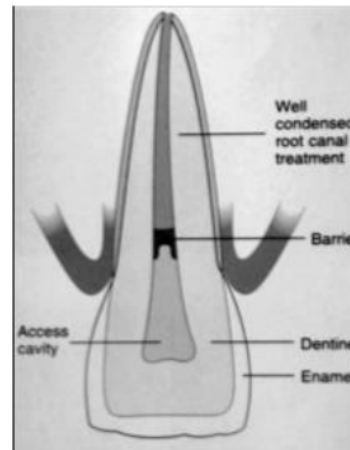


Figure 1. Bobsled Tunnel Appearance

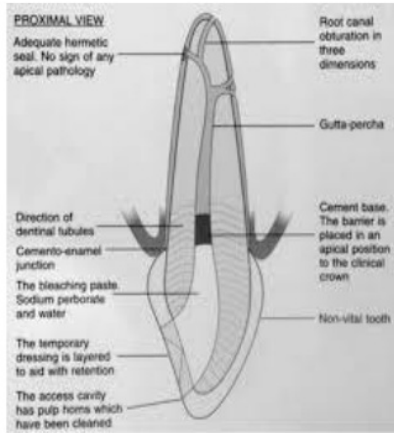


Figure 2. Ski Slope Appearance

On the third visit, a subjective examination was conducted, it was no complaints from the patient. Objective examination showed that tooth discoloration from C3 to A3 (Vitapan Classical). Two weeks later, the tooth was restored by composite materials which in accordance with the tooth colour.

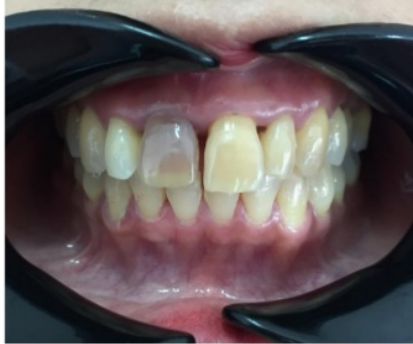

Figure 3. Preoperative photograph of discolored tooth

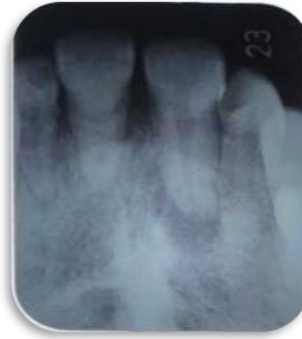

Figure 4. Preoperative radiograph

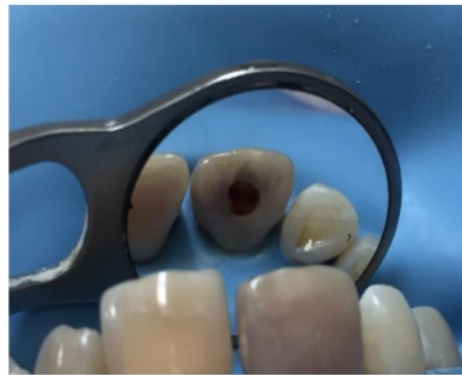

Figure 5. Photograph of the tooth after placing hydrogen peroxide intra coronally

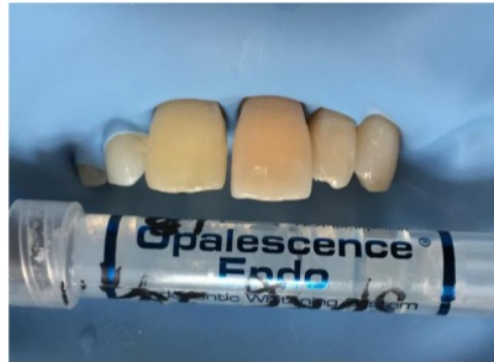

Figure 6. Internal Bleaching Agent

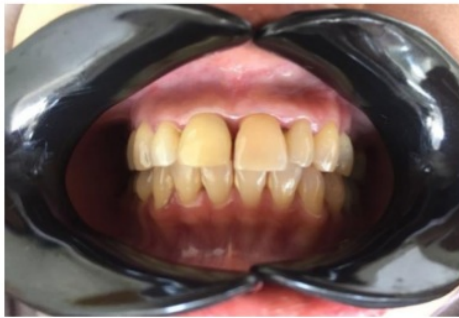

Figure 7. Post Operative Photograph

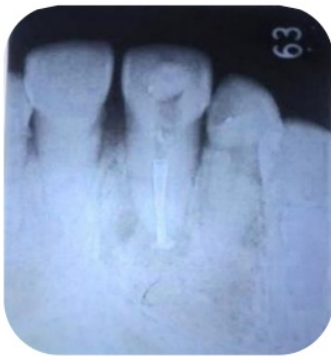

Figure 8. Post operative radiograph

On the third visit, a subjective examination was conducted, it was no complaints from the patient. Objective examination showed that tooth discoloration from C3 to A3 (Vitapan Classical). Two weeks later, the deposition was carried out by composite materials which in accordance with the tooth colour.

DISCUSSION

Tooth staining especially in the anterior teeth can interfere with a person's appearance. In addition to invasive treatment, such as the making of crowns or veneer, tooth whitening or bleaching can be an alternative treatment. Contrary to the making of crowns or veneer, tooth bleaching is a relatively non-invasive treatment. The tooth bleaching which has been carried out before root

canal treatment can be done with internal bleaching treatment.⁵ In this case, the tooth discoloration in the tooth 11 is caused by intrinsic factors.

Necrosis in the tooth 11 is caused by trauma that occurred about 10 years ago. Trauma to the tooth causes intra pulpa bleeding and erythrocytes lysis. Blood or blood components that bathe the pulp chamber will enter the dentinal tubules diffusely, resulting in a discoloration of the tooth down. The discoloration which occurs relates to how long the pulp has become necrosis, the longer the colored compounds are in the pulp, the greater the degree of discoloration.⁵

Bleaching is a more conservative alternative treatment than making of the crown and labial veneer in the stained teeth. The chemical process in bleaching occurs when the whitening material is applied to the teeth, usually using oxidizing materials such as hydrogen peroxide, chlorine or sodium hypochlorite. Although the bleaching process is a complex chemical process, the basic principle of the majority of bleaching processes is the step-by-step oxidation of the dye with decomposition. Bleaching material is oxidizing, reacting to the organic structure of a hard tooth tissue, pigments which have long chains slowly degraded into simple molecules such as carbon dioxide, oxygen and water which have a brighter colour, inorganic molecules are not broken down, the reduction-oxidation reaction which occurs in the bleaching process is known as redox reaction. In general, unstable peroxide becomes unstable free radicals. These free radicals oxidize other molecules.^{5,6,7}

Hydrogen peroxide is a strong oxidizing agent. The use of high concentration of hydrogen peroxide must be careful because it is unstable thermodynamically and can explode, because it must be placed in the refrigerator and stored on a dark container. Bleaching materials can be applied using the plastic and plugger instruments and must be replaced every 3-7 days. Usually it takes 2-4 sessions depending on the intensity of discoloration. The patient must be reminded to pay attention to her teeth everyday so as not to overbleach.⁸ When this material is in contact with teeth, hydrogen peroxide will loose and penetrate into the surface of enamel and dentine due to the relatively low molecular weight of peroxide (30 g/mol). These reactive molecules attack dark chromophore molecules and long chains and break down these molecules into smaller, more colourless, and more diffuse molecules.^{6,8}

The success of the intracoronal bleaching in endodontically treated teeth depends on the etiology, the precise diagnosis, and the selection of appropriate bleaching techniques. Walking bleach technique is chosen because it takes a shorter time, safer and more comfortable for the patient. Internal bleaching indications on the teeth that have been treated endodontically are: discoloration in the pulp chamber, dentine discoloration, discoloration which can not be lost with extracoronal bleaching. Internal bleaching contraindications: superficial discoloration, enamel formation with defects, severe dentine loss. The cervical seal/barrier used is the glassionomer to cover endodontic obturation. The coronal height closes the dentinal tubules and corresponds to the external epithelial attachment. The barrier thickness is approximately 2 mm, and is located 1 mm below the cemento-enamel junction.^{6,8}

This protection is carried out to prevent the occurrence of internal bleaching side effects in the form of external root resorption. Resorption occurs because of chemicals diffused through the dentine tubules and cementum defects. The leakage which occur can cause cementum necrosis, inflammation of the periodontal ligament so that eventually root resorption occurs. The application of bleaching material leads to denaturation of dentine protein with oxidizing agents and pH acid which induces foreign body reaction. A low PH of bleaching material can damage tissues due to the optimal acidic environment for osteoclas activity results in the root resorption.^{8,9,10}

In this case, restoration after internal bleaching using a composite resin. The remaining peroxide of the bleaching material, especially hydrogen peroxide can affect the strength of composite bonding, so it is advisable to wait several days after bleaching before the composite restoration is performed. The placement of calcium hydroxide in the pulp chamber for several days is useful for buffering acidity caused by bleaching material.

CONCLUSION

Internal bleaching procedures for traumatized teeth was the best option to restore the function and aesthetics according to the original tooth color.

References

1. Izidoro AC et al. 2015. *Combine Technique for Bleaching Non-Vital Teeth with 6-Month Clinical Follow Up*. Int J Oral Dent Health 1(2):1-4.
2. Almohareb T. 2017. *Management of Discolored Endodontically Treated Tooth Using Sodium Perborate*. J Int Oral Health. 9:133-5.
3. Awadhiya S, Narang A, Agarwal M, Jain M. 2018. *Nonvital Bleaching: A Case Series on Whitening Procedure for Discolored Endodontically Treated Teeth*. Int J Prosthodont Restor Dent. 8(1):28-31.
4. Abdelkader NN. 2015. *Modified Technique for Nonvital Tooth Bleaching: A Case Report*. Electronic Physician. 7(6): 1423-1426.
5. Bahuguna N. 2013. *Cervical Root Resorption and Non Vital Bleaching*. Endodontology. 25(1): 106-11.
6. Nagaveni NB, Umashankara KV, Radhika NB, Satisha TS. 2011. *Management of Tooth Discoloration In Non-Vital Endodontically Treated Tooth-A Report of 6 Year Follow Up*. J Clin Exp Dent. 3(2): 180-3.
7. Ambalia SV, Ramgadhia. 2017. *Nonvital Tooth Bleaching, Noninvasive Technique: A Case Report*. Journal of Dental and Medical Sciences. 16(3): 80-82.
8. Raina et al. 2017. *Report of Two Cases Using Vital Tooth Bleaching on Fluorosed Teeth*. J Dent Sci 4(1):47-50.
9. Jagannathan N, Neelantakan P. 2012. *Non Vital Bleaching- A Non Invasive Post Endodontic Treatment Option- A Case Report*. Journal of Clinical and Diagnostic Research p:1-3.
10. Plotino et al. 2010. *Nonvital Tooth Bleaching: A Review of The Literature and Clinical Procedures*. JOE. 3(4):1-2.

Management Of Non-Vital Teeth Discoloration With The Internal Bleaching : A Case Report

ORIGINALITY REPORT

10%	9%	3%	%
SIMILARITY INDEX	INTERNET SOURCES	PUBLICATIONS	STUDENT PAPERS

PRIMARY SOURCES

1	repository.unhas.ac.id Internet Source	5%
2	www.ordoneardentistrylibrary.org Internet Source	1%
3	repository.unair.ac.id Internet Source	1%
4	www.veterinaryworld.org Internet Source	1%
5	"Poster abstracts of the 6th biennial meeting of the European Federation of Conservative Dentistry (EFCD) held in association with the 33th national congress of the College National des Enseignants en Odontologie Conservatrice (CNEOC), France, 9–11 May 2013, Paris, France", Clinical Oral Investigations, 2013 Publication	1%
6	www.medicinaoral.com Internet Source	<1%

7 Arikan, V.. "Bleaching a devital primary tooth using sodium perborate with walking bleach technique: A case report", Oral Surgery, Oral Medicine, Oral Pathology, Oral Radiology and Endodontology, 200905 <1%
Publication

8 "Thursday, 31 August 2017 - Free Communication Sessions 49-72 and Poster Sessions 48-67", International Dental Journal, 2017 <1%
Publication

9 Dalia A. Saba, Rania A. Salama, Rasha Haridy. "Effect of different beverages on the color stability and microhardness of CAD/CAM hybrid versus feldspathic ceramic blocks: An in-vitro study", Future Dental Journal, 2017 <1%
Publication

Exclude quotes Off

Exclude matches Off

Exclude bibliography On