

Management of Non-Vital Teeth Discoloration with the Internal Bleaching : A Case Report

by Sukaton Sukaton

Submission date: 09-Apr-2023 07:41PM (UTC+0800)

Submission ID: 2059491107

File name: 13558-Article_Text-26018-1-10-20210104_skt_2.pdf (921.31K)

Word count: 2370

Character count: 13022

Management of Non-Vital Teeth Discoloration with the Internal Bleaching : A Case Report

Dewi Fitria Anugrahati¹, Rizky Ernawati¹, Windi Irsya¹, Yulianti Kartini Sumur¹,
Sukaton², Kun Ismiyatin²

¹Resident of Conservative Dentistry Department, Faculty of Dental Medicine, Universitas Airlangga, Surabaya, Indonesia, ²Staff of Conservative Dentistry Department, Faculty of Dental Medicine, Universitas Airlangga, Indonesia

Abstract

Tooth discoloration due to intra coronal bleeding after trauma can cause aesthetic disturbances and appearance. Internal bleaching is a non-invasive method to restore tooth color which is performed after endodontic treatment by placing a strong oxidizing agent in the pulp chamber. Aim of this study was to report the success of internal bleaching procedure to restore discolored teeth due to trauma. A 44-year-old female came to Conservative Dentistry Universitas Airlangga with chief complaint of the upper right insisor tooth looks darker than the adjacent teeth. The patient had fallen 10 years ago from her motorcycle and her tooth had been painful and then the pain disappeared. In intra oral clinical examination, it showed that tooth 11 had discoloured, vitality test of tooth 11 showed no response to electric pulp test. Radiographic view showed that radiolucen in periapical area and no fracture was found. At the first visit, treatment of single visit root canal using rotary instrument and gave dressing calcium hydroxide. A week later on the second visit, internal bleaching with hydrogen peroxide 35% was done. After bleaching, calcium hydroxide was applied to neutralize the oxidizing agent and then re-evaluated for the color. At the third visit, it showed that the tooth colour was obtain as desire from C3 to A3 (Vitapan Classical). The internal bleaching procedure on the traumatized tooth was the best option to restore the function and aesthetics according to the original tooth colour and also provided benefits in terms of saving time, lower price, and maximum results.

Keywords: non-vital teeth, internal bleaching, discoloration

Introduction

Discoloration of teeth can be caused by intrinsic, extrinsic or a combination of both. The occurrence of discoloration is caused by the incorporation of intrinsic chromatogenic materials into dentine and enamel during odontogenesis or after the eruption of teeth¹. The intrinsic cause of discoloration in pre-erupted teeth is the provision

of tetracycline or high number of fluoride exposure. In addition, it also can be caused by hereditary diseases such as amelogenesis imperfecta and dentinogenesis imperfecta². After the eruption of teeth, the main cause of discoloration is the pulp necrosis, the deposition of the blood component to the dentine tubules after trauma or pulpectomy, and secondary dentine deposition due to aging or iatrogenic^{2,3}. Foods and beverages such as coffee, tea, red wine, carrots, oranges, and tobacco are primarily responsible for extrinsic stains³.

Teeth whitening offers a conservative and aesthetic solution and is an option because it is not invasive, such as crowns or porcelain veneer. The non-vital teeth whitening technique puts the oxidizing agent inside the pulp chamber in direct contact with dentine. Chemicals which are often used as bleach are hydrogen peroxide 35%⁴. Walking bleach technique is a bleaching method

Corresponding authors:

Kun Ismiyatin

Conservative Dentistry Department, Faculty of Dental Medicine, Universitas Airlangga, Jl. Prof. DR. Moestopo No. 47, Surabaya - 60132, Indonesia
Phone numbers : +6231 5030255
Fax phone : +6231 5020256
E-mail address : kunismiyatin.fkgua@gmail.com

by placing the active ingredient in the pulp chamber, followed by closing the tooth cavities. The results obtained depends on the etiology of discoloration and for a satisfactory result bleaching can be carried out for two to four times the application⁴. The case report aims to demonstrate the success of non-vital teeth whitening that has discoloration after the endodontic treatment performed using a walking bleach technique with a good prognosis and without side effects

Case Report

A 44-year-old female came to Conservative Dentistry and Endodontics Clinic Airlangga University with chief complaint of the upper right insisor tooth looks darker than the adjacent teeth. Patient had fallen 10 years ago from her motorcycle and her tooth had been painful and then the pain disappeared. The patient wants her tooth colour same as the adjacent teeth. Patient does not has a history of systemic diseases.

Extra oral examination shows symmetrical face, no abnormalities of the lips, the left and right mandibular glands are unaffected and painless. Intra-oral examination showed that crown of tooth 11 is darker in colour than the adjacent teeth. Hygiene of the oral cavity is good, it shows an overview of radiolucency on periapical area. Examination of negative percussion test, negative bite test and negative palpation.

Radiographic view after endodontic treatment shows the radiopaque depiction of the crown to the apex which means that it fills the hermetic root canal. There is widening of lamina dura, alveolar bone resorbtion and radiolucen in periapical area which are smaller than before endodontic treatment.

On the first visit, the patient was given an explanation of the procedure to be performed. The cost of treatment, side effects can occured, possible outcame to be achieved, failures and complications about the use of bleaching material understood by the patient and then carried out the signing of informed consent. The next step was to do single visit root canal treatment using rotary instrument and given dressing calcium hydroxide.

A week later on the second visit, internal bleaching with hydrogen peroxide 35% was carried out for 7 days. Previously, it was carried out tooth colour recording before treatment and intra oral photographs. Previously, the tooth was cleaned using a rotary brush and pumice powder to obtain the actual colour. The tooth colour was matched using Vitapan classical shade guide. In this case, the initial colour was C3 and the colour which want to achieve was A3 colour.

The working area was isolated with rubber dam and coronal access was carried out by reopening the temporary patch using a rounded diamond bur. The root canal filler material was ejected to a depth of 2 mm below the CEJ by using a hot plugger that has been given a stopper to provide a place for cervical seal material. The depth of filler intake was confirmed again using periodontal probe. Tooth 11 cavity was irrigated with sterile aquadest until clean and dried. The cervical seal was made by applying 2 mm thick glass ionomer cement following the cervical stripe outline. The resultant shape from a facial view is the "bobsled tunnel" outline. The outline from the proximal view resembles a "ski-slope" (Figure 1, 2).⁵ After the cervical seal dried, the bleaching material in the form of hydrogen peroxide gel 35% (Opalescence Endo, Ultradent Product Inc., USA) was applied to the labial part, then the pulp chamber was given with cotton pellet and covered with glass ionomer cement. The patient was instructed to control 1 week later.

On the third visit, a subjective examination was conducted, it was no complaints from the patient. Objective examination showed that tooth discoloration from C3 to A3 (Vitapan Classical). Two weeks later, the tooth was restored by composite materials which in accordance with the tooth colour.

On the third visit, a subjective examination was conducted, it was no complaints from the patient. Objective examination showed that tooth discoloration from C3 to A3 (Vitapan Classical). Two weeks later, the deposition was carried out by composite materials which in accordance with the tooth colour.

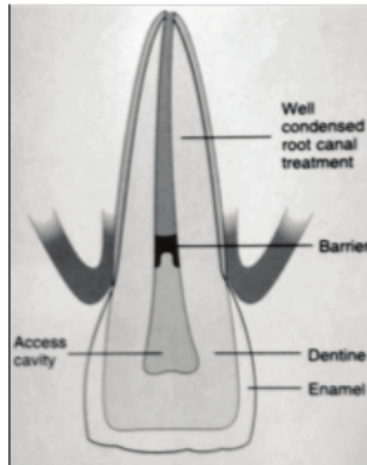


Figure 1. Bobsled Tunnel Appearance

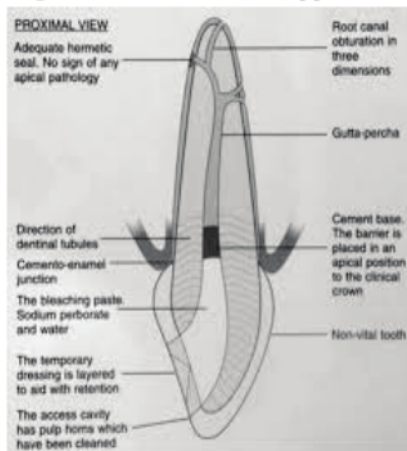


Figure 2. Ski Slope Appearance

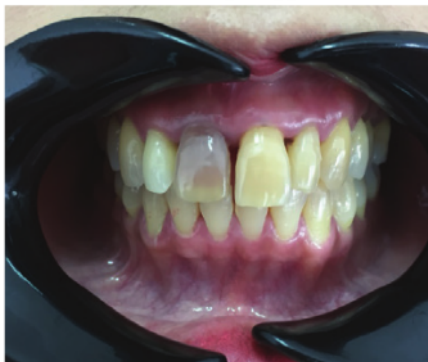

Figure 3. Preoperative photograph of discolored tooth

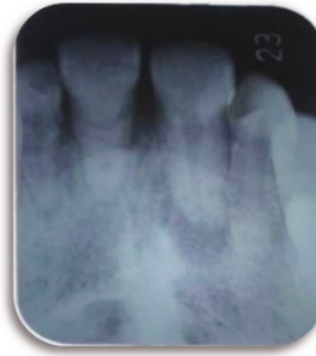

Figure 4. Preoperative radiograph

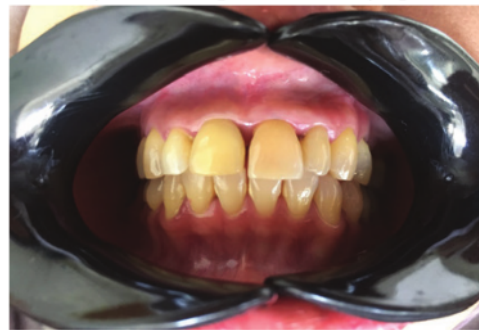

Figure 5. Post Operative Photograph

Discussion

Tooth staining especially in the anterior teeth can interfere with a person's appearance. In addition to invasive treatment, such as the making of crowns or veneer, tooth whitening or bleaching can be an alternative treatment. Contrary to the making of crowns or veneer, tooth bleaching is a relatively non-invasive treatment. The tooth bleaching which has been carried out before root canal treatment can be done with internal bleaching treatment⁵. In this case, the tooth discoloration in the tooth 11 is caused by intrinsic factors.

Necrosis in the tooth 11 is caused by trauma that occurred about 10 years ago. Trauma to the tooth causes intra pulpa bleeding and erythrocytes lysis. Blood or blood components that bathe the pulp chamber will enter the dentinal tubules diffusely, resulting in a discoloration of the tooth crown. The discoloration which occurs relates to how long the pulp has become necrosis, the longer the colored compounds are in the pulp, the greater the degree of discoloration⁵.

Bleaching is a more conservative alternative

treatment than making of the crown and labial veneer in the stained teeth. The chemical process in bleaching occurs when the whitening material is applied to the teeth, usually using oxidizing materials such as hydrogen peroxide, chlorine or sodium hypochlorite. Although the bleaching process is a complex chemical process, the basic principle of the majority of bleaching processes is the step-by-step oxidation of the dye with decomposition. Bleaching material is oxidizing, reacting to the organic structure of a hard tooth tissue, pigments which have long chains slowly degraded into simple molecules such as carbon dioxide, oxygen and water which have a brighter colour, inorganic molecules are not broken down, the reduction-oxidation reaction which occurs in the bleaching process is known as redox reaction. In general, unstable peroxide becomes unstable free radicals. These free radicals oxidize other molecules⁵⁻⁷.

Hydrogen peroxide is a strong oxidizing agent. The use of high concentration of hydrogen peroxide must be careful because it is unstable thermodynamically and can explode, because it must be placed in the refrigerator and stored on a dark container. Bleaching materials can be applied using the plastic and plugger instruments and must be replaced every 3-7 days. Usually it takes 2-4 sessions depending on the intensity of discoloration. The patient must be reminded to pay attention to her teeth everyday so as not to overbleach. 8 When this material is in contact with teeth, hydrogen peroxide will loose and penetrate into the surface of enamel and dentine due to the relatively low molecular weight of peroxide (30 g/mol). These reactive molecules attack dark chromophore molecules and long chains and break down these molecules into smaller, more colourless, and more diffuse molecules^{6,8}.

The success of the intracoronal bleaching in endodontically treated teeth depends on the etiology, the precise diagnosis, and the selection of appropriate bleaching techniques. Walking bleach technique is chosen because it takes a shorter time, safer and more comfortable for the patient. Internal bleaching indications on the teeth that have been treated endodontically are: discoloration in the pulp chamber, dentine discoloration, discoloration which can not be lost with extracoronal bleaching. Internal bleaching contraindications: superficial discoloration, enamel formation with defects,

severe dentine loss. The cervical seal/barrier used is the glassionomer to cover endodontic obturation. The coronal height closes the dentinal tubules and corresponds to the external epithelial attachment. The barrier thickness is approximately 2 mm, and is located 1 mm below the cemento-enamel junction^{6,8}.

This protection is carried out to prevent the occurrence of internal bleaching side effects in the form of external root resorption. Resorption occurs because of chemicals diffused through the dentine tubules and cementum defects. The leakage which occur can cause cementum necrosis, inflammation of the periodontal ligament so that eventually root resorption occurs. The application of bleaching material leads to denaturation of dentine protein with oxidizing agents and pH acid which induces foreign body reaction. A low PH of bleaching material can damage tissues due to the optimal acidic environment for osteoclas activity results in the root resorption⁸⁻¹⁰.

In this case, restoration after internal bleaching using a composite resin. The remaining peroxide of the bleaching material, especially hydrogen peroxide can affect the strength of composite bonding, so it is advisable to wait several days after bleaching before the composite restoration is performed. The placement of calcium hydroxide in the pulp chamber for several days is useful for buffering acidity caused by bleaching material.

Conclusion

Internal bleaching procedures for traumatized teeth was the best option to restore the function and aesthetics according to the original tooth color.

Funding : None

Conflict of Interest: None

Ethical Permission : Approved

References

1. Claudia Santos de Azevedo Izidoro A, Cristine Martins G, Higashi C, Zander-Grande C, Yileng Tay L, Carlos Gomes J, et al. International Journal of Oral and Dental Health Combined Technique for Bleaching Non-Vital Teeth with 6-Month Clinical Follow-Up: Case Report. *Int J Oral Dent Heal*.

- 2015;1(2).
2. Almohareb T. Management of discolored endodontically treated tooth using sodium perborate. *J Int Oral Heal*. 2017 May 1;9(3):133–5.
3. Agarwal M, Narang A, Awadhiya S, Jain M. Nonvital Bleaching: A Case Series on whitening Procedure for Discolored Endodontically Treated Teeth. *Int J Prosthodont Restor Dent*. 2018 Mar;8(1):28–31.
4. Abdelkader NN. Modified Technique for Nonvital Tooth Bleaching: A Case Report. *Electron physician*. 2015;7(6):1423–146.
5. Bahuguna N. Cervical root resorption and non vital bleaching.
6. Nagaveni NB, Umashankara K V., Radhika NB, Satisha TS. Management of tooth discoloration in non-vital endodontically treated tooth - A report of 6 year follow-up. *J Clin Exp Dent*. 2011 Apr;3(2).
7. Ambalia D V, Singh Ramgadhia H. Nonvital Tooth Bleaching, Noninvasive Technique: A Case Report. *IOSR J Dent Med Sci e-ISSN [Internet]*. 2017 [cited 2020 Feb 21];16(3):80–2. Available from: www.iosrjournals.org
8. Saha P, Sawhny A, Paul S, Raina A. Fluorosis and vital tooth bleaching Report of Two Cases using Vital Tooth Bleaching on Fluorosed Teeth. Vol. 4, *Rama Univ J Dent Sci*. 2017.
9. Neelakantan P, Jagannathan N. Non vital bleaching - A non invasive post endodontic treatment option: A case report. *J Clin Diagnostic Res*. 2012 May 1;6(3):527–9.
10. Plotino G, Buono L, Grande NM, Pameijer CH, Somma F. Nonvital Tooth Bleaching: A Review of the Literature and Clinical Procedures. Vol. 34, *Journal of Endodontics*. 2008. p. 394–407.

Management of Non-Vital Teeth Discoloration with the Internal Bleaching : A Case Report

ORIGINALITY REPORT

10%

SIMILARITY INDEX

10%

INTERNET SOURCES

6%

PUBLICATIONS

1%

STUDENT PAPERS

PRIMARY SOURCES

1	clinmedjournals.org Internet Source	4%
2	chikitsakjournal.co.in Internet Source	2%
3	www.readkong.com Internet Source	1%
4	I. Gusti Aju Wahyu Ardani, Ike Sesaria Pratiknjo, Irwadi Djaharu'ddin. "Correlation between Dentoalveolar Heights and Vertical Skeletal Patterns in Class I Malocclusion in Ethnic Javanese", European Journal of Dentistry, 2020 Publication	1%
5	Submitted to Universitas Airlangga Student Paper	1%
6	journals.sbm.ac.ir Internet Source	<1%
7	www.iosrjournals.org Internet Source	<1%

Exclude quotes Off

Exclude matches < 10 words

Exclude bibliography On

Management of Non-Vital Teeth Discoloration with the Internal Bleaching : A Case Report

GRADEMARK REPORT

FINAL GRADE

/0

GENERAL COMMENTS

Instructor

PAGE 1

PAGE 2

PAGE 3

PAGE 4

PAGE 5
