

# Tinea Capitis Kerion Type: A Case Report

*by* Dyah Ratri Anggarini

---

**Submission date:** 11-Feb-2023 11:16AM (UTC+0800)

**Submission ID:** 2011380927

**File name:** 22.\_Tinea\_Capitis\_Kerion\_Type\_A\_Case\_Report.pdf (598.53K)

**Word count:** 4671

**Character count:** 23870

---

## LAPORAN KASUS

---

### Tinea Capitis Kerion Type: A Case Report

Dyah Ratri Anggarini, Trisniartami Setyaningrum

Departement of Dermato and Venereology Faculty of Medicine Airlangga University

Dr. Soetomo General Hospital Surabaya-Indonesia

#### ABSTRACT

**Background:** Tinea capitis is a superficial fungal infection. Kerion is one of its form, which is an inflammation form due to a hypersensitivity reaction to fungal infection caused by group *Mycosporum* and *Trichophyton*. **Purpose:** To understand the clinical manifestation, species causing agent, and management of tinea capitis. **Case management:** A four-year-old boy, 17 kg, came with a mass on the head, accompanied with pain, fever, and hair loss since 1 week before hospitalization, it appeared after playing with the neighbor's pets. General examination showed enlargement of the right preauricular lymph node. Dermatological examination revealed a mass in the head 7 cm in size with pus, partially covered with crust, and there were also warm and pain on palpation. Wood lamp examination was negative, but in potassium hydroxide examination showed spores outside and inside the hair shaft. Result of fungal cultures was *T. mentagrophytes*. Routine blood tests obtained only leukocytosis, which was 12.390/ $\mu$ L. The patient was treated with griseofulvin, erythromycin, wet dressing, and ketokonazole shampoo. It was shown good results after therapy for 8 weeks. **Conclusions:** Tinea capitis caused by *T. mentagrophytes* presenting an inflammatory reaction, causing a fungal infection in the hair shaft. Auxiliary examination for the diagnosis of tinea capitis can be done in various ways, the easiest one is by potassium hydroxide 20% examination, fungal culture is then performed to determine the species causing the infection. Therapeutic use of griseofulvin is still the main choice.

**Key words:** tinea capitis kerion type, *T. mentagrophytes*, griseofulvin.

#### ABSTRAK

**Pendahuluan:** Tinea kapitis adalah infeksi jamur superfisial. Kerion adalah salah satu bentuknya, merupakan bentuk inflamasi karena reaksi hipersensitifitas terhadap infeksi jamur yang disebabkan golongan *Mycosporum* dan *Trichophyton*. **Tujuan:** Mengetahui gambaran klinis, spesies penyebab dan penatalaksanaan tinea kapitis. **Kasus:** Anak laki-laki, 4 tahun, 17 kg, datang dengan keluhan benjolan di kepala, terasa nyeri, demam, dan rambut rontok sejak 1 minggu sebelum masuk RS. Keluhan dirasakan setelah penderita bermain dengan binatang peliharaan milik tetangga. Pada pemeriksaan umum didapatkan adanya pembesaran kelenjar getah bening preaurikular kanan. Pada pemeriksaan dermatologis didapatkan benjolan di kepala berukuran 7 cm dengan pus, sebagian tertutup krusta, teraba hangat dan nyeri. Pada pemeriksaan lampu Wood hasil negatif, pada pemeriksaan KOH didapatkan spora di luar dan dalam batang rambut. Biakan dengan agar *Sabouroud Dextrose* tumbuh *T. mentagrophytes*. Pada pemeriksaan darah rutin hanya didapatkan lekositosis sebesar 12.390/ $\mu$ L. **Penatalaksanaan:** Terapi yang diberikan adalah griseofulvin, eritromisin, kompres basah, dan sampo ketokonazole. Hasil baik didapatkan setelah pemberian terapi selama 8 minggu. **Simpulan:** Tinea kapitis disebabkan oleh bermacam-macam spesies jamur. *Trichophyton mentagrophytes* menyebabkan reaksi inflamasi. Pemeriksaan penunjang untuk penegakan diagnosis tinea kapitis dapat dilakukan dengan berbagai macam cara, salah satunya dengan pemeriksaan KOH 20%, dilanjutkan kultur jamur untuk menentukan spesies penyebab. Terapi menggunakan griseofulvin masih merupakan pilihan utama.

**Kata kunci:** tinea kapitis tipe kerion, *T. mentagrophytes*, griseofulvin.

Correspondence address: Dyah Ratri Anggarini, Departement of Dermatology and Venereology Faculty of Medicine Airlangga University, Dr. Soetomo General Hospital Surabaya-Indonesia, Mayjen Prof. Dr. Moestopo Rd 6-8 Surabaya 60131, Telepon: +62315501605, e-mail: dr\_r1n1@yahoo.com

#### INTRODUCTION

Tinea capitis is a superficial fungal infection, affecting the scalp and hair. The cause is a fungus species, most commonly *Trichophyton* and

*Microsporium*.<sup>1,2,3,4</sup> The fungi are classified into three group according to where they are normally found. Geophilic organism lives in soil, zoophilic organism on animal, and anthropophilic organism on human. The

clinical appearances can be classified into grey patch, black dot, and kerion. Grey patch type showed circular pattern of alopecia with marked scalling. In black dot type, the dermatophytes invade the inside of the hair shaft, making it fragile and vulnerable to fracture so we can found swollen tubs of broken off hairs within the patch of alopecia. Kerion, boogy, localized swelling occur due to an aggressive inflammatory response to the organism, the patients often also have cervical lymphadenopathy. In diffuse scale, the form looks like dandruff with generalized scalling throughout scalp that can be masked with hair oils. Diffuse pustular pattern showed scattered pustules associated with alopecia scarring, it is maybe associated with painful lymphadenopathy. This is the most difficult type to diagnose and often incorrectly treated with antibiotics, because pus usually occurs in bacterial infections.<sup>2,3</sup>

The prevalence of tinea capitis in Spain was 0.23%, Turkey 0.3%, Madrid 0.64%, Barcelona 0.23%, London 2.5%, Ivory Coast 11.34%, and in Cleveland was 13%.<sup>5</sup> In the late 19<sup>th</sup> and early 20<sup>th</sup> centuries, *M. audouinii*, followed by *M. canis*, was the main causative agent in Western and Mediterranean Europe, whereas *T. schoenleinii* was the predominant agent in Eastern Europe, the most common cause worldwide is *M. canis*, in United State the most causing agent is *T. tonsurans* followed by *M. canis*. Anthropophilic dermatophytes, in particular *T. tonsurans*, have now emerged as the dominant agents in many regions. *T. tonsurans* has worldwide distribution and causes principally tinea capitis.<sup>1,6,7,8</sup> In the Middle East, *T. violaceum* is responsible for most cases of tinea capitis, 83% in Israel, 39% in Iraq, 64% in Libya.<sup>5</sup> The previous study made by Isa-Isa et al, revealed that the fungi caused kerion type were *M. canis* (32%), *T. mentagrophytes* (27%), *T. tonsurans* (21%), *M. gypseum* (5%) and *T. rubrum* (10%).<sup>9</sup> A retrospective study by Brook I. et al, evaluated the fungal and aerobic and anaerobic bacteriology in kerion type and showed that aerobic bacteria responsible in inflammatory process in 19/30 person (57%).<sup>10</sup> Incidence of tinea capitis in Micology Division Dr. Soetomo General Hospital Surabaya 2001-2006 was 0.31-1.55% while in Medan at 1996-1998 was 0.4%, Cipto Mangunkusumo Hospital Jakarta at 1989-1992 was 0.61-0.87% and in Manado at 1990-1991 was 2.2-6%.<sup>11</sup>

Tinea capitis predominantly occurs in preadolescent children (between 3-14 year old), uncommon in adult, boys are affected most than girls,

perhaps due to shorter hair allowing easier access for infecting fungal spores. Some factors that associated with the incidence of tinea capitis include poor personal hygiene, overcrowding, and low socio-economic level. Transmission of infection occurs via infected skin scales and hairs shed from infected human or animal host, or through the use of contaminated combs, hairbrushes, and other hairdressing equipment. The incubation period is short, 1-3 weeks.<sup>1,2,8,12</sup> The degree of inflammation is generally larger when zoophilic fungi are the cause.<sup>13</sup> The effects of tinea capitis on the children can be stark and tragic, they can be ridiculed and bullied by their classmates and playmates. This can lead to social ostracism and feeling inadequacy and low selfesteem.<sup>8</sup>

Diagnosis is ideally confirmed by microscopic observation of fungal elements in specimens of infected skin, hair obtained by scalp scrapings with the blunt side of a scalpel or hair plucked from the affected site. The Wood's light, which was traditionally used to diagnose, can detect infection by only *Microsporum sp.*<sup>3,13</sup> Tinea capitis requires systemic treatment because antifungal cream are unable to penetrate the hair shaft sufficiently to clear the infection. Furthermore, the use of topical antifungal treatment alone may contribute to the creation of carriers. Griseofulvin is the 'gold standard' for treatment of dermatophyte infections in children.<sup>1,2,8,14</sup>

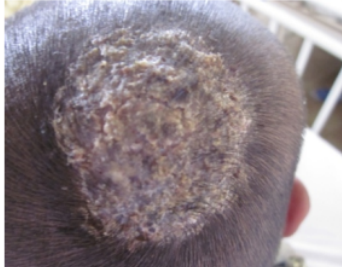
#### CASE REPORT

A four-year-old boy, 17 kg, with chief complaint mass on his head since 1 week before hospitalization. It is accompanied with fever, pain, and hair fall. The complaint appeared after he played with neighbor's cat. First it appeared as itchy red macule covered with thin scales, then became a mass, which felt pain. He also felt fever. His hair fell only on the mass side. He also complained about mass behind his right ear appeared along with the mass on the scalp. This was the first time he got this disease. No family member suffered from the same disease. No classmates suffered from the same disease. No history of drug or food allergy.

General physical examination on the first day admission revealed an alert boy, look well with no sign of anemic, icterus, cyanotic, or respiratory distress. The blood pressure was 100/70 mmHg, pulse rate 88 times per minute, respiratory rate 20 times per minute and body temperature was 37,7° C. There was an enlargement of right retroauricular lymphnode. There

was no abnormality on thorax and abdominal examination.

The dermatological state on region scalp there was an inflammatory mass with diameter 7 cm, studded with broken hair and follicular orificium oozing with pus and crust. The mass felt pain and warm on palpation (Figure 1).



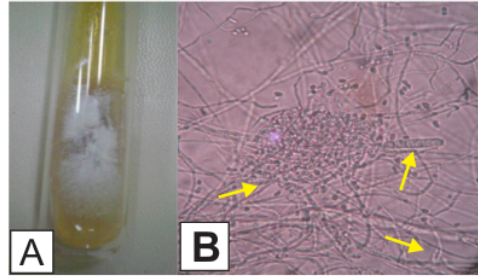
**Figure 1.** Tinea capitis kerion type on the scalp, with an inflammatory mass.

Laboratory examination on the first day showed leukocytosis. Hemoglobin was 12.3 g/dL, white blood cell was  $12.39 \times 10^3/\mu\text{L}$ , erythrocyte sedimentation rate was 45mm/hour, platelet was  $422 \times 10^3/\mu\text{L}$ . Urinary examinations were within normal limit. Wood's lamp examination was negative. Potassium hydroxide 20% examination revealed spores outside and inside the hair shaft (Figure 2). Culture was using Sabouraud's Dextrose Agar (SDA) and the result showed development of *T. mentagrophytes*, which is white to creamy with a cotton mounded surface, none to light brown reverse pigment (Figure 3). Microscopic examination showed clustered round of microconidia, rare cigar shaped of macroconidia, spiral hyphae (Figure 3).

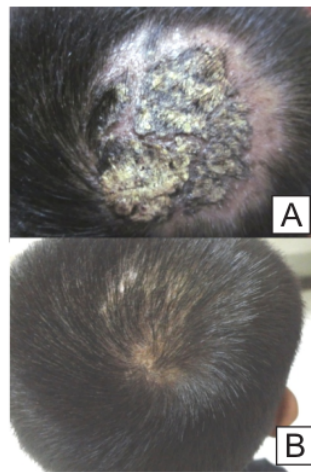
Patient was treated with griseofulvin 2x170 mg daily, erythromycin 4x100 mg, wet dressing with NaCl 0,9% to reduce the inflammation. After 1 week therapy, the mass decreased to 6 cm, no pus, no fever anymore so



**Figure 2.** Potassium hydroxide 20% + parker ink examination, spores outside and inside the hair shaft, magnification 40x.



**Figure 3.** Development of *T. mentagrophytes* on Sabouroud's Dextrose Agar (A) and microscopic appearance from fungi culture with lactophenol cotton blue, magnification 400x, clustered round microconidia, rare cigar shaped macroconidia, spiral hyphae (B).




**Figure 4.** The lesion at 4 weeks (A) and completely healing (B)

the antibiotics was stopped. After 2 weeks of treatment, the mass was decreased to 5.5 cm and there was crust on top of the lesion. The antifungal drugs were given, continued with wet dressing with NaCl 0,9%, and ketokonazole 2% shampoo 3 times weekly as a topical treatment. After 4 weeks of treatment the crust still persisted, with alopecia surrounding the mass (Figure 4). The therapy was continued and necrotomy was performed. At the 8 weeks of therapy there was alopecia area without any crust.

## DISCUSSION

Tinea capitis can be classified according to the microscopic pattern of fungal invasion as endothrix and ectothrix. Endothrix infections are characterized by arthroconidia (spores) within the hair shaft, replacing



**Figure 5.** Potassium hydroxide 20% + parker ink examination magnification 400x to confirm completely healing of tinea capitis. No spores inside or outside hair shaft anymore.

the intrapapillary keratin, but the cuticle is not destroyed. The hyphae grows downwards along the hair shaft. The hair is fragile, and breaks off at the base, where support from follicular wall is lost, leaving behind a tiny black dot. Generally it is caused by anthropophilic agents. Ectothrix infections can be either anthropophilic, zoophilic, or geophilic agents, characterized by mycelia fragmenting into arthroconidia on the outside of the hairshaft, just under the cuticle, which leads to cuticle destruction. The infection is in the perifollicular stratum corneum, spreading around and into the hair shaft of mid to late anagen hairs, the hairs break off at any level above the scalp.<sup>1,2,12,14</sup> The diagnosis of tinea capitis can be made by the additional examination. Abdo HM et al, reported that the sensitivity of potassium hydroxide 20% was 85.71%, while culture just 60%. Another study by Tandon et al, reported the sensitivity of potassium hydroxide 20% was 65.43% while from culture was 46.97%.<sup>15</sup>

The clinical appearance of tinea capitis is variable, depending on the type of hair invasion, the level of host resistance and the degree of inflammatory host response. In all types, the cardinal features are partial hair loss with inflammation of some degree. It is very important to confirm the diagnosis with a fungal culture before committing the patient to a course of treatment. A prominent cervical or occipital lymphadenopathy occurs in all types of tinea capitis and it is an important clinical clue to the proper diagnosis of the disease. Without adenopathy, the diagnosis of tinea capitis should be questioned because it is seldom associated with other noninfectious cause of hair loss.<sup>7,8,12,16</sup>

The inflammatory forms of tinea capitis are

divided into 2 groups. The most common is the hypersensitivity type or kerion celsi, characterized by an inflammatory mass that is painful on palpation and accompanied by regional adenopathy, shows a little tendency toward spontaneous recession, initiated as a dry tinea involving one or more pseudoalopecia plaques with scalling and short hairs, erythema and inflammation generating a painful lesion with clear border that covered with numerous pustules producing abundant pus and keratin debris. They are rarely secondarily infected with bacterial, although *S. aureus* may grow under a crust. Within around 8 weeks, the tissue response and cell mediated immunity leads to complete elimination of the fungi, but as consequence leaves behind areas of definitive alopecia with fibrosis due to the sustained attack on the hair follicle.<sup>12,17</sup>

Examination with Wood's lamp is useful technique because it is inexpensive, accessible, and practical. It will be negative in cases of tinea capitis involving *Tricophyton* species. It is a useful screening procedure and can be combined with another examination. In this case the Wood's lamp examination was negative and continued with potassium hydroxide 20% examination from the plucked hair stubs using sterile forceps to include the hair roots. A drop of potassium hydroxide 20% was placed next to the material and then thoroughly mixed then a cover slip was applied. The preparation was left for 20-60 minutes until softening and digestion of the specimen occurred. The presence of fungal element (hyphae and/or spores) within and/or around hair shaft under microscope magnification was considered to be a positive test. In this case we can found spores outside and inside the hair shafts.<sup>1,12,15,17</sup>

The sample for potassium hydroxide should also be inoculated in fungal culture medium such as Sabouroud's Dextrose Agar. The media were then incubated in a warm, moist environment at 28°C and examined regularly to detect growth of any fungus. Observation for growth of the colony was done periodically for 1 until 6 weeks after which the media were reported as positive or negative. The fungi were identified by colonial morphology and microscopic structures. Colonial morphology includes color, size, texture, and topography of the colony. The microscopic structure of fungi provide a definitive identification, includes the type, size, shape, and arrangement of spores and the size and color of hyphae.<sup>12,15</sup> In this case there was a growth of white to creamy colony with a cottony mounded surface, none to light brown reverse pigment.

The microscopic structures were clustered round microconidia, rare cigar shaped macroconidia, spiral hyphae. This is the identification of *Trichophyton mentagrophytes*.

Differential diagnosis for tinea capitis is vary, includes all conditions capable of causing patchy baldness with inflammatory changes of the scalp. Seborrheic dermatitis is one of it. This condition is chronic, relapsing inflammatory skin disease with predilection for areas rich in sebaceous glands. This disorder is characterized by scalling and sharply demarcated erythematous patches with greasy scales, with large variation in extent and morphologic characteristic depending on area of skin involved. It is triggered by stress and exposure to the sunlight. The cause are incompletely understood, fungi from genus *Malassezia* have been considered potentially pathogenic agent for this disease. This disease is usually more diffuse than tinea capitis.<sup>16,18,19</sup> In this case the disease appeared after the patient having contact with neighbor's cat, no relevance with sun exposure. The lesion was firstly revealed as an inflammatory mass, and also itchy erythematous macule with dry scale.

The other differential diagnosis is alopecia areata. In alopecia areata may show erythema but it is not common showing scaly condition. It is a chronic inflammatory disease which affects the hair follicles and sometime the nails. Onset may be at any age, usually presents as patches of hair loss on the scalp but any hair-bearing skin can be involved. Short broken hairs are frequently seen around the margins of expanding patches of alopecia areata. About 20% people with alopecia areata have family history of the disease.<sup>16,20</sup> Another differential diagnosis is psoriasis, it is a common, chronic disfiguring inflammatory disease of the skin, usually characterized by well defined scally, red, and indurated plaque mainly over extensor surface. This disease is usually relapsing and remitting with variation in severity and clinical manifestation. The onset of this disease between 15-30 years old, it is uncommonly occur under 10 years of age. The lesions often develop at site of skin trauma (Koebner phenomenon) such as knee, elbow, and scalp, and it may remain localized or become generalized over time. In psoriasis hair loss is found occasionally, broken-off hairs are not usually present.<sup>1,16,21,22</sup> Folliculitis devalcan is another differential diagnosis, which start with erythematous alopecic patches, follicular pustules, and follicular hyperkeratotic, it is predominantly occurs in

young and middle-aged adult.<sup>23</sup>

The aim of treatment in tinea capitis is to achieve clinical and mycological cure as soon as possible, prevent the disease spread out to other children either from infected animals or other children. The best method of treating tinea capitis is through oral antifungal therapy. The first antifungal drug used widely for this purpose was griseofulvin, introduced in 1958, has exhibited an excellent safety profile, used either in adult and children. Griseofulvin is fungistatic and inhibits the synthesis of nucleic acids and interrupts cell division in metaphase, thereby preventing synthesis of fungal cell wall. It is also have anti-inflammatory effect.<sup>2,12,24</sup> It was available in tablets forms or as a suspension and it is recommended that it is taken with fatty foods because it can increase the absorption of the drugs and improves its bioavailability. It was effective in treatment of most dermatophyte in a serum concentration of <1µg/mL. After absorption from the gastrointestinal tracts, peak plasma level is seen in about four hours after oral administration of 500 mg. The major metabolite, 6-desmethylgriseofulvin, is microbiologically inactive. Griseofulvin reaches the horny layer by diffusion and sweating within four to eight hours and it is detectable and selectively concentrated in the stratum corneum of the skin, hair, and nails. There is a rapid disappearance of the drug from the stratum corneum within 48 to 72 hours after oral dose. The dose and durations for treating tinea capitis are based on clinical and mycological observation and experience, but because the drugs is rapidly cleared from the site of infection, the treatment must be continued until all the hair within affected area has been replaced by new growth.<sup>8,12,24,25</sup> The side effects of this drug usually minor and well tolerated. Central nervous system side effects include headaches, letargy, irritability, and nightmares. Gastrointestinal symptoms include nausea, vomiting, diarrhea, dryness of the mouth, and taste disturbances. Dermatological side effects include urticaria, fixed drug eruption, maculopapular, and petechial exanthema, and light sensitive eruption. Griseofulvin is contraindicated in patient with porphyria, hepatocellular failure, and hypersensitivity to the drug. Pregnant women is contraindicated to have treatment with griseofulvin because of its possibility of teratogenic and abortifacient effects of the drug. The dose recommended is 10-20 mg/kg body weight/day for 6-10 weeks.<sup>2,12,25,26</sup>

Topical treatment alone is not recommended for tinea capitis because preparations of this type do not

penetrate the hair shaft adequately. However, topical treatment can reduce the risk of transmission at the beginning of systemic treatment. Patient with more aggressive clinical variant can also receive topical treatment to reduce the risk of progression while waiting for the mycological result. Allen et al, reported that the use of shampoo containing 2% selenium sulfide or 2% ketoconazole were effective in reducing the number of viable spores in the scalp parallel with griseofulvin. Patients should be told to use the shampoo 3 times weekly and to leave it in contact with the scalp for at least 5 minutes before rinsing. It should be used until the patient is clinically and mycologically cured.<sup>3,12,14</sup>

Some individuals are not clear at follow-up. The reason for this includes lack of compliance with the long course of treatment, suboptimal absorption of the drugs, relative intensivity of the organism, and reinfection. If there is no clinical response and signs persist at the end of treatment period, then the option are to increase the dose or duration of the original drug, and change to alternative antifungal.<sup>2</sup>

The optimal management of symptom-free carriers is unclear. Person contact with affected patient has to be examined too. It needs the strategy to prevent the disease spreading around the neighborhood or school environment. Better education including the mother, children, teacher, are required to prevent the progression of the disease. Other studies by Satimia et al revealed that preventive health education program to eradicate the infection is necessary, therefore health education programs to control health problem among school students, their families, and school staff is recommended.<sup>227</sup> It is quite impractical to keep children with tinea capitis out of the school because shedding of spores can continue for months although active therapies have already given, adults and siblings in the family (asymptomatic carriers) may be continuing source of the infection and may also require active treatment to cure persistent or intransigent infections, shared facilities and objects may promote the spread of infections both within the classroom and within the home environment.<sup>8</sup> It is necessary to educate the parents and school staff to prevent the disease spread out.

Tinea capitis caused by *T. mentagrophytes* presenting an inflammatory reaction, causing a fungal infection in the hair shaft. Auxiliary examination for the diagnosis of tinea capitis can be done in various ways, the easiest one is by potassium hydroxide 20%

examination, fungal culture is then performed to determine the species causing the infection. Therapeutic use of griseofulvin is still the main choice.

#### REFERENCES

1. Schieke SM, Garg A. Superficial fungal infection. In: Goldsmith LA, Katz SI, Gilchrist BA, Paller AS, Leffel DJ, Woff K, editors. Fitzpatrick's dermatology in general medicine. 8<sup>th</sup> ed. New York: McGraw Hill; 2012. p. 2277-97.
2. Higgins EM, Fuller LC, Smith CH. Guidelines for management of tinea capitis. British J of Dermatol 2000; 143:53-8.
3. Fuller LC, Child FJ, Midgley G, Higgins EM. Diagnosis and management of scalp ringworm. British Med J 2003; 326: 539-41.
4. Hay RJ. Fungal infections. Clin in Dermatol 2006; 24:201-12.
5. Perez-Gonzalez MP, Torres-Rodriguez JM. Prevalence of tinea pedis, tinea unguium of toenails and tinea capitis in school children from Barcelona. Rev Iberoam Micol 2009; 26(4):228-32.
6. Ameen M. Epidemiology of superficial fungal infection. Clin in Dermatol 2010; 28:197-201.
7. Chan TC, Friedlander SF. New treatment for tinea capitis. Curr Opin Infect Dis 2004; 17: 97-103.
8. Elewski BE. Tinea capitis: a current perspective. J Am Acad Dermatol 2000; 42(1):1-20.
9. Isa-isa R, Arenas R, Isa M. Inflammatory tinea capitis: kerion, dermatophytic granuloma, and mycetoma. Clin in Dermatol 2010; 28:133-6.
10. Brook I. Secondary bacterial infections complicating skin lesions. J Med Microbiol 2002; 51:808-12.
11. Suyoso S. Tinea kapitis pada bayi dan anak. [cited June 29, 2014]: from URL: <http://www.rsudrsoetomo.jatimprov.go.id/index.php>
12. Rebollo N, Lopez-Barcenas AP, Arenas R. Tinea capitis. Actas Dermosifiliogr 2008; 99:91-100.
13. Tomson N, Sterling JC. Infections and infestations of the skin in children. Paediatrics and child health 2007; 17(10):400-6.
14. Branscomb R. The dermatophytoses. Lab Medicine 2006; 36(8):496-500.
15. Abdo HM, Abdel-Hamed MR, Al-Hosiny AM. KOH mount versus culture in the diagnosis of tinea capitis. The Gulf J of Dermatol and Venereol 2011; 18(1):34-9.
16. Hay RJ, Ashbee HR. Mycology. In: Burns T,

- Breathnach S, Cox N, Griffiths C, editors. Rook's Textbook of dermatology 8<sup>th</sup> ed. Oxford: Blackwell Publishing; 2010.p.1657-725.
17. Sogair SA. Fungal infection in children: tinea capitis. *Clin in Dermatol* 2000; 18:679-85.
  18. Naldi L, Rebora A. Seborrheic dermatitis. *N Engl J of Med* 2009; 360(4):387-96.
  19. Stefanaki I, Katsambas A. Therapeutic update on seborrheic dermatitis. *Skin therapy letter* 2010;15(5):1-3.
  20. Hull SPM, Wood ML, Hutchinson PE, Sladden M, Messenger AG. Guidelines for management of alopecia areata. *British J of Dermatol* 2003;149: 692-9.
  21. Campalani E, Barker JNWN. The clinical genetics of psoriasis. *Curr genomics* 2005; 6:51-60.
  22. Lowes MA, Bowcock AM, Krueger JG. Pathogenesis and therapy of psoriasis. *Nature* 2007; 445: 866-73.
  23. Saphiro J. Hair growth disorder. In: Goldsmith LA, Katz SI, Gilchrist BA, Paller AS, Leffel DJ, Woff K, editors. *Fitzpatrick's dermatology in general medicine*. 8<sup>th</sup> ed. New York: McGraw Hill; 2012.p.979-1008.
  24. Millikan LE. Current concepts in systemic and topical therapy for superficial mycoses. *Clin in Dermatol* 2010;28:212-6.
  25. Finkelstein E, Amichai B, Grunwald MH. Griseofulvin and its uses. *Int J of Antimicrob Agents* 1996; 6:1889-94.
  26. Pardasani A. Oral antifungal agents used in dermatology. *Curr Prob Dermatol* 2000; 11:270-5.
  27. Ardestani MS, Shokravi FA, Rakhshani F, Shirvani ZG. Effective health education program on reduction of tinea capitis; a quasi-experimental study on primary school-age children. *Iranian J of Clin Infect Dis* 2010; 5(4):213-7.



# Tinea Capitis Kerion Type: A Case Report

---

## ORIGINALITY REPORT

---

19%

SIMILARITY INDEX

12%

INTERNET SOURCES

11%

PUBLICATIONS

7%

STUDENT PAPERS

---

## PRIMARY SOURCES

---

1	<a href="#">docshare.tips</a> Internet Source	1%
2	<a href="#">Submitted to Chulalongkorn University</a> Student Paper	1%
3	<a href="#">Submitted to McMaster University</a> Student Paper	1%
4	<a href="#">PAUL J. HONIG. "Tinea capitis: recommendations for school attendance", The Pediatric Infectious Disease Journal, 1999</a> Publication	1%
5	<a href="#">adoc.pub</a> Internet Source	1%
6	<a href="#">www.pagepress.org</a> Internet Source	1%
7	<a href="#">Submitted to University of Pittsburgh</a> Student Paper	1%
8	<a href="#">jmscr.igmpublication.org</a> Internet Source	1%

---

[www.sid.ir](#)

9	Internet Source	1 %
10	Boni E. Elewski. "Treatment of tinea capitis: beyond griseofulvin", Journal of the American Academy of Dermatology, 1999 Publication	1 %
11	slidetodoc.com Internet Source	1 %
12	Submitted to Universiti Teknologi MARA Student Paper	1 %
13	European Handbook of Dermatological Treatments, 2015. Publication	1 %
14	repository.umsu.ac.id Internet Source	1 %
15	Andrés Tirado-Sánchez, Alexandro Bonifaz. "Tinea Capitis: Current Review of the Literature", Current Fungal Infection Reports, 2018 Publication	<1 %
16	mafiadoc.com Internet Source	<1 %
17	www.tripdatabase.com Internet Source	<1 %
18	www.bad.org.uk Internet Source	<1 %

---

19	Submitted to Adtalem Global Education Student Paper	<1 %
20	Submitted to University of Salford Student Paper	<1 %
21	<a href="http://www.scitepress.org">www.scitepress.org</a> Internet Source	<1 %
22	N/A. "Lord of the ringworms: oral antifungals the battle cry for treating paediatric tinea capitis", <i>Drugs &amp; Therapy Perspectives</i> , 08/2006 Publication	<1 %
23	Shapiro, Jerry, and Nina Otberg. "Cicatricial alopecias: Pathogenesis, classification, clinical features, diagnosis, and management", <i>Hair Loss and Restoration Second Edition</i> , 2015. Publication	<1 %
24	Submitted to Fiji National University Student Paper	<1 %
25	J del Boz. "A 30-year survey of paediatric tinea capitis in southern Spain : A 30-year survey of paediatric tinea capitis in southern Spain", <i>Journal of the European Academy of Dermatology and Venereology</i> , 02/2011 Publication	<1 %
26	Jenny Hällgren. "Increasing tinea capitis prevalence in Stockholm reflects	<1 %

---

27

[healthjade.net](http://healthjade.net)

Internet Source

<1 %

28

[www.ncbi.nlm.nih.gov](http://www.ncbi.nlm.nih.gov)

Internet Source

<1 %

29

Subash Reddy D, Prasad J V D S, Narasimha Prasad K, Yashwanth T.

"CLINICOMYCOLOGICAL STUDY OF TINEA CAPITIS", Journal of Evolution of Medical and Dental Sciences, 2016

Publication

<1 %

30

[www.medcraveonline.com](http://www.medcraveonline.com)

Internet Source

<1 %

31

Matthias M??hrenschlager. "Pediatric Tinea Capitis", American Journal of Clinical Dermatology, 2005

Publication

<1 %

32

Rasha H. Bassyouni, Naglaa A. El-Sherbiny, Talal A. Abd El Raheem, Basma H. Mohammed. "Changing in the Epidemiology of Tinea Capitis among School Children in Egypt", Annals of Dermatology, 2017

Publication

<1 %

33

[academic.oup.com](http://academic.oup.com)

Internet Source

<1 %

34 docobook.com <1 %  
Internet Source

---

35 forgottenbooks.com <1 %  
Internet Source

---

36 journalrepository.org <1 %  
Internet Source

---

37 Ali Mikaeili, Hossein Kavoussi, Amir Hosein Hashemian, Mahdokht Shabandoost Gheshtemi, Reza Kavoussi. "Clinico-mycological profile of tinea capitis and its comparative response to griseofulvin versus terbinafine", Current Medical Mycology, 2019  
Publication

---

38 "Dermatophytes and Dermatophytoses", Springer Science and Business Media LLC, 2021  
Publication

---

Exclude quotes Off

Exclude matches Off

Exclude bibliography On

# Tinea Capitis Kerion Type: A Case Report

GRADEMARK REPORT

FINAL GRADE

**/100**

GENERAL COMMENTS

**Instructor**

PAGE 1

PAGE 2

PAGE 3

PAGE 4

PAGE 5

PAGE 6

PAGE 7