

Adverse Cardiac Events Following mRNA COVID-19 Vaccination

by Gadis Meinar Sari


Submission date: 15-Apr-2023 08:24AM (UTC+0800)

Submission ID: 2064881180

File name: Adverse_Cardiac_Events_Following_mRNA_COVID-19_Vaccination.pdf (988.71K)

Word count: 15182

Character count: 83035



Adverse cardiac events following mRNA COVID-19 vaccination: A systematic review and meta-analysis

[Eventos cardíacos adversos tras la vacunación con COVID-19 ARNm: Una revisión sistemática y metaanálisis]

Eka Arum Cahyaning Putri¹, Misbakhul Munir¹, Hayuris Kinandita Setiawan¹, Lilik Herawati¹, Gadis Meinar Sari¹, Citrawati Dyah Kencono Wungu¹, Hendri Susilo^{2,3}, Henry Sutanto⁴

¹Department of Medical Physiology and Biochemistry, Faculty of Medicine, Universitas Airlangga, Surabaya, Indonesia.

²Department of Cardiology and Vascular Medicine, Faculty of Medicine, Universitas Airlangga, Surabaya, Indonesia.

³Department of Cardiology and Vascular Medicine, Universitas Airlangga Hospital, Surabaya, Indonesia.

⁴Department of Cardiology, CARIM School for Cardiovascular Diseases, Maastricht University, 6211 Maastricht, The Netherlands.

*E-mail: eka-arum-cp@fk.unair.ac.id

Abstract

Context: Although have been proven able to control the prevalence of coronavirus disease-19 (COVID-19), Pfizer-BioNTech and Moderna COVID-19 vaccines are reported to have possible side effects on the heart.

Aims: To know the magnitude of adverse events in the cardiac after messenger ribonucleic acid (mRNA)-based vaccination.

Methods: An electronic search in PubMed, Web of Science, Scopus, and Ebsco/Cinahl was performed. The keywords were: "COVID-19 vaccine", "SARS-CoV-2 vaccine", "myocarditis", "myopericarditis", "pericarditis", "myocardial infarction", and "myocardial injury". The electronic search was updated until March 2022. STATA/MP Statistical Software: Release 14 (StataCorp LLC, College Station, Texas) was used in this study to perform a meta-analysis of a random-effect for myocarditis, pericarditis, myocarditis, myocardial infarction, and myocardial injury.

Results: Twenty-one case reports/case series studies with a total of 62 individuals who had been vaccinated against COVID-19 mRNA (Pfizer-BioNTech and Moderna) were included in the systematic review. Whereas seven observational cohort studies had 170,053,333 people who had been vaccinated, 245 of whom had myocarditis. In addition, two observational cohort studies with 13,948,595 vaccinated individuals, 16 of whom developed pericarditis. There was only one observational cohort study that had a total of 7,183,889 people who had been vaccinated and 11 had myopericarditis. Based on the pooled incidence, the result is <0.002%.

Conclusions: The Pfizer-BioNTech and Moderna vaccines have a low incidence of myocarditis. Men are more likely to develop post-COVID-19 myocarditis with an average age of 22 years and in the age range of 21-40 years. The type of mRNA COVID-19 vaccine that causes myocarditis the most is Pfizer. The diagnosis of myocarditis is mostly made by troponin examination. COVID-19 mRNA vaccination has a low incidence of myocarditis.

Keywords: cardiac disease; cardiac events; COVID-19; mRNA vaccines; SARS-CoV-2.

Resumen

Contexto: Aunque se ha demostrado que pueden controlar la prevalencia de la enfermedad por coronavirus-19 (COVID-19), se ha informado que las vacunas contra COVID-19 de Pfizer-BioNTech y Moderna tienen posibles efectos secundarios sobre el corazón.

Objetivos: Conocer la magnitud de los efectos adversos en el corazón tras la vacunación basada en ácido ribonucleico mensajero (ARNm).

Métodos: Se realizó una búsqueda electrónica en PubMed, Web of Science, Scopus y Ebsco/Cinahl. Las palabras clave fueron: "vacuna COVID-19", "vacuna SARS-CoV-2", "miocarditis", "miopericarditis", "pericarditis", "infarto de miocardio" y "lesión miocárdica". La búsqueda electrónica se actualizó hasta marzo de 2022. Software estadístico STATA/MP: Versión 14 (StataCorp LLC, College Station, Texas) se utilizó en este estudio para realizar un metanálisis de efecto aleatorio para miocarditis, pericarditis, miocarditis, infarto de miocardio y lesión miocárdica.

Resultados: Se incluyeron en la revisión sistemática 21 estudios de informes de casos/series de casos con un total de 62 individuos que habían sido vacunados contra COVID-19 ARNm (Pfizer-BioNTech y Moderna). Mientras que siete estudios observacionales de cohortes contaban con 170.053.333 personas que habían sido vacunadas, 245 de las cuales presentaron miocarditis. Además, dos estudios observacionales de cohortes con 13.948.595 personas vacunadas, 16 de las cuales desarrollaron pericarditis. Sólo hubo un estudio observacional de cohortes con un total de 7.183.889 personas vacunadas y 11 tuvieron miopericarditis. Basándose en la incidencia agrupada, el resultado es <0,002%.

Conclusiones: Las vacunas Pfizer-BioNTech y Moderna tienen una baja incidencia de miocarditis. Los hombres son más propensos a desarrollar miocarditis post-COVID-19 con una edad media de 22 años y en el rango de edad de 21-40 años. El tipo de vacuna COVID-19 de ARNm que causa más miocarditis es Pfizer. El diagnóstico de la miocarditis se realiza principalmente mediante el examen de troponina. La vacunación con ARNm COVID-19 tiene una baja incidencia de miocarditis.

Palabras Clave: enfermedad cardíaca; eventos cardíacos; COVID-19; vacunas de ARNm; SARS-CoV-2.

ARTICLE INFO

Received: October 19, 2022.

Accepted: December 20, 2022.

Available Online: December 29, 2022.

AUTHOR INFO

ORCID:

[0000-0003-4136-9720](https://orcid.org/0000-0003-4136-9720) (EACP)

[0000-0001-9187-0447](https://orcid.org/0000-0001-9187-0447) (MM)

[0000-0002-3997-3825](https://orcid.org/0000-0002-3997-3825) (HKS)

[0000-0002-8014-6952](https://orcid.org/0000-0002-8014-6952) (LH)

[0000-0002-9178-8926](https://orcid.org/0000-0002-9178-8926) (GMS)

[0000-0001-5180-957X](https://orcid.org/0000-0001-5180-957X) (CDKW)

[0000-0002-5603-9487](https://orcid.org/0000-0002-5603-9487) (HSus)

[0000-0002-5730-2013](https://orcid.org/0000-0002-5730-2013) (HSut)

INTRODUCTION

The 2019 coronavirus (COVID-19) pandemic revealed by the World Health Organization (WHO) requires a long-term solution to overcome (Cai et al., 2021; WHO, 2020a). Globally, as of October 2022, 621,797,133 confirmed cases of COVID-19, including 6,545,561 deaths, were reported to WHO. As of October 2022, the total number of vaccine doses administered per 100 population was 164 (WHO, 2020b). Safe vaccines are expected to have broad clinical and socio-economic benefits (Rowland and Johnson, 2020). There is growing evidence that a COVID-19 vaccine can reduce the severity of symptoms and prevent transmission. However, vaccines must still meet the minimum requirements to prevent infection and disease (Dye and Mills, 2021). Among all approaches, messenger RNA (mRNA-based vaccines have emerged as a rapid and versatile platform for responding quickly to this challenge (Zhang et al., 2020a). Evaluations of approved COVID-19 mRNA vaccines (PfizerBioNTech and Moderna) have consistently shown high vaccine efficacy in diverse populations (Tenforde et al., 2021; Thompson et al., 2021). Monitoring the safety after COVID-19 vaccination can help the policy-maker decide whether or not booster vaccines are probably indicated (Feng et al., 2018; Ferdinands et al., 2021).

In the first US multisite vaccine efficacy study with a negative healthcare professionals test design, a single-dose of PfizerBioNTech or Moderna COVID-19 vaccine was 82% effective against symptomatic COVID-19, and it was increased by 94% in double-dose (Pilishvili et al., 2021). The most frequent adverse drug reactions after COVID-19 vaccination are pain, fatigue, and headache (Cai et al., 2021). In Germany, 88.1% of healthcare workers reported at least one side effect after COVID-19 vaccination. The mRNA-based vaccines have been associated with a high prevalence of local side effects (such as pain at the injection site). The most common systemic side effects of mRNA-based vaccine recipients were headaches, myalgia, malaise, arthralgia, chills, and fever (Klugar et al., 2021). Headache is the most common systemic side effect reported by phase III volunteers in the Moderna (BNT162b2) vaccine Centers for Disease Control and Prevention (CDC) safety report, while the rest adverse events reported were myalgia, chills, arthralgia, and fever (CDC, 2021a). Of the Pfizer vaccine (mRNA1273), headache is the most common systemic side effect, followed by myalgia, arthralgia, chills, and fever, according to the CDC report (CDC, 2021b). Most of these reactions are well tolerated but there have also been reports of severe reactions such as thromboembolism, myocarditis, and

pericarditis (Cai et al., 2021). In a national mass vaccination setting, the BNT162b2 vaccine was not associated with an increased risk of most adverse events studied. Vaccines have been associated with an increased risk of myocarditis (1-5 events per 100,000 vaccinated people) (Barda et al., 2021; Oster et al., 2022; Patone et al., 2022; Witberg et al., 2021). The risk of this potentially serious adverse event and many other serious adverse events was significantly increased after SARS-CoV-2 infection (Barda et al., 2021; Boehmer et al., 2021; Patone et al., 2022). Multi-system inflammatory syndrome (MIS) is a rare but serious complication of SARS-CoV-2 infection and frequently involves the heart (CDC, 2021c). However, most of the published clinical information on myocarditis after the COVID-19 mRNA vaccine is in the form of case reports and case series as published before by Nassar et al. (2021). Several cohort studies are still being searched, so a meta-analysis can be carried out in this study. This study focuses on discussing the effects of cardiac events after the administration of the COVID-19 mRNA vaccines: Pfizer and Moderna, while the effects of cardiac events after the administration of other types of COVID-19 vaccines have been done before by Salah and Mehta (2021).

Given the high reaction to vaccination, especially in the heart, so this study took the object of people who had received the COVID-19 vaccination to be analyzed for adverse cardiac events after the COVID-19 vaccination. A systematic review and meta-analysis were also conducted to analyze myocarditis, pericarditis, myopericarditis, myocardial infarction, and myocardial injury after COVID-19 mRNA vaccination.

MATERIAL AND METHODS

This systematic review and meta-analysis article followed the guidelines for Preferred Reporting Items for Systematic Reviews and Meta-Analysis (PRISMA) (Moher et al., 2015), and was registered in the International Prospective Register of Systematic Review (PROSPERO) (Rombey et al., 2020) (CRD42021279756).

Search strategy

An electronic search in PubMed, Web of Science, Scopus, and Ebsco/Cinahl was performed. The keywords were: "COVID-19 vaccine", "SARS-CoV-2 vaccine", "myocarditis", "myopericarditis", "pericarditis", "myocardial infarction", and "myocardial injury". The electronic search was updated until March 2022 (Supplementary Table 1). Inclusion criteria were: (1) studies involving clinical outcome of myocarditis,

myopericarditis, pericarditis, myocardial infarction, and myocardial injury in the COVID-19 mRNA vaccinated people; (2) data about those clinical outcomes in prevalence; (3) English language; (4) observational cohort studies, case reports/series; and (5) human subjects. The exclusion criteria were: (1) review articles, systematic review, and meta-analysis; (2) duplicated studies; (3) patients with acute coronary syndrome, acute cardiac failure, uncontrolled arrhythmia, and hypertensive grade III (ESC 2018) at the time of vaccination; (4) non-English articles; and (5) insufficient data. The quality of the studies was assessed using the Joanna Briggs Institute (JBI) for assessing case reports, case series clinical and cohort studies (Zachary et al., 2019) (Supplementary Table 2-4).

Data extraction

The literature was screened and reviewed by two independent reviewers (EACP and M.M.). Any discrepancies, including the lack of concordance in the study selection evaluation, were resolved by discussion with other investigators (H.K. and L.H.) until reaching a consensus. The screening was done by assessing the relevance of the title and abstract of the studies. Any duplication of the studies was removed using Mendeley Reference Manager. From the reference literature, the following data were taken: the type of study design, study locations (state and/or country), the prevalence of myocarditis, myopericarditis, pericarditis, myocardial infarction, and myocardial injury after the COVID-19 mRNA vaccinated, number of COVID-19 mRNAs vaccinated people, age of patients, gender or patients, history of prior COVID-19 infection, history of prior cardiovascular disease, symptoms of adverse cardiac events, adverse cardiac events and its examination, the onset of the adverse cardiac events, and follow-up period. The risk of bias was going to be assessed using the Cochrane Risk of Bias (RoB) 2 Tool (Higgins et al., 2011) and Joanna Briggs Institute (JBI) (Aromataris and Munn, 2020) for RCTs and observational studies, respectively. However, in the final stage of the study selection, no suitable RCT was found; therefore, Cochrane RoB2 was not used.

Data analysis

¹⁹ The relevant studies were retrieved the PubMed, Web of Science, Scopus, and Ebsco/Cinahl databases for reports of myocarditis, pericarditis, myopericarditis, and perimyocarditis following Pfizer and Moderna vaccinations accepted by all people in the world from September 1, 2021, to March 31, 2022. All identified reports are reviewed for signs and symptoms that meet the case definitions previously used for surveillance of myocarditis, pericarditis, myopericarditis,

myocardial infarction, and myocardial injury after Pfizer and Moderna vaccines both after dose 1 and after dose 2; this study also included for review reports where there is a diagnosis by a doctor, regardless of if the reported case meets the published case definition. Case reports that meet the definition of myocarditis or pericarditis, myopericarditis, and myocardial injury diagnosed by a doctor, grouped by: age group and the known association between the COVID-19 mRNA vaccine administered and cardiac side effects. For each age group, analyzed cases based on the occurrence of adverse cardiac events from each primer study: 0-20 years; 21-40 years; 41-60 years; and 61-80 years old, gender, and timing of vaccination for the onset of symptoms. STATA/MP Statistical Software: Release 14 (StataCorp LLC, College Station, Texas) was used to perform a random-effect meta-analysis for myocarditis, pericarditis, myopericarditis, myocardial infarction, and myocardial injury.

71

RESULTS

Study selection

A total of 293 studies were identified in the literature search from database searching: PubMed, Web of Science, Scopus, and Ebsco/Cinahl as described in the PRISMA flow chart (Fig. 1). Ninety-nine duplicates were removed, and 149 studies were excluded because it is not relevant to the purpose of this study. Forty-five studies were thoroughly reviewed for feasibility. After a thorough review, 17 studies were excluded; thus, 28 studies were included in the review. Of them, seven studies were observational cohort studies, and 21 were case series/case reports. Furthermore, seven observational cohort studies were included in the meta-analysis.

Quality assessment

The quality assessment and risk of bias of observational cohort studies and case series/case reports using the JBI critical appraisal checklist was summarized in Supplementary Tables 2 and 3. Of the 28 existing studies, no conflicts of interest and study sponsors could influence the author's interpretation of the results, as shown in Supplementary Table 5.

Demographic characteristics

A total of 62 people from 21 case series/case reports who received mRNA COVID-19 vaccines were included in this systematic review. There were two types of mRNA vaccine studied in this study: Pfizer (79.03%) and Moderna (20.97%). The people's age ranged from 14 to 70 years. All of them reported having received an mRNA vaccine, either Pfizer-

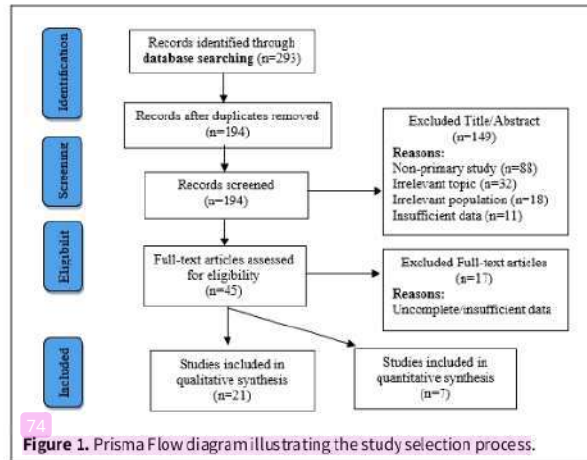


Table 1. Incidence myocarditis, pericarditis, and myopericarditis of included studies.

| Study | Year | Age (years old) | Myocarditis | Total mRNA vaccine population | Pericarditis | Total mRNA vaccine population | Myopericarditis | Total mRNA vaccine population |
|--------------------------|------|-----------------|-------------|-------------------------------|--------------|-------------------------------|-----------------|-------------------------------|
| (Shiyovich et al., 2021) | 2021 | >17 | 54 | 2,566,825 | NA | NA | NA | NA |
| (Mevorach et al., 2021) | 2021 | >15 | 117 | 149,786,065 | NA | NA | NA | NA |
| (Simone et al., 2021) | 2021 | >17 | 15 | 2,392,924 | NA | NA | NA | NA |
| (Knowlton et al., 2021) | 2021 | >17 | 21 | 914,611 | NA | NA | NA | NA |
| (di Dedda et al., 2022) | 2022 | >11 | 16 | 6,764,706 | 7 | 6,764,706 | NA | NA |
| (Yap et al., 2022) | 2022 | 12-55 | 14 | 7,183,889 | 9 | 7,183,889 | 11 | 7,183,889 |
| (June Choe et al., 2022) | 2022 | 16-18 | 8 | 444,313 | NA | NA | NA | NA |

BioNTech or Moderna. In this study, research subjects were divided into several age classifications: 0-20 years (44%); 21-40 years (46.77%); 41-60 years (4.84%); and 61-80 years old (4.84%). Most of the research subjects were in the age range of 21-40 years with the median being 22 years old. The gender of most research subjects was male (90.32%) and female (9.68%). Among these studies, 25.81% were conducted in the United States of America (USA), 3.23% in Israel, and the rest at 1.61% each in Italy, Germany, and Korea.

Of 170,053,333 people from seven observational cohort studies, 245 met the published case definition for myocarditis. As for cases of myopericarditis, 13,948,595 vaccinated people from 2 observational cohort studies, 16 met the published case definition for myopericarditis. While for cases of pericarditis,

7,183,889 vaccinated people from one observational cohort study, had 11 cases of pericarditis. Most reports describe people 11-65 years old (Table 1).

Previous history of exposure to COVID-19 and cardiac problems

Based on previous exposure to COVID-19, 56.45% of the subjects were not exposed to COVID-19 beforehand, 6.45% had been previously exposed to COVID-19, and 37.10% were unclear. While cardiac problems experienced by research subjects were also investigated in this study, the results were that 75.81% of subjects had no history of previous disorders, 9.68% of subjects had a history of previous disorders, and 14.52% was unclear. Of the several subjects who had a previous cardiac history, some had a history of hyper-

tension (50%), hyperlipidemia or hypercholesterolemia (66.67%), coronary artery disorders with or without bypass grafting surgery (50%), congestive heart failure (CHF) with preserved ejection fraction (16.67%), and significant mitral valve prolapse with resting tachycardia (16.67%) (Supplementary Table 4).

Symptoms of adverse cardiac events

Symptoms experienced by the subjects after vaccination were consecutively starting from the highest prevalence: chest pain (96.77%); fever (35.48%); dyspnea (27.42%); myalgia (17.74%); malaise (12.90%); headaches (11.29%); nausea (8.33%); chills (8.33%); vomiting (3.23%); cough (3.23%); and the remaining 1.61% each (rhinorrhea, diarrhea, orthopnea, syncope, diaphoresis, and palpitations) (Supplementary Table 6).

Adverse cardiac events and their examination

Adverse cardiac events after COVID-19 mRNA vaccination found in this study according to their prevalence, the most were myocarditis (62.90%), myopericarditis (30.65%), acute myocardial infarction (3.23%), and the least were pericarditis and acute myocardial injury respectively each has a prevalence of 1.61% (Fig. 2). In this study, further investigations were carried out to diagnose adverse cardiac events, consisting of 6 different combinations of examinations, including cardiac magnetic resonance (CMR) imaging (25.81%), troponin examination (33.87%), electrocardiogram (30.65%), echocardiogram (25.81%), chest radiography (9.68%) and computed tomography (CT) angiography (20.97%). The CMR imaging and echocardiogram mostly showed elevation of the left ventricular ejection fraction. Elevated troponin was the most frequent marker. Electrocardiogram mostly showed ST elevation, PR elevation, and PR depression. Chest radiography was mostly normal. Computed tomography angiography mostly showed normal results (Supplementary Table 7).

The onset of the adverse cardiac events

The adverse cardiac events mostly occurred after the second dose (83.87%), and few occurred after the first dose (16.13%). Of the subjects who experienced symptoms after the 1st dose of vaccination, 70% experienced symptoms on days 0-7 days, 20% experienced symptoms on days 8-14 days, and 10% experienced symptoms more than 14 days after the first dose of vaccination. Of the subjects who experienced symptoms after the second dose of vaccination, 98.08% experienced symptoms on days 0-7 after the second dose of vaccination, the remaining 1.92% experienced symptoms on days 8-14, and none developed symptoms after more than 14 days (0.00%). All subjects reported the incidence of adverse cardiac events on the 3rd day (median value) after the COVID-19 mRNA vaccination (Supplementary Table 6).

Prognosis

Of the 62 research subjects, 100% were hospitalized for 2-7 days. The median length of hospital stay was 4 days. Prognosis in the subject showed 46.77% of the subjects were discharged with normal conditions, 1.61% died, and 51.61% were unclear (Supplementary Table 7).

Pooled incidence

The results of the pooled incidence of myocarditis after administration of the mRNA COVID-19 vaccine were <0.002% with $I^2 = 93.98\%$ and all studies $ES = 0.00$. This is a rare occurrence, but it still needs to be watched out for and further investigated (Fig. 3). The pooled incidence of pericarditis and mRNA vaccines cannot be continued because there are only two articles. The pooled incidence of myopericarditis and mRNA vaccines cannot be continued because there is only one article (Table 1).

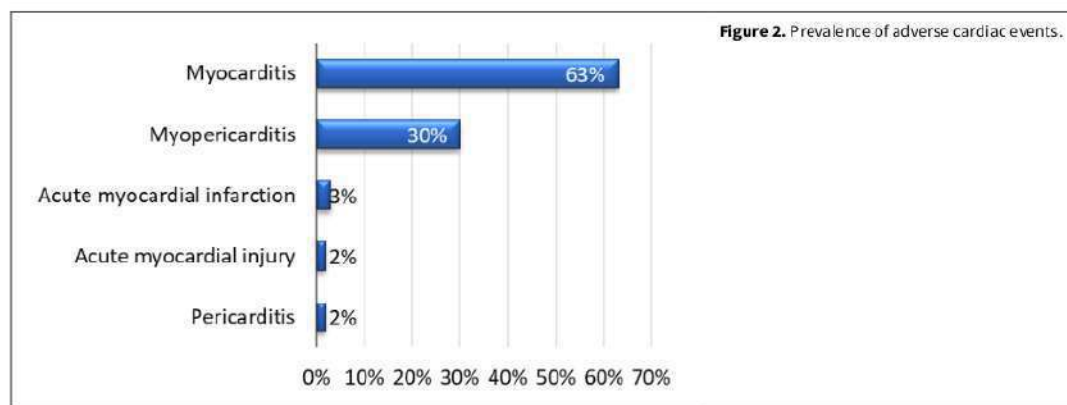


Figure 2. Prevalence of adverse cardiac events.

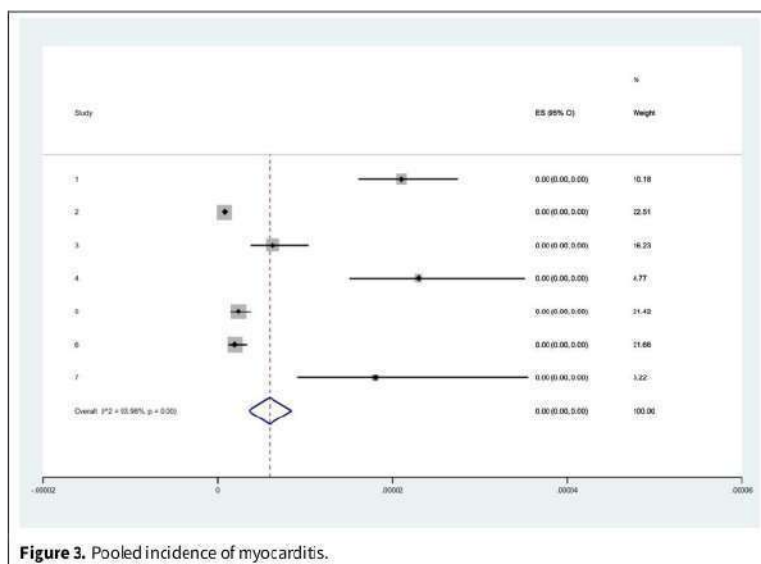


Figure 3. Pooled incidence of myocarditis.

DISCUSSION

Main finding

This review showed that the highest prevalence of adverse cardiac events following the administration of COVID-19 vaccination mRNA was the inflammatory process, either in the myocardium, pericardium, or both. In the results of this study, the highest incidence was myocarditis, followed by myopericarditis and pericarditis. Related to other disorders of the myocardium that can occur after the COVID-19 mRNA vaccination, namely acute myocardial infarction and acute myocardial injury, although the prevalence is very small. Based on the pooled incidence, the results are <0.002% in the publications involved in this study. The mRNA vaccines are based on the principle that mRNA is an intermediate messenger substance that is introduced into host cells and then translated into antigens by various routes. RNA molecules have been treated and studied for over 20 years, from the use of in vitro transcribed (IVT) mRNA, small interfering RNA (siRNA), RNA aptamer, riboswitch, and antisense RNA to recently developed mRNA vaccines (Sahin et al., 2014; Wittrop and Lieberman, 2015).

The first advantage of mRNA vaccines is the simplicity and speed of their manufacture. The central principle of an mRNA vaccine is to deliver a transcript that encodes a target antigen or immunogen. RNA synthesis can be performed on the same platform as soon as the immunogen coding sequence becomes available. The process can be easily scalable and cell-free, minimizing changes in the platform

<https://jppres.com>

during mRNA formulation and production (Jackson et al., 2020).

Second, mRNA vaccines express target proteins (antigens) rapidly after transfection by translation from mRNA. Because antigens are translated in the cytoplasm rather than in the nucleus, mRNA vaccines could be much biologically safer than DNA-based vaccines and more difficult to integrate mRNA into the genome than DNA-based vaccines. In addition, mRNA is a safer vector than DNA because it has a short sequence to be translated, is a transient molecule, and does not interact with the host genome. Third, while protein-based vaccines are often made from bacteria, mRNA vaccines are translated by the host's translational mechanism, producing antigens that mimic the protein structures expressed from the viral genome, including post-translational modifications (Park et al., 2021).

The innate immune system has evolved to protect against viral genomes and replication intermediates through a powerful Pathogen-Associated Molecular Pattern (PAMP). PAMP recognizes dsRNA via Pattern Recognition Receptors (PRRs) for most cell types and then activates the expression of inflammatory cytokines and type I Interferon (IFN) (Jensen and Thomsen, 2012). Unlike other antigenic properties of pathogens such as flagellin, mRNA is common to both the host and the pathogen, so a cellular mechanism is needed to distinguish between non-self and self-mRNA. Exogenously introduced mRNA is immunostimulatory in nature (Pardi et al., 2018). Therefore, the principle that distinguishes non-self mRNA

from the body's own mRNA is based on structural distinction, intracellular localization, and mRNA availability. For example, dsRNA, 3' triphosphate RNA, partially degraded or damaged RNA, and edit levels A through I represent the structural features of non-self mRNA, and these functions are innate immunity via PRR (Bartok and Hartmann, 2020).

There were concerns about their Antibody-Dependent Enhancement (ADE), regardless of the type of vaccine platform. Vaccination often causes the production of ineffective neutralizing antibodies in the host, which induces a detrimental immunological cascade to promote viral entry and pathological symptoms by producing excess cytokines and complement (Arvin et al., 2020). Due to the incompatibility of human Immunoglobulin-G (IgG) with its animal counterparts, it is difficult to predict vaccine ADE based on antibody-dependent in vitro effects or pre-clinical animal studies (Crowley and Ackerman, 2019; Dekkers et al., 2017). In addition, partially degraded mRNA can be transcribed into cleaved and conformationally altered proteins, which can lead to ADE without binding to the natural immunogen. It induces the production of neutralizing antibodies. Therefore, ADE needs to be identified and overcome.

Acute myocarditis is defined as a recent myocardial inflammation based on clinical features or histopathological criteria. It can be caused by an infection, drug toxicity, or excessive immune activation (Trachtenberg and Hare, 2017). Acute myocarditis is the second one maximum not unusual place inflammatory coronary heart ailment after pericarditis, with a predicted annual prevalence of twenty-two instances according to 100,000 subjects (Ammirati et al., 2020). Several causes may be due to direct infection, immune response, or a combination of direct or indirect effects. (Montgomery et al., 2021). Live viral infections are essential for inducing myocardial damage unless it is mechanically proven that viral lysates or recombinant proteins can cause cardiac dysfunction similar to viral infections. Antiviral immune responses (T cells and antibodies) can eliminate the virus, but the repair process is not completely restored, especially due to the limited ability of adult cardiomyocytes to regenerate (Lasrado and Reddy, 2020). Based on the immune response mechanism, the functional and structural changes in the coronary (micro) vasculature that occur in infectious myocarditis and the effects of these changes on their etiology. Thus, these changes in the coronary (micro) vasculature may partially explain the wide variety of clinical manifestations in patients with infectious myocarditis (Woudstra et al., 2018).

Autoinflammatory myocarditis has been reported as a suspected rare side effect of vaccine-related adju-

vants (Cheng et al., 2016). However, BNT162b2 is a novel mRNA vaccine and does not contain an adjuvant. Therefore, other components of BNT162b2 may be associated with this side effect. According to the FDA (Vaccines and Related Biological Products Advisory Committee Meeting, 2020), in addition to nucleoside-modified mRNA, the vaccine contains lipids: ((4 hydroxybutyl) azanediyl) bis (hexane 6, 1 day) bis (2 hexyldecanoate), 2 [(polyethylene glycol) 2000] N, N-ditetradecylacetamide, 1,2-distearoyl-sn-glycero-3-phosphocholine and cholesterol, potassium chloride, potassium phosphate monobasic, sodium chloride, sodium phosphate dibasic dihydrate, and sucrose.

Myocarditis has a slightly higher prevalence in men than in women. Recent studies and myocarditis enrollment have reported a female-to-male ratio of 1: 1.5 to 1: 1.7 (Caforio et al., 2007). Higher antibody levels in adult females (including more functional antibodies) compared to adult males (Potluri et al., 2019). When females have a strong immune response, these subjects are more susceptible to autoimmune disease and have more side effects to the vaccine (Fischinger et al., 2019). Some of these differences may be due to hormonal differences such as estrogen and testosterone levels (Ruggieri et al., 2016). Testosterone has been reported to reduce the response to vaccination (Trigunaite, 2015). Gender differences in the prevalence of myocarditis were observed, especially in young and middle-aged patients. Sex hormones can determine the risk of myocarditis (Thevathasan et al., 2021). Elevated testosterone contributes to acute myocarditis by increasing viral binding to myocytes (Lyden et al., 1987), inhibiting the anti-inflammatory cell population (Frisancho-Kiss et al., 2009), and up-regulating the fibrous remodeling genes of the heart (Fairweather et al., 2013). On the other hand, estrogens may play a role in preventing myocarditis by stimulating inhibitory T-regulatory cells and inhibiting pro-inflammatory T cells (Fairweather et al., 2013; Frisancho-Kiss et al., 2009).

Clinical manifestations generally range from asymptomatic increases in cardiac enzymes to sudden death from heart failure (Gürdoğan and Yalta, 2020). Therefore, symptoms generally show a heterogeneous clinical spectrum, such as dyspnea (usually with a decrease in left ventricular ejection fraction (LVEF)), palpitation, nausea, malaise, weight loss, and chest pain (Guo et al., 2020). This is in line with this study that the dominant symptoms that appeared in subjects with suspected acute myocarditis after the COVID-19 mRNA vaccination were chest pain, dyspnea, and malaise. Given the high incidence of myocarditis after the second dose, the condition may be hypersensitivity myocarditis (Montgomery et al.,

2021), and the first dose of the vaccine may be a sensitive dose.

Cardiac magnetic resonance (CMR) is an established diagnostic imaging method for the non-invasive diagnosis of acute myocarditis and provides evidence of myocardial hyperemia, edema, and fibrosis (Biesbroek et al., 2015; Valbuena-Lopez et al., 2016). In this situation, late myocardial gadolinium enhancement (LGE) can affect prognosis (Ammirati et al., 2018; Anzini et al., 2013; Imazio et al., 2013; 2014). Recently published data indicate that septal LGE independent of basal LVEF may be associated with poor prognosis (Aquaro et al., 2017). In this study, CMR imaging of acute myocarditis showed normal with an ejection fraction above 55% different from previous studies which chronic myocarditis (Zhang et al., 2020b). Septal Late Gadolinium Enhancement is not uncommon in patients with acute myocarditis and reduced LVEF undergoing CMR studies, but it does not appear to have an independent prognostic value compared to reduced LVEF. Most patients have an infarct-like appearance with intact LVEF and a good prognosis without the need for sudden cardiac death, heart failure, and cardiac transplantation or implanted cardiac defibrillator transplantation. Poor prognosis is limited to patients with reduced LVEF at onset (Imazio et al., 2018). As a non-invasive method, cardiac MRI plays a central role in early detection and continuous monitoring of myocarditis. Central myocardial edema and late gadolinium angiography, which are inconsistent with the anatomy of the coronary arteries, are of particular concern on T1-/T2-emphasized MRI of patients with ICI-related myocarditis (Zhang et al., 2020b) but the patient's cardiac MRI in the analysis was obtained in an acute situation, long-term follow-up is required to understand the extent and prognosis of permanent myocardial scarring (Matta et al., 2021).

Other tests, such as elevated troponin— which presenting symptom was the acute onset of severe chest pain, and myocardial injury— abnormal electrocardiogram, normal CT angiography, normal Chest radiography, and normal echocardiogram were also shown in this study. It is well known that healthy people have low levels of cTnI and cTnT. Dramatic changes in cTn occur only after damage to cardiomyocytes. Given that cTnT and cTnI are primarily bound to the troponin complex of cardiomyocytes (Bleier et al., 1998), the detection of high cTn plasma levels indicates severe destruction of the myocardial structure. A definite pathophysiological process is not well characterized, but rather from overt necrosis with cell death and myofilament destruction, it is less serious in the integrity and permeability of the sarcolemma, perhaps one. It shows the spectrum of changes lead-

ing up to transient changes. This means that regardless of the causative factor, heart damage inevitably leads to elevated cTn plasma levels, and the magnitude of the increase reflects the severity of the damage (Bass et al., 2010).

The most common ECG abnormalities in myocarditis are sinus tachycardia associated with nonspecific ST/T wave changes. The presence of decreased PR segment in both precordial and limb leads, decreased PR segment in ST-segment elevated lead, increased PR segment in aVR electrode, or ST elevation with a pattern of pericarditis is generally more than myocardial infarction. In patients with acute myocarditis, the following characteristics are associated with poor prognosis: abnormal Q-waves, wide QRS complex, QRS/T angles greater than 100°, prolonged QT interval, advanced atrioventricular block, and malignant. Ventricular tachyarrhythmia. In contrast, ST elevation with a typical early repolarization pattern is associated with a better prognosis (Buttà et al., 2020; Deb et al., 2021; Gargano et al., 2021; King et al., 2021). This is in line with our finding that the electrocardiogram mostly showed ST elevation, PR elevation, and PR depression.

Supportive care is central to treatment, targeting cardiac medications and interventions as needed. Current guidelines from the American Heart Association recommend limiting exercise until the heart recovers. However, many patients take non-steroidal anti-inflammatory drugs to improve their symptoms. Follow-up is underway to identify and understand the long-term outcomes of myocarditis that occur after COVID-19 mRNA vaccination (Maron et al., 2015).

Limitation

At last, there are several limitations of this systematic review/meta-analysis. First, our study did not perform the pooled incidence of pericarditis and myocarditis because of the insufficiency of available data. Second, the age limit of the population was different, so subgroup analysis based on age range did not be performed. Third, the unavailability of RCT also limits the interpretability of our findings. In the future, RCTs would be needed to support/confirm our findings. Additionally, further analysis is needed to know the underlying pathophysiology was that still not fully understood.

CONCLUSION

Subjects who experienced the most adverse cardiac events were males with a median age of 22 and 21-40 years. Of all the subjects, it was also found that the most adverse cardiac events were myocarditis, had

never been infected with COVID-19 before, with most types of COVID-19 mRNA vaccine given was Pfizer. The diagnosis of adverse cardiac events is mostly established by examination of troponin, which shows an increase without a history of previous cardiac disease. Based on the pooled incidence and the inclusion criteria taken into account in the present study, the results are $<0.002\%$. So, mRNA COVID-19 vaccination has a low incidence of myocarditis.

CONFLICT OF INTEREST

The authors declare no conflicts of interest.

ACKNOWLEDGMENTS

The authors wish to acknowledge Universitas Airlangga for providing funds for this research number: 1341/UN3.1.1/PT/2022.

REFERENCES

- Ammirati E, Cipriani M, Moro C, Raineri C, Pini D, Sormani P, Mantovani R, Varrenti M, Pedrotti P, Conca C, Mafriaci A, Grosu A, Briguglia D, Guglielmetto S, Perego GB, Colombo S, Caico SI, Giannattasio C, Maestroni A, Carubelli V, Metra M, Lombardi C, Campodonico J, Agostoni P, Peretto G, Scelsi L, Turco A, Di Tano G, Campana C, Belloni A, Morandi F, Mortara A, Cirò A, Senni M, Gavazzi A, Frigerio M, Oliva F, Camici PG; Registro Lombardo delle Miocarditi (2018) Clinical presentation and outcome in a contemporary cohort of patients with acute myocarditis: Multicenter Lombardy Registry. *Circulation* 138(11): 1088–1099. <https://doi.org/10.1161/CIRCULATIONAHA.118.035319>
- Ammirati E, Frigerio M, Adler E, Basso C, Birnie D, Brambatti M (2020) Management of acute myocarditis and chronic inflammatory cardiomyopathy: An expert consensus document. *Circ Heart Fail* 13(11): e007405. <https://doi.org/10.1161/CIRCHEARTFAILURE.120.007405>
- Anzini M, Merlo M, Sabbadini G, Barbati G, Finocchiaro G, Pinamonti B, Salvi A, Perkan A, Di Lenarda A, Bussani R, Bartunek J, Sinagra G (2013) Long-term evolution and prognostic stratification of biopsy-proven active myocarditis. *Circ Res* 128: 2384–2394. <https://doi.org/10.1161/CIRCULATIONAHA.113.003092>
- Aquaro GD, Perfetti M, Camastra G, Monti L, Dellegrottaglie S, Moro C, Pepe A, Todiere G, Lanzillo C, Scatteia A, Di Roma M, Pontone G, Perazzolo Marra M, Barison A, Di Bella G (2017) Cardiac magnetic resonance working group of the Italian Society of Cardiology. Cardiac MR with late gadolinium enhancement in acute myocarditis with preserved systolic function: ITAMY study. *J Am Coll Cardiol* 70: 1977–1987. <https://doi.org/10.1016/j.jacc.2017.08.044>
- Aromataris E, Munn Z (Editors) (2020) JBI Manual for Evidence Synthesis. JBI <https://doi.org/10.46658/JBIMES-20-01>
- Arvin AM, Fink K, Schmid MA, Cathcart A, Spreafico R, Havenar-Daughton C, Lanzavecchia A, Corti D, Virgin HW (2020) A perspective on potential antibody-dependent enhancement of SARS-CoV-2. *Nature* 584: 353–363. <https://doi.org/10.1038/s41586-020-2538-8>
- Barda N, Dagan N, Ben-Shlomo Y, Kepten E, Waxman J, Ohana R, Hernán MA, Lipsitch M, Kohane I, Netzer D, Reis BY, Balicer RD (2021) Safety of the BNT162b2 mRNA COVID-19 vaccine in a nationwide setting. *New Engl J Med* 385(12): 1078–1090. <https://doi.org/10.1056/NEJMoa2110475>
- Bartok E, Hartmann G (2020) Immune sensing mechanisms that discriminate self from altered self and foreign nucleic acids. *Immunity* 53: 54–77. <https://doi.org/10.1016/j.immuni.2020.06.014>
- Bass A, Patterson JH, Adams KF Jr (2010) Perspective on the clinical application of troponin in heart failure and states of cardiac injury. *Heart Fail Rev* 15(4): 305–317. <https://doi.org/10.1007/s10741-008-9124-8>
- Biesbroek PS, Beek AM, Gormans T, Niessen HW, van Rossum AC (2015) Diagnosis of myocarditis: Current state and future perspectives. *Int J Cardiol* 191: 211–219. <https://doi.org/10.1016/j.ijcard.2015.05.008>
- Bleier J, Vorderwinkler KP, Falkensammer J, Mair P, Papunt O, Puschendorf B, Mair J (1998) Different intracellular compartmentations of cardiac troponins and myosin heavy chains: a causal connection to their different early release after myocardial damage. *Clin Chem* 44: 1912–1918.
- Boehmer TK, Kompaniyets L, Lavery AM, Hsu J, Ko JY, Yusuf H, Romano SD, Gundlapalli AV, Oster ME, Harris AM (2021) Association between COVID-19 and myocarditis using hospital-based administrative data - United States, March 2020-January 2021. *MMWR Morb Mortal Wkly Rep* 70(35): 1228–1232. <http://dx.doi.org/10.15585/mmwr.mm7035e5>
- Butta C, Zappia L, Laterra G, Roberto M (2020) Diagnostic and prognostic role of electrocardiogram in acute myocarditis: A comprehensive review. *Ann Noninvasive Electrocardiol* 25(3): e12726. <https://doi.org/10.1111/anec.12726>
- Caforio AL, Calabrese F, Angelini A, Tona F, Vinci A, Bottaro S, Ramondo A, Carturan E, Iliceto S, Thiene G, Daliento L (2007) A prospective study of biopsy-proven myocarditis: prognostic relevance of clinical and aetiopathogenic features at diagnosis. *Eur Heart J* 28(11): 1326–1333. <https://doi.org/10.1093/eurheartj/ehm076>
- Cai C, Peng Y, Shen E, Huang Q, Chen Y, Liu P, Guo C, Feng Z, Gao L, Zhang X, Gao Y, Liu Y, Han Y, Zeng S, Shen H (2021) A comprehensive analysis of the efficacy and safety of COVID-19 vaccines. *Mol Ther* 29(9): 2794–2805. <https://doi.org/10.1016/j.jymthe.2021.08.001>
- CDC (2021a) Centres for Diseases Control and Prevention (CDC). Local Reactions, Systemic Reactions, Adverse Events, and Serious Adverse Events: Moderna COVID-19 Vaccine. <https://www.cdc.gov/vaccines/covid-19/info-by-product/moderna/reactogenicity.html> [Consulted: 7 February 2022].
- CDC (2021b) Centres for Diseases Control and Prevention (CDC). Reactions and Adverse Events of the Pfizer-BioNTech COVID-19 Vaccine. Available online: <https://www.cdc.gov/vaccines/covid-19/info-by-product/pfizer/reactogenicity.html> [Consulted: 7 February 2022].
- CDC (2021c) Centres for Diseases Control and Prevention (CDC). Multisystem Inflammatory Syndrome (MIS). Atlanta, ga: us department of health and human services. <https://www.cdc.gov/mis/index.html> [Consulted: 20 March 2022].
- Cheng MP, Kozoriz MG, Ahmadi AA, Kelsall J, Paquette K, Onrot JM (2016) Post-vaccination myositis and myocarditis in a previously healthy male. *Allergy Asthma Clin Immunol* 12: 6. <https://doi.org/10.1186/s13223-016-0114-4>
- Cereda A, Conca C, Barbieri L, Ferrante G, Tumminello G, Lucreziotti S, Guazzi M, Mafriaci A (2021) Acute myocarditis after the second dose of SARS-CoV-2 vaccine: Serendipity or atypical causal relationship? *Anatol J Cardiol* 25(7): 522–523. <https://doi.org/10.5152/AnatolJCardiol2021.99>
- Crowley A, Ackerman M (2019) Mind the gap: How interspecies variability in igg and its receptors may complicate comparisons of human and non-human primate effector

- function. *Front Immunol* 10: 697. <https://doi.org/10.3389/fimmu.2019.00697>
- Deb A, Abdelmalek J, Iwuiji K, Nugent K (2021) Acute myocardial injury following COVID-19 vaccination: a case report and review of current evidence from vaccine adverse events reporting system database. *J Prim Care Community Health* 12: 21501327211029230. <https://doi.org/10.1177/21501327211029230>
- Dekkers G, Bentlage AEH, Stegmann TC, Howie HL, Lissenberg-Thunnissen S, Zimring J, Rispens T, Vidarsson G (2017) Affinity of human IgG subclasses to mouse Fc gamma receptors. *MAbs* 9(5): 767–773. <https://doi.org/10.1080/19420862.2017.1323159>
- di Dedda EA, Barison A, Aquaro GD, Ismail TF, Hua A, Mantini C, Ricci F, Pontone G, Volpe A, Secchi F, Di Renzi P, Lovato L, Niro F, Liguori C, De Biase C, Monti L, Cirò A, Marano R, Natale L, Moliterno E, Esposito A, Vignale D, Faletti R, Gatti M, Porcu M, Saba L, Chimentì C, Galea N, Francone M (2022) Cardiac magnetic resonance imaging of myocarditis and pericarditis following COVID-19 vaccination: a multicenter collection of 27 cases. *Eur Radiol* 32(7): 4352–4360. <https://doi.org/10.1007/s00330-022-08566-0>
- Dickey JB, Albert E, Badr M, Laraja KM, Sena LM, Gerson DS, Saucedo JE, Qureshi W, Aurigemma GP (2021) A series of patients with myocarditis following SARS-CoV-2 vaccination with mRNA-1279 and BNT162b2. *JACC: Cardiovasc Imaging* 14(9): 1862–1863. <https://doi.org/10.1016/j.jcmg.2021.06.003>
- Dye C, Mills MC (2021) COVID-19 vaccination passports. *Science* 371(6535): 1184. <https://doi.org/10.1126/science.aba5245>
- Ehrlich P, Klingel K, Ohmann-Knafo S, Hüttinger S, Sood N, Pickuth D, Kindermann M (2021) Biopsy-proven lymphocytic myocarditis following first mRNA COVID-19 vaccination in a 40-year-old male: case report. *Clin Res Cardiol* 110(11): 1855–1859. <https://doi.org/10.1007/s00392-021-01936-6>
- Fairweather D, Cooper LT Jr, Blauwet LA (2013) Sex and gender differences in myocarditis and dilated cardiomyopathy. *Curr Probl Cardiol* 38(1): 7–46. <https://doi.org/10.1016/j.cpcardiol.2012.07.003>
- Feng S, Chiu SS, Chan ELY, Kwan MYW, Wong JSC, Leung CW, Chung Lau Y, Sullivan SG, Malik Peiris JS, Cowling BJ (2018) Effectiveness of influenza vaccination on influenza-associated hospitalizations over time among children in Hong Kong: a test-negative case-control study. *Lancet Respir Med* 6(12): 925–934. [https://doi.org/10.1016/s2213-2600\(18\)30419-3](https://doi.org/10.1016/s2213-2600(18)30419-3)
- Ferdinands JM, Gaglani M, Martin ET, Monto AS, Middleton D, Silveira F, Talbot HK, Zimmerman R, Patel M (2021) Waning vaccine effectiveness against influenza-associated hospitalizations among adults, 2015–2016 to 2018–2019, United States hospitalized adult influenza vaccine effectiveness network. *Clin Infect Dis* 73(4): 726–729. <https://doi.org/10.1093/cid/ciab045>
- Fischinger S, Boudreau CM, Butler AL, Streeck H, Alter G (2019) Sex differences in vaccine-induced humoral immunity. *Semin Immunopathol* 41(2): 239–249. <https://doi.org/10.1007/s00281-018-0726-5>
- Frisancho-Kiss S, Coronado MJ, Frisancho JA, Lau VM, Rose NR, Klein SL, Fairweather D (2009) Conadectomy of male BALB/c mice increases Tim-3(+) alternatively activated M2 macrophages, Tim-3(+) T cells, Th2 cells and Treg in the heart during acute coxsackievirus-induced myocarditis. *Brain Behav Immun* 23(5): 649–657. <https://doi.org/10.1016/j.bbi.2008.12.002>
- Gargano JW, Wallace M, Hadler SC, Langley G, Su JR, Oster ME, Broder KR, Gee J, Weintraub E, Shimabukuro T, Scobie HM, Moulia D, Markowitz LE, Wharton M, McNally VV, Romero JR, Talbot HK, Lee GM, Daley MF, Oliver SE (2021) Use of mRNA COVID-19 vaccine after reports of myocarditis among vaccine recipients: update from the advisory committee on immunization practices - united states, June 2021. *MMWR Morb Mortal Wkly Rep* 70(27): 977–982. <http://dx.doi.org/10.15585/mmwr.mm7027e2>
- Guo CW, Alexander M, Dib Y, Lau PKH, Weppler AM, Au-Yeung G, Lee B, Khoo C, Mooney D, Joshi SB, Creati L, Sandhu S (2020) A closer look at immune-mediated myocarditis in the era of combined checkpoint blockade and targeted therapies. *Eur J Cancer* 124: 15–24. <https://doi.org/10.1016/j.ejca.2019.09.009>
- Gürdoğan M, Yalta K (2020) Myocarditis associated with immune checkpoint inhibitors: Practical considerations in diagnosis and management. *Anatol J Cardiol* 24(2): 68–75. <https://doi.org/10.14744/anatoljcardiol.2020.79584>
- Hasnie AA, Hasnie UA, Patel N, Aziz MU, Xie M, Lloyd SG, Prabhu SD (2021) Perimyocarditis following first dose of the mRNA-1273 SARS-CoV-2 (Moderna) vaccine in a healthy young male: a case report. *BMC Cardiovasc Disord* 21: 375. <https://doi.org/10.1186/s12872-021-02183-3>
- Higgins JPT, Altman DG, Gotzsche PC, Jüni P, Moher D, Oxman AD, Savović J, Schulz KF, Weeks L, Sterne JAC (2011) The Cochrane collaboration's tool for assessing risk of bias in randomised trials. *BMJ (Online)* 343(7829): 1–9. <https://doi.org/10.1136/bmj.d5928>
- Hudson B, Mantooth R, DeLaney M (2021) Myocarditis and pericarditis after vaccination for COVID-19. *JACEP Open* 2: e12498. <https://doi.org/10.1002/emp2.12498>
- Imazio M, Angelico G, Andriani M, Lobetti-Bodoni L, Davini O, Giustetto C, Rinaldi M (2018) Prevalence and prognostic impact of septal late gadolinium enhancement in acute myocarditis with or without preserved left ventricular function. *Am J Cardiol* 122(11): 1955–1958. <https://doi.org/10.1016/j.amjcard.2018.08.038>
- Imazio M, Brucato A, Barbieri A, Ferroni F, Maestroni S, Ligabue G, Chinaglia A, Cumetti D, Della Casa G, Bonomi F, Mantovani F, Di Corato P, Lugli R, Faletti R, Leuzzi S, Bonamini R, Modena MG, Belli R (2013) Good prognosis for pericarditis with and without myocardial involvement: Results from a multicenter, prospective cohort study. *Circulation* 128(1): 42–49. <https://doi.org/10.1161/CIRCULATIONAHA.113.001531>
- Imazio M, Brucato A, Spodick D, Adler Y (2014) Prognosis of myopericarditis as determined from previously published reports. *J Cardiovasc Med (Hagerstown)* 15: 835–839. <https://doi.org/10.2459/jcm.0000000000000082>
- Jackson N, Kester K, Casimiro D, Gurunathan S, DeRosa F (2020) The promise of mRNA vaccines: A biotech and industrial perspective. *NPJ Vaccines* 5: 11. <https://doi.org/10.1038/s41541-020-0159-8>
- Jensen S, Thomsen A (2012) Sensing of RNA viruses: a review of innate immune receptors involved in recognizing RNA virus invasion. *J Virol* 86: 2900–2910. <https://doi.org/10.1128/jvi.05738-11>
- June Choe Y, Yi S, Hwang I, Kim J, Park YJ, Cho E, Jo M, Lee H, Hwa Choi E (2022) Safety and effectiveness of BNT162b2 mRNA COVID-19 vaccine in adolescents. *Vaccine* 40(5): 691–694. <https://doi.org/10.1016/j.vaccine.2021.12.044>
- Kim HW, Jenista ER, Wendell DC, Azevedo CF, Campbell MJ, Darty SN, Parker MA, Kim RJ (2021) Patients with acute myocarditis following mRNA COVID-19 vaccination. *JAMA Cardiol* 6(10): 1196–1201. <https://doi.org/10.1001/jamacardio.2021.2828>
- Kim IC, Kim H, Lee HJ, Kim JY, Kim JY (2021) Cardiac imaging of acute myocarditis following COVID-19 mRNA vaccination. *J Korean Med Sci* 36(32): e229. <https://doi.org/10.3346/jkms.2021.36.e229>

- King WW, Petersen MR, Malar RM, Budweg JB, Cuervo Pardo L, Petersen JW (2021) Myocarditis following mRNA vaccination against SARS-CoV-2, a case series. *Am Heart J Plus: Cardiol Res Pract* 8: 100042. <https://doi.org/10.1016/j.ahjo.2021.100042>
- Klugar M, Riad A, Mekhemar M, Conrad J, Buchbender M, Howaldt HP, Altia S (2021) Side effects of mRNA-based and viral vector-based COVID-19 vaccines among german healthcare workers. *Biology* 10(8): 752. <https://doi.org/10.3390/biology10080752>
- Knowlton KU, Knight S, Muhlestein JB, Le VT, Horne BD, May HT, Stenehjem E, Anderson JL (2021) A small but significant increased incidence of acute pericarditis identified after vaccination for SARS-COV-2. *Circulation* 144(Suppl. 1): A11396. https://doi.org/10.1161/circ.144.suppl_1.11396
- Lasrado N, Reddy J (2020) An overview of the immune mechanisms of viral myocarditis. *Rev Med Virol* 30: e2131. <https://doi.org/10.1002/rmv.2131>
- Lyden D, Olszewski J, Feran M, Job L, Huber S (1987) Cocksackievirus B-3-induced myocarditis. Effect of sex steroids on viremia and infectivity of cardiocytes. *Am J Pathol* 126: 432-438.
- Maron BJ, Udelsion JE, Bonow RO, Nishimura RA, Ackerman MJ, Estes NAM, Cooper LT, Link MS, Maron MS (2015) Eligibility and disqualification recommendations for competitive athletes with cardiovascular abnormalities: task force 3: hypertrophic cardiomyopathy, arrhythmogenic right ventricular cardiomyopathy and other cardiomyopathies, and myocarditis. *Circulation* 132(22): e273-e280. <https://doi.org/10.1161/CIR.0000000000000239>
- 8 Marshall M, Ferguson ID, Lewis P, Jaggi P, Gagliardo C, Collins JS, Shaughnessy R, Caron R, Fuss C, Corbin KJE, Emuren L, Faherty E, Hall EK, Pentima CD, Oster ME, Paintsil E, Siddiqui S, Timchak DM, Guzman-Cottrill JA (2021) Symptomatic acute myocarditis in 7 adolescents after Pfizer-BioNTech COVID-19 vaccination. *Pediatrics* 148(3): e2021052478. <https://doi.org/10.1542/peds.2021-052478>
- Matta A, Kunadharaju R, Osman M (2021) Clinical presentation and outcomes of myocarditis post mRNA vaccination: a meta-analysis and systematic review. *Cureus* 11: e19240. <https://doi.org/10.7759/cureus.19240>
- McLean K, Johnson TJ (2021) Myopericarditis in a previously healthy adolescent male following COVID-19 vaccination: A case report. *Acad Emerg Med* 28(8): 918-921. <https://doi.org/10.1111/acem.14322>
- Mevorach D, Anis E, Cedar N, Bromberg M, Haas EJ, Nadir E, Olsha-Castell S, Arad D, Hasin T, Levi N, Asleh R, Amir O, Meir K, Cohen D, Dichtiar R, Novick D, Hershkovitz Y, Dagan R, Leitersdorf I, Ben-Ami R, Miskin I, Saliba W, Muhsen K, Levi Y, Green MS, Keinan-Boker L, Alroy-Preis S (2021) Myocarditis after BNT162b2 mRNA vaccine against COVID-19 in Israel. *N Engl J Med* 385(23): 2140-2149. <https://doi.org/10.1056/nejmoa2109730>
- Moher D, Shamseer L, Clarke M, Ghersi D, Liberati A, Petticrew M, Shekelle P, Stewart LA, Group PP (2015) Preferred reporting items for systematic review and meta-analysis protocols (Prisma-p) 2015 statement. *Syst Rev* 4(1): 1. <https://doi.org/doi:10.1186/2046-4053-4-1>
- Montgomery J, Ryan M, Engler R, Hoffman D, McClenathan B, Collins L, Loran D, Hincir D, Herring K, Platzer M, Adams N, Sanou A, Cooper LT (2021) Myocarditis following immunization with mRNA COVID-19 vaccines in members of the US military. *JAMA Cardiol* 6(10): 1202-1206. <https://doi.org/10.1001/jamacardio.2021.2833>
- Nassar M, Nso N, Gonzalez C, Lakhdar S, Alshamam M, Elshafey M, Abdalazeem Y, Nyein A, Punzalan B, Durrance RJ, Alfishawy M, Bakshi S, Rizzo V (2021) COVID-19 vaccine-induced myocarditis: Case report with literature review. *Diabetes Metab Syndr* 15(5): 102205. <https://doi.org/10.1016/j.dsx.2021.102205>
- Nevet A (2021) Acute myocarditis associated with anti-COVID-19 vaccination. *Clin Exp Vaccine Res* 10(2): 196-197. <https://doi.org/10.7774/cevr.2021.102.196>
- Oster ME, Shay DK, Su JR, Gee J, Creech CB, Broder KR, Edwards K, Soslow JF, Dendy JM, Schlaudecker E, Lang SM, Barnett ED, Ruberg FL, Smith MJ, Campbell MJ, Lopes RD, Sperling LS, Baumblatt JA, Thompson DL, Marquez PL, Strid P, Woo J, Pugsley R, Reagan-Steiner S, DeStefano F, Shimabukuro TT (2022) Myocarditis cases reported after mRNA-based COVID-19 vaccination in the US from December 2020 to August 2021. *JAMA* 327(4): 331-340. <https://doi.org/doi:10.1001/jama.2021.24110>
- Pardi N, Hogan M, Porter F, Weissman D (2018) mRNA vaccines - a new era in vaccinology. *Nat Rev Drug Discov* 17: 261-279. <https://doi.org/10.1038/nrd.2017.243>
- Park JW, Lagniton PNP, Liu Y, Xu RH (2021) mRNA vaccines for COVID-19: What, why and how. *Int J Biol Sci* 17(6): 1446-1460. <https://doi.org/10.7150/ijbs.59233>
- Patel YR, Louis DW, Atalay M, Agarwal S, Shah NR (2021) Cardiovascular magnetic resonance findings in young adult patients with acute myocarditis following mRNA COVID-19 vaccination: a case series. *J Cardiovasc Magn Reson* 23: 101. <https://doi.org/10.1186/s12968-021-00795-4>
- Patone M, Mei XW, Handunnetthi L, Dixon S, Zaccardi F, Shankar-Hari M, Watkinson P, Khunti K, Harnden A, Coupland CAC, Channon KM, Mills NL, Sheikh A, Hippisley-Cox J (2022) Risks of myocarditis, pericarditis, and cardiac arrhythmias associated with COVID-19 vaccination or SARS-CoV-2 infection. *Nat Med* 28(2): 410-422. <https://doi.org/10.1038/s41591-021-01630-0>
- Pilishvili T, Fleming-Dutra KE, Farrar JL, Gierke R, Mohr NM, Talan DA, Krishnadasan A, Hailand KK, Smuthline HA, Hou PC, Lee LC, Lim SC, Moran GJ, Krebs E, Steele M, Beiser DG, Faine B, Haran JP, Nandi U, Schradling WA, Chincock B, Henning DJ, Vecchio FL, Nadle J, Barter D, Brackney M, Britton A, Marceaux-Galli K, Lim S, Phipps EC, Dumyati G, Pierce R, Markus TM, Anderson DJ, Debes AK, Lin M, Mayer J, Babcock HM, Safdar N, Fischer M, Singleton R, Chea N, Magill SS, Verani J, Schrag S (2021) Interim estimates of vaccine effectiveness of Pfizer-BioNTech and Moderna COVID-19 vaccines among health care personnel - 33 US sites, January-March 2021. *MMWR. Morb Mortal Wkly Rep* 70(20): 753-758. <https://doi.org/10.15585/mmwr.mm7020e2>
- Potluri T, Fink A, Sylvia K, Dhakal S, Vermillion MS, Steeg LV, Deshpande S, Narasimhan H, Klein SL (2019) Associated changes in the impact of sex steroids on influenza vaccine responses in males and females. *NPJ Vaccines* 4: 29. <https://doi.org/10.1038/s41541-019-0124-6>
- Rombey T, Doni K, Hoffmann F, Pieper D, Allers K (2020) More systematic reviews were registered in PROSPERO each year, but few records' status was up-to-date. *J Clin Epidemiol* 117: 60-67. <https://doi.org/10.1016/j.jclinepi.2019.09.026>
- Rosner CM, Genovese L, Tehrani BN, Atkins M, Bakshi H, Chaudhri S, Damluji AA, Lemos JAD, Desai SS, Emaminia A, Flanagan MC, Khera A, Maghsoudi A, Mekonnen G, Muthukumar A, Saeed IM, Sherwood MW, Sinha SS, O'Connor CM, deFilippi CR (2021) Myocarditis temporally associated with COVID-19 vaccination. *Circulation* 144(6): 502-505. <https://doi.org/10.1161/CIRCULATIONAHA.121.055891>
- Rowland C, Johnson CY (2020) Even finding a COVID-19 vaccine won't be enough to end the pandemic. *Washington Post*. May 11, 2020. <https://www.washingtonpost.com/business/2020/05/11/co>

- [ronavirus-vaccine-global-supply/](#) [Consulted: 1 February 2022].
- Ruggieri A, Anticoli S, D'Ambrosio A, Giordani L, Viora M (2016) The influence of sex and gender on immunity, infection and vaccination. *Ann Ist Super Sanita* 52(2): 198–204. <https://doi.org/10.4415/ann.16.02.11>
- Sahin U, Kariko K, Tureci O (2014) mRNA-based therapeutics—developing a new class of drugs. *Nat Rev Drug Discov* 13: 759–780. <https://doi.org/10.1038/nrd4278>
- Salah HM, Mehta JL (2021) COVID-19 vaccine and myocarditis. *Am J Cardiol* 157: 146–148. <https://doi.org/10.1016/j.amjcard.2021.07.009>
- Shaw KE, Cavalcante JL, Han BK, Gössl M (2021) Possible association between COVID-19 vaccine and myocarditis: Clinical and CMR findings. *JACC: Cardiovascular Imaging* 14(9): 1856–1861. <https://doi.org/10.1016/j.jcmg.2021.06.002>
- Shiyovich A, Witberg C, Aviv Y, Eisen A, Orvin K, Wiessman M, Grinberg T, Porter A, Kornowski R, Hamdan A (2021) Myocarditis following COVID-19 vaccination: magnetic resonance imaging study. *Eur Heart J Cardiovasc Imaging* 3(8): 1075–1082. <https://doi.org/10.1093/ehjci/jeab230>
- Simone A, Herald J, Chen A, Gulati N, Shen AY, Lewin B, Lee MS (2021) Acute myocarditis following COVID-19 mRNA vaccination in adults aged 18 years or older. *JAMA Intern Med* 181(12): 1668–1670. <https://doi.org/10.1001/jamainternmed.2021.5511>
- Singh B, Kaur P, Cedeno L, Brahmī T, Patel P, Virk H, Shamoon F, Bikkina M (2021) COVID-19 mRNA vaccine and myocarditis. *Eur J Case Rep Intern Med* 14(8(7): 002681. https://doi.org/10.12890/2021_002681
- Singh VP, Pir MS, Buch T, Kaur A, Kela K, Shah P, Miller J, Naseer R, Ghosh P (2021) Myocarditis linked to Pfizer-BioNTech COVID-19 vaccine. *Chest* 160(4): A444. <https://doi.org/10.1016/j.chest.2021.07.437>
- Snapiri O, Danziger CR, Shirman N, Weissbach A, Lowenthal A, Ayalon I, Adam D, Yarden-Bilavsky H, Bilavsky F (2021) Transient cardiac injury in adolescents receiving the BNT162b2 mRNA COVID-19 vaccine. *Pediatr Infect Dis J* 40(10): e360–e363. <https://doi.org/10.1097/INF.0000000000003235>
- Starekova J, Bluemke DA, Bradham WS, Grist TM, Schiebeler ML, Reeder SB (2021) Myocarditis associated with mRNA COVID-19 vaccination. *Radiology* 301(2): E409–E411. <https://doi.org/10.1148/radiol.2021211430>
- Sung JG, Sobieszcyk PS, Bhatt DL (2021) Acute myocardial infarction within 24 hours after COVID-19 vaccination. *Am J Cardiol* 156: 129–131. <https://doi.org/10.1016/j.amjcard.2021.06.047>
- Tenforde M, Olson S, Self W, Network IVY, Investigators H (2021) Effectiveness of Pfizer-BioNTech and Moderna vaccines against COVID-19 among hospitalized adults aged ≥65 years—United States, January–March 2021. *Morb Mortal Wkly Rep* 70: 674–679. <https://doi.org/10.15585/mmwr.mm7018e1>
- Thevathasan T, Kenny MA, Schreiber F, Fairweather D, Cooper LT, Last J, Krause FJJ, Paul J, Poller WC, Skurk C, Landmesser U, Balzer F, Heidecker B (2021) The strongest sex difference in myocarditis prevalence occurred in young adult patients – A descriptive, multi-center cohort study in 7,031 patients over 22 years. *Circulation* 144(Suppl. 1): A11548–A11548. https://doi.org/10.1161/circ.144.suppl_1.11548
- Thompson M, Burgess J, Naleway A, Tyner H, Yoon S, Meece J, Olsho L, Caban-Martinez A, Fowlkes A, Lutrick K, Groom H, Dunnigan K, Odean M, Hegmann K, Stefanski E, Edwards L, Schaefer-Solle N, Grant L, Ellingson K, Kuntz J, Zunie T, Thiese M, Ivacic L, Wesley M, Mayo Lambert J, Sun X, Smith M, Phillips A, Groover K, Yoo Y, Gerald J, Brown R, Herring M, Joseph G, Beitel S, Morrill T, Mak J, Rivers P, Poe B, Lynch B, Zhou Y, Zhang J, Kelleher A, Li Y, Dickerson M, Hanson E, Guenther K, Tong S, Bateman A, Reisdorf E, Barnes J, Azziz-Baumgartner E, Hunt D, Arvay M, Kutty P, Fry A, Gaglani M (2021) Prevention and attenuation of COVID-19 with the BNT162b2 and mRNA-1273 vaccines. *N Engl J Med* 385: 320–329. <https://doi.org/10.1056/NEJMoa2107058>
- Trachtenberg BH, Hare JM (2017) Inflammatory cardiomyopathic syndromes. *Circ Res* 121: 803–818. <https://doi.org/10.1161/CIRCRESAHA.117.310221>
- Triguñaite A, Dimo J, Jørgensen TN (2015) Suppressive effects of androgens on the immune system. *Cell Immunol* 294(2): 87–94. <https://doi.org/10.1016/j.cellimm.2015.02.004>
- Vaccines and Related Biological Products Advisory Committee Meeting (2020) FDA briefing document: Pfizer-BioNTech COVID-19 Vaccine. New York (NY): Pfizer and BioNTech.
- Valbuena-López S, Hinojar R, Puntmann VO (2016) Cardiovascular magnetic resonance in cardiology practice: A concise guide to image acquisition and clinical interpretation. *Rev Esp Cardiol* 69(2): 202–210. <https://doi.org/10.1016/j.rec.2015.11.011>
- Verma AK, Lavine KJ, Lin CY (2021) Myocarditis after Covid-19 mRNA vaccination. *N Engl J Med* 385: 1332–1334. <https://doi.org/10.1056/NEJMc2109975>
- Vollmann D, Eiffert H, Schuster A (2021) Acute perimyocarditis following first dose of mRNA vaccine against COVID-19. *Dtsch Arztebl Int* 118: 546. <https://doi.org/10.3238/arztebl.m2021.0288>
- WHO (2020a) World Health Organization. Statement on the second meeting of the international health. Regulations (2005) emergency committee regarding the outbreak of novel coronavirus. <https://www.who.int/news-room/detail/30-01-2020-st> [Consulted: 1 February 2022].
- WHO (2020b) World Health Organization. COVID-19 Dashboard. In Available online: <https://covid19.who.int/> [Consulted: 7 February 2022].
- Witberg C, Barda N, Hoss S, Richter I, Wiessman M, Aviv Y, Grinberg T, Auster O, Dagan N, Balicer RD, Kornowski R (2021) Myocarditis after COVID-19 Vaccination in a Large Health Care Organization. *N Engl J Med* 385: 2132–2139. <https://doi.org/10.1056/NEJMoa2110737>
- Wittrup A, Lieberman J (2015) Knocking down disease: a progress report on siRNA therapeutics. *Nat Rev Genet* 16(9): 543–552. <https://doi.org/10.1038/nrg3978>
- Woudsira L, Juffermans LJM, Rossum VAC (2018) Infectious myocarditis: The role of the cardiac vasculature. *Heart Fail Rev* 23: 583–595. <https://doi.org/10.1007/s10741-018-9688-x>
- Yap J, Tham MY, Poh J, Toh D, Chan CL, Lim TW, Lim SL, Chia YW, Lim YT, Choo J, Ding ZP, Foo LL, Kuo S, Lau YH, Lee A, Yeo KK (2022) Pericarditis and myocarditis after COVID-19 mRNA vaccination in a nationwide setting. *Ann Acad Med Singap* 51(2): 96–100. <https://doi.org/10.47102/annals-acadmedsg.2021425>
- Zachary M, Edoardo A, Catalin T (2019) The development of software to support multiple systematic review types. *Int J Evid Based Healthc* 17(1): 36–43. <https://doi.org/10.1097/XEB.0000000000000152>
- Zhang L, Awadalla M, Mahmood SS, Nohria A, Hassan MZO, Thuny F, Zlotoff DA, Murphy SP, Stone JR, Golden DLA, Alvi RM, Rokicki A, Jones-O'Connor M, Cohen JV, Heinzerling LM, Mulligan C, Armanious M, Barac A, Forrestal BJ, Sullivan RJ, Kwong RY, Yang EH, Damrongwatanasuk R, Chen CL, Gupta D, Kirchberger MC, Meskhi JJ, Coelho-Filho OR, Ganatra S, Rizvi MA, Sahni G, Tocchetti CG, Mercurio V, Mahmoudi M, Lawrence DP, Reynolds KL, Weinsaft JW, Baksi AJ, Ederly S, Groarke JD, Lyon AR, Fradley MG, Thavendiranathan P, Neilan TG (2020b) Cardiovascular magnetic resonance in

immune checkpoint inhibitor-associated myocarditis. *Eur Heart J* 41(18): 1733–1743. <https://doi.org/10.1093/eurheartj/ehaa051>

Zhang NN, Li XF, Deng YQ, Zhao H, Huang YJ, Yang G, Huang WJ, Gao P, Zhou C, Zhang RR, Guo Y, Sun SH, Fan H, Zu SL,

Chen Q, He Q, Cao TS, Huang XY, Qiu HY, Nie JH, Jiang Y, Yan HY, Ye Q, Zhong X, Xue XL, Zha ZY, Zhou D, Yang X, Wang, YC, Ying B, Qi CF (2020a) A thermostable mRNA vaccine against COVID-19. *Cell* 182(5): 1271–1283.e16. <https://doi.org/10.1016/j.cell.2020.07.024>.

AUTHOR CONTRIBUTION:

| Contribution | Putri EAC | Munir M | Setiawan HK | Herawati L | Sari GM | Wungu CDK | Susilo H | Sutanto H |
|------------------------------------|-----------|---------|-------------|------------|---------|-----------|----------|-----------|
| Concepts or ideas | ✗ | | | | | | | |
| Design | ✗ | ✗ | | | | | | |
| Definition of intellectual content | ✗ | ✗ | | | | | | |
| Literature search | ✗ | ✗ | | | | | | |
| Experimental studies | | | | | | | | |
| Data acquisition | | | ✗ | ✗ | | | | |
| Data analysis | | | ✗ | ✗ | ✗ | ✗ | | |
| Statistical analysis | | | | | ✗ | ✗ | | |
| Manuscript preparation | | | | | ✗ | ✗ | ✗ | ✗ |
| Manuscript editing | | | | | | | ✗ | ✗ |
| Manuscript review | ✗ | ✗ | ✗ | ✗ | ✗ | ✗ | ✗ | ✗ |

Citation Format: Putri EAC, Munir M, Setiawan HK, Herawati L, Sari GM, Wungu CDK, Susilo H, Sutanto H (2023) Adverse cardiac events following mRNA COVID-19 vaccination: A systematic review and meta-analysis. *J Pharm Pharmacogn Res* 11(1): 76–100.

https://doi.org/10.56499/jppres22.1524_11.1.76

Publisher's Note: All claims expressed in this article are solely those of the authors and do not necessarily represent those of their affiliated organizations, or those of the publisher, the editors and the reviewers. Any product that may be evaluated in this article, or claim that may be made by its manufacturer, is not guaranteed or endorsed by the publisher.

Open Access: This article is distributed under the terms of the Creative Commons Attribution 4.0 International License (<http://creativecommons.org/licenses/by/4.0/>), which permits use, duplication, adaptation, distribution and reproduction in any medium or format, as long as you give appropriate credit to the original author(s) and the source, provide a link to the Creative Commons license and indicate if changes were made.

Supplementary Table 1. Medline (PubMed) search strategy to identify published literature.

| | |
|----|---|
| #1 | Search(((((((COVID19 vaccin*[MeSH Terms]) OR (COVID-19 vaccin[MeSH Terms]) OR (SARSCOV2 vaccin*[MeSH Terms]) OR (SARS-COV-2 vaccin*[MeSH Terms])) OR (COVID19 vac- cin*[Title/Abstract])) OR (COVID-19 vaccin*[Title/Abstract])) OR (SARSCOV2 vaccin*[Title/Abstract])) OR (SARS-COV-2 vaccin*[Title/Abstract])) |
| #2 | Search((((((((((((myocarditis[MeSH Terms]) OR (pericarditis[MeSH Terms]) OR (angina pectoris*[MeSH Terms]) OR (arrhythmia[MeSH Terms]) OR (myocardial infarction[MeSH Terms])) OR (cardi- tis[MeSH Terms])) OR (myocarditis[Title/Abstract])) OR (pericarditis[Title/Abstract])) OR (angina pectoris*[Title/Abstract])) OR (arrhythmia[Title/Abstract])) OR (myocardial infarction[Title/Abstract])) |
| #3 | #1 and #2 |

Supplementary Table 2. Risk of bias evaluation of mRNA COVID-19 vaccines and adverse cardiac events (Case Series):

| No. | Reference (country) | 1. Were there clear criteria for inclusion in the case series? | 2. Was the condition measured in a standard, reliable way for all participants included in the case series? | 3. Were valid methods used for identification of the condition for all participants included in the case series? | 4. Did the case series have consecutive inclusion of participants? | 5. Did the case series have complete inclusion of participants? | 6. Was there clear reporting of the demographics of the participants in the study? | 7. Was there clear reporting of clinical information on the participants? | 8. Were the outcomes or follow up results clearly reported? | 9. Was there clear reporting of the presenting site(s)/clinic(s) demographic information? | 10. Was statistical analysis appropriate? | Overall Appraisal |
|-----|------------------------------|--|---|--|--|---|--|---|---|---|---|-------------------|
| 1 | Shaw et al., 2021 (USA) | Yes | Yes | Yes | Yes | Yes | Yes | Yes | Not applicable | Yes | Yes | Included |
| 2 | Dickey et al., 2021 (USA) | Yes | Yes | Yes | Yes | Yes | Yes | Yes | Not applicable | Yes | Yes | Included |
| 3 | Shepir et al., 2021 (USA) | Yes | Yes | Yes | Yes | Yes | Yes | Yes | Not applicable | Yes | Yes | Included |
| 4 | Patel et al., 2021 (USA) | Yes | Yes | Yes | Yes | Yes | Yes | Yes | Not applicable | Yes | Yes | Included |
| 5 | Kim HW et al., 2021 (USA) | Yes | Yes | Yes | Yes | Yes | Yes | Yes | Not applicable | Yes | Yes | Included |
| 6 | Marshall et al., 2021 (USA) | Yes | Yes | Yes | Yes | Yes | Yes | Yes | Not applicable | Yes | Yes | Included |
| 7 | Singh B et al., 2021 (USA) | Yes | Yes | Yes | Yes | Yes | Yes | Yes | Not applicable | Yes | Yes | Included |
| 8 | Starekova et al., 2021 (USA) | Yes | Yes | Yes | Yes | Yes | Yes | Yes | Not applicable | Yes | Yes | Included |
| 9 | Rosner et al., 2021 (USA) | Yes | Yes | Yes | Yes | Yes | Yes | Yes | Not applicable | Yes | Yes | Included |

According to The Joanna Briggs Institute (JBI), Critical Appraisal Checklist for Case Series.

Supplementary Table 3. Risk of bias evaluation of mRNA COVID-19 vaccines and adverse cardiac events (Case Report).

| No. | Reference (country) | 1. Were patient's demographic characteristics clearly described? | 2. Was the patient's history clearly described and presented as a timeline? | 3. Was the current clinical condition of the patient on presentation clearly described? | 4. Were diagnostic tests or assessment methods and the results clearly described? | 5. Was the intervention(s) or treatment procedure(s) clearly described? | 6. Was the post-intervention clinical condition clearly described? | 7. Were adverse events (harms) or unanticipated events identified and described? | 8. Does the case report provide takeaway lessons? | Overall Appraisal |
|-----|---------------------------------|--|---|---|---|---|--|--|---|-------------------|
| 1 | McLean and Johnson, 2021 (USA) | Yes | Yes | Yes | Yes | Yes | Yes | Yes | Included | |
| 2 | Cereda et al., 2021 (Italy) | Yes | Yes | Yes | Yes | Yes | Yes | Yes | Included | |
| 3 | Hudson et al., 2021 (USA) | Yes | Yes | Yes | Yes | Yes | Yes | Yes | Included | |
| 4 | Sung et al., 2021 (USA) | Yes | Yes | Yes | Yes | Yes | Yes | Yes | Included | |
| 5 | Hasnie et al., 2021 (USA) | Yes | Yes | Yes | Yes | Yes | Yes | Yes | Included | |
| 6 | Deb et al., 2021 (USA) | Yes | Yes | Yes | Yes | Yes | Yes | Yes | Included | |
| 7 | Nevet, 2021 (Israel) | Yes | Yes | Yes | Yes | Yes | Yes | Yes | Included | |
| 8 | Ehrlich et al., 2021 (Germany) | Yes | Yes | Yes | Yes | Yes | Yes | Yes | Included | |
| 9 | Kim J. et al., 2021 (Korea) | Yes | Yes | Yes | Yes | Yes | Yes | Yes | Included | |
| 10 | Singh VP et al., 2021 (USA) | Yes | Yes | Yes | Yes | Yes | Yes | Yes | Included | |
| 11 | Verma et al., 2021 (USA) | Yes | Yes | Yes | Yes | Yes | Yes | Yes | Included | |
| 12 | Vollmann et al., 2021 (Germany) | Yes | Yes | Yes | Yes | Yes | Yes | Yes | Included | |

According to The Joanna Briggs Institute (JBI), Critical Appraisal Checklist for Case Report.

Supplementary Table 4. Risk of bias evaluation of mRNA COVID-19 vaccines and adverse cardiac events (Cohort Studies).

| No. | Reference (origin country) | 1. Were the two groups similar and recruited from the same population? | 2. Were the exposures measured similarly to assign people to both exposed and unexposed groups? | 3. Was the exposure measured in a valid and reliable way? | 4. Were confounding factors identified? | 5. Were strategies to deal with confounding factors stated? | 6. Were the groups/participants free of the outcome at the start of the study (or at the moment of exposure)? | 7. Were the outcomes measured in a valid and reliable way? | 8. Was the follow up time reported and sufficient to be long enough for outcomes to occur? | 9. Was follow up complete, and if not, were the reasons to loss to follow up described and explored? | 10. Were strategies to address incomplete follow up utilized? | 11. Was an appropriate statistical analysis used? | Overall Appraisal |
|-----|----------------------------------|--|---|---|---|---|---|--|--|--|---|---|-------------------|
| 1 | Shiyovitch et al., 2021 (Israel) | Yes | Yes | Yes | Yes | Yes | Yes | Yes | Yes | Yes | Yes | Yes | Included |
| 2 | Mevorach et al., 2021 (Israel) | Yes | Yes | Yes | Yes | Yes | Yes | Yes | Yes | Yes | Yes | Yes | Included |
| 3 | Simone et al., 2021 (USA) | Yes | Yes | Yes | Yes | Yes | Yes | Yes | Yes | Yes | Yes | Yes | Included |
| 4 | Knowlton et al., 2021 (USA) | Yes | Yes | Yes | Yes | Yes | Yes | Yes | Yes | Yes | Yes | Yes | Included |
| 5 | di Dedda et al., 2022 (Italy) | Yes | Yes | Yes | Yes | Yes | Yes | Yes | Yes | Yes | Yes | Yes | Included |
| 6 | Yap et al., 2022 (Singapore) | Yes | Yes | Yes | Yes | Yes | Yes | Yes | Yes | Yes | Yes | Yes | Included |
| 7 | June Choe et al., 2022 (Korea) | Yes | Yes | Yes | Yes | Yes | Yes | Yes | Yes | Yes | Yes | Yes | Included |

According to The Joanna Briggs Institute (JBI), Critical Appraisal Checklist for Cohort Studies.

Supplementary Table 5. Source of funding and declare conflict of interest.

| No. | Reference (country) | Funding | Conflict of Interest |
|-----|----------------------------------|--|---|
| 1. | Shaw et al., 2021 (USA) | Dr Cavalcante has received research support from Circle Cardiovascular Imaging and Siemens Healthineers | Dr Góssi has served as a consultant for Abbott Vascular |
| 2. | Dickey et al., 2021 (USA) 48 | None | None |
| 3. | Shapiri et al., 2021 (USA) | None | None |
| 4. | Patel et al., 2021 (USA) | None | None |
| 5. | Kim HW et al., 2021 (USA) | Dr Campbell reported personal fees from Longseveron outside the submitted work | Dr R. J. Kim reported holding equity interest in Heart Imaging Technologies and grants from Siemens outside the submitted work |
| 6. | Marshall et al., 2021 (USA) | None | None |
| 7. | Singh B et al., 2021 (USA) 48 | None | None |
| 8. | Stankova et al., 2021 (USA) | None | None |
| 9. | Rosner et al., 2021 (USA) | Dr Damiliji receives research funding from the Pepper Scholars Program of the Johns Hopkins University. Claude D. Pepper Older Americans Independence Center funded by the National Institute on Aging (P30-AG021334) and a Mentored Patient-Oriented Research Career Development Award from the National Heart Lung, and Blood Institute (K23-HL153771-01). Dr deFilippi receives funding from the National Center for Advancing Translational Science of the National Institutes of Health (award UL1TR003015) | Dr Tehrani is a consultant for Medtronic, and is on the advisory board for Abbott Medical and Retriever Medical. Dr Atkins is on the advisory board for Arterys. Dr de Lemos has received grant support from Abbott Diagnostics and Roche Diagnostics and consulting income from Siemens Health Care Diagnostics, Ortho Clinical Diagnostics, and Quidel, Inc. Dr Desai serves on the Advisory Board at Abbott Medical. Dr. Muthu Kumar has received grant support from Abbott and Roche Diagnostics. Dr DeFilippo receives research funding to Inova from Abbott Diagnostics, Roche Diagnostics, Siemens Healthineers, and Ortho Diagnostics, and consults for Fujirebio, Roche Diagnostics, Siemens Healthineers, and Ortho Diagnostics |
| 10. | McLean and Johnson (2021 (USA) | None | None |
| 11. | Cereda et al., 2021 (Italy) | None | None |
| 12. | Hudson et al., 2021 (USA) | None | None |
| 13. | Sung et al., 2021 (USA) | None | None |
| 14. | Hasnie et al., 2021 (USA) | None | None |
| 15. | Deb et al., 2021 (USA) | None | None |
| 16. | Nevet, 2021 (Israel) | None | None |
| 17. | Ehrlich et al., 2021 (Germany) | None | None |
| 18. | Kim C et al., 2021 (Korea) | This work was supported by the research promoting grant from the Keimyung University Dongsan Medical Center in 2020 | None |
| 19. | Singh VP et al., 2021 (USA) | None | None |
| 20. | Verma et al., 2021 (USA) | None | None |
| 21. | Vollmann et al., 2021 (Germany) | None | None |

Supplementary Table 5. Source of funding and declare conflict of interest (continued...)

| No. | Reference (country) | Funding | Conflict of Interest |
|-----|---------------------------------|--|----------------------|
| 22. | Shiyovich et al., 2021 (Israel) | None | None |
| 23. | Mevorach et al., 2021 (Israel) | None | None |
| 24. | Simone et al., 2021 (USA) | None | None |
| 25. | Knowlton et al., 2021 (USA) | This work was funded by the Leif Loy Hansen Heart Foundation | None |
| 26. | di Dedda et al., 2022 (Italy) | None | None |
| 27. | Yap et al., 2022 (Singapore) | None | None |
| 28. | June Choe et al., 2021 (Korea) | None | None |

Supplementary Table 6. Clinical data of case series and case reports (part 1)

| Reference | Sample size | Sex (%) | Age (Median) | Previous cardiac disease history (%) | Previous other medical history (%) | Symptom | Onset of symptom (Median) | Dose (%) | Vaccine type (%) | Previous COVID-19 infection (%) |
|--------------------------|-------------|--------------------------|---------------------|--------------------------------------|------------------------------------|---|--------------------------------------|--------------------------------|-----------------------------------|---------------------------------|
| Shaw et al., 2021 | 4 | Male (50%); Female (50%) | 16-31 years (20.5) | (0%) | (0%) | Chest pain | 2-25 day after mRNA vaccination (4) | 1st dose (50%); 2nd dose (50%) | Pfizer (75%); Moderna (25%) | 5-7 months before symptom (50%) |
| Dickey et al., 2021 | 6 | Male (100%); Female (0%) | 16-40 years (20.25) | (0%) | (0%) | Fever, rhinorrhea, malaise, headache, positional / non-positional chest pressure, pleuritic chest pain, neck pain, chills, and myalgias | 2-4 day after mRNA vaccination (3.5) | 2nd dose (100%) | Pfizer (83.33%); Moderna (16.67%) | Unclear |
| McLean and Johnson, 2021 | 1 | Male (100%) | 16 years (16) | (0%) | (0%) | Chest pain, myalgias, and tactile fevers | 1 day after mRNA vaccination (1) | 2nd dose (100%) | Pfizer (100%) | Unclear |
| Cereda et al., 2021 | 1 | Male (100%) | 21 years (21) | (0%) | (0%) | Cardiac-sounding chest pain and fever | 2 days after mRNA vaccination (2) | 2nd dose (100%) | Pfizer (100%) | Unclear |
| Hudson et al., 2021 | 2 | Male (100%) | 22-24 years (23) | (0%) | (0%) | Chest pain, worsening myalgias, fevers, chills, nausea, vomiting, and 24 hours of worsening midline substernal burning that was worse when lying flat | 1-3 days after mRNA vaccination (2) | 2nd dose (100%) | Pfizer (100%) | Unclear |

Supplementary Table 6. Clinical data of case series and case reports (part 1) (continued...)

| Reference | Sample size | Sex (%) | Age (Median) | Previous cardiac disease history (%) | Previous other medical history (%) | Symptom | Onset of symptom (Median) | Dose (%) | Vaccine type (%) | Previous COVID-19 infection (%) |
|----------------------|-------------|--------------------------|--------------------|--|---|--|---------------------------------------|------------------------------------|-----------------------------|---------------------------------|
| Sung et al., 2021 | 2 | Male (50%); Female (50%) | 42-68 years (55) | Hypertension (50%), hyper-lipidemia (100%), coronary artery disease (100%) | Obesity (100%) | Later progressed to left-sided chest pain and shoulder pain | 1 day after mRNA vaccination (1) | 1st dose (100%) | Moderna (100%) | Unclear |
| Husnie et al., 2021 | 1 | Male (100%) | 22 years (22) | (0%) | (0%) | Sharp substernal non radiating chest pain | 3 days after mRNA vaccination (3) | 1st dose (100%) | Moderna (100%) | 6 months before symptom (100%) |
| Snagiri et al., 2021 | 7 | Male (100%) | 16-17 years (16) | (0%) | (0%) | Chest pain, headache, cough, dyspnea, diarrhea fever | 1-3 days after mRNA vaccination (2) | 1st dose (14.3%), 2nd dose (85.7%) | Pfizer (100%) | Unclear |
| Dab et al., 2021 | 1 | Male (100%) | 67 years (67) | Hypertension, hyper-lipidemia, coronary artery bypass grafting surgery, congestive heart failure with preserved ejection fraction (100%) | Type 2 diabetes mellitus, chronic obstructive pulmonary disease without any home oxygen requirement, hypothyroidism, and gastroesophageal reflux disease (100%) | Worsening shortness of breath, fever, chills, nausea, orthopnea, and also increasing fatigue | 1 day after mRNA vaccination (1 day) | 2nd dose (100%) | Moderna (100%) | (0%) |
| Navet, 2021 | 3 | Male (100%) | 20-29 years (24.5) | (0%) | (0%) | Chest pain and acute fever | 2 days after mRNA vaccination (2 day) | 2nd dose (100%) | Pfizer (100%) | Unclear |
| Ehrlich et al., 2021 | 1 | Male (100%) | 40 years (40) | (0%) | (0%) | Chest pain, shortness of breath, fever, and headache | 2 days after mRNA vaccination | 1st dose (100%) | Pfizer (100%) | (0%) |
| Kim IC et al., 2021 | 1 | Male (100%) | 24 years (24) | (0%) | (0%) | Chest pain | 1 day after mRNA vaccination (1) | 2nd dose (100%) | Pfizer (100%) | (0%) |
| Patei et al., 2021 | 5 | Male (100%) | 19-37 years (23) | (0%) | Attention-deficit hyper-activity disorder (20%), asthma (20%) | Chest pain, dyspnea, nausea, and vomiting | 1-3 days after mRNA vaccination (2) | 1st dose (20%), 2nd dose (80%) | Pfizer (80%), Moderna (20%) | (0%) |

Supplementary Table 6. Clinical data of case series and case reports (part 1) (continued...)

| Reference | Sample size | Sex (%) | Age (Median) | Previous cardiac disease history (%) | Previous other medical history (%) | Symptom | Onset of symptom (Median) | Dose (%) | Vaccine type (%) | Previous COVID-19 infection (%) |
|------------------------|-------------|--------------------------|--------------------|--|------------------------------------|--|--|--------------------------------------|-----------------------------------|---------------------------------|
| Kim HW et al., 2021 | 4 | Male (75%); Female (25%) | 23-70 years (45.5) | Hypertension (25%); hyper-cholesterolemia (25%) | (0%) | Chest pain, shortness of breath, diaphoresis, syncope/presyncope and palpitations | 1-5 days after mRNA vaccination (2.5) | 2nd dose (100%) | Pfizer (50%); Moderna (50%) | (0%) |
| Marshall et al., 2021 | 7 | Male (100%) | 14-19 years (17) | (0%) | (0%) | Chest pain, arm pain, myalgias, fatigue, weakness, subjective low-grade fevers/poor appetite (malaise), arthralgia, dry cough, sore throat, headache and shortness of breath | 2-3 days after mRNA vaccination (3) | 2nd dose (100%) | Pfizer (100%) | (0%) |
| Singh B et al., 2021 | 1 | Male (100%) | 24 years (24) | Unclear | (0%) | Chest pain | 3 days after mRNA vaccination (3) | 2nd dose (100%) | Pfizer (100%) | (0%) |
| Starckova et al., 2021 | 5 | Male (80%); Female (20%) | 17-38 years (27.5) | (0%) | (0%) | Chest pain | 2-3 days after mRNA vaccination (3) | 2nd dose (100%) | Pfizer (60%); Moderna (40%) | (0%) |
| Singh VP et al., 2021 | 1 | Male (100%) | 21 years (21) | Significant of mitral valve prolapse and resting tachy-cardia (100%) | (0%) | Chest pain fevers, nausea, and shortness of breath | 3 days after mRNA vaccination (3) | 2nd dose (100%) | Pfizer (100%) | (0%) |
| Rosner et al., 2021 | 6 | Male (100%) | 19-39 years (23.5) | Unclear | (0%) | Chest pain, fever, shortness of breath, numbness, myalgia, headache, and tingling in the left arm | 2-7 days after mRNA vaccination (3) | 1st dose (16.67%); 2nd dose (83.33%) | Pfizer (16.67%); Moderna (83.33%) | Yes (16.67%) |
| Verma et al., 2021 | 2 | Male (50%); Female (50%) | 42-45 years (43.5) | Unclear | (0%) | Chest pain, fever, dyspnea, and dizziness | 10-14 days after mRNA vaccination (12) | 1st dose (50%); 2nd dose (50%) | Pfizer (50%); Moderna (50%) | (0%) |
| Vollmann et al., 2021 | 1 | Male (100%) | 28 years (28) | Unclear | (0%) | Chest pain, fatigue, and fever | 9 days after mRNA vaccination (9) | 1st dose (100%) | Pfizer (100%) | Unclear |

Supplementary Table 7. Clinical data of case series and case reports (part 2)

| Reference | Troponin | Chest radiograph | CMR | Echocardiogram | Angiography | Electrocardiogram | Diagnosis | Length of stay in hospital (day) |
|--------------------------|--|--|--|--|---|---|---|----------------------------------|
| Shaw et al., 2021 | Troponin I was elevated to 7.961 ng/mL | Not available | CMR demonstrated normal systolic function (left ventricular ejection fraction: 54-64%) with no regional wall motion abnormalities, pericardial effusion, thickening, or enhancement. Confirmed as marked epicardial fibrosis on late gadolinium enhancement imaging, and regional interstitial expansion on extracellular volume fraction mapping (38-52%) | Not available | Not available | Electrocardiogram demonstrated subtle ST-segment elevation of the anterior limb leads | Acute myocarditis | Unclear |
| Dickey et al., 2021 | Troponin I was elevated to 38.3 ng/mL | not available | CMR demonstrated short-axis and 4-chamber views demonstrating areas of increased T2 signal and LGE | Echocardiogram showed ejection fraction 45-58% | Not available | Electrocardiogram revealed sinus rhythm with diffuse ST elevation, non-specific T wave abnormalities and PR depression; non-sustained ventricular tachycardia | CMR-proven myocarditis shortly after vaccination. | Unclear |
| McLean and Johnson, 2021 | Troponin T was elevated to 1018 ng/L | Chest radiograph showed no acute cardiopulmonary abnormality | CMR showed normal biventricular volumes, morphology, and systolic function. However, there were signs of myocardial fibrosis, myocardial hyperemia, and a small pericardial effusion consistent with myopericarditis | Echocardiogram which demonstrated normal anatomy, normal systolic function, no wall motion abnormalities, and no pericardial effusions, normal systolic function (61%), and no pericardial effusion. The right coronary artery was not well visualized | Computed tomography angiography of the heart revealed minimal lateral wall subpericardial hyperenhancement, suggestive of myocarditis. He was also noted to have an incidental benign coronary artery anomaly | Electrocardiogram revealed normal sinus rhythm with diffuse ST elevation in V2 to V6 and I and aVL | Myopericarditis | 6 days |
| Cerceda et al., 2021 | Troponin I was elevated to 6.53 ng/mL | Not available | CMR confirmed the diagnosis of myocarditis with evidence of edema and nonischemic delayed enhancement with a patchy pattern, predominantly epicardial | Echocardiogram showed normal ejection fraction with hypokinesis of the left ventricular inferior and posterior walls | Coronary angiography showed no significant stenosis or flow abnormalities | Electrocardiogram showed diffuse concave-upward ST-segment elevation | CMR-proven myocarditis shortly after vaccination | 7 days |
| Hudson et al., 2021 | Troponin I was elevated to 1.5 ng/mL | Chest radiograph was unremarkable. | Not available | Echocardiogram revealed a normal ejection fraction without any obvious abnormality | Computed tomography angiography of the chest unremarkable | Electrocardiogram showed J-point elevation in the lateral leads with slightly widened QRS complexes | Myopericarditis | 3 days |

Supplementary Table 7. Clinical data of case series and case reports (part 2) (continued...)

| Reference | Troponin | Chest radiograph | CMR | Echocardiogram | Angiography | Electrocardiogram | Diagnosis | Length of stay in hospital (day) |
|----------------------|--|--|---|---|--|--|-----------------------------|----------------------------------|
| Sung et al., 2021 | Troponin T was elevated to 1763 ng/mL | Not available | Not available | Echocardiogram showed ejection fraction 50-60% | Computed tomography coronary angiography showed a large amount of noncalcified plaque in the proximal LC artery, resulting in complete focal occlusion just proximal to the origin of first obtuse marginal artery | Electrocardiogram showed inferior ST elevation | Acute myocardial infarction | 3-7 days |
| Hasnie et al., 2021 | Troponin I was elevated to 13.7 ng/mL | Chest radiograph was unremarkable, with no signs of focal consolidation, pneumothorax, or pleural effusion | CMR showed a normal LVEF (58%) with findings of dyssynchrony of the septal wall | Echocardiogram revealed a low-normal left ventricular ejection fraction of 50-55% with mid to apical anterior and anterolateral segments appearing hypokinetic | Left heart catheterization revealed angiographically normal coronary arteries. | Electrocardiogram revealed normal sinus rhythm with diffuse ST elevation. PR segment depression was discernible in leads V3-V6 | Myopericarditis | Unclear |
| Snajiri et al., 2021 | Troponin I elevated to 137 ng/mL | Not available | Not available | Echocardiogram showed normal function, mild pericardial effusion | Not available | Electrocardiogram showed Mild ST elevation, RBBB | Myopericarditis | 4-5 days |
| Debetal., 2021 | An elevated high sensitivity troponin of 180.8 ng/L | Chest radiograph showed cardiomegaly and pulmonary edema without any focal consolidation | Not available | A transthoracic echocardiogram showed a mildly dilated left atrium, a left ventricle ejection fraction of 50%-54%, mild hypokinesia in the mid-septal and mid-anterior walls, and grade 2 diastolic dysfunction | Not available | Electrocardiogram revealed sinus tachycardia with non-specific ST/T wave changes | Acute myocardial injury | Unclear |
| Neveit, 2021 | Elevated inflammatory markers and myocardial enzymes | Not available | CMR showed myocardial edema and gadolinium enhancement of the myocardium | Echocardiogram showed normal | Not available | Electrocardiogram showed diffuse ST elevations | Acute myocarditis | Unclear |

Supplementary Table 7. Clinical data of case series and case reports (part 2) (continued...)

| Reference | Troponin | Chest radiograph | CMR | Echocardiogram | Angiography | Electrocardiogram | Diagnosis | Length of stay in hospital (day) |
|----------------------|--|------------------|---|---|---|---|-----------------------|----------------------------------|
| Ehrlich et al., 2021 | Troponin T concentration was elevated to 1030 ng/L | Not available | CMR showed a normalized left ventricular ejection fraction (69%) without regional wall motion abnormalities | Trans thoracic echocardiography in the emergency unit showed a normal sized left ventricle (end-diastolic diameter 52 mm) with a moderately reduced ejection fraction of 45% (biplane Simpson method) without regional wall motion abnormalities. The thickness of the basal septum was slightly increased to 13 mm. Pericardial effusion could be ruled out as well as a valvular heart disease. | Computed tomography angiography was normal | Electrocardiogram showed sinus rhythm with 82 beats per minute without any signs of acute ischemia | Myocarditis | 4 days |
| Kim IC et al., 2021 | Troponin I was elevated to 2.28 ng/mL | Not available | CMR showed abnormal findings compatible with acute myocarditis according to revised 2018 Lake Louise criteria: high signal intensity on T2-weighted short tau inversion recovery images, elevated T2 value on T2 mapping sequence (51 ms, normal reference value: 40 ms), and sub-epicardial pattern of late gadolinium enhancement (LGE) in basal inferior and inferolateral segment | Echocardiogram showed normal myocardial contractility and minimal amount of pericardial effusion. 2D-based global longitudinal strain (GLS) of built's map revealed the worsened strain value in basal inferior and inferolateral segments, particularly in epicardium than endocardium | Coronary computed tomographic angiography showed normal coronary arteries with no stenosis or occlusion | Electrocardiogram showed the mild ST segment elevation in leads I, II, aVF, and V2-V6 | Acute myocarditis | Unclear |
| Patel et al., 2021 | Troponin I was elevated to 37.58 pg/mL | Not available | CMR showed both subepicardial late gadolinium enhancement (LGE) and myocardial edema in the basal inferior, basal inferolateral, and apical lateral LV segments; Global longitudinal strain (GLS) by TTE and CMR was normal at -19.0% and -19.1% respectively (normal is < -18%) | Trans thoracic echocardiography showed an LVEF of 51-65% and no pericardial effusion | Invasive coronary angiography was negative for obstructive coronary artery disease | Electrocardiogram showed diffuse PR segment depression and PR segment elevation in lead aVR, consistent with acute pericarditis | Acute myopericarditis | Unclear |

Supplementary Table 7. Clinical data of case series and case reports (part 2) (continued...)

| Reference | Troponin | Chest radiograph | CMR | Echocardiogram | Angiography | Electrocardiogram | Diagnosis | Length of stay in hospital (day) |
|------------------------|---|--------------------------------|---|--|---|---|---|----------------------------------|
| Kim HW et al., 2021 | Troponin T was elevated to 598 ng/L. Troponin I was elevated to 7452 ng/L | Chest radiograph was normal | CMR showed LVFF 40-59%, regional wall motion abnormality, trace pericardial effusion, normal pericardial thickness, LGE in the apical lateral, myocardial pattern in epicardial, no pericardial enhancement | Not available | Chest CT was negative for pleural effusion | Electrocardiogram showed diffuse ST elevation, PR depression | Myocarditis | 2-4 days |
| Marshall et al., 2021 | Initial high-sensitivity troponin T 232 ng/L and CRP 6.7 mg/dL (highly elevated); Elevated troponin I (5550 ng/mL, peaked at 12.200 ng/mL) | Not available | Cardiac MRI revealed areas with high T2 values indicating edema, T1 early post-contrast heterogeneity indicating hyperemia, and late gadolinium enhancement indicating myocardial fibrosis, necrosis | Echocardiogram revealed normal function and coronaries, no effusion, trace mitral and aortic valve insufficiency, and decreased left ventricular basolateral and posterior regional strain | Not available | Electrocardiogram revealed atrioventricular dissociation with junctional escape and ST elevation; ECG revealed diffuse ST elevation consistent with acute myocardial injury or pericarditis | Suspected myocarditis; myocarditis; acute pericarditis | 3-4 days |
| Singh B et al., 2021 | High-sensitivity troponin I peak value 6,803 pg/mL | Chest radiography unremarkable | Cardiac magnetic resonance imaging (MRI) with and without contrast showed linear sub-epicardial enhancement involving the lateral wall of the left ventricle consistent with acute myocarditis | Echocardiogram showed an ejection fraction of 55% | Not available | Electrocardiogram showed normal sinus rhythm, a normal axis, 76 beats per minute, and a 1-mm ST-depression in lead III | Myocarditis | 4 days |
| Starekova et al., 2021 | Peak Troponin I: 14.65 ng/mL | Not available | MRI showed myocarditis-like findings including non-ischemic pattern of late gadolinium enhancement, corresponding signal abnormalities on T2-weighted images, and pericardial enhancement | Not available | Coronary CTA: negative | Electrocardiogram showed diffuse ST-elevations in inferior and anterolateral leads, non-specific T-wave abnormality, ST depression in aVR and V1 | Acute myocarditis | Unclear |
| Singh VP et al., 2021 | Troponins were trended, 460, 637, 832 ng/mL | Not available | Cardiac MRI showed findings suggestive of acute myocarditis | 2D echocardiogram showed Left Ventricular Ejection Fraction (LVEF) of 43%, with mildly reduced LV systolic function | CTA chest with IV contrast showed no aortic dissection, or pulmonary embolism | Electrocardiogram did not show any acute ischemic changes | Acute myocardial injury (suggestive of acute myocarditis) | Unclear |

Supplementary Table 7. Clinical data of case series and case reports (part 2) (continued...)

| Reference | Troponin | Chest radiograph | CMR | Echocardiogram | Angiography | Electrocardiogram | Diagnosis | Length of stay in hospital (day) |
|-----------------------|---|--|---|---|--|--|--------------------------------|---|
| Rosner et al., 2021 | Peak Troponin I: 44.80 ng/mL (elevated) Peak CTnt: 7000 ng/mL (elevated) | No acute process; no detectable active cardiopulmonary disease | CMR showed LVFF: 48-56%; LGE: Midmyocardial LGE in the septal and anterior walls; subepicardial LGE in the anterior, lateral, and inferior walls; no pericardial effusion | Echocardiogram showed LVEF: 35-61%, LVED internal dimension: 4.34-4.9 cm, intraventricular septal diagnostic thickness: 0.6-1.1 cm, mild global left ventricular hypokinesis; mildly decreased right ventricular function | Not available | Electrocardiogram showed normal sinus rhythm, PR depression in II, aVF, V4-V6 T wave inversion V1, no acute ST-T segment changes | Acute myocarditis-like illness | 2-4 days |
| Verma et al., 2021 | Troponin I level: 6,14 ng/mL (elevated) | Not available | Not available | Echocardiogram showed global biventricular dysfunction (ejection fraction, 15-20%), normal ventricular dimensions, and left ventricular hypertrophy. | Coronary angiography revealed no obstructive coronary artery disease | Electrocardiogram showed ST-segment depression (most prominent in the lateral leads) | Myocarditis | 3-7 days, there was one patient died because of cardiogenic shock |
| Vollmann et al., 2021 | Troponin T: 1.30 ng/mL (elevated) | Not available | CMR showed slightly reduced left ventricular pump function, myocardial edema, and subepicardial late gadolinium enhancement. | Not available | Not available | Electrocardiogram showed ST-segment elevations | Acute perimyocarditis | 4 days |

Adverse Cardiac Events Following mRNA COVID-19 Vaccination

ORIGINALITY REPORT

19%

SIMILARITY INDEX

12%

INTERNET SOURCES

16%

PUBLICATIONS

9%

STUDENT PAPERS

PRIMARY SOURCES

| | | |
|---|---|----|
| 1 | fjfsdata01prod.blob.core.windows.net Internet Source | 1% |
| 2 | Kohei Horiuchi, Shumpei Kosugi, Haruhiko Abe, Yasunori Ueda. "Fulminant myocarditis after the first dose of mRNA-1273 vaccination in a patient with previous COVID-19: a case report", <i>European Heart Journal - Case Reports</i> , 2022 Publication | 1% |
| 3 | Paolo Severino, Viviana Maestrini, Marco Valerio Mariani, Lucia Ilaria Birtolo et al. "Structural and myocardial dysfunction in heart failure beyond ejection fraction", <i>Heart Failure Reviews</i> , 2019 Publication | 1% |
| 4 | Submitted to Universitas Diponegoro Student Paper | 1% |
| 5 | www.scilit.net Internet Source | 1% |
| 6 | core.ac.uk Internet Source | 1% |

| | | |
|----|--|------|
| 7 | Submitted to Mount Carmel College of Nursing Student Paper | 1 % |
| 8 | www.scienceopen.com Internet Source | <1 % |
| 9 | www.binasss.sa.cr Internet Source | <1 % |
| 10 | Abdulla A. Damluji, Robert H. Christenson, Christopher deFilippi. "Clinical Application of Serologic Testing for Coronavirus Disease 2019 in Contemporary Cardiovascular Practice", Journal of the American Heart Association, 2021 Publication | <1 % |
| 11 | Elaheh Malakan Rad, Sara Momtazmanesh. "COVID-19-induced silent myocarditis and newly developed hypertension in a 3-year-old boy", The Egyptian Heart Journal, 2022 Publication | <1 % |
| 12 | Lucas Bacmeister, Michael Schwarzl, Svenja Warnke, Bastian Stoffers, Stefan Blankenberg, Dirk Westermann, Diana Lindner. "Inflammation and fibrosis in murine models of heart failure", Basic Research in Cardiology, 2019 Publication | <1 % |

Submitted to Adtalem Global Education, Inc.

13

Student Paper

<1 %

14

Alagarraju Muthukumar, Madhusudhanan Narasimhan, Quan-Zhen Li, Lenin Mahimainathan et al. "In-Depth Evaluation of a Case of Presumed Myocarditis After the Second Dose of COVID-19 mRNA Vaccine", *Circulation*, 2021

Publication

<1 %

15

skybrary.aero

Internet Source

<1 %

16

Xiaoxiao Liu, Minghui Li, Zhiwei Chen, Yong Yu, Hui Shi, Ying Yu, Yucheng Wang, Ruizhen Chen, Junbo Ge. "Mitochondrial calpain-1 activates NLRP3 inflammasome by cleaving ATP5A1 and inducing mitochondrial ROS in CVB3-induced myocarditis", *Basic Research in Cardiology*, 2022

Publication

<1 %

17

repository.publisso.de

Internet Source

<1 %

18

Submitted to New York College in Athens, Greece

Student Paper

<1 %

19

0-systematicreviewsjournal-biomedcentral-com.brum.beds.ac.uk

Internet Source

<1 %

20 Submitted to University of Tennessee
Chattanooga <1 %
Student Paper

21 Helen Kakkassery, Esme Carpenter, Piers E.M.
Patten, Sheeba Irshad. "Immunogenicity of
SARS-CoV-2 vaccines in patients with cancer",
Trends in Molecular Medicine, 2022 <1 %
Publication

22 eprints.ncl.ac.uk <1 %
Internet Source

23 jidc.org <1 %
Internet Source

24 mural.maynoothuniversity.ie <1 %
Internet Source

25 tede2.uepg.br <1 %
Internet Source

26 Jun Yasuhara, Kaihei Masuda, Tadao Aikawa,
Takuro Shirasu, Hisato Takagi, Simon Lee,
Toshiki Kuno. "Myopericarditis After COVID-19
mRNA Vaccination Among Adolescents and
Young Adults", JAMA Pediatrics, 2023 <1 %
Publication

27 Submitted to Milton High School <1 %
Student Paper

28 pubs.rsna.org <1 %
Internet Source

29

Paolo Bellavite, Alessandra Ferraresi, Ciro Isidoro. "Immune Response and Molecular Mechanisms of Cardiovascular Adverse Effects of Spike Proteins from SARS-CoV-2 and mRNA Vaccines", Biomedicines, 2023

Publication

<1 %

30

[bmcgeriatr.biomedcentral.com](https://www.bmcgeriatr.biomedcentral.com)

Internet Source

<1 %

31

[gloria.tv](https://www.gloria.tv)

Internet Source

<1 %

32

Fairweather, DeLisa, Leslie T. Cooper, and Lori A. Blauwet. "Sex and Gender Differences in Myocarditis and Dilated Cardiomyopathy", Current Problems in Cardiology, 2013.

Publication

<1 %

33

Submitted to Unity College

Student Paper

<1 %

34

Abdulla A Damluji, Devin Rajan, Amanda Haymond, Christopher deFilippi. "Serological Testing for COVID-19 Disease: Moving the Field of Serological Surveillance Forward", The Journal of Applied Laboratory Medicine, 2021

Publication

<1 %

35

Georgios Georgiopoulos, Stefano Figliozzi, Francesca Sanguineti, Giovanni Donato Aquaro et al. "Prognostic Impact of Late Gadolinium Enhancement by Cardiovascular

<1 %

Magnetic Resonance in Myocarditis", Circulation: Cardiovascular Imaging, 2021

Publication

36

Hao Dong, Yihang Qi, Xiangyi Kong,
Zhongzhao Wang, Yi Fang, Jing Wang. "PD-
1/PD-L1 Inhibitor-Associated Myocarditis:
Epidemiology, Characteristics, Diagnosis,
Treatment, and Potential Mechanism",
Frontiers in Pharmacology, 2022

Publication

<1 %

37

opus4.kobv.de

Internet Source

<1 %

38

ueaeprints.uea.ac.uk

Internet Source

<1 %

39

www.ucardioj.com.ua

Internet Source

<1 %

40

Yuji Yoshioka, Yohei Oshima, Koichiro Hata,
Susumu Sato et al. "Factors associated with
early postoperative exercise tolerance after
living - donor liver transplantation", Clinical
Transplantation, 2022

Publication

<1 %

41

abccardiol.org

Internet Source

<1 %

42

journals.copmadrid.org

Internet Source

<1 %

| | | |
|----|--|------|
| 43 | pulmo-ua.com Internet Source | <1 % |
| 44 | repositorio.udd.cl Internet Source | <1 % |
| 45 | www.monaldi-archives.org Internet Source | <1 % |
| 46 | Submitted to Hong Kong Baptist University Student Paper | <1 % |
| 47 | Na-Na Zhang, Xiao-Feng Li, Yong-Qiang Deng, Hui Zhao et al. "A thermostable mRNA vaccine against COVID-19", Cell, 2020 Publication | <1 % |
| 48 | Laura Ponce-Chazarri, Jose Antonio Ponce-Blandón, Palmira Immordino, Antonio Giordano, Fátima Morales. "Barriers to Breast Cancer-Screening Adherence in Vulnerable Populations", Cancers, 2023 Publication | <1 % |
| 49 | Mona Sheikh, Saumil Patel, Shavy Nagpal, Zeynep Yulkselen, Samina Zahid, Vivek Jha, Diana F Sanchez Velazco. "Analysis of Corticosteroids in Immune Checkpoint Inhibitor(ICE)Induced Myocarditis-A Systematic Review of 352 Screened Articles", Cold Spring Harbor Laboratory, 2021 Publication | <1 % |

50

Sonia Ndeupen, Zhen Qin, Sonya Jacobsen, Aurélie Bouteau, Henri Estanbouli, Botond Z. Igyártó. "The mRNA-LNP platform's lipid nanoparticle component used in preclinical vaccine studies is highly inflammatory", *iScience*, 2021

Publication

<1 %

51

Submitted to University of College Cork

Student Paper

<1 %

52

Juan Gao, Linya Feng, Yaru Li, Scott Lowe et al. "A Systematic Review and Meta-analysis of the Association Between SARS-CoV-2 Vaccination and Myocarditis or Pericarditis", *American Journal of Preventive Medicine*, 2023

Publication

<1 %

53

Submitted to Leeds Beckett University

Student Paper

<1 %

54

Tiziana Ciarambino, Ombretta Para, Mauro Giordano. "Immune system and COVID-19 by sex differences and age", *Women's Health*, 2021

Publication

<1 %

55

Diego Macías Saint-Gerons, María Teresa Ibarz, José Luis Castro, Jaume Forés-Martos, Rafael Tabarés-Seisdedos. "Myopericarditis Associated with the Novavax COVID-19

<1 %

Vaccine (NVX-CoV2373): A Retrospective Analysis of Individual Case Safety Reports from VigiBase", Drugs - Real World Outcomes, 2023

Publication

56

James J. Lucas, Stéphane L. Bouchoucha, Rojan Afrouz, Kirk Reed, Sharon L. Brennan-Olsen. "LGBTQ+ Loss and Grief in a Cis-Heteronormative Pandemic: A Qualitative Evidence Synthesis of the COVID-19 Literature", Qualitative Health Research, 2022

Publication

<1 %

57

cris.bgu.ac.il

Internet Source

<1 %

58

www.icf.fasper.bg.ac.rs

Internet Source

<1 %

59

www.mdguidelines.com

Internet Source

<1 %

60

Submitted to Ateneo de Naga University

Student Paper

<1 %

61

Bedanta Bhattacharjee, Abu Md Ashif Ikbal, Atika Farooqui, Ram Kumar Sahu et al. "Superior possibilities and upcoming horizons for nanoscience in COVID-19: noteworthy approach for effective diagnostics and management of SARS-CoV-2 outbreak", Chemical Papers, 2023

<1 %

62

Jennifer van Heerden, Jeremy Nel, Pramone Moodley, Preesha Govender et al.

"Multisystem inflammatory syndrome (MIS): a multicentre retrospective review of adults and adolescents in South Africa", International Journal of Infectious Diseases, 2021

Publication

<1 %

63

911.lsuhscc.edu

Internet Source

<1 %

64

Submitted to Kettering College of Medical Arts

Student Paper

<1 %

65

Kirk U Knowlton, Stacey Knight, Joseph B Muhlestein, Viet T Le et al. "A Small but Significantly Greater Incidence of Inflammatory Heart Disease Identified After Vaccination for Severe Acute Respiratory Syndrome Coronavirus 2", Open Forum Infectious Diseases, 2022

Publication

<1 %

66

S. Kristen Sexson Tejtel, Flor M. Munoz, Iyad Al-Ammouri, Fabio Savorgnan et al.

"Myocarditis and pericarditis: Case definition and guidelines for data collection, analysis, and presentation of immunization safety data", Vaccine, 2022

Publication

<1 %

67

Shadi Asadollahi, Liesl S. Eibschutz, Sanaz Katal, Vorada Sakulsaengprapha et al. "Post - COVID - 19 Vaccine Imaging Findings", Wiley, 2023

Publication

<1 %

68

Submitted to Sotogrande International School

Student Paper

<1 %

69

González de los Ángeles Vivian. "Evolución de COVID-19 en los recién nacidos con Síndrome Inflamatorio Multisistémico Neonatal (SIM-N) con infección temprana", TESIUNAM, 2023

Publication

<1 %

70

Weiqin Lin, Alfred Chung Lum Yip, Lauren Kay Mance Evangelista, Raymond Ching Chiew Wong et al. "Ventricular tachycardia from myocarditis following COVID - 19 vaccination with tozinameran (BNT162b2, Pfizer - BioNTech)", Pacing and Clinical Electrophysiology, 2022

Publication

<1 %

71

Wern Hann Ng, Thomas Tipih, Nigel A. Makoah, Jan-G Vermeulen et al. "Comorbidities in SARS-CoV-2 Patients: a Systematic Review and Meta-Analysis", mBio, 2021

Publication

<1 %

72

backend.orbit.dtu.dk

Internet Source

<1 %

73

books.ksplibrary.org

Internet Source

<1 %

74

scholar.sun.ac.za

Internet Source

<1 %

75

Duque Montoya Omar Andrés. "Hallazgos por tomografía de tórax en pacientes con COVID-19 y clínica de SDRA moderado-severo en el Hospital Juárez de México", TESIUNAM, 2020

Publication

<1 %

76

Mohammed Ali, Haaris A. Shiwani, Mohammed Y. Elfaki, Moaz Hamid et al. "COVID-19 and myocarditis: a review of literature", The Egyptian Heart Journal, 2022

Publication

<1 %

77

arro.anglia.ac.uk

Internet Source

<1 %

78

jeffreydachmd.com

Internet Source

<1 %

79

researchpad.co

Internet Source

<1 %

80

scholarlycommons.hcahealthcare.com

Internet Source

<1 %

81

0-www-mdpi-com.brum.beds.ac.uk

Internet Source

<1 %

82

Alfredo Parra-Lucares, Luis Toro, Sebastián Weitz-Muñoz, Cristóbal Ramos.

"Cardiomyopathy Associated with Anti-SARS-CoV-2 Vaccination: What Do We Know?", *Viruses*, 2021

Publication

<1 %

83

Allison Krug, Josh Stevenson, Tracy Beth Høeg. "BNT162b2 Vaccine - Associated Myo/Pericarditis in Adolescents: A Stratified Risk - Benefit Analysis", *European Journal of Clinical Investigation*, 2022

Publication

<1 %

84

Bibhuti B. Das, Utkarsh Kohli, Preeti Ramachandran, Hoang H. Nguyen et al. "Myopericarditis following mRNA COVID-19 Vaccination in Adolescents 12 through 18 Years of Age", *The Journal of Pediatrics*, 2021

Publication

<1 %

85

David W. Louis, Marwan Saad, Shilpa Vijayakumar, Suleman Ilyas, Aravind Kokkiralala, Herbert D. Aronow. "The Cardiovascular Manifestations of COVID-19", *Cardiology Clinics*, 2022

Publication

<1 %

86

Déborah Foltran, Clément Delmas, Clara Flumian, Pierre De Paoli et al. "Myocarditis and Pericarditis in Adolescents after First and Second doses of mRNA COVID-19 Vaccines", European Heart Journal - Quality of Care and Clinical Outcomes, 2021

Publication

<1 %

87

Fuentes Morales María Reyna. "Ratas macho normales y rápidas en competencia : consecuencias en la conducta y el eyaculado durante la cópula regulada por la hembra", TESIUNAM, 2021

Publication

<1 %

88

Jiaxin Chen, Yuangui Cai, Yicong Chen, Anthony P. Williams, Yifang Gao, Jinsheng Zeng. "Nervous and Muscular Adverse Events after COVID-19 Vaccination: A Systematic Review and Meta-Analysis of Clinical Trials", Vaccines, 2021

Publication

<1 %

89

Marta Trius - Soler, Dimitri A. Santillán - Alarcón, Miriam Martínez - Huélamo, Rosa M. Lamuela - Raventós et al. "Effect of physiological factors, pathologies, and acquired habits on the sweet taste threshold: A systematic review and meta - analysis", Comprehensive Reviews in Food Science and Food Safety, 2020

<1 %

90

Nicola Galea, Giulia Cundari, Emanuele Di Dedda, Cristina Chimenti et al. "Short term outcome of myocarditis and pericarditis following COVID-19 vaccines:a cardiac magnetic resonance imaging study", The International Journal of Cardiovascular Imaging, 2023

Publication

<1 %

91

Rosa Morello, Mara Pepe, Laura Martino, Ilaria Lazzareschi, Antonio Chiaretti, Antonio Gatto, Antonietta Curatola. " - 19 review shows that benefits of vaccinating children and adolescents appear to outweigh risks of post - vaccination myopericarditis ", Acta Paediatrica, 2022

Publication

<1 %

92

Submitted to University of Malta

Student Paper

<1 %

93

archiv.ub.uni-marburg.de

Internet Source

<1 %

94

ashmedai.substack.com

Internet Source

<1 %

95

repository.tudelft.nl

Internet Source

<1 %

96

www.lareb.nl

Internet Source

<1 %

| | | |
|-----|---|------|
| 97 | www.smj.org.sg Internet Source | <1 % |
| 98 | Hind A. ElSawi, Ahmed Elborollosy. "Immune-mediated adverse events post-COVID vaccination and types of vaccines: a systematic review and meta-analysis", The Egyptian Journal of Internal Medicine, 2022 Publication | <1 % |
| 99 | Justin Marley, Nisha Marley. "Characterising COVID-19 as a Viral Clotting Fever: A Mixed Methods Scoping Review", Cold Spring Harbor Laboratory, 2020 Publication | <1 % |
| 100 | "Sports Cardiology", Springer Science and Business Media LLC, 2021 Publication | <1 % |
| 101 | Aline Yen Ling Wang. "Modified mRNA-Based Vaccines Against Coronavirus Disease 2019", Cell Transplantation, 2022 Publication | <1 % |
| 102 | Brijesh Sathian, Mohammad Asim, Indrajit Banerjee, Bedanta Roy et al. "Development and implementation of a potential coronavirus disease 2019 (COVID-19) vaccine: A systematic review and meta-analysis of vaccine clinical trials", Nepal Journal of Epidemiology, 2021 Publication | <1 % |

103 Martina Patone, Xue W. Mei, Lahiru Handunnetthi, Sharon Dixon et al. "Risk of Myocarditis After Sequential Doses of COVID-19 Vaccine and SARS-CoV-2 Infection by Age and Sex", *Circulation*, 2022

Publication

<1 %

104 Marwan ElBagoury, Mahmoud M. Tolba, Hebatallah A. Nasser, Abdul Jabbar, Amy Hutchinson. "The find of COVID-19 vaccine: Challenges and opportunities", *Journal of Infection and Public Health*, 2020

Publication

<1 %

105 Massimo Imazio, Monica Andriani, Luisa Lobetti Bodoni, Fiorenzo Gaita. "Chapter 6 Myocarditis", Springer Science and Business Media LLC, 2019

Publication

<1 %

106 Raffaella Mormile. "Myocarditis and pericarditis following mRNA COVID-19 vaccination in younger patients: is there a shared thread?", *Expert Review of Cardiovascular Therapy*, 2022

Publication

<1 %

107 Wu He, Ling Zhou, Ke Xu, Huihui Li, James Jiqi Wang, Chen Chen, DaoWen Wang. "Immunopathogenesis and immunomodulatory therapy for myocarditis", *Science China Life Sciences*, 2023

<1 %