

Multidiscipline management of giant reccurent nasopharyngeal angiofibroma which extends to paranasal sinuses, orbita, and intracranial in adult

by Achmad Chusnu Romdhoni

Submission date: 04-Apr-2023 06:39AM (UTC+0800)

Submission ID: 2055030364

File name: Multidiscipline_management_of_giant_reccurent_nasopharyngeal.pdf (2.91M)

Word count: 3321

Character count: 18945



ELSEVIER

Contents lists available at ScienceDirect

International Journal of Surgery Case Reports

journal homepage: www.elsevier.com/locate/ijscr

Case report

Multidiscipline management of giant recurrent nasopharyngeal angiofibroma which extends to paranasal sinuses, orbita, and intracranial in adult



Yoga Rahmadiyanto, Achmad Chusnu Romdhoni*

Department of Otorhinolaryngology Head and Neck Surgery, Faculty of Medicine, Universitas Airlangga – Dr. Soetomo General Academic Hospital, Surabaya, Indonesia

ARTICLE INFO

Keywords:

Case report
Multidisciplinary management
Nasopharyngeal Angiofibroma
Disease
Lateral Rhinotomy
Intracranial
Recurrent

ABSTRACT

Nasopharyngeal angiofibroma (NA) is a benign, slowly growing tumour that affects males in their early puberty, and rarely men over 25 years of age. There was an interesting case of a giant recurrent NA in a 62-year-old male, which is challenging to manage due to wide tumour expansion to paranasal sinuses, orbital and intracranial. In cases of large angiofibromas disease, preoperative embolization should be performed to prevent profuse bleeding. Wide expansion of NA can cause post extirpation large defects of the tumour so that optimal defect closure techniques are needed to restore the aesthetics and function of the disturbed organs. This case's diagnosis and management of this disease was carried out by multidisciplinary discussion, and surgical extirpation of the joint tumour was performed in Dr. Soetomo General Academic Teaching Hospital. The tumour was removed by medial maxillectomy with an extended Killian right lateral rhinotomy approach followed by tumour defects reconstruction. The follow up showed that there were still tumour residue and suspicious intracranial abscess, but the patient had no complaint during follow-up for ten months after surgery.

1. Introduction

Nasopharyngeal angiofibroma (NA) is a benign mesenchymal tumour consisting of vascular proliferation in cells, dense collagenous stroma, and generally originating from the nasopharynx. Nasopharyngeal angiofibroma is a rare case commonly found in men aged 10–25 years and rarely above 25 years. The incidence includes 0.05%–0.5% of all head and neck tumours, with nasal obstruction and epistaxis as the main complaints [1]. Angiofibromas are highly vascular, locally aggressive, but histologically benign tumours [2]. It can invade intracranial, which is reported in 10%–36% of cases [3]. Nasopharyngeal angiofibroma surgery was performed with several surgical approaches, including transpalatal, lateral rhinotomies, sublabial rhinotomies (sublabial mid-facial degloving), frontotemporal craniotomy, or transnasal endoscopy [4]. After the surgery, there are recurrence rate of NA is approximately 14.5% to 20.6% [5]. The purpose of this paper is to report a case of multidisciplinary management of a recurrent giant NA that extends to the paranasal sinuses, orbit, and intracranial. This work has been reported in line with the SCARE criteria [6].

2. Case report

A 62-year-old male patient in Dr. Soetomo General Academic Teaching Hospital came with complaints of bilateral nasal obstruction, anosmia, nasal discharge, nasal bleeding, and nasal voice for 12 months. Accompanied by mass in both nasal cavities, easy to bleed, bilateral hearing decrease, blurred vision of both right and left eyes. The patient has had difficulty swallowing solid food for one month before admitted.

There was a medical history of recurrent bilateral nasal cavities masses for 15 years. He underwent twelve endoscopic mass removal operations. Some operations showed different histopathological results; there were nasal polyps and NA.

On examination, masses came out and covered entire both nasal cavities. The soft palate bulging was visible in the throat as an impression of upward pressure. The right and left eyes protruded laterally (Fig. 1).

Then the patient underwent biopsy at the inner part of tumour which came out from nostrils and the histological result showed a benign spindle mesenchymal tumour, suspicious for angiofibroma. The immunohistochemistry results showed positive CD34 in the tumour

* Corresponding author at: Department of Otorhinolaryngology Head and Neck Surgery, Faculty of Medicine, Universitas Airlangga – Dr. Soetomo General Academic Hospital, Street of Mayjen Prof. Dr. Moestopo number 6-8, Airlangga, Gubeng, Surabaya, East Java 60286, Indonesia.

E-mail address: romdhoni-a-c@fk.unair.ac.id (A.C. Romdhoni).

<https://doi.org/10.1016/j.ijscr.2022.107579>

Received 18 July 2022; Received in revised form 28 August 2022; Accepted 28 August 2022

Available online 7 September 2022

2210-2612/© 2022 The Authors. Published by Elsevier Ltd on behalf of IJS Publishing Group Ltd. This is an open access article under the CC BY-NC-ND license (<http://creativecommons.org/licenses/by-nc-nd/4.0/>).

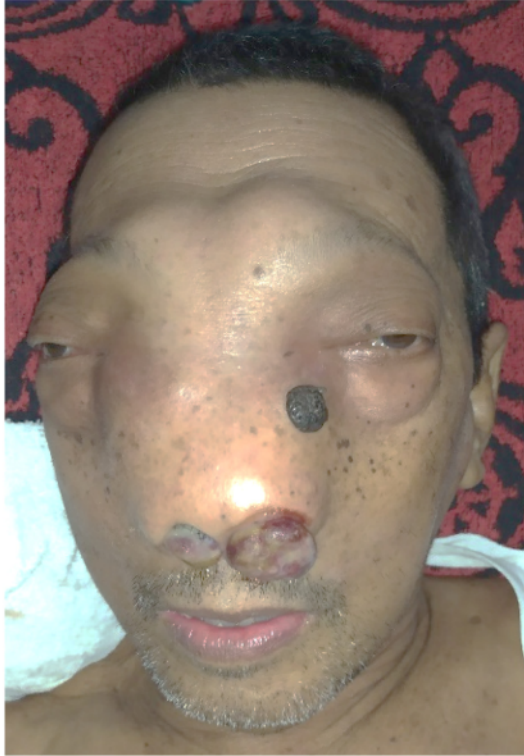

Fig. 1. Clinical features, the tumour came out of the left nostril and the right eyeball protruded.

cytoplasm, while S100 and CD117 were negative in tumour cells, so it was concluded that the tumour was an angiofibroma.

Computed tomography angiography 2 months before joint surgery showed a solid lesion (31 HU) occupied both the nasal cavities and the all paranasal sinuses, destroyed the nasal bone, anterior alveolar process, anterior fascia of the maxillary bone, extend to masticator space, nasopharyngeal space, mucosal pharyngeal space, retropharyngeal space, sticking to both temporalis muscles, destroyed lamina papyracea and forced both eye bulbs anterolaterally. In addition, the superior extension caused the destruction of the cribriform plate and filled the subdural space of the frontal region, and attached to the sulcus of the

frontal lobe, suggesting that it was vascularized from the right and left external carotid artery (ECA) branches (Fig. 2).

A multidisciplinary team is needed to manage giant NA that extends to the paranasal sinuses, the orbit till the skull base because the tumour must be completely resected. Multidisciplinary discussion by ORL-HNS doctor, Ophthalmologist, Neurosurgeon, and Plastic Reconstructive & Aesthetic Surgeon in Dr. Soetomo General Academic Teaching Hospital decided that the patient would undergo joint surgery. At first, 48 h before joint surgery, the patients underwent Trans Femoral Cerebral Angiography (TFCA) and embolization. From internal carotid artery (ICA) and ECA angiographies, there were found that the blush tumour originates from the right and left internal maxillary arteries and ophthalmic arteries. Subsequently, the right and left inner maxillary arteries were embolized using polyvinyl alcohol (PVA) 125–250 μ m through the right femur and then fixated for 8 h.

The multidisciplinary surgeon team removed the tumour and began with an ORL-HNS doctor performing a medial maxillectomy with an extended Killian right lateral rhinotomy approach to extract the tumours on the nasal cavities-sinonasal-nasopharynx until dura mater of the frontal sinus area. The Neurosurgeon continued tumour resection in the front-basal region and then closed the dura mater defect with fascia lata, taken from the left femoral region. The fascia lata was also used by an ophthalmologist to correct orbital prolapse after doing excision of the right and left orbital cavity tumour. Plastic Reconstructive & Aesthetic Surgeon performed reconstruction on defects in the medial wall of the right and left maxillary sinuses using polypropylene mesh. The total defect was approximately 7 \times 5 cm (Fig. 3).

The operation lasts for 10 h and the amount of bleeding during surgery in this patient was 1500 ml and he had fluid replacement and blood transfusion during surgery. The histopathological results from surgery showed mesenchymal spindle tumour was impressively benign with a differential diagnosis of solitary fibrous tumour, neurofibroma, cellular schwannoma, and angiofibroma. The patient was discharged five days after surgery. Then follow up was made at one week, one month, three months and ten months after surgery. The patient is still under surveillance, shows nasal crusting and had nasal wash therapy, no nasal obstruction and could carry out daily activities.

3. Discussion

Nasopharyngeal angiofibroma is rare in adult, a study in Poland for 50 years (1953–2002) reported the incidence of NA in adult male patients were 35 cases and patients aged over 30 years old only amounted to 3 cases out of 36 subjects [7]. The oldest NA patient was reported by Conley, et al. (1968) who was 79 years old [5]. Nasopharyngeal angiofibroma that extends intracranially may undergo postoperative

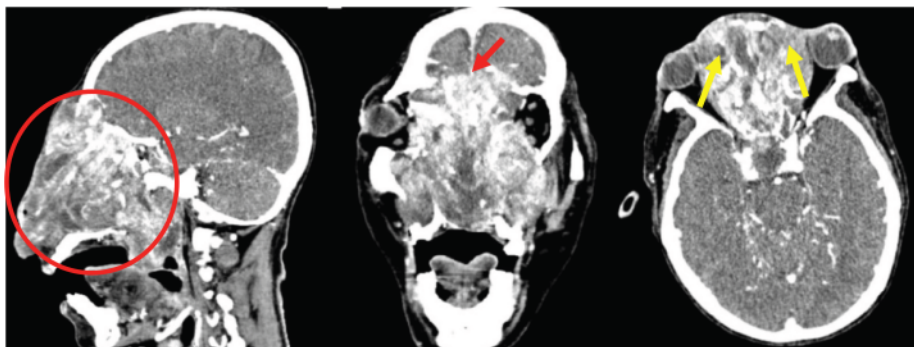


Fig. 2. CT angiography. (a) Sagittal section: tumour at the nasal cavities (red circle); (b) coronal section: tumour destructed the cribriform plate and occupied the subdural space of the frontal region (red arrow); (c) axial section: tumour pushed left and suitable bulbs oculi laterally (yellow arrow). (For interpretation of the references to colour in this figure legend, the reader is referred to the web version of this article.)

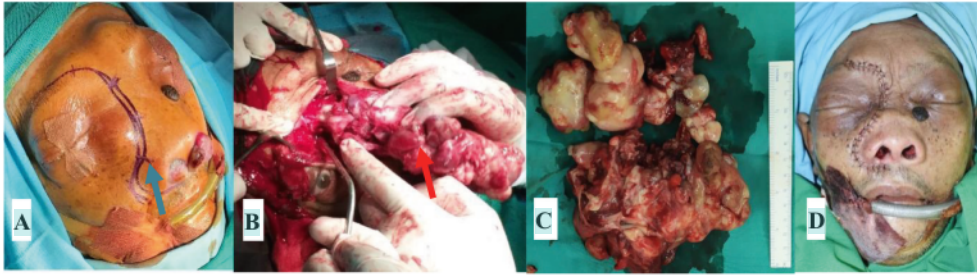

Fig. 3. Medial maxillectomy surgery with an extended Killian right lateral rhinotomy approach. (a) Killian incision groove (blue arrow); (b) tumour was well-defined, with a chewy solid consistency, easy to bleed (red arrow); (c) The tumour's size was 12.5 × 8.7 × 5.5 cm, weighed 258 g; (d) surgical wound closure. (For interpretation of the references to colour in this figure legend, the reader is referred to the web version of this article.)

recurrence due to residual tumour as by Fagan, et al. reported 37.5 % recurrence NA after surgical excision [8].

In this case, before joint surgery, preoperative embolization was performed on the right and left inner maxillary arteries using PVA foam particle agent. This agent produces non-absorbing occlusion, might aggregate proximally in the targeted arteries and cause less ulceration [9]. The embolization was generally performed 24–72 h before surgery to reduce intraoperative bleeding [5]. However, the left and right ophthalmic arteries supplying the tumour were left intact because embolization in that area could block the vascularity of the orbits and impair vision. Ballah D et al. reported that the amount of bleeding from NA extraction without embolization is about 915–3000 ml, compared to approximately 450 ml [3]. In this case, the amount of bleeding during the operation could be caused by the large size of the tumour, the blood vascularization from the ECA and ICA, and the long operation time.

Treatment options for NA are surgical, either open or endoscopic surgery and non-surgical including hormone therapy, radiotherapy and chemotherapy in cases that extend to the orbit and intracranial. In order to avoid tumour residues, especially those that extend to the infratemporal, parapharyngeal space, open surgery is required [10]. In our case, the complexities were because the tumour had massive anterior superior and lateral extension so that we decided to perform joint open surgery and choosing medial maxillectomy surgery with an extended Killian right lateral rhinotomy approach. The extended Killian lateral rhinotomy approach provides good visual access to the tumour especially for reaching tumour in the ethmoid sinus, orbits and intracranial. The approach of the surgery incision is largely determined by the stage of the tumour so that the approach used must be able to visualize the whole tumour to facilitate the optimal tumour extraction [11].

Most tumours could be removed with a smooth and gentle motion (without violence). The other difficult condition, the tumour teared and adhered to the dura mater so that it must be taken pieces by pieces and carefully to prevent CSF leakage. The tumour, in this case, was more prominent than giant NA with a size of 4.9 × 4.7 × 4.1 cm that as reported by Yuce S et al. and others with a size of 6 × 7 × 8 cm that was written by Yi ZX, et al. [12,13]. Optimal defect closure techniques are needed to restore the aesthetics and function of the disturbed organs [14,15]. The defect reconstruction on the dura mater and the medial orbital wall used fascia lata which was fixed with sutures. Then the defect of the nasal cavities, bilateral wall maxillary sinuses used polypropylene mesh which fixed to surrounding mucosal at sinonasal area. The application of polypropylene mesh is usually used for hernia surgery, anterior abdominal wall plaster, and internal organ fixation. Mesh endoprosthesis is flexible, elastic, stable for fluids and blood, and medium for blood vessel development and integration with surrounding tissues. A connective tissue barrier will appear after the healing process occurs. In addition, polypropylene mesh material also has other advantages in that it has no cancerous effect on the tissue [16].

Some advanced NA that extends widely even to intracranial like this case require multidisciplinary management of the head and neck surgical team and others. Naraghi, et al. reported case series on the multidisciplinary therapy of 6 patients with advanced NA with intracranial extension underwent both open surgery and endoscopic surgery by rhinosurgeon and neurosurgeon [17]. Renkonen, et al. reported 27 patients with NA who underwent multidisciplinary therapy by the head and neck surgical team, neurosurgery, pathologist and radiotherapist with various combinations of therapies including open surgery, endoscopic surgery, embolization and radiotherapy [18].

The postoperative histopathological result showed tumours were arranged diffusely in partly in long fascicles that intersect (perpendicular), consisting of proliferation of nucleated cells round oval to wavy spindle, chromatin smooth, cytoplasm elongated, among them there were proliferation and dilatation of capillaries with areas of bleeding. The result concluded a benign mesenchymal spindle tumour with a differential diagnosis of solitary fibrous tumour, neurofibroma cellular schwannoma, and angiofibroma. Angiofibroma is a commonly well-circumscribed tumour, localized in the superficial soft tissue and characterized by bland spindle-shaped cells arranged within vessels [2]. The patient was advised to undergo an immunohistochemical examination to establish a tumour diagnosis, but this was not done due to constraints on equipment and family considerations related to the Covid-19 pandemic. Before surgery, the immunohistochemical analysis from tumour biopsy showed positive CD34, while S100 and CD117 were negative in order to it was confirmed angiofibroma. Actually, angiofibromas will reveal positive CD34 in vascular endothelial cells, positive vimentin in stromal cells, and positive actin in smooth muscle cells around the vascular space [19,20].

4. Conclusions

Nasopharyngeal angiofibroma (NA) is a benign but locally aggressive tumour and rarely appears in adults. Although it is rare, NA should not be disregarded in elderly patients. Histopathological tests showed different results before surgery. The surgical technique chosen is embolization, MMRL and facial reconstruction through joint surgery ORL-HNS, Ophthalmologist, Neurosurgeon, and Plastic Reconstructive & Aesthetic Surgeon because of the large size of the tumour and has spread aggressively to the intracranial and many blood vessels involved.

Evaluation of the results of surgery and recurrence events has been carried out for 10 months postoperatively and there are no complaints, and the patient can carry out activities as usual.

Funding

This work was partially supported by the Department of Otolaryngology, Head and Neck Surgery, Dr. Soetomo General Academic

Teaching Hospital. Case reported in this publication was supported by Faculty of Medicine, Universitas Airlangga. The content is solely the responsibility of the authors.

Ethical approval

The study is exempt from review by the Ethics Committee of Dr. Soetomo General Academic Teaching Hospital No. 1486/110/4/VI/2022 based on the basis that this type of study is human subject research, and pursued the need for informed consent.

Consent

Written informed consent was obtained from the patient at Dr. Soetomo General Academic Teaching Hospital for publication of this case report and accompanying images. A copy of the written consent will be available for review by the Editor-in-Chief of this journal on request.

Author contribution

1. Conception and design of study: YR, ACR
2. Identified and/or managed the case(s): YR, ACR
3. Acquisition of data: YR, ACR
4. Analysis and/or interpretation of data: YR, ACR
5. Writing the final manuscript: YR, ACR

Note: The corresponding author has equally contributed as first author.

Registration of research studies

1. Name of the registry: The study protocol was approved by RSUP Dr. Soetomo
2. Unique identifying number or registration ID: 1486/110/4/VI/2022
3. Hyperlink to your specific registration (must be publicly accessible and will be checked):

Guarantor

The guarantor of this manuscript is the same as the corresponding author (ACR: Achmad Chusnu Romdhoni). He is also the Principal Investigator or Senior Researcher who will be responsible for the study supervision.

Declaration of competing interest

The authors report no conflicts of interest.

Acknowledgment

The authors would like to thank them for the invaluable assistance provided to them by Mentors, Seniors, and all members of Ceria and Resident of ORL-HNS Medical Faculty of Universitas Airlangga, Dr.

Soetomo General Academic Teaching Hospital Surabaya, East Java, Indonesia, in the management of the patient and the preparation of this paper for presentation and publication.

References

- [1] V. Parikh, C. Hennemeyer, Microspheres embolization of juvenile nasopharyngeal angiofibroma in an adult, *Int. J. Surg. Case Rep.* 5 (2014) 1203–1206, <https://doi.org/10.1016/j.ijscr.2014.10.019>.
- [2] A. Nabila, N.P.M. Sumarta, O. Prasetyo, A rare case of angiofibroma mimicking fibrous epulis in posterior gingival mucosa, *Acta Med. Philipp.* 55 (2021) 823–826, <https://doi.org/10.47895/AMP.V55I8.2128>.
- [3] D. Ballah, et al., Preoperative angiography and external carotid artery embolization of juvenile nasopharyngeal angiofibromas in a tertiary referral paediatric centre, *Clin. Radiol.* 68 (2013) 1097–1106, <https://doi.org/10.1016/j.crad.2013.05.092>.
- [4] V. Rupa, S.E. Mani, S. Backianathan, V. Rajshekhkar, Management and outcome in patients with advanced juvenile nasopharyngeal angiofibroma, *J. Neurol. Surg. Skull Base* 79 (2018) 353–360, <https://doi.org/10.1055/s-0037-1608658>.
- [5] V.C. Stubbs, et al., Nasopharyngeal angiofibroma: a forgotten entity in older patients, *Clin. Med. Insights Case Rep.* 12 (2019), <https://doi.org/10.1177/1179547619841062>.
- [6] R.A. Agha, et al., The SCARE 2020 guideline: updating consensus Surgical Case Report (SCARE) guidelines, *Int. J. Surg.* 84 (2020) 226–230, <https://doi.org/10.1016/j.ijssu.2020.10.034>.
- [7] M. Lukomski, M. Danilewicz, A. Pajor, Naczyniakowłókniak młodzieńcy u dorosłych, *Otolaryngol. Pol.* 62 (2008) 20–26, [https://doi.org/10.1016/s0030-6657\(08\)70203-8](https://doi.org/10.1016/s0030-6657(08)70203-8).
- [8] S. Mallick, R. Benson, S. Bhasker, B.K. Mohanti, Long-term treatment outcomes of juvenile nasopharyngeal angiofibroma treated with radiotherapy, *Acta Otorhinolaryngol. Ital.* 35 (2015) 75–79.
- [9] J.M. Kim, et al., Bariatric arterial embolization with non-spherical polyvinyl alcohol particles for ghrelin suppression in a swine model, *Cardiovasc. Interv. Radiol.* 40 (2017) 744–749, <https://doi.org/10.1007/s00270-017-1600-x>.
- [10] R. Meher, N. Arora, E.K. Bhargava, R. Juneja, Massive juvenile nasopharyngeal angiofibroma: ode to the open surgical approach, *BMJ Case Rep.* 2017 (2017), <https://doi.org/10.1136/bcr-2016-218731>.
- [11] H.K. Ginting, N. Supriana, Angiofibroma nasofaring juvenil, *Radioter. Onkol. Indones.* 9 (2018) 29–33, <https://doi.org/10.32532/jori.v9i1.73>.
- [12] S. Yüce, et al., A giant juvenile nasopharyngeal angiofibroma, *J. Craniofac. Surg.* 24 (2013) e207–e209, <https://doi.org/10.1097/SCS.0b013e318268cf2e>.
- [13] Z.X. Yi, et al., Huge nasopharyngeal angiofibroma with intracranial extension: change in the dura mater and choice of surgical management, *J. Laryngol. Otol.* 121 (2007) 1108–1112, <https://doi.org/10.1017/S0022215107005737>.
- [14] B.S. Santoso, C.D. Novastuti, Upper lip reconstruction after lip cancer wide excision, *Folia Med. Indones.* 55 (2021), <https://doi.org/10.20473/fmi.v55i2.24631>, 147–147.
- [15] F. Helmi, B.S. Santoso, Blowout fracture complex type, *Folia Med. Indones.* 55 (2021), <https://doi.org/10.20473/fmi.v55i1.24438>, 74–74.
- [16] V. Malanchuk, V. Efisko, I. Logvynenko, N. Efisko, Polypropylene mesh implant and a-Prf membrane for reconstruction of the traumatic defects of the lateral and back wall of the maxillary sinus, *EUREKA Health Sci.* 1 (2017) 51–57, <https://doi.org/10.21303/2504-5679.2017.00280>.
- [17] M. Naraghi, H. Saberi, A.S. Mirmohseni, M.S. Nikdad, M. Afarideh, Management of advanced intracranial intradural juvenile nasopharyngeal angiofibroma: combined single-stage rhinosurgical and neurosurgical approach, *Int. Forum Allergy Rhinol.* 5 (2015) 650–658, <https://doi.org/10.1002/alr.21507>.
- [18] S. Renkonen, et al., The changing surgical management of juvenile nasopharyngeal angiofibroma, *Eur. Arch. Otorhinolaryngol.* 268 (2011) 599–607, <https://doi.org/10.1007/s00405-010-1383-z>.
- [19] B.S. Tyagi, Extranasopharyngeal angiofibroma of the nasal septum in an elderly postmenopausal female: a very rare presentation, *Otorhinolaryngol. Clin.* 10 (2018) 39–41, <https://doi.org/10.5005/jp-journals-1003-1287>.
- [20] C. Sánchez-Romero, et al., Nasopharyngeal angiofibroma: a clinical, histopathological and immunohistochemical study of 42 cases with emphasis on stromal features, *Head Neck Pathol.* 12 (2018) 52–61, <https://doi.org/10.1007/s12105-017-0824-z>.

Multidiscipline management of giant recurrent nasopharyngeal angiofibroma which extends to paranasal sinuses, orbita, and intracranial in adult

ORIGINALITY REPORT

9%

SIMILARITY INDEX

10%

INTERNET SOURCES

8%

PUBLICATIONS

7%

STUDENT PAPERS

PRIMARY SOURCES

1	www.thieme-connect.com Internet Source	2%
2	www.binasss.sa.cr Internet Source	2%
3	research.gums.ac.ir Internet Source	1%
4	coek.info Internet Source	1%
5	www.hoajonline.com Internet Source	1%
6	cyberleninka.org Internet Source	1%
7	docplayer.net Internet Source	1%
8	pubannotation.org Internet Source	1%

Exclude quotes Off

Exclude matches < 17 words

Exclude bibliography On