

# Effect ropivacaine infiltration in incisional wound on caspase-3 expression and apoptosis squamous cells wound healing

*by Abdurrahman Abdurrahman*

---

**Submission date:** 08-Sep-2022 12:10PM (UTC+0800)

**Submission ID:** 1894890072

**File name:** pase-3\_expression\_and\_apoptosis\_squamous\_cells\_wound\_healing.pdf (361.11K)

**Word count:** 3192

**Character count:** 17610

**How to Cite:**

Abdurrahman, A., Airlangga, P. S., & Susilo, I. (2022). Effect ropivacaine infiltration in incisional wound on caspase-3 expression and apoptosis squamous cells wound healing. *International Journal of Health Sciences*, 6(S4), 1312–1320. <https://doi.org/10.53730/ijhs.v6nS4.6148>

# Effect ropivacaine infiltration in incisional wound on caspase-3 expression and apoptosis squamous cells wound healing

**Abdurrahman**

Anesthesiology and Reanimation Department of Medical Faculty of Universitas Airlangga / Soetomo General Hospital, Surabaya, Indonesia  
Email: [ma2nnis@yahoo.com](mailto:ma2nnis@yahoo.com)

**Prananda S. Airlangga**

Anesthesiology and Reanimation Department of Medical Faculty of Universitas Airlangga / Soetomo General Hospital, Surabaya, Indonesia  
Email: [prananda-s-a@fk.unair.ac.id](mailto:prananda-s-a@fk.unair.ac.id)

**Imam Susilo**

Anatomical Pathology Department of Medical Faculty of Universitas Airlangga / Soetomo General Hospital, Surabaya, Indonesia  
Email: [imam-susilo@fk.unair.ac.id](mailto:imam-susilo@fk.unair.ac.id)

**Abstract**--Wound healing and tissue regeneration consist of molecular and cellular process that occur right after wound formation. The intrinsic pathway of apoptosis, apoptosome produced to initiate the formation of Caspase 3 important role in apoptosis. One of the methods that accelerates wound healing process by eliminating pain by infiltration of local anesthesia. This study aims to determine the effect of ropivacaine infiltration as local anaesthesia in the expression of Caspase 3 and apoptosis. This study is an experimental study with randomized post-test only control group design. The samples of this study were 24 wistar rats. The rats divided into four groups then incised, either followed by 1 ml ropivacaine 0.2% infiltration or left as is. Excisional biopsy procedures were done on third and seventh day. Then analyzed by SPSS. Expression of Caspase 3 on squamous cell epithel of control and intervention group was found statistically different on day 3 ( $p=0.024$ ) and day 7 ( $p=0.041$ ). Number of apoptosis on squamous cell epithel of control and intervention was found statistically different on day 7 ( $p=0.031$ ) but not on day 3 ( $p=0.414$ ). Ropivacaine infiltration on incision wound decreased the expression of Caspase 3 on day 3 and 7; and apoptosis on day 7.

---

International Journal of Health Sciences ISSN 2550-6978 E-ISSN 2550-696X © 2022.

**Corresponding author:** Susilo, I.; Email: [imam-susilo@fk.unair.ac.id](mailto:imam-susilo@fk.unair.ac.id)

Manuscript submitted: 27 Feb 2022, Manuscript revised: 18 March 2022, Accepted for publication: 09 April 2022

**Keywords**---Ropivacaine, Local Anesthesia, Caspase 3, Apoptosis, Wound Healing.

## Introduction

Wound is a break in continuity of a tissue in human anatomy and a disturbance in tissue integrity that is caused by trauma, that can also be due to a surgical procedure (Enoch et al., 2008). Wound healing and tissue regeneration consist of molecular and cellular process that occur right after wound formation (Gonzalez et al., 2016). Cell death, especially apoptosis of squamous cells, is seen in the wound healing process of incision wound. Apoptosis consists of intrinsic and extrinsic pathways. Intrinsic pathway of apoptosis is controlled by mechanisms in mitochondria organelle and membrane which outcome is the release of Cytochrome c that interacts with APAF-1 and Caspase-9 and produce apoptosome. Apoptosome initiates the formation of Caspase 3 from Pro-caspase 3 that plays an important role in apoptosis (Ferreira et al., 2012).

Analgetic drugs such as Non Steroid Anti Inflammatory Drug (NSAID) that are administered on wound healing phases showed non satisfactory result in reducing pain after wound formation, therefore multimodal analgesics are needed to accelerate wound healing. One of the methods that accelerates wound healing process is by infiltration of local anaesthesia (LA) around incision wound, that aims to reduce sensitization and hyperalgesia therefore accelerates wound healing, and subcutaneous administration shows bacteriostatic and bactericidal properties (Abrão et al., 2020; Brower et al., 2003). LA infiltration reduces the release of inflammation mediators of neutrophils, decrease oxidant formation, edema formation, and reduce adhesion of neutrophils on cell endothels (Hollmann et al., 2000). This study aims to determine the effect of ropivacaine infiltration as local anaesthesia in the expression of Caspase 3 and apoptosis.

## Materials and Methods

### Study Design

This study is an experimental study with randomized post test only control group design with Wistar rats as study samples. The intervention given is ropivacain infiltration and the outcomes observed are Caspase-3 expression and squamous cell apoptosis that occurred. Staining methods used are hematoxylin & eosin and trichrome staining methods.

### Study Sample

Study samples are Wistar rats that are included in genus rattus, originating from American continent, and commonly used as animal models in scientific researches. The rats concluded in this study were selected in Experimental Animal Unit of Pharmacology Department of Airlangga Medical Faculty. Wistar rats' selection were conducted considering the inclusion and exclusion criterias of the study. Inclusion criterias were pure breed of Wistar rats, aged two to two and a-half months, weighed 250 to 300 grams and did not have any anatomical

anomalies. The exclusion criteria of the samples were those who were sick during the 7-days acclimatization period, those whose weight decreased by 10% during acclimatization period and had any other wounds prior to study.

Sample size was calculated using Federer formula and the result obtained was 24 rats. The samples were then divided randomly into four groups, each group consisted of 6 rats.

### **Ropivacaine Infiltration**

Ropivacaine, a local anesthesia agent that has long duration of action, was administered as 0.75% solution that was diluted into 0.2% solution, 1 ml solution was infiltrated  $\pm 0.5$  cm from the wound edge along the incision wound.

### **Measuring Caspase 3**

Caspase-3 protein expression was observed 1 cm around incision wound, on squamous epithelial cells above basement membrane, on stratum basale to stratum corneum. Measurement of Caspase-3 protein expression was by calculation of mean number of squamous epithelial cells that expressed Caspase-3 as seen in light microscopes with 400x magnification on 10 random visual fields. Staining technique used in Caspase-3 expression was immunohistochemistry using specific monoclonal antibody from paraffin block with Allred Scoring Guideline as scoring system (Maae et al., 2011).

### **Measuring Apoptosis**

Apoptosis was observed 1 cm around incision wound, on squamous epithelial cells above basement membrane, on stratum basale to stratum corneum. Number of cell undergoing apoptosis was measured by calculation of apoptotic cells morphology as seen in light microscope Olympus Type CX-21 with 400x magnification, while 200x magnification was used to determine fields to examine. There were 3 fields that were examined: two wound edges and the area below incision wound. Hematoxylin & eosin staining procedure was used in this measurement.

### **Study Procedure**

Wistar rats underwent acclimatization for seven days prior to experiment to adapt with study environment. Samples were given same food and drink and weighed every day during this period. After acclimatization period, samples were divided randomly into four groups: Intervention group 1 (I1) and Intervention group 2 (I2) in which rats were given ropivacaine infiltration; and Control group 1 (C1) and Control group 2 (C2) in which rats were given NaCl 0.9% instead. Each group consisted of 6 rats. The rats were then kept in 30x20x7cm cage according to their groups. All samples were anesthetized with ketamine-xylazine with the dose of 75-100mg/kgbw + 5-10mg/kgbw intraperitoneally for 10 to 30 minutes, the rats' backs were then shaved and disinfected with povidone iodine, before given a 2 cm incision wound. Incision wounds were then disinfected with povidone iodine and either given 1 ml ropivacaine 0,2% infiltration subcutaneously in I1 and I2 groups

0,5cm around them; or 1 ml NaCl 0.9% in C1 and C2 groups and disinfected once again before wound dressing were applied.

On the third day after incision, the rats in I1 and C1 groups were anaesthetized with ketamine to undergo excisional biopsy procedures by taking 3cm<sup>2</sup> tissue subcutaneous-deep. The same procedures were done to the rats in I2 and C2 groups on the seventh day after incision. The tissues obtained were then processed as histological specimen in paraffin blocks; undergoing fixation with formaline, dehydration process with alcohol, alcohol clearing process using xylol, impregnation in paraffin and paraffin block making. After paraffin blocks were made, the next procedure is hematoxylin and eosin staining. The tissues on the slides underwent deparaffinization in xylol and absolute ethanol, then hydration process using alcohol and water, stained with hematoxylin and eosin, dehydration using alcohol then alcohol clearing using xylol, and mounted using entelan and covered with deck glass. The slides were then examined by pathologists under microscopes for the expression of Caspase-3 using Allred Scoring Guideline by adding proportion score and intensity score of squamous epithelial cells that expressed Caspase-3; and identification of apoptosis that were marked with cell morphology change, condensation and fragmentation, with pink cell nucleus without inflammatory cells around using H&E staining technique.

14

The data was then tested for its distribution normality using Kolmogorov-Smirnov, and analysed for its differences using parametric test for both normally distributed data and non-parametric test for those that were not normally distributed. Data analysis was done using SPSS 17.0. P-value of <0.05 was considered statistically significant.

## Results and Discussions

### Expression of Caspase-3

Identification of Caspase-3 protein expression in this study was by doing immunohistochemistry examination, a method to localize or identify antigen on squamous epithelial cells samples using specific monoclonal antibody for Caspase-3. Squamous epithelial cells that expressed Caspase-3 would show brownish silver color.

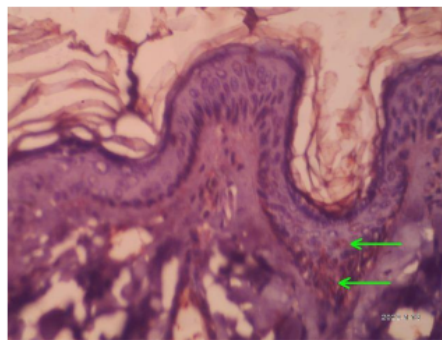


Figure 1. Caspase-3 protein expression (green arrow)

Caspase-3 expression on the third observation day was found less in the intervention group compared to the control group, similar results were seen on the seventh observation day. Highest Caspase-3 expression was seen in control group on the third day of observation.

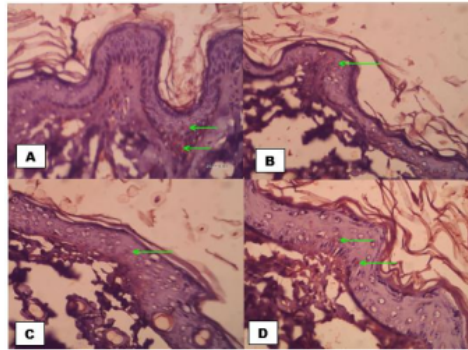


Figure 2. Expression of Caspase-3 on the third observation day on control group (A) and intervention group (B) seen under 400x magnification using immunohistochemistry staining. Expression of Caspase-3 on the third observation day on control group (C) and intervention group (D) seen under 400x magnification using immunohistochemistry staining

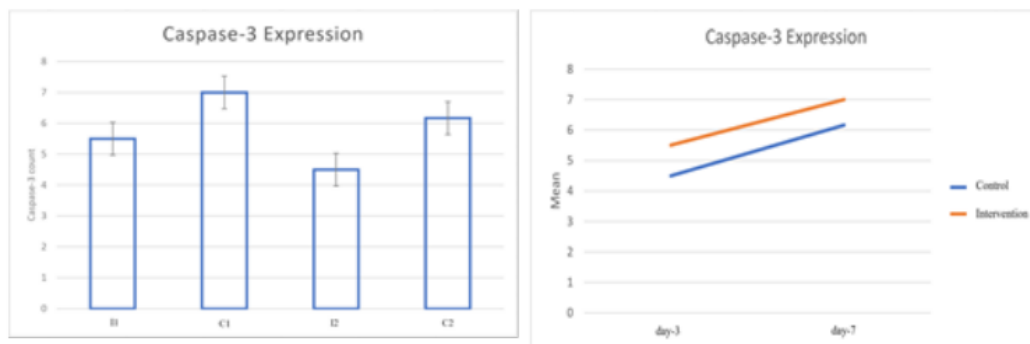


Figure 3. Mean and standard deviation of Caspase-3 protein between groups and Change of Caspase-3 expression on the third and seventh day of observation between both groups

Caspase-3 expression of control group was higher on the third day compared to the seventh day of observation, similar to the findings on the intervention group. Mean of Caspase-3 expression was higher on both observation days in control group, compared to the intervention group.

Wilcoxon test was then used to determine the significance of this difference. The calculation of Caspase-3 expression showed significant difference between both groups on the third ( $p=0.024$ ) and seventh ( $p=0.041$ ) observation days, while difference between measurement on the third and seventh day on the control group ( $p=0.059$ ) and intervention group ( $p=0.063$ ) showed no significant difference.

Table 1  
Measurement of Caspase-3 protein on the third and seventh day using Allred Scoring System

Group	Sample	Caspase 3 (Total Score)	Group	Caspase 3 (Total Score)
C1	1	7	C2	6
	2	7		7
	3	6		6
	4	7		6
	5	8		7
	6	7		5
I1	1	5	I2	5
	2	6		4
	3	5		5
	4	5		4
	5	6		4
	6	6		5

### Total Apoptosis

Apoptosis was identified by the change of cell morphology, condensation, fragmentation, pink cell nucleus and the absence of inflammatory cells around. After Hematoxylin & Eosin staining, squamous epithelial cells were pink in color, so the more cells underwent apoptosis, the more pink areas were seen.

On the third observation day, more apoptosis was seen on the control group compared to the intervention group, while on day seven, apoptosis seen in the intervention group was less than it was on the third day. Subsection should be written without a bold type. The result and analysis are presented by present form. Please avoid too many paragraphs in this section.

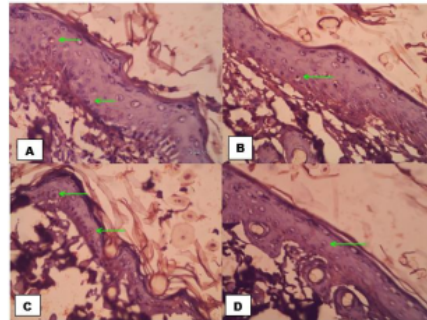


Figure 4. Apoptosis (green arrows) on the third observation day on control group (A) and intervention group (B) seen under 400x magnification using H&E staining. Apoptosis (green arrows) on the seventh observation day on control group (C) and intervention group (D) seen under 400x magnification using H&E staining.

Mean of apoptosis observed on the seventh day in the control group was seen more than intervention group, which mean was 1.34 times as many. While on the third day, apoptosis on the intervention group was 1.28 times more than the control group.

Table 2  
Measurement of Apoptosis on the third and seventh day

Group	Sample	Total Apoptosis	Group	Total Apoptosis
K1	1	7	K2	6
	2	6		7
	3	5		6
	4	7		6
	5	7		7
	6	6		5
P1	1	5	P2	5
	2	6		4
	3	6		5
	4	6		5
	5	7		4
	6	6		5

Wilcoxon test was also used to determine the significance of the difference between groups. Apoptosis of squamous epithelial cells on the third observation day between control and intervention group showed no significant difference ( $p=0.414$ ), while on the seventh observation day, apoptosis was found significantly different between both groups ( $p=0.031$ ). Measurement of the difference between the third and seventh day on the control group ( $p=0.655$ ) showed no significant difference but on the intervention group showed otherwise ( $p=0.033$ ).

Expression of Caspase-3 protein is a significant factor in the apoptosis process that occurs due to stress to cells in the wound formation process. Highest activity is found around three to seven days after wound formation. After tissue granulation, angiogenesis will stop, therefore there is a decrease in new blood vessels formation and endothelial cells will undergo apoptosis (Zoellner et al., 1996).

In this study, we found that the highest expression of Caspase-3 was found on the third observation day in the control group, and the lowest was found on the seventh day in the intervention group. On both groups, there was a decrease in Caspase-3 expression on the seventh day compared to the third day.

Local anesthesia agent infiltration in surgical incision wound can reduce pain and cell death after surgery therefore will accelerate wound healing. This can be explained with the decrease of cytokine production after ropivacaine infiltration from the blockage of pain transmission process. Eventhough the infiltration of local anesthesia like ropivacaine is used to block the nerve conduction, local anesthesia also has other characteristics which is its anti-inflammatory properties. A few studies have showed that local anesthesia dose-dependently



decreases leukocyte adhesion on blood vessels walls, and induces prostacycline that releases the leukocyte that adhere to the blood vessels endothels. It was shown that local anesthesia agent in low concentration can stimulate phospholipase A2 (PLA2) but in high concentration can block this (Abrão et al., 2020).

6

Data analysis in this study showed that there was significant difference in Caspase-3 expression of squamous epithelial cells on both the third ( $p=0.024$ ) and seventh day ( $p=0.041$ ) of observation between control group and intervention group, which meant ropivacaine infiltration around incision wound could decrease the expression of Caspase-3 therefore could also decrease cellular apoptosis, which was supported by the seventh day of observation result, where there was significant difference between control and intervention group apoptosis ( $p=0.031$ ).

There are a few ways of how infiltration of local anesthesia agent could accelerate wound healing. Infiltration of local anesthesia agent around incision wound could change the pH of the area surrounding the incision wound, which is different from the physiologic pH. Epinephrine could be used to lengthen the duration of action and decrease drug toxicity. Local anesthesia might also have an important role in eicosanoid, fibroblast formation, and scar tissue formation in wound healing (Abrão et al., 2020).

Ropivacaine is a local anesthesia agent in the amid (CONH-) group that was produced the first time as pure enantiomer. Ropivacaine has long duration of action and has lowest cardiotoxic and neurotoxic properties compared to other local anesthesia agents. Its mechanism of action is similar to the other local anesthesia agents, which is by reversible inhibition of sodium to the nerve. If minimum local analgesic concentration (MLAC) is achieved, the agent will surround the axon membrane to block sodium channel and block nerve impulse transmission (Pramono et al., 2016). This is similar to another study by Hanci (2012) that compared the effect of bupivacaine, lidocaine and tramadol infiltration to wound healing showed that scoring of tissue and vascular edema in the wounds infiltrated by lidocaine and bupivacaine were higher compared to tramadol (Hanci et al., 2012). Pramono (2016) stated that ropivacaine around incision wound could increase collagen synthesis in the wound healing process (Pramono et al., 2016).

## Conclusion

Ropivacaine 0.2% infiltration decreased the expression of Caspase-3 on the third and seventh day after after incision and reduced apoptosis observed on the seventh day. Further studies regarding the effects of ropivacaine infiltration to enhance wound healing still needed to be done, especially on the maturation phase because it had not been included in this study.

8

## Acknowledgments

The authors would like to thank the Pharmacology Department of Airlangga Medical Faculty for the arrangement made for data collections by the students.

## References

1. Abrão, J., Antunes, M., & Garcia, L. V. (2020). Local Anesthetics Infiltration and Wound Healing Process. *Topics in Local Anesthetics*, 119. <http://dx.doi.org/10.5772/intechopen.80137>
2. Brower, M. C., & Johnson, M. E. (2003). Adverse effects of local anesthetic infiltration on wound healing. *Regional anesthesia and pain medicine*, 28(3), 233. Available from: <https://www.proquest.com/openview/a4fb4cc892030895cfd928fe749f70b7/1?pq-origsite=gscholar&cbl=47693>
3. Enoch, S., & Leaper, D. J. (2008). Basic science of wound healing. *Surgery (Oxford)*, 26(2), 31-37.
4. Ferreira, K. S., Kreutz, C., MacNelly, S., Neubert, K., Haber, A., Bogyo, M., ... & Borner, C. (2012). Caspase-3 feeds back on caspase-8, Bid and XIAP in type I Fas signaling in primary mouse hepatocytes. *Apoptosis*, 17(5), 503-515. <https://doi.org/10.1007/s10495-011-0691-0>
5. Gonzalez, A. C. D. O., Costa, T. F., Andrade, Z. D. A., & Medrado, A. R. A. P. (2016). Wound healing-A literature review. *Anais brasileiros de dermatologia*, 91, 614-620. <https://doi.org/10.1590/abd1806-4841.20164741>
6. Hancı, V., Hakimoğlu, S., Özaçmak, H., Bektaş, S., Özaçmak, H. S., Özdamar, Ş. O., ... & Turan, I. Ö. (2012). Comparação dos efeitos da infiltração com bupivacaína, lidocaína e tramadol na cicatrização de feridas em ratos. *Revista Brasileira de Anestesiologia*, 62(6), 804-810. <https://doi.org/10.1590/S0034-70942012000600005>
7. Hollmann, M. W., Durieux, M. E., & Fisher, D. M. (2000). Local anesthetics and the inflammatory response: a new therapeutic indication?. *The Journal of the American Society of Anesthesiologists*, 93(3), 858-875. <https://doi.org/10.1097/0000542-200009000-00038>
8. Maae, E., Nielsen, M., Steffensen, K. D., Jakobsen, E. H., Jakobsen, A., & Sørensen, F. B. (2011). Estimation of immunohistochemical expression of VEGF in ductal carcinomas of the breast. *Journal of Histochemistry & Cytochemistry*, 59(8), 750-760. <https://doi.org/10.1369/0022155411412599>
9. Pramono, W. B., Leksana, E., & Satoto, H. H. (2016). Pengaruh pemberian ropivakain infiltrasi terhadap tampilan kolagen di sekitar luka insisi pada tikus Wistar. *JAI (Jurnal Anestesiologi Indonesia)*, 8(1), 1-10. <https://doi.org/10.14710/jai.v8i1.11859>
10. Zoellner, H., Hofler, M., Beckmann, R., Hufnagl, P., Vanyek, E., Bielek, E., ... & Binder, B. R. (1996). Serum albumin is a specific inhibitor of apoptosis in human endothelial cells. *Journal of cell science*, 109(10), 2571-2580. <https://doi.org/10.1242/jcs.109.10.2571>

# Effect ropivacaine infiltration in incisional wound on caspase-3 expression and apoptosis squamous cells wound healing

## ORIGINALITY REPORT

12%

SIMILARITY INDEX

11%

INTERNET SOURCES

7%

PUBLICATIONS

1%

STUDENT PAPERS

## PRIMARY SOURCES

1	<a href="http://www.neliti.com">www.neliti.com</a> Internet Source	2%
2	<a href="http://doaj.org">doaj.org</a> Internet Source	1%
3	<a href="http://s3.amazonaws.com">s3.amazonaws.com</a> Internet Source	1%
4	<a href="http://sloap.org">sloap.org</a> Internet Source	1%
5	<a href="http://www.balimedicaljournal.org">www.balimedicaljournal.org</a> Internet Source	1%
6	<a href="http://mro.massey.ac.nz">mro.massey.ac.nz</a> Internet Source	1%
7	<a href="http://siladikti.hangtuah.ac.id">siladikti.hangtuah.ac.id</a> Internet Source	1%
8	<a href="http://www.frontiersin.org">www.frontiersin.org</a> Internet Source	1%
9	Submitted to Universitas Airlangga Student Paper	1%

10	<a href="https://docksci.com">docksci.com</a> Internet Source	<1 %
11	<a href="http://ejournal.kemenperin.go.id">ejournal.kemenperin.go.id</a> Internet Source	<1 %
12	<a href="http://www.researchgate.net">www.researchgate.net</a> Internet Source	<1 %
13	<a href="http://www.vvmr.ru">www.vvmr.ru</a> Internet Source	<1 %
14	<a href="http://e-journal.unair.ac.id">e-journal.unair.ac.id</a> Internet Source	<1 %
15	<a href="http://onlinelibrary.wiley.com">onlinelibrary.wiley.com</a> Internet Source	<1 %
16	<a href="http://www.innovareacademics.in">www.innovareacademics.in</a> Internet Source	<1 %
17	Chen, Jia-Perng, Ming-Shiang Wu, Sung-Hsin Kuo, and Fang Liao. "IL-22 Negatively Regulates Helicobacter pylori-Induced CCL20 Expression in Gastric Epithelial Cells", PLoS ONE, 2014. Publication	<1 %
18	I Ketut Suyasa, Anak Agung Wiradewi Lestari. "Low expression of vascular endothelial growth factor and high serum level of cyclic guanine monophosphate as the risk factors of femoral head osteonecrosis in alcohol-exposed Wistar rat", Chinese Journal of Traumatology, 2020 Publication	<1 %

---

19	<a href="https://scholarcommons.sc.edu">scholarcommons.sc.edu</a> Internet Source	<1 %
20	<a href="http://www.intechopen.com">www.intechopen.com</a> Internet Source	<1 %
21	"8th International Conference on the Development of Biomedical Engineering in Vietnam", Springer Science and Business Media LLC, 2022 Publication	<1 %

---

Exclude quotes  On

Exclude matches  Off

Exclude bibliography  On

# Effect ropivacaine infiltration in incisional wound on caspase-3 expression and apoptosis squamous cells wound healing

---

GRADEMARK REPORT

---

FINAL GRADE

**/100**

GENERAL COMMENTS

**Instructor**

---

PAGE 1

---

PAGE 2

---

PAGE 3

---

PAGE 4

---

PAGE 5

---

PAGE 6

---

PAGE 7

---

PAGE 8

---

PAGE 9

---