

---

**Decision on your Manuscript #FSMP-D-22-00134**

1 message

---

**Claas T Buschmann** <em@editorialmanager.com>  
Reply-To: Claas T Buschmann <claas.buschmann@uksh.de>  
To: Rosy Setiawati <rosy-s@fk.unair.ac.id>

Sat, May 14, 2022 at 4:06 PM

Dear Dr Setiawati:

Thank you for submitting a manuscript to FSMP. Following the process of review the reviewers have identified a number of areas which I would wish you to address prior to a decision as to whether or not the manuscript is suitable for publication. Could you please:

1. consider the reviewers comments and address them where necessary
2. provide to me a revised manuscript within 4 weeks (Revision Due: 13 Jun 2022)
3. provide to me a letter indicating those changes which you have made and the reasons why you have not made the other suggested changes

Certain problems have been identified by reviewers in the English grammar/expression of your manuscript. The paper should either be edited by a native English speaker, or else the authors should use a professional editing service".

For editors and reviewers to accurately assess the work presented in your manuscript you need to ensure the English language is of sufficient quality to be understood. If you need help with writing in English you should consider:

\* Asking a colleague who is a native English speaker to review your manuscript for clarity.

\* Visiting the English language tutorial which covers the common mistakes when writing in English.  
<http://www.springer.com/gp/authors-editors/authorandreviewertutorials/writinginenglish>

\* Using a professional language editing service where editors will improve the English to ensure that your meaning is clear and identify problems that require your review. Two such services are provided by our affiliates Nature Research Editing Service and American Journal Experts.

<http://authorservices.springernature.com/>  
<http://www.aje.com/us/>

Please note that the use of a language editing service is not a requirement for publication in this journal and does not imply or guarantee that the article will be selected for peer review or accepted.

TO VIEW REVIEWER ATTACHMENTS (should there be any) please login to the journal site as "Author" and access "Submission Needing Revision" from the Author Main Menu.

On the next page display, navigate on the "Action Links" and select "View Reviewer Attachments" from the selection box. This will redirect you to the page that will allow you to "Download" and view the reviewer report attachments. Then, proceed with revising your manuscript.

PLEASE NOTE: YOUR REVISED VERSION CANNOT BE IN .PS OR .PDF AS TYPESETTING CANNOT MANIPULATE THE FILES.

In order to submit your revised manuscript electronically, please access the following web site:

<https://www.editorialmanager.com/fsmp/>

Your username is: drrosy

If you forgot your password, you can click the 'Send Login Details' link on the EM Login page.

Click "Author Login" to submit your revision.

Yours sincerely,

Claas T Buschmann  
Editor-in-Chief/Managing Editor  
Forensic Science, Medicine and Pathology

#### COMMENTS FOR THE AUTHOR:

Reviewer #4: The topic of the article is interesting. Different points have to be added and clarified. There is not enough anthropological background, the authors have to strength it. The article brings nothing new, as it does not include any Procrustes analysis which is accurate to differentiate shape and size differences. For all those reasons, I recommend a major revision of the manuscript concerning a potential publication in FSMP. If the modifications asked are not done, the article must be rejected.

Concerning the form:

- Some typographic mistakes (with some spaces missing, or too much spaces).

Concerning the content:

- Abstract: OK.
- Title: ok.
- Introduction:
  - o ok
- Material and methods:
  - o Add the name and the references of the software use for the 3D
  - o Add the references which justify the choice of the landmarks and distances measured,
  - o You have to calculate intra and inter-observer variations to increase the scientific value of your work,
  - o Add a figure with the points and distances,
- Results:
  - o You have to calculate intra and inter-observer variations to increase the scientific value of your work,
- Discussion:
  - o Add references dealing with anthropology, sex determination and dry bones, this is the base considering your topic,
  - o Add references and discuss the interest of the morphometry geometric analysis and Procrustes analysis,
  - o Discuss the results considering that you include differences of size and shape (which is a major limit),
- Conclusion:
  - OK
- Bibliography:
  - o Add references dealing with anthropology and the innominate, and morphometry geometric analyse. The list is not exhaustive, you can find a lot by yourself:
    - Book from Ubelaker, Scheuer and Black
    - Forensic Sci Int. 2014;234:189.e1-8. doi: 10.1016/j.forsciint.2013.10.037. Sex determination using the Probabilistic Sex Diagnosis (DSP: Diagnose Sexuelle Probabiliste) tool in a virtual environment. Tara Chapman, Philippe Lefevre, Patrick Semal, Fedor Moiseev, Victor Sholukha, Stéphane Louryan, Marcel Rooze, Serge Van Sint Jan, A Test of the DSP Sexing Method on CT Images from a Modern French Sample. Mestekova S, Bruzek J, Veleminska J, Chaumoitre K. J Forensic Sci. 2015 Sep;60(5):1295-9. doi: 10.1111/1556-4029.12817.
    - Validation and reliability of the sex estimation of the human os coxae using freely available DSP2 software for bioarchaeology and forensic anthropology. Brůžek J, Santos F, Dutailly B, Murail P, Cunha E. Am J Phys Anthropol. 2017 Oct;164(2):440-449. doi: 10.1002/ajpa.23282.
    - The accuracy of 3D virtual bone models of the pelvis for morphological sex estimation. Colman KL, van der Merwe AE, Stull KE, Dobbe JGG, Streekstra GJ, van Rijn RR, Oostra RJ, de Boer HH. Int J Legal Med. 2019 Nov;133(6):1853-

1860. doi: 10.1007/s00414-019-02002-7

Phenice IW. A newly developed visual method of sexing the os pubis. *Am J Phys Anthropol.* 1969;30:183-186. doi: 10.1002/ajpa.1330300214.

Krogman W, İşcan M. *The human skeleton in forensic science.* Springfield: CC Thomas; 1986.

MacLaughlin S, Bruce M. Population variation in sexual dimorphism in the human innominate. *Hum Evol.* 1986;1:221-231. doi: 10.1007/BF02436580.

Rogers T, Saunders S. Accuracy of sex determination using morphological traits of the human pelvis. *J Forensic Sci.* 1994;39:1047-1056. doi: 10.1520/JFS13683J.

Ubelaker DH, Volk CG. A test of the phenice method for the estimation of sex. *J Forensic Sci.* 2002;47:19-24

Human coxal bone sexual dimorphism and multislice computed tomography: geometric morphometric analysis of 65 adults. Bilfeld MF, Dedouit F, Rousseau H, Sans N, Braga J, Rougé D, Telmon N. *J Forensic Sci.* 2012 May;57(3):578-88. doi: 10.1111/j.1556-4029.2011.02009.x.

Ontogeny of Size and Shape Sexual Dimorphism in the Pubis: A Multislice Computed Tomography Study by Geometric Morphometry. Bilfeld MF, Dedouit F, Sans N, Rousseau H, Rougé D, Telmon N. *J Forensic Sci.* 2015 Sep;60(5):1121-8. doi: 10.1111/1556-4029.12761.

- Figures:
  - o Figure 1: lines are not enough visible,
  - o Add figures with all the points and measures,
- Tables:
  - o Globally, strength the legends
  - o Table : explain beta, wald ...

Reviewer #5: Thank you for this interesting article dealing with sex identification based on anthropometric analysis of 3D-CT-scanner of pelvis and a statistical regression formula.

General comments:

- This manuscript is well written and structured.
- I totally agree with the authors about the fact that the CT-scanner is an ideal tool to assess fractures on a skeleton, however, even if the "volume rendering" reconstruction is useful to perform some measurements, it should not be used to detect fractures. Indeed, its diagnostic capabilities are not sufficient (never used for this purpose in the "standard" radiology, neither in forensic radiology). This is not explained in the manuscript.

Specific comments:

Keywords :

- I don't understand the presence of the item "human & health"... It has nothing to do here.

Materials and Methods :

- The authors don't explain how they performed the measurements (only one measurement per region of interest? multiple measurements and mean value?), neither who performed those measures!

Tables :

- Table 1 is not introduced/quoted in the text.

Please note that this journal is a Transformative Journal (TJ). Authors may publish their research with us through the traditional subscription access route or make their paper immediately open access through payment of an article-processing charge (APC). Authors will not be required to make a final decision about access to their article until it has been accepted.

<b>Authors may need to take specific actions to achieve compliance with funder and institutional open access mandates.

</b> If your research is supported by a funder that requires immediate open access (e.g. according to Plan S principles) then you should select the gold OA route, and we will direct you to the compliant route where possible. For authors selecting the subscription publication route our standard licensing terms will need to be accepted, including our self-archiving policies. Those standard licensing terms will supersede any other terms that the author or any third party may assert apply to any version of the manuscript.

<a href= <https://www.springernature.com/gp/open-research/funding/policy-compliance-faqs>> Find out more about compliance</a>

This letter contains confidential information, is for your own use, and should not be forwarded to third parties.

Recipients of this email are registered users within the Editorial Manager database for this journal. We will keep your information on file to use in the process of submitting, evaluating and publishing a manuscript. For more information on how we use your personal details please see our privacy policy at <https://www.springernature.com/production-privacy-policy>. If you no longer wish to receive messages from this journal or you have questions regarding database management, please contact the Publication Office at the link below.

---

In compliance with data protection regulations, you may request that we remove your personal registration details at any time. (Use the following URL: <https://www.editorialmanager.com/fsmp/login.asp?a=r>). Please contact the publication office if you have any questions.

---

## Decision on your Manuscript #FSMP-D-22-00134R1

1 message

---

**Claas T Buschmann** <em@editorialmanager.com>  
Reply-To: Claas T Buschmann <claas.buschmann@uksh.de>  
To: Rosy Setiawati <rosy-s@fk.unair.ac.id>

Sun, Jul 10, 2022 at 11:51 PM

Dear Dr Setiawati:

Thank you for submitting a manuscript to FSMP. Following the process of review the reviewers have identified a number of areas which I would wish you to address prior to a decision as to whether or not the manuscript is suitable for publication. Could you please:

1. consider the reviewers comments and address them where necessary
2. provide to me a revised manuscript within 4 weeks (Revision Due: 09 Aug 2022)
3. provide to me a letter indicating those changes which you have made and the reasons why you have not made the other suggested changes

Certain problems have been identified by reviewers in the English grammar/expression of your manuscript. The paper should either be edited by a native English speaker, or else the authors should use a professional editing service".

For editors and reviewers to accurately assess the work presented in your manuscript you need to ensure the English language is of sufficient quality to be understood. If you need help with writing in English you should consider:

\* Asking a colleague who is a native English speaker to review your manuscript for clarity.

\* Visiting the English language tutorial which covers the common mistakes when writing in English.  
<http://www.springer.com/gp/authors-editors/authorandreviewertutorials/writinginenglish>

\* Using a professional language editing service where editors will improve the English to ensure that your meaning is clear and identify problems that require your review. Two such services are provided by our affiliates Nature Research Editing Service and American Journal Experts.

<http://authorservices.springernature.com/>  
<http://www.aje.com/us/>

Please note that the use of a language editing service is not a requirement for publication in this journal and does not imply or guarantee that the article will be selected for peer review or accepted.

TO VIEW REVIEWER ATTACHMENTS (should there be any) please login to the journal site as "Author" and access "Submission Needing Revision" from the Author Main Menu.

On the next page display, navigate on the "Action Links" and select "View Reviewer Attachments" from the selection box. This will redirect you to the page that will allow you to "Download" and view the reviewer report attachments. Then, proceed with revising your manuscript.

PLEASE NOTE: YOUR REVISED VERSION CANNOT BE IN .PS OR .PDF AS TYPESETTING CANNOT MANIPULATE THE FILES.

In order to submit your revised manuscript electronically, please access the following web site:

<https://www.editorialmanager.com/fsmp/>

Your username is: drrosy

If you forgot your password, you can click the 'Send Login Details' link on the EM Login page.

Click "Author Login" to submit your revision.

Yours sincerely,

Claas T Buschmann  
Editor-in-Chief/Managing Editor  
Forensic Science, Medicine and Pathology

#### COMMENTS FOR THE AUTHOR:

Reviewer #4: The article is now much better. I have only slight remarks. For all those reasons, I recommend a minor revision of the manuscript concerning a potential publication in FSMP.

Concerning the form:

- ok.

Concerning the content:

- Abstract: OK.
- Title: ok.
- Introduction:
  - o ok
- Material and methods:
  - o ok
- Results:
  - o Comment more precisely results. For example, what is your conclusion concerning eta test?
- Discussion:
  - o Discuss the results considering that you include differences of size and shape (which is a major limit comparatively to studied based on Procrustes data),
- Conclusion:
  - OK
- Bibliography:
  - o Ok
- Figures:
  - o ok
- Tables: Strength legends
  - o Table 5: What is Eta?
  - o Table 4: What is beta, wald, OR?

Reviewer #5: Thanks for considering the comments.

It would have been appreciated that the changes made to the text were notified in red or any color but easily identifiable in the text in addition to the letter indicating the changes.

Introduction:

- 3rd sentence of the 3rd paragraph : [For these reasons, \*the\* study which demonstrates the importance of an objective method by utilizing radiology technology in sex determination is needed.] should be change for --> [For these reasons, \*a\* study which demonstrates the importance of an objective method by utilizing radiology technology in sex determination is needed.]
- 4th sentence of the 3rd paragraph : [Although visual or morphological techniques are a quick way to assess, ...] should

be change for --> [Although visual or morphological techniques are a quick way of assessment, ...]

Material and methods:

- Sample of study : The 3rd sentence should be rephrased [On the other hand, the exclusion criteria in this study was pelvic CT images of patient's pelvis and sacrum \*from\* had some pathological conditions e.g. bone implant, chronic disease, bone fracture, osteoporosis that might interfere the measurement]
- Concerning the measurements, why two radiologists? Why no anthropologist took part in these measurements? Even together with a radiologist?

Discussion :

- The 2nd sentence of the 2nd paragraph seems to come out of nowhere.. [3D virtual pelvic models derived from CT scans.] --> The sequence of the sentences of the paragraph should be reviewed.
- Concerning the influence of the hormonal effects of pregnancy on pelvic bones structure, did you take into account whether the women included in the study had been pregnant or not? Is there a difference between women who have been pregnant and those who have never been?

Please note that this journal is a Transformative Journal (TJ). Authors may publish their research with us through the traditional subscription access route or make their paper immediately open access through payment of an article-processing charge (APC). Authors will not be required to make a final decision about access to their article until it has been accepted.

**Authors may need to take specific actions to achieve compliance with funder and institutional open access mandates.** If your research is supported by a funder that requires immediate open access (e.g. according to Plan S principles) then you should select the gold OA route, and we will direct you to the compliant route where possible. For authors selecting the subscription publication route our standard licensing terms will need to be accepted, including our self-archiving policies. Those standard licensing terms will supersede any other terms that the author or any third party may assert apply to any version of the manuscript.

<https://www.springernature.com/gp/open-research/funding/policy-compliance-faqs> Find out more about compliance

This letter contains confidential information, is for your own use, and should not be forwarded to third parties.

Recipients of this email are registered users within the Editorial Manager database for this journal. We will keep your information on file to use in the process of submitting, evaluating and publishing a manuscript. For more information on how we use your personal details please see our privacy policy at <https://www.springernature.com/production-privacy-policy>. If you no longer wish to receive messages from this journal or you have questions regarding database management, please contact the Publication Office at the link below.

---

In compliance with data protection regulations, you may request that we remove your personal registration details at any time. (Use the following URL: <https://www.editorialmanager.com/fsmp/login.asp?a=r>). Please contact the publication office if you have any questions.

---

**Decision on your manuscript #FSMP-D-22-00134R2 - [EMID:f7ca5ac098906a7d]**

1 message

---

**Claas T Buschmann** <em@editorialmanager.com>  
Reply-To: Claas T Buschmann <claas.buschmann@uksh.de>  
To: Rosy Setiawati <rosy-s@fk.unair.ac.id>

Tue, Aug 30, 2022 at 9:30 PM

Dear Dr Setiawati,

We are pleased to inform you that your manuscript, "ANTHROPOMETRIC STUDY USING THREE-DIMENTIONAL PELVIC CT SCAN IN SEX DETERMINATION AMONG ADULT INDONESIAN POPULATION", has been accepted for publication in

Forensic Science, Medicine and Pathology.

You will be contacted by Author Services in due course with a link to complete the grant of rights. Please note that you will receive your proofs after the publishing agreement has been received through the online system.

Please remember to quote the manuscript number, FSMP-D-22-00134R2, whenever inquiring about your manuscript.  
With best regards,  
Claas T Buschmann  
Editor-in-Chief/Managing Editor  
Forensic Science, Medicine and Pathology

Reviewer #4: The article is now much better. All modifications have been performed and explanations added. According to me, the article may now be published.

Reviewer #5: Thanks for considering the comments.

Please note that this journal is a Transformative Journal (TJ). Authors may publish their research with us through the traditional subscription access route or make their paper immediately open access through payment of an article-processing charge (APC). Authors will not be required to make a final decision about access to their article until it has been accepted.

<b>Authors may need to take specific actions to achieve compliance with funder and institutional open access mandates. </b> If your research is supported by a funder that requires immediate open access (e.g. according to Plan S principles) then you should select the gold OA route, and we will direct you to the compliant route where possible. For authors selecting the subscription publication route our standard licensing terms will need to be accepted, including our self-archiving policies. Those standard licensing terms will supersede any other terms that the author or any third party may assert apply to any version of the manuscript.

<a href= <https://www.springernature.com/gp/open-research/funding/policy-compliance-faqs>> Find out more about compliance</a>

This letter contains confidential information, is for your own use, and should not be forwarded to third parties.

Recipients of this email are registered users within the Editorial Manager database for this journal. We will keep your information on file to use in the process of submitting, evaluating and publishing a manuscript. For more information on how we use your personal details please see our privacy policy at <https://www.springernature.com/production-privacy-policy>. If you no longer wish to receive messages from this journal or you have questions regarding database management, please contact the Publication Office at the link below.

---

In compliance with data protection regulations, you may request that we remove your personal registration details at any



time. (Use the following URL: <https://www.editorialmanager.com/fsmp/login.asp?a=r>). Please contact the publication office if you have any questions.

	<b>Reviewer #5</b>	
	<p><b>Introduction :</b></p> <ul style="list-style-type: none"> <li>- 3rd sentence of the 3rd paragraph : For these reasons, <b>*the*</b> study which demonstrates the importance of an objective method by utilizing radiology technology in sex determination is needed</li> <li>- 4th sentence of the 3rd paragraph : Although visual or morphological techniques are a quick way <b>to assess,</b> ...)</li> </ul>	<p><b>We changed the sentences as follow :</b></p> <ul style="list-style-type: none"> <li>-For these reasons, <b>*a*</b> study which demonstrates the importance of an objective method by utilizing radiology technology in sex determination is needed</li> <li>- Although visual or morphological techniques are a quick way <b>of assessment,</b> ...)</li> </ul>
	<p><b>Material and methods:</b></p> <ul style="list-style-type: none"> <li>- Sample of study : The 3rd sentence should be rephrased [On the other hand, the exclusion criteria in this study was pelvic CT images of patient's pelvis and sacrum <b>*from*</b> had some pathological conditions e.g. bone implant, chronic disease, bone fracture, osteoporosis that might interfere the measurement]</li> <li>- Concerning the measurements, why two radiologists? Why no anthropologist took part in these measurements? Even together with a radiologist?</li> </ul>	<p><b>We changed the sentence as follow :</b></p> <ul style="list-style-type: none"> <li>-On the other hand, the exclusion criteria in this study was pelvic CT images of patient's pelvis and sacrum <b>which</b> had some pathological conditions e.g. bone implant, chronic disease, bone fracture, osteoporosis that might interfere the measurement.</li> </ul> <p>We did not include the anthropologist as observer. It's a good idea for the further study to make the result more acceptable</p>
	<p><b>Discussion :</b></p> <ul style="list-style-type: none"> <li>- The 2nd sentence of the 2nd paragraph seems to come out of nowhere.. [3D virtual pelvic models derived from CT scans.] --&gt; The sequence of the sentences of the paragraph should be reviewed.</li> <li>-Concerning the influence of the hormonal effects of pregnancy on pelvic bones structure, did you take into account whether the women included in the study had been pregnant or not? Is there a difference between women who have been pregnant and those who have never been?</li> </ul>	<p>I deleted the sentence " 3D virtual pelvic models derived from CT scans" It was misplaced on the paragraph</p> <p>We did not include the hormonal influence to the shape of pelvic bone in regard to the background of pregnancy However, this issue could be considered for the upcoming study</p>
	<b>Reviewer #4</b>	
	<b>Results :</b>	

	<p>-Comment more precisely results. For example, what is your conclusion concerning eta test?</p>	<p>I revised the description more clearly on result and recently in conclusion, we also put five parameters which had the highest correlation strength from Eta test (APOD, CPID, LIH, SPA, and TPO ) between two different sex</p>
	<p>What is Eta test</p>	<p><b>The eta correlation test is used to measure the association between interval and nominal variables.</b> This can also measure of effect size that is commonly used in ANOVA models,</p> <p>It measures the proportion of variance associated with each main effect and interaction effect in an ANOVA model.</p> <p>A p-value from other tests can only tell us whether or not there is some significant association between two variables, but a measure of effect size like Eta squared can tell us the strength of association between the variables.</p>
	<p>What is Wald test</p>	<p><b>Wald test is used to analyze the association between the independent variables (predictors) and the criterion variable (dependent) variable.</b> Statistic test with known probability distribution (a chi-square distribution) that is used to test whether the <math>\beta</math> coefficient for a predictor in a logistic regression model is significantly different from zero. It is analogous to the t-statistic in a regression model in that it is simply the <math>\beta</math> coefficient divided by its standard error</p>
		<p><b>Eta and Wald are not abbreviation .</b></p> <p><b>OR is abbreviation from Outcome Regression</b></p>
	<p>Comment more precisely results. For example, what is your conclusion concerning eta test?</p>	<p><b>Yes I add information in the discussion session</b></p> <p><b>Discussion :</b></p> <p>The APOD, CPID, LIH, SPA, and TPO were conducted through multivariate analysis using logistic regression in order to find significant variables and generate a formula that might determine a person's sex with high accuracy [19]. The CPID, LIH, and SPA components showed significant values in accordance to previous discussion. These three components</p>

		<p>consistently showed differences in sexual dimorphism in both sexes, especially SPA served as one of the high scoring factors consistently.</p> <p><b>Conclusion :</b></p> <p>The APOD, CPID, LIH, TPO, and SPA had the highest correlation between both sexes and had the greatest power than other components of the pelvic measurement for sex determination</p>
	<p>Discuss the results considering that you include differences of size and shape (which is a major limit comparatively to studied based on Procrustes data),</p>	<p><b>Yes I add information in the discussion session</b></p> <p>This study showed that the estimated values of pelvic measurements using 3D-CT could give birth to a pelvic model with a formula that has a high accuracy value using CPID, LIH, and SPA values. These specific radiometric parameter obtained from this study has a positive impact for analyzing and describing the pelvic shape and size among male and female group population.</p>

**ANTHROPOMETRIC STUDY USING THREE-DIMENTIONAL PELVIC CT SCAN IN SEX  
DETERMINATION AMONG ADULT INDONESIAN POPULATION**

Rosy Setiawati<sup>a\*</sup>, Paulus Rahardjo<sup>a</sup>, Ika Ruriana<sup>a</sup>, Giuseppe Guglielmi<sup>b,c</sup>

*rosy-s@fk.unair.ac.id, paulus.r.rahardjo@gmail.com, rurianaika@gmail.com, giuseppe.guglielmi@unifg.it*

<sup>a</sup> *Musculoskeletal consultant, Radiology Department, Faculty of Medicine, Universitas Airlangga, Surabaya, Indonesia*

<sup>b</sup> *Department of Clinical and Experimental Medicine, School of Medicine, Foggia University, Foggia, Italy*

<sup>c</sup> *Department of Radiology, School of Medicine, Foggia University, Foggia, Italy*

\*Corresponding author

**Rosy Setiawati**

Radiology Department, Faculty of Medicine, Universitas Airlangga Surabaya – Dr Soetomo General Academic Hospital Surabaya

Jl. Mayjen Prof. Dr. Moestopo No.47, Surabaya, Indonesia

Email: rosy-s@fk.unair.ac.id

**Abstract**

This study aims to determine pelvic anthropometry characteristics and logistic regression formula for adult sex identification obtained from adult three-dimensional pelvic computed tomography images. This study was an observational analytical study with retrospective regression and cross-sectional approach. The population was all patients at Radiology Installation of Dr. Soetomo General Academic Hospital as referral hospital in East Indonesian region, from September to December 2019 who underwent 3D pelvic CT examination. Then, age distribution and pelvic measurements data were obtained. In this case, statistical analysis was conducted for all the data obtained. A number of 204 samples were included in this study. All radiologic components were also significantly different between sexes ( $p < 0.05$ ) except for transverse diameter of sacral segment ( $p = 0.180$ ). Moreover, the conjugate pelvic inlet diameter (CPID), the left innominate height (LIH) and sub pubic angle (SPA) showed significant values for regression formula to determine an adult's sex using 3D pelvic CT. The calculation result  $> 0$  is a prediction for female while  $< 0$  is a prediction for male. From logistic regression model calculation, a high validity value (91.05%) was found with 100% sensitivity to identify male sex and 81.1% specificity to identify female sex. There were differences on radiometric variable characteristics in pelvic anthropometric study among adult Indonesians at Dr. Soetomo General Academic Hospital, Surabaya. The estimated values of pelvic measurements using 3D CT images could develop a pelvic model with a regression formula with high accuracy value using CPID, LIH, and SPA values.

**Keywords:** sex determination; sexual dimorphism; anthropometric study; pelvic 3D CT scan

**Article Classification:** 10.020: Medicine, 10.050: Radiology, 10.090: Anthropology

**Word Count:** 4,978

**Abbreviations:**

ABS : Anterior breadth of the sacrum  
AHS : Anterior height of sacrum  
APOD : Anteroposterior pelvic outlet diameter  
CPID : Conjugate pelvic inlet diameter  
LIB : Left iliac breadth  
LIL : Left ischium length  
LPL : Left pubic length  
LGSN : Left width of greater sciatic notch  
LIH : Left innominate height  
MIP : Maximum Intensity Projection  
NMDS : Non-metric Multidimensional Scaling  
PCoA : Principal Coordinates Analysis  
PSL : Pubic symphysis length  
RIL : Right ischium length  
RPL : Right pubis length  
PL : Pubic length  
RGSN : Right width of greater sciatic notch  
RIH : Right iliac breadth  
RIH : Right innominate height  
SPA : Sub pubic angle  
TDSS : Transverse diameter of sacral segment 1  
TPI : Transverse pelvic inlet  
TPO : Transverse pelvic outlet  
CT : Computered Tomography  
MRI : Magnetic Resonance Imaging  
VR : Volume Rendering

## **Declarations**

### **Author Contribution**

- Rosy Setiawati: Conceived and designed the analysis; Contributed data or analytic tools; Performed the analysis; Wrote the paper .
- Paulus Rahardjo: Collected the data, Contributed data or analytic tools; Performed the analysis.
- Ika Ruriana: Collected the data; Contributed data or analytic tools; Wrote the paper.
- Giuseppe Guglielmi: Conceived and designed the analysis; Contributed data or analytic tools, Performed the analysis; Wrote the paper.

### **Funding**

The study did not receive any funding.

### **Conflict of Interest**

The authors declared no conflict of interest in this study.

### **Ethical approval**

This study was approved by Medical Research Ethic Committee of Dr. Soetomo General Academic Hospital, Surabaya for ethical clearance with registration number: 0106/LOF/301.4.2/VIII/2020. All participants included had given their written informed consent to participate in this study.

### **Data Availability**

The data that support the findings of this study are available from the corresponding author.

### **Conflict of Interests**

The authors declared no conflict of interest in this study.

### **Consent to Participate**

All participants consented to participate in the survey.

## **Introduction**

Sex identification on remaining human bone is the first step to do in helping forensic anthropologists to identify a person [1]. The accuracy of sex identification depends on bone components that are analyzed and the technique used. Forensic anthropology is a branch of applied physical anthropology that combines a variety of modified scientific techniques and skills from many scientific disciplines and is used to answer medico-legal related questions. Some of these techniques are quantitative and can be tested empirically e.g. sex and age estimation technique from unidentified bone remains [2-3].

In adults, the coxa is the most reliable indicator of sex because of its sexual dimorphism. Each population must have a specific identification standard [11]. Os coxae shows a broadly common pattern of sexual dimorphism across many regions in the world, and this pattern of pelvic sexual dimorphism appeared in early modern humans, approximately 100–150 years ago [32].

Accurate estimation of sex for adults is affected by the state of the individual preservation of bones, their degree of expression of sexual dimorphism, and methods employed. In some instances, metric methods are better than morphological ones [20]. For these reasons, a study which demonstrates the importance of an objective method by utilizing radiology technology in sex determination is needed. Although visual or morphological techniques are a quick way of **assessment**, they have the disadvantage of being highly subjective, requiring experienced



observers and often not being able to guarantee accuracy. Without quantifiable data, there are clear implications for determining conclusive results that even the method cannot be used as a basis of reference [21].

Conventionally, anthropologists have relied on metric and non-metric observational analyses of actual bones [3]. One of the oldest methods known in anthropology is Procrustes analysis. Generalized Procrustes analysis standardizes the landmark configurations for variation in position, scale, and orientation. The resulting Procrustes shape coordinates represent the shape of the pelvis only, whereas information about the overall pelvis size is represented by the centroid size of the landmark configurations. They performed a principal component analysis (PCA) of the Procrustes shape coordinates, jointly for males and females. The dependence of pelvis shape on body size, was estimated by multivariate linear regression of the Procrustes coordinates on body height, separately for males and females. However, these matrices must first be back-converted into an object-by-variable table by principal coordinates analysis (PCoA), non-metric multidimensional scaling (NMDS), or another suitable ordination method. In general, its use seems desirable since the analysis of shape differences and landmark configuration will increase the likelihood of detecting more subtle local patterns, but the main disadvantage in this analysis is the increased computer time necessary to compute the necessary parameters [22-23].

Over the past decade, modern cross-sectional imaging techniques have revolutionized forensic medicine. Virtual anthropology obtained by the 3D imaging techniques such as computer tomography (CT) allow us to visualize almost every anatomical and pathological bone structure with high resolution and quality. Multi-slice computed tomography (MSCT) is becoming more and more widely used for post-mortem examinations. CT provides data sources to examine modern human variation quantitatively when expanding the resources for osteological assessment to researchers. These studies have shown significant improvements in accuracy and reproducibility over conventional linear methods of constructing a person's biological profile [4-5].

Various attempts have been made to be able to 'metricize' or measure non-metric properties accurately in several body areas [5-6]. More objective data for sex estimation might allow very accurate results along with metrication of certain non-metric pelvis areas [1]. Moreover, other pelvic indices such as those used in clinical medicine might be used to supplement and give additional measurements in anthropological assessment. In adults, pelvic

bones are the most reliable indicator of sex because of its sexual dimorphism. Each population must have a special identification standard [3]. This study aims to determine pelvic anthropometry characteristics obtained from 3D pelvic CT in identifying sex among adult Indonesians in Dr. Soetomo General Academic Hospital, Surabaya, Indonesia.

## **Materials and Methods**

### **Study design**

This study was an observational analytical study with retrospective regression and cross-sectional approach. This study was approved by Medical Research Ethic Committee of Dr. Soetomo General Academic Hospital, Surabaya for ethical clearance with registration number: 0106/LOF/301.4.2/VIII/2020. All participants included had given their written informed consent to participate in this study. Moreover, the population was all patients in Radiology Installation from September to December 2019 who underwent 3D pelvic CT examination. All methods were carried out in accordance with relevant guidelines and regulations.

### **Sample of study**

The sample of this study was 3D pelvic CT data which obtained from consecutive sampling that suited to the inclusion and exclusion criteria. The inclusion criteria were MIP and VR image reconstruction of 3D pelvic CT images of patients in the Radiology Installation, both male and female patient's age were more than 18 years old and non-pregnant women. On the other hand, the exclusion criteria in this study was pelvic CT images of patient's pelvis and sacrum **which** had some pathological conditions e.g. bone implant, chronic disease, bone fracture, osteoporosis that might interfere the measurement.

### **Study procedure**

Pelvic CT scans examinations in the form of digital data served as study material. Furthermore, radiological examination tool used a 16-slices Siemens SOMATOM CT scan machine in Radiology Installation of Dr. Soetomo Surabaya General Academic Hospital. The parameters that have been used in axial Pelvic CT scans in this study were 120 Kv, 140 effective mAs, 1.5 mm of slice collimation, 5.0 mm of slice width, 24.0 mm feed/rotation, 0.5 sec. rotation time as well as the effective dose for male: 3.3 mSv and female: 4.8 mSv. 3D CT image began with the acquisition and reconstruction of axial image data. Furthermore, axial

images were sent to the work-station (Siemens, Leonardo, Erlanger, Germany). MIP and VR images were obtained using reconstructions procedure on axial image. We obtained 3D images in optimal resolution and spatial resolution in all of the patients. The pelvic CT axial images were reconstructed to produce 3D pelvic CT images that were presented as DICOM (Digital Imaging and Communications in Medicine) images. Each patient's pelvic data was imported into Mimics software (Materialise, Leuven, Belgium) in DICOM format, the "CT Bone Segmentation" tool is used [24, 31].

All demographic data were obtained from medical records. The age distribution and pelvic measurements data were obtained as well in **Table 1** [3]. Blinded pelvic measurements were performed by two observers, musculoskeletal radiologist consultants with more than 10 years of experience. Multiple pelvic measurements of each variable by observer were then obtained and determined the mean of radiometric values. In the inter-observer error test, the results of 10 measured specimens from each radiologist were compared. The inter-observer agreement was evaluated by the calculated Cohen's Kappa coefficient.

### **Statistical analysis**

Data analysis was performed using SPSS 23 statistics software. The mean of radiometric value from each observer was tested for inter-observer agreement. The inter-observer agreement was evaluated by Cohen's Kappa coefficient test, where  $p < 0.05$ . T-test analysis was used when the data was parametric; however, Mann Whitney test was used when the data was non-parametric. The purpose was to determine a significant difference between sexes. The correlation strength analysis was conducted using eta test if there were significant differences. Moreover, the variable with the strongest correlation was tested to find the regression formula to determine an adult's sex. Then, after the formula was determined, the variable was used to test the second observation group. Afterwards, the validity and specificity were measured. Chi square test was conducted to determine correlation relationship.

## **Results**

### **Study sample demography**

There were 204 patients who were included in this study. Most of the samples were male with female-to-male ratio of 1:1.13. Mean age of the patients was  $50.23 \pm 14.36$  years old and

the mean age of male group older than female group. Patient's age was divided according to age group, with an age range of 10 years for each group. Group with the most patients was 41 - 50 years age group and followed by 51 - 60 years age group. Most men were included in 51 - 60 years age group while most female were included in 41 - 50 years age group (**Table 2**).

### **Radiologic components**

All radiologic components consisted of pelvic measurement results. The Cohen's kappa test was carried out to determine the inter-observer agreement on the radiometric value's measurement with the obtained  $p = 0.000$  ( $p < 0.05$ ) and the calculated Cohen's Kappa coefficient ( $\kappa$ ) was determined to be 0.856. These results indicated that the two observers have strong agreement in the evaluation of all radiometric values. Pelvic radiometric measurement values were taken for the entire sample. Data were presented in the form of mean and standard deviation and further divided by sex. **Table 3** provided pelvic measurement results. Several variables were found to have a greater size for men than women i.e. ABS, AHS, bilateral IB, bilateral IH, RIL, PSL. Furthermore, the data were divided based on each component of pelvic measurements obtained as in **Figure 1**.

In this study, 19 out of 20 variables had significant differences ( $p < 0.05$ ) between male and female group. One variable that did not have a significant difference between male and female group was transverse variable diameter of sacral segment 1 variable ( $p = 0.180$ ). Variables that have significant differences were analyzed for their correlation strength using eta test. The results of the analysis can be seen in **Table 4**.

In this case, the highest correlation between variables was RIH, APOD, CPID, LIH, TPO, and SPA. The innominate height variable had a high correlation strength for both sides (left and right), therefore, the authors decided to take the left side of innominate height (LIH) of pelvis to avoid result duplication and artificial inflation of the calculation results in making statistical models. Variables that used for making statistical models with logistic regression were APOD, CPID, LIH, TPO, and SPA.

### **Making statistical models with logistic regression statistical analysis**

Multivariate calculations were performed using binomial logistic regression on four variables with the highest correlation strength. Logistic regression calculations are presented in **Table 5**. From **Table 5**, it can be seen that the variable with a significant value for further use in

logistic regression formula model from calibration group were CPID (p=0.035), LIH (p=0.001) and SPA (p=0.015).

The formula generated by logistic regression model from calibration group was obtained as follows:

$$\text{Sex} = (0,125 \times \text{CPID}) - (0,180 \times \text{LIH}) + (0,078 \times \text{SPA}) + 8,912$$

If the result > 0 the predicted sex is female, whereas, if the result < 0 the predicted sex is male.

### **Logistic regression model validity**

Logistic regression model was applied in the studied groups to determine the formula accuracy. Data of model validity were presented in **Table 6**. From logistic regression model calculation, a high validity value (91.05% accuracy) was found with 100% sensitivity to identify male and 81.1% specificity to identify female. A case illustration of using the regression formula in 43 year old female described in **Figure 2**.

### **Discussion**

Geographically and genetically isolated human groups were the sources of metric sex determination. One of them was based on display population-specific skeletal characteristics. Many of which are evident in the relative expression and magnitude of sexually dimorphic features [25-26]. In fact, each population has its special identification standard. Implementing visual or morphological techniques is the quick way to assess the samples. The weakness of this technique is in the sense of a very subjective assessment which requires an experienced observers or assessors and the level of accuracy is not guaranteed. Moreover, sexual dimorphism varies geographically. Therefore, forensic anthropologists are constantly trying to test the existing methods and developing standards that are more efficient and objective in which it can optimize the positive identification of the human skeleton. Numerous attempts at metric classification have been published, but often require complex or time-consuming measurements. However, while nonmetric methods are a quick means of assessment, they tend to be extremely subjective [25-29].

This study demonstrated the importance of an objective method utilizing radiological technology in human anthropometric determination in order to assist the analysis of sex determination. Medical image data provide the opportunity for high-end forensic analysis to be conducted outside the usual confines of traditional anthropological procedures. Imaging

modalities, e.g. CT, are extensively used in the diagnosis and treatment of patients in a clinical setting. Murail and his colleagues have developed a database called Probabilistic Sex Diagnosis (DSP: Diagnose Sexuelle Probabiliste) in 2005, a sex determination method based on a worldwide hip bone metrical database. CT scans of bones were then analysed to obtain three-dimensional (3D) virtual models then importing the models into a customised software programme. CT scan imaging of the above dry bones was performed to obtain three-dimensional (3D) virtual models. 3D models were obtained using a commercial software (Amira) allowing semi-automatic segmentation [20, 30].

This study utilized medical image data from a 16-slice CT scanner. The speed of CT and its ability was applied to demonstrate bony features without the need for soft tissue removal. In the extent to make it an ideal modality to reduce time evaluation and could avoid physical manipulation. The virtual model of the pelvis can be analysed out of contact with the actual bone. Therefore, the speed of the resulting virtual bone model and measurements make this method a practical alternative to traditional analyses [1-8]. This study was undertaken to investigate whether three-dimensional (3D) volumetric virtual models can be used in the estimation of sex from the pelvis and if they can, whether “metricizing” nonmetric sex estimation traits in the pelvis and utilizing current medicine indices will increase the accuracy and reliability of the data over current methods [3,4,6,10,11,17].

As a matter of fact, Asia consists of many countries and ethnics. This extent could result in many variations of body size. Unfortunately, the anthropometric studies that had been published were more likely discuss the coverage of European, North American and African population. Only few studies portrayed the characteristic data of Asians. In this study, the population of in the eastern part of Indonesia is expected to be a population representing of the pelvic shape of the Indonesian population.

The mean age of sample in this study was  $50.23 \pm 14.36$  years. Moreover, a study conducted by Kolesova et al, the pelvic size difference was associated with changes in age. Age-related changes observed in the study were carried out in linear parameters of pelvic cavity and confirmed the anterior tilt of sacral floor as well as more horizontal sacrum location relating to aging. This study also showed that there was no change in pelvic proportion to ischial height in female while the distance of transverse pelvic diameter shortens with age.[7] As it is stated

previously, age-related ankylosing processes decreased sacroiliac joints motility and facilitated these changes [8-10].

There were significant differences ( $p < 0.05$ ) on radiologic components measured between male and female except for transverse diameter of the sacral segment ( $p = 0.180$ ). These significant differences finding was similar to other studies in different populations which there were significant differences in pelvic measurements between the sexes [9,11]. In a study by Patriquin et al., they demonstrated significant sexual dimorphism in a population study on South Africa. This study reported differences in pelvic size between sexes as well as differences between races [9].

Furthermore, this study showed a significant difference in APOD measurement between male and female group. This result was in accordance to a study conducted by Kolesova and Vetra, that there was significant difference in APOD measurements of the two sexes [12]. The result obtained from our study provided a lower mean of APOD value than their study, but it was similar in the sense of APOD value for male due to the fact that it had lower mean than female. The measurement of CPID component in this study showed a higher value in female group.

In previous literature, male pelvic structure is significantly heavier and thicker than female. The male pelvis is also adjusted to fit in more massive and sturdy body architecture e.g. the male acetabulum has been designed to fit a larger femur. Even though most of pelvic sexual dimorphisms are due to size differences, sex-related shape variations are also very striking and cannot be considered as an allometric difference in body size between both sexes [13]. This variation in shape was indicated by a rounder frame of female pelvis. Sciatic indentation was wider in the sense of female. They have larger, shallower, lower, bigger pelvis and larger pelvic inlet and outlet (pubic bone is longer and curvature degree of pectineal line is greater). Therefore, women's pelvic bones also differ in characteristics related to sacroiliac joints position on the iliac bones [14].

The SPA measurement showed a significant difference between male and female group with high correlation strength. This result was in accordance to previous studies which concluded that SPA was the most reliable indicator of pelvic sex [15]. This was also in accordance to a study by Igbigbi and Msamati, who stated that the accuracy of SPA dimensions in determining sex was 94.7% for female and 95.5% for male [16]. Moreover, a similar result was also portrayed in a study by Mostafa, which showed a significant difference in SPA measurements

between both sexes [17]. Women's growths tend to increase during adolescence, especially in ischium and pubic areas, resulting in a larger pelvic outlet, longer pubic and a blunter SPA. This growth difference was related to sexual dimorphism associated to birth process [18-19].

The TPO measurement showed a significant difference in both sexes with high strength of correlation between male and female group. These findings were in accordance to previous studies which concluded that a significant difference was observed in transverse diameter of pelvic midplane and outlet. This could be explained by hormonal effects of pregnancy which result in pubic symphysis softening and pubic bone movement as wide as one cm, as a consequence there was an increase on pelvic diameter [12, 17-19]. Females tend to exhibit an increase in growth during the adolescent growth phase in the region of the pubis and ischium, which results in a longer pubis, a larger pelvic outlet, and a more obtuse subpubic angle. These differences in growth are related to the sexual dimorphism between males and females associated with parturition [18].

The significant differences in the radiological components of the pelvis measured in this study have desirable value in determining sex; however, we believed that using all components of the pelvic measurement as a sex-determining formula for the human skeleton is an inefficient concept. Therefore, the correlation strength test was carried out with the ETA test where it was seen that the variables had higher power than the others. **The APOD, CPID, LIH, SPA, and TPO were conducted through multivariate analysis using logistic regression in order to find significant variables and generate a formula that might determine a person's sex with high accuracy [19]. The CPID, LIH, and SPA components showed significant values in accordance to previous discussion. These three components consistently showed differences in sexual dimorphism in both sexes, especially SPA served as one of the high scoring factors consistently.** The APOD, CPID, LIH, SPA, and TPO were conducted through multivariate analysis using logistic regression in order to find significant variables and generate a formula that might determine a person's sex with high accuracy [19]. The CPID, LIH, and SPA components showed significant values in accordance to previous discussion. These three components consistently showed differences in sexual dimorphism in both sexes, especially SPA served as one of the high scoring factors consistently. This formula was able to provide a high overall validity (91.05% accuracy) with 100% sensitivity for male identification and 81.1% specificity for female identification. Nevertheless, these results need to be compared with previous studies in which they were able to



provide higher validity values that could reach 100% [3, 17]. This study showed that the estimated values of pelvic measurements using 3D-CT could give birth to a pelvic model with a formula that has a high accuracy value using CPID, LIH, and SPA values. These specific radiometric parameter obtained from this study has a positive impact for analyzing and describing the pelvic shape and size among male and female group population.

This study had some limitations in the extent of a complete and intact pelvis CT data; however, in some instance, the actual case remains that have been examined in the anthropological setting is incomplete or fragmented pelvic bone. Furthermore, the important aspect by taking advantage 3D software that could reconstruct the bone fragmentation in virtual space and the anthropometric measurement is highly possible to deliver in determining the human sex. Multicentric studies were needed to obtain a greater variety of data and produce more accurate data and formulas. In addition, an analytical study of previously published studies could compare differences in pelvic anthropometric values from different races and geographic areas.

## **Conclusion**

There were differences on radiometric variable characteristics in adult Indonesian's pelvic anthropometric study at Dr. Soetomo General Academic Hospital, Surabaya. The APOD, CPID, LIH, TPO, and SPA had the highest correlation between both sexes and had the greatest power than other components of the pelvic measurement for sex determination. The estimated values of pelvic measurements by using 3D CT images could develop a pelvic model with a regression formula with high accuracy value using CPID, LIH, and SPA values. The regression formula for sex determination on adults using 3D CT produces validity of 91.05%, sensitivity of 100% for male identification, and specificity of 81.1% for female identification.

## **Key Points**

1. There were differences on radiometric variable characteristics in pelvic anthropometric study among adult Indonesian at Dr. Soetomo General Academic Hospital, Surabaya.
2. A pelvic model is developed by pelvic measurements by using 3D CT images and resulting in a regression formula with high accuracy on CPID, LIH, and SPA values.
3. There were significant differences ( $p < 0.05$ ) on radiologic components measured between

male and female except for transverse diameter of the sacral segment ( $p = 0.180$ )

4. The regression formula for sex determination on adults using 3D CT produces validity of 91.05%, sensitivity of 100% for male identification, and specificity of 81.1% for female identification.

## References

1. Franklin, D., Cardini, A., Flavel, A. and Marks, M. K. 'Morphometric analysis of pelvic sexual dimorphism in a contemporary Western Australian population', *International Journal of Legal Medicine*, 2014. 128(5), pp. 861–872. <https://doi.org/10.1007/s00414-014-0999-8>
2. Grivas, C. R. and Komar, D. A. 'Kumho, Daubert, and the nature of scientific inquiry: Implications for forensic anthropology', *Journal of Forensic Sciences*, 2008. 53(4), pp. 771–776. <https://doi.org/10.1111/j.1556-4029.2008.00771.x>
3. Decker, S. J., Davy-Jow, S. L., Ford, J. M. and Hilbelink, D. R. 'Virtual Determination of Sex: Metric and Nonmetric Traits of the Adult Pelvis from 3D Computed Tomography Models', *Journal of Forensic Sciences*, 2011. 56(5), pp. 1107–1114. <https://doi.org/10.1111/j.1556-4029.2011.01803.x>
4. Zech, W. D., Hatch, G., Siegenthaler, L., Thali, M. J. and Lösch, S. 'Sex determination from os sacrum by postmortem CT', *Forensic Science International*, 2012. 221(1–3), pp. 39–43. <https://doi.org/10.1016/j.forsciint.2012.03.022>
5. Krishan, K., Chatterjee, P. M., Kanchan, T., Kaur, S., Baryah, N. and Singh, R. K. 'A review of sex estimation techniques during examination of skeletal remains in forensic anthropology casework', *Forensic Science International*. Elsevier Ireland Ltd, 2016. 261, pp. 165.e1-165.e8. <https://doi.org/10.1016/j.forsciint.2016.02.007>
6. Mahfouz, M., Badawi, A., Merkl, B., Fatah, E. E. A., Pritchard, E., Kesler, K., Moore, M., Jantz, R., Jantz, L. 'Patella sex determination by 3D statistical shape models and nonlinear classifiers', *Forensic Science International*, 2007. 173(2–3), pp. 161–170. <https://doi.org/10.1016/j.forsciint.2007.02.024>
7. Kolesova, O., Kolesovs, A. and Vetra, J. 'Age-related trends of lesser pelvic architecture in females and males: a computed tomography pelvimetry study', *Anatomy & Cell Biology*, 2017. 50(4), p. 265. <https://doi.org/10.5115/acb.2017.50.4.265>
8. Amonoo-Kuofi, U. S. 'Changes in the Lumbosacral Angle, Sacral Inclination and the Curvature of the Lumbar Spine during Aging', *Cells Tissues Organs*, 1992. 145(4), pp. 373–377. <https://doi.org/10.1159/000147392>
9. Patriquin, M. L., Steyn, M. and Loth, S. R. 'Metric analysis of sex differences in South African black and white pelvises', *Forensic Science International*, 2005. 147(2–3), pp. 119–127. <https://doi.org/10.1016/j.forsciint.2004.09.074>
10. Abdel Moneim, W. M., Abdel Hady, R. H., Abdel Maaboud, R. M., Fathy, H. M. and Hamed, A. M. 'Identification of Sex Depending on Radiological Examination of Foot

- and Patella', *The American Journal of Forensic Medicine and Pathology*, 2008. 29(2), pp. 136–140. <https://doi.org/10.1097/PAF.0b013e318173f048>
11. Mostafa, E. M. A., M. Dessouki, S. K., Hashish, R. K., M. Gad, A. A. and M. Khafagy, A. A. 'Adult Sex Identification Using Three-Dimensional Computed Tomography (3D-CT) of the Pelvis: A Study Among a Sample of the Egyptian Population', *Arab Journal of Forensic Sciences and Forensic Medicine*. 2016 <https://doi.org/10.12816/0026460>
  12. Kolesova, O. and Větra, J. 'Sexual dimorphism of pelvic morphology variation in live humans', *Papers on Anthropology*, 2012. 20, p. 209. <https://doi.org/10.12697/poa.2011.20.21>
  13. Jordaan, H. V 'The differential development of the hominid pelvis.', *South African medical journal = Suid-Afrikaanse tydskrif vir geneeskunde*, 1976. 50(19), pp. 744–8. Available at: <http://www.ncbi.nlm.nih.gov/pubmed/818723>.
  14. Leong, A. 'Sexual dimorphism of the pelvic architecture: a struggling response to destructive and parsimonious forces by natural & mate selection.', *McGill journal of medicine : MJM : an international forum for the advancement of medical sciences by students*, 2006 9(1),pp.61–6. <https://doi.org/10.26443/mjm.v9i1.602>  
Available at: <http://www.ncbi.nlm.nih.gov/pubmed/19529812>.
  15. Đurić, M., Rakočević, Z. and Đonić, D. 'The reliability of sex determination of skeletons from forensic context in the Balkans', *Forensic Science International*, 2005. 147(2–3), pp. 159–164. <https://doi.org/10.1016/j.forsciint.2004.09.111>
  16. Igbigbi, P. and Msamati, B. 'Sex determination from femoral head diameters in black Malawians', *East African Medical Journal*, 2009. 77(3). <https://doi.org/10.4314/eamj.v77i3.46611>
  17. Mostafa, E., Gad, A., Dessouki, S., Hashish, R. and Khafagy, A. 'Sex Determination Using Three-Dimensional Computed Tomography of Pelvis Measurements in Adult Egyptian population..', *European Journal of Forensic Sciences*, 2017. 4(2), p. 1. <https://doi.org/10.5455/ejfs.231267>
  18. Klales, A. R., Ousley, S. D. and Vollner, J. M. 'A revised method of sexing the human innominate using Phenice's nonmetric traits and statistical methods', *American Journal of Physical Anthropology*, 2012. 149(1), pp. 104–114. doi: <https://doi.org/10.1002/ajpa.22102>
  19. Ruriana I, Setiawati R., Prijambodo. 'Sex Identification Using Adult Pelvic 3D CT Scan: An Anthropometric Study', *International Journal of Research Publication*, 2021. 64(1), p. 143-148. <https://doi.org/10.47119/IJRP1006411120201537>
  20. Brůžek J, Santos F, Dutailly B, Murail P, and Cunha E. Validation and reliability of the sex estimation of the human os coxae using freely available DSP2 software for bioarchaeology and forensic anthropology. *Am J Phys Anthropol*. 2017. Oct;164(2):440-449. <https://doi.org/10.1002/ajpa.23282>
  21. Gonzalez, P. N., Bernal, V., & Perez, S. I. Geometric morphometric approach to sex estimation of human pelvis. *Forensic Science International*, 2009. 189(1-3), 68–74. <https://doi.org/10.1016/J.FORSCIINT.2009.04.012>
  22. Best, K. C. Garvin, H., Cabo, L. An Investigation into the Relationship between Human Cranial and Pelvic Sexual Dimorphism. *Journal of Forensic Sciences*. 2017.

- <https://doi.org/10.1111/1556-4029.13669>
23. Fischer, B, Mitteroecker, P. Allometry And Sexual Dimorphism In The Human Pelvis. *The Anatomical Record*, 2017. 300:698–705. <https://doi.org/10.1002/ar.23549>
  24. Ma, N., Hu, X., Tao, Z. et al. Application of a three-dimensional virtual model to study the effect of fluoroscopic angle on infra-acetabular corridor parameters and screw insertion rates. *J Orthop Surg Res*, 2021. 16, 574. <https://doi.org/10.1186/s13018-021-02730-w>
  25. Patriquin ML, Steyn M, Loth SR. Metric analysis of sex differences in South African black and white pelvises. *Forensic Sci Int* 2005;147:119– 27. 27. <https://doi.org/10.1016/j.forsciint.2004.09.074>
  26. Steyn M, Iscan MY. Metric sex determination from the pelvis in modern Greeks. *Forensic Sci Int* 2008;179:86.e1–6. 29. <https://doi.org/10.1016/j.forsciint.2008.04.022>
  27. Steyn M, Patriquin ML. Osteometric sex determination from the pelvis—does population specificity matter? *Forensic Sci Int* 2009;191: 113.e1–5. 30. <https://doi.org/10.1016/j.forsciint.2009.07.009>
  28. Wilson LA, MacLeod N, Humphrey LT. Morphometric criteria for sexing juvenile human skeletons using the ilium. *J Forensic Sci* 2008;53(2): 269–78. <https://doi.org/10.1111/j.1556-4029.2008.00656.x>
  29. Rissech C, Garcia M, Malgosa A. Sex and age diagnosis by ischium morphometric analysis. *Forensic Sci Int* 2003;135:188–96. 28. [https://doi.org/10.1016/s0379-0738\(03\)00215-9](https://doi.org/10.1016/s0379-0738(03)00215-9)
  30. Murail P, Bruzek J, Houët F, Cunha E. DSP: A tool for probabilistic sex diagnosis using worldwide variability in hip-bone measurements. *Bulletins et mémoires de la Société d'Anthropologie de Paris*, 2005:17 (3-4), 167-176. <https://doi.org/10.4000/bmsap.1157>
  31. Haak, D., Page, C.-E., and Deserno, T. M. A Survey of DICOM Viewer Software to Integrate Clinical Research and Medical Imaging. *Journal of Digital Imaging*, 2015 29(2), 206–215. <https://doi.org/10.1007/s10278-015-9833-1>
  32. Betti L. Sexual dimorphism in the size and shape of the os coxae and the effects of microevolutionary processes. *Am J Phys Anthropol* 2014;153:167–77. <https://doi.org/10.1002/ajpa.22410>

**Table 1.**

**Table 1. Pelvic Measurements Definition included in This Study**

No.	Measurement	Definition
1.	Anterior breadth of the sacrum (ABS)	The maximum transverse point of the sacrum on the anterior orientation of the auricular surface
2.	Anterior height of sacrum (AHS)	Distance between sacrum/coccygeal margin and sacral promontorium
3.	Anteroposterior pelvic outlet diameter (APOD)	Distance between inferior pubic symphysis and coccyx bone
4.	Conjugate pelvic inlet diameter (CPID)	Distance between superior pubic symphysis and sacral promontorium
5.	Left iliac breadth (LIB)	Distance between anterior superior iliac spine to superior posterior iliac spine (taken from the left side)
6.	Left ischium length (LIL)	Distance between the innermost point of ischial tuberosity and acetabular junction (taken from the left side)

7.	Left pubic length (LPL)	Distance between the superior point at pubic symphysis and acetabular junction (taken from the left side)
8.	Left width of greater sciatic notch (LGSN)	The line between iliac spine, the innermost part of greater sciatic notch, and ischial spine (taken from the left side)
9.	Left innominate height (LIH)	Distance between the most superior point of iliac crest and the lowest point of ischial tuberosity (taken from the left side)
10.	Pubic symphysis length (PSL)	Distance between the most superior and inferior points of pubic symphysis (taken from the left side)
11.	Right ischium length (RIL)	Distance between the innermost point of ischial tuberosity and acetabular junction (taken from the right side)
12.	Right pubic length (RPL)	Distance between the superior point at pubic symphysis and acetabular junction (taken from the right side)
13.	Right width of greater sciatic notch (RGSN)	The line between iliac spine, the innermost part of greater sciatic notch, and ischial spine (taken from the right side)
14.	Right iliac breadth (RIB)	Distance between anterior superior iliac spine to superior posterior iliac spine (taken from the right side)
15.	Right innominate height (RIH)	Distance between the most superior point of iliac crest and the lowest point of ischial tuberosity (taken from the right side)
16.	Sub pubic angle (SPA)	The angle formed by the point of iliac spine, the innermost part of great sciatic notch and ischial spine
17.	Transverse diameter of sacral segment1 (TDSS)	Distance between the two most lateral points of the first sacral segment
18.	Transverse pelvic inlet (TPI)	Distance between coccyx and inferior pubic symphysis
19.	Transverse pelvic outlet (TPO)	Distance between sacral promontorium and superior pubic symphysis
20.	Left IschPub Index	Pubic length (x100) divided with ischial length

**Table 2. Age Group of Patients**

Age group (years)	Sex		Total
	Male	Female	
11-20	2	3	5
21-30	7	10	17
31-40	10	11	21
41-50	27	32	59
51-60	31	16	47
61-70	25	21	46
71-80	3	1	4
81-90	3	2	5

**Table 3. The Mean and Standard Deviation of Radiometric Components**

Radiologic components	Male		Female		P Value
	Mean	Standard Deviation	Mean	Standard Deviation	

Anterior breadth of the sacrum (ABS)	95.89	7.90	91.98	13.44	0,004 <sup>a</sup>
Anterior height of sacrum (AHS)	102.86	8.99	100.25	9.00	0,034 <sup>b</sup>
Anteroposterior pelvic outlet diameter (APOD)	82.81	8.21	88.58	9.21	<0,001 <sup>b</sup>
Conjugate pelvic inlet diameter (CPID)	107.44	7.78	120.68	35.77	<0,001 <sup>a</sup>
Left iliac breadth (LIB)	116.97	9.79	113.85	11.59	<0,001 <sup>a</sup>
Left ischium length (LIL)	79.05	6.03	75.10	4.61	<0,001 <sup>a</sup>
Left pubic length (LPL)	66.04	6.25	66.79	4.13	0,021 <sup>a</sup>
Left width of greater sciatic notch (LGSN)	43.89	13.63	47.84	4.97	<0,001 <sup>a</sup>
Left innominate height (LIH)	197.53	7.91	178.66	20.03	<0,001 <sup>a</sup>
Pubic symphysis length (PSL)	29.71	3.45	28.46	3.00	0,011 <sup>a</sup>
Right ischium length (RIL)	79.29	5.82	73.73	10.84	<0,001 <sup>a</sup>
Right pubis length (RPL)	65.65	3.80	68.60	21.21	0,024 <sup>a</sup>
R width of greater sciatic notch (RGSN)	42.84	4.19	47.16	7.00	<0,001 <sup>a</sup>
Right iliac breadth (RIB)	117.69	5.28	112.70	9.24	<0,001 <sup>a</sup>
Right innominate height (RIH)	195.96	18.81	178.96	11.54	<0,001 <sup>a</sup>
Sub pubic angle (SPA)	99.69	11.78	128.01	14.43	<0,001 <sup>a</sup>
Transverse diameter of sacral segment 1(TDSS)	106.87	5.21	108.20	6.81	0,180 <sup>b*</sup>
Transverse pelvic inlet (TPI)	114.03	6.64	122.48	6.52	<0,001 <sup>b</sup>
Transverse pelvic outlet (TPO)	94.00	7.64	108.90	9.57	<0,001 <sup>a</sup>
Left IschPub Index (LIPI)	84.02	11.26	89.12	5.80	<0,001 <sup>a</sup>

<sup>a</sup>non-parametric difference test using mann-whitney test, <sup>b</sup>parametric difference test using t-test, \* not significant

**Table 4. Correlation Strength Test between Variables with Eta Test\***

Radiometric components	Eta value	p
Right iliac breadth (RIB)	0.231	0.447
Pubic symphysis length (PSL)	0.705	0.733
Right pubis length (RPL)	0.751	0.529
Left pubic length (LPL)	0.816	0.363
R width of greater sciatic notch	0.834	0.289
Left ischium length (LIL)	0.838	0.290
Left width of greater sciatic notch	0.847	0.428
Right ischium length (RIL)	0.855	0.378
Left iliac breadth (LIB)	0.857	0.239
Transverse pelvic inlet (TPI)	0.859	0.434
Anterior breadth of the sacrum (ABS)	0.883	0.427
Left IschPub Index	0.893	0.331
Anterior height of sacrum (AHS)	0.899	0.428

Right innominate height (RIH)	0.926	0.245
Anteroposterior pelvic outlet diameter (APOD)	0.955	0.154
Conjugate pelvic inlet diameter (CPID)	0.945	0.302
Left innominate height (LIH)	0.960	0.183
Transverse pelvic outlet (TPO)	0.972	0.120
Sub pubic angle (SPA)	0.982	0.204

\*The eta correlation test is used to measure the association between interval and nominal variables. This can also measure of effect size that is commonly used in ANOVA models

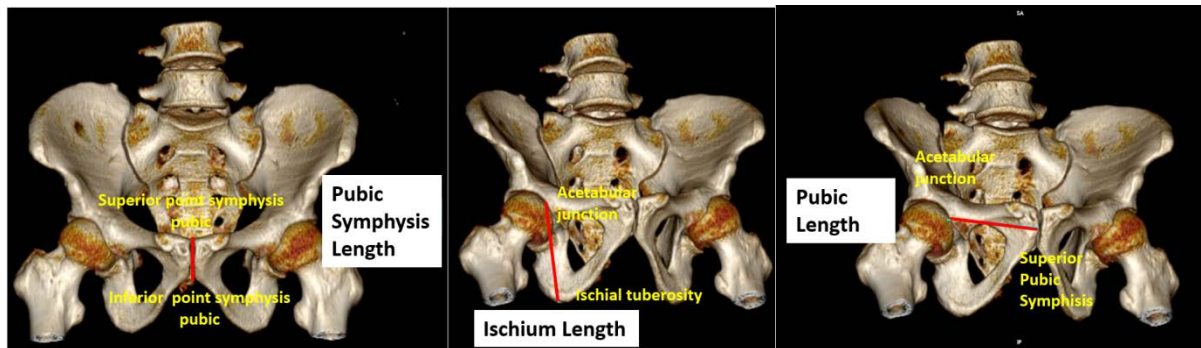
**Table 5. Logistic Regression Analysis of APOD, CPID, LIH, SPA and TPO in Calibration Group**

Variables	$\beta$	Wald <sup>a</sup>	p	OR <sup>b</sup>
APOD	0.038	0.678	0.410	1.038
CPID	0.125	4.443	0.035	1.133
LIH	-0.180	16.243	0.001	0.835
SPA	0.078	5.901	0.015	1.081
TPO	-0.007	4.443	0.864	0.993
Constant	8.912	0.976	0.323	7423.517

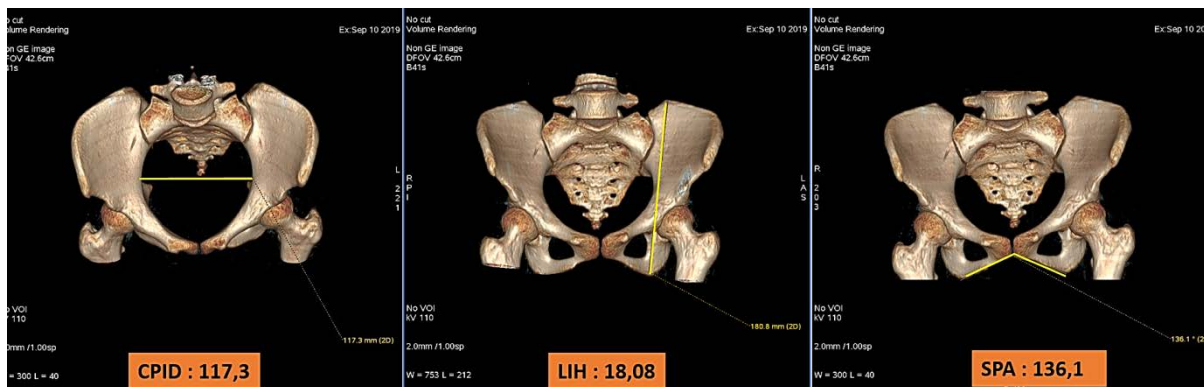
<sup>a</sup>Wald test is used to analyze the association between the independent variables (predictors) and the criterion variable (dependent) variable <sup>b</sup>OR is an abbreviation from Outcome Regression

**Table 6. Logistic Regression Formula Validity in Determining Sex of the Studied Groups**

Sex	Correct sex		n	p
	Male	Female		
<i>Sex prediction according to formula</i>				< 0.001
Male	40	5	45	
Female	0	23	23	
<b>Total</b>	<b>40</b>	<b>28</b>	<b>68</b>	
Sensitivity	100%			
Specificity		81.1%		
Total accuracy	91.05%			



**Figure 1.** Illustration of measuring the pubic symphysis length, ischium length, pubic length on 3D model of pelvic CT. Pubic symphysis length (PSL) is measured by distance between the most superior and inferior points, ischium length (IL) is measured by distance between the innermost point of ischial tuberosity and acetabular junction, as well as pubic length (PL) is measured by distance between the superior point at pubic symphysis and acetabular junction.



**Figure 2.** A case illustration of applying the regression formula using 3D Pelvic CT anthropometric parameters in 43 year old female patient. A total calculated value is 30.9, consistent with the sex of female pelvis.



---

**Re: Forensic Science, Medicine and Pathology, Article 526 -- for approval**

1 message

---

**Melissa Delgado** <melissa.delgado@springer.com>  
To: rosy setiawati <rosy-s@fk.unair.ac.id>

Tue, Sep 13, 2022 at 11:43 AM

Dear Dr. Rosy Setiawati,

This is to confirm receipt of your approval.

Thank you.

Best Regards,  
Sassa

---  
**Melissa T. Delgado**  
Production Coordinator  
Journals Production

**Springer Nature**  
T +639167525199  
[melissa.delgado@springer.com](mailto:melissa.delgado@springer.com)  
[www.springernature.com](http://www.springernature.com)

---  
Springer Nature is one of the world's leading global research, educational and professional publishers, created in May 2015 through the combination of Nature Publishing Group, Palgrave Macmillan, Macmillan Education and Springer Science+Business Media.

---

**From:** rosy setiawati <rosy-s@fk.unair.ac.id>  
**Sent:** Tuesday, September 13, 2022 11:29 AM  
**To:** Melissa Delgado <[melissa.delgado@springer.com](mailto:melissa.delgado@springer.com)>  
**Subject:** Re: Forensic Science, Medicine and Pathology, Article 526 -- for approval

**[External - Use Caution]**

Dear Sassa

Yes, I approve this attached manuscript as my final checking

Regards

Rosy

On Mon, Sep 12, 2022 at 7:29 PM Melissa Delgado <[melissa.delgado@springer.com](mailto:melissa.delgado@springer.com)> wrote:

Dear Dr. Rosy Setiawati,

Good day!

Please see attached corrected proofs for your final checking and approval.

Thank you.

Best Regards,  
Sassa

---

**Melissa T. Delgado**

Production Coordinator  
Journals Production

**Springer Nature**

T +639167525199

[melissa.delgado@springer.com](mailto:melissa.delgado@springer.com)

[www.springernature.com](http://www.springernature.com)

---

Springer Nature is one of the world's leading global research, educational and professional publishers, created in May 2015 through the combination of Nature Publishing Group, Palgrave Macmillan, Macmillan Education and Springer Science+Business Media.



# Anthropometric study using three-dimensional pelvic CT scan in sex determination among adult Indonesian population

Rosy Setiawati<sup>1</sup> · Paulus Rahardjo<sup>1</sup> · Ika Ruriana<sup>1</sup> · Giuseppe Guglielmi<sup>2,3</sup>

Accepted: 30 August 2022  
© The Author(s) 2022

## Abstract

This study aims to determine pelvic anthropometry characteristics and logistic regression formula for adult sex identification obtained from adult three-dimensional pelvic computed tomography images. This study was an observational analytical study with retrospective regression and cross-sectional approach. The population was all patients at Radiology Installation of Dr. Soetomo General Academic Hospital as referral hospital in East Indonesian region, from September to December 2019 who underwent 3D pelvic CT examination. Then, age distribution and pelvic measurements data were obtained. In this case, statistical analysis was conducted for all the data obtained. A number of 204 samples were included in this study. All radiologic components were also significantly different between sexes ( $p < 0.05$ ) except for transverse diameter of sacral segment ( $p = 0.180$ ). Moreover, the conjugate pelvic inlet diameter (CPID), the left innominate height (LIH), and sub pubic angle (SPA) showed significant values for regression formula to determine an adult's sex using 3D pelvic CT. The calculation result  $> 0$  is a prediction for female while  $< 0$  is a prediction for male. From logistic regression model calculation, a high validity value (91.05%) was found with 100% sensitivity to identify male sex and 81.1% specificity to identify female sex. There were differences on radiometric variable characteristics in pelvic anthropometric study among adult Indonesians at Dr. Soetomo General Academic Hospital, Surabaya. The estimated values of pelvic measurements using 3D CT images could develop a pelvic model with a regression formula with high accuracy value using CPID, LIH, and SPA values.

**Keywords** Sex determination · Sexual dimorphism · Anthropometric study · Pelvic 3D CT scan

## Abbreviations

ABS	Anterior breadth of the sacrum	LPL	Left pubic length
AHS	Anterior height of sacrum	LGSN	Left width of greater sciatic notch
APOD	Anteroposterior pelvic outlet diameter	LIH	Left innominate height
CPID	Conjugate pelvic inlet diameter	MIP	Maximum intensity projection
LIB	Left iliac breadth	NMDS	Non-metric multidimensional scaling
LIL	Left ischium length	PCoA	Principal coordinates analysis
		PSL	Pubic symphysis length
		RIL	Right ischium length
		RPL	Right pubis length
		PL	Pubic length
		RGSN	Right width of greater sciatic notch
		RIH	Right iliac breadth
		RIH	Right innominate height
		SPA	Sub pubic angle
		TDSS	Transverse diameter of sacral segment 1
		TPI	Transverse pelvic inlet
		TPO	Transverse pelvic outlet
		CT	Computed tomography
		MRI	Magnetic resonance imaging
		VR	Volume rendering

✉ Rosy Setiawati  
rosy-s@fk.unair.ac.id

Paulus Rahardjo  
paulus.r.rahardjo@gmail.com

Ika Ruriana  
rurianaika@gmail.com

Giuseppe Guglielmi  
giuseppe.guglielmi@unifg.it

<sup>1</sup> Radiology Department, Faculty of Medicine, Universitas Airlangga, Surabaya, Indonesia

<sup>2</sup> Department of Clinical and Experimental Medicine, School of Medicine, Foggia University, Foggia, Italy

<sup>3</sup> Department of Radiology, School of Medicine, Foggia University, Foggia, Italy

## Introduction

Sex identification on remaining human bone is the first step to do in helping forensic anthropologists to identify a person [1]. The accuracy of sex identification depends on bone components that are analyzed and the technique used. Forensic anthropology is a branch of applied physical anthropology that combines a variety of modified scientific techniques and skills from many scientific disciplines and is used to answer medico-legal related questions. Some of these techniques are quantitative and can be tested empirically, e.g., sex and age estimation technique from unidentified bone remains [2, 3].

In adults, the coxa is the most reliable indicator of sex because of its sexual dimorphism. Each population must have a specific identification standard [4]. Os coxae shows a broadly common pattern of sexual dimorphism across many regions in the world, and this pattern of pelvic sexual dimorphism appeared in early modern humans, approximately 100–150 years ago [5].

Accurate estimation of sex for adults is affected by the state of the individual preservation of bones, their degree of expression of sexual dimorphism, and methods employed. In some instances, metric methods are better than morphological ones [6]. For these reasons, a study which demonstrates the importance of an objective method by utilizing radiology technology in sex determination is needed. Although visual or morphological techniques are a quick way of assessment, they have the disadvantage of being highly subjective, requiring experienced observers and often not being able to guarantee accuracy. Without quantifiable data, there are clear implications for determining conclusive results that even the method cannot be used as a basis of reference [7].

Conventionally, anthropologists have relied on metric and non-metric observational analyses of actual bones [3]. One of the oldest methods known in anthropology is Procrustes analysis. Generalized Procrustes analysis standardizes the landmark configurations for variation in position, scale, and orientation. The resulting Procrustes shape coordinates represent the shape of the pelvis only, whereas information about the overall pelvis size is represented by the centroid size of the landmark configurations. They performed a principal component analysis (PCA) of the Procrustes shape coordinates, jointly for males and females. The dependence of pelvis shape on body size was estimated by multivariate linear regression of the Procrustes coordinates on body height, separately for males and females. However, these matrices must first be back-converted into an object-by-variable table by principal coordinates analysis (PCoA), non-metric multidimensional scaling (NMDS), or another suitable ordination method. In

general, its use seems desirable since the analysis of shape differences and landmark configuration will increase the likelihood of detecting more subtle local patterns, but the main disadvantage in this analysis is the increased computer time necessary to compute the necessary parameters [8, 9].

Over the past decade, modern cross-sectional imaging techniques have revolutionized forensic medicine. Virtual anthropology obtained by the 3D imaging techniques such as computer tomography (CT) allows us to visualize almost every anatomical and pathological bone structure with high resolution and quality. Multi-slice computed tomography (MSCT) is becoming more and more widely used for post-mortem examinations. CT provides data sources to examine modern human variation quantitatively when expanding the resources for osteological assessment to researchers. These studies have shown significant improvements in accuracy and reproducibility over conventional linear methods of constructing a person's biological profile [10, 11].

Various attempts have been made to be able to “metricize” or measure non-metric properties accurately in several body areas [11, 12]. More objective data for sex estimation might allow very accurate results along with metrication of certain non-metric pelvis areas [1]. Moreover, other pelvic indices such as those used in clinical medicine might be used to supplement and give additional measurements in anthropological assessment. In adults, pelvic bones are the most reliable indicator of sex because of its sexual dimorphism. Each population must have a special identification standard [3]. This study aims to determine pelvic anthropometry characteristics obtained from 3D pelvic CT in identifying sex among adult Indonesians in Dr. Soetomo General Academic Hospital, Surabaya, Indonesia.

## Materials and methods

### Study design

This study was an observational analytical study with retrospective regression and cross-sectional approach. This study was approved by Medical Research Ethic Committee of Dr. Soetomo General Academic Hospital, Surabaya, for ethical clearance with registration number 0106/LOF/301.4.2/VIII/2020. All participants included had given their written informed consent to participate in this study. Moreover, the population was all patients in Radiology Installation from September to December 2019 who underwent 3D pelvic CT examination. All methods were carried out in accordance with relevant guidelines and regulations.

## Sample of study

The sample of this study was 3D pelvic CT data which obtained from consecutive sampling that suited to the inclusion and exclusion criteria. The inclusion criteria were MIP and VR image reconstruction of 3D pelvic CT images of patients in the Radiology Installation, both male and female patient's age were more than 18 years old, and non-pregnant women. On the other hand, the exclusion criteria in this study was pelvic CT images of patient's pelvis and sacrum which had some pathological conditions, e.g., bone implant, chronic disease, bone fracture, osteoporosis, that might interfere the measurement.

## Study procedure

Pelvic CT scan examinations in the form of digital data served as study material. Furthermore, radiological

examination tool used a 16-slice Siemens SOMATOM CT scan machine in Radiology Installation of Dr. Soetomo Surabaya General Academic Hospital. The parameters that have been used in axial pelvic CT scans in this study were 120 kV, 140 effective mAs, 1.5 mm of slice collimation, 5.0 mm of slice width, 24.0 mm feed/rotation, 0.5 s rotation time, as well as the effective dose for male: 3.3 mSv and female: 4.8 mSv. 3D CT image began with the acquisition and reconstruction of axial image data. Furthermore, axial images were sent to the workstation (Siemens, Leonardo, Erlanger, Germany). MIP and VR images were obtained using reconstruction procedure on axial image. We obtained 3D images in optimal resolution and spatial resolution in all of the patients. The pelvic CT axial images were reconstructed to produce 3D pelvic CT images that were presented as DICOM (Digital Imaging and Communications in Medicine) images. Each patient's pelvic data was imported into Mimics software

**Table 1** Pelvic measurement definition included in this study

No.	Measurement	Definition
1.	Anterior breadth of the sacrum (ABS)	The maximum transverse point of the sacrum on the anterior orientation of the auricular surface
2.	Anterior height of sacrum (AHS)	Distance between sacrum/coccygeal margin and sacral promontorium
3.	Anteroposterior pelvic outlet diameter (APOD)	Distance between inferior pubic symphysis and coccyx bone
4.	Conjugate pelvic inlet diameter (CPID)	Distance between superior pubic symphysis and sacral promontorium
5.	Left iliac breadth (LIB)	Distance between anterior superior iliac spine to superior posterior iliac spine (taken from the left side)
6.	Left ischium length (LIL)	Distance between the innermost point of ischial tuberosity and acetabular junction (taken from the left side)
7.	Left pubic length (LPL)	Distance between the superior point at pubic symphysis and acetabular junction (taken from the left side)
8.	Left width of greater sciatic notch (LGSN)	The line between iliac spine, the innermost part of greater sciatic notch, and ischial spine (taken from the left side)
9.	Left innominate height (LIH)	Distance between the most superior point of iliac crest and the lowest point of ischial tuberosity (taken from the left side)
10.	Pubic symphysis length (PSL)	Distance between the most superior and inferior points of pubic symphysis (taken from the left side)
11.	Right ischium length (RIL)	Distance between the innermost point of ischial tuberosity and acetabular junction (taken from the right side)
12.	Right pubic length (RPL)	Distance between the superior point at pubic symphysis and acetabular junction (taken from the right side)
13.	Right width of greater sciatic notch (RGSN)	The line between iliac spine, the innermost part of greater sciatic notch, and ischial spine (taken from the right side)
14.	Right iliac breadth (RIB)	Distance between anterior superior iliac spine to superior posterior iliac spine (taken from the right side)
15.	Right innominate height (RIH)	Distance between the most superior point of iliac crest and the lowest point of ischial tuberosity (taken from the right side)
16.	Sub pubic angle (SPA)	The angle formed by the point of iliac spine, the innermost part of great sciatic notch and ischial spine
17.	Transverse diameter of sacral segment1 (TDSS)	Distance between the two most lateral points of the first sacral segment
18.	Transverse pelvic inlet (TPI)	Distance between coccyx and inferior pubic symphysis
19.	Transverse pelvic outlet (TPO)	Distance between sacral promontorium and superior pubic symphysis
20.	Left IschPub index	Pubic length ( $\times 100$ ) divided with ischial length

(Materialise, Leuven, Belgium) in DICOM format; the “CT Bone Segmentation” tool is used [13, 14].

All demographic data were obtained from medical records. The age distribution and pelvic measurements data were obtained as well in Table 1 [3]. Blinded pelvic measurements were performed by two observers, musculoskeletal radiologist consultants with more than 10 years of experience. Multiple pelvic measurements of each variable by observer were then obtained and determined the mean of radiometric values. In the inter-observer error test, the results of 10 measured specimens from each radiologist were compared. The inter-observer agreement was evaluated by the calculated Cohen’s kappa coefficient.

### Statistical analysis

Data analysis was performed using SPSS 23 statistics software. The mean of radiometric value from each observer was tested for inter-observer agreement. The inter-observer agreement was evaluated by Cohen’s kappa coefficient test, where  $p < 0.05$ . T-test analysis was used when the data was parametric; however, Mann–Whitney test was used when the data was non-parametric. The purpose was to determine a significant difference between sexes. The correlation strength analysis was conducted using eta test if there were significant differences. Moreover, the variable with the strongest correlation was tested to find the regression formula to determine an adult’s sex. Then, after the formula was determined, the variable was used to test the second observation group. Afterward, the validity and specificity were measured. Chi square test was conducted to determine correlation relationship.

## Results

### Study sample demography

There were 204 patients who were included in this study. Most of the samples were male with female-to-male ratio of 1:1.13. Mean age of the patients was  $50.23 \pm 14.36$  years old and the mean age of male group is older than female group. Patient’s age was divided according to age group, with an age range of 10 years for each group. Group with the most patients was 41–50 years age group and followed by 51–60 years age group. Most men were included in 51–60 years age group, while most females were included in 41–50 years age group (Table 2).

### Radiologic components

All radiologic components consisted of pelvic measurement results. The Cohen’s kappa test was carried out to

**Table 2** Age group of patients

Age group (years)	Sex		Total
	Male	Female	
11–20	2	3	5
21–30	7	10	17
31–40	10	11	21
41–50	27	32	59
51–60	31	16	47
61–70	25	21	46
71–80	3	1	4
81–90	3	2	5

determine the inter-observer agreement on the radiometric value’s measurement with the obtained  $p = 0.000$  ( $p < 0.05$ ) and the calculated Cohen’s Kappa coefficient ( $\kappa$ ) was determined to be 0.856. These results indicated that the two observers have strong agreement in the evaluation of all radiometric values. Pelvic radiometric measurement values were taken for the entire sample. Data were presented in the form of mean and standard deviation and further divided by sex. Table 3 provided pelvic measurement results. Several variables were found to have a greater size for men than women, i.e., ABS, AHS, bilateral IB, bilateral IH, RIL, PSL. Furthermore, the data were divided based on each component of pelvic measurements obtained as in Fig. 1.

In this study, 19 out of 20 variables had significant differences ( $p < 0.05$ ) between male and female groups. One variable that did not have a significant difference between male and female groups was transverse variable diameter of sacral segment 1 variable ( $p = 0.180$ ). Variables that have significant differences were analyzed for their correlation strength using eta test. The results of the analysis can be seen in Table 4.

In this case, the highest correlation between variables was RIH, APOD, CPID, LIH, TPO, and SPA. The innominate height variable had a high correlation strength for both sides (left and right); therefore, the authors decided to take the left side of innominate height (LIH) of pelvis to avoid result duplication and artificial inflation of the calculation results in making statistical models. Variables that used for making statistical models with logistic regression were APOD, CPID, LIH, TPO, and SPA.

### Making statistical models with logistic regression statistical analysis

Multivariate calculations were performed using binomial logistic regression on four variables with the highest correlation strength. Logistic regression calculations are presented in Table 5. From Table 5, it can be seen that the

**Table 3** The mean and standard deviation of radiometric components

Radiologic components	Male		Female		P value
	Mean	Standard deviation	Mean	Standard deviation	
Anterior breadth of the sacrum (ABS)	95.89	7.90	91.98	13.44	0.004 <sup>a</sup>
Anterior height of sacrum (AHS)	102.86	8.99	100.25	9.00	0.034 <sup>b</sup>
Anteroposterior pelvic outlet diameter (APOD)	82.81	8.21	88.58	9.21	<0.001 <sup>b</sup>
Conjugate pelvic inlet diameter (CPID)	107.44	7.78	120.68	35.77	<0.001 <sup>a</sup>
Left iliac breadth (LIB)	116.97	9.79	113.85	11.59	<0.001 <sup>a</sup>
Left ischium length (LIL)	79.05	6.03	75.10	4.61	<0.001 <sup>a</sup>
Left pubic length (LPL)	66.04	6.25	66.79	4.13	0.021 <sup>a</sup>
Left width of greater sciatic notch (LGSN)	43.89	13.63	47.84	4.97	<0.001 <sup>a</sup>
Left innominate height (LIH)	197.53	7.91	178.66	20.03	<0.001 <sup>a</sup>
Pubic symphysis length (PSL)	29.71	3.45	28.46	3.00	0.011 <sup>a</sup>
Right ischium length (RIL)	79.29	5.82	73.73	10.84	<0.001 <sup>a</sup>
Right pubis length (RPL)	65.65	3.80	68.60	21.21	0.024 <sup>a</sup>
R width of greater sciatic notch (RGSN)	42.84	4.19	47.16	7.00	<0.001 <sup>a</sup>
Right iliac breadth (RIB)	117.69	5.28	112.70	9.24	<0.001 <sup>a</sup>
Right innominate height (RIH)	195.96	18.81	178.96	11.54	<0.001 <sup>a</sup>
Sub pubic angle (SPA)	99.69	11.78	128.01	14.43	<0.001 <sup>a</sup>
Transverse diameter of sacral segment 1 (TDSS)	106.87	5.21	108.20	6.81	0.180 <sup>b*</sup>
Transverse pelvic inlet (TPI)	114.03	6.64	122.48	6.52	<0.001 <sup>b</sup>
Transverse pelvic outlet (TPO)	94.00	7.64	108.90	9.57	<0.001 <sup>a</sup>
Left IschPub index (LIPI)	84.02	11.26	89.12	5.80	<0.001 <sup>a</sup>

\* not significant

<sup>a</sup>Non-parametric difference test using Mann–Whitney test<sup>b</sup>parametric difference test using t-test

variables with a significant value for further use in logistic regression formula model from calibration group were CPID ( $p=0.035$ ), LIH ( $p=0.001$ ), and SPA ( $p=0.015$ ).

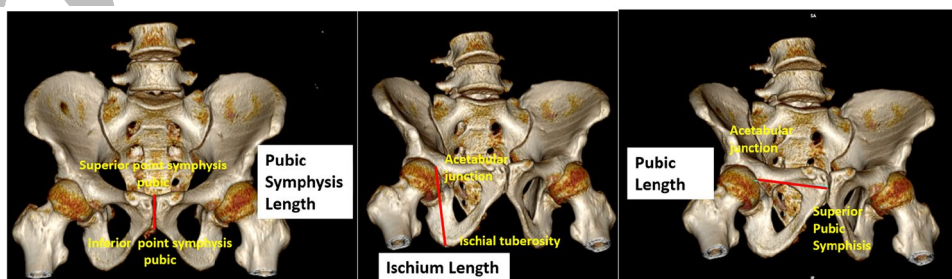
The formula generated by logistic regression model from calibration group was obtained as follows:

$$\text{Sex} = (0.125 \times \text{CPID}) - (0.180 \times \text{LIH}) + (0.078 \times \text{SPA}) + 8.912$$

If the result  $>0$ , the predicted sex is female; whereas, if the result  $<0$ , the predicted sex is male.

## Logistic regression model validity

Logistic regression model was applied in the studied groups to determine the formula accuracy. Data of model validity were presented in Table 6. From logistic regression model calculation, a high validity value (91.05% accuracy) was found with 100% sensitivity to identify male and 81.1% specificity to identify female. A case illustration of using the regression formula in 43-year-old female is described in Fig. 2.



**Fig. 1** Illustration of measuring the pubic symphysis length, ischium length, pubic length on 3D model of pelvic CT. Pubic symphysis length (PSL) is measured by distance between the most superior and inferior points, ischium length (IL) is measured by distance between

the innermost point of ischial tuberosity and acetabular junction, as well as pubic length (PL) is measured by distance between the superior point at pubic symphysis and acetabular junction

**Table 4** Correlation strength test between variables with eta test\*

Radiometric components	Eta value	<i>p</i>
Right iliac breadth (RIB)	0.231	0.447
Pubic symphysis length (PSL)	0.705	0.733
Right pubis length (RPL)	0.751	0.529
Left pubic length (LPL)	0.816	0.363
R width of greater sciatic notch	0.834	0.289
Left ischium length (LIL)	0.838	0.290
Left width of greater sciatic notch	0.847	0.428
Right ischium length (RIL)	0.855	0.378
Left iliac breadth (LIB)	0.857	0.239
Transverse pelvic inlet (TPI)	0.859	0.434
Anterior breadth of the sacrum (ABS)	0.883	0.427
Left IschPub index	0.893	0.331
Anterior height of sacrum (AHS)	0.899	0.428
Right innominate height (RIH)	0.926	0.245
Anteroposterior pelvic outlet diameter (APOD)	0.955	0.154
Conjugate pelvic inlet diameter (CPID)	0.945	0.302
Left innominate height (LIH)	0.960	0.183
Transverse pelvic outlet (TPO)	0.972	0.120
Sub pubic angle (SPA)	0.982	0.204

\*The eta correlation test is used to measure the association between interval and nominal variables. This can also measure of effect size that is commonly used in ANOVA models

## Discussion

Geographically and genetically isolated human groups were the sources of metric sex determination. One of them was based on display population-specific skeletal characteristics. Many of which are evident in the relative expression and magnitude of sexually dimorphic features [15, 16]. In fact, each population has its special identification standard. Implementing visual or morphological techniques is the quick way to assess the samples. The weakness of this technique is in the sense of a very subjective assessment which requires an experienced observers or assessors and the level

**Table 5** Logistic regression analysis of APOD, CPID, LIH, SPA, and TPO in calibration group

Variables	$\beta$	Wald <sup>a</sup>	<i>p</i>	OR <sup>b</sup>
APOD	0.038	0.678	0.410	1.038
CPID	0.125	4.443	0.035	1.133
LIH	-0.180	16.243	0.001	0.835
SPA	0.078	5.901	0.015	1.081
TPO	-0.007	4.443	0.864	0.993
Constant	8.912	0.976	0.323	7423.517

<sup>a</sup>Wald test is used to analyze the association between the independent variables (predictors) and the criterion variable (dependent) variable

<sup>b</sup>OR is an abbreviation from outcome regression

**Table 6** Logistic regression formula validity in determining sex of the studied groups

Sex	Correct sex		<i>n</i>	<i>p</i>
	Male	Female		
<i>Sex prediction according to formula</i>				<0.001
Male	40	5	45	
Female	0	23	23	
<b>Total</b>	40	28	68	
Sensitivity	100%			
Specificity		81.1%		
Total accuracy	91.05%			

91.05% accuracy was found with 100% sensitivity to identify male and 81.1% specificity to identify female

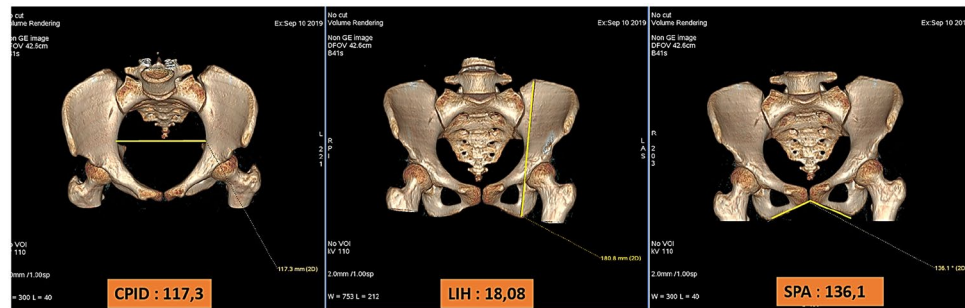
of accuracy is not guaranteed. Moreover, sexual dimorphism varies geographically. Therefore, forensic anthropologists are constantly trying to test the existing methods and developing standards that are more efficient and objective in which it can optimize the positive identification of the human skeleton. Numerous attempts at metric classification have been published, but often require complex or time-consuming measurements. However, while nonmetric methods are a quick means of assessment, they tend to be extremely subjective [15–19].

This study demonstrated the importance of an objective method utilizing radiological technology in human anthropometric determination in order to assist the analysis of sex determination. Medical image data provide the opportunity for high-end forensic analysis to be conducted outside the usual confines of traditional anthropological procedures. Imaging modalities, e.g., CT, are extensively used in the diagnosis and treatment of patients in a clinical setting. Murail and his colleagues have developed a database called Probabilistic Sex Diagnosis (DSP: Diagnose Sexuelle Probabiliste) in 2005, a sex determination method based on a worldwide hip bone metrical database. CT scans of bones were then analyzed to obtain three-dimensional (3D) virtual models then importing the models into a customized software program. CT scan imaging of the above dry bones was performed to obtain three-dimensional (3D) virtual models. 3D models were obtained using a commercial software (Amira) allowing semi-automatic segmentation [6, 20].

This study utilized medical image data from a 16-slice CT scanner. The speed of CT and its ability were applied to demonstrate bony features without the need for soft tissue removal, in the extent to make it an ideal modality to reduce time evaluation and could avoid physical manipulation. The virtual model of the pelvis can be analyzed out of contact with the actual bone. Therefore, the speed of the resulting virtual bone model and measurements make this method a practical alternative to traditional analyses [1–3, 10–12,



**Fig. 2** A case illustration of applying the regression formula using 3D pelvic CT anthropometric parameters in 43-year-old female patient. A total calculated value is 30.9, consistent with the sex of female pelvic



21, 22]. This study was undertaken to investigate whether three-dimensional (3D) volumetric virtual models can be used in the estimation of sex from the pelvis and if they can, whether “metricizing” nonmetric sex estimation traits in the pelvis and utilizing current medicine indices will increase the accuracy and reliability of the data over current methods [3, 4, 10, 12, 23, 24].

As a matter of fact, Asia consists of many countries and ethnics. This extent could result in many variations of body size. Unfortunately, the anthropometric studies that had been published more likely discuss the coverage of European, North American, and African population. Only few studies portrayed the characteristic data of Asians. In this study, the population of the eastern part of Indonesia is expected to be a population representing the pelvic shape of the Indonesian population.

The mean age of sample in this study was  $50.23 \pm 14.36$  years. Moreover, in a study conducted by Kolesova et al., the pelvic size difference was associated with changes in age. Age-related changes observed in the study were carried out in linear parameters of pelvic cavity and confirmed the anterior tilt of sacral floor as well as more horizontal sacrum location relating to aging. This study also showed that there was no change in pelvic proportion to ischial height in female, while the distance of transverse pelvic diameter shortens with age [21]. As it is stated previously, age-related ankylotic processes decreased sacroiliac joint motility and facilitated these changes [22, 23, 25].

There were significant differences ( $p < 0.05$ ) on radiologic components measured between males and females except for transverse diameter of the sacral segment ( $p = 0.180$ ). These significant difference finding was similar to other studies in different populations which there were significant differences in pelvic measurements between the sexes [4, 25]. In a study by Patriquin et al., they demonstrated significant sexual dysmorphism in a population study on South Africa. This study reported differences in pelvic size between sexes as well as differences between races [25].

Furthermore, this study showed a significant difference in APOD measurement between male and female groups. This result was in accordance to a study conducted by Kolesova and Vetra that there was significant difference in APOD

measurements of the two sexes [26]. The result obtained from our study provided a lower mean of APOD value than their study, but it was similar in the sense of APOD value for males due to the fact that it had lower mean than females. The measurement of CPID component in this study showed a higher value in female group.

In previous literature, male pelvic structure is significantly heavier and thicker than females. The male pelvis is also adjusted to fit in more massive and sturdy body architecture, e.g., the male acetabulum has been designed to fit a larger femur. Even though most of pelvic sexual dimorphisms are due to size differences, sex-related shape variations are also very striking and cannot be considered an allometric difference in body size between both sexes [27]. This variation in shape was indicated by a rounder frame of female pelvis. Sciatic indentation was wider in the sense of females. They have larger, shallower, lower, bigger pelvis and larger pelvic inlet and outlet (pubic bone is longer and curvature degree of pectineal line is greater). Therefore, women’s pelvic bones also differ in characteristics related to sacroiliac joint position on the iliac bones [28].

The SPA measurement showed a significant difference between male and female groups with high correlation strength. This result was in accordance to previous studies which concluded that SPA was the most reliable indicator of pelvic sex [29]. This was also in accordance to a study by Igbigbi and Msamati, who stated that the accuracy of SPA dimensions in determining sex was 94.7% for females and 95.5% for males [30]. Moreover, a similar result was also portrayed in a study by Mostafa, which showed a significant difference in SPA measurements between both sexes [24]. Women’s growths tend to increase during adolescence, especially in ischium and pubic areas, resulting in a larger pelvic outlet, longer pubic, and a blunter SPA. This growth difference was related to sexual dimorphism associated with birth process [31, 32].

The TPO measurement showed a significant difference in both sexes with high strength of correlation between male and female groups. These findings were in accordance to previous studies which concluded that a significant difference was observed in transverse diameter of pelvic midplane and outlet. This could be explained by hormonal

effects of pregnancy which result in pubic symphysis softening and pubic bone movement as wide as 1 cm, as a consequence there was an increase on pelvic diameter [24, 26, 31, 32]. Females tend to exhibit an increase in growth during the adolescent growth phase in the region of the pubis and ischium, which results in a longer pubis, a larger pelvic outlet, and a more obtuse subpubic angle. These differences in growth are related to the sexual dimorphism between males and females associated with parturition [31].

The significant differences in the radiological components of the pelvis measured in this study have desirable value in determining sex; however, we believed that using all components of the pelvic measurement as a sex-determining formula for the human skeleton is an inefficient concept. Therefore, the correlation strength test was carried out with the ETA test where it was seen that the variables had higher power than the others. The APOD, CPID, LIH, SPA, and TPO were conducted through multivariate analysis using logistic regression in order to find significant variables and generate a formula that might determine a person's sex with high accuracy [32]. The CPID, LIH, and SPA components showed significant values in accordance to previous discussion. These three components consistently showed differences in sexual dimorphism in both sexes, especially SPA served as one of the high scoring factors consistently. The APOD, CPID, LIH, SPA, and TPO were conducted through multivariate analysis using logistic regression in order to find significant variables and generate a formula that might determine a person's sex with high accuracy [32]. The CPID, LIH, and SPA components showed significant values in accordance to previous discussion. These three components consistently showed differences in sexual dimorphism in both sexes, especially SPA served as one of the high scoring factors consistently. This formula was able to provide a high overall validity (91.05% accuracy) with 100% sensitivity for male identification and 81.1% specificity for female identification. Nevertheless, these results need to be compared with previous studies in which they were able to provide higher validity values that could reach 100% [3, 24]. This study showed that the estimated values of pelvic measurements using 3D-CT could give birth to a pelvic model with a formula that has a high accuracy value using CPID, LIH, and SPA values. These specific radiometric parameter obtained from this study has a positive impact for analyzing and describing the pelvic shape and size among male and female group population.

This study had some limitations in the extent of a complete and intact pelvis CT data; however, in some instance, the actual case remains that have been examined in the anthropological setting are incomplete or fragmented pelvic bone. Furthermore, the important aspect by taking advantage 3D software that could reconstruct the bone fragmentation in virtual space and the anthropometric

measurement is highly possible to deliver in determining the human sex. Multicentric studies were needed to obtain a greater variety of data and produce more accurate data and formulas. In addition, an analytical study of previously published studies could compare differences in pelvic anthropometric values from different races and geographic areas.

## Conclusion

There were differences on radiometric variable characteristics in adult Indonesian's pelvic anthropometric study at Dr. Soetomo General Academic Hospital, Surabaya. The APOD, CPID, LIH, TPO, and SPA had the highest correlation between both sexes and had the greatest power than other components of the pelvic measurement for sex determination. The estimated values of pelvic measurements by using 3D CT images could develop a pelvic model with a regression formula with high accuracy value using CPID, LIH, and SPA values. The regression formula for sex determination on adults using 3D CT produces validity of 91.05%, sensitivity of 100% for male identification, and specificity of 81.1% for female identification.

## Key Points

1. There were differences on radiometric variable characteristics in pelvic anthropometric study among adult Indonesian at Dr. Soetomo General Academic Hospital, Surabaya.
2. A pelvic model is developed by pelvic measurements by using 3D CT images and resulting in a regression formula with high accuracy on CPID, LIH, and SPA values.
3. There were significant differences ( $p < 0.05$ ) on radiologic components measured between males and females except for transverse diameter of the sacral segment ( $p = 0.180$ )
4. The regression formula for sex determination on adults using 3D CT produces validity of 91.05%, sensitivity of 100% for male identification, and specificity of 81.1% for female identification.

**Author contribution** Rosy Setiawati: Conceived and designed the analysis; contributed data or analytic tools; performed the analysis; wrote the paper. Paulus Rahardjo: Collected the data, contributed data or analytic tools; performed the analysis. Ika Ruriana: Collected the data; contributed data or analytic tools; wrote the paper. Giuseppe Guglielmi: Conceived and designed the analysis; contributed data or analytic tools; performed the analysis; wrote the paper.

**Data availability** The data that support the findings of this study are available from the corresponding author.

## Declarations

**Ethics approval** This study was approved by Medical Research Ethic Committee of Dr. Soetomo General Academic Hospital, Surabaya for ethical clearance with registration number: 0106/LOF/301.4.2/VIII/2020. All participants included had given their written informed consent to participate in this study.

**Consent to participate** All participants consented to participate in the survey.

**Conflict of interest** The authors declare no competing interests.

**Open Access** This article is licensed under a Creative Commons Attribution 4.0 International License, which permits use, sharing, adaptation, distribution and reproduction in any medium or format, as long as you give appropriate credit to the original author(s) and the source, provide a link to the Creative Commons licence, and indicate if changes were made. The images or other third party material in this article are included in the article's Creative Commons licence, unless indicated otherwise in a credit line to the material. If material is not included in the article's Creative Commons licence and your intended use is not permitted by statutory regulation or exceeds the permitted use, you will need to obtain permission directly from the copyright holder. To view a copy of this licence, visit <http://creativecommons.org/licenses/by/4.0/>.

## References

- Franklin D, Cardini A, Flavel A, Marks MK. Morphometric analysis of pelvic sexual dimorphism in a contemporary Western Australian population. *Int J Legal Med.* 2014;128(5):861–72. <https://doi.org/10.1007/s00414-014-0999-8>.
- Grivas CR, Komar DA. Kumho, Daubert, and the nature of scientific inquiry: Implications for forensic anthropology. *J Forensic Sci.* 2008;53(4):771–6. <https://doi.org/10.1111/j.1556-4029.2008.00771.x>.
- Decker SJ, Davy-Jow SL, Ford JM, Hilbelink DR. Virtual determination of sex: metric and nonmetric traits of the adult pelvis from 3D computed tomography models. *J Forensic Sci.* 2011;56(5):1107–14. <https://doi.org/10.1111/j.1556-4029.2011.01803.x>.
- Mostafa E, Dessouki SK, Hashish RK, Gad AM, Khafagy AA. Adult sex identification using three-dimensional computed tomography (3D-CT) of the pelvis: a study among a sample of the Egyptian population. *Arab Journal of Forensic Sciences and Forensic Medicine.* 2016. <https://doi.org/10.12816/0026460>.
- Betti L. Sexual dimorphism in the size and shape of the os coxae and the effects of microevolutionary processes. *Am J Phys Anthropol.* 2014;153:167–77. <https://doi.org/10.1002/ajpa.22410>.
- Brůžek J, Santos F, Dutailly B, Murail P, Cunha E. Validation and reliability of the sex estimation of the human os coxae using freely available DSP2 software for bioarchaeology and forensic anthropology. *Am J Phys Anthropol.* 2017;164(2):440–449. <https://doi.org/10.1002/ajpa.23282>.
- Gonzalez PN, Bernal V, Perez SI. Geometric morphometric approach to sex estimation of human pelvis. *Forensic Sci Int.* 2009;189(1–3):68–74. <https://doi.org/10.1016/J.FORSCIINT.2009.04.012>.
- Best KC, Garvin H, Cabo L. An investigation into the relationship between human cranial and pelvic sexual dimorphism. *J Forensic Sci.* 2017. <https://doi.org/10.1111/1556-4029.13669>.
- Fischer B, Mitteroecker P. Allometry and sexual dimorphism in the human pelvis. *Anat Rec.* 2017;300:698–705. <https://doi.org/10.1002/ar.23549>.
- Zech WD, Hatch G, Siegenthaler L, Thali MJ, Löscher S. Sex determination from os sacrum by postmortem CT. *Forensic Sci Int.* 2012;221(1–3):39–43. <https://doi.org/10.1016/j.forsciint.2012.03.022>.
- Krishan K, Chatterjee PM, Kanchan T, Kaur S, Baryah N, Singh RK. A review of sex estimation techniques during examination of skeletal remains in forensic anthropology casework. *Forensic Science International Elsevier Ireland Ltd.* 2016;261:165.e1–165.e8. <https://doi.org/10.1016/j.forsciint.2016.02.007>.
- Mahfouz M, Badawi A, Merkl B, Fatah EEA, Pritchard E, Kesler K, Moore M, Jantz R, Jantz L. Patella sex determination by 3D statistical shape models and nonlinear classifiers. *Forensic Sci Int.* 2007;173(2–3):161–70. <https://doi.org/10.1016/j.forsciint.2007.02.024>.
- Ma N, Hu X, Tao Z, et al. Application of a three-dimensional virtual model to study the effect of fluoroscopic angle on infra-acetabular corridor parameters and screw insertion rates. *J Orthop Surg Res.* 2021;16:574. <https://doi.org/10.1186/s13018-021-02730-w>.
- Haak D, Page C-E, Deserno TM. A survey of DICOM Viewer Software to integrate clinical research and medical imaging. *J Digit Imaging.* 2015;29(2):206–15. <https://doi.org/10.1007/s10278-015-9833-1>.
- Patriquin ML, Steyn M, Loth SR. Metric analysis of sex differences in South African black and white pelvises. *Forensic Sci Int.* 2005;147(119–27):27. <https://doi.org/10.1016/j.forsciint.2004.09.074>.
- Steyn M, Iscan MY. Metric sex determination from the pelvis in modern Greeks. *Forensic Sci Int.* 2008;179:86.e1–6. 29. <https://doi.org/10.1016/j.forsciint.2008.04.022>.
- Steyn M, Patriquin ML. Osteometric sex determination from the pelvis—does population specificity matter? *Forensic Sci Int.* 2009;191:113.e1–5. 30. <https://doi.org/10.1016/j.forsciint.2009.07.009>.
- Wilson LA, MacLeod N, Humphrey LT. Morphometric criteria for sexing juvenile human skeletons using the ilium. *J Forensic Sci.* 2008;53(2):269–78. <https://doi.org/10.1111/j.1556-4029.2008.00656.x>.
- Rissech C, Garcia M, Malgosa A. Sex and age diagnosis by ischium morphometric analysis. *Forensic Sci Int.* 2003;135(188–96):28. [https://doi.org/10.1016/s0379-0738\(03\)00215-9](https://doi.org/10.1016/s0379-0738(03)00215-9).
- Murail P, Bruzek J, Houët F, Cunha E. DSP: a tool for probabilistic sex diagnosis using worldwide variability in hip-bone measurements. *Bulletins et mémoires de la Société d'Anthropologie de Paris.* 2005;17(3–4):167–76. <https://doi.org/10.4000/bmsap.1157>.
- Kolesova O, Kolesovs A, Vetra J. Age-related trends of lesser pelvic architecture in females and males: a computed tomography pelvimetry study. *Anatomy & Cell Biology.* 2017;50(4):265. <https://doi.org/10.5115/acb.2017.50.4.265>.
- Amonoo-Kuofi US. Changes in the lumbosacral angle, sacral inclination and the curvature of the lumbar spine during aging. *Cells Tissues Organs.* 1992;145(4):373–7. <https://doi.org/10.1159/000147392>.
- Abdel Moneim WM, Abdel Hady RH, Abdel Maaboud RM, Fathy HM, Hamed AM. Identification of sex depending on radiological examination of foot and patella. *Am J Forensic Med Pathol.* 2008;29(2):136–40. <https://doi.org/10.1097/PAF.0b013e318173f048>.
- Mostafa E, Gad A, Dessouki S, Hashish R, Khafagy A. Sex determination using three-dimensional computed tomography of pelvis measurements in adult Egyptian population. *Forensic Sci Int.* 2017;4(2):1. <https://doi.org/10.5455/ejfs.231267>.

25. Patriquin ML, Steyn M, Loth SR. Metric analysis of sex differences in South African black and white pelvis. *Forensic Sci Int*. 2005;147(2–3):119–27. <https://doi.org/10.1016/j.forsciint.2004.09.074>.
26. Kolesova O, Větra J. Sexual dimorphism of pelvic morphology variation in live humans. *Papers on Anthropology*. 2012;20:209. <https://doi.org/10.12697/poa.2011.20.21>.
27. Jordaan HV. The differential development of the hominid pelvis. *S Afr Med J*. 1976; 50(19):744–8. Available at: <http://www.ncbi.nlm.nih.gov/pubmed/818723>.
28. Leong A. Sexual dimorphism of the pelvic architecture: a struggling response to destructive and parsimonious forces by natural & mate selection. *McGill journal of medicine: MJM: an international forum for the advancement of medical sciences by students*, 2006;9(1):61–6. <https://doi.org/10.26443/mjm.v9i1.602>. Available at: <http://www.ncbi.nlm.nih.gov/pubmed/19529812>. Accessed 21 Jan 2020.
29. Đurić M, Rakočević Z, Đonić D. The reliability of sex determination of skeletons from forensic context in the Balkans. *Forensic Sci Int*. 2005;147(2–3):159–64. <https://doi.org/10.1016/j.forsciint.2004.09.111>.
30. Igbigbi P, Msamati B. Sex determination from femoral head diameters in black Malawians. *East Afr Med J*. 2009;77(3). <https://doi.org/10.4314/eamj.v77i3.46611>.
31. Klales AR, Ousley SD, Vollner JM. A revised method of sexing the human innominate using Phenice's nonmetric traits and statistical methods. *Am J Phys Anthropol*. 2012;149(1):104–14. <https://doi.org/10.1002/ajpa.22102>.
32. Ruriana I, Setiawati R. Sex identification using adult pelvic 3D CT scan: an anthropometric study. *Int J Res Publication*. 2021;64(1):143–148. <https://doi.org/10.47119/IJRP100641120201537>.

**Publisher's Note** Springer Nature remains neutral with regard to jurisdictional claims in published maps and institutional affiliations.