

Morphology of Humeral Head and Glenoid in Normal

by Heri Suroto

Submission date: 02-Apr-2023 05:12AM (UTC+0800)

Submission ID: 2053018499

File name: Morphology_of_Humeral_Head_and_Glenoid_in_Normal.pdf (2.34M)

Word count: 6457

Character count: 30904

Morphology of Humeral Head and Glenoid in Normal Shoulder of Indonesian Population

Heri Suroto¹, Daniel Licindo¹, Pramono Ari Wibowo¹, Goklas Ridwan Ricardo Gultom¹, Dina Aprilya², Rosy Setiawati³, Steven Samijo⁴

¹Department of Orthopaedic & Traumatology, Dr. Soetomo General Academic Hospital / Faculty of Medicine, Universitas Airlangga, Surabaya, Indonesia; ²Orthopaedic & Traumatology, Indonesian Association for Upper Limb and Microsurgery, Jakarta, Indonesia; ³Department of Radiology, Dr Soetomo General Academic Hospital / Faculty of Medicine, Universitas Airlangga, Surabaya, Indonesia; ⁴Department of Orthopaedic Surgery and Traumatology, Zuyderland Medisch Centrum, Heerlen, Netherlands

Correspondence: Heri Suroto, Department of Orthopaedic & Traumatology, Dr. Soetomo General Academic Hospital / Faculty of Medicine, Universitas Airlangga, Mayjen Prof. Dr. Moestopo Street No. 47, Surabaya, East Java, 60132, Indonesia, Tel +62 31 5020251, Fax +62 31 5022472, Email heri-suroto@fk.unair.ac.id

Purpose: Shoulder prostheses designed and used around the world may not fit an Asian shoulder. Normal shoulder morphology in Asian population had been reported, ie, Chinese, Indian, Japanese, and Thai populations, but no data from the Indonesian population. The aim of this study was to evaluate the three-dimensional (3D) morphology of the glenohumeral joint in the normal Indonesian population, identify its normal values, and compare them with those of other populations in the literature.

Patients and Methods: Images for analysis were computed tomography (CT) scans of 85 normal shoulders from 71 patients who had CT scans for another diagnosis. Morphometry of the humeral head and glenoid were measured using 3D reconstruction. Gender differences and correlations between age, height, and glenohumeral morphometry were evaluated. Indonesians' glenohumeral morphometry was compared with those of other populations in the literature.

Results: In the normal Indonesian population, the mean of humeral head inclination (HHI), height (HHH), diameter in sagittal plane (DS), diameter in frontal plane (DF), radius of curvature in sagittal plane (RS), and radius of curvature in frontal plane (RF) were 134.1°, 15.6mm, 39.3mm, 41.3mm, 20.4mm, and 21.4mm, respectively. The glenoid height (GH), upper width (GUW), lower width (GLW), inclination (GI), and version (GV) mean values were 34.2mm, 18.4mm, 24.5mm, 74.0mm, and 12.3mm, respectively. There was a significant difference in HHH, DS, DF, RS, RF, GH, GUW, GLW between males and females. Except for HHI and GI, glenohumeral morphometry was correlated with patient height. Age was not correlated with any glenohumeral morphometry.

Conclusion: In the Indonesian population, males had a larger humeral head and glenoid than females, and the size of the humeral head and glenoid was correlated to body height. Indonesians' humeral head and glenoid sizes were smaller than those of Western populations, but close to those of other Asian populations.

Keywords: head humerus, glenoid, Asian shoulder, CT shoulder, Indonesian shoulder morphology

Introduction

Shoulder arthroplasty as a treatment option for shoulder pathologies is gaining popularity for the last few decades. In the United States, the number of total shoulder arthroplasty procedures has increased by 1373% from 1997 to 2016, and it is estimated to continue increasing.¹ Prosthetic design plays an important role in improving the clinical outcomes of shoulder arthroplasty. The design of the shoulder prostheses must consider the normal anatomical morphology of the glenohumeral joint itself in order to restore normal shoulder function. Studies using three-dimensional (3D) geometry and morphology of the normal human glenohumeral shoulder in different races showed that there were racial differences in glenohumeral dimensions.²⁻⁸ Shoulder prostheses, which are designed based on European and American populations, had been reported not to fit Asian shoulders.^{3,7-9} There is also no guarantee that shoulder prostheses, which were designed using other Asian populations' morphometry, will be suitable for Indonesian shoulders.

Normal shoulder morphology in Asian population had been reported for Chinese⁷⁻⁹, Japanese^{5,10}, Thai² and Indian⁶ populations. However, the details of the normal glenohumeral joints in Indonesian population have not been reported. The aim of this study was to evaluate the three-dimensional (3D) morphology of the glenohumeral joint in the normal Indonesian population, identify its normal values, and compare them with those of other populations in the literature. The hypothesis was that the normal value of Indonesian glenohumeral morphometry were smaller than Western populations, but close to other Asian populations.

Materials and Methods

Images for analysis were collected from computed tomography (CT) scans of patients with normal shoulder who underwent chest CT scans for other medical reasons at Dr. Soetomo General Hospital Surabaya, Indonesia. Only chest CT scans with fully visualized shoulder joints were included in this study. Subjects with past illnesses, injuries, deformities, or degenerative processes of the shoulder joint were excluded. Patient characteristics such as gender, age, weight, height, and medical diagnosis were collected from medical records.

High-resolution CT (HRCT) of the chest was performed using a 64-slice MDCT scanner. Thin-slice images were obtained and post-processed in a high-spatial-frequency algorithm for bone multi-planar reconstruction. Ford and Decker's¹¹ study discovered that when attempting 3D reconstructions of anatomical features or other fine details, a maximum slice thickness of 1.25 mm is recommended. This standard requirement has been fulfilled in our study since the slice thickness in HRCT of the chest ranged between 0.625–1.25 mm.¹² Glenohumeral morphometry was measured using 3D reconstruction of the shoulder joint. The study protocol was approved by the Health Research Ethics Committee of our hospital (certificate number: 1724/KEPK/XII/2019).

Morphometry Measurement

Humeral head morphometries evaluated in this study were humeral head height, inclination diameter in frontal and sagittal planes, and radius of curvature in frontal and sagittal planes. Humeral head height (HHH) was defined as the distance between the humeral head base at the anatomical neck and the furthest point from it at the humeral head articular surface (Figure 1A).

Humeral head is not a perfect sphere, and there is a mismatch in the frontal and sagittal planes.^{3,7,13-15} The Humphrey et al¹⁴ study found that the elliptical shape of the base of the humeral head seemed to elongate in the frontal plane as head size increased. Humeral head diameter was defined as the diameter of the humeral head at its base. Superior-inferior distance was measured in the frontal plane (DF), while the anterior-posterior distance was measured in the sagittal plane (DS) (Figure 1B).

Radius of curvature was defined as a line drawn from the center of the humeral head to the furthest point on the humeral head surface. Radius of curvature was also measured in the frontal (RF) and sagittal (RS) planes. Humeral head inclination (HHI) is the angle between the humeral head axis and the humeral shaft axis. The humeral head axis is a line drawn perpendicular to the anatomical neck plane, while the humeral shaft axis is a best-fit line through the center of the humeral shaft.

Glenoid morphometries in this study were glenoid inclination, height, width, and version. Glenoid height (GH) was the distance between the highest and the lowest point on the glenoid (Figure 2A). Various shapes of the glenoid cavity made the anterior-posterior distance between the upper half and the lower half of the glenoid cavity were different. This study used glenoid upper and lower width terms to measure those distances. Glenoid upper width (GUW) was defined as the anterior-posterior distance of the upper half of the glenoid cavity at the midpoint between the mid-equator and the superior edge. The maximum width of the glenoid cavity was usually found in the lower half part and not always in the midpoint between the mid-equator and the inferior edge. This is why the glenoid lower width (GLW) was defined as the maximum distance between the most anterior and most posterior points in the lower half of the glenoid cavity.

Many different methods were used to measure both the glenoid inclination and the glenoid version. In our study, the glenoid inclination (GI) was measured using the β angle, which was the most reproducible measurement for glenoid inclination as described by Maurer et al¹⁶ The β angle was defined as the angle between a line connecting the superior-inferior glenoid edges and a line drawn through the floor of supraspinatus fossa (Figure 2B). The glenoid version (GV)

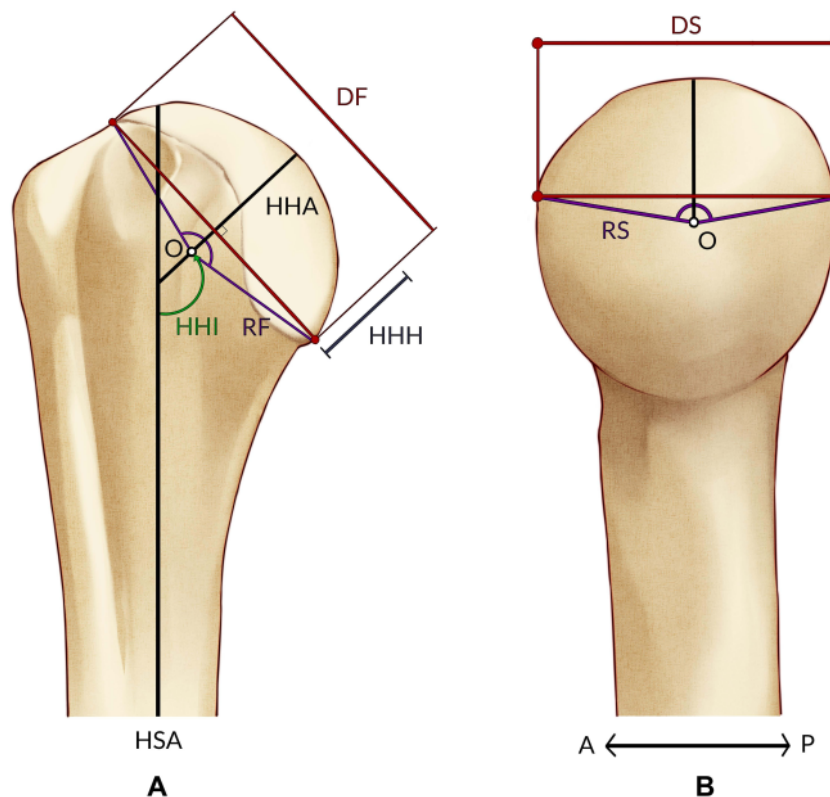


Figure 1 Humeral head measurement in (A) Frontal plane, and (B) Sagittal plane. **Abbreviations:** HHH, humeral head height; DF, humeral head diameter in frontal; O, center of humeral head; RF, radius of curvature in frontal plane; HHI, humeral head inclination; HHA, humeral head axis; and HSA, humeral shaft axis; DS, humeral head diameter in sagittal plane; RS, radius of curvature in sagittal plane.

was measured using the Friedman et al¹⁸ method, which was the most common method used to measure the glenoid version. The glenoid version was defined as an angle between a line connecting the anterior-posterior glenoid edges and a line perpendicular to the scapula axis (Figure 2C). The scapula axis was a line connecting the tip of the medial border of the scapula to the center of the glenoid cavity.

Statistical Analysis

Statistical analysis was performed using the SPSS Statistics 25 Software for Windows. The normality test was performed using Kolmogorov–Smirnov tests to examine the distributions of all parameters. Differences between males and females were analyzed using the Student's *T*-test if the data was normal, otherwise, Mann–Whitney *U* was used. Correlations between patients' height, age, and shoulder morphometry were analyzed using the Spearman test. The significance level was set at 0.05 for all analyses.

Results

CT scans of 85 normal shoulders from 71 patients met the criteria and included in this study. The mean age of the subjects was 57.8 years, the mean height was 163.9 cm and the mean weight was 63.8 kg. Patients' demographics are shown in Table 1.

The means of HHH, DS, DF, RS, RF, and HHI were 15.6 ± 1.1 mm (range, 13.3–18.5) mm, 39.3 ± 2.4 mm (range, 34.0–45.9), 41.3 ± 3.5 mm (range, 33.6–50.9), 20.4 ± 1.5 mm (range, 17.0–24.6), 21.4 ± 1.9 mm (range, 17.3–26.5),

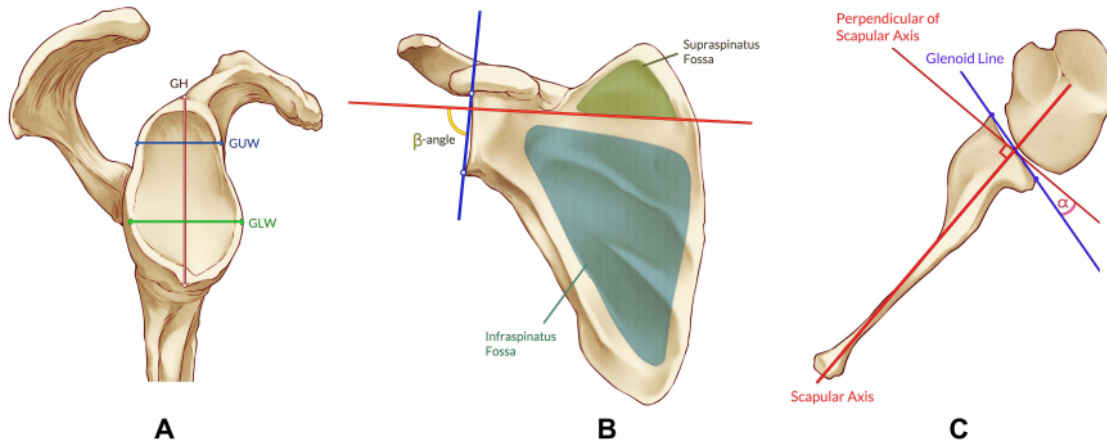


Figure 2 Glenoid measurement.

Notes: (A) Glenoid cavity parameters from lateral view: GH, G UW, and GLW. (B) Glenoid inclination (GI) was measured using β -angle. (C) α -angle represents glenoid version (GV) ^{16,17}

Abbreviations: GH, glenoid height; G UW, glenoid upper width; GLW, glenoid lower width.

and $134.1^\circ \pm 0.8^\circ$ (range, 131.9–135.9), respectively. This study showed that the humeral head diameter in the frontal plane (DF) was longer than its diameter in the sagittal plane (DS). Radius of curvature in the frontal (RF) was also longer than its radius in the sagittal plane (RS). The mean of GH, G UW, GLW, and GI were 34.2 ± 3.4 mm (range, 28.8–41.8), 18.4 ± 2.2 mm (range, 13.8–24.0), 24.5 ± 2.8 mm (range, 19.5–31.7), and $74.0^\circ \pm 1.0^\circ$ (range, 71.4–76.8), respectively. The average Indonesian glenoid version was $12.3 \pm 1.2^\circ$ (range, 9.5–15.6) retroversion. Details about the humeral head and glenoid morphometry are shown in Table 2.

Kolmogorov–Smirnov tests showed normal distribution only for HHI and G UW. Thus, comparison and correlation studies were performed using Mann–Whitney *U*-test and Spearman test. Comparison studies between males and females showed significant differences for glenohumeral dimensions such as HHH ($p < 0.001$), DS ($p < 0.001$), DF ($p < 0.001$), RS

Table 1 Demographic Data in Subjects

Parameter	Classification	Total	Percentage (%)
Gender	Male	25	35.2
	Female	46	64.8
Age	< 30 years	1	1.4
	31–40 years	4	5.6
	41–50 years	11	15.5
	51–60 years	24	33.8
	61–70 years	25	35.2
	>70 years	6	8.5
Shoulder Evaluation	Right	41	57.8
	Left	16	22.5
	Both	14	19.7
Diagnosis	Lung Ca	32	45.1
	Breast Ca	10	14.1
	Lung Metastasis	13	18.3
	Lung TB	6	8.5
	Others	10	14.1

Table 2 Humeral Head and Glenoid Morphometry in Normal Indonesian Adults

Parameter	Mean ± SD			Gender Difference
	Total	Male	Female	p value
Age, years	57.8 ± 9.9 (28–77)	56.3 ± 10.0	58.6 ± 9.9	0.595
Weight, kg	63.8 ± 6.0 (55–79)	66.2 ± 6.4	62.6 ± 5.3	0.015*
Height, cm	163.9 ± 6.0 (150–175)	165.5 ± 6.5	163.1 ± 5.0	0.105
Humeral Head				
Height (HHH), mm	15.6 ± 1.1 (13.3–18.5)	16.5 ± 0.7	15.1 ± 0.9	<0.001*
Diameter in Sagittal Plane (DS), mm	39.3 ± 2.4 (34.0–45.9)	41.3 ± 1.6	38.3 ± 2.1	<0.001*
Diameter in Frontal Plane (DF), mm	41.3 ± 3.5 (33.6–50.9)	44.3 ± 2.3	39.8 ± 3.0	<0.001*
Radius of Curvature in Sagittal Plane (RS), mm	20.4 ± 1.5 (17.0–24.6)	21.7 ± 1.0	19.7 ± 1.3	<0.001*
Radius of Curvature in Frontal Plane (RF), mm	21.4 ± 1.9 (17.3–26.5)	22.9 ± 1.2	20.6 ± 1.6	<0.001*
Inclination (HHI), degree	134.1 ± 0.8 (131.9–135.9)	133.9 ± 0.7	134.1 ± 0.8	0.123
Glenoid				
Height (GH), mm	34.2 ± 3.4 (28.8–41.8)	37.6 ± 2.1	32.6 ± 2.6	<0.001*
Upper Width (GUW), mm	18.4 ± 2.2 (13.8–24.0)	20.0 ± 1.9	17.6 ± 1.9	<0.001*
Lower Width (GLW), mm	24.5 ± 2.8 (19.5–31.7)	27.2 ± 2.0	23.2 ± 2.2	<0.001*
Inclination (GI), degree	74.0 ± 1.0 (71.4–76.8)	74.0 ± 0.9	73.9 ± 1.1	0.903
Version (GV), degree	12.3 ± 1.2 (9.5–15.6)	12.3 ± 1.1	12.4 ± 1.2	0.929

Note: *Significant level at <0.05.

5 (p<0.001), RF (p<0.001), GH (p<0.001), GUW (p<0.001), and GLW (p<0.001) in all analysis), but not for glenohumeral orientations such as HHI (p=0.123), GI (p=0.903) and GV (p=0.929). In this comparison study, male subjects had larger humeral heads and glenoid than female subjects.

3 Body height was correlated with HHH (r (83)=0.303, p=0.002), DS (r (83)=0.303, p=0.002), DF (r (83)=0.303, p=0.002), RS (r (83)=0.303, p=0.002), RF (r (83)=0.306, p=0.002), GH (r (83)=0.319, p=0.001), GUW (r (83)=0.313, p=0.004), GLW (r (83)=0.283, p=0.002), GD (r=0.313) and GV (r (83)= -0.233, p=0.016). The correlation study showed that subjects with higher body height tend to have larger humeral head and glenoid. Among the Indonesian population, no correlation was found between age and any glenohumeral morphometry. Details on correlation analysis are shown in Table 3.

Table 3 Correlations Between Glenohumeral Morphometry with Age, Height, and Weight

Parameter	Age		Height		Weight	
	Correlation Coefficient	P value	Correlation Coefficient	P value	Correlation Coefficient	P value
Humeral Head						
Height (HHH), mm	-0.110	0.157	0.303*	0.002	0.423*	<0.001
Diameter in Sagittal Plane (DS), mm	-0.110	0.157	0.303*	0.002	0.423*	<0.001
Diameter in Frontal Plane (DF), mm	-0.110	0.157	0.303*	0.002	0.423*	<0.001
Radius of Curvature in Sagittal Plane (RS), mm	-0.110	0.157	0.303*	0.002	0.423*	<0.001
Radius of Curvature in Frontal Plane (RF), mm	-0.106	0.166	0.306*	0.002	0.421*	<0.001
Inclination (HHI), degree	-0.023	0.418	-0.062	0.285	0.011	0.459
Glenoid						
Height (GH), mm	-0.013	0.454	0.319*	0.001	0.332*	<0.001
Upper Width (GUW), mm	0.107	0.166	0.313*	0.002	0.213*	0.025
Lower Width (GLW), mm	0.014	0.450	0.283*	0.004	0.394*	<0.001
Inclination (GI), degree	-0.045	0.340	-0.037	0.370	-0.060	0.292
Version (GV), degree	-0.024	0.413	-0.233*	0.016	-0.244*	0.012

Note: *Significant level at <0.05.

Discussion

Prosthetic that resembles normal shoulder anatomy can improve joint kinematics and final outcomes. Improperly sized may lead to stiffness, pain, component loosening, and a potentially inferior outcome.³ Studies showed that most of the shoulder prostheses currently used worldwide, which were designed for the American and European populations, did not fit for Asian shoulders.⁵⁻¹⁰ Knowledge about normal glenohumeral morphometry in a specific population is necessary for prosthetic design, sizing, and positioning during arthroplasty.

Morphometry

Previous studies reported that the humeral head size in the Asian population was smaller than in the Western populations.^{2,3,14,15} The normal Indonesian humeral head height, diameter, and radius of curvature in this study were also smaller than in western populations (Table 4). Compared to other studies in Asian populations, normal Indonesian humeral head size was greater than Japanese population but close to Chinese and Indian populations. Despite its geographical proximity, a Singaporean cadaveric study by Manoharan et al¹⁹ reported a significantly huge humeral head size, even the greatest among all studies. In their study, Manoharan et al¹⁹ used direct measurement on a fresh cadaver in which the articular cartilage was still intact. The presence of articular cartilage combined with direct measurement could be the reason for these differences since most other studies were using CT scan, which neglected the presence of articular cartilage.

Our study showed that the mean humeral head diameter in the frontal plane (41.3 mm) was greater than the sagittal plane (39.3 mm). In addition, Hertel et al¹⁵ Humphrey et al¹⁴ and Sahu et al⁶ also reported a greater humeral head diameter in the frontal plane compared to the sagittal plane. Analysis done by Humphrey et al found that the shape of the base of small humeral heads was closer to being spherically shaped, whereas the shape of larger humeral heads was typically more elongated in the frontal plane. Our results showed that the shape of the humeral head base in the Indonesian population was not spherical and elongated in the frontal plane.

The mean Indonesian humeral head radius of curvature in the frontal plane (21.4 mm) was greater than that in the sagittal plane (20.4 mm). Hertel et al¹⁵ and Humphrey et al¹⁴ also reported similar findings. Another study by Cabezas et al³ found that the humeral head radius of curvature in the frontal plane was also greater than in the axial plane. However, the relationship between the radius of curvature in the axial and sagittal planes was unknown because their study did not measure the radius of curvature in the sagittal plane.

Wataru et al²⁰ in their cadaveric study equally divided the humeral head's articular surface into 3 portions from superior to inferior and 3 portions from anterior to posterior, with a final result of 9 parts. Their study found that the mean radii of all parts were changed from superior to inferior and from anterior to posterior. The superior portion radius of curvature was significantly greater than the central portion and the mean radii of curvature in anterior and posterior portions were significantly less than that of the central portion. Since the radius of curvature in the frontal plane was measured in the central portion between the anterior and posterior, it explains why the radius of curvature in the frontal plane was greater than the sagittal plane in our study and previous studies. From our findings and supporting literature, we conclude that the shape of the surface of the humeral head is a complex 3D spheroid of which curvature changes from superior to inferior and from anterior to posterior.

The normal value of Indonesian humeral head inclination was close to Japanese, Indian and Chinese populations, and slightly greater than Thai and Singaporean populations. Humeral head inclinations in the Indonesian population were smaller than those studies in the Western population.^{3,14,15} However, there was a study on Caucasians bones which had a smaller humeral head inclination compared to our study.² It is hard to determine whether Indonesian humeral head inclination is smaller or greater compared to Western populations because the normal value of humeral head inclination in previous studies was varied.

Another important morphometry for prosthetic design was the humeral head version. The previous study showed that humeral head retroversion in Asian populations was greater than in Western populations.² However, this study was unable to measure the humeral head version due to the lack of distal humerus imaging in Chest CT.

Indonesian glenoid height is the greatest among other Asian populations, but it is still considered small compared to Western populations (Table 5). The Indonesian glenoid lower width or glenoid maximum width was also close to other

Table 4 Humeral Head Morphometry in Other Studies

Studies	Subjects	Measurement Method	Humeral Head Parameter											
			Humeral Head Height, mm		Humeral Head Diameter, mm (Frontal / Sagittal)		Radius of Curvature, mm (Axial / Frontal / Sagittal)				Humeral Head Inclination, degree		Humeral Head Retroversion, degree	
			M	F	M	F	M	F	M	F	M	F	M	F
This Study	Indonesian	CT	16.5 ± 0.7	15.1 ± 0.9	DF = 44.3 ± 2.3 DS = 41.3 ± 1.6	DF = 38.7 ± 2.3 DS = 36.7 ± 2.4	RF = 22.9 ± 1.2 RS = 21.7 ± 1.0	RF = 20.6 ± 1.6 RS = 19.7 ± 1.3	133.9 ± 0.7	134.1 ± 0.8				
Aroonjarattham et al ¹	Caucasian Bone Thai Bone	CT CT	19.00 ± 2.0	14.84 ± 1.86	43.30 ± 4.30 40.51 ± 3.88				131.0 ± 3.0	127.64 ± 4.28	19.0 ± 6.0	31.01 ± 9.72		
Cabezas et al ²	North American	CT	19.7 ± 1.7	17.3 ± 1.4			RF = 24.6 ± 2.2 RA = 22.7 ± 2.3		136.0 ± 5.7	135.6 ± 4.0				
	East Asian	CT	18.0 ± 1.8	16.1 ± 1.6			RF = 22.3 ± 1.9 RA = 20.9 ± 1.6		135.6 ± 3.2	137.4 ± 1				
Humphrey et al ⁵	White American & Australian	CT	18.2	16.8	DF = 51 DS = 44.5	DF = 46 DS = 42.4	RF = 26.4 RS = 24.7	RF = 23.8 RS = 22.5	135	135				
Matsumura et al ⁹	Japanese	CT	14.2 ± 1.3	12.4 ± 1.4	45.9 ± 1.9	39.8 ± 1.7			134 ± 3	134 ± 3	34 ± 11	30 ± 10		
Sahu et al ¹¹	Indian	CT	17.4 ± 1.4	16.0 ± 1.5	DF = 43.3 ± 2.2 DS = 41.2 ± 1.9	DF = 38.7 ± 2.3 DS = 36.7 ± 2.4	23.6 ± 1.3	20.8 ± 0.9	133.3 ± 6.7	135.4 ± 5.5	33.4 ± 9.2	33.9 ± 6.4		
Zhang et al ⁴	Chinese	CT	16.7 ± 1.9		44.6 ± 4.4				132.4 ± 4.69		21.11 ± 12.16			
Zhang et al ¹⁵	Chinese	CT	17.9 ± 1.2	16.0 ± 1.1	45.6 ± 2.8	40.1 ± 1.7	23.5 ± 1.5	20.6 ± 0.9	132.9 ± 2.8	132.8 ± 3.4	24.4 ± 10.4	20.7 ± 9.6		
Herrel et al ¹	Swiss Bone	Direct/ Xray	17.0 ± 1.7		DF = 44.5 ± 4 DS = 42.0 ± 3.8		RF = 24.0 ± 2.2 RS = 21.0 ± 1.8		137 ± 3.62		23.3 ± 11.75			
Iannotti et al ⁶	American Cadaver & Patient	Direct / MRI	19 ± 2.4		24 ± 2.1									
Manoharan et al ⁸	Singaporean Cadaver	Direct	24.28 ± 4.17		46.23±4.24				128 ± 4					

Abbreviations: CT, computed tomography; X-Ray, conventional radiograph; MRI, magnetic resonance imaging; DF, humeral head diameter in frontal plane; DS, humeral head diameter in sagittal plane; RF, radius of curvature in frontal plane; RS, radius of curvature in sagittal plane; RA, radius of curvature in axial plane.

Asian populations and smaller than Western populations. The data showed that the glenoid lower width was greater than its upper width. This is similar to previous studies.^{3,21}

The mean of the normal Indonesian glenoid inclination, which was measured using β angle, was 74.0° and the mean of the normal Indonesian glenoid version was 12.3° retroversion.⁶ It was difficult to compare both the glenoid inclination and version with previous studies due to differences in measurement methods. The authors only compared these study results with other studies that used similar measurement methods. The mean of Indonesian glenoid inclination was slightly smaller than the Indian population. The mean of the Indonesian glenoid version was more retroverted than Hongkong and Indian populations.

Gender Analysis

Gender analysis found that Indonesian males had a larger humeral head height, diameter, and radius of curvature than females ($p < 0.001$ in all analyses), but no difference was found in humeral head inclination ($p = 0.123$). Previous studies also found that gender difference affected the values of humeral head height, diameter, and radius of curvature, but did not affect the value of humeral head inclination.^{2,3,6,7,10,14}

Indonesian glenoid height and width in males were also greater than the females ($p < 0.001$ in all analyses), similar to previous studies.^{3-8,10,21,22} In this study, no gender difference was found in both glenoid inclination ($p = 0.903$) and glenoid version ($p = 0.929$). The Slocum et al⁸ study also found no significant difference in the glenoid version between males and females. However, Matsumura et al²³ reported that Japanese males had a higher retroversion for both humeral head and glenoid than Japanese females. This study showed that age was not correlated with all glenohumeral morphometry. In contrast with age, body height was found to be correlated with humeral head height, humeral head diameter, the humeral head radius of curvature, glenoid height, and glenoid width, but not to humeral head inclination, glenoid inclination, and glenoid version. Similar to our study, body height had been reported to correlate with humeral head size^{7,10,14,23,24} and glenoid size.^{5,10,21-23} Thus, it is proved that body height affects both the humeral head and the glenoid size regardless race.

Limitations

This study had several limitations. First, subjects in this study were patients who had chest CT scans for any medical reason other than the shoulder, thus the subjects were not truly come from the healthy population. Our study excluded subjects with past illnesses, injuries, deformities, or degenerative processes of the shoulder joint. However, the accuracy of our subjects to represent the normal shoulder of Indonesian is difficult to determine.

Second, the extraction of shoulder imaging from chest CT had several limitations. The difference in positioning, slice thickness, and focus area between shoulder CT and chest CT may affect the quality of 3D reconstruction and shoulder measurement. However, this study used thin-slice HRCT of the chest with a post-processing bone algorithm to optimize the 3D reconstruction quality. The humerus was not completely visible on the chest CT. This explains why this study could not measure the humeral head version, medial and posterior offset.

Finally, the limitation of CT scan in visualizing soft tissues made our measurement neglect the thickness of the articular cartilage. This may result in slight differences between the glenohumeral morphometry that we measured and its actual morphometry.

Conclusion

This study presented the morphology of glenohumeral joint in the normal Indonesian population. The size of Indonesian humeral head and glenoid were greater in males than females and were correlated to body height. Indonesians humeral head and glenoid size were smaller than Western populations, but close to other Asian populations. These results would be useful to determine the size of implants and to improve the development of shoulder prostheses design especially for Asian populations.

Table 5 Glenoid Morphometry in Other Studies

Studies	Subjects	Measurement		Glenoid Parameter						
		Method	Glenoid Height, mm		Glenoid Width, mm (Upper/Lower)		Glenoid Inclination, Degree		Glenoid Version, Degree	
			M	F	M	F	M	F	M	F
This Study	Indonesian	CT	37.6 ± 2.1	32.6 ± 2.6	20.0 ± 1.9	17.6 ± 1.9	74.0 ± 0.9	73.9 ± 1.1	-12.3 ± 1.1	-12.4 ± 1.2
Cabezas et al ²	North American	CT	38.4 ± 2.2	33.3 ± 2.4	UW = 24.5 ± 2.8	UW = 24.5 ± 2.8				
					LW = 30.5 ± 2.2	LW = 30.5 ± 2.2				
	East Asian	CT	34.3 ± 2.6	31.9 ± 2.5	UW = 24.5 ± 2.8	UW = 24.5 ± 2.8				
					LW = 30.5 ± 2.2	LW = 30.5 ± 2.2				
Matsumura et al ⁹	Japanese	CT	33.6 ± 1.9	29.4 ± 1.7	24.9 ± 1.7	21.3 ± 1.4				
Mizuno et al ¹⁰	Japanese	CT	35.3 ± 1.8	31.4 ± 1.8	27.4 ± 2.4	23.5 ± 1.6				
	French	CT	37.3 ± 1.9	33.5 ± 1.8	28.7 ± 2.1	24.7 ± 1.7				
Sahu et al ¹¹	Indian	CT	31.8 ± 2.1	29.9 ± 1.9	24.5 ± 1.9	22.5 ± 1.5	77.8 ± 4.2	81.5 ± 5.9	-2.5 ± 3.4	0.5 ± 4.3
Singh et al ¹²	Malay	CT	39.0 ± 3.0	34.5 ± 2.3	26.9 ± 2.7	22.3 ± 1.4				
Slocum et al ¹³	Southern Chinese/ Hongkong	CT	36.6 ± 2.66	32.2 ± 2.17	27.4 ± 2.4	23.5 ± 1.6				
Zhang et al ¹⁵	Chinese	CT	33.43 ± 2.45	27.09 ± 1.14	22.51 ± 1.84	18.34 ± 1.03				
Churcill et al ³	Black American Bone	Direct	37.6 ± 2.1	32.7 ± 1.7	27.6 ± 1.4	23.4 ± 1.6				
	White American Bone	Direct	37.4 ± 1.9	32.5 ± 1.8	28.1 ± 1.6	23.8 ± 1.2				
lanotti et al ⁶	American Cadaver & Patient	Direct / MRI	39 ± 3.5		LW = 29 ± 3.2					
Khan et al ⁷	South African Bone	Direct	35.3 ± 3.1	34.6 ± 2.8	UW = 18.2 ± 3.3	UW = 17.4 ± 2.6				
					LW = 24.2 ± 2.7	LW = 23.7 ± 2.8				
Manoharan et al ⁸	Singaporean Cadaver	Direct	34.34 ± 4.26		25.23 ± 3.17					

Abbreviations: CT, computed tomography; MRI, magnetic resonance imaging; UW, glenoid upper width; LW, glenoid lower width.

Ethical Committee Approval

This study was reviewed and approved by the Ethics Committee of the Dr. Soetomo General Hospital with reference number: 1724/KEPK/XII/2019. Patient consent to review their medical records was not required by the ethics committee. This study covered patient data confidentiality and compliance according to the Declaration of Helsinki.

11

Disclosure

The authors report no conflicts of interest in this work.

References

- Rabinowitz J, Kothandaraman V, Lin J, Li X, Friedman RJ, Eichinger JK. Utilization of shoulder arthroplasty in the United States – an analysis of current trends and future predictions. *Semin Arthroplasty JSES*. 2020;30(3):200–209. doi:10.1053/j.sart.2020.08.004
- Aroonjarattham P, Jiamwathanachai P, Mahaisavariya B, Kiatiwat T, Aroonjarattham K, Siththiseripratip K. Three-dimensional morphometric study of the Thai proximal humerus: cadaveric study. *J Med Assoc Thai*. 2009;92(9):1191–1197.
- Cabezas AF, Krebs K, Hussey MM, et al. Morphologic variability of the shoulder between the populations of North American and East Asian. *Clin Orthop Surg*. 2016;8(3):280–287. doi:10.4055/cios.2016.8.3.280
- Churchill RS, Brems JJ, Kotschi H. Glenoid size, inclination, and version: an anatomic study. *J Shoulder Elbow Surg*. 2001;10(4):327–332. doi:10.1067/mse.2001.115269
- Mizuno N, Nonaka S, Ozaki R, Yoshida M, Yoneda M, Walch G. *Three-Dimensional Assessment of the Normal Japanese Glenoid and Comparison with the Normal French Glenoid*. Vol. 103. Elsevier Masson SAS; 2017:1271–1275.
- Sahu D, Joshi M, Rathod V, Nathani P, Valavi AS, Jagiasi JD. Geometric analysis of the humeral head and glenoid in the Indian population and its clinical significance. *JSES Int*. 2020;4(4):992–1001. doi:10.1016/j.jseint.2020.06.008
- Zhang Q, Shi LL, Ravella KC, et al. Distinct proximal humeral geometry in Chinese population and clinical relevance. *J Bone Joint Surg Am*. 2016;98(24):2071–2081. doi:10.2106/JBJS.15.01232
- Slocum AMY, Siu YC, Ma CM, Lui TH. The study of 2-dimensional computed tomography scans of the glenoid anatomy in relation to reverse shoulder arthroplasty in the Southern Chinese population. *JSES Int*. 2021;5(4):714–721. doi:10.1016/j.jseint.2021.02.006
- Zhang L, Yuan B, Wang C, Liu Z. Comparison of anatomical shoulder prostheses and the proximal humeri of Chinese people. *Proc Inst Mech Eng H*. 2007;221(8):921–927. doi:10.1243/09544119JEIM267
- Matsumura N, Oki S, Ogawa K, et al. Three-dimensional anthropometric analysis of the glenohumeral joint in a normal Japanese population. *J Shoulder Elbow Surg*. 2016;25(3):493–501. doi:10.1016/j.jse.2015.08.003
- Ford JM, Decker SJ. Computed tomography slice thickness and its effects on three-dimensional reconstruction of anatomical structures. *J Forensic Radiol Imaging*. 2016;4:43–46. doi:10.1016/j.jofri.2015.10.004
- Di Muzio B, Fahrenhorst-Jones T. HRCCT chest (protocol). Reference Article, Radiopaedia.org; 2022.
- Kadavkolan AS, Jawhar A. Glenohumeral joint morphometry with reference to anatomic shoulder arthroplasty. *Curr Orthop Pract*. 2018;29(1):71–83. doi:10.1097/BCO.0000000000000552
- Humphrey CS, Sears BW, Curtin MJ. An anthropometric analysis to derive formulae for calculating the dimensions of anatomically shaped humeral heads. *J Shoulder Elbow Surg*. 2016;25(9):1532–1541. doi:10.1016/j.jse.2016.01.032
- Hertel R, Knothe U, Ballmer FT. Geometry of the proximal humerus and implications for prosthetic design. *J Shoulder Elbow Surg*. 2002;11(4):331–338. doi:10.1067/MSE.2002.124429
- Maurer A, Fucentese SF, Pfirrmann CWA, et al. Assessment of glenoid inclination on routine clinical radiographs and computed tomography examinations of the shoulder. *J Shoulder Elbow Surg*. 2012;21(8):1096–1103. doi:10.1016/j.jse.2011.07.010
- Mamatha T, Pai SR, Murlimanju BV, Kalthur SG, Pai MM, Kumar B. Morphometry of glenoid cavity. *Online J Heal Allied Sci*. 2011;10(3):1–4.
- Friedman RJ, Hawthorne KB, Genez BM. The use of computerized tomography in the measurement of glenoid version. *J Bone Joint Surg Am*. 1992;74(7):1032–1037. doi:10.2106/00004623-199274070-00009
- Manoharan V, Sheng JM, Chou SM, Soon Yew AK, Tan SH, Tjoen Lie DT. A normative anatomic study of the glenohumeral joint and rotator cuff tendons. *Proc Singapore Healthc*. 2014;23(3):201–208. doi:10.1177/201010581402300305
- Wataru S, Kazuomi S, Yoshikazu N, Hiroaki I, Takaharu Y, Hideki Y. Three-dimensional morphological analysis of humeral heads: a study in cadavers. *Acta Orthop*. 2005;76(3):392–396. doi:10.1080/00016470510030878
- Khan R, Satyapal KS, Lazarus L, Naidoo N. An anthropometric evaluation of the scapula, with emphasis on the coracoid process and glenoid fossa in a South African population. *Heliyon*. 2020;6(1):e03107. doi:10.1016/j.heliyon.2019.e03107
- Singh SSL, Tengku Md Shihabudin TM, Pall Singh TS, Bin Musa AT, Mohd Daud NB, Dragoo JL. Morphological characteristics of Malaysian Malay shoulders for the Latarjet procedure: a cross-sectional CT scan based study. *Curr Orthop Pract*. 2020;31(2):8–12. doi:10.1097/BCO.0000000000000837
- Matsumura N, Ogawa K, Kobayashi S, et al. Morphologic features of humeral head and glenoid version in the normal glenohumeral joint. *J Shoulder Elbow Surg*. 2014;23(11):1724–1730. doi:10.1016/j.jse.2014.02.020
- Iannotti JP, Gabriel JP, Schneck SL, Evans BG, Misra S. The normal glenohumeral relationships. An anatomical study of one hundred and forty shoulders. *J Bone Joint Surg*. 1992;74(4):491–500. doi:10.2106/00004623-199274040-00004

Orthopedic Research and Reviews

Dovepress

Publish your work in this journal

Orthopedic Research and Reviews is an international, peer-reviewed, open access journal that focusing on the patho-physiology of the musculoskeletal system, trauma, surgery and other corrective interventions to restore mobility and function. Advances in new technologies, materials, techniques and pharmacological agents are particularly welcome. The manuscript management system is completely online and includes a very quick and fair peer-review system, which is all easy to use. Visit <http://www.dovepress.com/testimonials.php> to read real quotes from published authors.

Submit your manuscript here: <https://www.dovepress.com/orthopedic-research-and-reviews-journal>

Morphology of Humeral Head and Glenoid in Normal

ORIGINALITY REPORT

17%

SIMILARITY INDEX

11%

INTERNET SOURCES

15%

PUBLICATIONS

0%

STUDENT PAPERS

PRIMARY SOURCES

1	sogacot.org Internet Source	1%
2	U. Kandemir, R. B. Allaire, J. T. Jolly, R. E. Debski, P. J. McMahon. "The relationship between the orientation of the glenoid and tears of the rotator cuff", <i>The Journal of Bone and Joint Surgery</i> . British volume, 2006 Publication	1%
3	"Abstracts of the 18th Congress of the International Pediatric Nephrology Association, Venice (Italy), October 2019", <i>Pediatric Nephrology</i> , 2019 Publication	1%
4	Akiyama, K.. "Three-dimensional distribution of articular cartilage thickness in the elderly cadaveric acetabulum: a new method using three-dimensional digitizer and CT", <i>Osteoarthritis and Cartilage</i> , 201006 Publication	1%
5	bmcpublichealth.biomedcentral.com Internet Source	<1%

6

Sahara Wataru, Sugamoto Kazuomi, Nakajima Yoshikazu, Inui Hiroaki, Yamazaki Takaharu, Yoshikawa Hideki. "Three-dimensional morphological analysis of humeral heads", *Acta Orthopaedica*, 2009

Publication

<1 %

7

Matsumura, Noboru, Kiyohisa Ogawa, Shuzo Kobayashi, Satoshi Oki, Anri Watanabe, Hiroyasu Ikegami, and Yoshiaki Toyama. "Morphologic features of humeral head and glenoid version in the normal glenohumeral joint", *Journal of Shoulder and Elbow Surgery*, 2014.

Publication

<1 %

8

bmcgastroenterol.biomedcentral.com

Internet Source

<1 %

9

Heri Suroto, Muhammad Rifqi Farizan Akbar, Dina Aprilya, Firman Pribadi. "Validity and Reliability of Prognosis Brachial Plexus Injury Score for Traumatic Brachial Plexus Injury", *Clinics in Orthopedic Surgery*, 2022

Publication

<1 %

10

tel.archives-ouvertes.fr

Internet Source

<1 %

11

Aditya Sai Kadavkolan, Ahmed Jawhar. "Glenohumeral joint morphometry with reference to anatomic shoulder arthroplasty", *Current Orthopaedic Practice*, 2018

<1 %

12	imcidu.idu.edu.tr Internet Source	<1 %
13	jidc.org Internet Source	<1 %
14	Takeda, H.. "The influence of medial reattachment of the torn cuff tendon for retracted rotator cuff tears", Journal of Shoulder and Elbow Surgery, 200705/06 Publication	<1 %
15	Rouleau, D.M.. "Glenoid version: How to measure it? Validity of different methods in two-dimensional computed tomography scans", Journal of Shoulder and Elbow Surgery, 201012 Publication	<1 %
16	innovpub.org Internet Source	<1 %
17	www.scitepress.org Internet Source	<1 %
18	www.science.gov Internet Source	<1 %
19	www.thieme-connect.de Internet Source	<1 %
20	Adijat Omowumi Inyang, Steve Roche, Theo Rosch, Sudesh Sivarasu. "INVESTIGATING THE	<1 %

INTRA-ANCESTRAL MORPHOMETRIC
VARIATIONS OF THE THREE-DIMENSIONAL
GEOMETRY OF THE PROXIMAL HUMERUS",
Journal of Musculoskeletal Research, 2019

Publication

21

Krishna Gopal, Anurag Singh, Onkar Singh,
Chanchal Sharma. "MORPHOMETRIC
EVALUATION OF GLENOID CAVITY AND
OTHER DIMENSIONS OF DRY HUMAN
SCAPULAE", International Journal of Anatomy
and Research, 2018

Publication

<1 %

22

Yuhui Yang, Jianlin Zuo, Tong Liu, Pu Shao,
Haihe Wu, Zhongli Gao, Jianlin Xiao. "Glenoid
morphology and the safe zone for protecting
the suprascapular nerve during baseplate
fixation in reverse shoulder arthroplasty",
International Orthopaedics, 2017

Publication

<1 %

23

mail.scopemed.org

Internet Source

<1 %

24

Thomas Suter, Ariane Gerber Popp, Yue
Zhang, Chong Zhang, Robert Z. Tashjian,
Heath B. Henninger. "The influence of
radiographic viewing perspective and
demographics on the critical shoulder angle",
Journal of Shoulder and Elbow Surgery, 2015

Publication

<1 %

25	actavetscand.biomedcentral.com Internet Source	<1 %
26	www.hindawi.com Internet Source	<1 %
27	DeLude, J.A.. "An anthropometric study of the bilateral anatomy of the humerus", <i>Journal of Shoulder and Elbow Surgery</i> , 200707 Publication	<1 %
28	Jonathan M. Ford, Summer J. Decker. "Computed tomography slice thickness and its effects on three-dimensional reconstruction of anatomical structures", <i>Journal of Forensic Radiology and Imaging</i> , 2016 Publication	<1 %
29	radiopaedia.org Internet Source	<1 %
30	www.sjkdt.org Internet Source	<1 %
31	"35 Pyrocarbon Scaphoid Implant Allowing Adaptive Mobility in Proximal Scaphoid Pseudarthrosis", Georg Thieme Verlag KG, 2011 Publication	<1 %
32	Jean-Marc Glasson, Floris van Rooij, Luca Nover, Mo Saffarini, Jean Kany. "The Y plane is	<1 %

a reliable CT-based reference for glenoid component positioning in shoulder arthroplasty", Journal of Experimental Orthopaedics, 2022

Publication

33

Pearl, Michael L., Spencer Woolwine, Fabian van de Bunt, Gabriel Merton, and Raoul Burchette. "Geometry of the proximal humeral articular surface in young children: a study to define normal and analyze the dysplasia due to brachial plexus birth palsy", Journal of Shoulder and Elbow Surgery, 2013.

Publication

<1 %

34

ecios.org

Internet Source

<1 %

35

rbmb.net

Internet Source

<1 %

36

www.febrasgo.org.br

Internet Source

<1 %

37

Chandrasekhar Bodanki, Hari Krishna Yadoji, Venkateshwar Reddy Maryada, Gurava Reddy Annapareddy Venkata. "Three Dimensional Anthropometric Analysis of Glenoid Anatomy in Normal Indian Population", Indian Journal of Orthopaedics, 2021

Publication

<1 %

38

Graichen, H.. "Sex-specific differences of subacromial space width during abduction, with and without muscular activity, and correlation with anthropometric variables", *Journal of Shoulder and Elbow Surgery*, 200103

Publication

<1 %

39

Vlachopoulos, Lazaros, Celestine Dünner, Tobias Gass, Matthias Graf, Orcun Goksel, Christian Gerber, Gábor Székely, and Philipp Fürnstahl. "Computer algorithms for three-dimensional measurement of humeral anatomy: analysis of 140 paired humeri", *Journal of Shoulder and Elbow Surgery*, 2016.

Publication

<1 %

40

link.springer.com

Internet Source

<1 %

41

Daniel J. Lorenzana, Justin Solomon, Robert J. French, Erin McCrum et al. "Comparison of Simulated Low-Dose and Conventional-Dose CT for Preoperative Planning in Shoulder Arthroplasty", *Journal of Bone and Joint Surgery*, 2022

Publication

<1 %

42

www.frontiersin.org

Internet Source

<1 %

43

Benjamin W. Sears, Robert A. Creighton, Patrick J. Denard, Justin W. Griffin, Sven Lichtenberg, Evan Lederman, Brian Werner. "Stemless Components Lead to Improved Radiographic Restoration of Humeral Head Anatomy Compared to Short-stemmed Components in Total Shoulder Arthroplasty", *Journal of Shoulder and Elbow Surgery*, 2022

Publication

<1 %

44

Jing Zhou, Bin Zhong, Rongmei Qu, Lei Qian et al. "Anatomic measurement of osseous parameters of the glenoid", *Scientific Reports*, 2022

Publication

<1 %

45

K L Dunn. "Medical record review of deaths, unexpected intensive care unit admissions, and clinician referrals: detection of adverse events and insight into the system", *Archives of Disease in Childhood*, 5/24/2005

Publication

<1 %

46

Matthew Daggett, Birgit Werner, Marc Olivier Gauci, Jean Chaoui, Gilles Walch. "Comparison of glenoid inclination angle using different clinical imaging modalities", *Journal of Shoulder and Elbow Surgery*, 2016

Publication

<1 %

47

Patrick M. Williamson, Philip Hanna, Kaveh Momenzadeh, Aron Lechtig et al. "Effect of

<1 %

rotator cuff muscle activation on
glenohumeral kinematics: A cadaveric study",
Journal of Biomechanics, 2020

Publication

48

Peter Ericson Lingamdenne, Pavani
Marapaka. "MEASUREMENT AND ANALYSIS
OF ANTHROPOMETRIC MEASUREMENTS OF
THE HUMAN SCAPULA IN TELANGANA
REGION, INDIA", International Journal of
Anatomy and Research, 2016

Publication

<1 %

49

Rajani Singh. "Surgical Anatomy of the
Glenoid Cavity and Its Use in Shoulder
Arthroplasty Among the North Indian
Population", Cureus, 2020

Publication

<1 %

50

pubmed.ncbi.nlm.nih.gov

Internet Source

<1 %

51

Dawson, C.K.. "The Management of Localized
Articular Cartilage Lesions of the Humeral
Head in the Athlete", Operative Techniques in
Sports Medicine, 200801

Publication

<1 %

52

Marc-Olivier Gauci, Pierric Deransart, Jean
Chaoui, Manuel Urvoy et al.
"TRIDIMENSIONAL GEOMETRY OF THE
NORMAL SHOULDER: A SOFTWARE

<1 %

ANALYSIS", Journal of Shoulder and Elbow Surgery, 2020

Publication

-
- | | | |
|----|--|------|
| 53 | Vivek Manoharan, Jia-Min Sheng, Siaw Meng Chou, Andy Khye Soon Yew, Soon Huat Tan, Denny Tijauw Tjoen Lie. "A Normative Anatomic Study of the Glenohumeral Joint and Rotator Cuff Tendons", Proceedings of Singapore Healthcare, 2014
Publication | <1 % |
| 54 | acikbilim.yok.gov.tr
Internet Source | <1 % |
| 55 | coek.info
Internet Source | <1 % |
| 56 | engagedscholarship.csuohio.edu
Internet Source | <1 % |
| 57 | online.boneandjoint.org.uk
Internet Source | <1 % |
| 58 | synapse.koreamed.org
Internet Source | <1 % |
| 59 | www.healio.com
Internet Source | <1 % |
| 60 | www.wjgnet.com
Internet Source | <1 % |
| 61 | De Wilde, L.F.. "Glenohumeral relationship in the transverse plane of the body", Journal of | <1 % |

62

Holong Mangasah, Iman Widya Aminata. "Three-dimensional morphometric analysis of glenoid in the Indonesian population and its clinical significance", Journal of Orthopaedics, 2023

Publication

<1 %

63

Mary Alkesan, Salwa Ouies, Zahraa Ismael, Ahmed Galal. "Morphological and morphometric study on human glenoid cavity with correlation to its functions", مجلة سوهاج لشباب الباحثين, 2022

Publication

<1 %

64

Noboru Matsumura, Satoshi Oki, Masateru Kitashiro, Mayu Minemoto et al. "Three-dimensional quantitative analysis of humeral head and glenoid bone defects with recurrent glenohumeral instability", Journal of Shoulder and Elbow Surgery, 2017

Publication

<1 %

65

Qiang Zhang, Lewis L. Shi, Krishna C. Ravella, Jason L. Koh, Shaobai Wang, Cailong Liu, Guoan Li, Jianhua Wang. "Distinct Proximal Humeral Geometry in Chinese Population and Clinical Relevance", The Journal of Bone and Joint Surgery, 2016

Publication

<1 %

66 Clavert, P.. "Glenoid resurfacing: What are the limits to asymmetric reaming for posterior erosion?", Journal of Shoulder and Elbow Surgery, 200711 <1 %

Publication

67 European Surgical Orthopaedics and Traumatology, 2014. <1 %

Publication

68 Sahara, W.. "The three-dimensional motions of glenohumeral joint under semi-loaded condition during arm abduction using vertically open MRI", Clinical Biomechanics, 200703 <1 %

Publication

69 Wong, A.S.. "The effect of glenoid inclination on superior humeral head migration", Journal of Shoulder and Elbow Surgery, 200307/08 <1 %

Publication

Exclude quotes On

Exclude matches Off

Exclude bibliography On

Morphology of Humeral Head and Glenoid in Normal

GRADEMARK REPORT

FINAL GRADE

/100

GENERAL COMMENTS

Instructor

PAGE 1

PAGE 2

PAGE 3

PAGE 4

PAGE 5

PAGE 6

PAGE 7

PAGE 8

PAGE 9

PAGE 10

PAGE 11