

Nimotuzumab as additional therapy for GLIOMA in ediatic and Adolescent A systematic Review

by Muhammad Arifin Parenrengi

Submission date: 24-Jun-2022 10:26AM (UTC+0800)

Submission ID: 1862082303

File name: py_for_GLIOMA_in_ediatric_and_Adolescent_A_systematic_Review.pdf (888.87K)

Word count: 6548

Character count: 35344

Nimotuzumab as Additional Therapy for GLIOMA in Pediatric and Adolescent: A Systematic Review

Cancer Control
Volume 29: 1–10
© The Author(s) 2022
Article reuse guidelines:
sagepub.com/journals-permissions
DOI: 10.1177/10732748211053927
journals.sagepub.com/home/ccx
SAGE

Muhammad A Parenrengi, MD, PhD^{1,3}, Wihasto Suryaningtyas, MD, PhD^{1,3},
Asra Al Fauzi, MD, PhD^{1,3}, Abdul Hafid Bajamal, MD, PhD^{1,3},
Kurnia Kusumastuti, MD, PhD^{2,3}, Budi Utomo, MD, PhD⁴,
Ahmad Muslim Hidayat Thamrin, MD^{1,3}, and Bagus Sulistiono, MD^{1,3}

Abstract

Introduction: Pediatric gliomas represent the most common brain tumor in children and its higher grades are associated with higher recurrence and low survival rate. All therapeutic modalities are reported to be insufficient to achieve satisfactory result, with follow-up treatment such as adjuvant radiotherapy and chemotherapy recommended to increase survival and hinder tumor progression. Nimotuzumab is a monoclonal antibody that acts as an inhibitor of epidermal growth factor receptor found on the surface of glioma cells and had been studied for its usage in pediatric gliomas in recent years.

Methods: A systematic review is performed according to Preferred Reporting Items for Systematic Reviews and Meta-Analysis (PRISMA) guidelines. A thorough literature search was conducted on PubMed, Scopus, Cochrane, and clinicaltrials.gov database. Articles were selected systematically based on the PRISMA protocol and reviewed completely. The relevant data were summarized and discussed. We measured overall survival, progression-free survival, and adverse Events (AE) for nimotuzumab usage as an adjunct therapy in pediatric glioma population.

Result: From 5 studies included for qualitative analysis, 151 patients are included with overall survival (OS) that vary from 3.2–22.8 mo, progression-free survival (PFS) from 1.7–21.6 mo, and relatively low serious adverse events (0–21) are recorded. Follow-up ranged from 2.4–66 mo with four studies reporting diffuse intrinsic pontine glioma (DIPG) patients and only one study reporting nimotuzumab usage in pediatric high-grade glioma (HGG) patients with better outcome in HGG patients than DIPG.

Conclusion: There are no significant differences in the PFS and OS of nimotuzumab as adjunct therapy for pediatric compared to result of standard therapy in majority of previous studies. There were also no differences in the AE of nimotuzumab for pediatric glioma between studies, and low event of serious adverse events indicating its safety. But still there is an evidence of possible benefit of nimotuzumab as adjuvant therapy in pediatric glioma. We recommend further studies with larger number of patients that may lead to possibly different results. There should also be more studies with better level of evidence to further validate the effect of nimotuzumab on pediatric glioma.

¹Department of Neurosurgery, Faculty of Medicine, Universitas Airlangga, Surabaya, Indonesia

²Department of Neurology, Faculty of Medicine, Universitas Airlangga, Surabaya, Indonesia

³Dr. Soetomo General Academic Hospital, Surabaya, Indonesia

⁴Department of Public Health and Preventive Medicine, Faculty of Medicine, Universitas Airlangga, Surabaya, Indonesia

Corresponding Author:

Muhammad A Parenrengi, Department of Neurosurgery, Faculty of Medicine, Universitas Airlangga, Surabaya, Indonesia.
Email: muhammad.arifin@fk.unair.ac.id



Creative Commons Non Commercial CC BY-NC: This article is distributed under the terms of the Creative Commons Attribution-NonCommercial 4.0 License (<https://creativecommons.org/licenses/by-nc/4.0/>) which permits non-commercial use, reproduction and distribution of the work without further permission provided the original work is attributed as specified on the SAGE and

Open Access pages (<https://us.sagepub.com/en-us/nam/open-access-at-sage>).

Keywords

Cancer, Child Mortality, Immunology, Glioma, Brain Tumor

Introduction

Glioma is the second most prevalent tumor of the central nervous system (CNS) after meningioma. Glioma of benign histology (WHO grade I) can be treated effectively with surgery (pilocytic astrocytoma). However, gliomas of higher grades (i.e., anaplastic astrocytoma and glioblastoma multiforme) have a higher growth risk or recurrence despite optimal therapy. The survival of patients with glioma varies according to histology, for example, pilocytic astrocytoma has a 10 year survival of more than 90%, whereas only 5% of patients with glioblastoma multiforme (GBM) survive up to 5 years.^{1,2} Management of patients with glioma is not only achieved through surgery but also other non-surgical means including radiotherapy, chemotherapy, and other supportive therapies (anti-epileptic drugs, medical rehabilitation). Nevertheless, these measures are still not sufficient to significantly improve the survival rate of glioma. Stupp et al.³ (2009) reported that the overall survival period for patients with glioblastoma was 14.6 months with current conventional therapy, namely surgery, which was subsequently processed with radiotherapy and chemotherapy with temozolamide.

Pediatric gliomas represent the most common brain tumor in children.⁴ The incidence of brain tumors in children lies at 5 cases per 100 000 population, 75% of which are classified as gliomas.⁵ The current evidence for best therapeutic approach remains to be maximal surgical excision for all types of glioma.^{4,6} In those of higher grades, this therapeutic approach itself is reported to be insufficient to achieve satisfactory result, with follow-up treatment such as adjuvant RT and chemotherapy recommended to increase survival and hinder tumor progression.^{4,6} Although, newer drugs and therapeutic modalities are continuously being studied to further improve care for pediatric patients with glioma.⁶

Diffuse intrinsic pontine glioma (DIPG) is an aggressive type of glioma occurring in childhood that arises in the ventral pons. Although brainstem tumors are rare among adults, they comprise approximately 10–15% of pediatric brain tumors.⁷ The diagnosis of DIPG is mainly based on the clinical examination combined with radiographic findings. Because DIPG is diffusely infiltrative, the tumor margins appear unclear, distinguishing DIPG from less aggressive focal brainstem masses.^{8,9} It is classically a high-grade lesion, most often representing glioblastoma multiforme (WHO grade IV) or high-grade anaplastic astrocytoma (WHO grade III) or lower. But, still, the lower grade has equally aggressive manner with the higher ones.¹⁰ Radiation therapy has remained the mainstay of treatment for DIPG; but, other emerging therapies, such as some chemotherapy and additional therapy like monoclonal antibody and dopamine receptor agonist (ONC201) that believed can control DIPG progression have been used, either routinely or trial.^{11,12} Despite of the emerging therapeutic modality, the median survival rate is still under 12 months, even worse in untreated patient.¹³

Epidermal growth factor receptor (EGFR) is a family of tyrosine kinase receptors and forms dimers when activated and plays a role in tumorigenesis. EGFR is reported to be over-expressed in half of GBM cases.¹⁴ Studies on pediatric high-grade glioma (HGG) have demonstrated the over expression of EGFR protein in about 80-85% of tumors tested. However, the presence of EGFR on normal human tissue leads to side effects with these drugs, and with only 7% EGFR amplification found in tumor samples, showing the importance of EGFR and its tissue samples recognition in DIPG.^{15,16}

Nimotuzumab is a monoclonal antibody that acts as an inhibitor of EGFR found on the surface of glioma cells. Nimotuzumab has been approved as a treatment for squamous cell carcinoma and nasopharyngeal cancer in several countries, as well as for pediatric gliomas.¹⁷ In vivo experiments using human brain tumor cell line shows that nimotuzumab is superior in reducing the number of CD133+ cancer stem cells when used as monotherapy or in combination with radiotherapy (RT), compared to RT alone. It also plays role in increasing radiosensitivity of human glioblastoma cell line.¹⁶

This study is a systematic review regarding the effects of nimotuzumab as an adjunct therapy in pediatric patients with glioma.

Materials and Methods

Criteria for Considering Studies for This Review

Type of Participants. Eligible participants are pediatric and adolescent aged ≤ 21 year-old and both genders with clinical or radiological or confirmed histopathological diagnosis of glioma (any WHO Grade) who have received nimotuzumab as additional therapy.

Type of Intervention

The intervention arms of eligible studies were nimotuzumab as additional therapy for glioma.

Type of Outcome Measures

The studies assessing both the primary and secondary outcomes were included in this study.

Primary outcome. The primary outcome of this review is:

1. Overall survival (OS)
2. Progression-free survival (PFS)

Secondary outcome. The secondary outcome of this review is adverse events (AEs)

Type of Studies

Phase II trial or later of nimotuzumab as additional therapy for glioma were searched.

Exclusion criteria

1. Patients older than 21 or diagnosed with other type of tumor
2. Studies in which neither OS, PFS, nor AEs are measured
3. Studies more than 10 years or not written in English

Search methods for the identification of studies. This systematic review was conducted according to the Preferred Reporting Items for Systematic Reviews and Meta-Analysis (PRISMA) 2009 guideline. An advanced systematic literature review was performed by searching electronic database, which are PubMed, Cochrane, Scopus, and clinicaltrials.gov.

The keyword used on each electronic database in this review was (“nimotuzumab”) AND (“ glioma”). The search result from all databases was imported to Mendeley. Duplicate results were detected using “check for duplicate” in Mendeley and were excluded.

This study has also been registered on PROSPERO with registration ID of 271 654

Data collection and analysis

Selection of studies. All articles’ titles and abstracts were scanned independently by all authors. The results of independent searches were matched in order to find the common result; two physicians reviewed unmatched findings once more, in order to check if they met the inclusion eligibility criteria.

Data appraisal and extraction. All authors independently reviewed the full texts in order to confirm their eligibility according to the predefined participants, intervention, comparison, outcome, and study type (PICOS) and also extract the data. In case of disagreement, the issue was discussed by all authors and the decision was made accordingly.

Assessment of risk of bias in included studies. Review authors independently assessed risk of bias for each included study using the criteria outlined in the Cochrane Handbook for Systematic Reviews of Interventions for non-randomized studies, called as Risk of Bias in Non-randomized Studies of Interventions (ROBINS-I) for non-randomized studies and Risk of Bias 2 (RoB 2) for randomized studies.¹⁸ Accordingly, all studies were classified as “low risk,” “high risk,” or “unclear risk” of bias. Any disagreement was resolved by discussion or by involving third assessor. We summarized judgements in “Risk of bias” tables along with the characteristics of the included studies and interpreted the results in light of the overall “Risk of bias” analysis.^{19,20}

Measures of treatment effect. OS and PFS were collected as median and range of months, and presented as dichotomous

outcome. AEs are presented as incidence by the number of AEs and serious adverse events (SAEs)

Dealing with missing data. Data were extracted as they were reported in the studies. Missing data were noted and reported as bias or explained in the result and/or discussion.

Data synthesis. Data of OS, PFS, and AEs were collected and presented in the form of table and results.

Results

Description of Included Studies

Search results. A systematic search was done on March–April 2021. Initially, a total of 46 publications were identified. Five studies were included for qualitative synthesis. The PRISMA flow diagram was presented in Figure 1.

Included Studies. Five studies were included in this review. All results of included studies are summarized in Table 1.

Risk of Bias Analysis

The result of bias risk assessment of studies involved was measured by ROBINS-I for non-randomized studies. The result is shown in Figure 2.

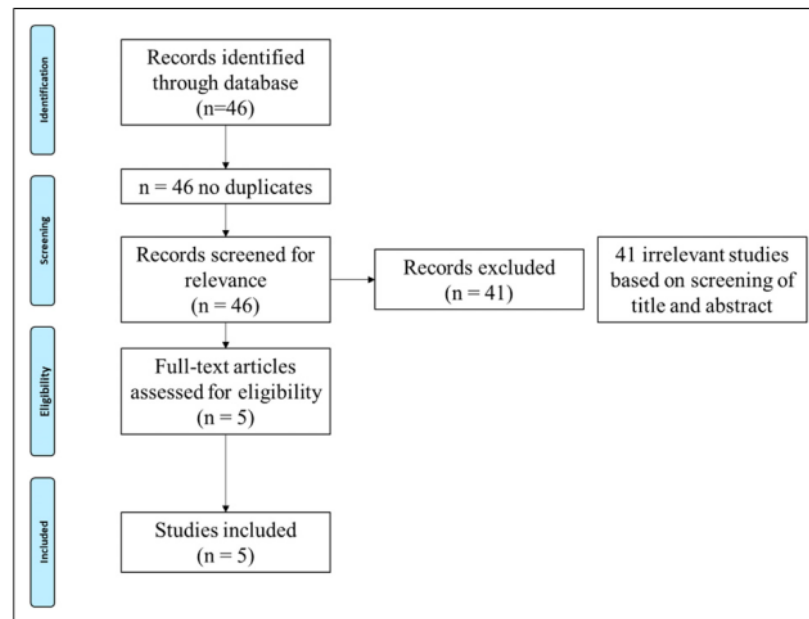
The risk of bias is unclear for confounding bias in all study due to the non-randomized single armed design. Intervention bias was unclear in two studies due to high variability of radiotherapy dosage.

Overall Survival

Massimino et al, reported in their study, the median OS is 15 months in patient with newly diagnosed diffuse intrinsic pontine glioma receiving nimotuzumab and vinorelbine. Median OS of Kebudi’s study in 2018 was 11 months in newly diagnosed group receiving combination of radiation, temozolomide and nimotuzumab and 12 months in progressive disease group receiving either temozolomide and nimotuzumab, carboplatin and nimotuzumab or vinorelbine and nimotuzumab. Median OS in Bartels et al for progressive disease DIPG receiving radiation and nimotuzumab was 3.2 months. Fleischhack reported median OS 9.4 months for newly diagnosed DIPG receiving radiation and nimotuzumab. Siraichainan reported median OS 22.8 months for high-grade glioma patients receiving combination of surgical, radiation, nimotuzumab and irinotectan.

Progression-Free Survival

The median PFS in Massimino study was 8.5 months. Kebudi reported median PFS 4 months for newly diagnosed DIPG and 3 months for progressive disease DIPG. In Bartels’ study, the



34
Figure 1. PRISMA flow diagram.

Table 1. Included studies.

Author, year	Type of study	Patients (n)	Patient characteristics	Length of follow-up	Type of intervention (n)	Outcome		
						OS*	PFS*	AE SAE/AE (n)
Massimino, 2014 ¹²	Phase II	25	Median age 6.1 yo ND DIPG	29 (19–42)	N + V	15	8.5	8 (2/8)
Kebudi, 2019 ¹³	Retrospective	24	Median age 7 yo ND DIPG	n/a	Radiation + N + TMZ	11	4	7 (0/7)
			Median age 6 yo PD DIPG	n/a	TMZ + N or N + C or N + V	12	3	
Bartels, 2014 ¹⁴	Phase II	44	Median age 6 yo PD DIPG	n/a	Radiation + N	3.2	1.7	54 (4/54)
Fleischhack, 2019 ¹⁵	Phase III	42	Median age 7.4 yo ND DIPG	n/a	Radiation + N	9.4	5.8	72 (8/72)
Sirachainan, 2017 ¹⁶	Cohort	16	Median age 7.95 yo GBM, AO, AA	12 (2.4–66)	Surgery + Radiation + N + I	22.8	21.6	4 (0/4)

AE: Adverse events, OS and PFS presented in median (months), length of follow-up presented in median, N: Nimotuzumab, C: Carboplatin, V: Vinorelbine, TMZ: Temozolamide, ND DIPG: Newly diagnosed diffuse intrinsic pontine glioma, PD DIPG: Progressive disease diffuse intrinsic pontine glioma, DIPG: Diffuse intrinsic pontine glioma, GBM: Glioblastoma, AA: Anaplastic astrocytoma, AO: Anaplastic oligoastrocytoma, I: Irinotecan.

median PFS was 1.7 months. Fleischhack et al reported median PFS 5.8 months. Sirachainan's study, in high-grade glioma patients, reported median PFS 21.6 months.

Adverse Events

Massimino reported 8 adverse events in their study, 1 grade hypokalemia, 1 appendicitis, 3 patients developed fever, 2

patients had acute respiratory infection, and 1 child developed iron deficiency. Kebudi's study recorded no adverse events in both newly diagnosed and progressive disease DIPG. Bartels' reported 54 adverse events, but only 21 are serious adverse events such as intracranial tumor hemorrhage and tumor necrosis. 72 adverse events were reported in Fleischhack's study, 8 of those were serious adverse events assessed to be possibly, probably, or definitely related to administration of

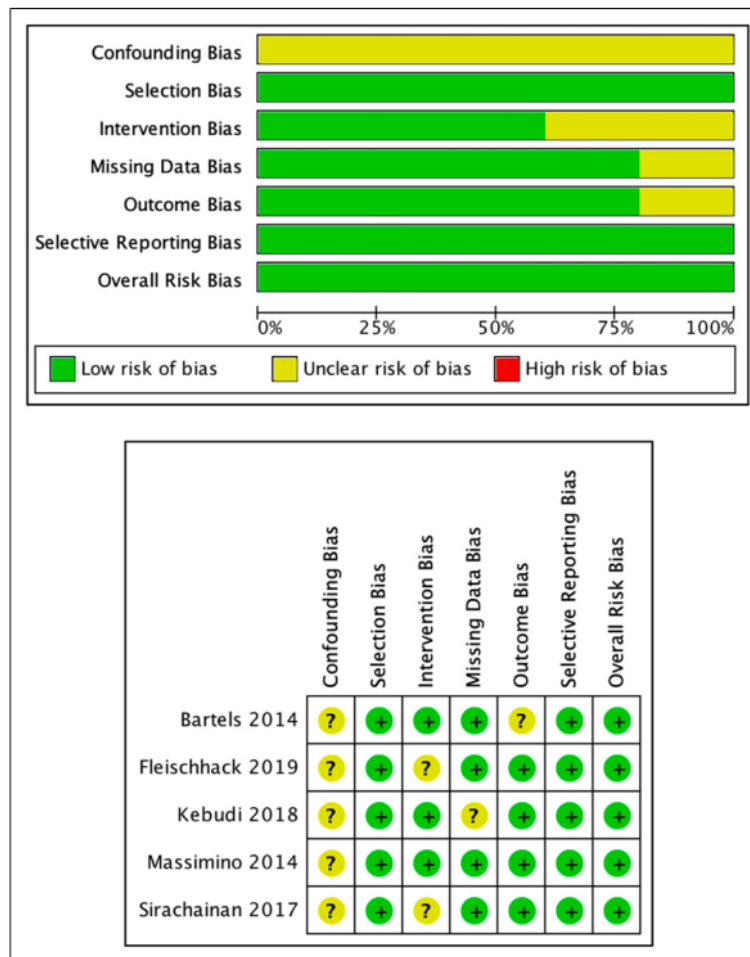


Figure 2. Result of ROBINS-I assesment. A, Risk assessment of bias using ROBINS-I for non-randomized studies in each study. B, the proportion of bias risk assessment results using ROBINS-I for the non-randomized study.

nimotuzumab. No serious adverse events were recorded in Sirachainan’s study.

Discussion

Overall Survival

Massimino et al reported in their study, the median OS is 15 months in patient with newly diagnosed diffuse intrinsic pontine glioma receiving nimotuzumab and vinerolbine. In comparison to all the other studies included in this systematic review, this number is fairly high considering it being the second highest after the study by Sirachainan et al. Massimino et al compared their OS rates with those of the patients accrued in the international BSC-PED-05 trial administering nimotuzumab with standard local radiotherapy for the primary

treatment of DIPG in children and adolescents.²¹ They concluded that their results were statistically different, with their study resulting in a higher number of OS of more than 5 months longer. The study also pointed out a difference in OS in regards to a more specific parameters analyzed. Seven patients whose tumor had been reduced more than 20% had a 1 and 2 year OS rates of 100% and 50 ± 20%, whilst 18 others whose had less tumor volume reduction had lower OS rates 67 ± 11% and 17 ± 10%, respectively. In addition, patients who were diagnosed at a younger age were reported to have better OS rates compared to older ones, along with the shunted compared to those who were not shunted. These are in accordance with previous literatures reporting of better prognosis in younger patients²² and those with shunts due to larger tumors leading to obstructive hydrocephalus,²³ although these previous studies did not analyze the effect of nimotuzumab on

DIPG. Although DIPG has been generally considered as having a poor prognosis, these results may incentivize further studies regarding its efficacy on specific populations of pediatric DIPG patients.

The median survival of newly diagnosed DIPG in the study by Kebudi et al was 11 months, while the progressive disease had a median survival of 12 months. These two numbers were reported to be not significantly different. The authors also compared these numbers with their previous report of DIPG patients before the use of nimotuzumab who received radiotherapy and temozolomide as standard therapy with median survival of 13 months. These indicate little or no benefits of nimotuzumab in terms of survival compared to previously established standard therapy for DIPG.²⁴ In comparison to the study by Massimino et al,²⁵ which is also included in this review, the study by Kebudi et al had shorter median survival of 3–4 months less. This may be due to the fact that patients who had repeat irradiation for DIPG was also included in the study by Massimino et al contributing to a longer OS, as evidently reported by previous studies.^{26,27} Fleischhack et al reported a median OS of 9.4 months for newly diagnosed DIPG receiving radiation and nimotuzumab. This study stated that DIPG itself is known to be most effectively treated with radiotherapy (RT). Until recently, the result of past studies shows inconsistent result of RT alone and RT combined with other adjuvant chemotherapy, including nimotuzumab. But nimotuzumab offers lower complications and can be administered in outpatient settings.

The median OS in the study by Bartels et al for progressive disease DIPG receiving radiation and nimotuzumab was 3.2 months. The mean survival of patients who completed induction therapy and showed progressive disease after completion of induction therapy was 4.87 months (2.9–8.93 months), which did not differ significantly compared with the overall survival participants with SD/PR of 9.4 months (range, 2.83–22.1 months). Bartels et al stated that the interpretation of these data is complex as the main limitation of their trial includes the lack of tissue material, which is necessary for the analysis of molecular correlation with clinical response. Patients were diagnosed through clinical and radiological confirmations only, who had failed standard first-line therapy. At the time their study was conducted, the data of safety for biopsy at initial diagnosis of DIPG have not yet been established.^{28,29} These may hinder further analysis of molecular study, especially regarding EGFR over expression or amplification, which is an important aspect in the mechanism of action of nimotuzumab itself. Nevertheless, the results of the OS was considerably unsatisfactory considering its similarity to previous studies reporting of failure in achieving optimal results of other therapeutic modalities for pediatric gliomas.^{30,31}

Siraichainan et al reported median OS 22.8 months for high-grade glioma patients receiving combination of surgical, radiation, nimotuzumab, and irinotecan. This study reported of the longest OS among all other literatures included in this study. In their study, only pediatric patients with newly

diagnosed high-grade glioma (HGG) were included. Different from all the other studies, this study did not exclusively involve DIPG, which is known to have bad prognosis despite multiple therapeutic modalities. The characteristics of tumor influence the prognostic factors of HGG. These include the extension of surgery, location, and histology.^{32,33} The study reported similar results in which patients who mostly had total tumor removal or near total removal were associated with better outcomes, in which their OS rate was as high as 66.7% after 45.6 months, conforming to a previous report that indicated gross tumor removal in children with HGG had an OS rate as high as 63% after 60 months.³⁴ Tumors located in the supratentorial region are also reported to have better prognosis in terms of OS, compared to those located infratentorially. Moreover, all patients whose tumors were located at the brainstem died from the tumor progression. This may explain the considerably large difference of OS from this study compared to other ones included in this review, in which half of the participants had supratentorial masses, compared to others who were mostly DIPG.^{25,35-37}

Progression-Free Survival

The median PFS in Massimino study was 8.5 months. Similarly to the OS, the PFS rates were significantly higher (5.8 months) compared to a previous study of nimotuzumab with standard local radiotherapy for primary treatment of DIPG in children and adolescents, despite having a difference not as high as the difference in OS.²¹ However, unlike the OS, Massimino et al²⁵ did not report of a better PFS in those of younger age and those who are shunted. There was also a pseudoprogression in one patient in which a patient had the tumor increased in size by 53% with worsening clinical symptoms, and other one patient with stable local disease who developed spinal dissemination. Despite these, the response rate was fairly high at 96%.

Having the next lower length of PFS, the median PFS of patients in the study by Fleischhack et al was 5.8 months. On the other hand, Kebudi et al reported of a PFS of 4 months in newly diagnosed DIPG pediatric patients. These numbers were similar to two other studies also involving nimotuzumab for DIPG.^{38,39} Similar to that of OS, data from MD Anderson also highlighted the importance of repeat radiation as the most effective treatment at relapse in terms of tumor progression.⁴⁰ The two studies were conducted by the same group, in which a phase III trial enrolled 42 children with newly diagnosed DIPG from Germany, Italy, and Russia during 2006 to 2007.³⁸ The median PFS was 5.9 months and the median OS was 9.7 months with a significantly longer survival in radiological responders than in non-responders. In 2011, the same group reported the results of 47 newly diagnosed patients where the median PFS was 7 months and OS was 11 months.³⁹ The indifference in the numbers from multiple studies regarding the PFS may show the lack of efficacy in terms of prolonging progression-free condition in DIPG patients.

²³ The study by Bartels et al reported of a median PFS of 1.7 months. This number is the lowest of all studies included in this review. The authors evaluated and determined clinical progression as sufficient for a participant to be considered failing at being progression-free in that time of follow-up. Hence, clinical progression was considered as tumor progression in this study. This classification may affect the determination of PFS itself, since it may be possible that patients who experienced clinical progression first, even without evidence of radiological progression, and reduces the median PFS itself to a shorter period of time. This also may contribute to the study having the shortest PFS among all the other studies included in this study.

Having the longest number among all of the studies included in this review, the study by Sirachainan et al reported a median PFS of 21.6 months in HGG patients. All tumors that were located at the brainstem progressed and ended up in death, indicating the significance of tumor location in the prognosis of glioma previously explained.^{32,33}

Reasons for this inconclusive result for the survival rate after nimotuzumab therapy are because not all of the gliomas respond significantly with anti-EGFR. Recent studies show there are some tumors that respond poorly to nimotuzumab because of the low level of EGFR and its related downstream effector kinases, such as proline rich Akt substrate of 40 kDa (PRAS40) and ribosomal protein S6 (RPS6). This study shows selection of the patient by the level of PRAS40 and RPS6 as markers, which might increase the benefit from the EGFR-blocking antibody nimotuzumab.^{41,42} A clear trend toward a benefit from nimotuzumab therapy was also detectable in that whole study cohort using activation of mTORC1 as a marker for dichotomy. In the future, selection of the patients by those markers may be necessary to determine the decision for nimotuzumab administration.⁴²

Adverse Events

Massimino et al reported eight adverse events in their study, 1 grade hypokalemia, 1 appendicitis, 3 patients developed fever, 2 patients had acute respiratory infection, and 1 child developed iron deficiency. These results were safe considering none had a hematological toxicity beyond grade 1 and only 8 out of 25 had AEs. One child died 7 months after the beginning of trial due to infectious complications of shunt, although the authors did not report any correlation with the nimotuzumab intervention.⁵⁶

In terms of safety, patients in the study by Kebudi et al did not show major adverse effect. There were cases of mild thrombocytopenia that required no erythrocyte transfusion, and no other major therapeutic approach was required for any kinds of adverse events. Similar to other studies regarding the safety of nimotuzumab on DIPG, this study highlighted its safety, despite the questionable results in its efficacy on prolonging survival and tumor progression.

Out of 44 patients, Bartels' reported 54 different adverse events related to the drug, but only 4 were serious adverse

events, such as grade 3 lymphopenia, neutropenia, hypokalemia, intracranial tumoral hemorrhage, and necrosis. The remaining majority were mild to moderate (grade 1-2) in severity. Other adverse events were unrelated/unlikely related to the study drug but were rather due to CNS dysfunction and disease progression. These were mostly attributed to the disease progression itself. Although a causal relationship to the treatment with nimotuzumab cannot be ruled out with certainty, the occurrence of spontaneous intra-tumoral bleeding in the disease course of DIPGs is reported in nearly 20% of patients and is most commonly located in the necrotic area of the tumors.⁴³

The study by Fleishhack et al reported 72 adverse events, in which 8 of those were serious adverse events assessed to be possibly, probably, or definitely related to administration of nimotuzumab. The authors concluded that nimotuzumab administered concomitantly and continued after RT was well tolerated and had comparable efficacy to the combination of intensive chemotherapy and RT. Despite serious therapy-related adverse events that were still reported, including intra-tumoral bleeding and acute respiratory failure occurring in 2 different patients, these occurrences were difficult to distinguish from the effects of the tumor progression themselves.

The study by Sirachainan et al reported of no serious adverse events in all of the patients included in their study. Grade 1 anemia was found in 3 patients, and 1 patient developed watery diarrhea due to irinotecan, which responded to 23 doses of loperamide. Previously reported side effects associated with long-term treatment (up to 2 years) with nimotuzumab include skin rash and mucositis, which did not occur in any of the patients in the study by Sirachainan et al.⁴⁴ Although the authors explained that this may be due to the shorter duration or different population, other studies reporting the safety of nimotuzumab conform to the result in this study, in which it is deemed safe for use in pediatric patients with glioma.

⁴⁶ Limitations

There were several limitations in this study. The first being not all studies included in the analysis were RCTs. Randomized controlled trials have the strongest level of evidence just below systematic reviews and meta-analysis, yet some of the literatures in this study include cohort and retrospective studies. Second, there were different types of interventions between studies included in this analysis. Similar types of the same variable (i.e., intervention) may increase the strength of evidence regarding a specific type variable, but the limitation of study availability may hinder this study from achieving that kind of result.

Novelty

We propose several novelties that this study provides. First, our study systematically reviewed the use of nimotuzumab as an adjunct therapy for glioma in pediatric patients, which, to

the authors' knowledge, has not been conducted before. Second, although the majority result of studies still show no significant differences found in the PFS and OS of using nimotuzumab as an adjunct therapy for pediatric, this analysis provided evidence for a possible additional benefit of nimotuzumab as adjuvant therapy in pediatric glioma, indicating the need for more possibly larger studies to further elaborate nimotuzumab's role in treating pediatric glioma. Third, there was a minimum AE reported from multiple studies, indicating nimotuzumab's safety for pediatric glioma. Although these may still require further studies to validate our findings, this study may serve as a scientific basis or incentive for many other researchers to study the use of nimotuzumab for pediatric glioma.

Conclusions

There are no significant differences in the PFS and OS of nimotuzumab as an adjunct therapy for pediatric compared to result of standard therapy in majority of previous studies. There were also no differences in the AE of nimotuzumab for pediatric glioma between studies, and low event of SAE indicating its safety. But still there is an evidence of possible benefit of nimotuzumab as adjuvant therapy in pediatric glioma. We recommend further studies with larger number of patients that may lead to possibly different results. There should also be more studies with better level of evidence to further validate the effect of nimotuzumab on pediatric glioma.

Acknowledgements

The authors would like to acknowledge Dr. Soetomo General Academic Hospital and Surabaya Neuroscience Institute for its support in this study.

Declaration of Conflicting Interests

The author(s) declared no potential conflicts of interest with respect to the research, authorship, and/or publication of this article.

Funding

The author(s) received no financial support for the research, authorship, and/or publication of this article.

Ethical Approval

This article is systematic review. Ethical permission and patient consent are not necessary.

ORCID iD

Bagus Sulistiono  <https://orcid.org/0000-0001-7776-8788>

References

- Ostrom QT, Gittleman H, Farah P, et al. CBTRUS statistical report: Primary brain and central nervous system tumors diagnosed in the United States in 2006-2010. *Neuro Oncol.* 2013;15(suppl 2):ii1-ii56. doi:10.1093/neuonc/not151.
- McNeill KA. Epidemiology of brain tumors. *Neurol Clin.* 2016; 34(4):981-998. doi:10.1016/j.ncl.2016.06.014.
- Stupp R, Hegi ME, Mason WP, et al. Effects of radiotherapy with concomitant and adjuvant temozolomide versus radiotherapy alone on survival in glioblastoma in a randomised phase III study: 5-year analysis of the EORTC-NCIC trial. *Lancet Oncol.* 2009;10(5):459-466. doi:10.1016/S1470-2045(09)70025-7.
- Blionas A, Giakoumettis D, Klonou A, Neromyliotis E, Karydakis P, Themistocleous MS. Paediatric gliomas: Diagnosis, molecular biology and management. *Ann Transl Med.* 2018; 6(12):251. doi:10.21037/atm.2018.05.11.
- Diwanji TP, Engelman A, Snider JW, Mohindra P. Epidemiology, diagnosis, and optimal management of glioma in adolescents and young adults. *Adolesc Health Med Therapeut.* 2017;Volume 8:99-113. doi:10.2147/ahmt.s53391.
- Kanti Das K, Kumar R, Kumar R. Pediatric glioblastoma. In: De Vleeschouwer, ed. *Glioblastoma*. Brisbane: Codon Publications; 2017:297-312. DOI: 10.15586/codon.glioblastoma.2017.Glioblastoma
- Warren KE. Diffuse intrinsic pontine glioma: Poised for progress. *Frontiers in Oncology.* 2012;2:205. doi:10.3389/fonc.2012.00205.
- Fisher PG, Breiter SN, Carson BS, et al. A clinicopathologic reappraisal of brain stem tumor classification. *Cancer.* 2000;89(7): 1569-1576. doi:10.1002/1097-0142(20001001)89:7<1569::aid-cncr22>3.0.co;2-0.
- Donaldson SS, Laningham F, Fisher PG. Advances toward an understanding of brainstem gliomas. *J Clin Oncol.* 2006;24(8): 1266-1272. doi:10.1200/JCO.2005.04.6599.
- Yoshimura J, Onda K, Tanaka R, Takahashi H. Clinicopathological study of diffuse type brainstem gliomas: Analysis of 40 autopsy cases. *Neurol Med -Chir.* 2003;43(8):375-382. doi:10.2176/nmc.43.375.
- Langmoen IA, Lundar T, Storm-Mathisen Ir., Lie SO, Hovind KH. Management of pediatric pontine gliomas. *Child's Nerv Syst.* 1991;7(1):13-15. doi:10.1007/BF00263825.
- Perrone MG, Ruggiero A, Centonze A, Carrieri A, Ferorelli S, Scilimati A. Diffuse intrinsic pontine glioma (DIPG): Breakthrough and clinical perspective. *Curr Med Chem.* 2021;28(17): 3287-3317. doi:10.2174/0929867327666200806110206.
- Johung T, Monje M. Diffuse intrinsic pontine glioma: New pathophysiological insights and emerging therapeutic targets. *Curr Neuropharmacol.* 2016;15(1):88-97. doi:10.2174/1570159X14666160509123229.
- Normanno N, De Luca A, Bianco C, et al. Epidermal growth factor receptor (EGFR) signaling in cancer. *Gene.* 2006;366(1): 2-16. doi:10.1016/j.gene.2005.10.018.
- Bredel M, Pollack IF, Hamilton RL, James CD. Epidermal growth factor receptor expression and gene amplification in high-grade non-brainstem gliomas of childhood. *Clin Cancer.* 1999;5(7):1786-1792.

16. Diaz Miqueli A, Rolff J, Lemm M, Fichtner I, Perez R, Montero E. Radiosensitisation of U87MG brain tumours by anti-epidermal growth factor receptor monoclonal antibodies. *Br J Cancer*. 2009;100(6):950-958. doi:10.1038/sj.bjc.6604943.
17. Chen Z-p., Yang Q, Guo C-c.. Profile of nimotuzumab in the treatment of high-grade glioma. *OncoTargets Ther*. 2015;8: 819-825. doi:10.2147/OTT.S60032.
18. Higgins J, Thomas J, Chandler J, et al., eds. *Cochrane Handbook for Systematic Reviews of Interventions*. Chichester, England: Cochrane; 2020. Version 6.1(Updated September 2020).
19. Sterne JA, Hernán MA, Reeves BC, et al. ROBINS-I: A tool for assessing risk of bias in non-randomised studies of interventions. *Bmj*. 2016;355:i4919. Published online October 12. doi: 10.1136/bmj.i4919.
20. Lo CK-L, Mertz D, Loeb M. Newcastle-Ottawa Scale: Comparing reviewers' to authors' assessments. *BMC Med Res Methodol*. 2014;14(1):45. doi:10.1186/1471-2288-14-45.
21. Bode U, Massimino M, Bach F, et al. Nimotuzumab treatment of malignant gliomas. *Expert Opin Biol Ther*. 2012;12(12): 1649-1659. doi:10.1517/14712598.2012.733367.
22. Broniscer A, Laningham FH, Sanders RP, Kun LE, Ellison DW, Gajjar A. Young age may predict a better outcome for children with diffuse pontine glioma. *Cancer*. 2008;113(3):566-572. doi: 10.1002/cncr.23584.
23. Sedlacik J, Winchell A, Kocak M, Loeffler RB, Broniscer A, Hillenbrand CM. MR imaging assessment of tumor perfusion and 3D segmented volume at baseline, during treatment, and at tumor progression in children with newly diagnosed diffuse intrinsic pontine glioma. *Am J Neuroradiol*. 2013;34(7): 1450-1455. doi:10.3174/ajnr.A3421.
24. Kebudi R, Cakir FB, Agaoglu FY, Gorgun O, Ayan I, Darendeliler E. Pediatric diffuse intrinsic pontine glioma patients from a single center. *Child's Nerv Syst*. 2013;29(4):583-588. doi: 10.1007/s00381-012-1986-3.
25. Massimino M, Biassoni V, Miceli R, et al. Results of nimotuzumab and vinorelbine, radiation and re-irradiation for diffuse pontine glioma in childhood. *J Neuro Oncol*. 2014;118(2): 305-312. doi:10.1007/s11060-014-1428-z.
26. Janssens GO, Gandola L, Bolle S, et al. Survival benefit for patients with diffuse intrinsic pontine glioma (DIPG) undergoing re-irradiation at first progression: A matched-cohort analysis on behalf of the SIOP-E-HGG/DIPG working group. *European Journal of Cancer*. 2017;73:38-47. doi:10.1016/j.ejca.2016.12.007.
27. Lassaletta A, Strother D, Laperriere N, et al. Reirradiation in patients with diffuse intrinsic pontine gliomas: The Canadian experience. *Pediatr Blood Cancer*. 2018;65(6):e26988. doi:10.1002/pbc.26988.
28. Chassot A, Canale S, Varlet P, et al. Radiotherapy with concurrent and adjuvant temozolomide in children with newly diagnosed diffuse intrinsic pontine glioma. *J Neuro Oncol*. 2012;106(2):399-407. doi:10.1007/s11060-011-0681-7.
29. Puget S, Blauwblomme T, Grill J. Is biopsy safe in children with newly diagnosed diffuse intrinsic pontine glioma? *Am Soc of Clin Oncol Educ B*. 2012;32:629-633. doi:10.14694/EdBook_AM.2012.32.59.
30. Korones DN, Fisher PG, Kretschmar C, et al. Treatment of children with diffuse intrinsic brain stem glioma with radiotherapy, vincristine and oral VP-16: A children's oncology group phase II study. *Pediatr Blood Cancer*. 2008;50(2): 227-230. doi:10.1002/pbc.21154.
31. Cohen KJ, Heideman RL, Zhou T, et al. Temozolomide in the treatment of children with newly diagnosed diffuse intrinsic pontine gliomas: A report from the children's oncology group. *Neuro Oncol*. 2011;13(4):410-416. doi:10.1093/neuonc/nuq205.
32. Gottardo NG, Gajjar A. Chemotherapy for malignant brain tumors of childhood. *J Child Neurol*. 2008;23(10):1149-1159. doi:10.1177/0883073808321765.
33. Qaddoumi I, Sultan I, Gajjar A. Outcome and prognostic features in pediatric gliomas. *Cancer*. 2009;115(24):5761-5770. doi:10.1002/cncr.24663.
34. Wolff JEA, Driever PH, Erdlenbruch B, et al. Intensive chemotherapy improves survival in pediatric high-grade glioma after gross total resection: Results of the HIT-gBM-c protocol. *Cancer*. 2010;116(3):705-712. doi:10.1002/cncr.24730.
35. Fleischhack G, Massimino M, Warmuth-Metz M, et al. Nimotuzumab and radiotherapy for treatment of newly diagnosed diffuse intrinsic pontine glioma (DIPG): A phase III clinical study. *J Neuro Oncol*. 2019;143(1):107-113. doi:10.1007/s11060-019-03140-z.
36. Kebudi R, Cakir FB, Bay SB, et al. Nimotuzumab-containing regimen for pediatric diffuse intrinsic pontine gliomas: A retrospective multicenter study and review of the literature. *Child's Nerv Syst*. 2019;35(1):83-89. doi:10.1007/s00381-018-4001-9.
37. Bartels U, Wolff J, Gore L, et al. Phase 2 study of safety and efficacy of nimotuzumab in pediatric patients with progressive diffuse intrinsic pontine glioma. *Neuro Oncol*. 2014;16(11): 1554-1559. doi:10.1093/neuonc/nou091.
38. Bode U, Windelberg M, Massimino M, et al. Phase III trial of nimotuzumab for the treatment of newly diagnosed diffuse intrinsic pontine gliomas in children and adolescents. *J Clin Oncol*. 2008;26(15_suppl 1):2058. doi:10.1200/jco.2008.26.15_suppl.2058.
39. Massimino M, Bode U, Biassoni V, Fleischhack G. Nimotuzumab for pediatric diffuse intrinsic pontine gliomas. *Expert Opin Biol Ther*. 2011;11(2):247-256. doi:10.1517/14712598.2011.546341.
40. Wolff JE, Rytting ME, Vats TS, et al. Treatment of recurrent diffuse intrinsic pontine glioma: The MD anderson cancer center experience. *J Neuro Oncol*. 2012;106(2):391-397. doi:10.1007/s11060-011-0677-3.
41. Ronellenfitsch MW, Zeiner PS, Mittelbronn M, et al. Akt and mTORC1 signaling as predictive biomarkers for the EGFR antibody nimotuzumab in glioblastoma. *Acta Neuropathologica*

- Communications*. 2018;6(1):81. doi:[10.1186/s40478-018-0583-4](https://doi.org/10.1186/s40478-018-0583-4).
42. Luger A-L, Lorenz NI, Urban H, et al. Activation of epidermal growth factor receptor sensitizes glioblastoma cells to hypoxia-induced cell death. *Cancers*. 2020;12(8):2144. doi:[10.3390/cancers12082144](https://doi.org/10.3390/cancers12082144).
43. Broniscer A, Laningham FH, Kocak M, et al. Intratumoral hemorrhage among children with newly diagnosed, diffuse brainstem glioma. *Cancer*. 2006;106(6):1364-1371. doi:[10.1002/cncr.21749](https://doi.org/10.1002/cncr.21749).
44. Sirachainan NN, Boongird T, Swangsilpa A, Klaisuban S, Lusawat A, Hongeng S. Reported outcomes of children with newly diagnosed high-grade gliomas treated with nimotuzumab and irinotecan. *Child's Nervous System*. 2017;33(6):893-897. doi:[10.1007/s00381-017-3409-y](https://doi.org/10.1007/s00381-017-3409-y).

Nimotuzumab as additional therapy for GLIOMA in ediatric and Adolescent A systematic Review

ORIGINALITY REPORT

18%

SIMILARITY INDEX

15%

INTERNET SOURCES

16%

PUBLICATIONS

0%

STUDENT PAPERS

PRIMARY SOURCES

1	onlinelibrary.wiley.com Internet Source	1%
2	researchportal.northumbria.ac.uk Internet Source	1%
3	thejns.org Internet Source	1%
4	Tessa Johung, Michelle Monje. "Diffuse Intrinsic Pontine Glioma: New Pathophysiological Insights and Emerging Therapeutic Targets", Current Neuropharmacology, 2016 Publication	1%
5	atm.amegroups.com Internet Source	1%
6	pure.rug.nl Internet Source	1%
7	www.physiciansweekly.com Internet Source	1%

8	Ayu Yoniko Christi, Nur Setiawan Suroto, Zaky Bajamal, Asra Al Fauzi. "Primary mechanical thrombectomy for anterior circulation stroke in children: Report of two cases and literature review", International Journal of Surgery Case Reports, 2021 Publication	1 %
9	www.pbtc.org Internet Source	1 %
10	journals.plos.org Internet Source	1 %
11	actaneurocomms.biomedcentral.com Internet Source	<1 %
12	"Cancer Immunology", Springer Science and Business Media LLC, 2020 Publication	<1 %
13	Www.dovepress.com Internet Source	<1 %
14	Asra Al Fauzi, Yunus Kuntawi Aji, Rudy Gunawan, Nur Setiawan Suroto. "Neuroangiography patterns and anomalies of middle cerebral artery: A systematic review", Surgical Neurology International, 2021 Publication	<1 %
15	ccforum.biomedcentral.com Internet Source	

<1 %

16

worldwidescience.org

Internet Source

<1 %

17

repository.unair.ac.id

Internet Source

<1 %

18

www.researchgate.net

Internet Source

<1 %

19

Brian R. Rood, Tobey J. MacDonald. "Pediatric High-grade Glioma: Molecular Genetic Clues for Innovative Therapeutic Approaches", *Journal of Neuro-Oncology*, 2005

Publication

<1 %

20

journals.viamedica.pl

Internet Source

<1 %

21

www.ajnr.org

Internet Source

<1 %

22

insights.ovid.com

Internet Source

<1 %

23

"Advances in Biology and Treatment of Glioblastoma", Springer Science and Business Media LLC, 2017

Publication

<1 %

24

Michael W. Ronellenfitsch, Pia S. Zeiner, Michel Mittelbronn, Hans Urban et al. "Akt

<1 %

and mTORC1 signaling as predictive biomarkers for the EGFR antibody nimotuzumab in glioblastoma", Acta Neuropathologica Communications, 2018

Publication

25

www.tandfonline.com

Internet Source

<1 %

26

Anusuya V, Ashok Kumar Jena, Jitendra Sharan. "Effects of functional appliance treatment on pharyngeal airway passage dimensions in Class II malocclusion subjects with retrognathic mandibles: A systematic review", APOS Trends in Orthodontics, 2019

Publication

<1 %

27

Sean Beggs, Yi Chao Foong, Hong Cecilia T Le, Danial Noor, Richard Wood-Baker, Julia AE Walters. "Swimming training for asthma in children and adolescents aged 18 years and under", Cochrane Database of Systematic Reviews, 2013

Publication

<1 %

28

Www.statpearls.com

Internet Source

<1 %

29

eprints.whiterose.ac.uk

Internet Source

<1 %

30

Gordon Li, Siddhartha S. Mitra, Michelle Monje, Kristy N. Henrich, C. Dana Bangs, Ryan

<1 %

T. Nitta, Albert J. Wong. "Expression of epidermal growth factor variant III (EGFRvIII) in pediatric diffuse intrinsic pontine gliomas", *Journal of Neuro-Oncology*, 2012

Publication

31

www.clinicaltrialsarena.com

Internet Source

<1 %

32

www.omicsonline.org

Internet Source

<1 %

33

Novak, U.. "Expression of EGFR-family proteins in the brain: role in development, health and disease", *Journal of Clinical Neuroscience*, 200103

Publication

<1 %

34

chiromt.biomedcentral.com

Internet Source

<1 %

35

cyberleninka.org

Internet Source

<1 %

36

www.frontiersin.org

Internet Source

<1 %

37

Ahmad Y. Jabbar, Hassan Baydoun, Maissaa Janbain, Keith C. Ferdinand. "Current concepts in the management of stable ischemic heart disease and acute coronary syndrome in patients with hemophilia", *Annals of Translational Medicine*, 2018

Publication

<1 %

38 Bradford, Natalie, Edwards, Rachel, Chan, Ray. "Heparin versus 0.9% sodium chloride intermittent flushing for the prevention of occlusion in long term central venous catheters in infants and children", 'Wiley', 2015
Internet Source <1 %

39 Jetan Badhiwala, William K Decker, Michael E Berens, Ratan D Bhardwaj. "Clinical trials in cellular immunotherapy for brain/CNS tumors", Expert Review of Neurotherapeutics, 2014
Publication <1 %

40 Xiaofan Guo, Wei Qiu, Jian Wang, Qinglin Liu et al. " Glioma exosomes mediate the expansion and function of myeloid - derived suppressor cells through microRNA - 29a/ and microRNA - 92a/ pathways ", International Journal of Cancer, 2019
Publication <1 %

41 content.iospress.com
Internet Source <1 %

42 mdpi-res.com
Internet Source <1 %

43 mediccreview.org
Internet Source <1 %

44

Cabanas, Ricardo, Giselle Saurez, Martha Rios, Jose Alert, Adnolys Reyes, Jose Valdes, Maria C. Gonzalez, Jorge L. Pedrayes, Melba Avila, Raiza Herrera, Mariela Infante, Ernesto Echevarria, Myrna Moreno, Patricia Lorenzo Luaces, and Tania Crombet Ramos.
"Treatment of children with high grade glioma with nimotuzumab: A 5-y institutional experience", mAbs, 2013.

Publication

<1 %

45

Matthew Gallitto, Stanislav Lazarev, Isaac Wasserman, James M. Stafford et al. "Role of Radiation Therapy in the Management of Diffuse Intrinsic Pontine Glioma: A Systematic Review", Advances in Radiation Oncology, 2019

Publication

<1 %

46

Ryan H. Barnes, Anthony V. Paterno, Feng-Chang Lin, Jingru Zhang, David Berkoff, R. Alexander Creighton. "Glenohumeral Hydrodistension for Postoperative Stiffness After Arthroscopic Primary Rotator Cuff Repair", Orthopaedic Journal of Sports Medicine, 2022

Publication

<1 %

47

Wihasto Suryaningtyas, Joni Wahyuhadi, Agus Turchan, Eko Agus Subagio et al.
"Neurosurgery at the epicenter of the COVID-

<1 %

19 pandemic in Indonesia: experience from a
Surabaya academic tertiary hospital",
Neurosurgical Focus, 2020

Publication

48 academic.oup.com <1 %
Internet Source

49 archive.org <1 %
Internet Source

50 ebin.pub <1 %
Internet Source

51 www.dovepress.com <1 %
Internet Source

52 www.lifeextension.com <1 %
Internet Source

53 www.oapen.org <1 %
Internet Source

54 www.oncotarget.com <1 %
Internet Source

55 Katherine O'Flaherty, Julia Maguire, Julie A. Simpson, Freya J. I. Fowkes. "Immunity as a predictor of anti-malarial treatment failure: a systematic review", Malaria Journal, 2017
Publication

56 "Textbook of Pediatric Neurosurgery", Springer Science and Business Media LLC, 2020 <1 %

57

John M. Allen, Lolade Bakare, Anthony M. Casapao, Ken Klinker, Lindsey M. Childs-Kean, Ariel F. Pomputius. "Cefazolin Versus Anti-Staphylococcal Penicillins for the Treatment of Patients with Methicillin-Susceptible Staphylococcus aureus Infection: A Meta-Analysis with Trial Sequential Analysis", *Infectious Diseases and Therapy*, 2019

Publication

<1 %

58

doi.org
Internet Source

<1 %

59

livrepository.liverpool.ac.uk
Internet Source

<1 %

Exclude quotes On

Exclude matches Off

Exclude bibliography On

Nimotuzumab as additional therapy for GLIOMA in ediatric and Adolescent A systematic Review

GRADEMARK REPORT

FINAL GRADE

/100

GENERAL COMMENTS

Instructor

PAGE 1

PAGE 2

PAGE 3

PAGE 4

PAGE 5

PAGE 6

PAGE 7

PAGE 8

PAGE 9

PAGE 10