

A case report of pediatric  
germinoma with SARS-CoV-2  
Lessons learned from an  
academic tertiary referral  
hospital in Asian COVID  
Episentrum

*by* Mustaqim Apriyansa Rahmadhan

---

**Submission date:** 24-Jun-2022 10:19AM (UTC+0800)

**Submission ID:** 1862079148

**File name:** cademic\_tertiary\_referral\_hospital\_in\_Asian\_COVID\_Episentrum.pdf (859.73K)

**Word count:** 4070

**Character count:** 23009



ELSEVIER

Contents lists available at ScienceDirect

## International Journal of Surgery Case Reports

journal homepage: [www.elsevier.com/locate/ijscr](http://www.elsevier.com/locate/ijscr)

## Case report

## A Case Report of Pediatric Germinoma With SARS-CoV-2: Lessons Learned From an Academic Tertiary Referral Hospital in Asian COVID Epicentrum

Mustaqim Apriyansa Rahmadhan, M. Arifin Parenrengi<sup>\*</sup>, Wihasto Suryaningtyas

Department of Neurosurgery, Dr. Soetomo Academic General Hospital – Faculty of Medicine Universitas Airlangga, Surabaya, Indonesia

## ARTICLE INFO

**Keywords:**  
 COVID-19  
 Pediatric  
 Brain tumor  
 Germinoma

## ABSTRACT

**Background:** Patients often present with one or more pre-existing underlying chronic diseases that will affect their prognoses and mortality. A study revealed that the majority of children with SARS-CoV-2 infection presented with either no or a single symptom. Meanwhile, multiple other studies reported of more severe diseases in SARS-CoV-2 infected children with brain tumor and/or cancer as a whole.

**Case report:** The patient was a 15-year-old male who was referred to our hospital with complaints of vomiting, headache, and signs of worsening right hemiparesis. Initial MRI suggested of a high-grade astrocytoma and hydrocephalus, but a subtotal tumor resection and external ventricular drainage gave light to a histopathological examination conclusive of germinoma. After adhering to radiotherapy and recovering well, the patient fell into unconsciousness 9 months later and tested positive for SARS-CoV-2 infection. The patient deteriorated on the third day of admission with respiratory failure, shock, arrhythmias, fever, and increased d-dimer. After multiple attempts stabilization with ventilatory, defibrillator, and medical support, the patient deceased at the 6th day of admission.

**Discussion:** Cancer patients with COVID-19 have been reported to have relatively higher mortality rate when compared to the non-infected patients. Moreover, malignancies were also reported to increase the risk of developing more severe disease in children. Although rare, patients may develop a condition called multisystem inflammatory syndrome in children (MIS-C), which is a state of hyperinflammatory and severe illness temporally associated with COVID-19 infection. No observations have been evident in indicating the influence of COVID-19 on the neurological state of the patient, but we believe that it may be reasonable to not yet exclude the possibility of it exacerbating the CNS malignancy our patient suffered from.

**Conclusion:** Children with intracranial brain tumor infected by SARS-CoV-2 may fall into a worse condition with poor prognosis, exacerbated by severe acute respiratory distress and the need for breathing support in intensive care unit. Multidisciplinary tumor boards have to convene regularly, including through call-conferences and telemedicine platforms.

## 1. Background

The Coronavirus Disease (COVID-19) caused by a novel zoonotic coronavirus (SARS-CoV-2) emerged from Wuhan, China and rapidly escalated into a global pandemic. A systematic review conducted by Christophers *et al.* revealed that the majority of children with SARS-CoV-2 presented with either no symptoms or a single symptom, with 75% of asymptomatic children exhibiting abnormal chest radiography or computed tomography findings [1].

The first case reported in Indonesia was on March 2020, and ever

since then the number of active cases of COVID-19 has grown exponentially with a mortality rate of 8,9%. As the top referral hospital in the East Java province, Dr. Soetomo Academic General Hospital (DSAGH) gives a standard health care of tertiary referral hospital [2]. East Java, in August 2021, based on the data of East Java Province Government, has 383.209 cumulative cases with 28.204 death cases. Indonesia has become a large epicentrum in Asia.

The Indonesian Pediatric Society have reported 2712 confirmed pediatric cases of COVID-19 with 51 deaths on 20th of July 2020. The highest mortality rate was seen in patients aged >10 years and those

<sup>\*</sup> Corresponding author at: Department of Neurosurgery, Airlangga University/Dr. Soetomo, Jalan Mayjen, Prof Dr. Moetopo No 6-8, Surabaya, East Java 60286, Indonesia.

E-mail address: [muhammad.arifin@fk.unair.ac.id](mailto:muhammad.arifin@fk.unair.ac.id) (M.A. Parenrengi).

<https://doi.org/10.1016/j.ijscr.2022.106774>

Received 3 September 2021; Received in revised form 10 January 2022; Accepted 10 January 2022

Available online 17 January 2022

2210-2612/© 2022 Published by Elsevier Ltd on behalf of IJS Publishing Group Ltd. This is an open access article under the CC BY-NC-ND license

<http://creativecommons.org/licenses/by-nc-nd/4.0/>.

placed in severe category upon admission. Most patients presented with generalized or systemic symptoms such as fever, malaise, myalgia and fatigue. This condition is interchangeably referred to as pediatric inflammatory multisystem syndrome temporally associated with SARS-CoV-2 (PIMS-TS) or multisystem inflammatory syndrome in children (MIS-C) associated with COVID-19 [1].

As an academic centre is a national tertiary referral hospital, patients often present with one or more pre-existing underlying chronic diseases that will affect their prognoses and mortality. The present findings differ from those of another study which reported that 86% of patients had at least one comorbidity, with the most prevalent pre-existing conditions being medically complex conditions (40%), immunosuppression or malignancy (23%), and obesity (15%). There were two deaths reported in this study, and both of the patients who died had comorbidities [3].

Children with delayed brain cancer diagnosis have a higher risk for developing irreversible neurological disabilities from acquired brain lesions, such as loss of vision and endocrinopathies. Changes in the decision-making process for children with brain tumors due to fear and pressure of SARS-CoV-2 infection could negatively influence their final outcome [3].

## 2. Case report

We report a case of a 15-year-old male with germinoma, who tested positive for SARS-CoV-2 on June 19th, 2021. This case report is in accordance with the SCARE Guideline [4].

The problem began a year earlier, with a worsening right hemiparesis. The patient already received a medical support from a remote hospital far from ours, and was diagnosed with a brain abscess without any surgical intervention. In September 2020, he was referred to our hospital, as one of the tertiary medical centre in Indonesia, with a chief complaint of vomiting for 4 times in the last 3 h. The vomiting was accompanied with a headache. He was given dexamethasone with a loading dose of 10 mg, continued with a maintenance dose of 5 mg 3 times a day. Scheduled brain magnetic resonance imaging revealed high grade astrocytoma and obstructive hydrocephalus (Fig. 1).

Surgical intervention was performed through a subtotal tumor resection and external ventricular drainage to relieve the hydrocephalus. The histopathological examination of the tumor sample was conclusive of germinoma. A month after the surgery, the patient began undergoing a radiotherapy protocol of total 40 Gy for 27 times. Due to the operation and patient's adherence to the radiation protocol, the patient recovered well.

On June 2021, he was admitted to the emergency department after experiencing a seizure for 30 min followed by decreased consciousness. Since March 2020, a "lockdown" for all Indonesian citizen was adopted; and a screening program through nasopharyngeal swab (NPS) for every

patient with any kind of intervention, emergency or elective, was encouraged. The patient underwent NPS and revealed a positive result for SARS-CoV-2. Upon admission, he weighed 54 kg, with a heart rate of 88 bpm, blood pressure of 110/80 mm Hg. The patient also presented with no catarrhal inflammation of the mucous membranes, no hepatosplenomegaly, no abnormalities upon auscultation of both the heart and lungs, and a tracheostomy status from previous admission. His body temperature was 36.8 °C. Laboratory studies were normal except for a white blood cell count of  $20,46 \times 10^3$  cells/ $\mu$ L, 73,5% neutrophils and 21,7% lymphocytes, and a CRP of 4,6. Chest x-ray revealed a right hemithorax infiltrate suggestive of pneumonia (Fig. 2). Oxygen saturation (SpO<sub>2</sub>) was 96–99%. Neurological status in the emergency room was E<sub>3</sub>M<sub>5</sub>V<sub>x</sub> (tracheostomy), symmetrical pupils with normal light reflexes, and spastic limbs. Patient received an antiviral treatment of remdesivir 100 mg/24 h.

On the third day of admission, the patient started to develop a fluctuating fever up to 39 °C. Decreased condition occurred with a hypovolemic shock caused by massive diarrhea. The vital signs were 131/71 mmHg (supported by 50 ng of nor-epinephrine), HR 200×/min, and an ECG indicative of ventricular tachycardia (Fig. 3). Neurological status revealed a GCS of E<sub>1</sub>M<sub>4</sub>V<sub>x</sub> with asymmetrical pupils. In regards to the ventricular tachycardia and unstable condition, a cardioversion with 150 J was performed. After three times of cardioversion with DC shock, the heart rate began to slow down (174×/min), although the ECG still showed a VT. Amiodarone was administered for maintenance. Laboratory evaluation was within normal limits, but we found an increased D-dimer of 2980, and blood gas analysis revealed a severe respiratory acidosis and failure. The SARS CoV-2 pandemic made it hard to find a ventilator to support the respiratory failure of the patient.

On the fourth day, the patient's condition worsened with arrhythmias (refractory VT) that cannot be overcome by medical and direct cardioversion (Fig. 4). Neurological condition revealed a motor posturing, decerebrated, bilaterally dilate pupils, and no light reflexes. Breathing problem of the patient was indicated by the increased respiratory rate and decreased saturation of 90% with maximum oxygen delivery using Jackson-Rees Circuit (15 lpm). We still administered remdesivir, dexamethp789-asonone, and amiodarone with a maintenance dose of 550 mg/24 h.

On the fifth day, evaluation of continuous monitoring ECG showed a sinus rhythm with slower heart rate 135–144×/min (Fig. 5). Unfortunately, the vital signs and neurological status got worse. Saturation of patient was 85–90% with Jackson Rees 15 lpm. We found hematin on the patient indicative of a GI tract bleeding suspected to be caused by administration of corticosteroids and the SARS-CoV-2 status. Laboratory evaluation revealed an elevated leukocyte of  $19,78 \times 10^3$  cells/ $\mu$ L, without blood coagulation abnormalities.

On the sixth day, the vital signs of the patient was unstable with a

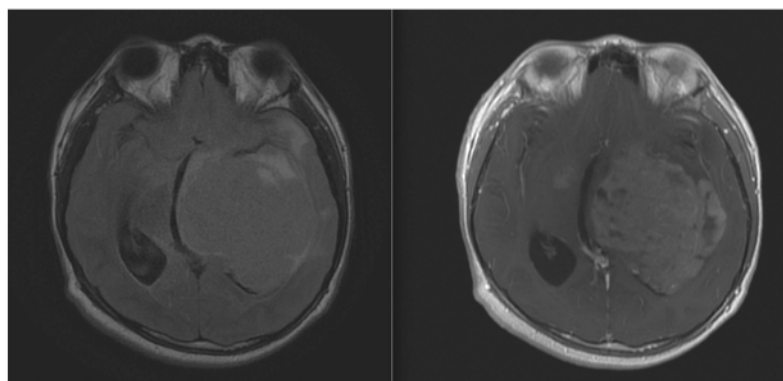


Fig. 1. First MRI on September 2020, axial MRI with T2 (left) and T1 + contrast (right) sequence.

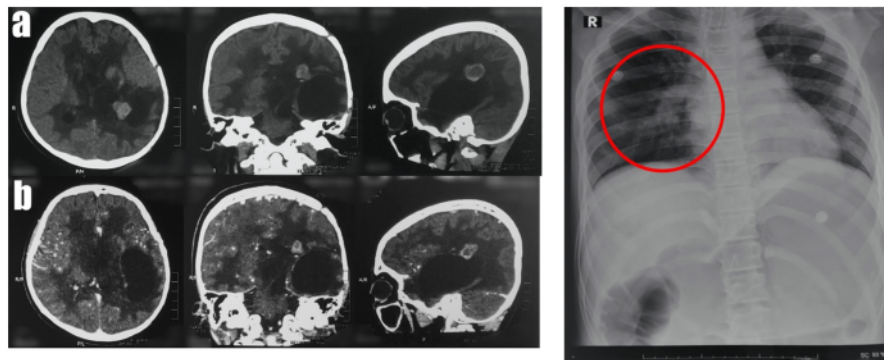


Fig. 2. Imaging evaluation of CT scan; non contrast (a), with contrast (b); and chest x-ray (c).




Fig. 3. Tachycardia monitoring ECG with ventricular tachycardia on 3rd day of admission.

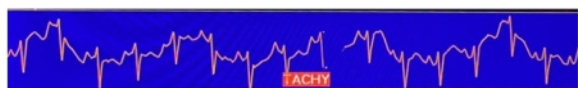

Fig. 4. Tachycardia monitoring ECG with ventricular tachycardia on 4th day of admission after DC shock and administration of amiodarone.

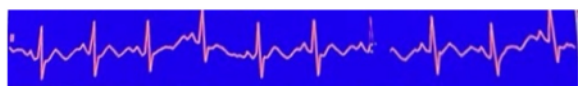


Fig. 5. Tachycardia monitoring ECG with conversion of ventricular tachycardia to sinus Rhythm on 5th day of admission.

blood pressure of 70/40 mm Hg (supported by dopamine 10 µg), heart rate and respiration rate was slowing down 80×/min and 16×/min, while saturation remained at 50%. Monitoring of ECG showed a sinus rhythm. Hematin was still produced. The condition did not improve for some time, and after a several hours of observation, the patient died (Fig. 6). The intracranial lesion could not therefore be confirmed nor operated further. The final suspicion was based on the final histopathology examination, conclusive of germinoma.

### 3. Discussion

Central nervous system (CNS) tumors contribute to about 1–3% of all cases of malignancies. These types of tumors are heterogeneous in nature as they differentiate widely genetically and biologically leading to the various presentations and clinical outcomes [5]. Several factors,



Fig. 6. Asystole on 6th day of admission after progressive deterioration of condition.

namely age, performance status, histology, surgery and history of post-operative adjuvant therapy contribute to the course of disease. In neuro-oncology, radiotherapy plays an important role in the management of brain tumors [6]. It is important for neurosurgeons to understand not only on how to administer it in general, but also about what and when to give it to patients with various diseases, including COVID-19. It is only logical that there needs to be a concise and comprehensive agreement regarding its use on neurosurgery patients with COVID-19.

Cancer patients with COVID-19 have been reported to have relatively higher mortality rate when compared to the non-infected patients [7]. Wu et al. documented that the case fatality rate for cancer patients in was higher compared to non-cancer patients at a number of 5.6% and 2.1%, respectively [7]. Liang [8] from China showed that patients with cancer were observed to have a higher risk of severe events, indicated by the percentage of patients being admitted to the intensive care unit with the need for invasive ventilation or death compared to those without cancer. Moreover, these cancer patients tend to progressively worsen in the clinical course more rapidly than those with no diagnosis of cancer [8]. Not only does the infection affects the oncologic condition itself, the other way around also applies. Several studies from China and Italy have indicated that patients with malignancies have a higher risk of being infected along with higher case-fatality rate [9,10].

Data regarding pediatric patients in China indicated the role of malignancy in contributing to the increased risk of developing more severe disease compared to those who do not have them [11]. The French Society of Pediatric Oncology (2020) reported of more severe clinical course of disease in five out of 33 patients who were positive for COVID-19 infection [12]. In addition, Stokes documented two cases of severe COVID-19 disease in children with cancer, suggesting of the possibility that the profound inflammatory markers common in cancer patients might have an influence in this phenomenon [13]. Although the correlation was still deemed inconclusive, data on adult patients suggested that clinical improvement with tocilizumab, a humanized monoclonal antibody against the interleukin-6 (IL-6) receptor, was observed in COVID-19 infections [14]. In regards to pediatrics, the American Society of Hematology (ASH) registry (2020) suggested that more severe outcomes may be found in pediatric patients with a mortality rate of 5.3% [15]. There were also reports from two particular registries, the Pediatric Oncology COVID Case Report (POCC Report) and the St. Jude Children's Research Hospital global registry, reporting of higher mortality rates and admission to the intensive care unit (ICU) in COVID-19 positive pediatric patients [16,17].

Even so, it appears that in several other studies, in contrast to adult patients, pediatric COVID-19 patients may not exhibit more severe clinical course of disease. Studies from New York City by Boulad et al. and Gampel reported lower rates of infection, morbidity, and no mortality in pediatric oncology patients [18,19]. Wu and McGoogan one of the early studies regarding COVID-19 also reported that asymptomatic

infections are not uncommon [20].

Studies have indicated the occurrence of severe life-threatening neurological involvement in pediatric patients with COVID-19. Although rare, patients may develop a condition called multisystem inflammatory syndrome in children (MIS-C), which is a state of hyper-inflammatory and severe illness temporally associated with COVID-19 infection [21,22]. Children and adolescents hospitalized with MIS-C may develop central and/or peripheral nervous system involvement [22,23]. The frequency itself is still unclear, but the range of severity and various clinical course may be somewhat of a challenge for neurosurgeons and other physicians of various specialties to deal with. As in our case, no observations have been evident in indicating the influence of COVID-19 on the neurological state of the patient, but we believe that it may be reasonable to not yet exclude the possibility of it of exacerbating the CNS malignancy our patient suffered from [23].

Radiotherapy (RT) plays an important role in the management of oncologic patients, including those of neurosurgical malignancies [24]. The scope of RT may vary from its elective use to emergency ones, which may vary from neurologic injury from cord compression, brain metastases, airway compromise, and bleeding [25–27]. Radiotherapy with palliative intent is suited for patients with limited functional status and is effective for providing care and limiting morbidity due to the disease progression [24]. COVID-19 pandemic has led to the importance in our developing more meticulous patient selection, as this situation may affect patients from an individual level, especially in neuro-oncologic cases, and to a more administrative and public health issues. This should also prompt healthcare facilities to create guidelines on whether it is crucial to delay treatments and set priorities for cases that are clinically urgent or not [28].

The Royal College of Radiologists (RCR) defined several aspects of prioritization amidst the COVID-19 pandemic for neuro-oncology patients [29]. They stressed the importance of knowing the context of delineation normal, non-pandemic suggestions and COVID-19 based advice, and physicians will need to be clear on the difference between them. Patients and their family members should always be consulted with proper documentation and performed by consultants. The RCR noted that the highest priority of care should be addressed towards those diagnosed with large benign tumors with acute symptoms (pressure, loss of sight) and posterior fossa tumors (malignant or non-malignant) causing life-threatening hydrocephalus. The next, which they noted as high-intermediate priority, include medulloblastoma and grade 3 glioma in younger patients. The other two, intermediate and low, are reserved for high-grade glioma in young fit patients, and those with small benign tumors, high grade glioma in elderly, and low-grade glioma of any age, respectively. They also stressed that age plays a significant factor in treatment response and prognosis, which should also influence a physician's choice in which patients should get which appropriate modalities. For patients whom are already on treatment, the continuation of any RT and chemotherapy, with the changing risk, should be documented and discussed comprehensively with other specialties and the patients [29].

The influence of age and COVID-19 highlighted through multiple relevant studies may help understand the state of the patient in our case and how to further manage cases such as this. Although one could not accurately point out which factor accounts for the most deleterious effect on the patient's condition, it is proven that COVID-19 and brain tumors in pediatric cases do not mix well. The hyperinflammatory state of COVID-19 infection and tumoral environment may be believed to have exacerbated the patient's general condition indicated by the increased D-dimer and possibly due to a cytokine storm. The patient's condition deteriorated at the third day of admission, and ultimately died after experiencing an atrial fibrillation, ventricular tachycardia, and multiple attempts of DC-shocks. This case may help elucidate the importance of patient selection in the case of RT in pediatric neuro-oncology cases, and what to monitor to further decide the appropriate management for similar cases. Although no clear distinction whether the

condition of the patient was due to the tumor, COVID-19, or both, the current evidence suggests links between them. Moreover, age also plays a factor in the exacerbation of the clinical condition of these patients.

#### 4. Conclusion

Children with intracranial brain tumor infected by SARS-CoV-2 may fall into a worse condition with poor prognosis, exacerbated by severe acute respiratory distress and the need for breathing support in intensive care unit. The pandemic situation may lead us to make tough decision in taking care of multiple pediatric patients. Multiple organ complications, especially those of cardiovascular, shorten the rate and time of survival. These should be a major concern, aside from the breathing problems caused by SARS-CoV-2 infection. Multidisciplinary tumor boards have to convene regularly, including through call-conferences and telemedicine platforms.

#### Consent

Written informed consent was obtained from the patient for publication of this case report and accompanying images. A copy of the written consent is available for review by the Editor-in-Chief of this journal on request.

#### Provenance and peer review

Not commissioned, externally peer-reviewed.

#### Ethical approval

Ethical approval to report this case was obtained from The Hospital Research Ethics Committee of "Rumah Sakit Umum Daerah Dr. Soetomo" where the patient was admitted.

#### Funding

The authors received no financial support for the research, authorship and/or publication of this article

#### Guarantor

Muhammad Arifin Parenrengi, M.D., PhD.

#### Research registration number

None.

#### CRedit authorship contribution statement

**Muhammad Arifin Parenrengi, M.D., PhD:** Conceptualization, Investigation, Resources, Writing – Original draft, Supervision, Project administration

**Wihasto Suryaningtyas, M.D:** Conceptualization, Writing – Original draft, Writing – Review and editing

**Mustaqim Apriyansa Rahmadhan, M.D.:** Investigation, Resources, Writing – Original draft.

#### Declaration of competing interest

The authors declared no potential conflicts of interest with respect to the research, authorship and/or publication of this article.

## References

- [1] R. Dewi, et al., Mortality in children with positive SARS-CoV-2 polymerase chain reaction test: lessons learned from a tertiary referral hospital in Indonesia, *Int. J. Infect. Dis.* 107 (2021) 78–85.
- [2] W. Suryaningtyas, et al., Neurosurgery at the epicenter of the COVID-19 pandemic in Indonesia: experience from a Surabaya academic tertiary hospital, *Neurosurg. Focus.* 49 (2020) E5.
- [3] D. Graetz, et al., Global effect of the COVID-19 pandemic on paediatric cancer care: a cross-sectional study, *Lancet Child Adolesc. Heal.* 5 (2021) 332–340.
- [4] R.A. Agha, et al., The SCARE 2020 guideline: updating consensus surgical CARE REport (SCARE) guidelines, *Int. J. Surg.* 84 (2020) 226–230.
- [5] Q.T. Ostrom, et al., CBTRUS statistical report: primary brain and other central nervous system tumors diagnosed in the United States in 2013–2017, *Neuro. Oncol.* 22 (2020) iv1–iv96.
- [6] R. Balakrishnan, P. Sebastian, B.R. Rajkrishna, J.P. Venkatasai, S. Backianathan, Radiotherapeutic management of brain tumours during the COVID-19 pandemic, *J. Radiother. Pract.* 20 (2021) 238–241.
- [7] X. Wu, R.C. Nethery, M.B. Sabath, D. Braun, F. Dominici, Air pollution and COVID-19 mortality in the United States: Strengths and limitations of an ecological regression analysis, *Sci. Adv.* 6 (2020), eabd4049.
- [8] W. Liang, et al., Cancer patients in SARS-CoV-2 infection: a nationwide analysis in China, *Lancet Oncol.* 21 (2020) 335–337.
- [9] Y. Xia, R. Jin, J. Zhao, W. Li, H. Shen, Risk of COVID-19 for patients with cancer, *Lancet Oncol.* 21 (2020), e180.
- [10] G. Onder, G. Rezza, S. Brusaferro, Case-fatality rate and characteristics of patients dying in relation to COVID-19 in Italy, *JAMA* (2020), <https://doi.org/10.1001/jama.2020.4683>.
- [11] X. Lu, et al., SARS-CoV-2 infection in children, *N. Engl. J. Med.* 382 (2020) 1663–1665.
- [12] N. André, et al., COVID-19 in pediatric oncology from french pediatric oncology and hematology centers: high risk of severe forms? *Pediatr. Blood Cancer* 67 (2020).
- [13] C.L. Stokes, et al., Severe COVID-19 disease in two pediatric oncology patients, *Pediatr. Blood Cancer* 67 (2020).
- [14] P. Luo, et al., Tocilizumab treatment in COVID-19: a single center experience, *J. Med. Virol.* 92 (2020) 814–818.
- [15] American Society of Hematology, COVID-19 Registry in Hematology, ASH Research Collaborative, 2020. <https://www.ashresearchcollaborative.org/s/covid-19-registry-data-summaries>.
- [16] UAB, The Pediatric COVID-19 Cancer Case Report, 2020. <https://www.uab.edu/medicine/icos/icos-research/the-pccc-report>.
- [17] St. Jude Global, Global Registry of COVID-19 in Pediatric Cancer, 2020. <https://globalstjude.org/en-us/global-covid-19-observatory-and-resource-center-for-childhood-cancer/registry.html>.
- [18] B. Gampel, et al., COVID-19 disease in New York City pediatric hematology and oncology patients, *Pediatr. Blood Cancer* 67 (2020).
- [19] F. Boulad, M. Kamboj, N. Bouvier, A. Mauguen, A.L. Kung, COVID-19 in children with cancer in New York City, *JAMA Oncol.* 6 (2020) 1459.
- [20] Z. Wu, J.M. McGoogan, Characteristics of and important lessons from the coronavirus disease 2019 (COVID-19) outbreak in China, *JAMA* 323 (2020) 1239.
- [21] L.R. Feldstein, et al., Multisystem inflammatory syndrome in U.S. children and adolescents, *N. Engl. J. Med.* 383 (2020) 334–346.
- [22] E.M. Dufort, et al., Multisystem inflammatory syndrome in children in New York state, *N. Engl. J. Med.* 383 (2020) 347–358.
- [23] K.L. Larovere, et al., Neurologic involvement in children and adolescents hospitalized in the United States for COVID-19 or multisystem inflammatory syndrome, *JAMA Neurol.* 78 (2021) 536–547.
- [24] D. Yerramilli, et al., Palliative radiation therapy for oncologic emergencies in the setting of COVID-19: approaches to balancing risks and benefits, *Adv. Radiat. Oncol.* 5 (2020) 589–594.
- [25] D. Rades, et al., Evaluation of five radiation schedules and prognostic factors for metastatic spinal cord compression, *J. Clin. Oncol.* 23 (2005) 3366–3375.
- [26] D. Rades, A. Panzner, V. Rudat, J.H. Karstens, S.E. Schild, Dose escalation of radiotherapy for metastatic spinal cord compression (MSCC) in patients with relatively favorable survival prognosis, *Strahlentherapie und Onkol.* 187 (2011) 729–735.
- [27] D. Rades, et al., Radiotherapy with 4 gy × 5 versus 3 gy × 10 for metastatic epidural spinal cord compression: final results of the SCORE-2 trial (ARO 2009/01), *J. Clin. Oncol.* 34 (2016) 597–602.
- [28] V. Achard, P. Tsoutsou, T. Zilli, Radiotherapy in the time of the coronavirus pandemic: when less is better, *Int. J. Radiat. Oncol.* 107 (2020) 600–601.
- [29] RCR, Neuro-oncology Treatment Guidance During COVID-19 Pandemic, The Royal College of Radiologists, 2020.

# A case report of pediatric germinoma with SARS-CoV-2 Lessons learned form an academic tertiary referral hospital in Asian COVID Episentrum

## ORIGINALITY REPORT

19%

SIMILARITY INDEX

16%

INTERNET SOURCES

16%

PUBLICATIONS

0%

STUDENT PAPERS

## PRIMARY SOURCES

|   |  |    |
|---|--|----|
| 1 | <a href="https://repository.unair.ac.id">repository.unair.ac.id</a><br>Internet Source   | 1% |
| 2 | Wihasto Suryaningtyas, I.G.M. Aswin R. Ranuh, Muhammad Arifin Parenrengi. "Shunt exposure as a ventriculoperitoneal shunt complication: A case series", International Journal of Surgery Case Reports, 2021<br>Publication               | 1% |
| 3 | Zahra Siavashpour, Neda Goharpey, Mosayyeb Mobasheri. "Radiotherapy based management during Covid-19 pandemic – A systematic review of presented consensus and guidelines", Critical Reviews in Oncology/Hematology, 2021<br>Publication | 1% |
| 4 | <a href="http://www.karger.com">www.karger.com</a><br>Internet Source  | 1% |
| 5 | <a href="http://jamanetwork.com">jamanetwork.com</a><br>Internet Source  | 1% |

|    |   |      |
|----|---|------|
| 6  | <a href="http://coek.info">coek.info</a><br>Internet Source   | 1 %  |
| 7  | <a href="http://dontforgetthebubbles.com">dontforgetthebubbles.com</a><br>Internet Source   | 1 %  |
| 8  | <a href="http://rega.kuleuven.be">rega.kuleuven.be</a><br>Internet Source   | 1 %  |
| 9  | <a href="http://ir.tdc.ac.jp">ir.tdc.ac.jp</a><br>Internet Source   | 1 %  |
| 10 | <a href="http://thejns.org">thejns.org</a><br>Internet Source   | 1 %  |
| 11 | <a href="http://www.pipsqc.org">www.pipsqc.org</a><br>Internet Source   | 1 %  |
| 12 | <a href="http://ousar.lib.okayama-u.ac.jp">ousar.lib.okayama-u.ac.jp</a><br>Internet Source   | 1 %  |
| 13 | <a href="http://platcovid.com">platcovid.com</a><br>Internet Source   | 1 %  |
| 14 | <a href="http://ripetomato2uk.files.wordpress.com">ripetomato2uk.files.wordpress.com</a><br>Internet Source   | 1 %  |
| 15 | Ahmed Arafat, Dinara Sadykova, Ayrat Ziatdinov, Svetlana Senek, Natalya Samoiloova, Tamara Makarova. "COVID-19, Acute Lymphoblastic Leukemia, and Down Syndrome: A Short Review and a Case Report", Case Reports in Oncology, 2021<br>Publication | <1 % |



|    |  |      |
|----|--|------|
| 16 | <a href="https://files.covid19treatmentguidelines.nih.gov">files.covid19treatmentguidelines.nih.gov</a><br>Internet Source   | <1 % |
| 17 | <a href="https://bmcpregnancychildbirth.biomedcentral.com">bmcpregnancychildbirth.biomedcentral.com</a><br>Internet Source   | <1 % |
| 18 | <a href="https://www.pubfacts.com">www.pubfacts.com</a><br>Internet Source   | <1 % |
| 19 | <a href="https://jcimcr.org">jcimcr.org</a><br>Internet Source   | <1 % |
| 20 | <a href="https://pericles.pericles-prod.literatumonline.com">pericles.pericles-prod.literatumonline.com</a><br>Internet Source   | <1 % |
| 21 | <a href="https://www.frontiersin.org">www.frontiersin.org</a><br>Internet Source   | <1 % |
| 22 | <a href="https://e-cep.org">e-cep.org</a><br>Internet Source   | <1 % |
| 23 | <a href="https://rsds.org">rsds.org</a><br>Internet Source   | <1 % |
| 24 | Daniel C. Moreira, Gerard C. Millen, Stephen Sands, Pamela R. Kearns, Douglas S. Hawkins. "The Care of Children With Cancer During the COVID-19 Pandemic", American Society of Clinical Oncology Educational Book, 2021<br>Publication | <1 % |
| 25 | <a href="https://www.hilarispublisher.com">www.hilarispublisher.com</a><br>Internet Source   | <1 % |

|    |  |      |
|----|--|------|
| 26 | <a href="http://www.tumorzentrum.uk-erlangen.de">www.tumorzentrum.uk-erlangen.de</a><br>Internet Source  | <1 % |
| 27 | John A. Clark, Nazima Pathan. "Hide and seek in a pandemic: Review of SARS - CoV - 2 infection and sequelae in children", <i>Experimental Physiology</i> , 2021<br>Publication   | <1 % |
| 28 | <a href="http://gupea.ub.gu.se">gupea.ub.gu.se</a><br>Internet Source  | <1 % |
| 29 | <a href="http://link.springer.com">link.springer.com</a><br>Internet Source  | <1 % |
| 30 | <a href="http://www.mdpi.com">www.mdpi.com</a><br>Internet Source  | <1 % |
| 31 | Slava Agafonoff, Anna Sobolewski, Timothy S. Braverman. "Adenoid cystic carcinoma of the breast - Discordant size on imaging and pathology: A case report and review of literature", <i>Annals of Medicine and Surgery</i> , 2019<br>Publication | <1 % |
| 32 | <a href="http://crstonline.com">crstonline.com</a><br>Internet Source  | <1 % |
| 33 | <a href="http://onlinelibrary.wiley.com">onlinelibrary.wiley.com</a><br>Internet Source  | <1 % |
| 34 | <a href="http://openaccess.maltepe.edu.tr">openaccess.maltepe.edu.tr</a><br>Internet Source  | <1 % |

35

repositoriosalud.es

Internet Source

&lt;1 %

36

Aravind Ganesh, Isabella R. Reis, Malavika Varma, David G. Patry, Lara J. Cooke.

"Neurological and HEENT Manifestations of COVID-19: A Systematic Review and Meta-Analysis", Canadian Journal of Neurological Sciences / Journal Canadien des Sciences Neurologiques, 2021

Publication

&lt;1 %

37

Muhammad Arifin Parenrengi, Wihasto Suryaningtyas, Joandre Fauza. "Endovascular embolization for cases of 'hidden' pediatric cerebral arteriovenous malformations: A diagnostic & therapeutic challenge", International Journal of Surgery Case Reports, 2021

Publication

&lt;1 %

38

Nipunie Rajapakse, Devika Dixit. "Human and novel coronavirus infections in children: a review", Paediatrics and International Child Health, 2020

Publication

&lt;1 %

39

Wihasto Suryaningtyas, Joni Wahyuhadi, Agus Turchan, Eko Agus Subagio et al.

"Neurosurgery at the epicenter of the COVID-19 pandemic in Indonesia: experience from a

&lt;1 %

Surabaya academic tertiary hospital",  
Neurosurgical Focus, 2020

Publication

---

40

Nurnaningsih, Gladys Indika Danudibroto,  
Desy Rusmawatiningtyas, Intan Fatah  
Kumara, Firdian Makrufardi, Titis Widowati.  
"Acute appendicitis in pediatric patients with  
Coronavirus Disease 2019 (COVID-19): A case  
series from a developing country's tertiary  
hospital", Annals of Medicine and Surgery,  
2022

Publication

---

<1 %

---

Exclude quotes      On

Exclude matches      Off

Exclude bibliography      On

# A case report of pediatric germinoma with SARS-CoV-2 Lessons learned form an academic tertiary referral hospital in Asian COVID Episentrum

---

GRADEMARK REPORT

---

FINAL GRADE

**/100**

GENERAL COMMENTS

**Instructor**

---

PAGE 1

---

PAGE 2

---

PAGE 3

---

PAGE 4

---

PAGE 5

---