

The aggressive progression of primary atypical teratoidrhabdoid tumor after surgical resection A case report

by Muhammad Arifin Parenrengi

Submission date: 24-Jun-2022 10:29AM (UTC+0800)

Submission ID: 1862083563

File name: eratoidrhabdoid_tumor_after_surgical_resection_A_case_report.pdf (5.15M)

Word count: 3340

Character count: 18488



ELSEVIER

Contents lists available at ScienceDirect

International Journal of Surgery Case Reports

journal homepage: www.elsevier.com/locate/ijscr

Case report

The aggressive progression of primary intracranial atypical teratoid/rhabdoid tumor after surgical resection: A case report

Muhammad Arifin Parenrengi^{a,*}, Galih Indra Permana^a, Wihasto Suryaningtyas^a,
Dyah Fauziah^b^a Department of Neurosurgery, Universitas Airlangga – Dr. Soetomo General Academic Hospital, Surabaya, East Java, Indonesia^b Department of Anatomical Pathology, Universitas Airlangga – Dr. Soetomo General Academic Hospital, Surabaya, East Java, Indonesia

ARTICLE INFO

Keywords:

Atypical teratoid/rhabdoid tumor (AT/RT)
Malignancy
Recurrence
Aggressive growth
Child health

ABSTRACT

Introduction and importance: Atypical teratoid/rhabdoid tumor (AT/RT) is a rare and highly aggressive malignancy in children. Management of this aggressive tumor is associated with various diagnostic and therapeutic challenges. Maximum safe resection, followed by radiation therapy and multiagent chemotherapy, is the best course of treatment. This study aims to demonstrate the aggressive progression of the clinical presentation and radiographic features for an AT/RT after surgical resection.

Case presentation: We reported a case of a 7-years-old girl with recurrent tumor mass in the left parieto-occipital region after performing craniotomy surgical resection. The tumor mass aggressively grew within a month after surgery.

Conclusion: AT/RT is a rare and highly progressive malignancy in the children population. This tumor aggressively grows after the first surgery. The INI-1 gene has been found as a diagnostic tumor marker in AT/RT. The characteristic of AT/RT is an absence of INI-1 staining in tumor cells. The treatment in AT/RT serves as palliative treatment, aiming to improve patient's quality of life. The poor prognosis is associated with MR imaging evidence of disseminated leptomeningeal tumor.

1. Introduction and importance

Primary atypical teratoid/rhabdoid tumors (AT/RT) are a rare malignant intracranial neoplasm that affects children. AT/RT contains nests or sheets of rhabdoid tumor cells, various proportions of primitive neuroectodermal tumor (PNET) cells, mesenchymal spindle-shaped tumor cells, and/or epithelial-type tumor cells. AT/RT accounts for 1%–2% of all pediatric CNS tumors and 10%–20% of CNS tumors in children under three [1,2]. AT/RT can occur in both supratentorial and infratentorial regions and is frequently associated with poor survival depending on the location and degree of resection. The tumor is most commonly found in the infratentorial region and is less common in the supratentorial region. With loss of INI-1 staining in neoplastic cells, immunohistochemistry plays a role in confirming the diagnosis. There are no standard therapeutic strategies for these tumors, AT/RT treatment approaches differ between institutions and countries [3]. Furthermore, the preferred treatment modality is determined by the

patient's age and the extent of tumor progression.

The prognosis for patients with AT/RT is generally dismal, especially in the presence of residual tumor or metastasis. AT/RT is a deadly brain neoplasm with a median survival time of 6 to 13 months. This is due to the aggressive nature of the disease and the lower tolerance of young patients to treatment. This is exacerbated by a reluctance to use radiotherapy in young patients due to the risk of functional impairment of the developing brain [4,5]. We presented a 7-year-old girl with the recurrent tumor mass and the progression of the clinical presentation and radiographic features for an AT/RT. It is critical for clinicians to recognize the diverse presentation and progression of the AT/RT. This report aims to discuss the rarity of this tumor and the treatment strategy to improve the patient's quality of life.

2. Case presentation

A 7-years-old girl came with recurrent tumor mass in the left parieto-

* Corresponding author at: Department of Neurosurgery, Airlangga University – Dr. Soetomo General Academic Hospital, Mayjen Prof. Dr. Moestopo Street No. 6-8, 60286 Surabaya, East Java, Indonesia.

E-mail address: muhammad.arifin@fk.unair.ac.id (M.A. Parenrengi).

<https://doi.org/10.1016/j.ijscr.2022.106790>

Received 26 November 2021; Received in revised form 16 January 2022; Accepted 20 January 2022

Available online 24 January 2022

2210-2612/© 2022 The Authors. Published by Elsevier Ltd on behalf of IJS Publishing Group Ltd. This is an open access article under the CC BY-NC-ND license

<http://creativecommons.org/licenses/by-nc-nd/4.0/>.

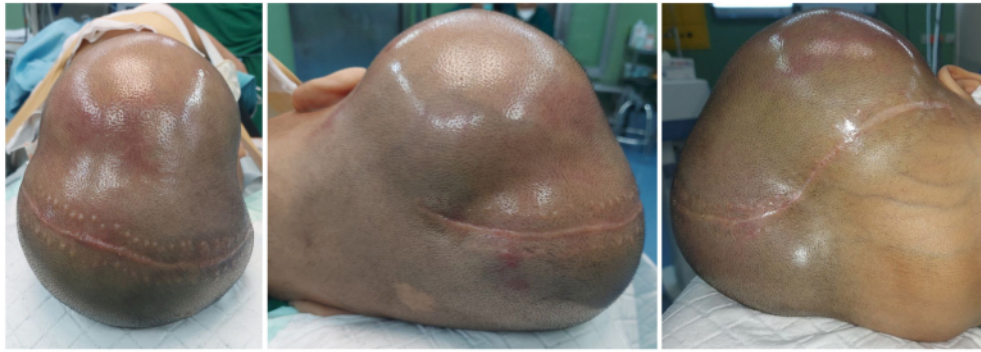

Fig. 1. Clinical presentation a month after the first surgery. The tumor mass aggressively grew, exceeding the calvaria. The tumor mass is located in the temporo-parieto-occipital region with the measurement 20 × 12 × 10 cm. The tumor had soft to solid consistency and cyst.

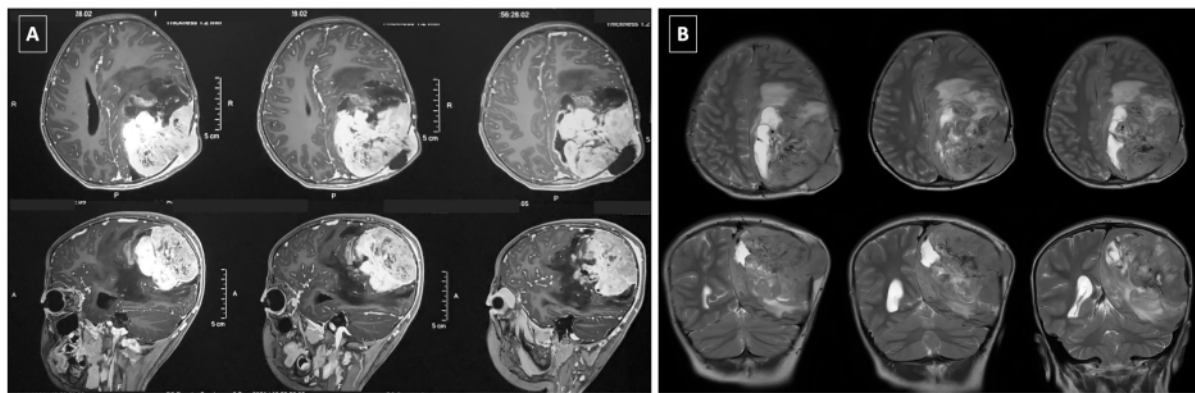


Fig. 2. MR imaging at the presentation before performing the first surgical procedure. T1-weighted imaging with gadolinium (A) shows heterogeneous contrast enhancement in the left parieto-occipital tumor region. T2-weighted imaging (B) shows hyperintense in general (hemorrhagic areas can be hypointense).

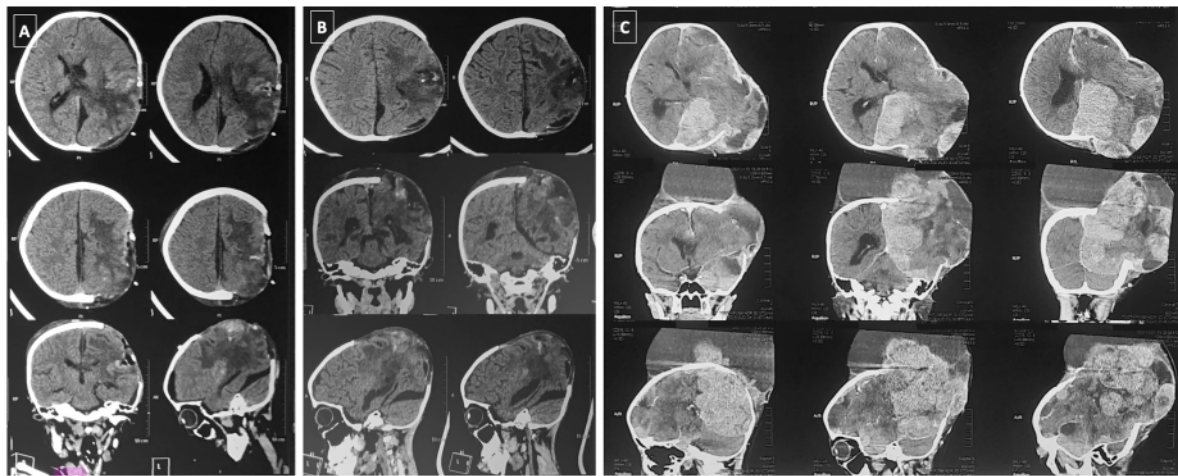


Fig. 3. CT Scan imaging progression of the tumor mass after the first surgical procedure. CT Scan imaging early post-operative (A) shows a hemorrhage in the surgical bed without any residual mass. CT Scan imaging 5-days later (B) shows growth of the tumor mass with perifocal edema. CT Scan imaging a month after the first surgery (C) shows aggressive growth of the tumor mass exceeding the calvaria with multi-density in the imaging.

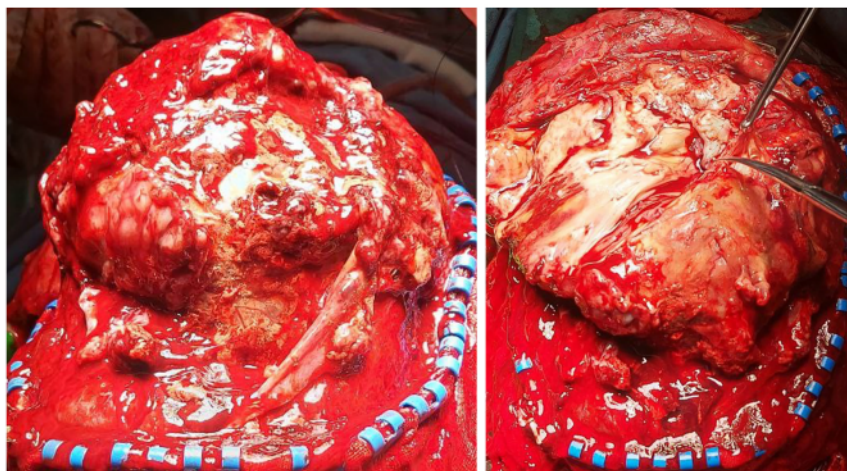


Fig. 4. The tumor mass changed consistency from soft to solid during surgery, exhibiting hypervascularity throughout the tumor site. Cyst development was present in some of the tumors.

occipital region. The tumor mass exceeded the calvaria. The patient had a history of craniotomy surgical resection 1 month before and consumed corticosteroid for the tumor. There is no family history of the tumor mass on the other site. The surgical site was decompressed because the tumor was infiltrating the calvaria. The patient complained about persistent headache, worsening vomiting, and progressive weakness of the right extremities over a period of 1 month after surgery, to the point of inability to ambulate. Physical examination demonstrated tumor mass in the temporo-parieto-occipital region, exceeding the calvaria with the measurement $20 \times 12 \times 10$ cm (Fig. 1). The tumor mass has soft-solid consistency in majority and cystic in the other region. Her neurological examination revealed decreased rapid alternating movements of the right upper and lower extremities at the time of presentation.

Magnetic resonance imaging (MRI) of the brain shows a large heterogeneous contrast-enhancing mass on T1-weighted with gadolinium. MRI T2-weighted imaging revealed heterogenous enhancing mass in the supratentorial, left parieto-occipital region, with peritumoral edema. MRI demonstrated necrosis, multiple foci of the cyst, and hemorrhage (Fig. 2). CT Scan was performed after craniotomy tumor resection. CT Scan showed that near-total resection of the tumor and a little hemorrhage at the surgical bed. The edema was shown around the surgical bed area. Five days later, the patient complained about bulging in the decompression area. CT Scan evaluation showed rapid growth of the tumor mass exceeding the bone. Patient waited for chemotherapy and radiotherapy. Within this period, the tumor mass grew rapidly and destroyed the bone. A month later, the tumor mass grew aggressively and became bigger than before. CT Scan evaluation was performed and showed multi-density in the parieto-occipital region, same as the surgical location, indicating tumor mass with the cyst, necrosis, and calcification (Fig. 3).

Patient performed second surgery of tumor resection in a month after the first surgery. All of the surgical procedures were performed by the author, as the pediatric neurosurgeon, and the neurosurgical team. The aim of this surgery is gross total resection and decompresses of the tumor mass. During surgery, half of the tumor was resected; the tumor had soft to a hard consistency, cyst formation, necrosis area, and hypervascularization (Fig. 4). Surgery was discontinued because of the tumor hypervascularization and massive bleeding from the tumor. We planned to radiotherapy and chemotherapy after this second surgery. Because the patient's general state was deteriorating, she could not continue radiotherapy and chemotherapy. Unfortunately, she died a month after surgery.

Microscopic examination revealed a round blue cell tumor with high cellularity composed of atypical cells with eccentric nuclei, small nucleoli, and abundant eosinophilic cytoplasm with frequent mitotic figures. Immunohistochemistry studies revealed a loss of INI-1 staining in neoplastic cells, positive Vimentin in the tumor cell cytoplasm, negative GFAP in the tumor cell membrane, focal positive Myogenin tumor cell nucleus, confirming the diagnosis of AT/RT (Fig. 5). This case report is presented based on the Surgical Case Report (SCARE) Guidelines [6].

3. Clinical discussion

AT/RT remains a significant problem in pediatric neuro-oncology. AT/RT is a rare and aggressive CNS tumor with unknown histology. The diagnosis is difficult due to the possibility of significant microscopic overlap with other embryonal tumors. AT/RT patients have yet to find an effective treatment. Children frequently progress within months to a year of diagnosis due to the aggressive nature of the disease and the high rate of leptomeningeal dissemination [7,8]. Our patient had progressive symptoms for a month, with progressive growth, necrosis area, cyst formation, and intratumoral hemorrhage, which is typical for this highly malignant CNS tumor. Her age at presentation was unusual, given that this tumor type is more common in children under three.

There are no imaging characteristics that distinguish intracranial AT/RT. They are typically intraaxially positioned but can also be supra- or infratentorial in nature and show reduced diffusion on MRI [9,10]. In some cases, supratentorial AT/RT can have a cystic appearance with a heterogeneously enhancing wall. Although not unique to AT/RT and not statistically significant, AT/RT has a higher proclivity to be large and frequently has some calcification, hemorrhage, or necrosis on imaging [11]. In our patient, the tumor did exhibit some of these nonspecific AT/RT characteristics. Our patient had a supratentorial tumor, with malignancy imaging characteristics. Our serial imaging showed that the tumor progressively grew within a month after the surgical procedure.

AT/RT can histologically and radiographically mimic supratentorial PNET. One of the first studies, which looked at a group of infants with CNS AT/RT, discovered a link to a chromosomal abnormality on chromosome 22 [12,13]. AT/RT is distinguished by the loss of chromosome 22's long arm, which results in the loss of the hSNF5/INI-1 gene. This has become the AT/RT's defining molecular signature. Because of its pathologic and genetic characteristics, AT/RT is recognized as a separate clinical entity [14]. AT/RT has sheets of rhabdoid cells on a backdrop of

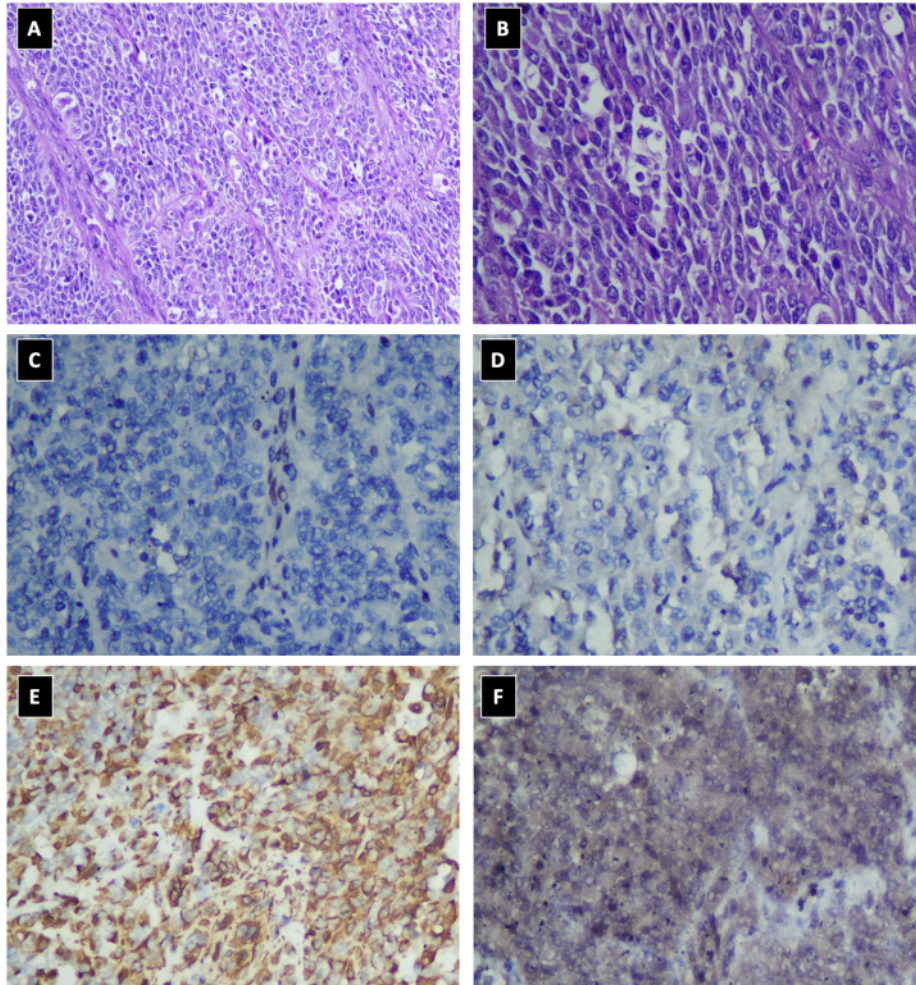


Fig. 5. Pathological anatomy of the AT/RT with Hematoxylin and Eosin stain $\times 200$ (A) and $\times 400$ (B) in our patient showing cell boundaries is well defined. The cytoplasm is rich with eosinophilic inclusions, and the nuclei are eccentrically placed and contain vesicular chromatin. Immunohistochemistry studies revealed a loss of INI-1 staining (C), negative GFAP (D), positive Vimentin (E), and positive Myogenin (F).

neuroectodermal cells, mesenchymal cells, or epithelial cells histologically. Immunohistochemical characteristics aid in disease identification; however, they differ depending on the tumor's cellular composition. Vimentin, epithelial membrane antigen (EMA), and smooth muscle actin are expressed by rhabdoid cells (SMA). Neurofilament protein (NFP), glial fibrillary acidic protein (GFAP), keratin, and desmin are all expressed differently in primitive neuroectodermal cells. AT/RT tumors are fast-growing tumors with MIB-1 labeling indices of 50–100% [15,16]. The absence of INI-1 immunohistochemical staining distinguishes AT/RT from PNET due to molecular advances in our understanding of AT/RT. Although the exact function of the INI-1 gene is unknown, a mutation is likely to change the transcriptional control of downstream targets. The presence of an INI-1 mutation in a tumor with histologic characteristics suggestive of a primitive neuroectodermal tumor, but no apparent rhabdoid component is thought to be sufficient to diagnose AT/RT. [17,18] Although ATRTs are uncommon tumors, particularly in the elderly pediatric population, it is critical to recognize the various presentation and radiographic features that may mimic those of low-grade glial neoplasms. Our cases showed pathological anatomy characteristic of AT/RT with an absence of INI-1 staining in

neoplastic cells, positive Vimentin in the tumor cell cytoplasm, negative GFAP in the tumor cell membrane, and focal positive Myogenin tumor cell nucleus. The study's limitation is that establishing a diagnosis takes time due to pathological anatomy immunohistochemistry for AT/RT antibodies.

In the treatment of AT/RT, no particular guidelines have been established. However, a multimodal therapy involving gross surgical excision and targeted RT, whether or not in conjunction with concurrent combined modality treatment, improved the overall prognosis of these lesions. Because of the tumor's huge size, surrounding infiltration of brain regions, and young age upon diagnosis, total excision is generally challenging. When comparing subtotal/near-total resection to gross entire resection, combined modality treatment substantially improved overall survival. After the first surgery, the patient was scheduled for radiotherapy and chemotherapy. Over time, the tumor became increasingly aggressive. We discussed the second surgery with the family as a palliative care treatment to improve the patient's quality of life. She died a month after the second surgery before receiving radiotherapy and chemotherapy.

4. Conclusion

AT/RT is a rare and highly progressive malignancy in the children population. This tumor aggressively grew after the first surgery. The INI-1 gene has been found as a diagnostic tumor marker in AT/RT. The characteristic of AT/RT is an absence of INI-1 staining in tumor cells. The treatment in our AT/RT case serves as palliative treatment, aiming to improve the patient's quality of life. The poor prognosis is associated with MR imaging evidence of disseminated leptomeningeal tumor.

Source of funding

None.

Ethical approval

All ethical principles were considered in conducting this case report. All patient information kept confidential.

Consent

Written informed consent was obtained from the patient for publication of this case report and accompanying images. A copy of the written consent is available for review by the Editor-in-Chief of this journal on request.

Author contribution

Muhammad Arifin Parenrengi - data collection, manuscript writing, critically revising article, reviewed final version of article.

Galih Indra Permana - study concept, patient contribution, revising article, reviewed final version of article, study oversight, creation of figures.

Wihasto Suryaningtyas - data collection, critically revising article, reviewed final version of article.

Dyah Fauziah - study concept, patient contribution, revising article, reviewed final version of article, creation of figures, creation of histology microscopic figure.

Research registration

Not applicable.

Guarantor

Dr. Muhammad Arifin Parenrengi.

Provenance and peer review

Not commissioned, externally peer-reviewed.

Submission statement

This manuscript is original and has not been submitted elsewhere in part or in whole.

Declaration of competing interest

The authors declare that they have no conflict of interest.

References

- [1] M. Stevens, C. Frobisher, M. Hawkins, M. Jenney, E. Lancashire, R. Reulen, A. Taylor, D. Winter, The British Childhood Cancer Survivor Study: objectives, methods, population structure, response rates and initial descriptive information, *Pediatr. BloodCancer* 50 (2008) 1018–1025, <https://doi.org/10.1002/pbc>.
- [2] M. Fossey, H. Li, S. Afzal, A.-S. Carret, D.D. Eisenstat, A. Fleming, J. Hukin, C. Hawkins, N. Jabado, D. Johnston, T. Brown, V. Larouche, K. Scheinemann, D. Strother, B. Wilson, S. Zelcer, A. Huang, E. Boufflet, L. Lafay-Cousin, Atypical teratoid rhabdoid tumor in the first year of life: the Canadian ATRT registry experience and review of the literature, *J. Neuro-Oncol.* 132 (2017) 155–162, <https://doi.org/10.1007/s11060-016-2353-0>.
- [3] K. Ginn, A. Gajjar, Atypical teratoid rhabdoid tumor: current therapy and future directions, *Front. Oncol.* 2 (2012) 114, <https://doi.org/10.3389/fonc.2012.00114>.
- [4] A. Biswas, L. Kashyap, A. Kalkar, C. Sarkar, P.K. Julka, Atypical teratoid/rhabdoid tumors: challenges and search for solutions, *Cancer Manag. Res.* 8 (2016) 115–125, <https://doi.org/10.2147/CMAR.S83472>.
- [5] J. Lee, D.S. Kim, J.W. Han, C.O. Suh, Atypical teratoid/rhabdoid tumors in children treated with multimodal therapies: the necessity of upfront radiotherapy after surgery, *Pediatr. Blood Cancer* 64 (2017), <https://doi.org/10.1002/pbc.26663>.
- [6] R. Agha, T. Franchi, C. Sohrabi, G. Mathew, the S. Group, The SCARE 2020 guideline: updating consensus Surgical Case Report (SCARE) guidelines, *Int. J. Surg.* 84 (2020) 226–230.
- [7] T.M. Tekautz, C.E. Fuller, S. Blaney, M. Fouladi, A. Broniscer, T.E. Merchant, M. Krasin, J. Dalton, G. Hale, L.E. Kun, D. Wallace, R.J. Gilbertson, A. Gajjar, Atypical teratoid/rhabdoid tumors (ATRT): improved survival in children 3 years of age and older with radiation therapy and high-dose alkylator-based chemotherapy, *J. Clin. Oncol.* 23 (2005) 1491–1499, <https://doi.org/10.1200/JCO.2005.05.187>.
- [8] M. Park, J.W. Han, S.M. Hahn, J.A. Lee, J.Y. Kim, S.H. Shin, D.S. Kim, H.I. Yoon, K. T. Hong, J.Y. Choi, H.J. Kang, H.Y. Shin, J.H. Phi, S.K. Kim, J.W. Lee, K.H. Yoo, K. W. Sung, H.H. Koo, D.H. Lim, H.J. Shin, H. Kim, K.N. Koh, H.J. Im, S. Do Ahn, Y. S. Ra, H.J. Baek, H. Kook, T.Y. Jung, H.S. Choi, C.Y. Kim, H.J. Park, C.J. Lyu, Atypical teratoid/rhabdoid tumor of the central nervous system in children under the age of 3 years, *cancer resTreat.* 53 (2021) 378–388, <https://doi.org/10.4143/CRT.2020.756>.
- [9] K. Koral, L. Gargan, D.C. Bowers, B. Gimi, C.F. Timmons, B. Weprin, N.K. Rollins, Imaging characteristics of atypical teratoid-rhabdoid tumor in children compared with medulloblastoma, *Am. J. Roentgenol.* 190 (2008) 809–814, <https://doi.org/10.2214/AJR.07.3069>.
- [10] S.P. Meyers, Z.P. Khademian, J.A. Biegel, S.H. Chuang, D.N. Korones, R. A. Zimmerman, Primary intracranial atypical teratoid/rhabdoid tumors of infancy and childhood: MRI features and patient outcomes, *Am. J. Neuroradiol.* 27 (2006) 962–971.
- [11] K.J. Au Yong, J.L. Jaremko, L. Jans, R. Bhargava, L.T. Coleman, V. Mehta, M. R. Ditchfield, How specific is the MRI appearance of supratentorial atypical teratoid rhabdoid tumors? *Pediatr. Radiol.* 43 (2013) 347–354, <https://doi.org/10.1007/s00247-012-2530-z>.
- [12] Y.T. Udaka, K. Shayan, N.A. Chuang, J.R. Crawford, Atypical presentation of atypical teratoid rhabdoid tumor in a child, *Case Rep. Oncol. Med.* 2013 (2013) 1–4, <https://doi.org/10.1155/2013/815923>.
- [13] A.T. Reddy, Atypical teratoid/rhabdoid tumors of the central nervous system, *J. Neuro-Oncol.* 75 (2005) 309–313, <https://doi.org/10.1007/s11060-005-6762-8>.
- [14] J. Lutterbach, J. Liegibel, D. Koch, A. Madlinger, H. Frommhold, A. Pagenstecher, Atypical teratoid/rhabdoid tumors in adult patients: case report and review of the literature, *J. Neuro-Oncol.* 52 (2001) 49–56, <https://doi.org/10.1023/A:1010683416555>.
- [15] U.H. Athale, J. Duckworth, I. Odame, R. Barr, Childhood atypical teratoid rhabdoid tumor of the central nervous system: a meta-analysis of observational studies, *J. Pediatr. Hematol. Oncol.* 31 (2009) 651–663, <https://doi.org/10.1097/MPH.0b013e3181b258a9>.
- [16] A. Singh, X. Lun, A. Jayanthan, H. Obaid, Y. Ruan, D. Strother, S.N. Chi, A. Smith, P. Forsyth, A. Narendran, Profiling pathway-specific novel therapeutics in preclinical assessment for central nervous system atypical teratoid rhabdoid tumors (CNS ATRT): favorable activity of targeting EGFR- ErbB2 signaling with lapatinib, *Mol. Oncol.* 7 (2013) 497–512, <https://doi.org/10.1016/j.molonc.2013.01.001>.
- [17] E.A. Richardson, B. Ho, A. Huang, Atypical teratoid rhabdoid tumour: from tumours to therapies, *J. Korean Neurosurg. Soc.* 61 (2018) 302–311, <https://doi.org/10.3340/jkns.2018.0061>.
- [18] Y.-W. Chen, T.-T. Wong, D.M.-T. Ho, P.-I. Huang, K.-P. Chang, C.-Y. Shiau, S.-H. Yen, Impact of radiotherapy for pediatric CNS atypical teratoid/rhabdoid tumor (single institute experience), *Int. J. Radiat. Oncol. Biol. Phys.* 64 (2006) 1038–1043, <https://doi.org/10.1016/j.ijrobp.2005.10.001>.

The aggressive progression of primary atypical teratoid/rhabdoid tumor after surgical resection A case report

ORIGINALITY REPORT

19%

SIMILARITY INDEX

11%

INTERNET SOURCES

19%

PUBLICATIONS

0%

STUDENT PAPERS

PRIMARY SOURCES

- 1 Alyssa T. Reddy, Emily S. Waite. "Chemotherapy for CNS Atypical Teratoid/Rhabdoid Tumor", Elsevier BV, 2018
Publication 1%
- 2 Sholeh Ebrahimpour, Mehdi Mohammadi, Kheirollah Gholami. "Drug Reaction with Eosinophilia and Systemic Symptoms (DRESS) with Teicoplanin: A Case Report", Drug Safety - Case Reports, 2016
Publication 1%
- 3 Alyssa T. Reddy. "Atypical Teratoid/Rhabdoid Tumors of the Central Nervous System", Journal of Neuro-Oncology, 2005
Publication 1%
- 4 "Multiple drugs", Reactions Weekly, 2022
Publication 1%
- 5 Garret P. Greeneway, Paul S. Page, Viharkumar Patel, Azam S. Ahmed. "Atypical Teratoid/Rhabdoid Tumor of the Cerebellum

in an Adult: Case Report and Literature Review", World Neurosurgery, 2021

Publication

6	R Shrestha, S Gauchan, A K Jha. "Atypical teratoid/rhabdoid tumor: A rare case report", Journal of Chitwan Medical College, 2017 Publication	1 %
7	Kerstin Bartelheim, Karolina Nemes, Angela Seeringer, Kornelius Kerl et al. "Improved 6-year overall survival in AT/RT - results of the registry study Rhabdoid 2007", Cancer Medicine, 2016 Publication	1 %
8	Posterior Fossa Tumors in Children, 2015. Publication	1 %
9	aspho.org Internet Source	1 %
10	Galih Indra Permana, M. Arifin Parenrengi, Wihasto Suryaningtyas, Dyah Fauziah, Muhammad Azzam. "The recurrent plexiform neurofibroma of the scalp in neurofibromatosis type 1: illustrative case", Journal of Neurosurgery: Case Lessons, 2021 Publication	1 %
11	Gengyin Guo, Jianfeng Zhuang, Keke Zhang, Zhizhen Zhou, Yanjun Wang, Zhen Zhang. "Atypical Teratoid/Rhabdoid Tumor of the	1 %

Central Nervous System in Children: Case Reports and Literature Review", Frontiers in Surgery, 2022

Publication

12 geb.uni-giessen.de 1 %
Internet Source

13 www.thieme-connect.com 1 %
Internet Source

14 repositori.upf.edu 1 %
Internet Source

15 Dyah Fauziah, Sutrisno Sutrisno, Gondo Mastutik. "Correlation of CD133 and SOX2 Expression with Regional Lymph Nodes Metastatic Status in Invasive Breast Carcinoma of No Special Type", Indonesian Journal of Cancer, 2021 1 %
Publication

16 Mohannad F. Tobaigy, Layan K. Al Tawil, Hind M. Alkatan, Yasser H. Al-Faky. "An incidental finding of intraocular choristoma in an enucleated microphthalmic globe: A histopathologic case report", International Journal of Surgery Case Reports, 2021 1 %
Publication

17 Shobhan Vachhrajani. "Medulloblastoma", Oncology of CNS Tumors, 2010 1 %
Publication

18	doi.org Internet Source	<1 %
19	Wang, Xingfu, Xueyong Liu, Zhixiong Lin, Yupeng Chen, Pengcheng Wang, and Sheng Zhang. "Atypical Teratoid/Rhabdoid Tumor (AT/RT) Arising From the Acoustic Nerve in a Young Adult : A Case Report and a Review of Literature", <i>Medicine</i> , 2015. Publication	<1 %
20	www.ajtmh.org Internet Source	<1 %
21	www.ncbi.nlm.nih.gov Internet Source	<1 %
22	www.turkjpath.org Internet Source	<1 %
23	cancer.dartmouth.edu Internet Source	<1 %
24	journal.frontiersin.org Internet Source	<1 %
25	Adomas Bunevicius, Algimantas Matukevicius, Vytenis Deltuva, Inga Gudinaviciene, Darius Pranys, Arimantas Tamasauskas. "Atypical Teratoid/Rhabdoid Tumor After In Vitro Fertilization: Illustrative Case Report and Systematic Literature Review", <i>World Neurosurgery</i> , 2018	<1 %

26

Daisuke Muroya, Toshihiro Sato, Hisamune Sakai, Toru Hisaka, Yoshito Akagi, Koji Okuda. "Spontaneous regression of lung metastases in hepatocellular carcinoma: a case report", International Journal of Surgery Case Reports, 2020

Publication

<1 %

27

hwmain.jco.ascopubs.org

Internet Source

<1 %

28

Andri Maruli Tua Lubis, Muhammad Rizqi Adhi Primaputra, Ismail H. Dilogo. "A case report of ten-month-neglected anterior shoulder dislocation managed by open reduction combined with Latarjet procedure", International Journal of Surgery Case Reports, 2019

Publication

<1 %

29

Hiroshi Kodama, Masayuki Maeda, Hiroshi Imai, Toshio Matsubara, Waro Taki, Kan Takeda. "MRI of primary spinal atypical teratoid/rhabdoid tumor: a case report and literature review", Journal of Neuro-Oncology, 2007

Publication

<1 %

30

Lee, I.H.. "Atypical teratoid/rhabdoid tumors of the central nervous system: imaging and

<1 %

clinical findings in 16 children", Clinical Radiology, 200903

Publication

31

onlinelibrary.wiley.com

Internet Source

<1 %

32

thejns.org

Internet Source

<1 %

33

www.ajnr.org

Internet Source

<1 %

34

Keating, Robert F., James Tait Goodrich, and Roger J. Packer. "Atypical Teratoid/Rhabdoid Tumors", Tumors of the Pediatric Central Nervous System, 2013.

Publication

<1 %

35

discovery.researcher.life

Internet Source

<1 %

Exclude quotes On

Exclude matches Off

Exclude bibliography On

The aggressive progression of primary atypical teratoidrhabdoid tumor after surgical resection A case report

GRADEMARK REPORT

FINAL GRADE

/100

GENERAL COMMENTS

Instructor

PAGE 1

PAGE 2

PAGE 3

PAGE 4

PAGE 5
