

# Cranioplasty split calvaria in pediatric patient

*by* Ditto Darlan

---

**Submission date:** 22-Sep-2022 05:46PM (UTC+0800)

**Submission ID:** 1906104035

**File name:** Cranioplasty\_split\_calvaria\_in\_pediatric\_patient.pdf (3.74M)

**Word count:** 2144

**Character count:** 11773



ELSEVIER

Contents lists available at ScienceDirect

International Journal of Surgery Open

journal homepage: [www.elsevier.com/locate/ijso](http://www.elsevier.com/locate/ijso)



## Case Report

# Cranioplasty split calvaria in pediatric patient

Ditto Darlan, Wihasto Suryaningtyas, Muhammad Arifin Parenrengi\*

Department of Neurosurgery, Faculty of Medicine Universitas Airlangga – Dr. Soetomo General Academic Hospital, Surabaya, Indonesia

### ARTICLE INFO

**Keywords:**  
Cranioplasty  
Split calvaria  
Autologous  
Case report

### ABSTRACT

**Background:** Cranioplasty in pediatrics often results in a poor outcome. Therefore, proper consideration and decision-making are needed in choosing surgical techniques for cranioplasty in children, especially autologous, which can cause abnormal skull and brain growth.

**Case description:** A 3-year-old girl presented to our outpatient clinic with a complaint of a left fronto-temporo-parietal skull defect due to a history of acute subdural hemorrhage evacuation and decompressive craniectomy. After a series of failed cranioplasties, the patient then underwent a split calvarial cranioplasty. Post-operatively, the patient was fully conscious and had no neurological deficit.

**Discussion:** Commonly used autologous material with bone graft is those of split rib and split calvarial. Large defect area does not allow the use of split rib. Therefore, split calvaria is the main choice in this case, due to its capability of giving larger defect area obtained, more suitable contour for the defect area, single incision, and more rigidity for cosmetic purpose.

**Conclusion:** Autologous cranioplasty with split calvaria can be used in certain cases of infection or trauma that often causes bone tissue damage, so that autograft bone flap cannot be reused. In pediatric cases, the split calvaria technique is appropriate for children patient that has a problem of skull defect.

## 1. Introduction

Cranioplasty is a commonly performed procedure in neurosurgery [1]. This procedure aims to reconstruct calvarial bony defect. Aside from its protection of cerebral structures and cosmetic reconstruction, cranioplasty also plays a therapeutic role in metabolic changes and cerebral blood flow [2–4]. It is indicated in calvarial defects due to traumatic brain injury, decompressive craniectomy, brain tumor, infection, or congenital pathologies.

In pediatric patients, the goal of cranioplasty is aesthetic reconstruction and prevent complications such as post-trephined syndrome. Surgical options vary depending on the age of the patient [4]. The anatomy and physiology of the dural layer and calvaria expand significantly between the ages of newborns and eight years of age [4]. Dura mater possesses osteogenic properties that can naturally lead to the healing of cranial defects at the age of 0–24 months. Autologous cranioplasty is one of the most common methods of cranioplasty in children. Split calvarial and rib are the methods most often used. Split calvarial is chosen in large defects. Children less than four years old do not yet have diploic space development, thus making the split calvarial cranioplasty method often resulting in a poor outcome [1,4,5]. This

means that proper consideration and decision making are needed in choosing surgical techniques for cranioplasty in children, especially autologous, which can cause abnormal skull and brain growth.

## 2. Case presentation

This case report is already in line with the SCARE 2020 criteria [6]. A 3-year-old girl presented to our outpatient clinic with a complaint of a left fronto-temporo-parietal skull defect (Fig. 1). The patient's family have provided an informed consent for the publication of this case. The patient had no significant clinical history aside from a craniotomy for an acute subdural hemorrhage evacuation and bone decompression previously. Bone is deposited subgaleally at the contralateral side to the lesion. One year later, an acrylic cranioplasty was performed due to bone flap shrinkage. Despite routine & compliant outpatient visits by the patient, the patient returned a month later with an epidural abscess, wound dehiscence, and exposed acrylic. Surgical measures were then performed, including debridement, acrylic flap removal, and abscess evacuation. At this time, the patient is well conscious, and there is no neurological deficit. The skull defect area is not bulging, and the wound bed is not dehiscence.

\* Corresponding author.

E-mail address: [muhammad.arifin@fk.unair.ac.id](mailto:muhammad.arifin@fk.unair.ac.id) (M.A. Parenrengi).

<https://doi.org/10.1016/j.ijso.2022.100511>

Received 13 May 2022; Received in revised form 6 July 2022; Accepted 7 July 2022

Available online 12 July 2022

2405-8572/© 2022 The Authors. Published by Elsevier Ltd on behalf of Surgical Associates Ltd. This is an open access article under the CC BY-NC-ND license (<http://creativecommons.org/licenses/by-nc-nd/4.0/>).

Split calvarial cranioplasty was then decided for the patient. A printed model of the left fronto-tempo-parietal defect skull size was made based on the contour of the patients' skull and drawn on paper, then put into sterile plastic wrap (Fig. 2). The incision was performed on the right side of the donor area in the form of a question mark according to the size of the bone defect on the left. A layer-by-layer incision was performed, and the periosteum was preserved as much as possible. The presence of dural loss and dehiscence were repaired, or grafted when necessary. The outer surface of the skull was exposed through a subgaleal dissection. The outlines of the cranial defect were then traced manually onto a sheet of transparent plastic and transferred onto the surface of the skull, chosen as the harvested area.

The donor area measurements were made according to the size of the mold that had been drawn. One burr hole was performed and then connected using a craniotome. A dural hitch-stitch was performed and sources of bleeding were carefully controlled.

The inner and outer table of the donor bone flap of the right side of the skull was cut split using an oscillating saw (Fig. 3). The diploe was cut until it was split transversely in half. The harvested part of the skull was split and the outer table was applied to cover the defect. This then left part of the diploe and inner table to cover the newly made defect at the donor site. The result is aesthetically pleasing in nature, owing to the natural-like contour. Larger, split-thickness grafts may be chosen to replace numerous smaller fragmented fractures. This helps facilitate the fixation process and provides much thicker scaffolding, which is expected to be better at maintain the contouring of soft tissue structures during remodelling process. The outer table was then inserted into the defect and formed through cutting by burr. The inner table was then returned to the donor site and fixated with absorbable sutures. Any possibilities of intracerebral or subarachnoid hemorrhage, dural defects or laceration, and cerebrospinal fluid leakage should always be considered and paid attention to. Subsequently, bilateral subgaleal drains were placed for up to 2 days after the surgery. Postoperatively, the patient was fully conscious and had no neurological deficit. Upon the sixth month after the surgery, the patient presented with no complications and neurological deficit with good skull contour (Fig. 4). There were no signs of excessive bone resorption with cosmetically pleasing scar tissue.

### 3. Discussion

Allograft cranioplasty, using acrylic material, has been frequently

reported to lead to post-operative infections [4,7]. Acrylic is a foreign object that leads to a cascade of immune responses that may be capable of activating inflammatory reactions [4,8]. Abscess formation is the most common manifestation encountered due to the use of acrylic in cranioplasty, so it is important to also consider other methods and materials of autologous cranioplasty, still from the patient's own body [1]. A commonly used autologous material with bone graft is those of split rib and calvarial [1,9].

Large defect areas do not allow the use of the autologous cranioplasty method with split rib [4]. In addition, with extensive defects, donor removal requires multiple incisions in several rib segments. This increases the risk of complications, namely those of pulmonary, such as atelectasis in this procedure. The neurosurgeons decided that split calvarial technique is the main choice in this case, due to its capability of giving larger defect area to be obtained, more suitable contour for the defect area, single area incision, and more rigidity so that it is cosmetically pleasing [1,9,10]. In addition, the importance of preserving the dura mater below and the periosteum above the grafted bone is very important, as it helps the process of osteogenesis and ossification.

### 4. Conclusion

Autologous cranioplasty with split calvaria can be used in certain cases of infection or trauma that often causes bone tissue damage, so that autograft bone flap cannot be reused. Split calvaria has a low complication rate, lower cost, and is more rigid, easing the fixation process so that osteogenesis is expected to be more effective. In pediatric cases, split calvaria technique is appropriate for children patient that has a problem of skull defect.

### Ethical approval

Ethical approval to report this case was obtained from The Hospital Research Ethics Committee of "Rumah Sakit Umum Daerah Dr. Soetomo" where the patient was admitted.

### Sources of funding for your research

The authors received no financial support for the research, authorship and/or publication of this article.

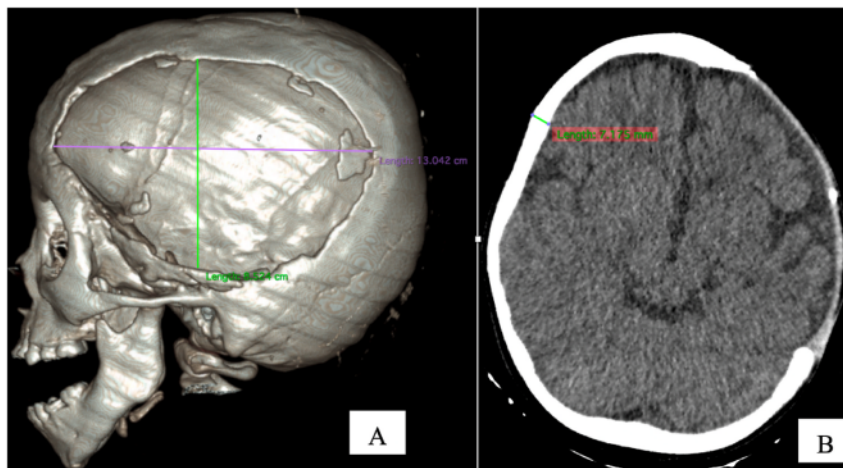
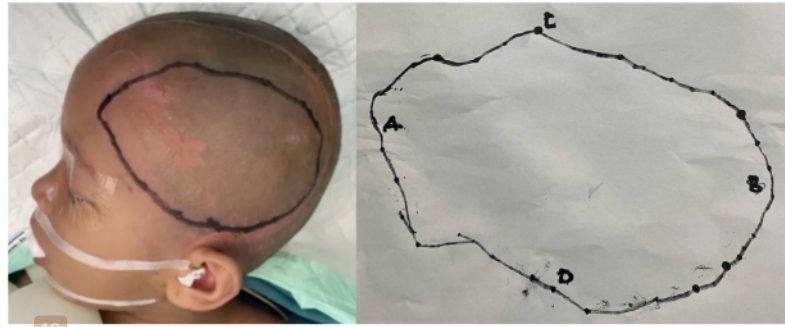

Fig. 1. Pre-operative computed tomography. (A) A skull defect on the left front-tempo-parietal with a size of 13 cm × 8.5 cm. (B) The thickness of diploe was 7.1cm.



19  
Fig. 2. The marked skull defect on the left side of the patient's head (left) and the guide for bone harvest on the normal calvaria, with points for reference; A: frontal, B: occipital, C: parietal, and D: temporobasal (right).

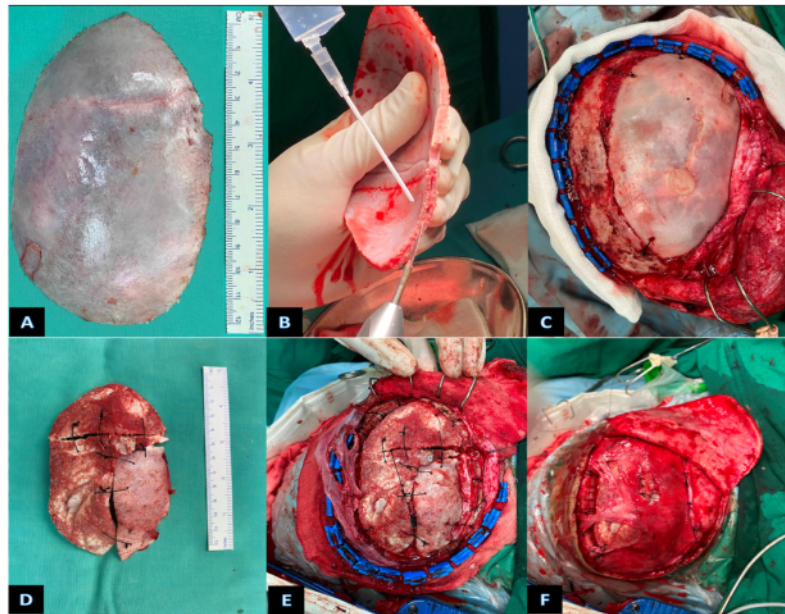


Fig. 3. (A) Harvested bone graft (B) Inner and outer table separation using an oscillating saw. (C) End-result of the split calvarial cranioplasty recipient site (D) inner membrane reconstruction and sutures fixation. (E) Donor site. (F) Preservation periosteum at donor site that has more intact periosteum.

**Author contribution**

**Ditto Darlan, M.D.:** Investigation, Resources, Writing – Original Draft.

**16 Wihasto Suryaningtyas, M.D, PhD:** Conceptualization, Writing – Original Draft, Writing – Review and Editing.

**Muhammad Arifin Parenrengi, M.D., PhD:** Conceptualization, Investigation, Resources, Writing – Original Draft, Supervision, Project Administration.

**Registration of research studies**

(No registration number required as this was a retrospective case report based on medical record, requiring & involving no human subjects).

**Guarantor**

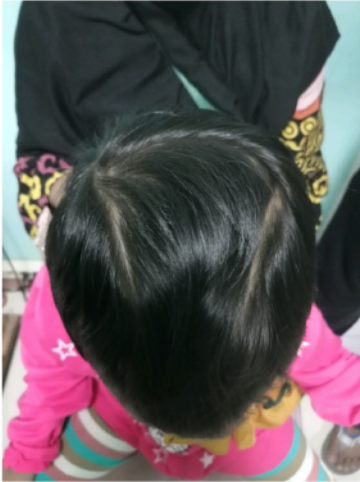Muhammad Arifin Parenrengi, M.D., PhD.

**1 Consent**

Written informed consent was obtained from the patient for publication of this case report and accompanying images. A copy of the written consent is available for review by the Editor-in-Chief of this journal on request.

**Disclosure of ethics**

**10**  
Written informed consent was obtained from the patient for publication of this case report and accompanying images. Medical data had been de-identified before publication to ensure patient confidentiality.



**Fig. 4.** Patient's head 6 months following the cranioplasty showing good skull contour without complications.

#### Disclosure of interest

The authors declare that they have no known competing financial interests or personal relationships that could have appeared to influence the work reported in this paper.

#### Funding

This study did not receive any funding or grant.

11

#### Provenance and peer review

Not commissioned, externally peer-reviewed.

#### Declaration of competing interest

The authors declared no potential conflicts of interest with respect to the research, authorship and/or publication of this article.

#### Appendix A. Supplementary data

Supplementary data to this article can be found online at <https://doi.org/10.1016/j.ijso.2022.100511>.

#### References

- [1] Agrawal A, Garg L. Split calvarial bone graft for the reconstruction of skull defects. *J Surg Tech Case Rep* 2011;3(1):13.
- [2] Lee KB, Ang ES, Tan KC. Reconstructive challenges in the management of a rare case of sphenoid osteosarcoma—a case report. *Singap Med J* 2001 Dec;42(12):586–9.
- [3] Turpin IM. Bone autografting of the calvaria and craniofacial skeleton. *Plast Reconstr Surg* 2004 Sep;114(4):70e–1e.
- [4] Bykowski MR, Goldstein JA, Losee JE. Pediatric cranioplasty. *Clin Plast Surg* 2019 Apr;46(2):173–83.
- [5] Prodel JL. Calvarial bone graft harvest in children. *Otolaryngol Neck Surg* 1999 Jul 17;121(1):78–81.
- [6] Agha RA, Franchi T, Sohrabi C, Mathew G, Kerwan A, Thoma A, et al. The SCARE 2020 guideline: updating consensus surgical CAse REport (SCARE) guidelines [Internet]. *Int J Surg* 2020;84:226–30. Available from: <https://www.sciencedirect.com/science/article/pii/S1743919120307718>.
- [7] Smolka W, Eggensperger N, Kollar A, Iizuka T. Midfacial reconstruction using calvarial split bone grafts. *Arch Otolaryngol Neck Surg* 2005 Feb 1;131(2):131.
- [8] Blum KS, Schneider SJ, Rosenthal AD. Methyl methacrylate cranioplasty in children: long-term results. *Pediatr Neurosurg* 1997;26(1):33–5.
- [9] Jung YT, Cho JI, Lee SP. Cranioplasty using a modified split calvarial graft technique in cleidocranial dysplasia. *J Korean Neurosurg Soc* 2015;58(1):79–82.
- [10] Josan VA, Sgouros S, Walsh AR, Dover MS, Nishikawa H, Hockley AD. Cranioplasty in children. *Child's Nerv Syst* 2005;21(3):200–4.

# Cranioplasty split calvaria in pediatric patient

## ORIGINALITY REPORT

19%

SIMILARITY INDEX

17%

INTERNET SOURCES

14%

PUBLICATIONS

0%

STUDENT PAPERS

## PRIMARY SOURCES

1	<a href="http://openaccess.maltepe.edu.tr">openaccess.maltepe.edu.tr</a> Internet Source	2%
2	<a href="http://journalpulmonology.org">journalpulmonology.org</a> Internet Source	2%
3	<a href="http://researchmgt.monash.edu">researchmgt.monash.edu</a> Internet Source	2%
4	<a href="http://fmed.stafpu.bu.edu.eg">fmed.stafpu.bu.edu.eg</a> Internet Source	2%
5	<a href="http://pure.rug.nl">pure.rug.nl</a> Internet Source	2%
6	<a href="http://e-journal.unair.ac.id">e-journal.unair.ac.id</a> Internet Source	1%
7	Artico, M.. "Bone autografting of the calvaria and craniofacial skeleton", <i>Surgical Neurology</i> , 200307 Publication	1%
8	Anne Bowers, Alexandra Monteverde, Alan Heimann, Edna Kapenhas, Antoinette Notaro. "Case report and literature review:	1%

# Management of squamous cell carcinoma in situ of the nipple", International Journal of Surgery Open, 2017

Publication

---

9	<a href="https://core.ac.uk">core.ac.uk</a> Internet Source	1 %
10	<a href="http://www.jcpsp.pk">www.jcpsp.pk</a> Internet Source	1 %
11	<a href="http://tel.archives-ouvertes.fr">tel.archives-ouvertes.fr</a> Internet Source	1 %
12	<a href="http://journals.lww.com">journals.lww.com</a> Internet Source	1 %
13	<a href="http://ousar.lib.okayama-u.ac.jp">ousar.lib.okayama-u.ac.jp</a> Internet Source	1 %
14	<a href="http://idoc.pub">idoc.pub</a> Internet Source	1 %
15	<a href="http://trepo.tuni.fi">trepo.tuni.fi</a> Internet Source	1 %
16	Luca Ferrario, Anna Maffioli, Andrea A. Bondurri, Claudio Guerci, Francesco Lazzarin, Piergiorgio Danelli. "COVID-19 and surgical training in Italy: Residents and young consultants perspectives from the battlefield", The American Journal of Surgery, 2020 Publication	<1 %

---

[www.karger.com](http://www.karger.com)

17

Internet Source

<1 %

---

18

[www.spandidos-publications.com](http://www.spandidos-publications.com)

Internet Source

<1 %

---

19

Cranial Osteomyelitis, 2016.

Publication

<1 %

---

Exclude quotes      On

Exclude matches      Off

Exclude bibliography      On



# Cranioplasty split calvaria in pediatric patient

---

GRADEMARK REPORT

---

FINAL GRADE

**/100**

GENERAL COMMENTS

**Instructor**

---

PAGE 1

---

PAGE 2

---

PAGE 3

---

PAGE 4

---