

# Cranial vault reduction cranioplasty for severe hydrocephalus

*by* Wihasto Suryaningtyas

---

**Submission date:** 24-Jun-2022 10:20AM (UTC+0800)

**Submission ID:** 1862079831

**File name:** raniel\_vault\_reduction\_cranioplasty\_for\_severe\_hydrocephalus.pdf (628.38K)

**Word count:** 3109

**Character count:** 17609

**Case Report:****CRANIAL VAULT REDUCTION CRANIOPLASTY FOR SEVERE HYDROCEPHALUS****Wihasto Suryaningtyas, Muhammad Arifin Parenrengi**

Department of Neurosurgery, Faculty of Medicine, Universitas Airlangga, Dr. Soetomo General Hospital, Surabaya, Indonesia

**ABSTRACT**

*Extreme hydrocephalic macrocephaly is still encountered in developing countries due to delayed treatment, rapidly progressing hydrocephalus and family socioeconomic problems. Reduction cranioplasty was used with several techniques to address the issue. The study aimed to determine the safety and feasibility of barrel-stave technique for reducing the size of extreme hydrocephalic macrocephaly. Three post-diversion patients underwent surgical reconstruction. Children with head circumference more or equal to two standard deviation above mean on given age, no active wound at the area of surgery, presentation of sufficient "potential removable fluid" that allows dura reduction and no active shunt infection were eligible. The surgical procedure includes modified pi, barrel-stave technique, and diversion of the cerebrospinal fluid and subdural collection. Clinical data were recorded. Three patients with age range of 2 month to 2 years old underwent the surgery. Two patients had shunt implanted at least 1 month before the surgery and 1 patient had an ETV procedure 3 months before the reduction. The frontal-occipital circumference before surgery ranged from 50 to 63 cm. The maximum reduction that could be achieved was 15 cm. One patient (2 months old) died within 24 hour due to failure to cope with excessive blood loss. Two patients were followed up for 3 months and 6 months without complications. Reduction cranioplasty using barrel-stave techniques is an option for children with extreme large head that poses a mechanical or cosmetic problem. Risk and pitfalls should be considered and taken care meticulously, especially the age and blood loss.*

**Keywords:** Hydrocephalic macrocephaly; cranial vault; reduction cranioplasty

**ABSTRAK**

*Makrosefali hidrosefalus ekstrem masih ditemui di negara-negara berkembang karena keterlambatan pengobatan, hidrosefalus yang berkembang pesat dan masalah sosial ekonomi keluarga. Reduksi cranioplasty digunakan dengan beberapa teknik untuk mengatasi masalah ini. Penelitian ini bertujuan untuk menentukan keamanan dan kelayakan teknik barrel-stave untuk mengurangi ukuran makrosefali hidrosefalus yang ekstrem. Tiga pasien pasca-pengalihan menjalani rekonstruksi bedah. Anak-anak dengan lingkaran kepala lebih atau sama dengan dua standar deviasi di atas rata-rata pada usia tertentu, tidak ada luka aktif di area operasi, presentasi "potensi cairan yang dapat dilepas" yang cukup yang memungkinkan pengurangan dura dan tidak ada infeksi shunt aktif yang memenuhi syarat. Prosedur bedah termasuk modifikasi pi, teknik laras-stave, dan pengalihan cairan serebrospinal dan pengumpulan subdural. Data klinis dicatat. Tiga pasien dengan rentang usia 2 bulan hingga 2 tahun menjalani operasi. Dua pasien harus ditanamkan setidaknya 1 bulan sebelum operasi dan 1 pasien memiliki prosedur ETV 3 bulan sebelum pengurangan. Lingkaran frontal-okspital sebelum operasi berkisar antara 50 hingga 63 cm. Pengurangan maksimum yang bisa dicapai adalah 15 cm. Satu pasien (2 bulan) meninggal dalam waktu 24 jam karena kegagalan untuk mengatasi kehilangan darah yang berlebihan. Dua pasien ditindaklanjuti selama 3 bulan dan 6 bulan tanpa komplikasi. Pengurangan cranioplasty menggunakan teknik barrel-stave adalah pilihan untuk anak-anak dengan kepala besar yang ekstrim yang memiliki masalah mekanis atau kosmetik. Risiko dan jebakan harus dipertimbangkan dan dirawat dengan cermat, terutama usia dan kehilangan darah.*

**Kata kunci:** Hidrosefalus makrosefali; brankas tengkorak; cranioplasty reduksi

**Correspondence:** Wihasto Suryaningtyas, Department of Neurosurgery, Faculty of Medicine, Universitas Airlangga, Dr. Soetomo General Hospital, Jl. Mayjen Prof Moestopo 6-8, Surabaya, Indonesia. E-mail: wihasto-s@fk.unair.ac.id

## INTRODUCTION

Neglected or partially treated hydrocephalus in infant may cause rapid enlargement of the head (Manwaring et al 2013). Diagnosis of macrocephaly is made when rapid enlargement of the head is greater than two standard deviations above mean of given age (Mathews et al 2007). Massive hydrocephalic macrocephaly (head circumference >60 cm) may be rarely seen in developed countries but is still encountered in low-income or developing countries. Difficult access to facility and socioeconomic issues are the precipitating factors. Despite the advancement of shunt technology, the very abnormal size of the cranial vault cannot be addressed using shunt alone.

Abnormally large and heavy head causes mobility and cosmetic problems that are sufficient enough to interfere with motor development, important activities and nursing care. Reduction cranioplasty should be considered in this group of patients. The indication of reduction cranioplasty is briefly summarized as follows: 1) head circumference >60 cm, and one the following conditions: a) limitation of normal development or activities in relatively good neurologic function; b) reduced quality of life and impediment to nursing care in neurologically impaired patient; c) severe cosmetic problem that interferes with psychosocial development or function (Mathews et al 2007, Winston et al 1995). Several techniques had been described in literatures with its advantages limitations. This report describes barrel-stave surgical techniques for reduction cranioplasty and discusses its feasibility and safety.

## MATERIALS AND METHODS

### Operative technique

After the anesthesiologist safely intubated orally and the endotracheal tube was secured, we put the patient in a standard supine position with small gel padding to get the head slightly flexed. Foley catheter, arterial and intravenous lines were inserted. The line of incision is marked for bi-coronal skin incision. The operating area was prepped with povidone-iodine solution. The incision line was then infiltrated with mixture of 0.5% lidocaine and 1:100.000 epinephrine solution. The skin was incised using a knife and scalp flaps were raised anteriorly and posteriorly. Meticulous effort was carried out to minimize blood loss. Bilateral temporal muscle flaps were separated. To reduce bleeding from the bone, pericranium was not opened until the craniotomy lines were marked using sterile pencil. The pericranium was then stripped only on the marked cutting line. The first cut was to remove the parasagittal bones as far as four

centimeters on each side and left the sagittal bone intact (approximately 2-3 cm wide) almost similar to pi technique (Fig. 1). Wedge-shape cut was made on either side at coronal line, mid-parietal line, and occipital line. The tip of the wedge cut was made as close as possible to the skull base (Fig. 2). The cut was similar the picket fence technique but it was done without removing the sagittal bandeau. The difference with the picket fence technique was the shape had no pointing triangular tip. The previously implanted shunt was removed and secured before application of the wedge-shaped cut.

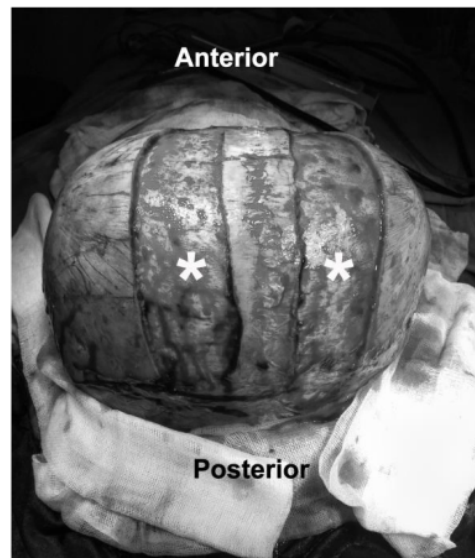


Fig. 1. Operative photograph. A three-centimeter-wide parasagittal craniotomy was done on each side (white asterisk), leaving the sagittal bandeau intact.

The sagittal bandeau was preserved or shortened depending on whether it was necessary to adjust the anterior-posterior distance. On one of our case, the cranial index was more than 1. Therefore, we didn't shorten the sagittal bone. For other cases, the sagittal bandeau was shortened. We placed multiple drill holes through sagittal bone to allow fixation of the remaining bones using wires or absorbable sutures. Multiple drill holes also applied on frontal and parietal bones.

Cerebrospinal fluid was drained from the shunt insertion point as needed to reduce the intracranial volume before fixing the bone. Direct fixation between parietal bones was applied to reinforce the reduction capacity (Fig. 3). To prevent the sagging of the dura and to avoid the death space, no dural plication was performed. Dura along the sagittal bandeau was tacked up to prevent any

kinking of the sagittal sinus. The shunt system was put back to its original insertion and was checked for its patency.

The wound was generously irrigated with sterile solution. The pericranial flaps were suspended with absorbable sutures. The scalp was again generously irrigated before skin closure. The redundant skin was left "as is" to expect self-remodeling or removed if the excess was too much.

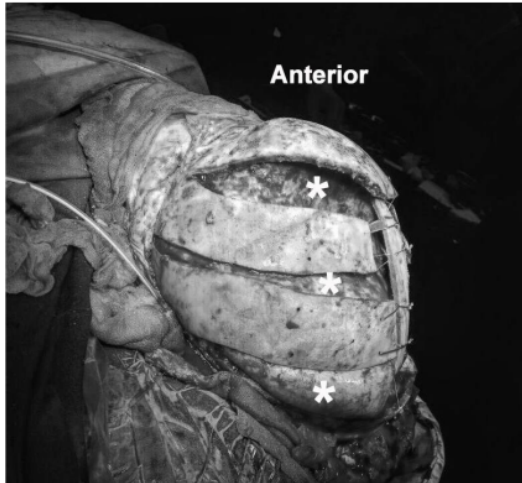


Fig. 2. Operative photograph. A wedge cut craniotomy (white asterisk) was made on frontal-parietal-occipital bone as close as possible to the skull base.

#### Case illustration

##### Case 1

The patient was a two-month-old boy. He was known to have a hydrocephalus during pregnancy. We put the shunt few days after he was born. The head circumference kept climbing despite normal patency of the shunt. It was known later that he developed chronic subdural collection. The head circumference on follow up was 50 cm. There was no history of seizure or shunt infection. The parents concerned about the head circumference and insisted to go for a reduction cranioplasty. The surgery was performed using the barrel stave technique. The blood loss from surgery was 300 mL. During the ICU stay, the subgaleal drain was filled up to 250 mL. The boy experienced cardiac arrest a couple of times, despite volume replacement. He died within 24 hours in ICU.

##### Case 2

The patient was a nine-month-old boy presenting with developmental delay, severe hydrocephalus, and abnormally large head. The cranial index was more than 1 indicated that he has longer lateral distance than the anterior-posterior part. The endoscopic third ventriculostomy was performed 3 months before with resultant of subdural collection. External drainage was placed to remove the subdural collection seven days before he underwent cranial vault reduction. The reduction craniotomy took place after external drainage removal. Modified pi and barrel staving of parietal-temporal-occipital bones were employed. No shunt was implanted after the surgery. Three days after the surgery, the patient was discharged from ICU and sent home on day 9.

##### Case 3

A-seventeen-month-old girl suffered from severe hydrocephalus with very large head. She had undergone ventriculo-peritoneal (VP) shunt placement 3 months before. There was no history of seizure or shunt malfunction. The latest CT scan showed large lateral ventricles, despite normal function of the shunt. Her massive large head prevented her to move and made it difficult for her mother to mobilize her. Preoperatively, the skin was very thin otherwise unremarkable. During the surgery, she underwent modified pi craniotomy, barrel staving of the parietal-temporal and occipital bones. Eight hundreds milliliters of CSF was removed slowly from the ventricle. Before closing the skin, the VP shunt was put back to its original insertion and secured. No complication was found during ICU stay. She was back to the ward on the third day after surgery and discharged on day 8.

#### RESULTS

The patients in our series had some degree of developmental delay. Developmental assessment was not performed in one patient due to age limitation. Two patients underwent VP shunt procedures before the cranial reduction and one patient had ETV done. We kept the shunt in place after reduction surgery except for the patient with ETV that was left with no shunt. The ICU stay was as short as 3 days. One patient died within 24 hours in ICU due to inability to cope with volume loss during surgery.

The skull was thick enough on patients older than nine months with a deformed skull base. The maximum reduction of head circumference was 15 centimeters. The patient characteristics are summarized in Table 1.

**DISCUSSION**

First reduction cranioplasty was performed in a communicating hydrocephalic child by Ehni in 1951 and was reported 30 years after. He carried out the surgery in 13 stages over a period of 22 months using specially designed gap-closing devices made by the patient's father (Ehni 1982). In 1964, Sayers and Duran reported three-stage operation from previously planned four-stage surgery. The parents declined the fourth stage for frontal reduction. A Holter valve shunt was placed at the first stage followed by reduction cranioplasty involving posterior two-thirds of calvaria in the second and third stage. In 1979, Vries and Habal described a five-stage surgery involving the supraorbital repositioning and two-stage reduction cranioplasty (Vries & Habal 1979). Ventureyra and Da Silva commenced the era of single-stage procedure in three-year-old patient in a semi sitting position. After 8 hours of surgery and half a liter of blood, they successfully attempted to reduce the anterior part of the skull (Ventureyra & Da Silva 1980). In 1985, Park and colleagues performed a one-stage procedure using a modified prone position, later known as sphinx position (Park et al 1985, Piatt & Arguelles 1990). This modified position allowed the surgeon to expose the calvaria frominion to nasion. In 1990, Piatt and Arguelles reported reduction cranioplasty in craniocerebral disproportion involving complete removal of the cranial vault and utilizing coronal crossbar. Permanent shunt placement was delayed as the collapsing cortical mantle resulted in blood spillage into cerebrospinal fluid (CSF) (Piatt & Arguelles 1990). Winston and friends reported on reduction cranioplasty in four patients using various techniques including quadrantal plate, picket fence, and crossbar techniques (Winston et al 1995). In 1998, Erdinçler and colleagues described two single-stage procedures of reduction cranioplasty using modified crossbar and modified pi techniques (Erdinçler et al 1998). In 2006, Sundine and colleagues reported four hydrocephalic macrocephalic patients that underwent single-stage total cranial vault reduction cranioplasty (Sundine et al 2006).

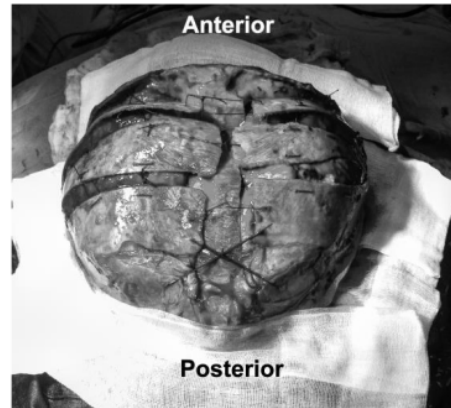


Fig. 3. Operative photograph. Bony fixation using big absorbable sutures. The sagittal bandeau protected the sinus from kinking. The dura was snugly fit against the bones.

Indication for surgery in our series involved quality of life, nursing care and cosmetic consideration as stated by Winston and colleagues (Winston et al 1995). All of our patients were seriously impaired in terms of neurological, intellectual and developmental status. Pre-operative plan consideration includes positioning of the patients in regard to the weight and size of the head and the safety of the anesthetic tube. We planned our position in supine position to reduce the hazard on anesthetic side, pressure on eyes, and movement of the head. We avoid using three-pin fixation system.

Intraoperative CSF drainage must be considered after bony removal as it interferes with intracranial pressure on closure. Attention should be taken to avoid overdrainage, as it will lead to dural sagging, folding and increasing death space once the bone is fixated. The rounded contour of the dural-brain should be maintained to keep it snugly attached to the bone until the adherence takes place. Inserting the shunt back to its place did not lead to postoperative dural enveloping in our series.

13  
Table 1. Patients' characteristics

Patient	Age	Head Circumference (cm)		OR Time	Estimated Blood Loss	ICU Stay
		Before	After			
1	2 mo	50	40	4 hrs 15 mins	300 mL	1 day (death)
2	9 mo	61	50	4 hrs 15 mins	1000 mL	3 days
3	17 mo	63	48	4 hrs. 25 mins	600 mL	3 days

Identification of kinking or buckling of the sagittal sinus, when exists, should be done and address accordingly. Tacking up the dura snugly to the sagittal bandeau can help to prevent the kinking of the sinus. We started the tack up stitch from occipital and moved forward to the anterior part of the sinus. This strategy will prevent the buckling of the sinus in the posterior part. When anterior-posterior reduction is necessary by shortening the sagittal bone, utilizing our strategy, the risk of buckling will take place as far as the anterior one-third.

Blood loss should be very carefully considered and meticulously addressed. One of our cases was died 24 hours after the operation due to cardiac inability to cope with excessive blood loss. Relatively young calvarial bone tends to ooze and cannot be stopped using electrocautery. Application of bone wax may not control the bleeding completely. The technique of choice to minimize bony bleeding is to strip the pericranium only on the cutting side and leaves the pericranium intact on the uncut surface. It can reduce the blood loss significantly (633 vs. 1003 mL, average) compared to the amount reported by Sundine and colleagues (Sundine et al 2006). The ICU stay was also shorter than the previous report.

Several techniques have been published along with its advantages and disadvantages. None of it is best for all patients. The selection is based on the shape of the head, facility and familiarity of the surgeon to the specific technique. Our technique is easy in terms of position, facility, and technical challenge. The operating time and ICU stay were shorter than the previous report (Sundine et al 2006). Other advantages are good structural stability, possibility to reduce anteroposterior distance, and absence of free bone flap that can maximize the healing. Limitations in our series, similar to other techniques, are inability to alter the size of cranial base and may be difficult to apply in older child with rigid bone.

## CONCLUSION

Barrel-stave technique for reduction cranioplasty is an option for patient with hydrocephalic macrocephaly that has cranial index of 1 or more. Risk and pitfalls should be considered and taken care of meticulously, especially

the age and blood loss. Keeping the blood loss low will minimize the complication, shorter ICU stay, and allows for one-stage procedure. This procedure is relatively safe but surgeons with casual interest in cranial reconstruction should undertake special precaution.

## REFERENCES

- Ehni G (1982). Reduction of head size in advanced hydrocephalus: a case report. *Neurosurgery* 11, 223-228
- Erdoğan P, Kaynar MY., Canbaz B, Etus V, Çiplak N, Kудay C (1998). Two different surgical techniques for reduction cranioplasty. *Child's Nervous System* 14, 372-377. DOI: 10.1007/s003810050247
- Manwaring JC, Truong D, Deukmedjian AR, Carey CM, Storrs BB, Rodriguez LF, et al (2013). Cranial reduction and fixation with a resorbable plate combined with cerebrospinal fluid shunting for difficult-to-manage macrocephaly related to hydrocephalus. *Journal of Neurosurgery: Pediatrics* 11, 210-213. DOI: 10.3171/2012.10.PEDS12340
- Mathews MS, Loudon WG, Muhonen MG, Sundine MJ (2007). Vault reduction cranioplasty for extreme hydrocephalic macrocephaly. *Journal of Neurosurgery: Pediatrics* 107, 332-337. DOI: 10.3171/PED-07/10/332
- Park TS, Gready MS, Persing JA, Delashaw JB (1985). One-stage reduction cranioplasty for macrocephaly associated with advanced hydrocephalus. *Neurosurgery* 17, 506-509
- Piatt JH, Arguelles JH (1990). Reduction cranioplasty for craniocerebral disproportion in infancy: indications and technique. *Pediatric Neurology* 16, 265-270
- Sundine MJ, Wirth GA, Brenner KA, Loudon WG, et al (2006). Cranial vault reduction cranioplasty in children with hydrocephalic macrocephaly. *Journal of Craniofacial Surgery* 17, 645-655. DOI: 10.1097/00001665-200607000-00007
- Ventureyra ECG, Da Silva VF (1980). Reduction cranioplasty for neglected hydrocephalus. *Surgical Neurology* 15, 236-238
- Vries JK, Habal MB (1979). Cranio-orbital correction for massive enlargement of the cranial vault. plastic and reconstructive surgery. *Reconstructive Surgery* 63, 466-472
- Winston KR, Ogilvy C, McGrail K (1995). Reduction Cranioplasty. *Pediatric Neurosurgery* 22, 228-234

# Cranial vault reduction cranioplasty for severe hydrocephalus

## ORIGINALITY REPORT

9%

SIMILARITY INDEX

5%

INTERNET SOURCES

7%

PUBLICATIONS

1%

STUDENT PAPERS

## PRIMARY SOURCES

- 1** Michael J. Sundine, Garrett A. Wirth, Kevin A. Brenner, William G. Loudon et al. "Cranial Vault Reduction Cranioplasty in Children with Hydrocephalic Macrocephaly", *Journal of Craniofacial Surgery*, 2006  
Publication 4%
- 2** Ahmad Data Dariansyah, Wihasto Suryaningtyas, Muhammad Arifin Parenrengi. "Tuberculoma mimicking postoperative VP shunt seeding of craniopharyngioma: A rare case report", *Surgical Neurology International*, 2021  
Publication 1%
- 3** [thejns.org](http://thejns.org)  
Internet Source 1%
- 4** Submitted to Universitas Airlangga  
Student Paper 1%
- 5** Jong-Il Choi, Eun Sang Dhong, Dong-Jun Lim, Sang-Dae Kim. "Reduction cranioplasty for macrocephaly with long-standing hydrocephalus and non-fused fontanelle in <1%

# Chiari malformation type I", Child's Nervous System, 2014

Publication

6

"Vault reduction cranioplasty for extreme hydrocephalic macrocephaly", Journal of Neurosurgery Pediatrics, 10/2007

Publication

<1 %

7

Emil Kohan, Eric Jackson, Justin Heller, Jorge Lazareff, James P. Bradley. "Correction of Hydrocephalic Macrocephaly with Total Cranial Vault Remodeling and Molding Helmet Therapy", Plastic and Reconstructive Surgery, 2010

Publication

<1 %

8

[www.rawberryvegan.de](http://www.rawberryvegan.de)

Internet Source

<1 %

9

[academic.oup.com](http://academic.oup.com)

Internet Source

<1 %

10

[media.neliti.com](http://media.neliti.com)

Internet Source

<1 %

11

[www.norosirurji.org](http://www.norosirurji.org)

Internet Source

<1 %

12

[www.siftdesk.org](http://www.siftdesk.org)

Internet Source

<1 %

13

[archive-ouverte.unige.ch](http://archive-ouverte.unige.ch)

Internet Source

<1 %



---

Exclude quotes      On

Exclude matches      Off

Exclude bibliography      On

# Cranial vault reduction cranioplasty for severe hydrocephalus

---

GRADEMARK REPORT

---

FINAL GRADE

**/100**

GENERAL COMMENTS

**Instructor**

---

PAGE 1

---

PAGE 2

---

PAGE 3

---

PAGE 4

---

PAGE 5

---