

# Jarcho-levin syndrome a case report

*by* Wihasto Suryaningtyas

---

**Submission date:** 24-Jun-2022 10:24AM (UTC+0800)

**Submission ID:** 1862081248

**File name:** Jarcho-levin\_syndrome\_a\_case\_report.pdf (1.46M)

**Word count:** 2705

**Character count:** 15019

See discussions, stats, and author profiles for this publication at: <https://www.researchgate.net/publication/340645036>

# Jarcho-Levin syndrome: A case report

Article · April 2020

DOI: 10.15562/ijrv.203.93

CITATIONS

0

READS

294

2 authors:



Wihasto Suryaningtyas  
Airlangga University

45 PUBLICATIONS 121 CITATIONS

SEE PROFILE



Muhammad Arifin  
Airlangga University

49 PUBLICATIONS 90 CITATIONS

SEE PROFILE

Some of the authors of this publication are also working on these related projects:



Experimental Hydrocephalus View project



Epilepsy surgery View project

Wihasto Suryaningtyas<sup>1\*</sup>, Muhammad Arifin Parenrengi<sup>1</sup>

## ABSTRACT

**Introduction:** Jarcho-Levin syndrome is a genetic skeletal disorder characterized by short-trunk dwarfism with vertebral and rib anomalies. The association with other organs such as the spinal, brain, and the urinary system has been reported. The paper reports a rare case of Jarcho-Levin syndrome associated with neural tube defects and other congenital malformations.

**Case presentation:** The patient came with neglected myelomeningocele and severe hydrocephalus. Type 3 growing skull

fracture complicated the management of this syndrome. This paper describes the management of JLS associated with neural tube defects as well as the severe hydrocephalus and the growing skull fracture.

**Conclusion:** The paper reports a rare case of Jarcho-Levin syndrome associated with neural tube defects and other congenital malformations. The treatment should be carefully tailored.

**Keywords:** Growing skull fracture, hydrocephalus, Jarcho-Levin syndrome, myelomeningocele, spondylocostal dysostosis

**Cite This Article:** Suryaningtyas, W., Parenrengi, M.A. 2020. Jarcho-Levin syndrome: A case report. *Indonesian Journal of Neurosurgery* 3(1): 8-11. DOI: 10.15562/ijn.v2i3.93

<sup>1</sup>Department of Neurosurgery,  
Faculty of Medicine, Universitas  
Airlangga, Dr. Soetomo General  
Hospital, Surabaya, Indonesia.

## INTRODUCTION

Jarcho-Levin syndrome (JLS) is a rare disorder due to genetic mutation resulting in abnormality of the vertebrae and ribs coupled with major features of a short neck, scoliosis, short trunk, and deformity of the rib cage.<sup>1,2</sup> Other abnormalities have also been described in Jarcho-Levin syndrome, including neural tube defects, Arnold-Chiari malformation, renal/urinary tract abnormalities, hydrocephalus, hydrourteronephrosis, and myelomeningocele.<sup>3</sup> This set of particular presentations is usually identified in a newborn. Jarcho and Levin first report it in 1938.<sup>4</sup> Later, Jarcho-Levin syndrome was confusingly used as a synonym of several vertebral-costal malformations including spondylothoracic dysplasia/dysostosis, spondylocostal dysplasia/dysostosis, costovertebral dysplasia, and occipital-facial-cervicothoracic-abdominal-digital dysplasia. Published reports mixed up the use of two different phenotypes, spondylothoracic dysplasia/dysostosis, and spondylocostal dysostosis, as a single entity known as JLS. Those phenotypes are different in terms of typical presentation, underlying genetic mutation, prognosis, and mortality.<sup>5</sup> In this report, we describe a two-month-old baby with JLS associated with neglected myelomeningocele, severe hydrocephalus, and growing skull fracture.

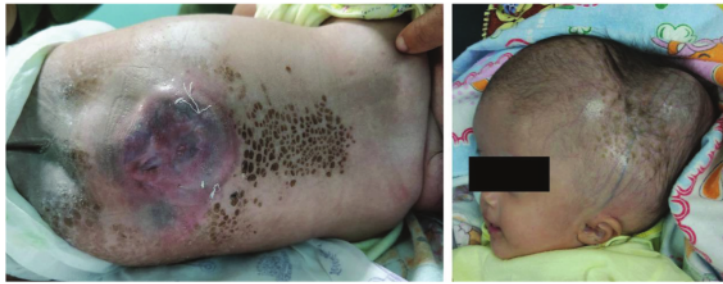## CASE PRESENTATION

A two-month-old full-term baby girl presented to our hospital with progressive head enlargement, a lump on the head, and chronic wound of the back (Figure 1). She was the second offspring of non-consanguineous parents, her sibling was normal and there was no history of similar abnormalities in any of her family members. She was born spontaneously by a midwife. Apgar score was 9/10. The prenatal diagnosis could not be obtained, as the mother never visited an obstetrician. All prenatal and delivery history was retrieved from the midwife. The pregnancy was uneventful. During delivery, there was temporary difficulty to move out the head from the pelvic outlet. No forceps was used during delivery. At birth, she had an opening at her back and watery leakage was found from the defect. The head circumference at birth was 38 cm.

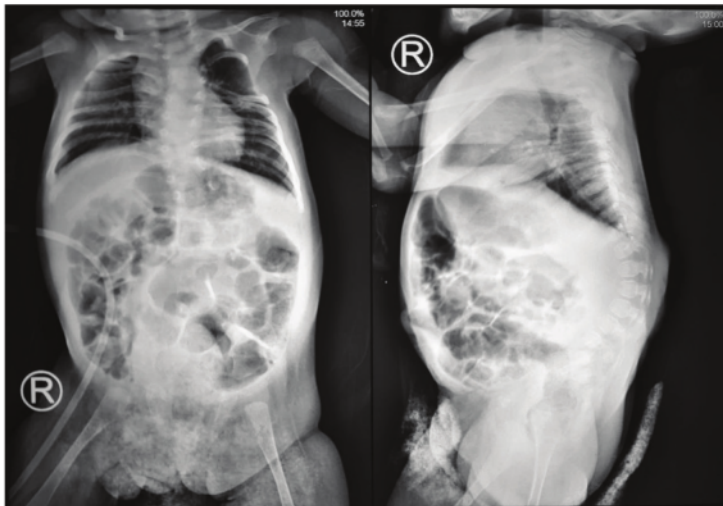
Physical examination revealed thoracolumbar kyphoscoliosis, dried chronic wound on the lumbar spine defect, and severe head enlargement. The head circumference was 52.5 cm (> 95 percentile). A five-centimeter cystic lump with a positive result on illumination was palpable over the bony defect of the skull. The lower limb deformities were also observed. On neurological examination, power was 4 of 5 in both the lower limbs, deep tendon reflexes were sluggish, the plantar response was extensor on both sides and superficial sensations were decreased

\*Corresponding author:  
Wihasto Suryaningtyas;  
Department of Neurosurgery,  
Faculty of Medicine, Universitas  
Airlangga, Dr. Soetomo General  
Hospital, Surabaya, Indonesia;  
wihasto-s@fk.unair.ac.id

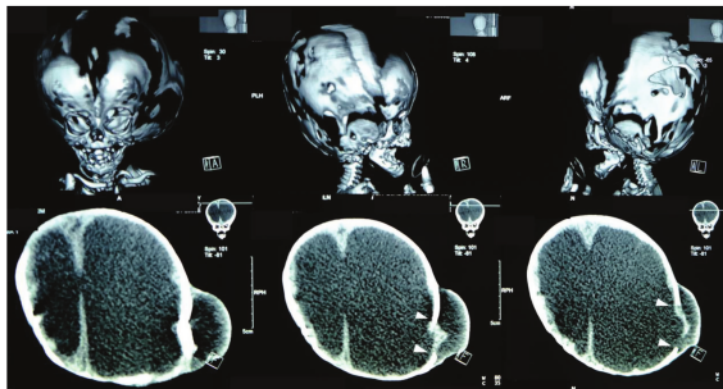
Received: 2019-11-22  
Accepted: 2020-02-20  
Published: 2020-04-01



**Figure 1.** Clinical presentation of the neglected myelomeningocele (left) and enlargement of the head associated with cystic mass on parieto-occipital region (right).



**Figure 2.** The babygram showed thoracic scoliosis to the right side and kyphotic lumbar spine. Deformation of the ribs was observed on the 2<sup>nd</sup> and 5<sup>th</sup> right side ribs as well as the 5<sup>th</sup> left side. Fusion occurred on 2<sup>nd</sup>, 3<sup>rd</sup>, 4<sup>th</sup> right ribs and also on 3<sup>rd</sup>-4<sup>th</sup>, 6<sup>th</sup>-7<sup>th</sup>, and 8<sup>th</sup>-9<sup>th</sup> left ribs. There was no evidence of “pebble stone” vertebra or hemivertebra.



**Figure 3.** Head CT scan showed a severe hydrocephalus with porencephalic cyst protruding from bone defect (white arrowhead) on left parieto-occipital region. The 3D reconstruction revealed a large bone defect and severely fragmented bone.

below the L-1 level.

The babygram revealed thoracic scoliosis to the right side, kyphosis of the lumbar spine, agenesis of L5 spinal process and sacral spine, and multiple bilateral abnormalities of the ribs in the form of fusion and deformation (Figure 2). Head CT scan showed severe hydrocephalus, deformational plagiocephaly, bone defect on the parieto-occipital region, and protruded porencephalic cyst through the bony defect on the parieto-occipital (Figure 3).

The staging operation was performed for the correction of the spinal myelomeningocele, VP shunt to reverse severe hydrocephalus, and correction of growing skull fracture. Neglected myelomeningocele featured with a scarring tissue made the surgery challenging to determine the border between the placode and adjacent arachnoid layer.

A small midline linear skin incision was employed at the upper limit of the lesion. The incision was continued along the border between the dystrophic skin and the arachnoid that surrounds the malformation and circumferentially until the entire placode. The arachnoid border was identified on some part of the lesion where the scar is minimal. Finally, a further midline linear incision was made at the lower part of the defect. Blood loss was kept minimal as the scar tended to bleed. The placode was too big to put back into the spinal canal. The kyphotic lumbar spine also discouraged it. Adequate undermining was necessary to reduce the skin tension on the skin closure.

VP shunt was placed right after the closure of the spinal defect. Despite the severe hydrocephalus, the other purpose of the shunt was to facilitate the reconstruction of the growing skull fracture later by reducing the cyst size.

During the postoperative period, there was no new or progressive neurological deficit. No cerebrospinal fluid leakage or collection in the operative wound was found. No respiratory problem was observed during the hospitalization. Orthopedic and Cardiothoracic surgeons decided to observe the patient and indicated that the surgical measures for the spine and ribs deformities were not needed in the time being. The patient was discharged uneventfully.

## DISCUSSION

Back in 1938, Saul Jarcho and Paul Levin from Johns Hopkins Hospital reported two cases of short trunk babies due to the vertebral body and rib anomalies.<sup>4</sup> In 1966, Norman Lavy and colleagues from Indiana University reported a similar syndrome. It was followed by a report by John E. Moseley from New York City who coined the name of spondylo-thoracic



dysplasia (dysostosis) for the first time.<sup>6</sup> In 1978, Solomon and colleagues classified both clinical phenotypes into the same syndrome, Jarcho-Levin syndrome, which started the seemingly confusing terms.<sup>7</sup> After 30 years of inaccurate classification, in 2011, Berdon and associates differentiate both phenotypes based on findings reported by Jarcho-Levin and Lavy-Moseley. Jarcho-Levin syndrome (JLS) is now applied to the clinical phenotype of spondylocostal dysostosis (SCD), while spondylothoracic dysplasia/dysostosis (STD) wears a name of Lavy-Moseley syndrome (LMS). JLS has a more benign clinical course with a higher survival rate than STD.<sup>8</sup> JLS is widely distributed among races worldwide but STD is mostly found in Puerto Rican. The incidence is unknown for STD, but JLS has a reported prevalence of 1 per 40,000 live-born infants.<sup>9</sup>

Molecular genetic advances in JLS patients allow us to detect mutations in the delta-like 3 (DLL3) gene on chromosome 19q13.1. Contrary, the genetics of patients with STD are not as well elucidated. In contrast to JLS, patient with STD only showed mutations in the Notch-associated gene MESP2.<sup>1,10,11</sup>

Typical clinical presentations of a patient with JLS are intrinsic rib malformations (broadening, fusion, missing ribs, abnormal orientation, bifurcation, irregularity of shape and size) in addition to multiple vertebral segmentation defects as in our case.<sup>12</sup> Those with STD have multiple vertebral anomalies with a posterior fusion of the ribs giving a “fan” like configuration of the ribs and crab-like appearance of the thorax and do not have intrinsic rib malformations. The vertebral defects in both JLS and STD include a decreased number of vertebrae with segmentation and formation defects like block vertebrae, hemivertebrae, butterfly vertebrae, missing vertebra, and fused vertebrae. All cases of STD and the majority of JLS have an autosomal recessive pattern of inheritance.<sup>13</sup>

Neural tube defects (NTDs) like spina bifida, meningocele, meningomyelocele, lipomyelomeningocele, and diastematomyelia have been reported to be associated with Jarcho-Levin syndrome. Spina bifida is present in 25% of patients with Jarcho-Levin syndrome.<sup>2,14</sup> A high prevalence of hydrocephalus and NTD was reported in one study. A ventriculoperitoneal shunt was needed in 55% cases.<sup>3</sup> The severity of the hydrocephalus was not reported. Our case had very severe hydrocephalus similar to other report.<sup>15</sup> Deformational plagiocephaly occurs in our case was also the result of severe hydrocephalus coupled with the growing skull fracture, which causes a

growing cerebrospinal fluid (CSF) deposition under the subgalea. Little was known regarding the cause of the diastasis fracture. The birth injury was one of the possible explanations since the baby was born by the midwife without any medical doctor supervision. Increasing intracranial fluid pressure from hydrocephalus posed the fractured site more rapidly to separate further. A type 3 growing skull fracture occurred, characterized by the CSF-filled-arachnoid balloon protruding from the bone defect.

The diagnosis of JLS should be suspected through prenatal ultrasound in the spinal neural tube defect fetus as early as the first trimester. Improved resolution of ultrasound has allowed for a better definition of normal and dysplastic fetal anatomy. Dysostosis syndrome should be suspected in any fetus showing vertebral deformities and spina bifida during ultrasound exploration. Once the diagnosis is made (either pre- or postnatally), genetic counseling should be provided to the family as they have a 25% risk of recurrence in siblings.<sup>5</sup>

The phenotype of JLS must be considered in neurosurgical planning and complications management. To a lesser degree, the scoliotic or kyphotic form of the spine may interfere with the repair of MMC. In hydrocephalus treatment, the severe thoracic deformity may constitute difficulty in VP shunt placement. Placement of the peritoneal catheter should be performed in two steps by making an incision over the clavicle to avoid pulmonary complications. Thoracic deformity or scoliosis may increase intra-abdominal pressure that can cause VP shunt malfunction.<sup>3</sup> While STD is related to a thoracic mechanical restriction that contributes to the respiratory problem, JLS has a lower degree of respiratory problem. However, JLS can develop progressive scoliosis and neurological complications. In this case, orthopedic surgery, including vertical expandable titanium rib techniques may be beneficial.<sup>9,16</sup> The growing skull fracture is the least problem related directly to the JLS but anesthesia problems may arise.

Lesson learned from the case includes the prenatal diagnosis of JLS should be kept in mind when spina bifida and hydrocephalus occurred.<sup>17</sup> The possibility of having a sibling with the same problem may happen. Surgical treatment and its pitfalls should be considered.

## CONCLUSION

The paper reports a rare case of Jarcho-Levin syndrome associated with neural tube defects and other congenital malformations. The treatment should be carefully tailored.

**CONFLICT OF INTEREST**

All authors stated that there is no financial or other potential conflict of interest.

**FUNDING**

None

**AUTHORS' CONTRIBUTIONS:**

WS was drafting the article, collecting the data, literature search and review, review of the manuscript, and revision of the article; MAP was collecting the data, critical review of the manuscript, and revision of the manuscript.

**REFERENCES:**

- Kulkarni ML, Navaz SR, Vani HN, Manjunath KS, Matani D. Jarcho-Levin syndrome. *Indian J Pediatr.* 2006; 73(3): 245 – 7. DOI: [10.1007/bf02825493](https://doi.org/10.1007/bf02825493).
- Dane B, Dane C, Aksoy F, Cetin A, Yayla M. Jarcho-Levin syndrome presenting as neural tube defect: Report of four cases and pitfalls of diagnosis. *Fetal Diagn Ther.* 2007; 22(6): 416 – 9. DOI: [10.1159/000106345](https://doi.org/10.1159/000106345).
- Alatas I, Canaz H, Akkoyun N, Er A, Demirhan O, Kizilay D, et al. Neural tube defects in Jarcho-Levin syndrome: Study of twenty-eight cases. *Pediatr Neurosurg.* 2015; 50(2): 57 – 62. DOI: [10.1159/000380770](https://doi.org/10.1159/000380770).
- Jarcho S, Levin P. Hereditary malformation of the vertebral bodies. *Bull John Hopkins Hosp.* 1938; 62: 216 – 26.
- Cornier AS, Ramirez N, Carlo S, Reiss A. Controversies surrounding Jarcho-Levin syndrome. *Curr Opin Pediatr.* 2003; 15(6): 614 – 20. DOI: [10.1097/00008480-200312000-00012](https://doi.org/10.1097/00008480-200312000-00012).
- Lavy NW, Palmer CG, Merritt AD. A syndrome of bizarre vertebral anomalies. *J Pediatr.* 1966; 69(6): 1121 – 5. DOI: [10.1016/s0022-3476\(66\)80304-9](https://doi.org/10.1016/s0022-3476(66)80304-9).
- Solomon L, Jimenez RB, L Reiner. Spondylothoracic dysostosis: Report of two cases and review of the literature. *Arch Pathol Lab Med.* 1978; 102(4): 201 – 5.
- Berdon WE, Lampl BS, Cornier AS, Ramirez N, Turnpenny PD, Vitale MG, et al. Clinical and radiological distinction between spondylothoracic dysostosis (Lavy-Moseley syndrome) and spondylocostal dysostosis (Jarcho-Levin syndrome). *Pediatr Radiol.* 2011; 41(3): 384 – 8. DOI: [10.1007/s00247-010-1923-8](https://doi.org/10.1007/s00247-010-1923-8).
- Campbell Jr RM. Spine deformities in rare congenital syndromes: Clinical issues. *Spine (Phila Pa 1976).* 2009; 34(17): 1815 – 27. DOI: [10.1097/BRS.0b013e3181ab64e9](https://doi.org/10.1097/BRS.0b013e3181ab64e9).
- Whitlock NV, Sparrow DB, Wouters MA, Sillence D, Ellard S, Dunwoodie SL, et al. Mutated MESP2 causes spondylocostal dysostosis in humans. *Am J Hum Genet.* 2004; 74(6): 1249 – 54. DOI: [10.1086/421053](https://doi.org/10.1086/421053).
- Cornier AS, Staehling-Hampton K, Delventhal KM, Saga Y, Caubet JF, Sasaki N, et al. Mutations in the MESP2 gene cause spondylothoracic dysostosis/Jarcho-Levin syndrome. *Am J Hum Genet.* 2008; 82(6): 1334 – 41. DOI: [10.1016/j.ajhg.2008.04.014](https://doi.org/10.1016/j.ajhg.2008.04.014).
- Kurup PM, Tanigasalam V, Bhat BV. Spondylocostal dysostosis (Jarcho-Levin syndrome). *Indian J Pediatr.* 2018; 85(6): 486.
- Srinivas BH, Puligopu AK, Sukhla D, Ranganath P. Rare association of spondylo costal dysostosis with split cord malformations type II: A case report and a brief review of literature. *J Pediatr Neurosci.* 2014; 9(2): 142 – 144. DOI: [10.4103/1817-1745.139320](https://doi.org/10.4103/1817-1745.139320).
- Giacoia GP, Say B. Spondylocostal dysplasia and neural tube defects. *J Med Genet.* 1991; 28(1): 51 – 3. DOI: [10.1136/jmg.28.1.51](https://doi.org/10.1136/jmg.28.1.51).
- Yurttutan S, Degirmencioglu H, Oncel MY, Kara S, Sari F, Dilmen U. Jarcho-Levin syndrome presenting with severe hydrocephalus: A report of three cases. *Genet Couns.* 2013; 24(4): 361 – 6.
- Kwan KYH, Cheung JPY, Yiu KKL, Cheung KMC. Ten year follow-up of Jarcho-Levin syndrome with thoracic insufficiency treated by VEPTR and MCGR VEPTR hybrid. *Eur Spine J.* 2018; 27(Suppl 3): 287 – 91. DOI: [10.1007/s00586-017-5164-x](https://doi.org/10.1007/s00586-017-5164-x).
- Santos JLM, Dmytriw AA, Fermin S. Neurosurgical management of a large meningocele in Jarcho-Levin syndrome: Clinical and radiological pearls. *BMJ Case Rep.* 2015; 2015: bcr2015210240. DOI: [10.1136/bcr-2015-210240](https://doi.org/10.1136/bcr-2015-210240).



This work is licensed under a Creative Commons Attribution

# Jarcho-levin syndrome a case report

## ORIGINALITY REPORT

19%

SIMILARITY INDEX

10%

INTERNET SOURCES

16%

PUBLICATIONS

0%

STUDENT PAPERS

## PRIMARY SOURCES

- 1 Massimo Caldarelli. "Myelomeningocele Primary Repair Surgical Technique", The Spina Bifida, 2008 1%

Publication
- 2 AKIN, Mustafa Ali, GÜNEŞ, Tamer, BAYKAN, Ali, ÇOBAN, Dilek, SEZER, Sadettin and VATANKULU, Ferhat. "Aynı olguda iki nadir hastalık: Jarcho-Levin sendromu ve kompleks kardiyak patoloji", TUBITAK, 2010. 1%

Publication
- 3 balimedicaljournal.org 1%

Internet Source
- 4 publication.babcock.edu.ng 1%

Internet Source
- 5 link.springer.com 1%

Internet Source
- 6 mill.onesearch.id 1%

Internet Source
- 7 G P Giacoia, B Say. "Spondylocostal dysplasia and neural tube defects.", Journal of Medical 1%

## Genetics, 1991

Publication

8

Vazquez-Lopez, M.E.. "Anomalies of vertebrae and ribs: Jarcho Levin syndrome. Description of a case and literature review", Joint Bone Spine, 200505

Publication

1 %

9

M Schulman, M T Gonzalez, M R Bye. "Airway abnormalities in Jarcho-Levin syndrome: a report of two cases.", Journal of Medical Genetics, 1993

Publication

1 %

10

[cyberleninka.org](http://cyberleninka.org)

Internet Source

1 %

11

[www.fqmadrid.org](http://www.fqmadrid.org)

Internet Source

1 %

12

M. L. Kulkarni. "Jarcho-Levin syndrome", The Indian Journal of Pediatrics, 03/2006

Publication

1 %

13

RamachandranNair, R.. "Incomplete Alpha Coma Pattern in a Child", Pediatric Neurology, 200508

Publication

1 %

14

"A thoracic myelomeningocele in a patient with spondylocostal dysostosis", Journal of Neurosurgery Pediatrics, 01/2006

Publication

1 %



15 Rachel S. Honjo. "Spondylocostal Dysostosis Associated with Methylmalonic Aciduria", Genetic Testing and Molecular Biomarkers, 02/28/2009 1 %  
Publication

---

16 "6 Congenital Deformities", Georg Thieme Verlag KG, 2018 <1 %  
Publication

---

17 G. Wong. "Jarcho-Levin syndrome: two consecutive pregnancies in a Puerto Rican couple", Ultrasound in Obstetrics and Gynecology, 7/1998 <1 %  
Publication

---

18 William Quitiaquez, Isaac Simbaña, César A. Isaza-Roldán, Patricio Quitiaquez et al. "Revisión del estado del arte de sistemas DX-SAHP para la obtención de agua caliente sanitaria", Enfoque UTE, 2020 <1 %  
Publication

---

19 [www.ncbi.nlm.nih.gov](http://www.ncbi.nlm.nih.gov) <1 %  
Internet Source

---

20 "Trends in Reconstructive Neurosurgery", Springer Science and Business Media LLC, 2017 <1 %  
Publication

---

21 Norman Ramirez, Sigfredo Villarin, Robert Ritchie, Kenira J. Thompson. "Thoracic <1 %

Insufficiency Syndrome: An Overview", Razavi  
International Journal of Medicine, 2015

Publication

22

[synapse.koreamed.org](http://synapse.koreamed.org)

Internet Source

<1 %

23

[www.bcpsbd.org](http://www.bcpsbd.org)

Internet Source

<1 %

24

Anthony C. Casamassima. "Spondylocostal  
dysostosis associated with anal and  
urogenital anomalies in a Mennonite sibship",  
American Journal of Medical Genetics, 1981

Publication

<1 %

25

Banu Dane, Cem Dane, Figen Aksoy, Ahmet  
Cetin, Murat Yayla. "Jarcho-Levin Syndrome  
Presenting as Neural Tube Defect: Report of  
Four Cases and Pitfalls of Diagnosis", Fetal  
Diagnosis and Therapy, 2007

Publication

<1 %

26

Merih Çetinkaya, Hilal Özkan, Nilgün Köksal,  
Zeynep Yazıcı, Ulviye Yalçınkaya.

"Spondylocostal dysostosis associated with  
diaphragmatic hernia and neural tube  
defects", Clinical Dysmorphology, 2008

Publication

<1 %

27

[coek.info](http://coek.info)

Internet Source

<1 %

28

Muhammad Arifin, Wihasto Suryaningtyas, Abdul Hafid Bajamal. "Frontoethmoidal encephalocele: clinical presentation, diagnosis, treatment, and complications in 400 cases", *Child's Nervous System*, 2018

Publication

<1 %

29

Nihat Demir, Erdal Peker, İsmail Gülşen, Kemal Ağengin, Sultan Kaba, Oğuz Tuncer. "A Single-Center Experience of CNS Anomalies or Neural Tube Defects in Patients With Jarcho-Levin Syndrome", *Journal of Child Neurology*, 2015

Publication

<1 %

Exclude quotes On

Exclude matches Off

Exclude bibliography On

# Jarcho-levin syndrome a case report

---

## GRADEMARK REPORT

---

FINAL GRADE

**/100**

GENERAL COMMENTS

**Instructor**

---

PAGE 1

---

PAGE 2

---

PAGE 3

---

PAGE 4

---

PAGE 5

---