

# Use of a Three-dimensional Smartphone Scanner in

*by* Kartika P. Sari

---

**Submission date:** 01-Apr-2023 08:16AM (UTC+0800)

**Submission ID:** 2052515448

**File name:** Use\_of\_a\_Three-dimensional\_Smartphone\_Scanner\_in..pdf (954.94K)

**Word count:** 4355

**Character count:** 23403

# Use of a Three-dimensional Smartphone Scanner in the Quantitative Analysis of Repaired Unilateral Cleft Lip during the Coronavirus Disease Pandemic

Kartika P. Sari, MD

Iswinarno D. Saputro, MD, PhD

Lynda Hariani, MD, PhD

**Background:** Cleft lip, a major craniofacial abnormality, is highly prevalent among people with low socioeconomic status in Indonesia. Direct two-dimensional measurement of the affected region is the gold standard for surgical preparation; however, its compliance and usability are limited in pediatric patients. Modern smartphones, including iPhones, are equipped with high-resolution cameras, which can record images and videos of a face. Here, we investigated whether a three-dimensional (3D) smartphone scanner can be used for the facial measurements of patients with unilateral cleft lip.

**Methods:** Twelve facial measurements were acquired after cleft lip surgery in three female and seven male patients (aged 11–29 months) with unilateral cleft lip using direct anthropometry and a 3D smartphone scanner. The accuracy and precision of the 3D smartphone scanner were assessed through comparative analyses (*t* test and Bland–Altman plot).

**Results:** The anthropometric data obtained using the 3D smartphone scanner matched the direct measurement data. The linear measurements did not differ significantly between two-dimensional and 3D modalities ( $P > 0.05$ ). The intra-observer reliabilities of the two-dimensional smartphone scanner of the first and second observers were high (intraclass correlation coefficient 0.876–0.993 and Cronbach alpha 0.920–0.998) and moderate to high (intraclass correlation coefficient 0.839–0.996 and Cronbach alpha 0.940–0.996), respectively. Inter-observer data showed an intraclass correlation coefficient of 0.876–0.981 and a Cronbach  $\alpha$  of 0.960–0.997.

**Conclusion:** The 3D smartphone scanner is effective, efficient, economical, quick, and feasible for facial measurements of patients with unilateral cleft lip and is a viable alternative to direct two-dimensional measurements. (*Plast Reconstr Surg Glob Open* 2023; 11:e4895; doi: 10.1097/GOX.0000000000004895; Published online 29 March 2023.)

## INTRODUCTION

Cleft lip and palate are major craniofacial anomalies and are mostly reported in populations with low socioeconomic status in Indonesia.<sup>1</sup> The incidence of cleft lip is

17

From the Department of Reconstructive and Aesthetic Plastic Surgery, Dr. Soetomo General Hospital affiliated to the Faculty of Medicine Airlangga University, Surabaya, Indonesia.

Received for publication September 21, 2022; accepted February 6, 2023.

Presented at the 14th International Congress of Cleft Lip, Palate & Related Craniofacial Anomalies, July 11–15, 2022, Edinburgh.

Copyright © 2023 The Authors. Published by Wolters Kluwer Health, Inc. on behalf of The American Society of Plastic Surgeons. This is an open-access article distributed under the terms of the Creative Commons Attribution-Non Commercial-No Derivatives License 4.0 (CCBY-NC-ND), where it is permissible to download and share the work provided it is properly cited. The work cannot be changed in any way or used commercially without permission from the journal.

DOI: 10.1097/GOX.0000000000004895

two per 1000 live births in Indonesia.<sup>2</sup> In Indonesia, we have developed our own surgical repair method known as the Djhonsjah method, which is a modification of the traditional Millard rotation-advancement lip repair in which the flap is coupled to a vermilion muscle lateral flap for the repair of cleft lip.<sup>3</sup> Primary correction of cleft lip deformity aims to restore the balance between function and proper anatomy and to achieve long-term symmetry.<sup>1</sup> Anthropometric measurements showed symmetrical nose improvement after primary correction using a systematic strategy for unilateral cleft nose abnormalities.<sup>4</sup>

11

**Disclosure:** The authors have no financial interest to declare in relation to the content of this article. This study received no external funding.

5

Related Digital Media are available in the full-text version of the article on [www.PRSGlobalOpen.com](http://www.PRSGlobalOpen.com).

Smartphones represent an affordable and ubiquitous technology. Furthermore, a three-dimensional (3D) smartphone scanner operating system-based application can be obtained online for free. In low-income countries, such as Indonesia, there is a serious need for cost-effective modalities for accurate facial measurements of patients without increasing the overall treatment cost. This is particularly pertinent during the ongoing coronavirus disease (COVID-19) pandemic, wherein doctors are experiencing difficulties in performing accurate measurements in patients after surgery due to isolation requirements and exposure risk, demonstrating a need for cost- and time-effective facial measurement methods.

Herein, we introduce the use of a 3D smartphone scanner in the quantitative analysis of unilateral cleft lip during the COVID-19 pandemic to reduce physician–patient exposure, assess its utility in reducing cost and addressing the unique challenges posed by the COVID-19 pandemic, and evaluate the accuracy and precision of the scanner.

## MATERIALS AND METHODS

### Patients

We evaluated 10 patients (three female patients and seven male patients) who presented to the Cleft Lip and Palate Center in Surabaya between July and August 2021 during the COVID-19 pandemic. These patients had a history of cleft lip repair using the Djohansjah method at our center. The Djohansjah method is a modified Millard technique wherein a lateral vermilion muscle flap is inserted to form the upper lip tubercle. All participants were children aged between 11 and 29 months. Patients with unilateral cleft lip who had undergone cleft lip repair at our center more than 6 months ago and had no evidence of any syndrome were included. Patients lost to follow-up and with secondary revisions were excluded.

This study was conducted following the tenets of the Declaration of Helsinki and approved by the local institutional review board with the serial number 127/EC/KEPK/FKUA/2021. Parental informed consent was obtained for all patients in a written statement.

### Data Acquisition

We evaluated the accuracy and precision of the iPhone XI camera scanner (Apple Inc., Cupertino, Calif.) and Scandy Pro medical application (Louisiana Entertainment, La.). Data acquired (Standard Tessellation Language and OBJ files) from the smartphone, which were encrypted and password protected, were compiled into 3D images using Meshlab software (ISTI–CNR, Pisa, Italy) to obtain the required measurements. All medical personnel who performed the scans underwent COVID-19 polymerase chain reaction testing before and after the scans. The patients underwent 3D scanning three times each, performed by two observers with an expertise in plastic surgery and familiar with three-dimensional technology. The scanning was performed in natural light with distance according to the application settings and when the patients were awake. The children’s collaboration was obtained by the help of

### Takeaways

**Question:** Cleft lip is highly prevalent among those with a low socioeconomic status in Indonesia. Direct two-dimensional measurements of the affected region have limited compliance and usability in pediatric patients.

**Findings:** Twelve facial measurements were acquired after cleft lip surgery with a unilateral cleft lip. The accuracy and precision of the three-dimensional smartphone scanner were assessed through comparative analysis. The anthropometric data obtained using the three-dimensional smartphone scanner matched the direct measurement data.

**Meaning:** The three-dimensional smartphone scanner is feasible for facial measurements in patients with a unilateral cleft lip.

the parents, toys or snacks as a reward, and also a cartoon movie as a decoy for the children. The parents played an important role by pacifying their children before the photographs were taken by observers. Parental education by observers was done before the data acquisition. The scanning process was simple and straightforward to be performed without any complicated protocols beside COVID-19 protocols, which limited the persons involved in this research. Figure 1 shows the 2D data acquisition process. The 3D scanning process was done using iPhone XI Pro Max with the help of parents, toys, and a cartoon movie as a decoy (See Video [online], which displays the 3D scanning process by using iPhone XI Pro Max with the help of parents, toys, and a cartoon movie as a decoy). We determined 12 landmarks for cleft lip anthropometry. The landmarks are shown in Figure 2.

### Accuracy and Precision Assessments

The direct (2D) measurements were repeated three times by the same surgeon at intervals of 60 min. The mean of all measurements was calculated using SPSS software (SPSS Inc. Released 2007. SPSS for Windows/Macintosh, version 16.0, Chicago, SPSS Inc.). We calculated the sample size using the hypothesis of single group<sup>5</sup>; the sample size was determined to be a minimum of nine samples. The formula for determining sample size is given below:

$$n = \left( \frac{(Z\alpha + Z\beta) \cdot SD}{X_1 - X_2} \right)^2$$

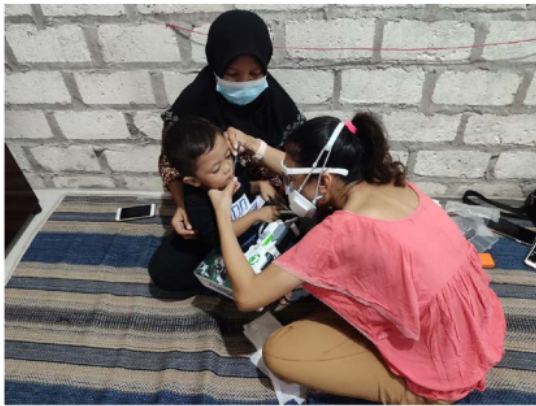$$n = \left( \frac{(1.96 + 1.64) \cdot 1.09}{20.73 - 19.34} \right)^2$$

$$n = \left( \frac{3.92}{1.39} \right)^2 = 7.95 + 10\% = 9$$

Zα	:	Error type I	1.96
Zβ	:	Power β	1.64
SD	:	Standard deviation	1.09*
X <sub>1</sub>	:	Mean direct anthropometry	20.73*
X <sub>2</sub>	:	Mean 3D	19.34*

\*Value of SD, X<sub>1</sub>, X<sub>2</sub> were acquired from Li 2013.<sup>5</sup>

The distribution of the data was tested using the Kolmogorov–Smirnov test. All data are presented as mean,



**Fig. 1.** The direct anthropometry by using caliper was performed in children, with the help of parents and toys.

standard deviation, and mean difference. Comparative analyses between the two methods (direct measurement and 3D) were performed using a Bland–Altman plot and

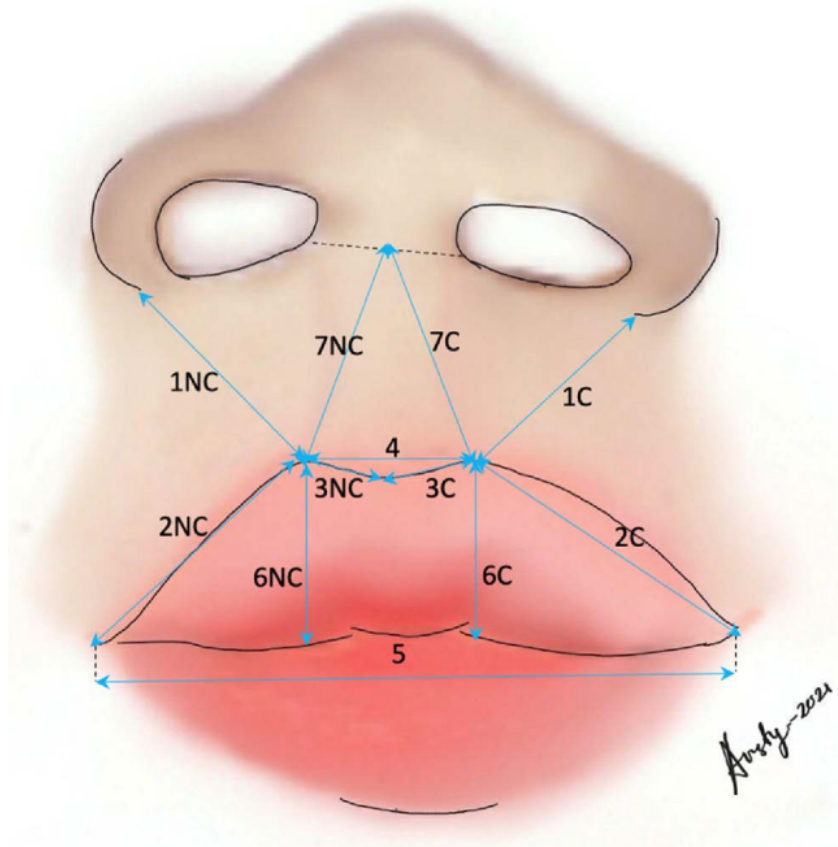
paired *t* test. Differences were considered statistically significant at a *P* value less than 0.05. The precision of the 3D smartphone scanner was assessed, and measurements were performed by two different observers. We tested the intra- and inter-observer reliabilities. We used the interclass correlation coefficient (ICC) and Cronbach  $\alpha$  to test the reproducibility of these landmark measurements using the 3D smartphone scanner. An ICC of more than 0.5 and a Cronbach  $\alpha$  of more than 0.7 were considered reliable.

#### Time Interval for Each Session

The total time required for each measurement session was determined using a stopwatch. Data were processed using SPSS version 16 and compared using a paired *t* test. Results with *P* less than 0.05 were considered statistically significant.

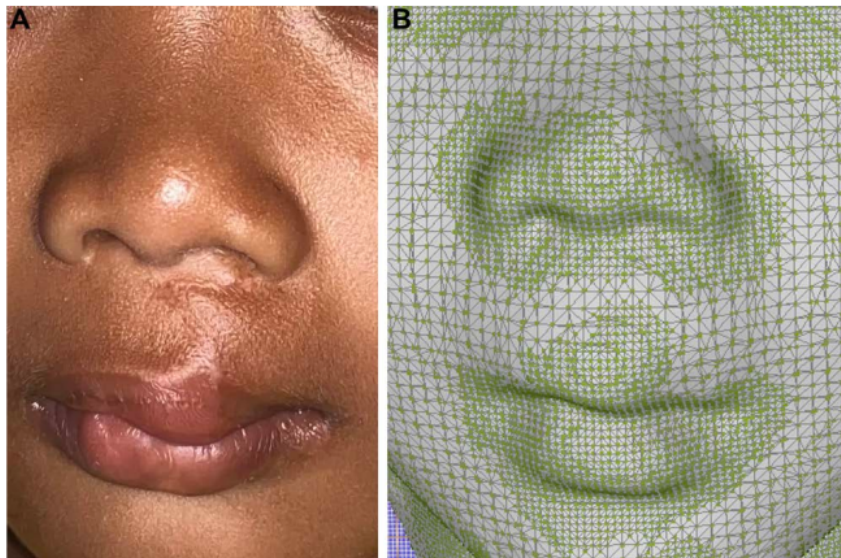
### RESULTS

The study population comprised male and female patients at a ratio of 2.3:1. All patients were aged between 11 and 29 months. Left-sided cleft was dominant (4:1) in



**Fig. 2.** The 12 anthropometric anatomic landmarks for unilateral cleft anthropometry, determined by us.





**Fig. 3.** Results obtained with the smartphone scanner. A, Three-dimensional smartphone scan showing results of application scanning using free iPhone operating system software. B, Three-dimensional smartphone scan showing acquired data being processed in Meshlab software on a computer.

the patients. The results obtained with the smartphone scanner are shown in Figure 3. All observers tested negative in the COVID-19 polymerase chain reaction test.

**Scanning Time**

The mean time from scanning until measurement was  $7.33 \pm 1.41$  min.

**3D Smartphone Scanner Accuracy**

A reasonable agreement was evident between the 2D and 3D measurements. The Bland–Altman plot values were between the measures of agreement (-4.830 to 5.310). There were no significant differences in the linear measurements between the 2D and 3D measurements ( $P > 0.05$ ). The mean difference was in the range of 0.35–1.57 mm. The highest difference was observed in

the horizontal lip length on the noncleft side (1.57 mm; Table 1).

**Intra- and Interobserver Reliabilities of the 3D Smartphone Scanner for Precision**

The intraobserver reliability and validity of the first observer were 0.876–0.993 with ICC and 0.920–0.998 with Cronbach  $\alpha$ , and those of the second observer were 0.839–0.996 with ICC and 0.940–0.996 with Cronbach  $\alpha$  (Table 2). The inter-observer reliability and validity were 0.876–0.981 with ICC and 0.960–0.997 with Cronbach  $\alpha$  (Table 3).

**DISCUSSION**

Anthropometric measurements can be obtained using direct or indirect methods. Direct anthropometry

**Table 1. Paired t Test Comparing Linear Measurements between the Direct (2D) Method and the Indirect (3D) Smartphone Scanner Method**

Variable (Mean $\pm$ SD)	2D	3D	Mean Difference	P
Lip vertical height cleft	10.40 $\pm$ 2.09	10.90 $\pm$ 2.04	0.5	0.590
Lip vertical height noncleft	11.20 $\pm$ 2.29	11.71 $\pm$ 2.40	0.51	0.634
Lip horizontal length cleft	16.81 $\pm$ 2.87	17.31 $\pm$ 2.97	0.5	0.709
Lip horizontal length noncleft	17.28 $\pm$ 2.89	18.85 $\pm$ 2.88	1.57	0.664
Peak cupid's bow to midpoint cleft	5.05 $\pm$ 1.24	5.89 $\pm$ 1.46	0.84	0.182
Peak cupid's bow to midpoint noncleft	3.90 $\pm$ 1.21	4.70 $\pm$ 1.37	0.8	0.185
Cupid's bow width	7.66 $\pm$ 1.58	7.74 $\pm$ 1.70	0.08	0.920
Lip width	33.25 $\pm$ 1.43	33.78 $\pm$ 1.49	0.53	0.423
Cupid's bow vermilion width cleft	7.46 $\pm$ 1.98	8.07 $\pm$ 2.05	0.61	0.508
Cupid's bow vermilion width noncleft	7.03 $\pm$ 1.68	7.39 $\pm$ 1.71	0.36	0.639
Midline columellar crease to cupid's bow cleft	10.06 $\pm$ 1.50	10.53 $\pm$ 1.66	0.47	0.522
Midline columellar crease to cupid's bow noncleft	10.13 $\pm$ 1.85	10.48 $\pm$ 1.96	0.35	0.687

Downloaded from https://journals.lww.com/prsgo by BNDMISPHKantZEqumTICIN4a4kLHEZ9astHs4XIM0H0yWCX1A-WNYQp/ICHD3I3D0004Rj/7V5FAC3V/C4/OA/VpDDe8KKGK/V0Ymy+78=on 03/29/2023

**Table 2. Intraobserver Statistical Analysis of the Three-dimensional Smartphone Scanner Measurements**

Variable	Observer 1		Observer 2	
	ICC	Cronbach $\alpha$	ICC	Cronbach $\alpha$
Lip vertical height cleft	0.936	0.978	0.979	0.993
Lip vertical height noncleft	0.928	0.975	0.900	0.990
Lip horizontal length cleft	0.992	0.997	0.996	0.996
Lip horizontal length noncleft	0.993	0.998	0.994	0.994
Peak cupid's bow to midpoint cleft	0.876	0.920	0.967	0.989
Peak cupid's bow to midpoint noncleft	0.916	0.970	0.839	0.940
Cupid's bow width	0.987	0.939	0.996	0.979
Lip width	0.961	0.987	0.969	0.990
Cupid's bow vermilion width cleft	0.986	0.995	0.976	0.992
Cupid's bow vermilion width noncleft	0.978	0.992	0.964	0.988
Midline columellar crease to cupid's bow cleft	0.985	0.995	0.987	0.995
Midline columellar crease to cupid's bow noncleft	0.988	0.996	0.982	0.994

**Table 3. Interobserver Statistical Analysis of the Three-dimensional Smartphone Scanner Measurements**

Variable	Cronbach $\alpha$	Interclass Correlation Coefficient
Lip vertical height cleft	0.989	0.940
Lip vertical height noncleft	0.995	0.973
Lip horizontal length cleft	0.997	0.981
Lip horizontal length noncleft	0.995	0.972
Peak cupid's bow to midpoint cleft	0.977	0.878
Peak cupid's bow to midpoint cleft noncleft	0.977	0.876
Cupid's bow width	0.975	0.951
Lip width	0.960	0.922
Cupid's bow vermilion width cleft	0.997	0.980
Cupid's bow vermilion width noncleft	0.992	0.954
Midline columellar crease to cupid bow cleft	0.987	0.926
Midline columellar crease to cupid bow noncleft	0.994	0.963

is the gold standard,<sup>4</sup> but it requires patient experience and cooperation.<sup>6</sup> Digital imaging helps understand the mathematical symmetry and architecture of the lips. Linear measurements of the lip height and width are used to assess symmetry. Aesthetic improvements are objectively evaluated by comparing the proportions of unoperated and operated lips.<sup>7</sup> Conventional photography is prone to errors, and direct anthropometry is impractical for daily use.<sup>8</sup> Djohansjah Cleft Lip surgical method was applied without measurement preoperatively. It trained plastic surgical residents to be more meticulous in creating symmetrical lips between cleft and noncleft.<sup>3</sup>

Smartphones have been applied to plastic surgery for improved communication, ease of data collection and storage, education, and postoperative monitoring.<sup>9</sup> Currently, the most popular smartphone operating systems are iOS, by Apple, and Android, which is open source. Modern smartphones, such as iPhones, are equipped with high-resolution cameras, which can record images and videos of the user's face. In iPhone generation X, Apple was the first to introduce a 3D scanner. The scanner, which uses a patented scanning method involving structured light called, the True Depth System, is used for 3D face authentication and recognition by the Face ID system. This involves exact registration of facial data captured from 30,000 points, which are recorded via infrared

camera with a refresh rate of 60 Hz and processed by the neural engine of the smartphone chip. Apple itself does not specify the accuracy of the relevant technologies or hardware.<sup>10</sup>

The 3D scanning technology has evolved to be inexpensive, accurate, and easy to use. 3D face scanning has wide applications in medicine and dentistry, and also in capturing facial emotions.<sup>11</sup> Mobile applications provide better accuracy in scanning results. Numerous 3D scanning applications are available online, for example, on the Apple store. Mobile applications improve the performance and scanning results of smartphones.<sup>12,13</sup> Scandy Pro provides images closest to the real face in terms of similarity. It is also better in process performance and smoothness. Scandy Pro requires 35 seconds to complete facial scanning and processing. It offers one free scan per day and paid memberships at 1.99 Euros weekly, 5.99 Euros monthly, and 49.99 Euros annually.<sup>12,13</sup> Dzelzalēja et al assessed four mobile apps for 3D face scanning and showed, based on visual evaluation, that the most accurate 3D models for human faces were developed by Scandy Pro. The other applications such as Heges 3D scanner, Bellus 3D Face Application, 3D Scan Anything, Tmio 3D Scanner, and 3D Scanner Pro had given inferior results when applied on human male and female models.<sup>12,13</sup>

In our current study, we observed a mean difference of 0.35–1.57 mm when compared with direct anthropometry.



In another study, the accuracy using an iPhone as a three-dimensional scanner has been published by Rudy et al.<sup>14</sup> The iPhone was found to be accurate and precise to within 0.5 mm when compared with a commonly used, validated, and expensive three-dimensional Canfield Vectra H1 camera.<sup>14</sup> Knoops et al investigated the precision of the Structure Sensor (Occipital Inc, Boulder, Colo.) and M4D Scanner (Rodin 4D, Merignac, France) and reported root mean square errors of  $0.5 \pm 0.04$  mm and  $0.51 \pm 0.03$  mm.<sup>15</sup>

The learning process of 3D point tracing and experience in recognizing 3D landmarks are essential benchmarks in ensuring the accuracy and precision of 3D measurements.<sup>16</sup> The results of the 3D scanning measurements are user-dependent, in line with those of previously reported studies that involved anthropometric measurements using stereophotogrammetric devices. Furthermore, expensive devices rely on manual marking protocols in measurement software, and their use requires extensive training.<sup>17</sup> Tse et al used three raters to perform indirect anthropometry in 26 consecutive patients with unrepaired unilateral cleft lip ± palate. This study tested the reliability of nasolabial anthropometric measurements using three-dimensional stereophotogrammetry. The mean differences for nose and lip measurements were less than 1 mm and between 0.8 mm and 1.3 mm<sup>18</sup>; these values were similar to those obtained in our study.

The 3D scanning data obtained using smartphones are an alternative to routine documentation in patients with a preoperative cleft lip. The data are helpful for surgical planning and teaching reconstruction and animation for trainee plastic surgeons on the proviso that routine measurements are undertaken before and after surgery for proper evaluation.

The 3D scanning anthropometry method used in this study reduces both patient–doctor contact during the pandemic and a child’s procedural fear, owing to noncontact with calipers. The application and software used in this study are accessible, user-friendly, and recommended for lower- and middle-income countries, such as Indonesia. No such study in patients with unilateral cleft lip has been reported during the COVID-19 pandemic. Our study indicates that the 3D smartphone single-center scanner is a welcomed technology with potential in medical quantitative analysis.

This study was limited by its small sample and design. Further multicenter studies with larger samples are warranted in the future. The study results are limited to the data on postoperative results because of our surgical method, which does not use any preoperative measurements. The number of observers was limited by rule of minimal contact between patient and physician, which was caused by the COVID-19 pandemic. The 3D smartphone scanner technology can be applied in other cases of craniofacial surgery, such as hemifacial microsomia, Parry-Romberg syndrome, and facial cleft. Measurements can be elaborated further to include linear and volumetric measurements.

The 3D smartphone scanner can perform anthropometric measurements in patients with cleft lip accurately. It is more effective, efficient, and economical;

faster; and easier to apply than 2D measurement systems. Volumetric measurement is another approach that can be used besides linear measurement to perform a more accurate analysis of facial anatomy in the preoperative or postoperative settings. 3D smartphone scanning can also be applied to other craniofacial abnormalities where measurements are required, such as hemifacial microsomia and facial cleft. Mobile applications such as Scandy Pro require practice and skill to obtain the best results.

## CONCLUSIONS

The 3D smartphone scanner is accurate and precise. It can be applied in patients with unilateral cleft lip and other conditions that require quantitative analysis. Our study revealed that the 3D smartphone scanner is efficient, cost-effective, and suitable for facial measurement during the COVID-19 pandemic. The 3D smartphone scanner shows potential for application in medical quantitative analysis.

**Kartika Puspa Sari, MD**

8 Plastic, Reconstructive and Aesthetic Surgery  
Dr. Soetomo General Hospital Affiliated Faculty of Medicine  
– Airlangga University  
Jl. Mayjen. Prof. Dr. Moestopo no. 6-8  
Surabaya, 60131 East Java  
Indonesia  
E-mail: dr.kartikapuspasari@gmail.com

**Lynda Hariani, MD, PhD**

8 Plastic, Reconstructive and Aesthetic Surgery  
Dr. Soetomo General Hospital Affiliated Faculty of Medicine  
– Airlangga University  
Jl. Mayjen. Prof. Dr. Moestopo no. 6-8  
Surabaya, 60131 East Java  
Indonesia  
Email: lynda.hariani@fk.unair.ac.id

## ACKNOWLEDGMENTS

We thank Prof Djohansjah Marzoeqi, MD, PhD and Lobredia Zarasade, MD, PhD for their unwavering support. We also thank the Surabaya Cleft Lip Palate Center, Indonesia.

## PATIENT CONSENT

The patients (or parents or guardians of patients) provided written consent for the use of their images.

## REFERENCES

1. Sjamsudin E, Maifara D. Epidemiology and characteristics of cleft lip and palate and the influence of consanguinity and socioeconomic in West Java, Indonesia: a five-year retrospective study. *Int J Oral Maxillofac Surg*. 2017;46:69.
2. National Guidelines Management of Cleft Lip and Palate. 2019. Decision Indonesia Ministry of Health No. HK.01.07/Menkes/321/2019.
3. Marzoeqi D, Jailani Muhammad, Perdanakusuma D. Surgical technique of cleft lip and palate [Teknik Pembedahan Celah Bibir Dan Langit-Langit]. Sagung Seto; 1987.
4. Vyas RM, Warren SM. Unilateral cleft lip repair. *Clin Plast Surg*. 2014;41:165–177.

5. Li G, Wei J, Wang X, et al. Three-dimensional facial anthropometry of unilateral cleft lip infants with a structured light scanning system. *J Plast Reconstr Aesthet Surg.* 2013a;66:1109–1116.
6. Sitzman TJ, Marcus JR. Cleft lip and palate: current surgical management. *Clin Plast Surg.* 2014;41:xi–xii.
7. Ramanathan M, Dadwal H, Anantanarayanan P, et al. Comparative aesthetic evaluation of lip reconstruction using Abbe's flap in secondary cleft lip deformities: a retrospective study. *J Maxillofac Oral Surg.* 2021;20:13–18.
8. Wu J, Liang S, Shapiro L, et al. Measuring symmetry in children with cleft lip. Part 2: quantification of nasolabial symmetry before and after cleft lip repair. *Cleft Palate Craniofac J.* 2016;53:705–713.
9. Boissin C, Fleming J, Wallis L, et al. Can we trust the use of smartphone cameras in clinical practice? Laypeople assessment of their image quality. *Telemed E-Health.* 2015;21:887–892.
10. Vogt M, Rips A, Emmelmann C. Comparison of iPad Pro's LiDAR and TrueDepth capabilities with an industrial 3D scanning solution. *Technologies.* 2021;9:25.
11. Taeger J, Bischoff S, Hagen R, et al. Utilization of smartphone depth mapping cameras for app-based grading of facial movement disorders: development and feasibility study. *JMIR MHealth UHealth.* 2021;9:e19346.
12. Dzelzkalēja L, Knēts JK, Rozenovskis N, et al. Mobile apps for 3D face scanning. 2022:34–50.
13. Arai K. Intelligent systems and applications. Vol 295. *Lecture Notes in Networks and Systems.* Springer International Publishing.
14. Rudy HL, Wake N, Yee J, et al. Three-dimensional facial scanning at the fingertips of patients and surgeons: accuracy and precision testing of iPhone X three-dimensional scanner. *Plast Reconstr Surg.* 2020;146:1407–1417.
15. Knoops PGM, Beaumont CAA, Borghi A, et al. Comparison of three-dimensional scanner systems for craniomaxillofacial imaging. *J Plast Reconstr Aesthet Surg.* 2017;70:441–449.
16. Baysal A, Sahan AO, Ozturk MA, et al. Reproducibility and reliability of three-dimensional soft tissue landmark identification using three-dimensional stereophotogrammetry. *Angle Orthod.* 2016;86:1004–1009.
17. Petrides G, Clark JR, Low H, et al. Three-dimensional scanners for soft-tissue facial assessment in clinical practice. *J Plast Reconstr Aesthet Surg.* 2021;74:605–614.
18. Tse R, Booth L, Keys K, et al. Reliability of nasolabial anthropometric measures using three-dimensional stereophotogrammetry in infants with unrepaired unilateral cleft lip. *Plast Reconstr Surg.* 2014;133:530e–542e.



# Use of a Three-dimensional Smartphone Scanner in

## ORIGINALITY REPORT

17%

SIMILARITY INDEX

11%

INTERNET SOURCES

15%

PUBLICATIONS

0%

STUDENT PAPERS

## PRIMARY SOURCES

1

[www.lib.kobe-u.ac.jp](http://www.lib.kobe-u.ac.jp)

Internet Source

2%

2

Mats Kirkeby Fjeld, Anders Pedersen Årnes, Bo Engdahl, Bente Morseth et al. "Consistent pattern between physical activity measures and chronic pain levels: the Tromsø Study 2015-2016.", *Pain*, 2022

Publication

2%

3

[www.science.gov](http://www.science.gov)

Internet Source

1%

4

Hayeem L. Rudy, Nicole Wake, Judy Yee, Evan S. Garfein, Oren M. Tepper. "Three-Dimensional Facial Scanning at the Fingertips of Patients and Surgeons: Accuracy and Precision Testing of iPhone X Three-Dimensional Scanner", *Plastic & Reconstructive Surgery*, 2020

Publication

1%

5

[rcastoragev2.blob.core.windows.net](http://rcastoragev2.blob.core.windows.net)

Internet Source

1%

6	Laura Dzelzkalēja, Jēkabs Kārlis Knēts, Normens Rozenovskis, Armands Stīlītis. "Chapter 4 Mobile Apps for 3D Face Scanning", Springer Science and Business Media LLC, 2022 Publication	1 %
7	<a href="http://www.3dmd.com">www.3dmd.com</a> Internet Source	1 %
8	<a href="http://www.inabj.org">www.inabj.org</a> Internet Source	1 %
9	"Cleft Lip and Palate Treatment", Springer Science and Business Media LLC, 2018 Publication	1 %
10	"Cleft and Craniofacial Orthodontics", Wiley, 2023 Publication	1 %
11	Raymond Tse, Samuel Lien. "Unilateral Cleft Lip Repair Using the Anatomical Subunit Approximation", Plastic and Reconstructive Surgery, 2015 Publication	1 %
12	<a href="http://www.ingentaconnect.com">www.ingentaconnect.com</a> Internet Source	<1 %
13	Robert Massof. "Likert and Guttman scaling of visual function rating scale questionnaires", Ophthalmic Epidemiology, 2009 Publication	<1 %

14	<a href="http://www.ijcep.com">www.ijcep.com</a> Internet Source	<1 %
15	<a href="http://www.sid.ir">www.sid.ir</a> Internet Source	<1 %
16	Frederick J. Menick, Arthur Salibian. "Microvascular Repair of Heminasal, Subtotal, and Total Nasal Defects with a Folded Radial Forearm Flap and a Full-Thickness Forehead Flap", Plastic and Reconstructive Surgery, 2011 Publication	<1 %
17	<a href="http://www.researchgate.net">www.researchgate.net</a> Internet Source	<1 %
18	<a href="http://www.thejcn.com">www.thejcn.com</a> Internet Source	<1 %
19	"XV Mediterranean Conference on Medical and Biological Engineering and Computing – MEDICON 2019", Springer Science and Business Media LLC, 2020 Publication	<1 %
20	Rejani Chandran, Rajeev K Singh, Achal Singh, Kantharajan Ganesan et al. "Evaluating the influence of environmental variables on the length-weight relationship and prediction modelling in flathead grey mullet, Linnaeus, 1758 ", PeerJ, 2023 Publication	<1 %



21 [www.mdpi.com](http://www.mdpi.com) Internet Source <1 %

---

22 [link.springer.com](http://link.springer.com) Internet Source <1 %

---

23 Siti A. Othman, Lyddia Saffai, Wan N. Wan Hassan. "Validity and reproducibility of the 3D VECTRA photogrammetric surface imaging system for the maxillofacial anthropometric measurement on cleft patients", Clinical Oral Investigations, 2019  
Publication <1 %

---

24 Kyung S. Koh. "Modified Design of Cupid's Bow in the Repair of Unilateral Microform Cleft Lip", Journal of Craniofacial Surgery, 09/2009  
Publication <1 %

---

25 Manikandhan Ramanathan, Himani Dadwal, P. Anantanarayanan, Senthil Murugan, Hermann Sailer. "Comparative Aesthetic Evaluation of Lip Reconstruction Using Abbe's Flap in Secondary Cleft Lip Deformities: A Retrospective Study", Journal of Maxillofacial and Oral Surgery, 2019  
Publication <1 %

---

26 [mhealth.jmir.org](http://mhealth.jmir.org) Internet Source <1 %

---

[turkjorthod.org](http://turkjorthod.org)

27

Internet Source

<1 %

28

N. Naga Prasad. "Lip-Nose Complex Anthropometry", International Journal of Cosmetic Surgery and Aesthetic Dermatology, 09/2002

Publication

<1 %

29

Raymond Tse, Lindsay Booth, Kari Keys, Babette Saltzman, Erik Stuhaug, Hitesh Kapadia, Carrie Heike. "Reliability of Nasolabial Anthropometric Measures Using Three-Dimensional Stereophotogrammetry in Infants with Unrepaired Unilateral Cleft Lip", Plastic and Reconstructive Surgery, 2014

Publication

<1 %

30

Romero, R.. "The Millard rotation-advancement lip repair using accurate measurements", Oral Surgery, Oral Medicine, Oral Pathology, Oral Radiology and Endodontology, 199710

Publication

<1 %

Exclude quotes On

Exclude matches Off

Exclude bibliography On

# Use of a Three-dimensional Smartphone Scanner in

GRADEMARK REPORT

FINAL GRADE

**/100**

GENERAL COMMENTS

**Instructor**

PAGE 1

PAGE 2

PAGE 3

PAGE 4

PAGE 5

PAGE 6

PAGE 7