

Expression of NF- κ B and MMP-7 on Defenses of the Gingival Epithelium Injected LPS Porphyromonas Gingivalis with the Administration of Curcumin

by Eka Fitria Augustina

Submission date: 04-Apr-2023 09:46AM (UTC+0800)

Submission ID: 2055170226

File name: 17-D18_570_Eka_Fitria_A_JIDMR_2019.pdf (568.46K)

Word count: 3652

Character count: 20256

Expression of NF- κ B and MMP-7 on Defenses of the Gingival Epithelium Injected LPS Porphyromonas Gingivalis with the Administration of Curcumin

Eka Fitria Augustina^{1*}, I Ketut Sudiana², Soetjipto³, Muhammad Rubianto¹

1. Department Periodontics, Faculty of Dental Medicine, Universitas Airlangga, Surabaya, Indonesia.
2. Department of Electron Microscopy, Faculty of Medicine, Universitas Airlangga, Surabaya Indonesia.
3. Department of Medical Biochemistry, Faculty of Medicine, Universitas Airlangga, Surabaya Indonesia.

Abstract

Epithelial cells in the gingiva epithelium are among the first host cells encountered by periodontal pathogens such as Porphyromonas gingivalis. The lipopolysaccharide (LPS) of P. gingivalis is a crucial virulence factor critically involved in the regulation of immune inflammatory responses. Early prevention is necessary for the onset of periodontitis, especially in tissues that have been exposed to gingivitis by maintaining the primary defenses of the gingival epithelium. One of the effective and efficient efforts by utilizing the plant nutritious plant extracts curcumin. Curcumin is a medicinal plant material that has anti-inflammatory properties, as a factor inhibiting transcription factor NF- κ B. Barriers to NF- κ B are expected to decrease the expression of pro-inflammatory mediators that play a role in defective gingival epithelial defenses in cases of gingivitis. It is therefore suspected that inflammatory mediators associated with periodontitis, NF- κ B and MMP-7 also play an important role in the mechanism of damage to the gingival epithelial defect which may result in the breakdown of deeper periodontal tissue.

The aim of the study is to determine the role of NF- κ B and MMP-7 in the defense of the gingival epithelium in intervention by LPS Porphyromonas gingivalis by administering curcumin. Materials and methods: 40 wistar rats, aged 2-3 months divided into control and treatment group. which got 5 heads for each group. Animal production of gingivitis, performed by induction of LPS P.gingivalis is injected into the gingival sulcus of the mandibular incisor proximal portion and since 48 hours from injection of LPS P gingivalis done giving kurkumin. Days 1, 7, and 14, wistar is sacrificed according to the group and gingival epithelial tissue is taken for immunohistochemical examination procedure to determine expressions of NFK β and MMP-7.

The results showed that administration of curcumin in wistar rats after induction with LPS P. gingivalis decreased NF- κ B and MMP-7 expression. Decreased expression of inflammatory mediators can keep the gingival epithelial defenses.

Experimental article (J Int Dent Med Res 2019; 12(3): 941-946)

Keywords: Gingiva epithelium, LPS, Porphyromonas gingivalis, NF-Kb, MMP-7.

Received date: 07 February 2018

Accept date: 15 November 2018

Introduction

Inflammatory disease in periodontal tissue (periodontitis) is still a problem in many developing countries including in Indonesia due to its very high prevalence. Periodontitis is irreversible, so if treatment not optimal, most patients have the potential for lifelong disruption.¹

Periodontitis begins with the onset of gingivitis, which is clinically visible features of inflammation of the gingiva, redness, the presence of gingival enlargement and bleeding (bledding on probing) and does not cause attachment loss.² Proper treatment of gingivitis, can prevent the occurrence of periodontitis. Therefore, an effective prevention of the progression of periodontitis is more important than treating it because of the irreversible nature of periodontitis and has a broad impact of exudate and reversible when etiologic factors are removed.³ Periodontal tissues that have been damaged, difficult to regenerate, even tend to be irreversible. It is therefore necessary early prevention of the onset of periodontitis, especially in tissues that have been exposed to gingivitis by

*Corresponding author:

Eka Fitria Augustina
Department Periodontics,
Faculty of Dental Medicine, Universitas Airlangga,
Surabaya, Indonesia.
E-mail: efitria003@gmail.com

maintaining the primary defenses of the gingival epithelium.

Various efforts have been made in the treatment of periodontitis, among others by the use of local or systemic antibiotics, periodontal surgery, but the results are still less satisfactory. One of the effective and efficient efforts by utilizing the plant nutritious plant extracts. One of the plant extract is efficacious as a drug that is turmeric (*Curcuma longa*). The main active ingredient of turmeric is curcuminoid. The main content of curcuminoid from turmeric is curcumin, which is the most active ingredient.⁴ Various studies have shown that curcumin has antioxidant, anti-inflammatory, and anti-cancer properties.^{5,6} The role of 1% curcumin as subgingival irrigation can lead to a decrease in gingival inflammation with bleeding on probing indicators.⁷

The fact that prevalence periodontitis in remains high, the ideal strategy for reducing its prevalence is with prevention. In theory, the defect of gingival epithelial occurs due to invasion of bacteria, causing inflammation, so one of the prevention efforts by giving anti-inflammation, one of the alternatives is the plant nutritious plant extract. Curcumin is a medicinal plant material that has anti-inflammatory properties, as a factor inhibiting transcription factor for NF- κ B.⁴ Barriers to NF- κ B are expected to decrease the expression of pro-inflammatory mediators that contribute to damage to the gingival epithelial defenses in cases of gingivitis. With efforts to prevent the occurrence of periodontitis in cases of gingivitis, it is expected cases of periodontitis decreased more, and cases of gingivitis can become a reversible healthy. This thought arises because the defective process of gingival epithelial defenses occurs in the inflammatory process. It is therefore suspected that inflammatory mediators associated with periodontitis, NF- κ B and MMP-7 may also play an important role in the mechanism of damage to the gingival epithelial defect which may result in the breakdown of deeper periodontal tissues.

26 Materials and methods

This study was an experimental study in vivo using a 20-week-old white rats (*Rattus norvegicus*) male, weighing 325-350 grams, was obtained from the Biochemistry Laboratory of the

11
Faculty of Medicine, Airlangga University, Surabaya. The research design used is randomized control design. This study received ethical approval from The Ethical Committee of Dental Research Airlangga University 2017. Animals were divided into 4 groups: group K (n = 5) control group without treatment, sacrificed on the first day. Animal model gingivitis without treatment group K1 (n = 5) was sacrificed on the first day, group K2 (n = 5) was sacrificed on day 7, group K3 (n = 5) was sacrificed on day 14 and group K4 (n = 5) with the provision of corn oil as a curcumin carrier sacrificed on day 14. Animal model gingivitis with treatment of curcumin, group P1 (n = 5) sacrificed on the first day, group P2 (n = 5) sacrificed on day 7, group P3 (n = 5) was sacrificed on the 14th day. Curcumin is obtained from Tokyo Chemical Industry, purity is 95%. Preparation of 1% curcumin solution using curcumin in powder form which has been standardized and certified, using solvent corn oil as a carrier, curcumin powder weight 1 gram then dissolved in corn oil until 100 ml. Gingival epithelial tissue was taken for immunohistochemical procedures to determine the expression of NF- κ B and MMP-7.

Animal production of gingivitis, performed by induction of LPS *P. gingivalis*, injected into the gingival sulcus of the mandibular incisor proximal portion. Each experimental animal injected by LPS *P. gingivalis* with volume 10 μ l and concentration 1 mg/ml with syringe tuberculin 1 cc/ml (terumo) and needle 30 G (BD).^{8,9} Consecutive days and since 48 hours of injection of LPS *P. gingivalis*, curcumin is given.¹⁰ Curcumin active ingredients derived from turmeric rhizome (*Curcuma longa*) in the form of certified powder, from Tokyo Chemical Industry. Curcumin is made in concentrations of 1% in corn oil, administered 0.03 ml (30 μ l), twice daily for 2 weeks, topically on the gingival sulcus of the mandibular incisor proximal portion.

Immunohistochemical staining used in this study was for the examination of NF- κ B and MMP-7 expression from gingival tissues of the mandibular incisor. The primary antibodies NF- κ B were purchased from Santa Cruz Biotechnology (NF κ B p65 (F-6): sc-8008) and MMP-7 from Biossantibodies (bs-0423R-HRP). Histologic samples of the gingival epithelium performed immunohistochemical tests for NF- κ B and MMP-7. Statistical analyses were performed using SPSS software version 21. All data were

expressed as mean ± standard deviation (SD). Differences between experimental groups were analyzed with ANOVA. A p value < 0.05 was considered statistically significant.

Results

NF-κB and MMP-7 expression in response to LPS *P. gingivalis* stimulation and with the curcumin administration, determination by immunohistochemical examination procedured in gingival epithelial. Based on immunohistochemical examination, increased expression of NF-κB and MMP-7 after treatment of LPS *P. gingivalis*.

Immunohistochemical measurement of of NF-κB and MMP-7 showed the following results:

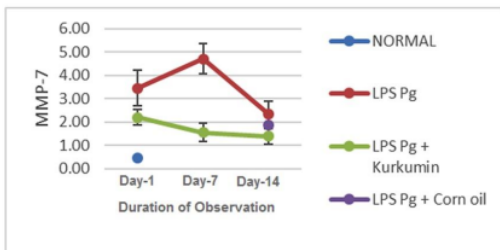


Figure 1. Increased MMP-7 Expression in LPS Pg Treatment Group on Day 1 and Day 7 Then Decreased at Day 14 (Red Line). Compared with the Gray Line Showing Decreased MMP-7 Expression in the LPS Pg + Curcumin Treatment Group on Days 1, 7 and 14. Blue Dots Showed MMP-7 Expression in the Control Group.

Furthermore, the results of ANOVA test comparing between group, both on NF-κB and MMP-7 expressions demonstrated $p < 0.05$ indicating that significant difference.

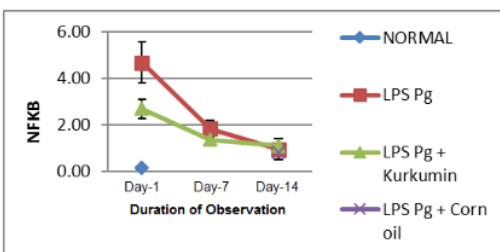


Figure 2. An Increase in NF-κB Expression in the LPS Pg Treatment Group (Red Line), Compared with Control Group (Blue Dot). Compared with Grey Line That Showed Decreased and Lower NF-κB Expression in the LPS Pg Treatment Group on Day 1, 7 and 14. The Blue Dot, Showed NF-κB Expression in the LPS Pg on Control Group.

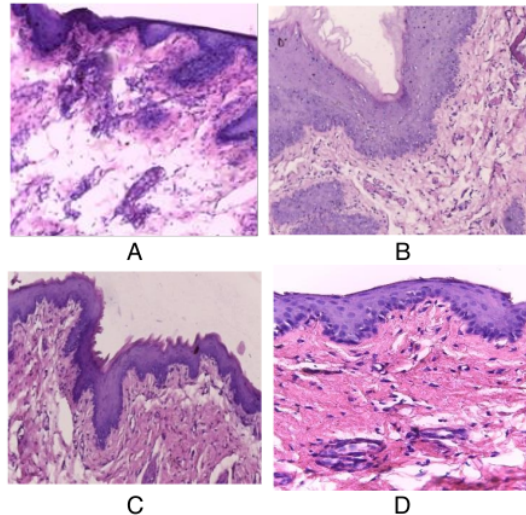
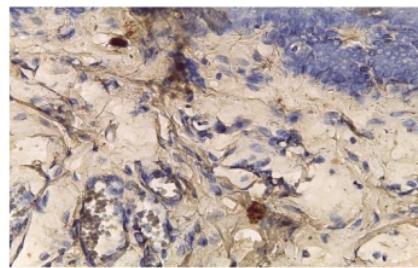
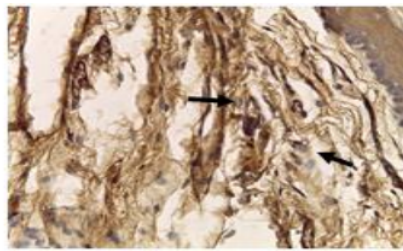


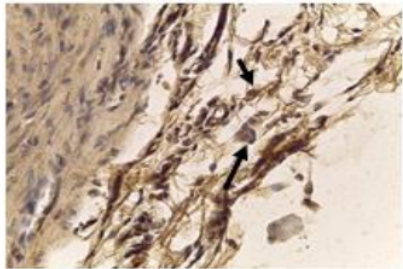
Figure 3. Histological Compared oo **A:** Normal Appearance in the Control Group (Original Magnification, × 400), Epithelial Cells and Few Inflammatory Cells **B:** Moderate Inflammation Histological Appearance in the LPS Pg Group. **C:** Severe Inflammation Histological Appearance in the LPS Pg Group. **D:** Mild Inflammation Histological Appearance in the LPS Pg Group Administered Curcumin.

Immunohistochemical staining MMP-7 in the gingiva epithelial after injection LPS *P. gingivalis* administered curcumin.

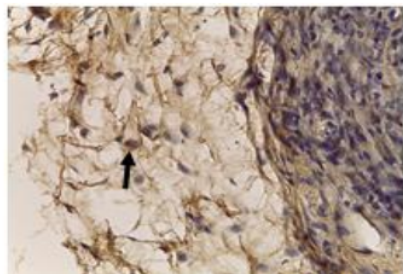




B



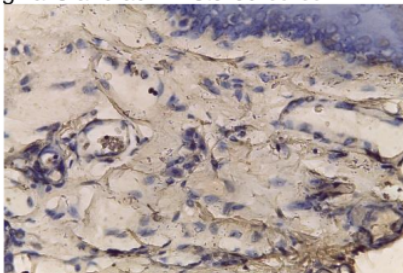
C



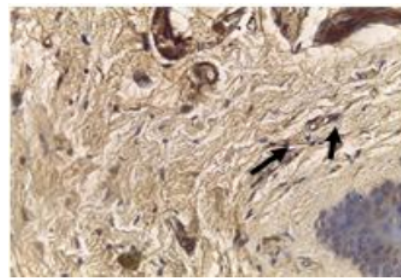
D

Figure 4. Immunohistochemical Staining MMP-7 in the Gingiva Epithelial After Injection LPS Pg Administered Curcumin. MMP-7 Expression in Control Group (A), in LPS Pg Group (B), in LPS Pg and Administered Curcumin (C), and in Corn Oil LPS Pg Group (D).

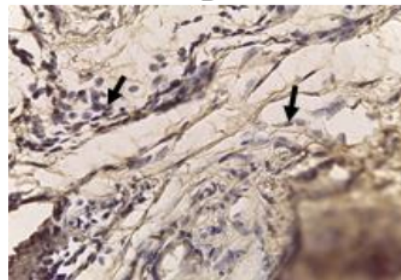
Immunohistochemical staining for NF- κ B in the gingiva epithelial after injection LPS *P. gingivalis* and administered curcumin



A



B



C



D

Figure 5. Immunohistochemical Staining NF- κ B in the Gingiva Epithelial After Injection LPS *P. gingivalis* Administered Curcumin. NF- κ B Expression in Control Group (A), in LPS Pg Group (B), in LPS Pg and Administered Curcumin (C), and in Corn Oil LPS Pg Group (D).

12 Discussion

In the present study, we analysed NF- κ B and MMP-7 expression in the gingiva epithelial of the anterior lower incisor after injection LPS *P. gingivalis*. *P. gingivalis* is an anaerobic gram-negative bacteria that is involved in the pathogenesis of periodontitis. Lipopolysaccharide from *P. gingivalis* is the key leading cause of periodontitis.¹¹ LPS is a bioactive component and can induce IL-1 and mononuclear cell immunoregulation in multiple doses of pg/ml.¹²

All of the animals in the positive (LPS Pg) group showed macroscopic signs of inflammation, which was confirmed by histological examination. These findings are consistent with those of the study by Dumitrescu *et al*, 2004.¹³ Several studies have used LPS to induce periodontal inflammation in rats.¹⁴ Topical application of LPS results in typical inflammatory changes such as junctional epithelial disruption, infiltration of leukocytes and oedema of the subepithelial connective tissue. We found that the expression of NF- κ B and MMP-7 in the positive (LPS Pg) group were higher than those in the negative group. We also found NF- κ B and MMP-7 levels in the LPS Pg group were higher than the treatment group of LPS Pg given curcumin. Similarly, Araghizadeh *et al*, found that the levels of IL-1 β and TNF- α in the positive control group were higher than those in the negative control group. Enrico G, *et al* reported increases in LTB4, PGE2, PGF2 α and PAF after LPS injection.¹⁵

LPS serves to integrate bacterial structures and protect bacteria from the system host immune defenses consisting of lipids A, O antigens and oligosaccharides bonded together is the main structure of gram-negative bacteria cell wall. Lipid A can trigger an inflammatory response. LPS is endotoxin because LPS binds to the CD14 receptor which is the cell surface receptor on macrophages or monocytes. LPS is able to activate the innate immune system to stimulate Toll-Like Receptor-4 (TLR4) which is a protein on surface cells that can recognize bacterial products.¹⁶

In periodontal disease the most important pathways include the mitogen activated protein kinase (MAPK) and janus tyrosine kinase-signal transducer and activator of transcription (JAK/STAT).¹⁷ NF- κ B was first identified as a transcription factor that binds to a 10 base pairs (bp) DNA element in kappa immunoglobulin light chain enhancer in B cells. The NF- κ B family of transcription factors has been shown to be involved in many different pathways and has a central role in regulating the expression of a wide variety of genes that control both innate and adaptive immune responses. NF- κ B under normal circumstances is found in inactive form in the cytoplasm as a p50/p65 heterodimer that binds to the I κ Ba inhibitor unit. Signals from pathogens will activate complex I κ Ba kinase so that I κ Ba is phosphorylated which subsequently undergoes ubiquitination and degrades sub unit

by proteasome. This results in increased transcription activity, so that NF- κ B expression also increases in the LPS *P. gingivalis* group. Activation of the NF- κ B pathway occurs in the presence of many pro inflammatory mediators present in large quantities in tissues with periodontal diseases such as bacterial LPS, TNF- α , IL-1, MMPs, COX-2 and inducible nitric oxide synthase (iNOS).¹⁸ In this study, MMP-7 expression also showed increased in LPS group. This suggests that there is a role of MMP-7 in the gingival epithelium that is inflamed by invading pathogenic bacteria. MMP-7 plays a role in the mucosal immune response and its expression increases rapidly in the attacked epithelium.¹⁹ This increase in MMP-7 expression can be caused by exposure to LPS *P. gingivalis* thus stimulating and activating NF- κ B. The activated NF- κ B then express MMP-7. The expression of NF- κ B and MMP-7 on gingival wistar rats exposed to LPS of *Pg* bacteria in group K without treatment was significantly different from LPS *P. gingivalis* group; K1, K2, K3, K4, and LPS *P. gingivalis* group administered curcumin; P1, P2 and P3. When viewed from the average in figure 1 and 2, control group has average NF- κ B and MMP-7 expression lower than LPS *P. gingivalis*. In the LPS *P. gingivalis* group showed higher NF- κ B and MMP-7 expression than LPS *P. gingivalis* group with curcumin administration.¹⁵

Curcumin has anti-inflammatory, antimicrobial, antiviral, anti-fungal, antioxidant and wound healing.²⁰ 1% curcumin as irrigant showed good results to reduce signs of gingival inflammation (BOP and redness) and improve healing by reducing the depth of residual pockets.²¹ Curcumin affects expression of NF- κ B and MMP-7 because curcumin inhibits the activation of NF- κ B induced by LPS *P. gingivalis*. Curcumin mainly gives its therapeutic effect by inhibiting the I κ Ba degradation and subsequently inactivate NF- κ B, thus initiating the cascade in inflammation and immunogenic.²² Curcumin inhibits the phosphorylation of inhibitor factor of I κ B kinase so that the NF- κ B translocation into the nucleus of the cell is inhibited, which further causes NF- κ B activity to decrease and the expression of proinflammatory cytokine also decreased.²³ Barriers to phosphorylation of inhibitor factor I κ B kinase in this cytoplasm may occur because curcumin is lipophilic in order to penetrate the cell membrane and reside in the

cytoplasm and nucleus.²⁴ NF- κ B activation also determines the activity of MMP-7, it means that when NF- κ B activation decreases due to the administration of curcumin, the transcription activity performed by NF- κ B to express the MMP-7 gene may also be delayed. In this study, administration of curcumin in wistar rat gingival epithel treated with LPS *P. gingivalis* decreased NF- κ B and MMP-7 expression. When NF- κ B expression as a transcription factor mediator of inflammation decreases feeding of MMP-7 expression as inflammatory mediator also decreases.

Conclusion

The present investigation showed that expression of MMP-7 and NF- κ B on the wistar rat gingival epithelium increased at induction with LPS *P. gingivalis*. This suggests that MMP-7 and NF- κ B play an important role in the inflammatory response of inflammatory processes in the gingiva due to invasion of pathogenic bacteria. Administration of curcumin decreased the expression of MMP-7 and NF- κ B in the wistar gingival epithelium.

Declaration of Interest

The authors report no conflict of interest and the article is not funded or supported by any research grant.

References

- Joshi D, Garg T, Goyal AK, Rath G. Advanced drug delivery approaches against periodontitis. *Drug Delivery*. 2016;23(2):363-77.
- Yeturu SK, Acharya S, Urala AS, Pentapati KC. Effect of Aloe vera, chlorine dioxide, and chlorhexidine mouth rinses on plaque and gingivitis : A randomized controlled trial. *J Oral Biol Craniofac Res*. 2015;182:1-5.
- Chapple ILC, Van der Weijden F, Doerfer C. Primary prevention of periodontitis: managing gingivitis. *J Clin Periodontol*. 2015;42 (Suppl.16):S71-S76.
- Akram M, Uddin S, Ahmed A, Usmanghani K, Hannan A, Mohiuddin E, Asif M. Curcuma longa and curcumin: A review article. *J Biol-Plant Biol*. 2010;55(2):65-70.
- Gottumukkala S, Koneru S, Mannem S, Mandalapu N. Effectiveness of sub gingival irrigation of an indigenous 1% curcumin solution on clinical and microbiological parameters in chronic periodontitis patients: A pilot randomized clinical trial. *Contemp Clin Dent*. 2013;4(2):186-91.
- Guimarães MR, Coimbra LS, Garcia de Aquino S, Spolidorio LC, Kirkwood KL, Rossa Junior C. Potent anti-inflammatory effects of systemically-administered curcumin modulates periodontal disease in vivo. *Periodont Res*. 2011;46(2):269-79.
- Suhag A, Dixit J, Dhan P. Role of Curcumin as a subgingival irrigant: a pilot study. *Quintessence J*. 2007;4(2):115-21.
- Taguchi H, Aono Y, Kawato T, Asano M, Shimizu N, Saigusa T. Intragingival injection of Porphyromonas gingivalis-derived lipopolysaccharide induces a transient increase in gingival tumour necrosis factor- α , but not interleukin-6, in anaesthetised rats. *Int J Oral Sci*. 2015;7:155-60.
- Araghizadeh N, Paknejad M, Alaeddini M, Minaii B, Abdollahi M, Khorasanie R. The efficacy and prophylactic characteristics of omega-3 fatty acids in experimental gingivitis in rats. *Iran J Basic Med Sci*. 2014;17:87-92.
- Chen Y, Wu ZF, and Yang LJ. Influence of Baicalin on Alveolar Bone Resorption in rat Experimental Periodontitis. *Sci Pharm*. 2008;76:689-98.
- Olsen I, Taubman MA, Singhrao SK. Porphyromonas gingivalis suppresses adaptive immunity in periodontitis, atherosclerosis, and Alzheimer's disease. *J Oral Microbiol*. 2016;8:1.33029. DOI:10.3402/jom.v8.33029.
- Dixon DR, Darveau RP. Lipopolysaccharide heterogeneity: innate host responses to bacterial modification of lipid A structure. *J Dent Res*. 2005;84(7):584-95.
- Dumitrescu AL, El-Aleem A. A model of periodontitis in the rat: effect of lipopolysaccharide on bone resorption, osteoclast activity, and local peptidergic innervation. *J Clin Periodontol*. 2004;31:596-603.
- Song B, Zhang Y, Chen L, Zhou T, Huang W, Zhou X, Shao L. The role of Toll-like receptors in periodontitis. *Oral Diseases*. 2016;23(2):168-80. DOI:10.1111/odi.12468.
- Enrico G, Roberta F, Ramona D, Angela M, Giacomo O, Wallace John L, Rosanna D, Salvatore C. Anti-inflammatory effect of ATB-352, a H2S releasing ketoprofen derivative, on lipopolysaccharide-induced periodontitis in rats. *Pharmacological Research*. 2017. <https://doi.org/10.1016/j.phrs.2017.12.022>.
- KØllgaard T, Enevold C, Bendtzen K, Hansen PR, Givskov M, Holmstrup P, et al. Cholesterol Crystals Enhance TLR2- And TLR4-mediated pro-inflammatory Cytokine responses of monocytes to the proatherogenic oral bacterium Porphyromonas Gingivalis. *PLoS ONE*. 2017;12(2):e0172773. DOI:10.1371/journal.pone.0172773.
- Mao C-y, Wang Y-g, Zhang X, Zheng X-y, Tang T-t, Lu E-y. Double-edged-sword effect of IL-1B on the osteogenesis of periodontal ligament stem cells via crosstalk between the NF- κ B, MAPK and BMP/Smad signaling pathways. *Cell Death and Disease*. 2016;7:e2296. DOI:10.1038/cddis.2016.204.
- Serasanambati M, Chilakapati SR. Function of Nuclear Factor kappa B(NF- κ B) in human diseases-A Review. *South Indian J Biological Sci*. 2016;2(4): 368-87.
- Gharib SA, Altemeir WA. Matrix Metalloproteinase-7 Coordinates Airway Epithelial Injury Response and Differentiation of Ciliated Cells. *Am J Respir Cell Mol Biol*. 2013; (48):iss.3:390-396.
- Kunnumakkara AB, Bordoloi D, Padmavathi G, Monisha J, Roy NK, Prasad N, Bharat B, Aggarwal. Curcumin, The Golden Nutraceutical: Multitargeting for Multiple Chronic Diseases. *Anti-Inflammation Research Institute*, San Diego, California, USA. 2016. DOI:10.1111/bph.13621.
- Sharma A, Ahlawat B, Sharma S. Turmeric Its Applications in Dentistry. *J Adv Res Med*. 2016; 3(1):27-30.
- Jagetia GC, Aggarwal BB, "Spicing up" of the immune system by curcumin. *J Clin Immunol*. 2007;(27):1:30.
- Xie YL, Chu JG, Jian X_M, Dong JZ, Wang LP, Li GX, Yang NB. Curcumin Attenuates lipopolysaccharide/ D - galactosamine-induced Acute Liver Injury By Activating Nrf2 Nuclear Translocation And Inhibiting NF- κ B activation. *Biomedic. Pharmacotherapy*. 2017;91(7):70-7.
- Minear S, O'Donnell AF, Ballew A, Giaever G, Nishow C. Curcumin inhibits growth of saccharomyces cerevisiae through iron chelation. *Eukaryotic cell*. 2011;11:1574-81.

Expression of NF-κB and MMP-7 on Defenses of the Gingival Epithelium Injected LPS Porphyromonas Gingivalis with the Administration of Curcumin

ORIGINALITY REPORT

18%

SIMILARITY INDEX

13%

INTERNET SOURCES

16%

PUBLICATIONS

0%

STUDENT PAPERS

PRIMARY SOURCES

1	recob-tlse.org Internet Source	2%
2	worldwidescience.org Internet Source	2%
3	www.jkimsu.com Internet Source	1%
4	bm Cresnotes.biomedcentral.com Internet Source	1%
5	www.tmj.ro Internet Source	1%
6	opendentistryjournal.com Internet Source	1%
7	repositorio.unesp.br Internet Source	1%
8	S. Yamamoto, T. Okuda, K. Yamasaki, H. Tanaka, S. Takemura, Y. Minamiyama, K. Ikeda, K. Hirohashi, S. Suehiro. "FK778	1%

controls acute rejection after rat liver allotransplantation showing positive interaction with FK506", Transplantation Proceedings, 2005

Publication

9

researchonline.jcu.edu.au

Internet Source

1 %

10

"Polyphenols-based Nanotherapeutics for Cancer Management", Springer Science and Business Media LLC, 2021

Publication

1 %

11

Nanik Zubaidah, Dian Dwi Pratiwi, Maria Margaretha S. Nogo Masa, Ernie Maduratna Setiawatie, Sri Kunarti. "The Osteogenesis Mechanisms of Dental Alveolar Bone Socket Post Induction with Hydroxyapatite Bovine Tooth Graft: An Animal Experimental in Rattus norvegicus Strain Wistar", European Journal of Dentistry, 2022

Publication

<1 %

12

Taguchi, Hiroko, Yuri Aono, Takayuki Kawato, Masatake Asano, Noriyoshi Shimizu, and Tadashi Saigusa. "Intragingival injection of Porphyromonas gingivalis-derived lipopolysaccharide induces a transient increase in gingival tumour necrosis factor- α , but not interleukin-6, in

<1 %

anaesthetised rats", International Journal of Oral Science, 2015.

Publication

13

Ajaikumar B. Kunnumakkara, Mangala Hegde, Dey Parama, Sosmitha Girisa et al. "Role of Turmeric and Curcumin in Prevention and Treatment of Chronic Diseases: Lessons Learned from Clinical Trials", ACS Pharmacology & Translational Science, 2023

Publication

<1 %

14

www.jimmunol.org

Internet Source

<1 %

15

Decote-Ricardo, D.. "Modulation of in vitro murine B-lymphocyte response by curcumin", Phytomedicine, 200910

Publication

<1 %

16

Yan-Feng Zou, Feng-Lai Yuan, Xiao-Liang Feng, Jin-Hui Tao, Ning Ding, Fa-Ming Pan, Fang Wang. "Association Between NFKB1 -94ins/delATTG Promoter Polymorphism and Cancer Risk: A Meta-Analysis", Cancer Investigation, 2010

Publication

<1 %

17

www.frontiersin.org

Internet Source

<1 %

18

H. Kumada. "Biological properties of the native and synthetic lipid A of Porphyromonas

<1 %

gingivalis lipopolysaccharide : Biological properties of P.gingivalis lipid A", Oral Microbiology and Immunology, 12/19/2007

Publication

19

patents.google.com

Internet Source

<1 %

20

www.thieme-connect.com

Internet Source

<1 %

21

Hao Feng, Ziyu Li, Juan Du, Jing Sun, Wei Feng, Dongfang Li, Shanshan Liu, Wei Wang, Hongrui Liu, Norio Amizuka, Minqi Li. "Dual function of peroxiredoxin I in lipopolysaccharide-induced osteoblast apoptosis via reactive oxygen species and the apoptosis signal-regulating kinase 1 signaling pathway", Cell Death Discovery, 2018

Publication

<1 %

22

Qing Tian, Guijie Wang, Yamin Zhang, Fubo Zhang, Long Yang, Zirong Liu, Zhongyang Shen. "Engeletin inhibits Lipopolysaccharide/d-galactosamine-induced liver injury in mice through activating PPAR-γ", Journal of Pharmacological Sciences, 2019

Publication

<1 %

23

Ru Jin, Xiaoqiao Ning, Xiang Liu, Yueyang Zhao, Guo Ye. "Porphyromonas gingivalis-induced periodontitis could contribute to cognitive impairment in Sprague–Dawley rats

<1 %

via the P38 MAPK signaling pathway",
Frontiers in Cellular Neuroscience, 2023

Publication

24

[bmccomplementmedtherapies.biomedcentral.com](https://www.bmccomplementmedtherapies.biomedcentral.com)

Internet Source

<1 %

25

[mdpi-res.com](https://www.mdpi-res.com)

Internet Source

<1 %

26

repository.stikim.ac.id

Internet Source

<1 %

27

www.veterinaryworld.org

Internet Source

<1 %

28

"Studies on Biomarkers and New Targets in
Aging Research in Iran", Springer Science and
Business Media LLC, 2021

Publication

<1 %

29

Chae Hyeong Lee, Yong-Tark Jeon, Su-Hyeong
Kim, Yong-Sang Song. "NF- κ B as a potential
molecular target for cancer therapy",
BioFactors, 2007

Publication

<1 %

30

"Handbook of Famine, Starvation, and
Nutrient Deprivation", Springer Nature, 2019

Publication

<1 %

31

M. K. Chan, K. W. Chan, W. L. Ng.
"Amelioration of Gentamicin Nephrotoxicity

<1 %

by Phospholipids", Nephrology Dialysis
Transplantation, 1991

Publication

32

Mark Nomden, Leonie Beljaars, Henkjan J. Verkade, Jan B. F. Hulscher, Peter Olinga. "Current Concepts of Biliary Atresia and Matrix Metalloproteinase-7: A Review of Literature", Frontiers in Medicine, 2020

Publication

<1 %

33

Marwan Almoiliqy, Jin Wen, Bin Xu, Yu-chao Sun et al. "Cinnamaldehyde protects against rat intestinal ischemia/reperfusion injuries by synergistic inhibition of NF-κB and p53", Acta Pharmacologica Sinica, 2020

Publication

<1 %

Exclude quotes Off

Exclude matches Off

Exclude bibliography On

Expression of NF- κ B and MMP-7 on Defenses of the Gingival Epithelium Injected LPS Porphyromonas Gingivalis with the Administration of Curcumin

GRADEMARK REPORT

FINAL GRADE

/0

GENERAL COMMENTS

Instructor

PAGE 1

PAGE 2

PAGE 3

PAGE 4

PAGE 5

PAGE 6
